

Fall 3

Fall 3

71-årig Man.

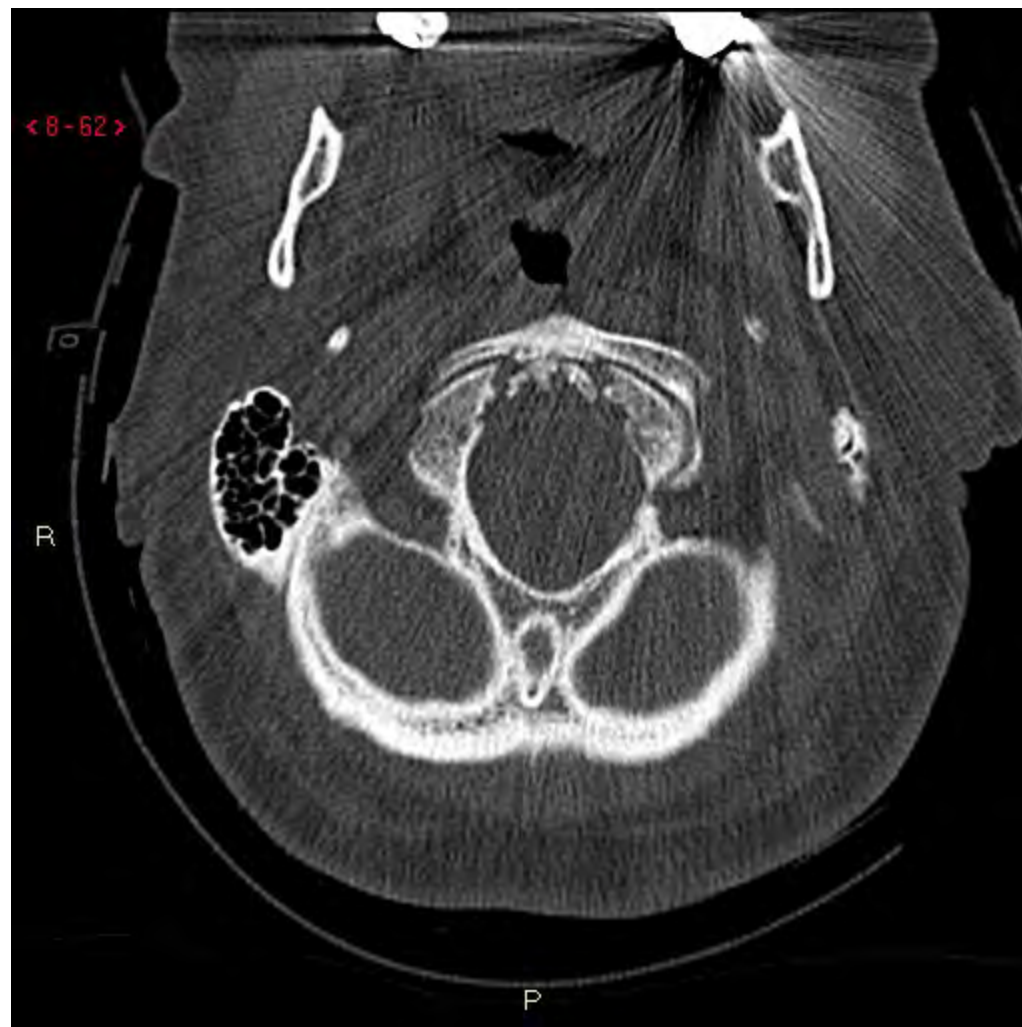Voltat med bil 90km/h. Minneslucka. Ont i nacken.

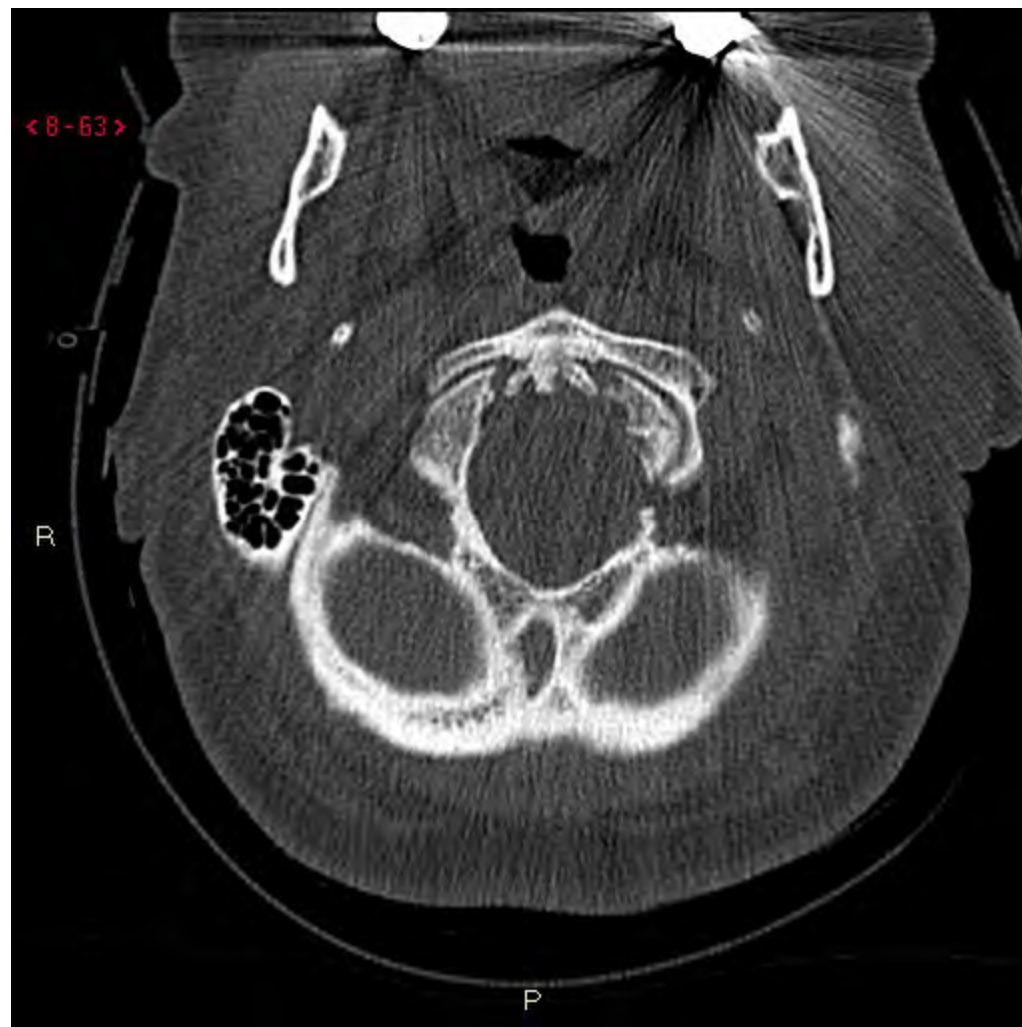Högt BT, över 200 systoliskt.

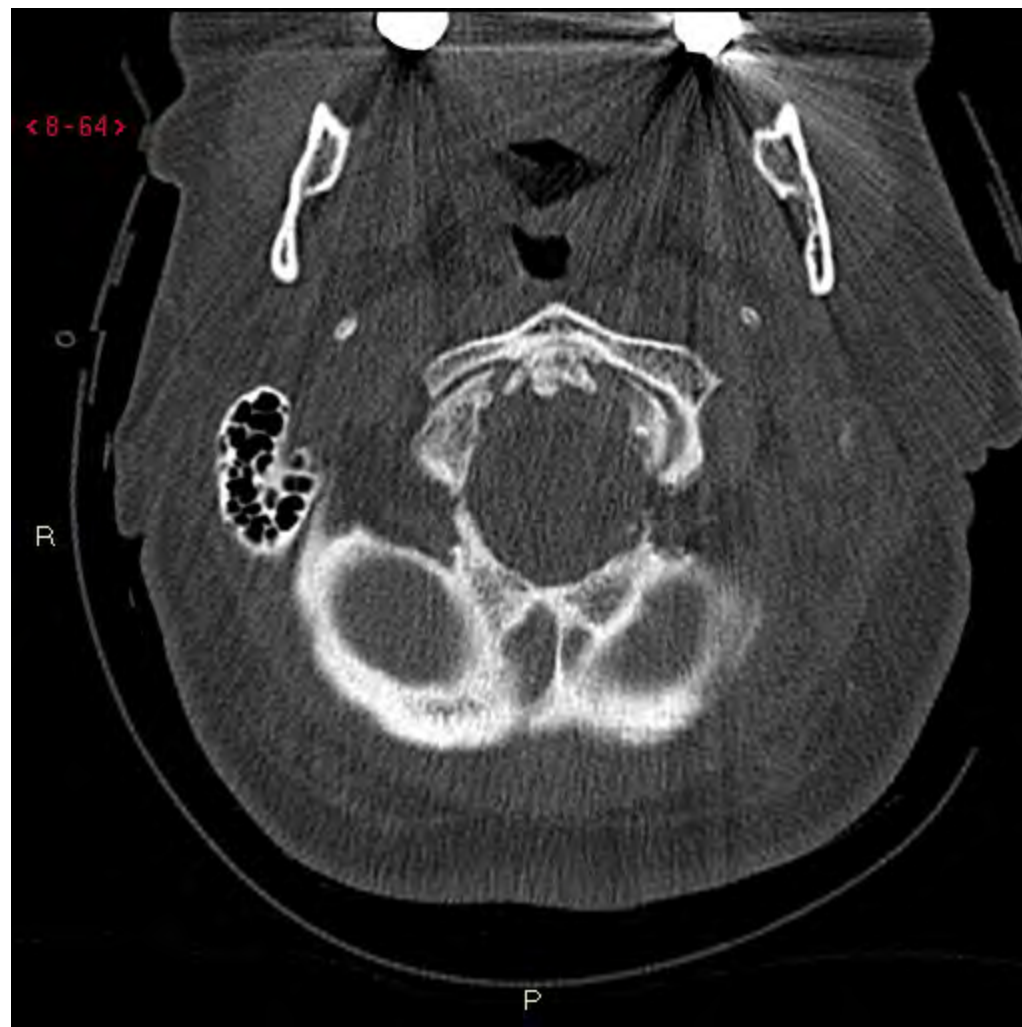Fall 3

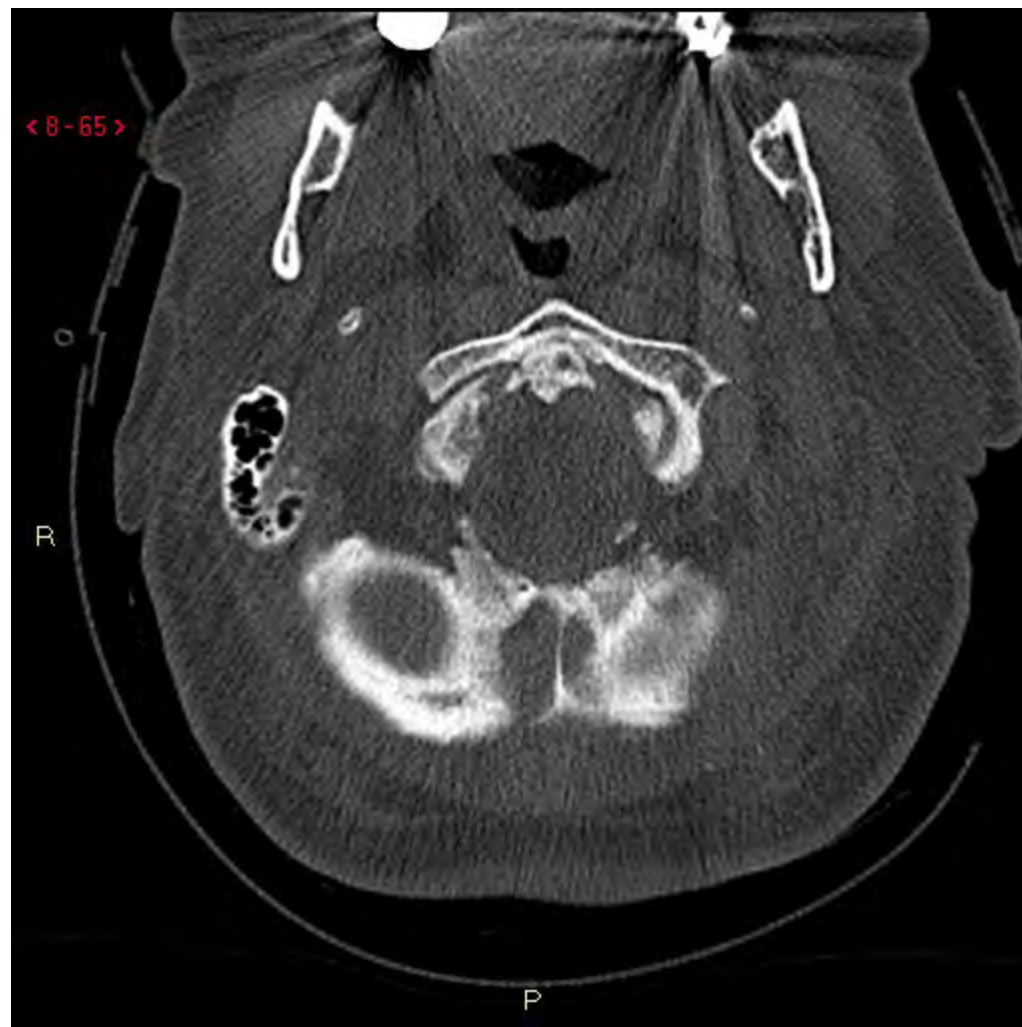1:a us, DT Hjärna: 0 fynd.

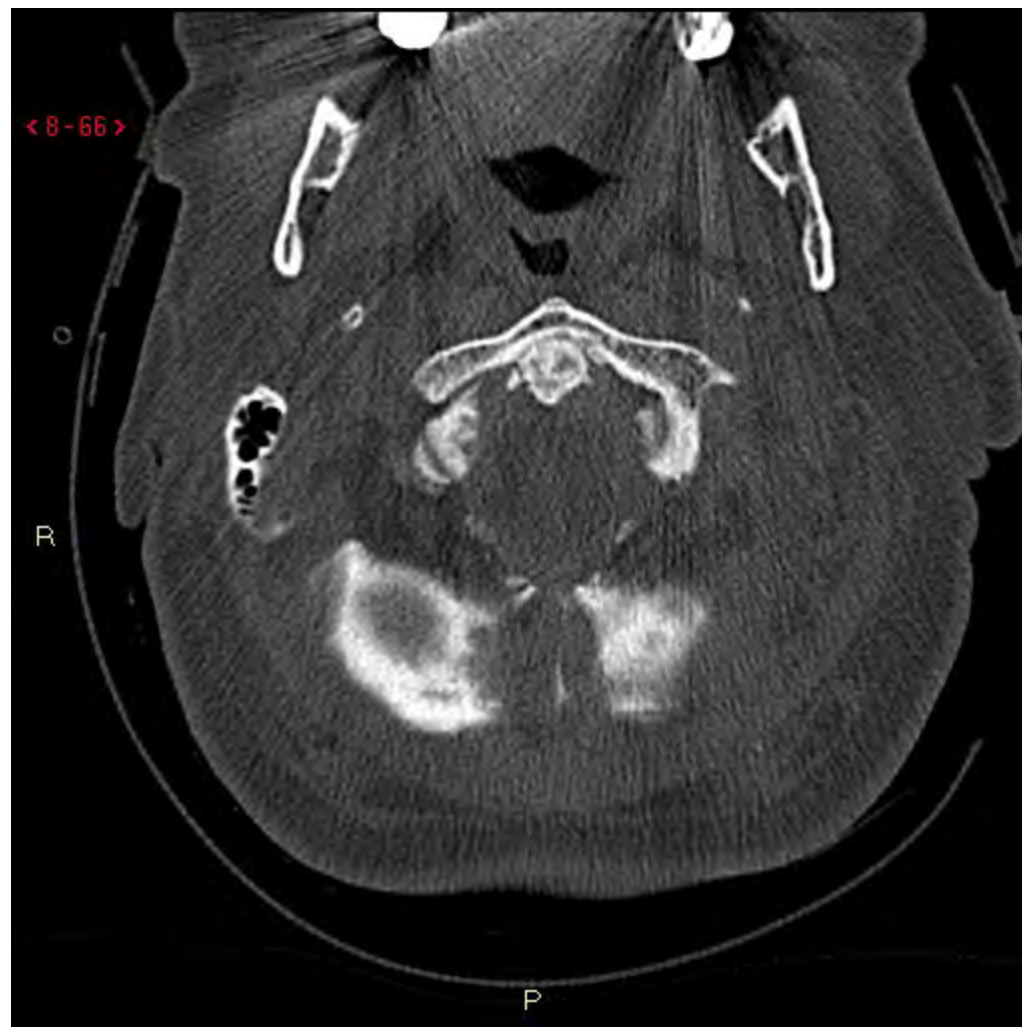DT Halsrygg:

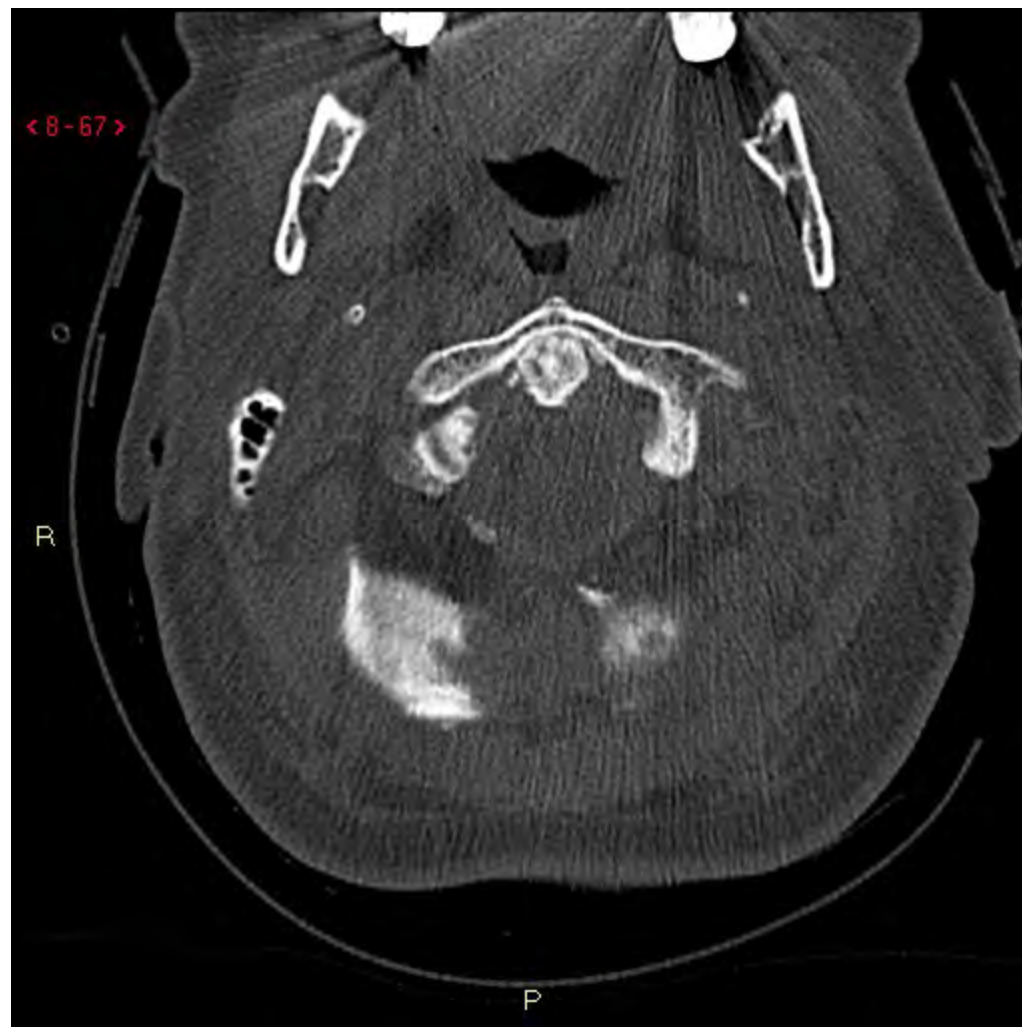


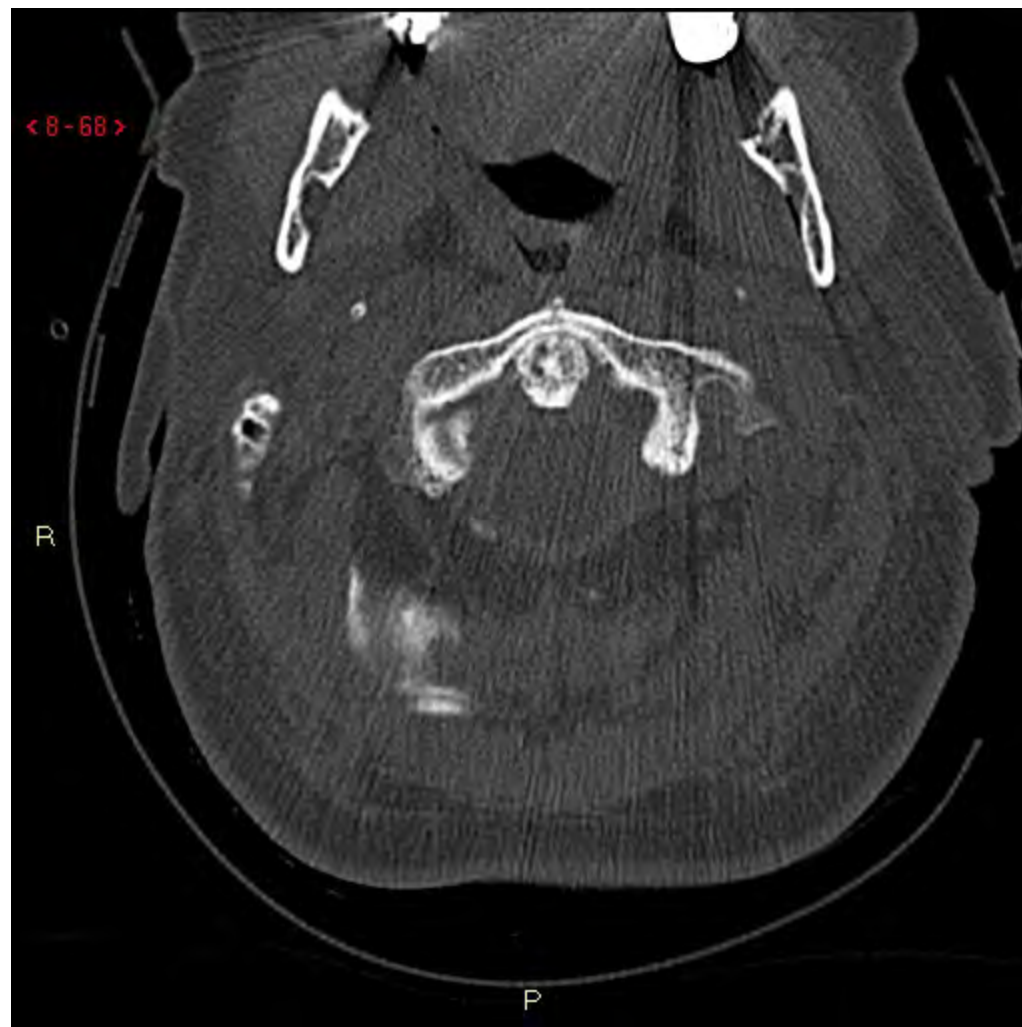


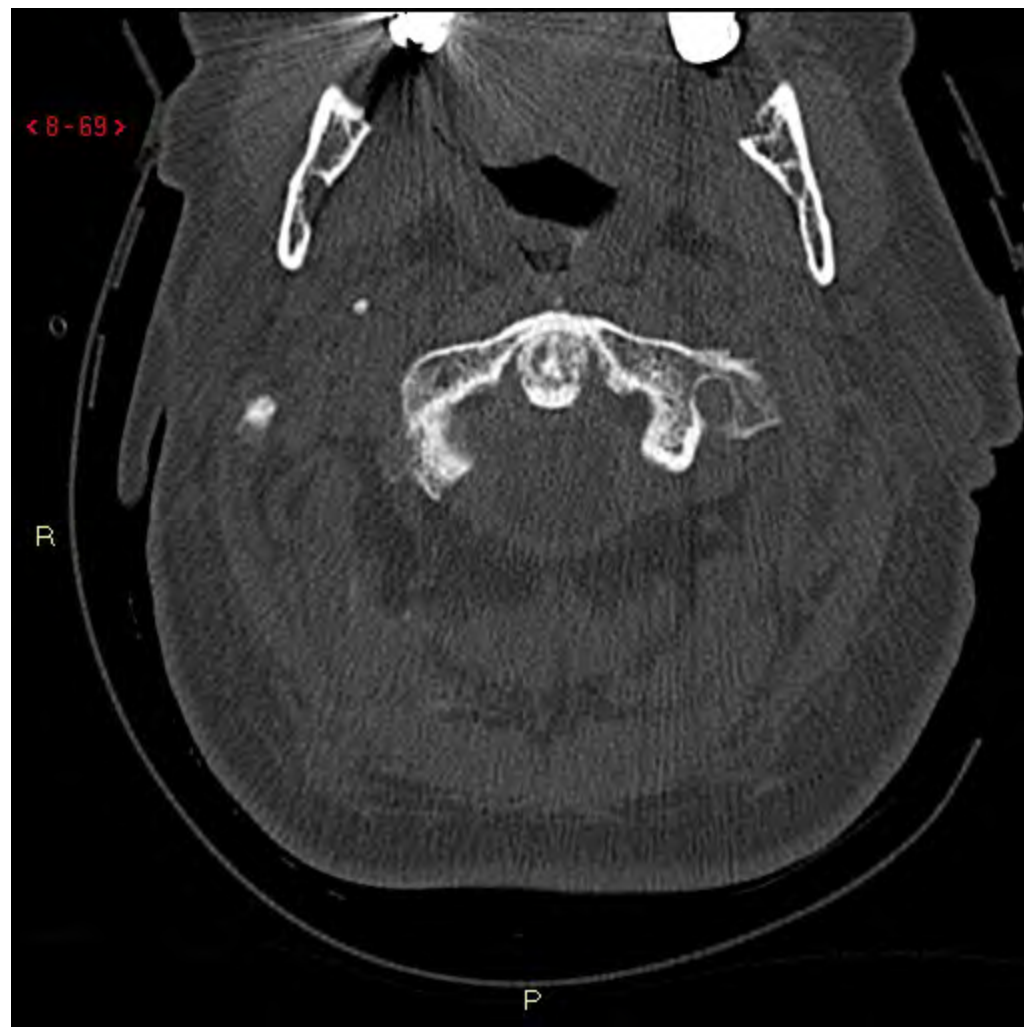


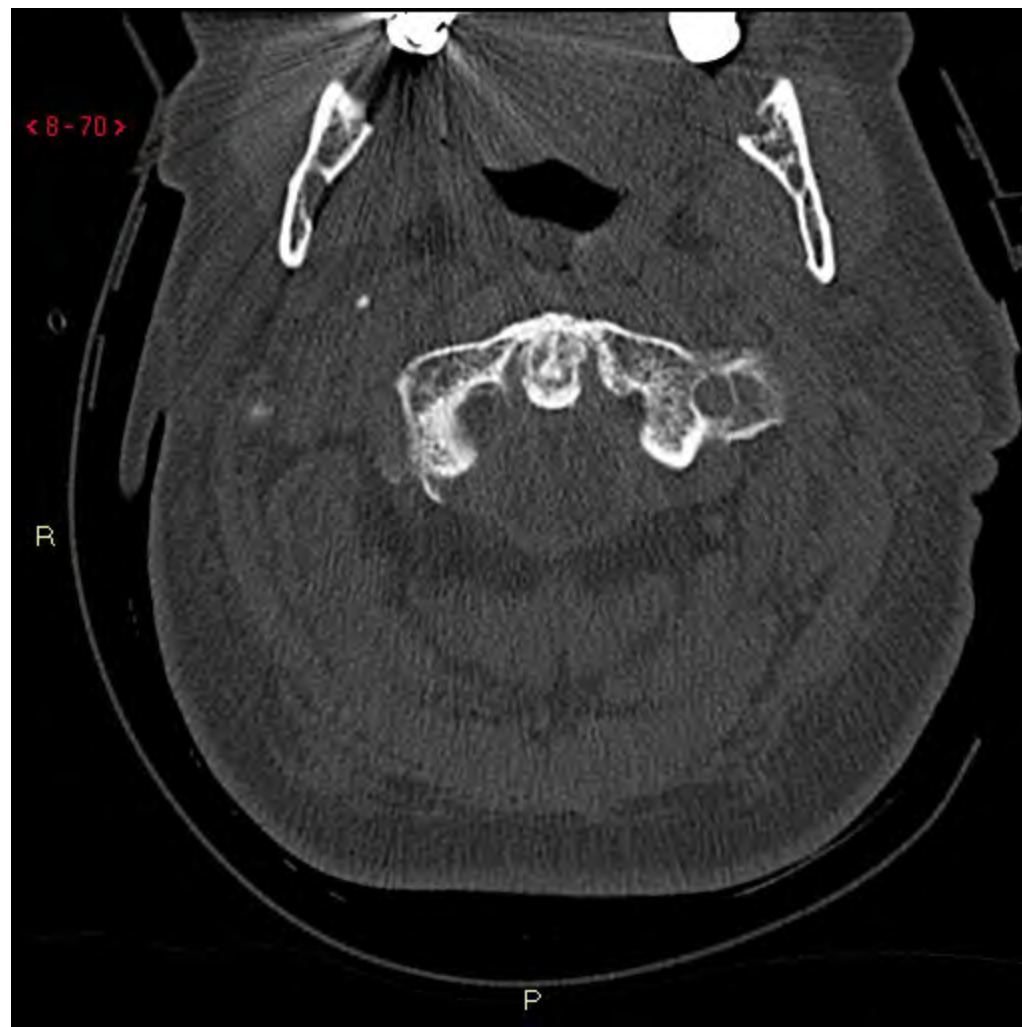


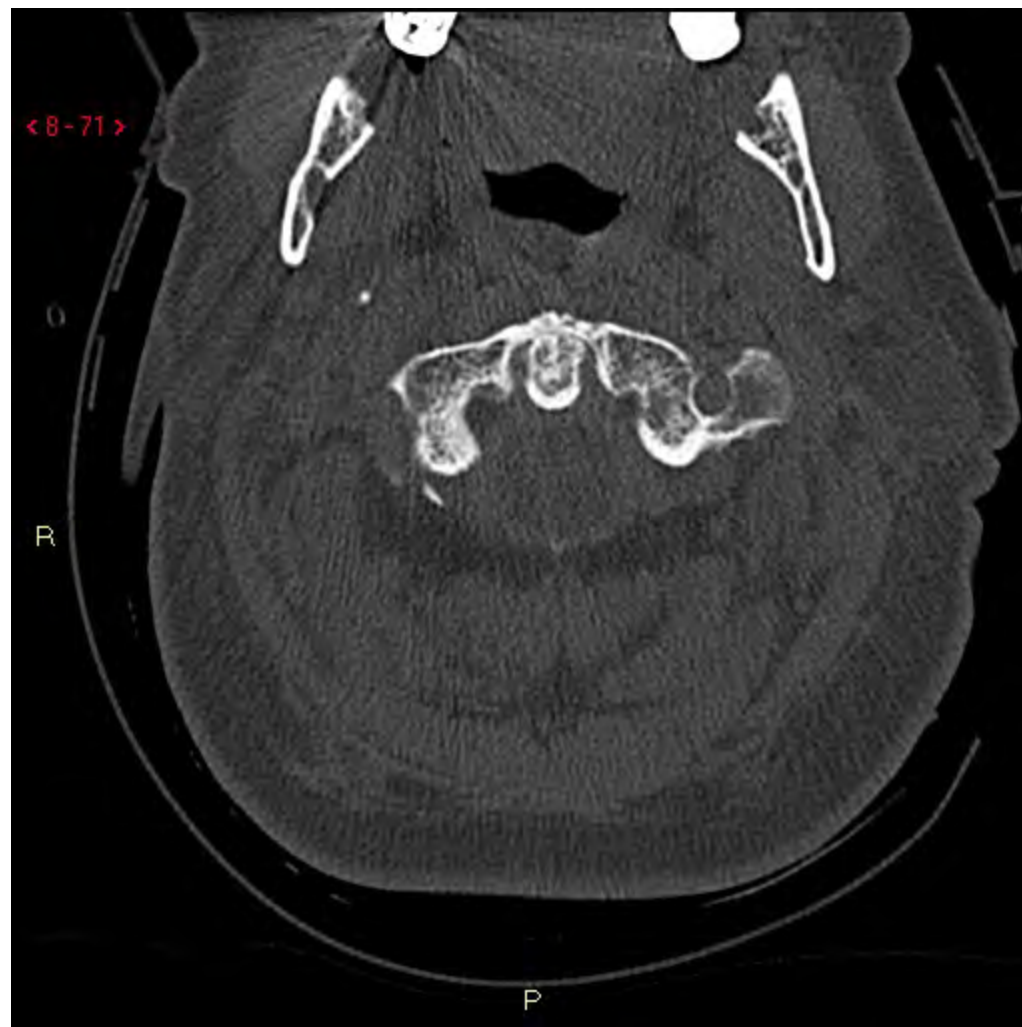


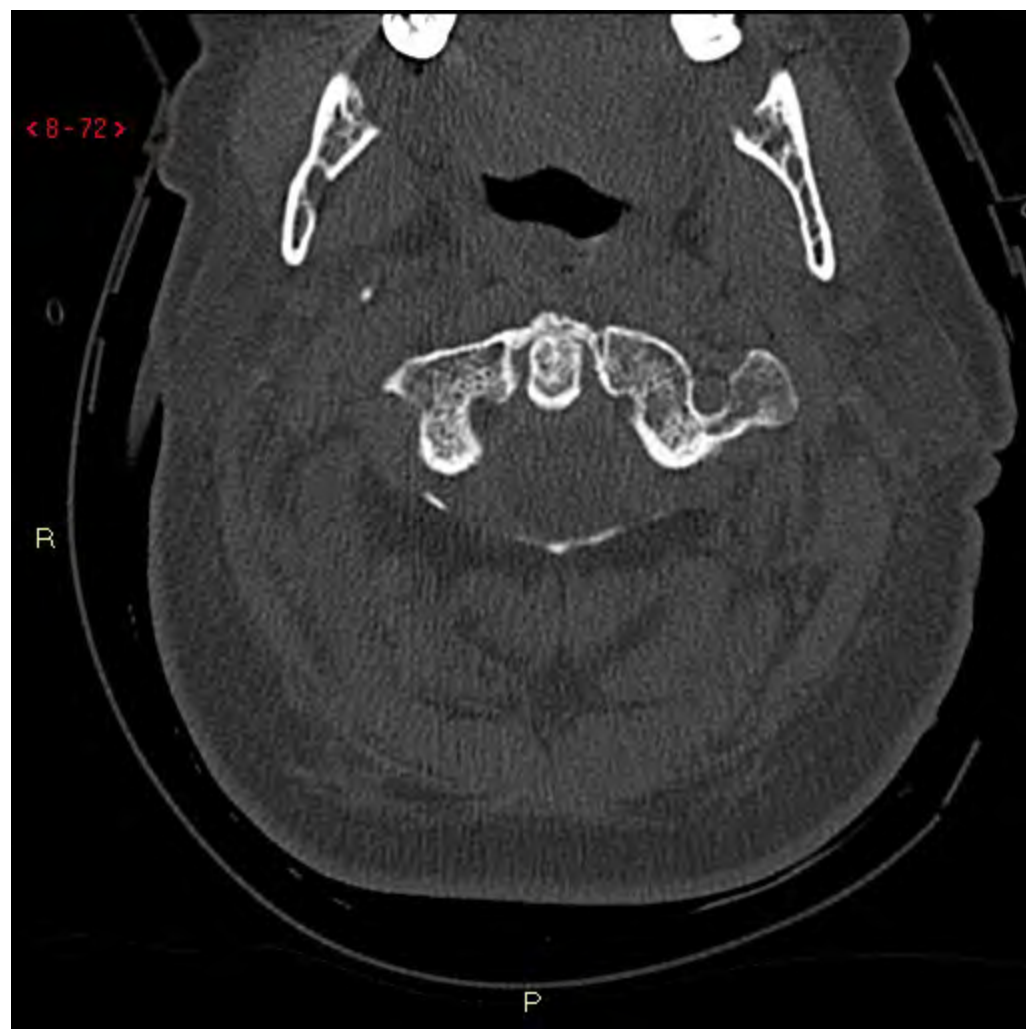


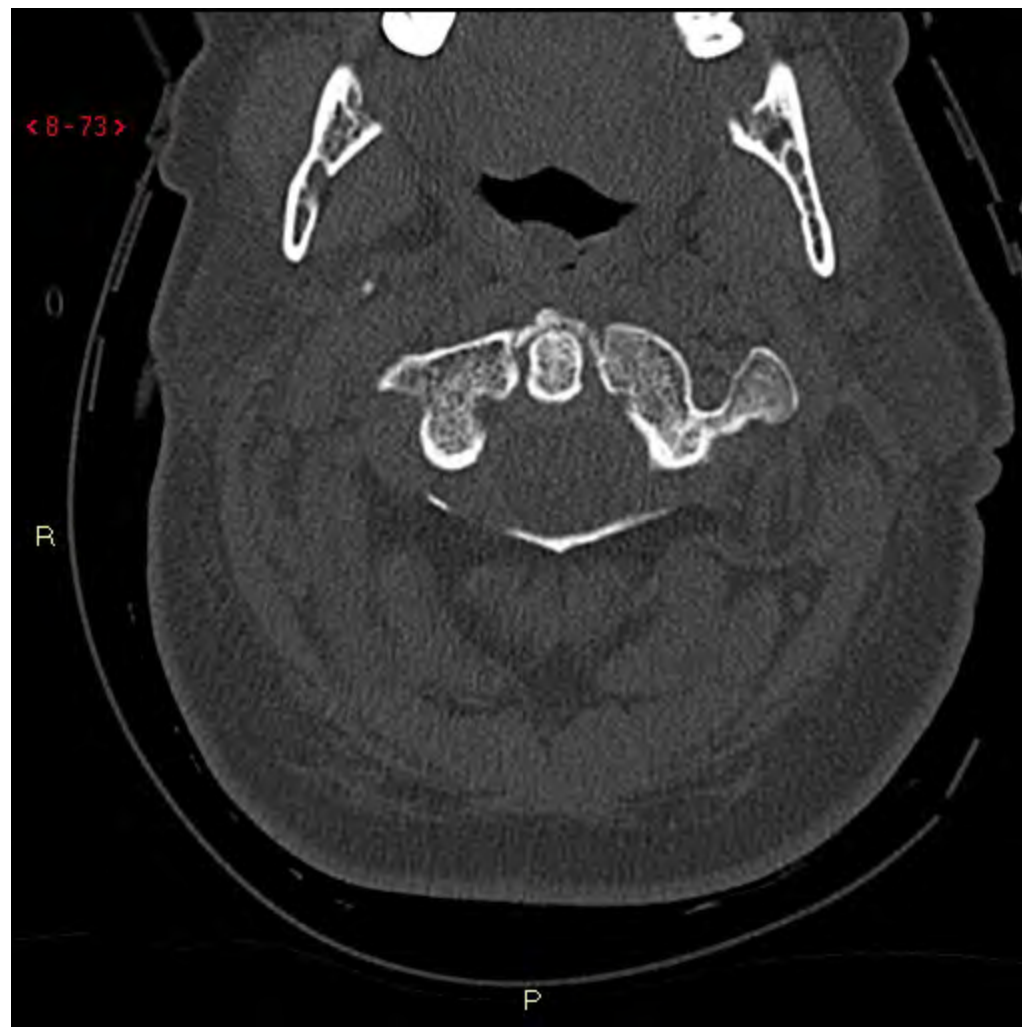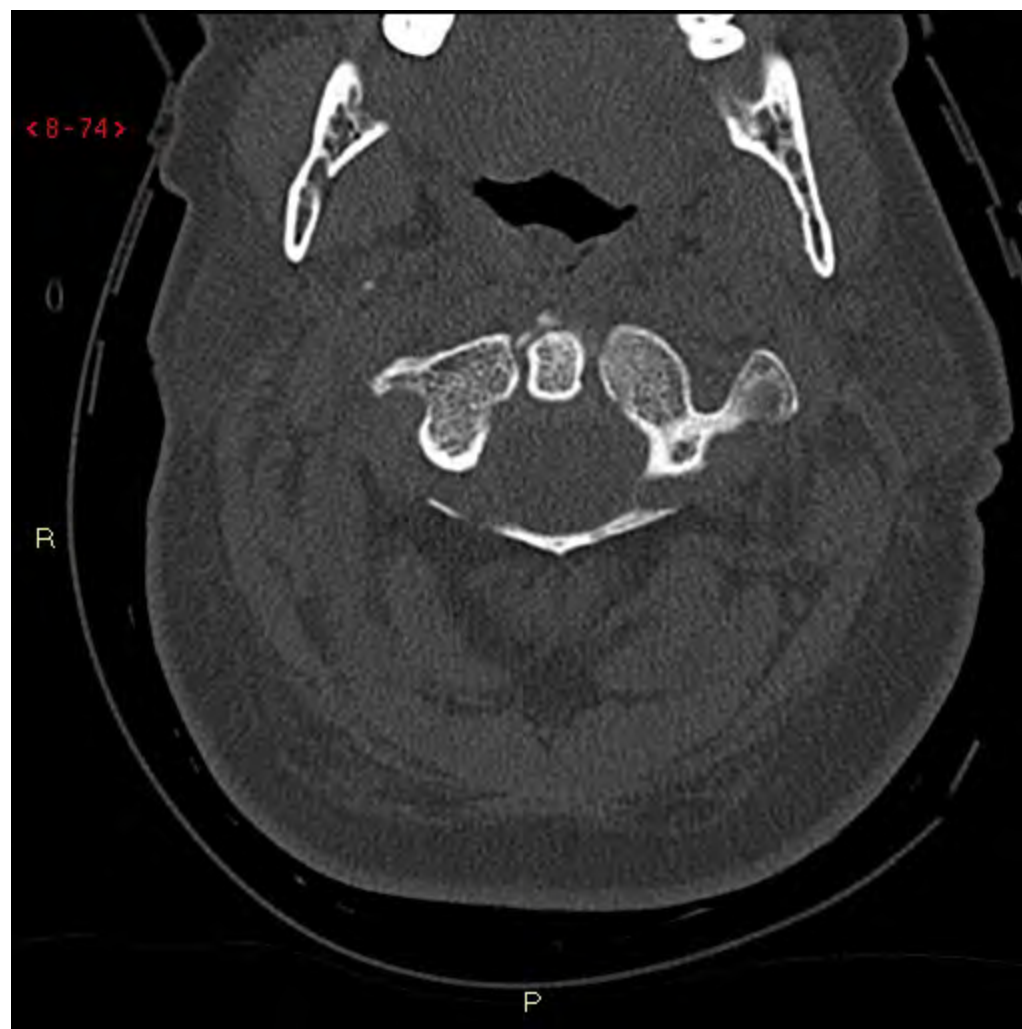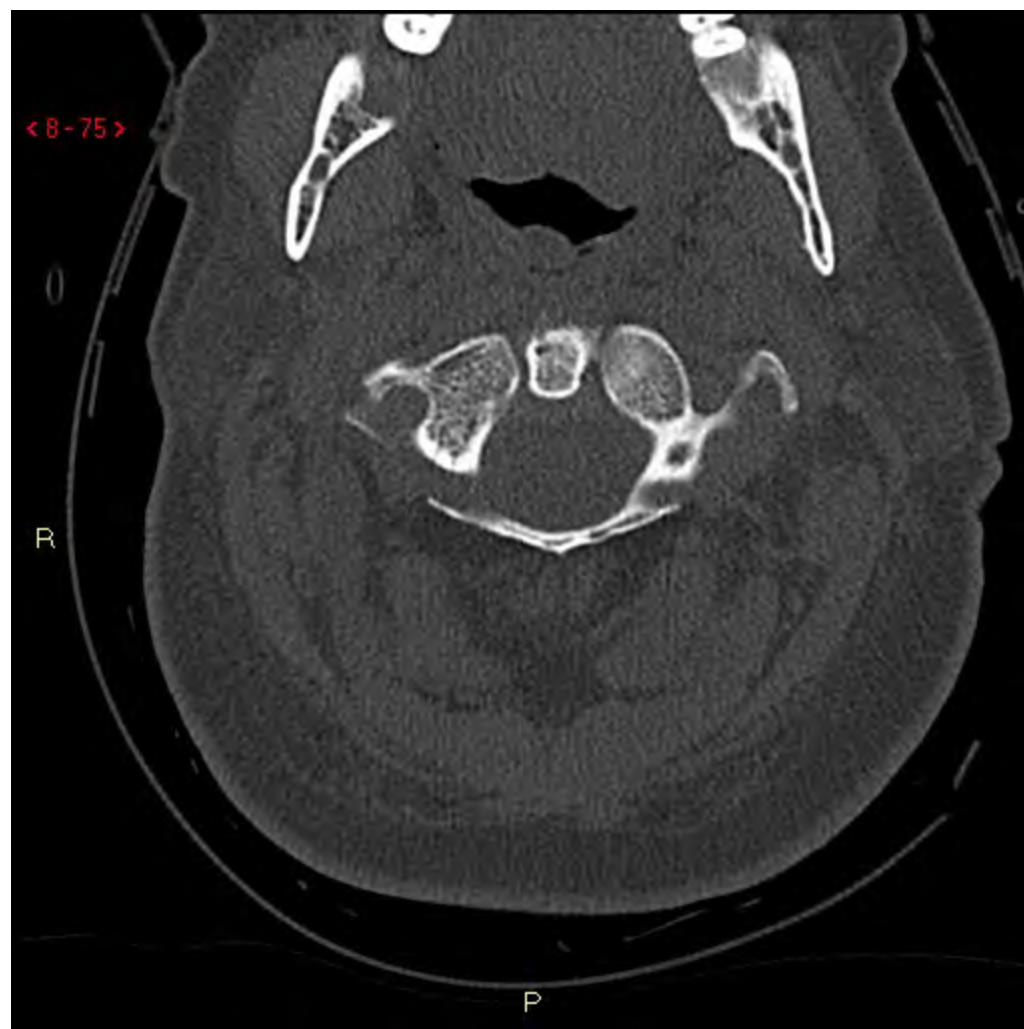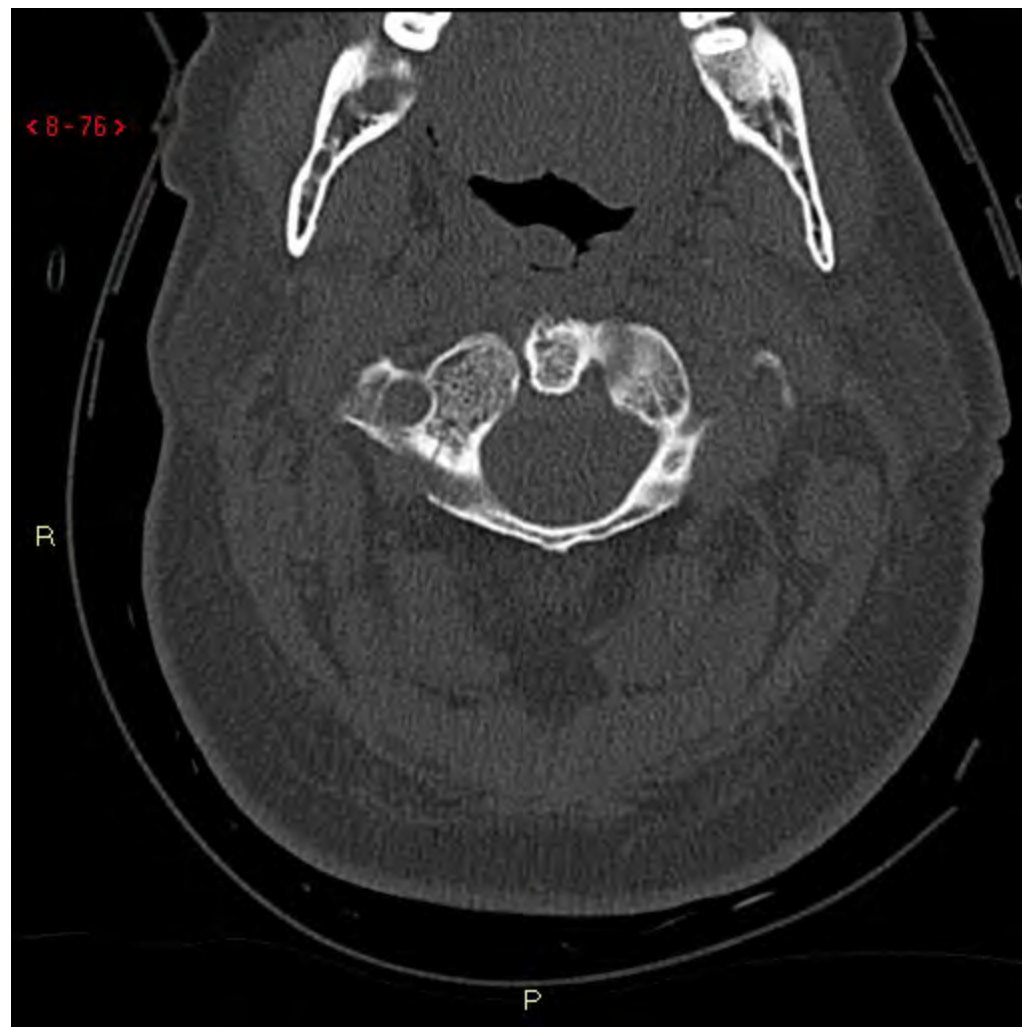











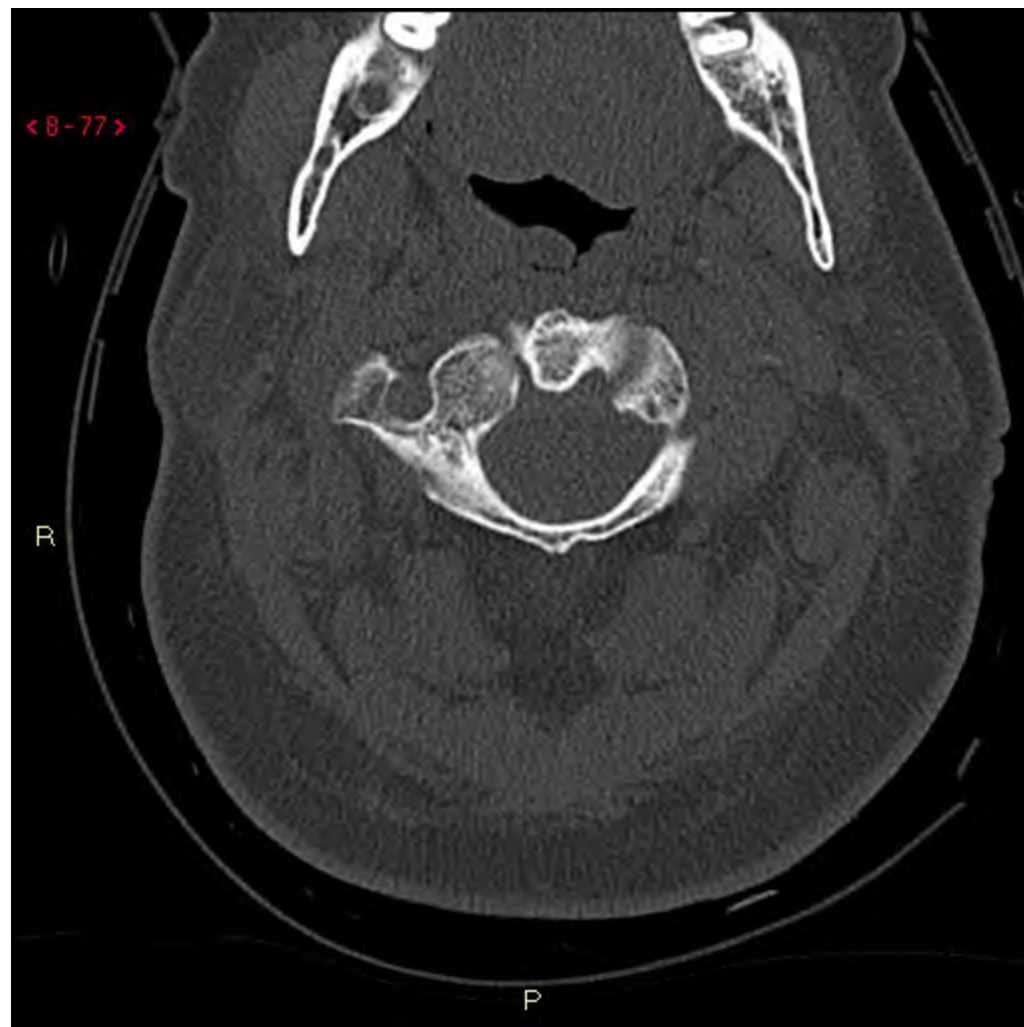
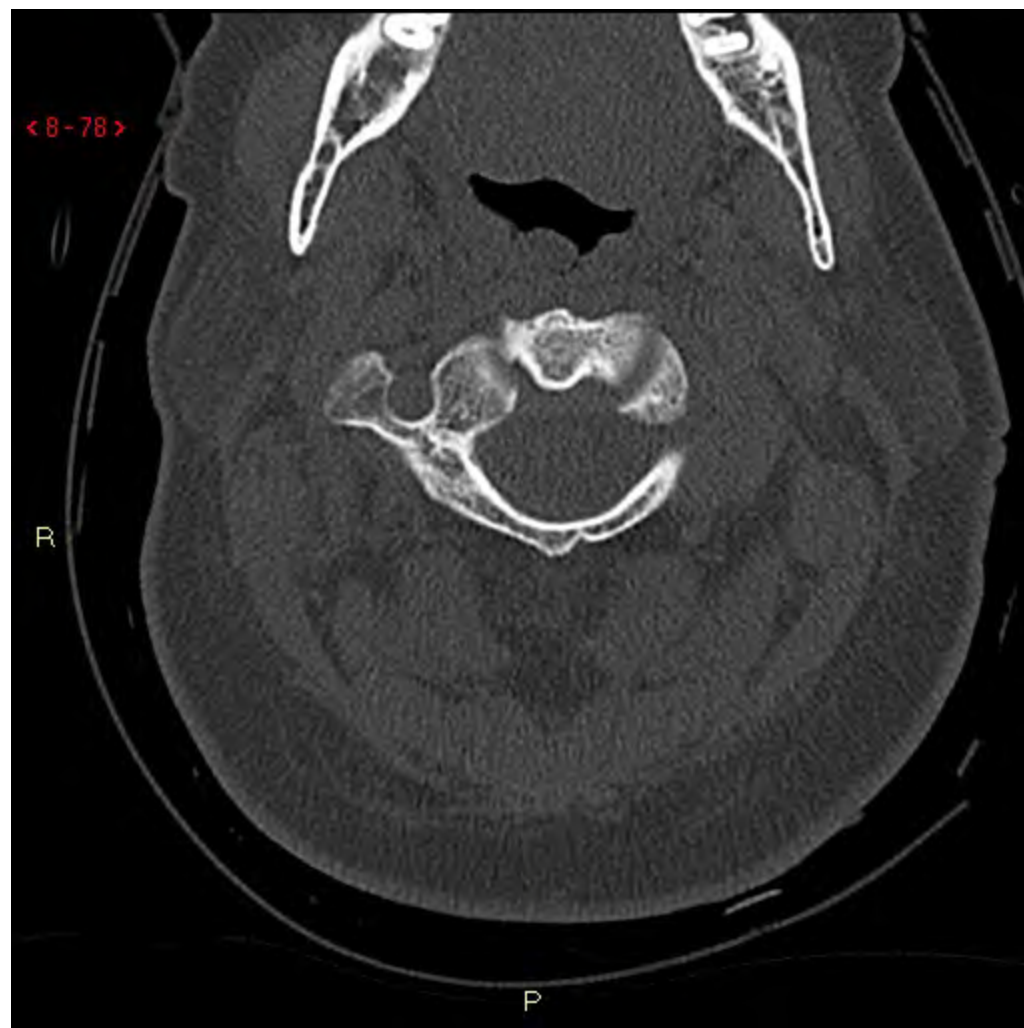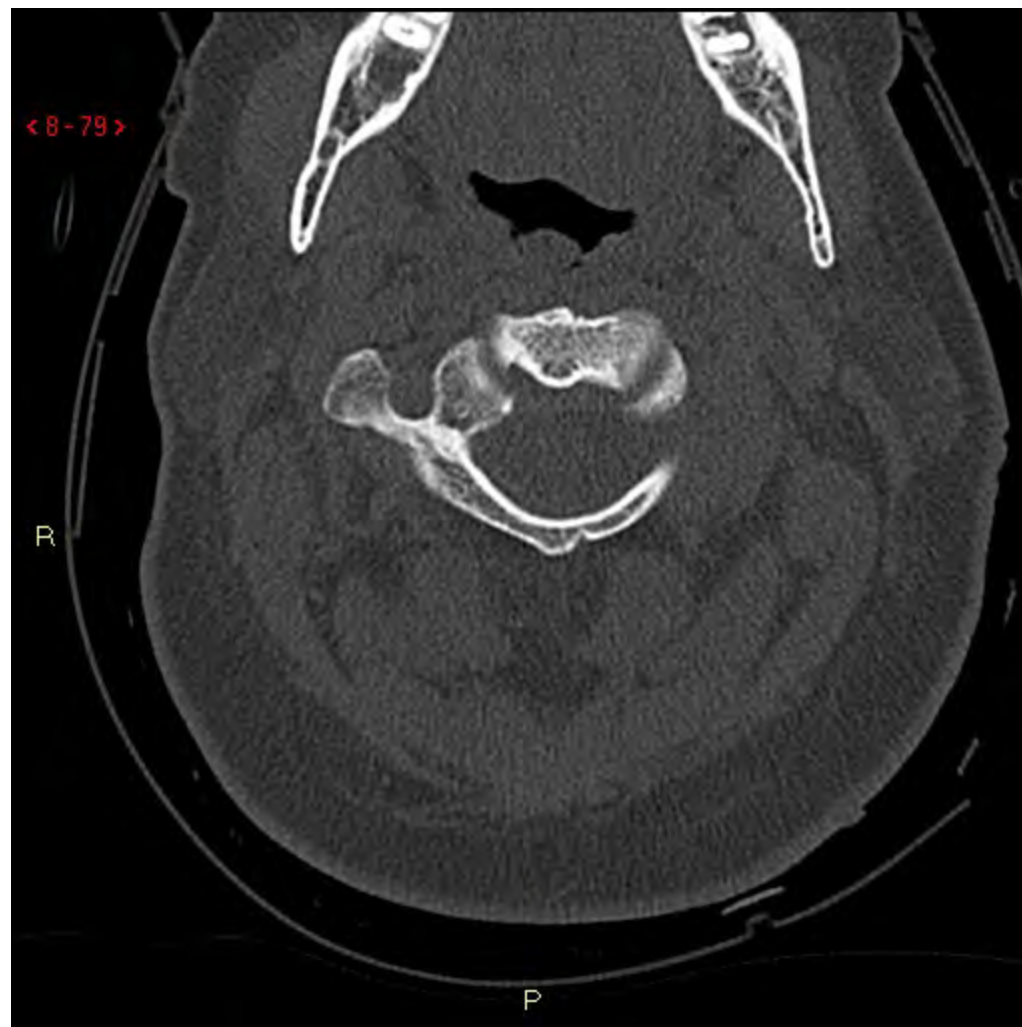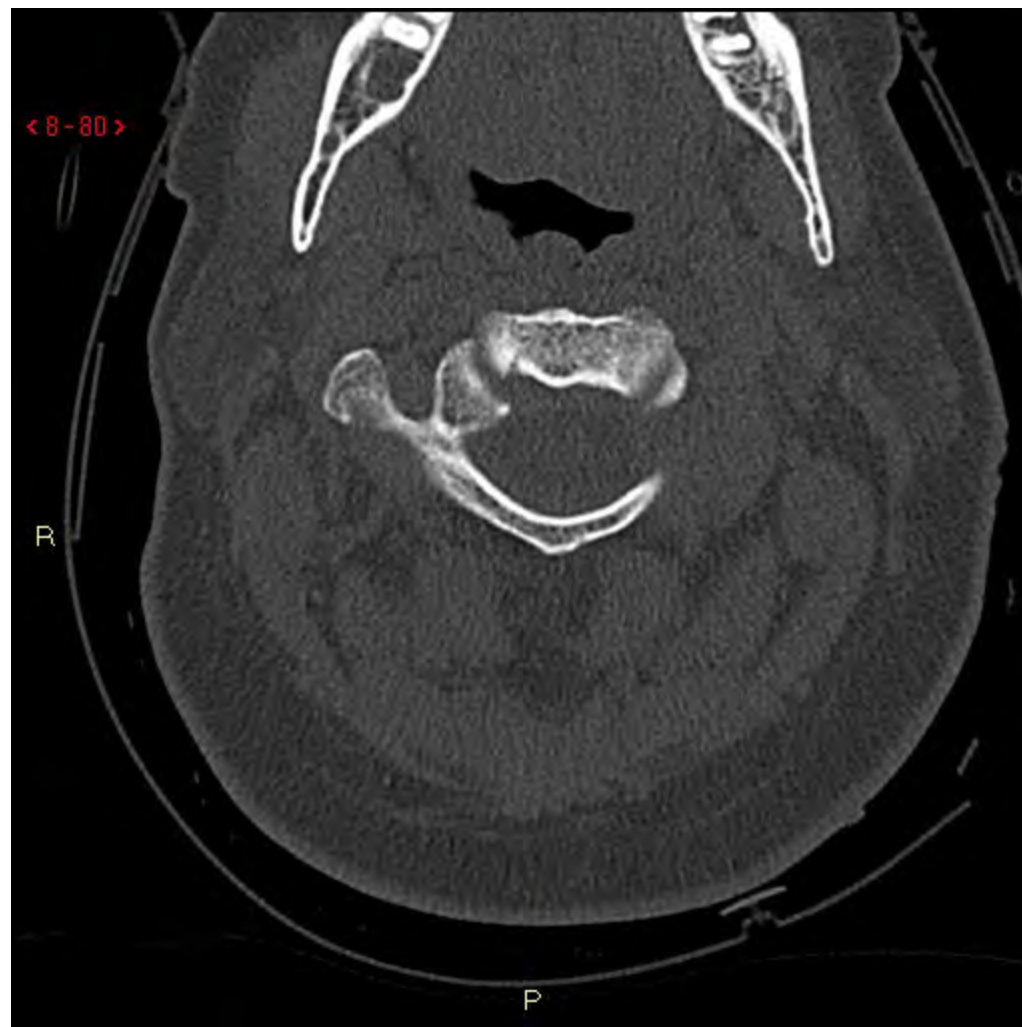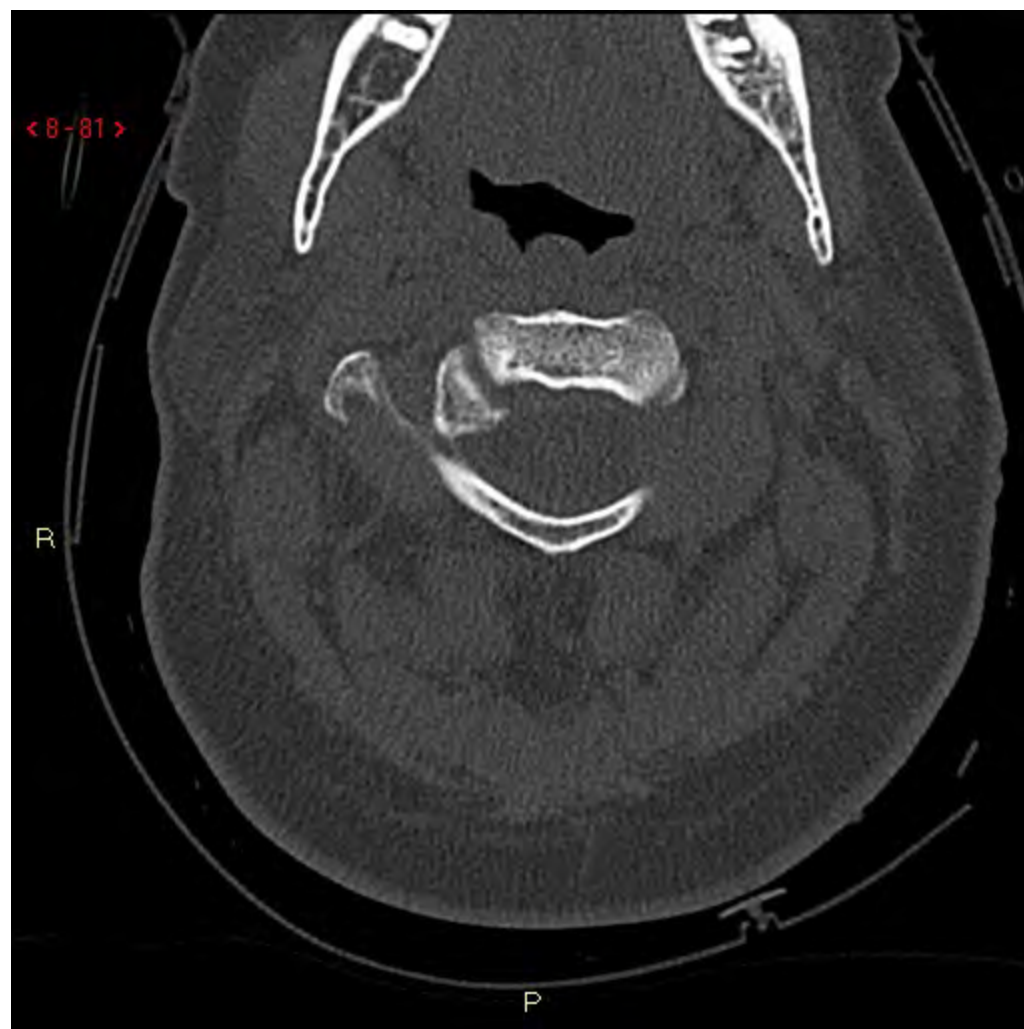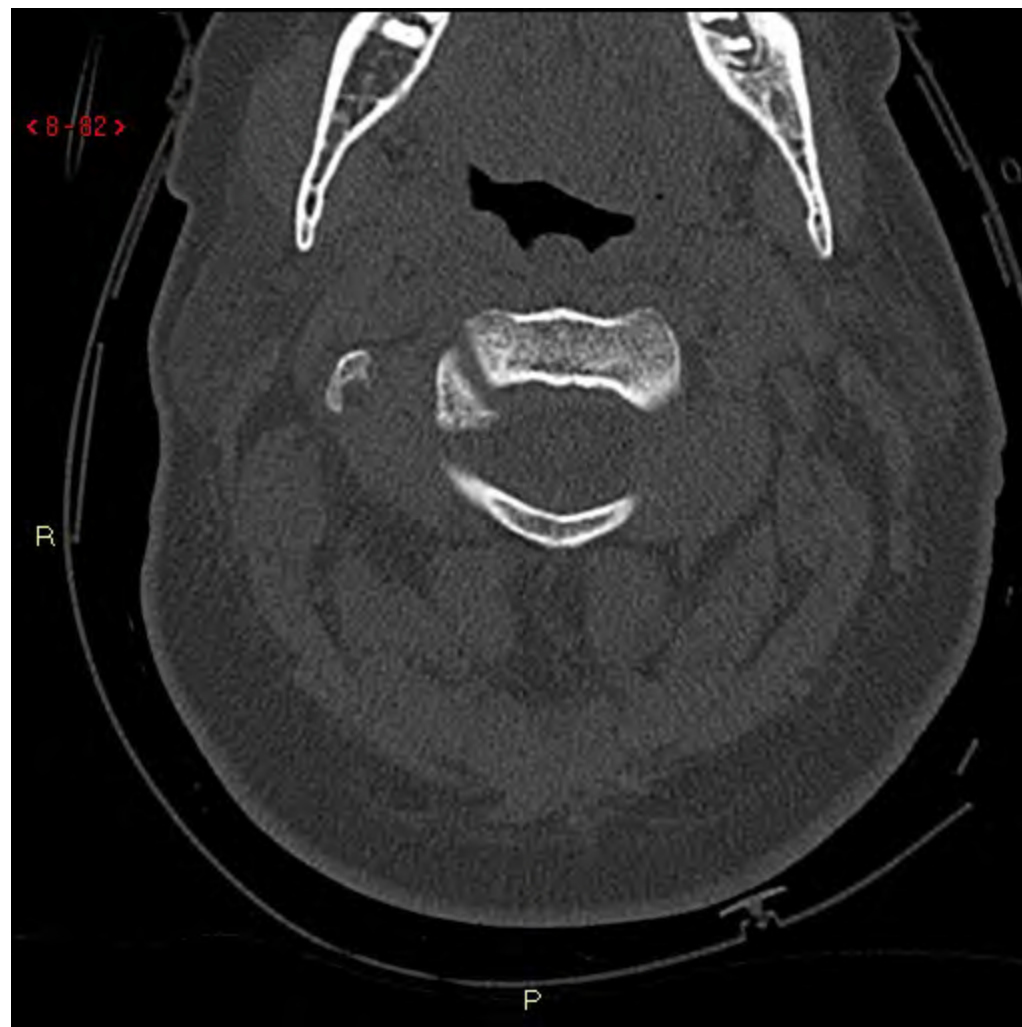


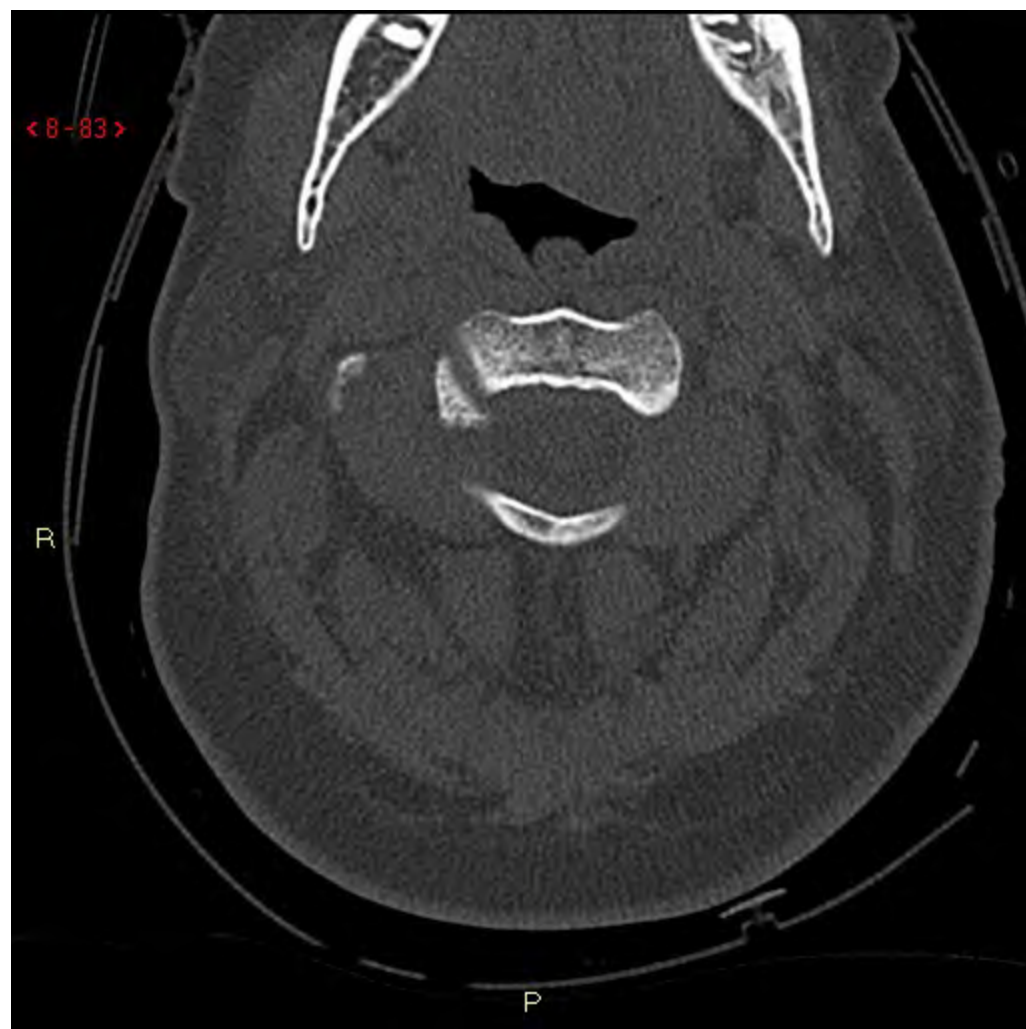


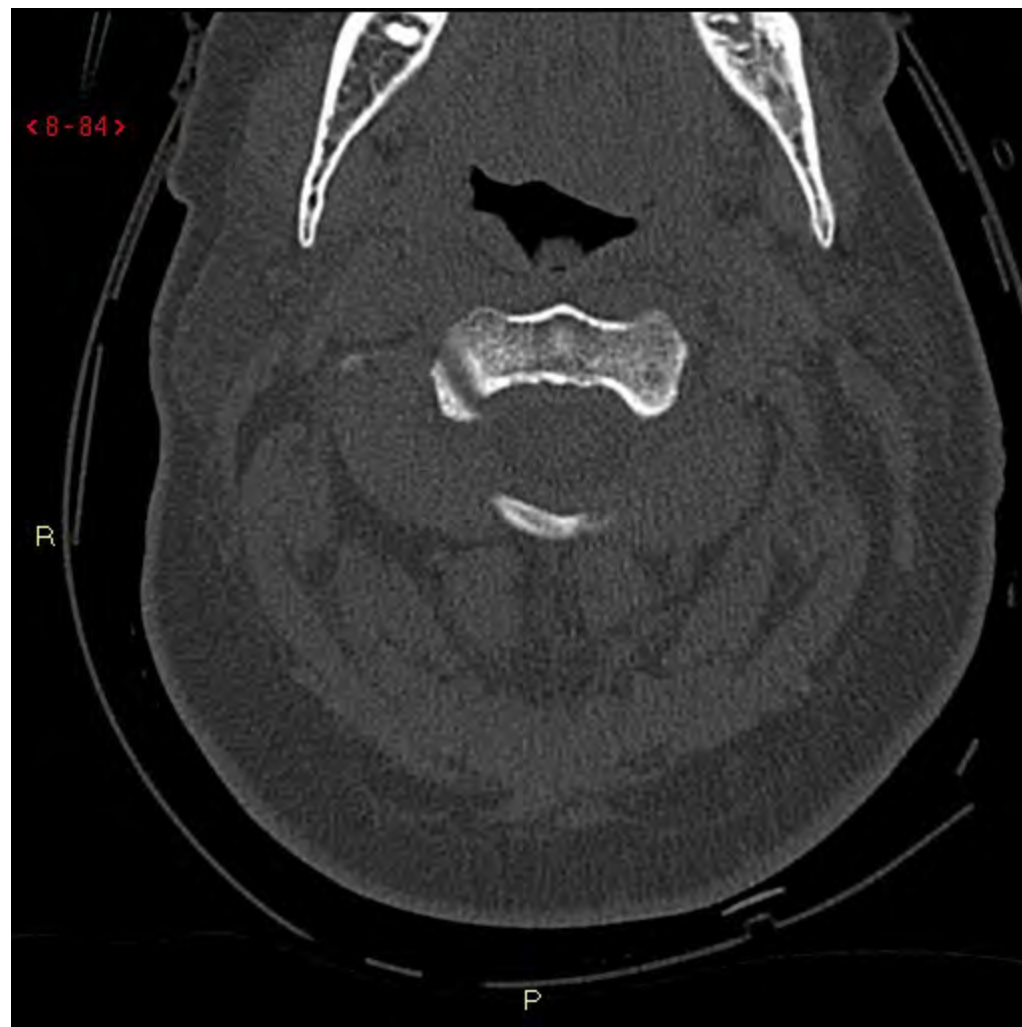


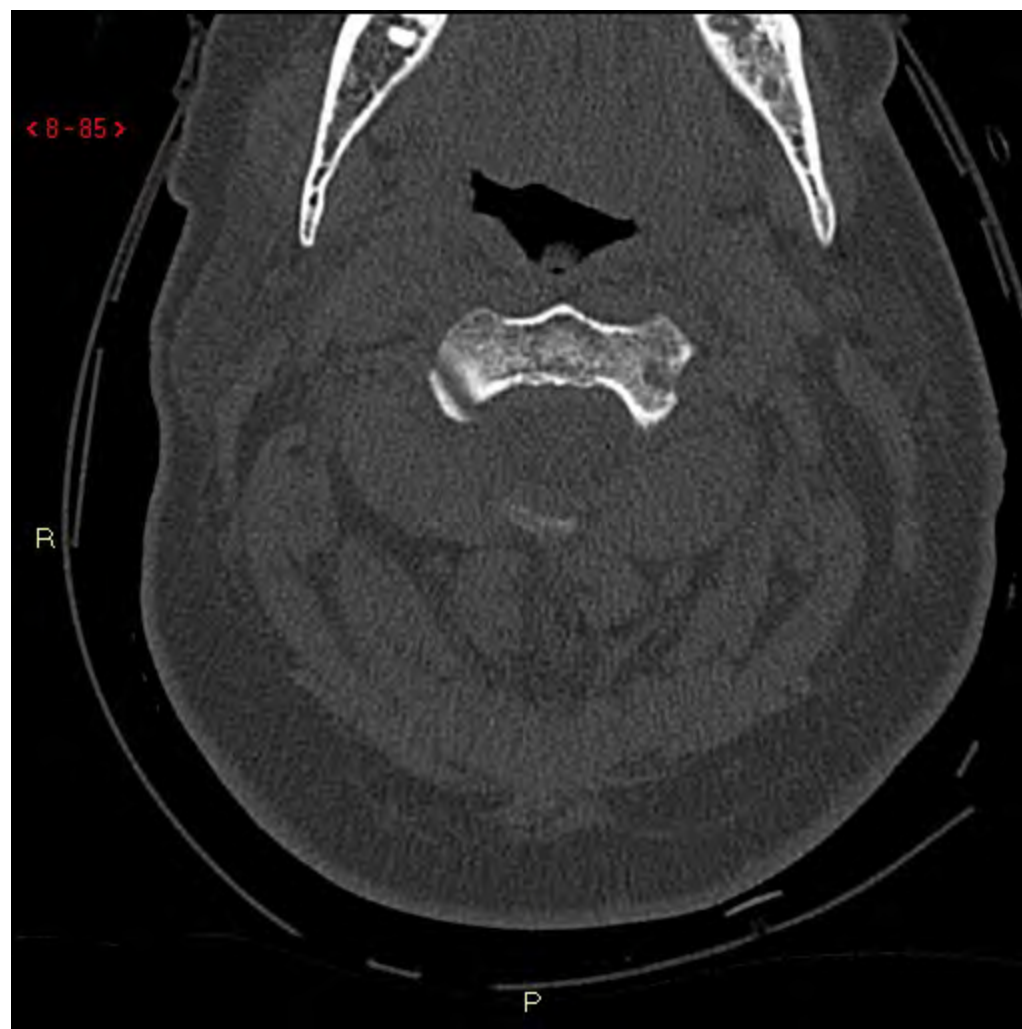


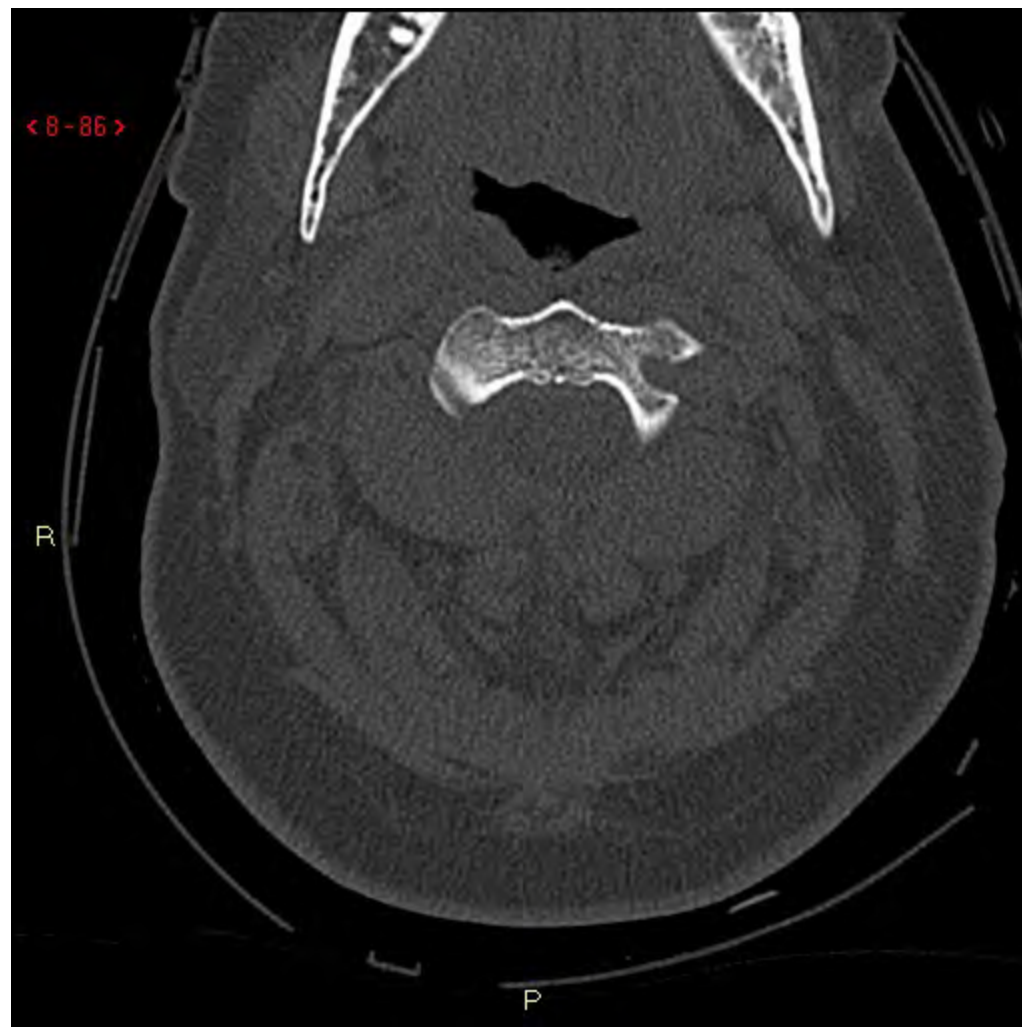


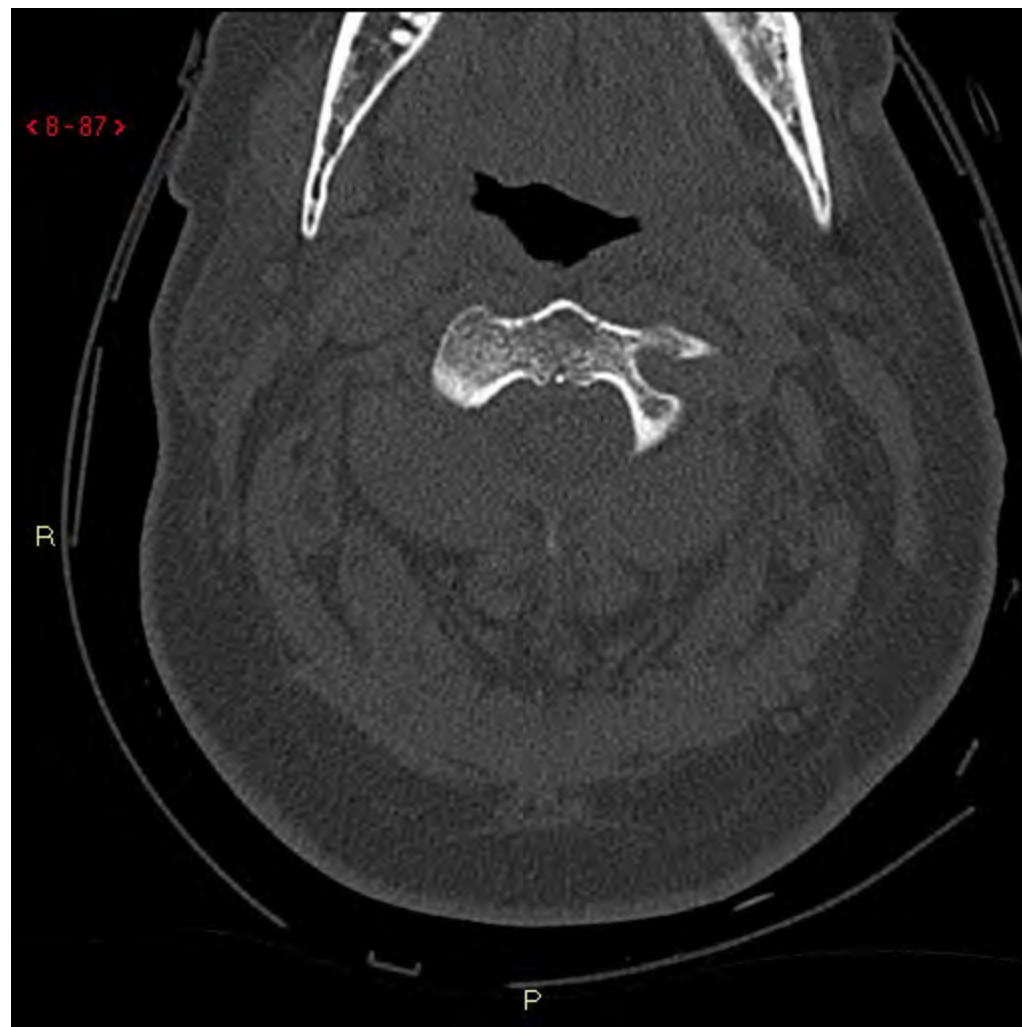


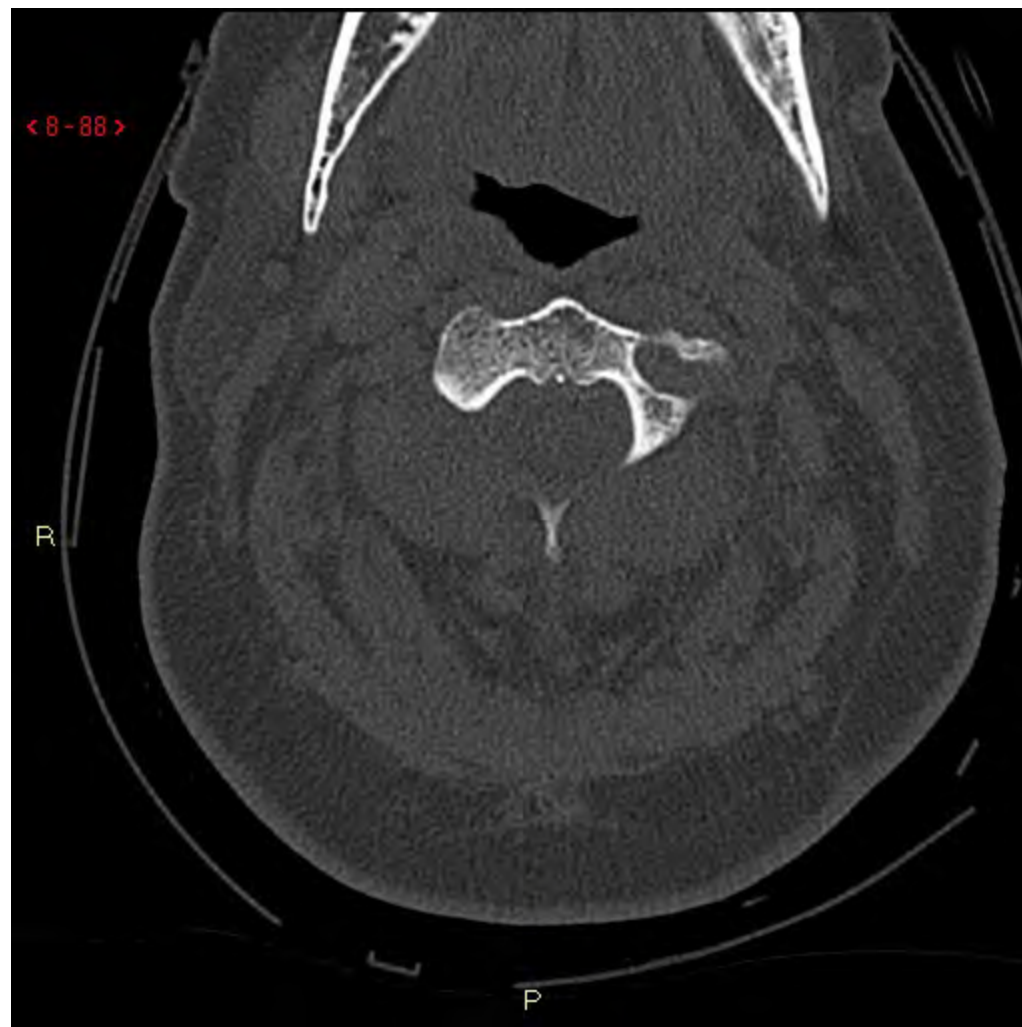


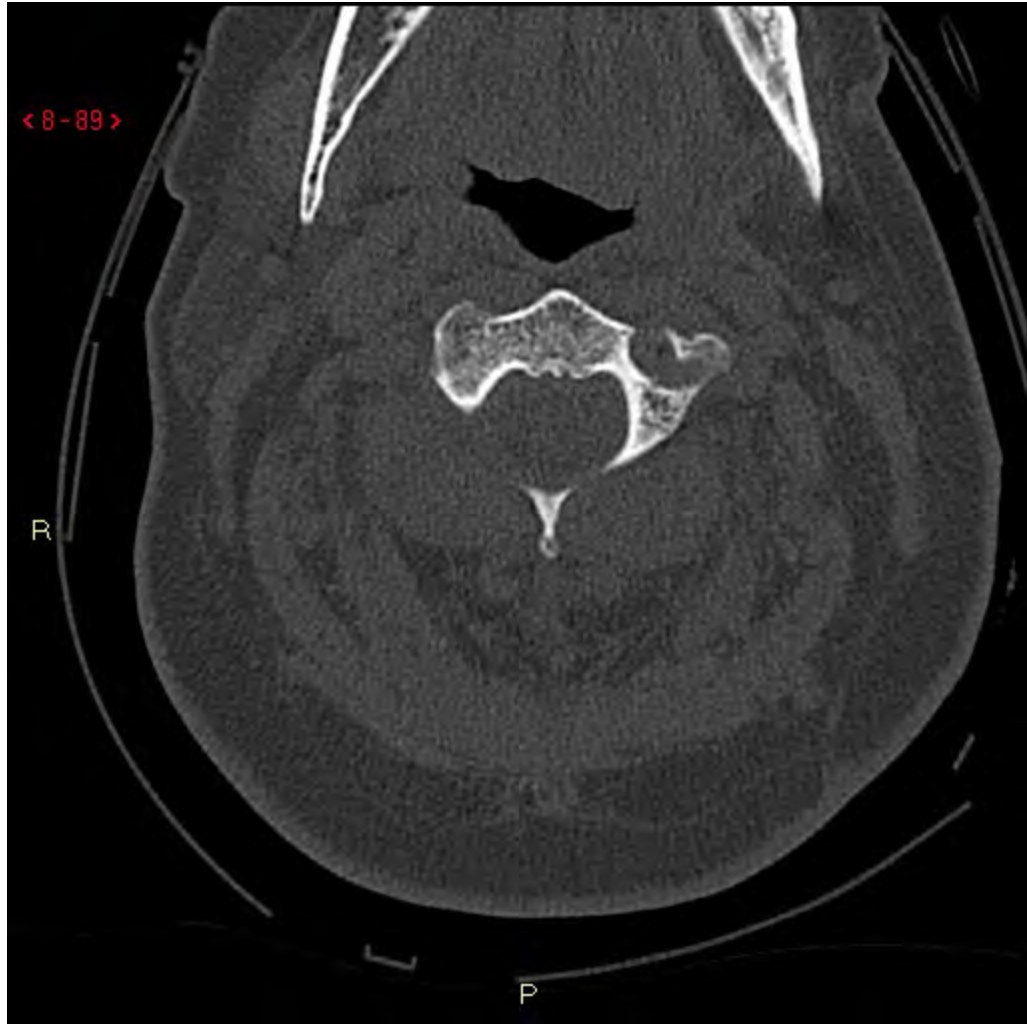


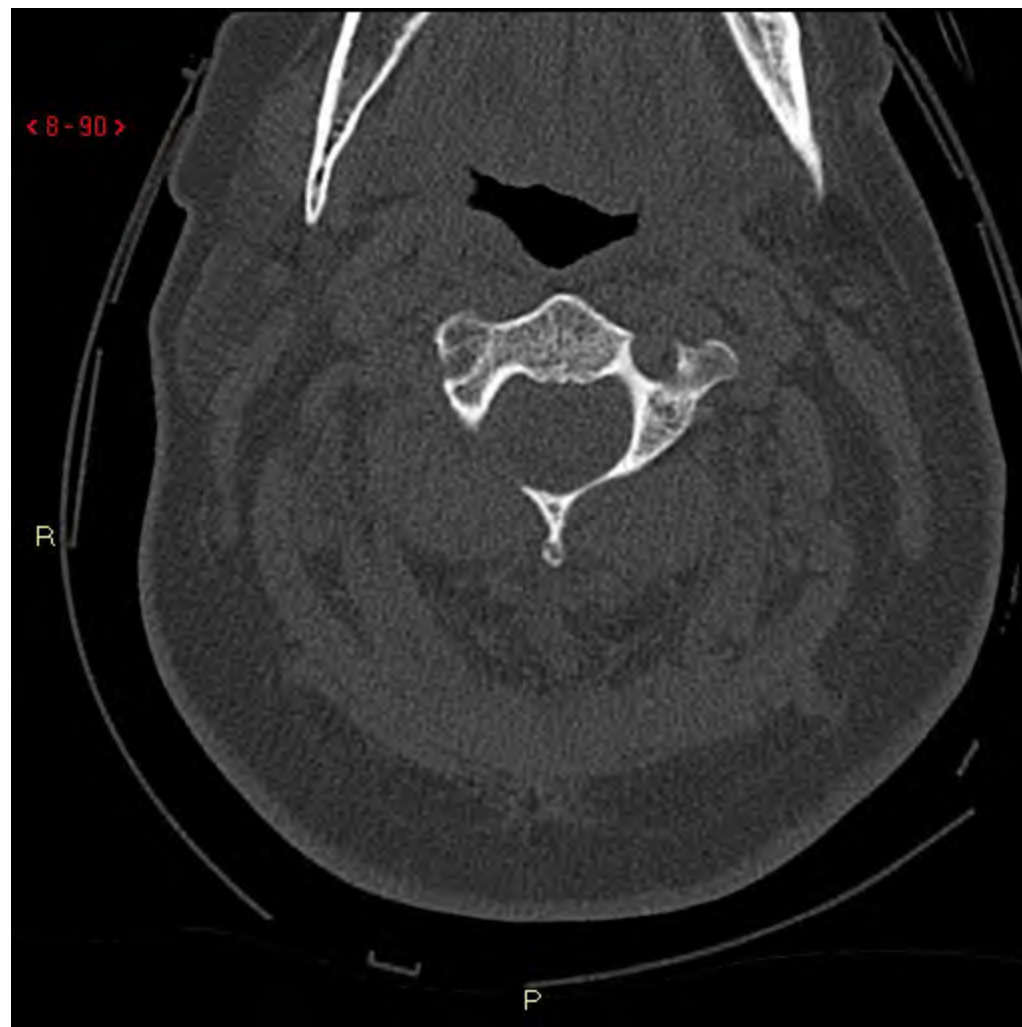




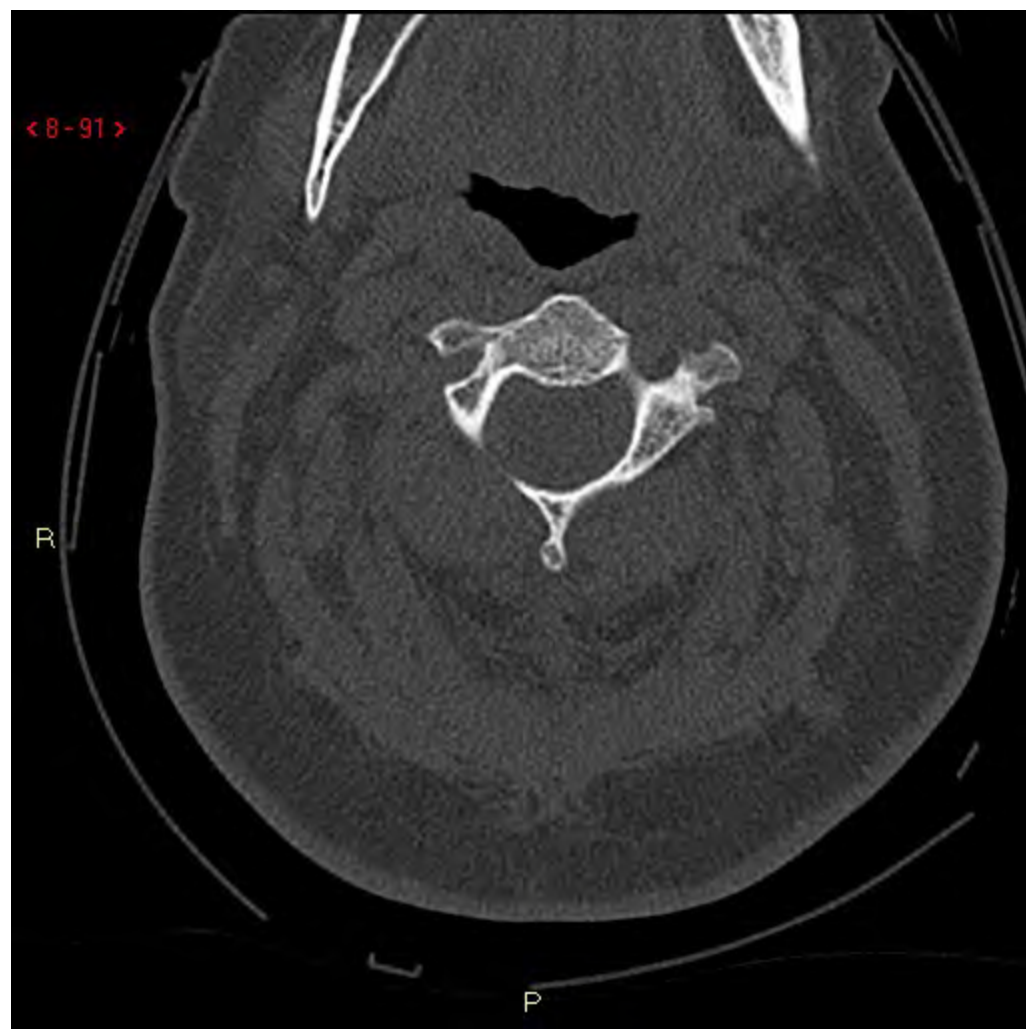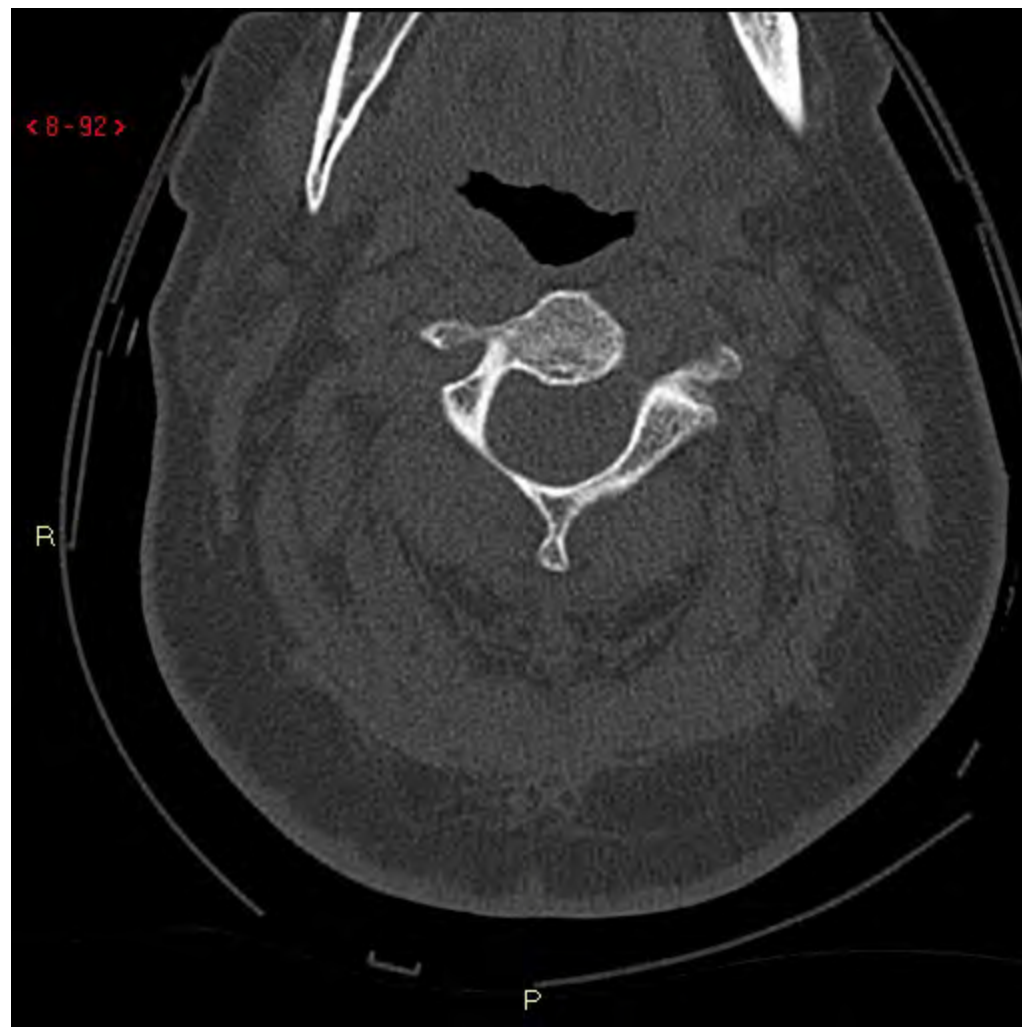










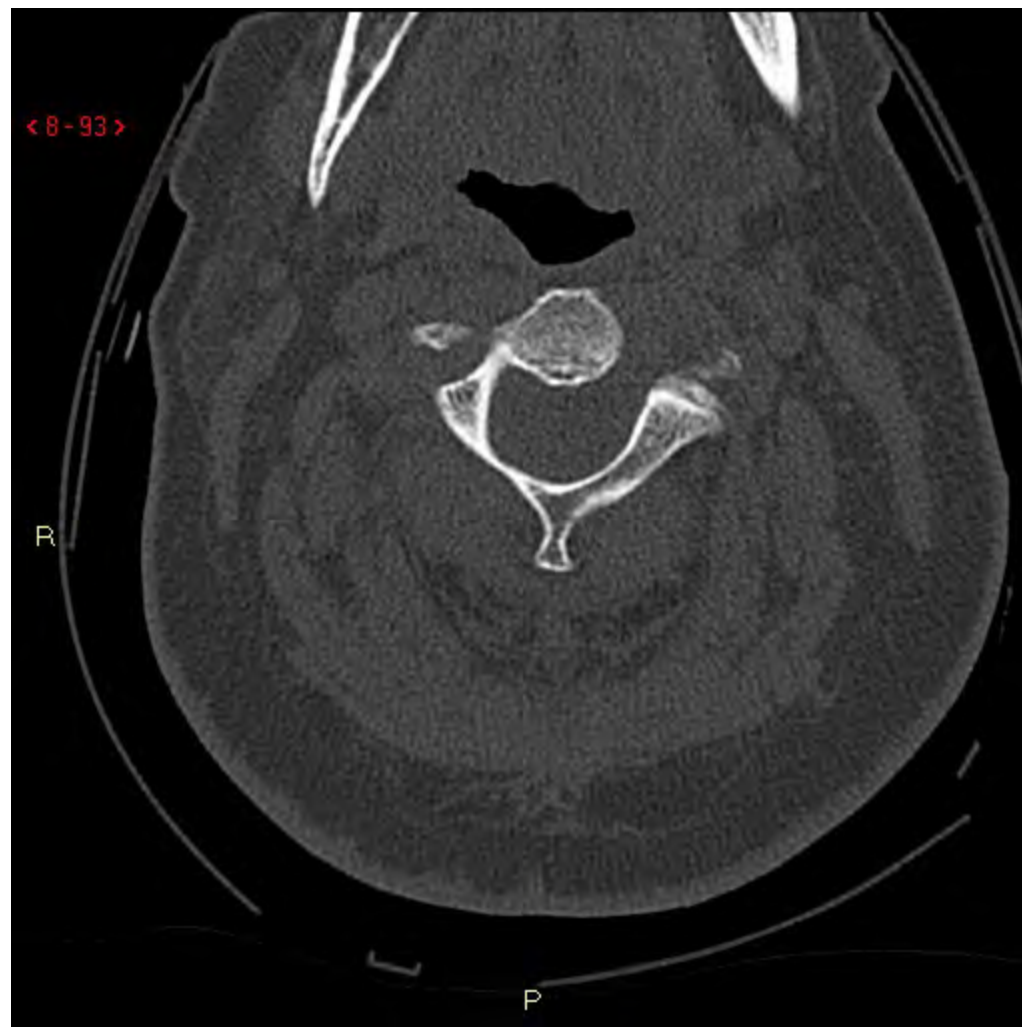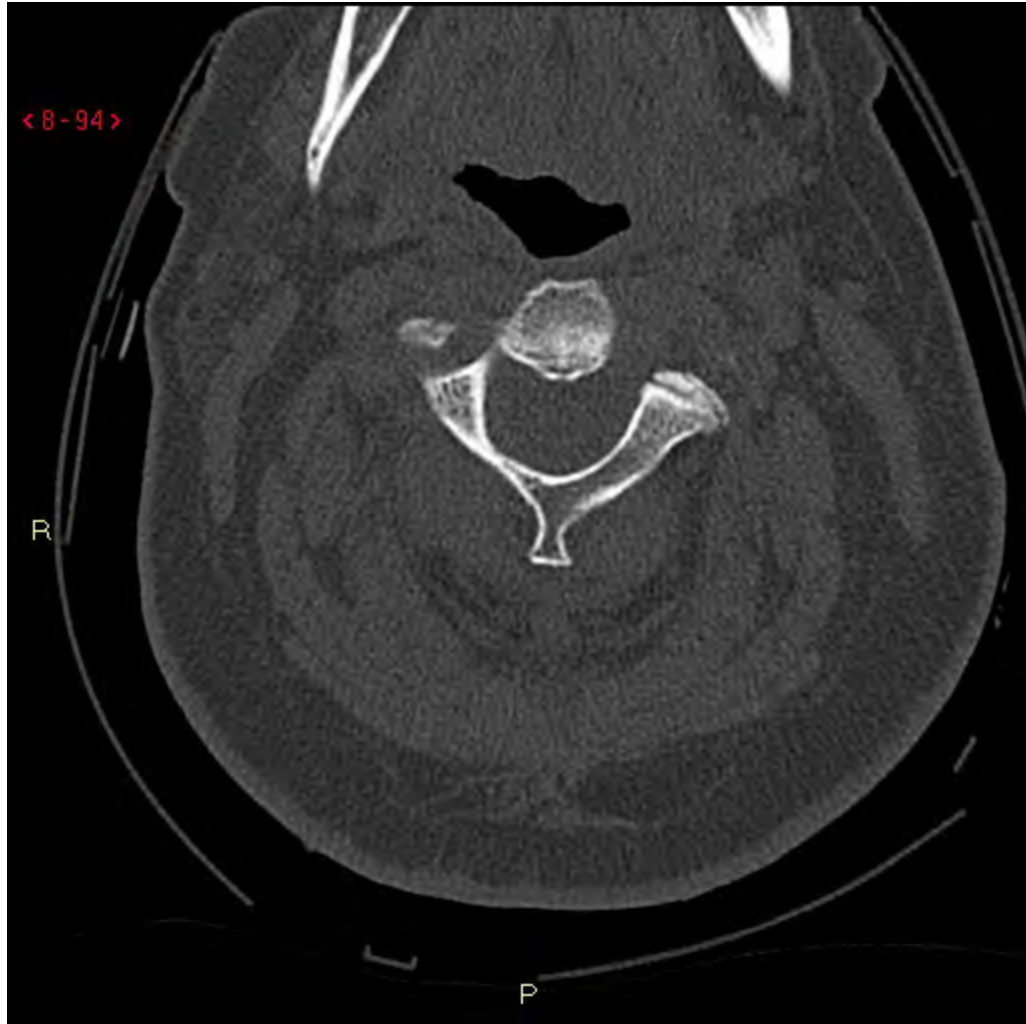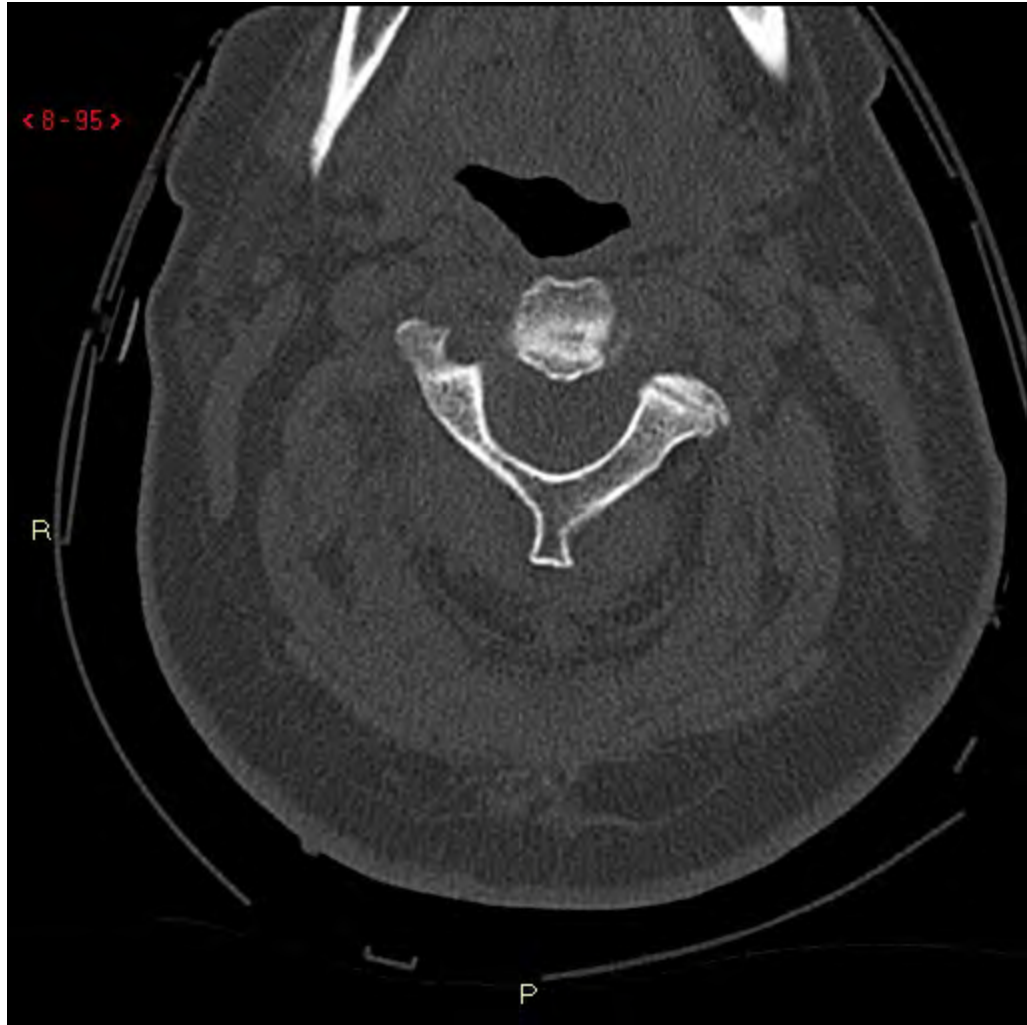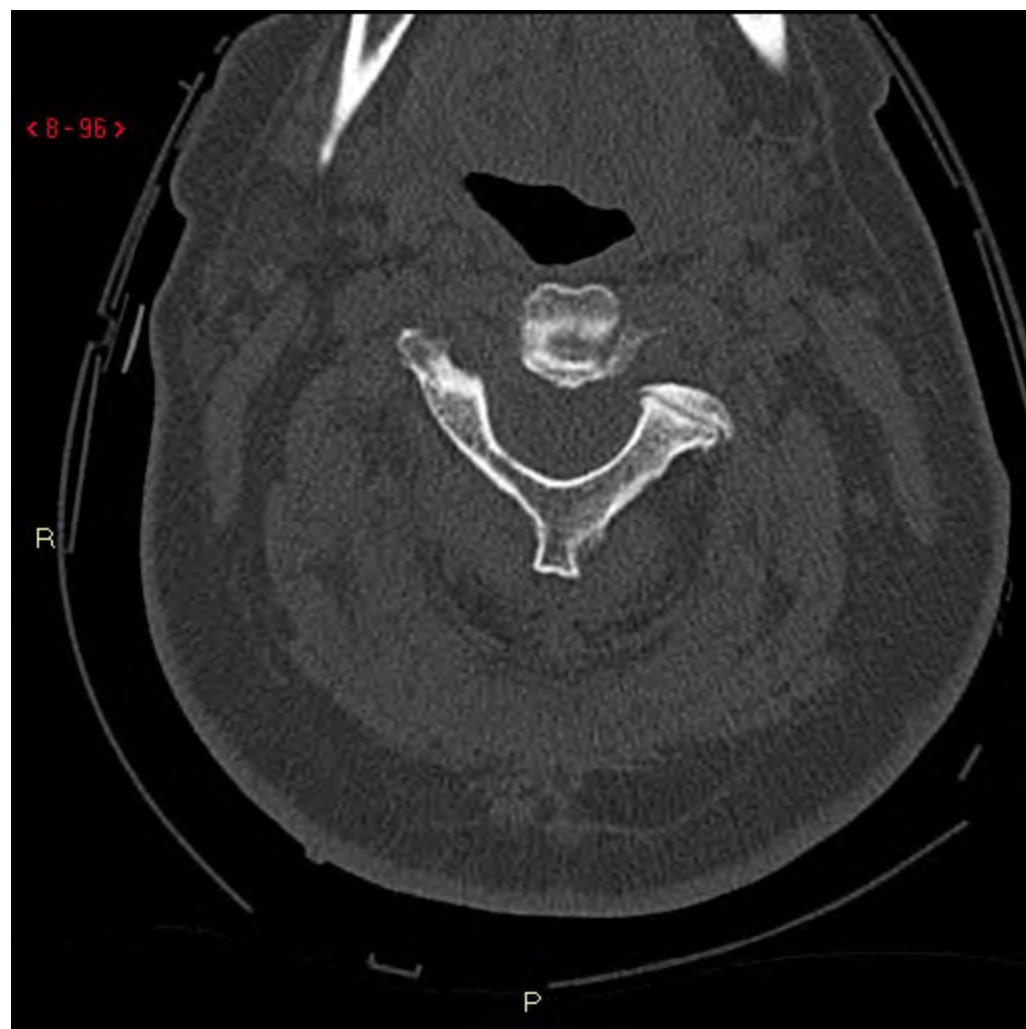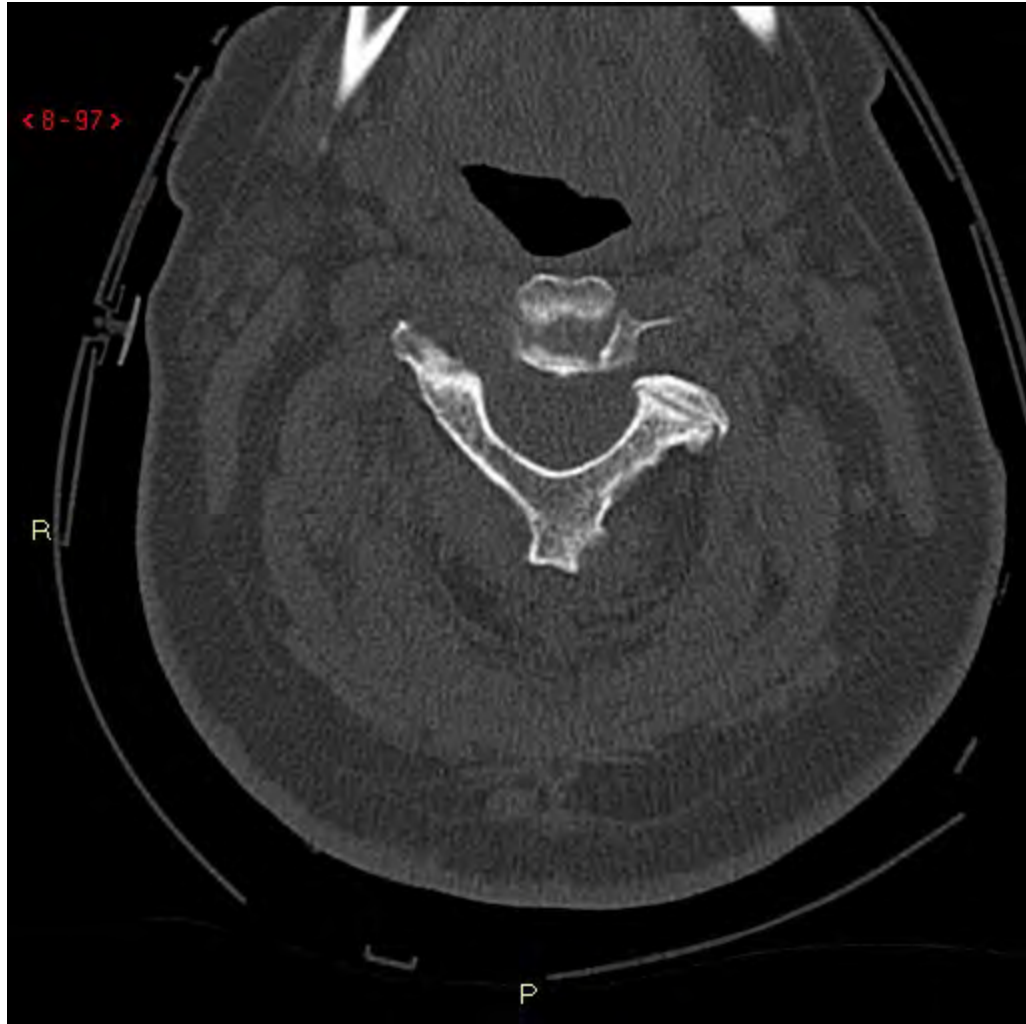


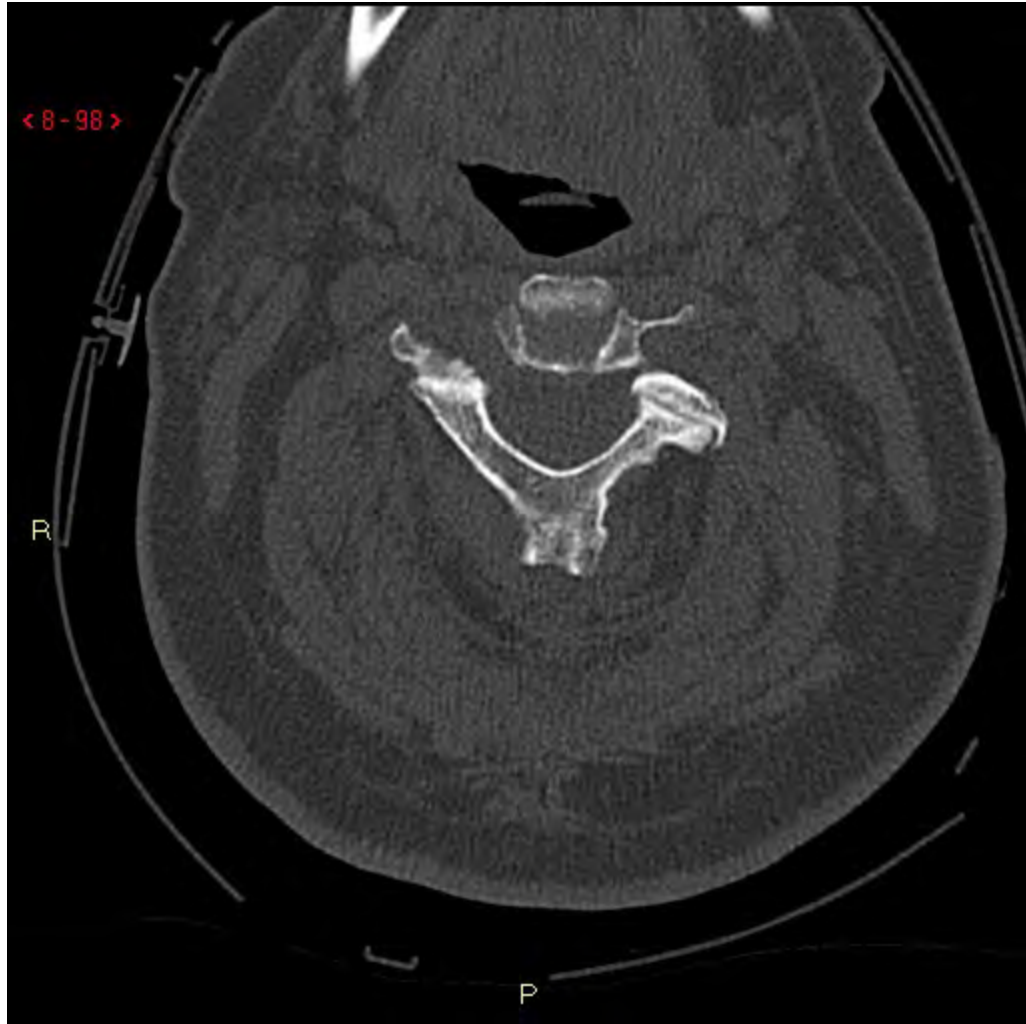


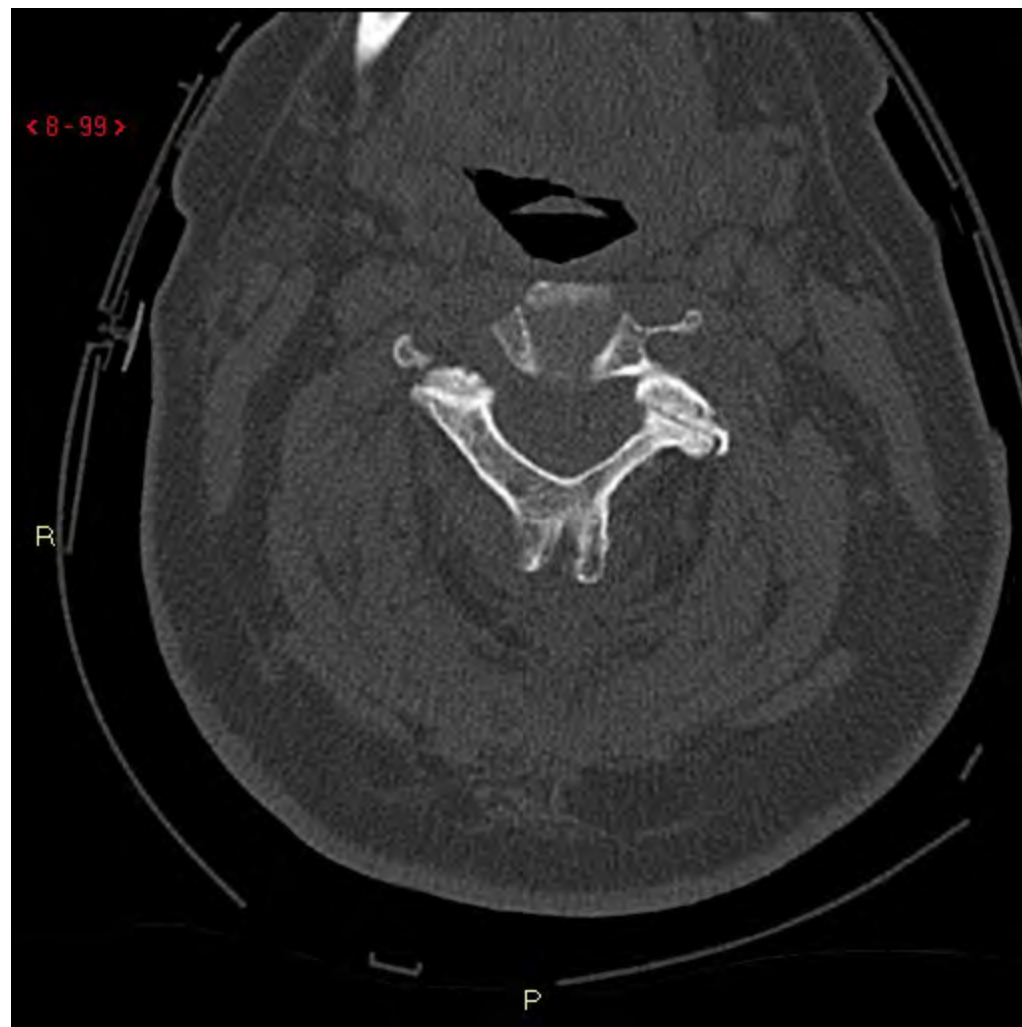


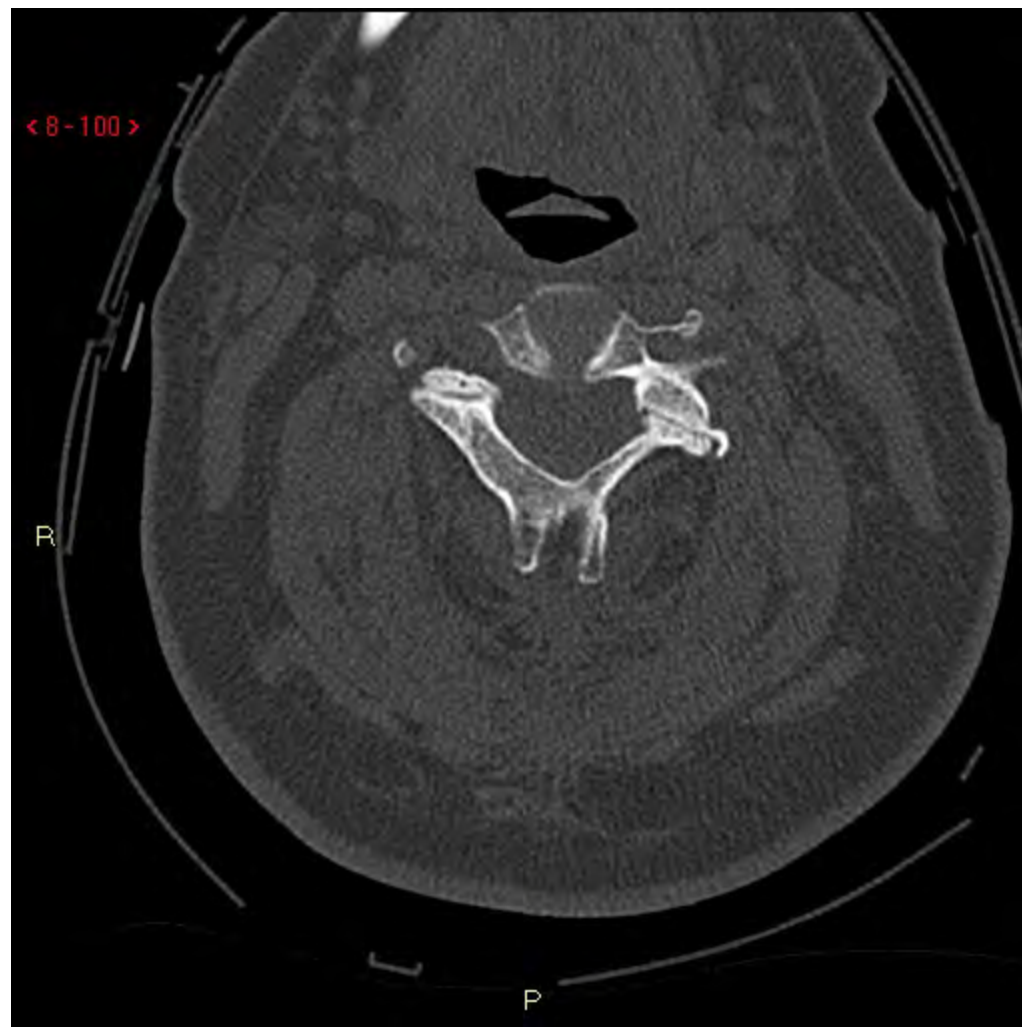


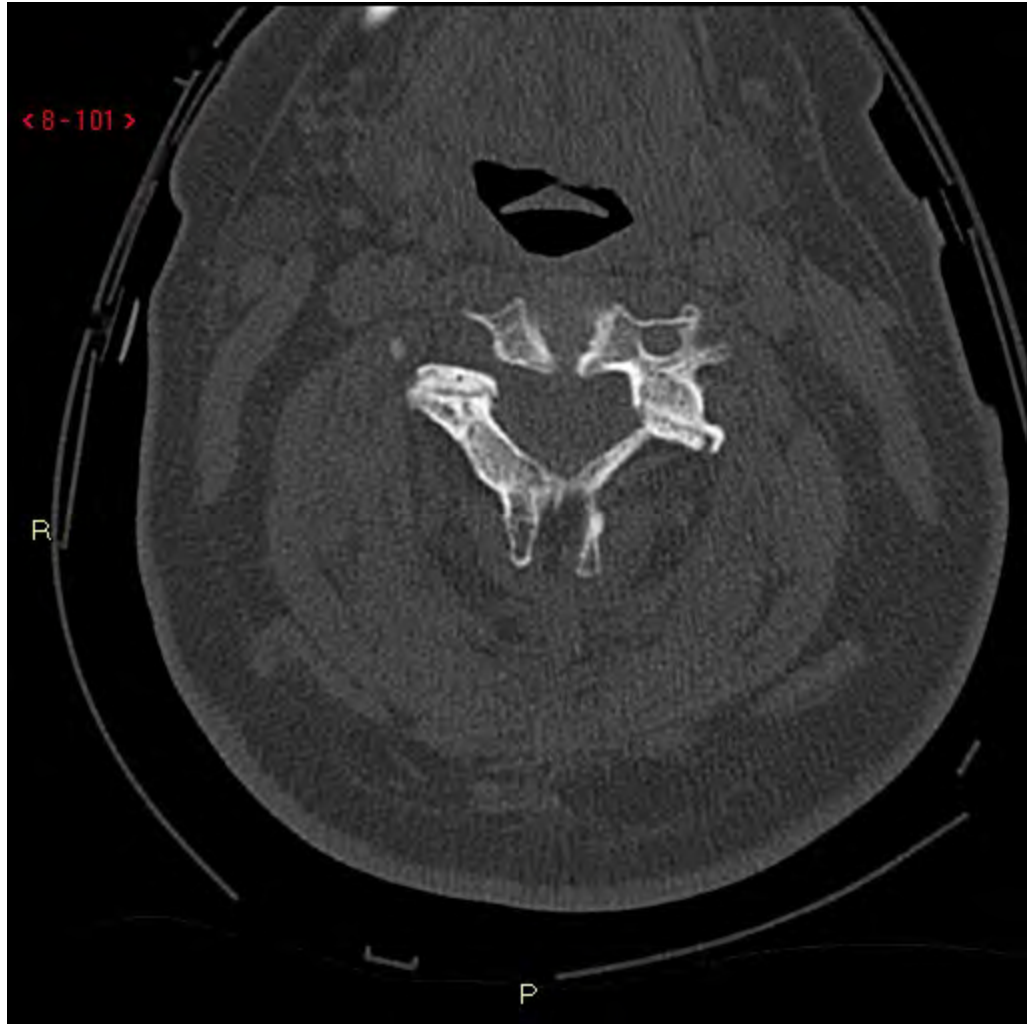


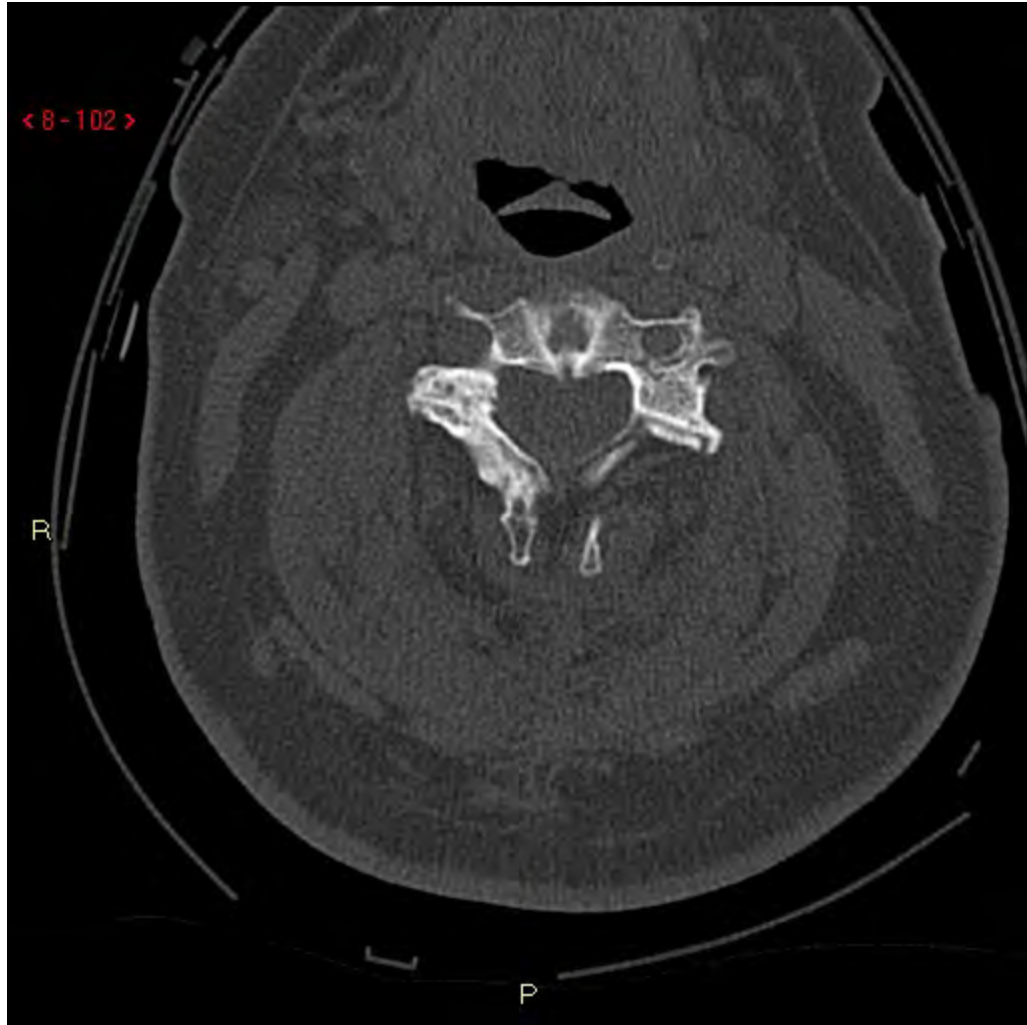


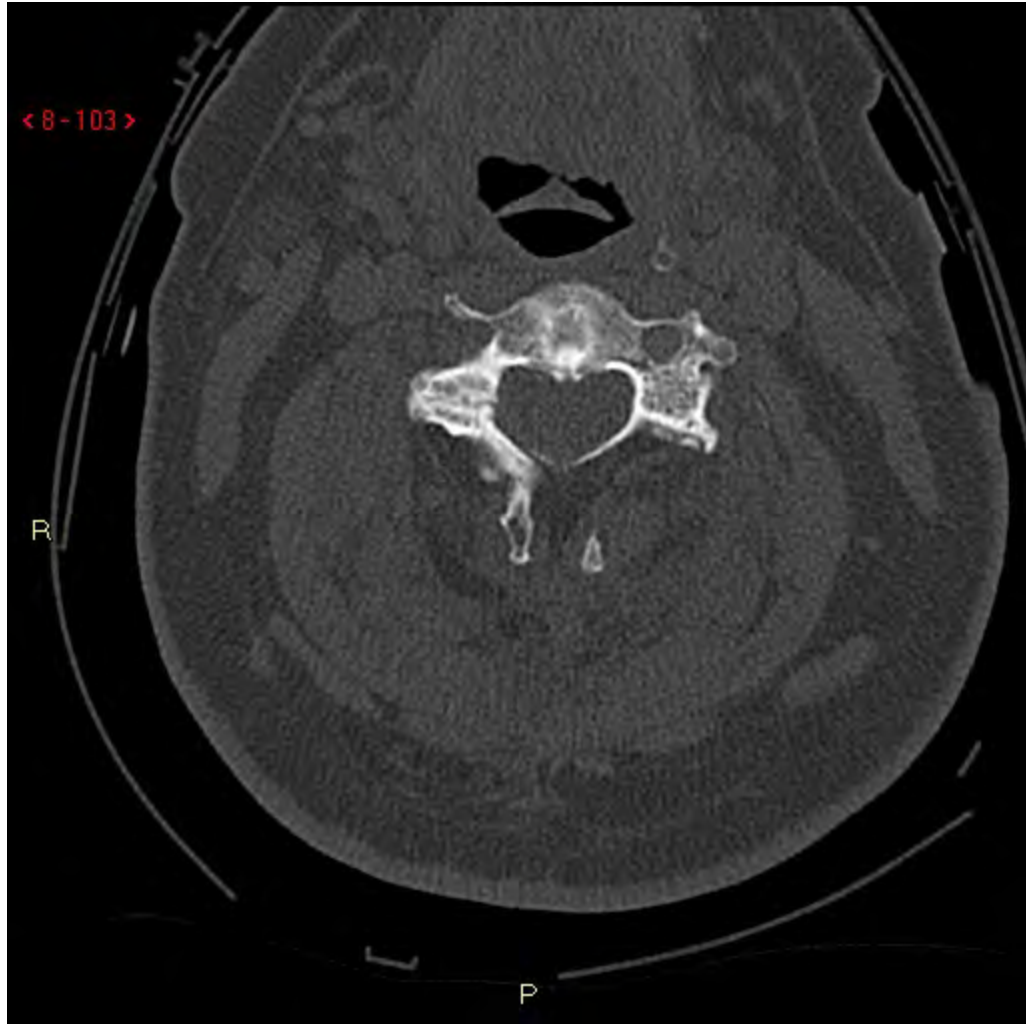


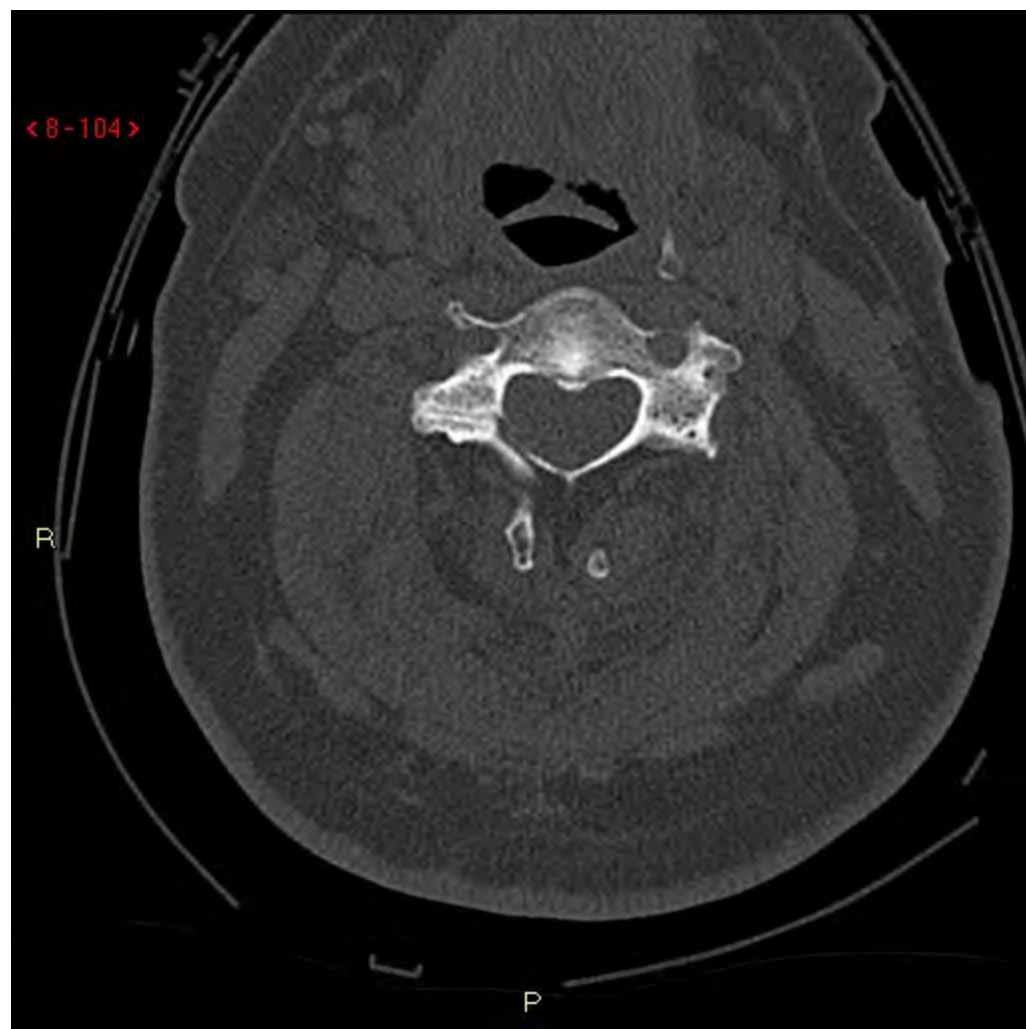


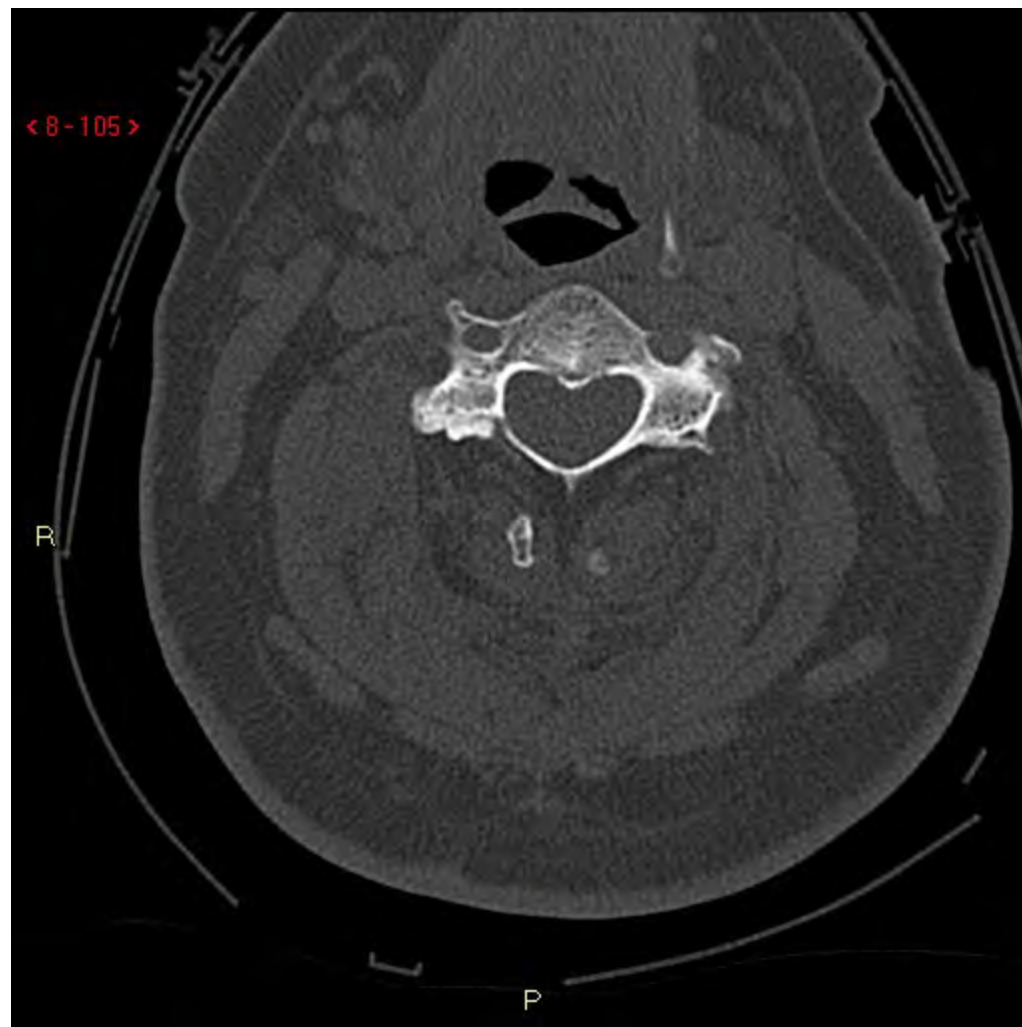


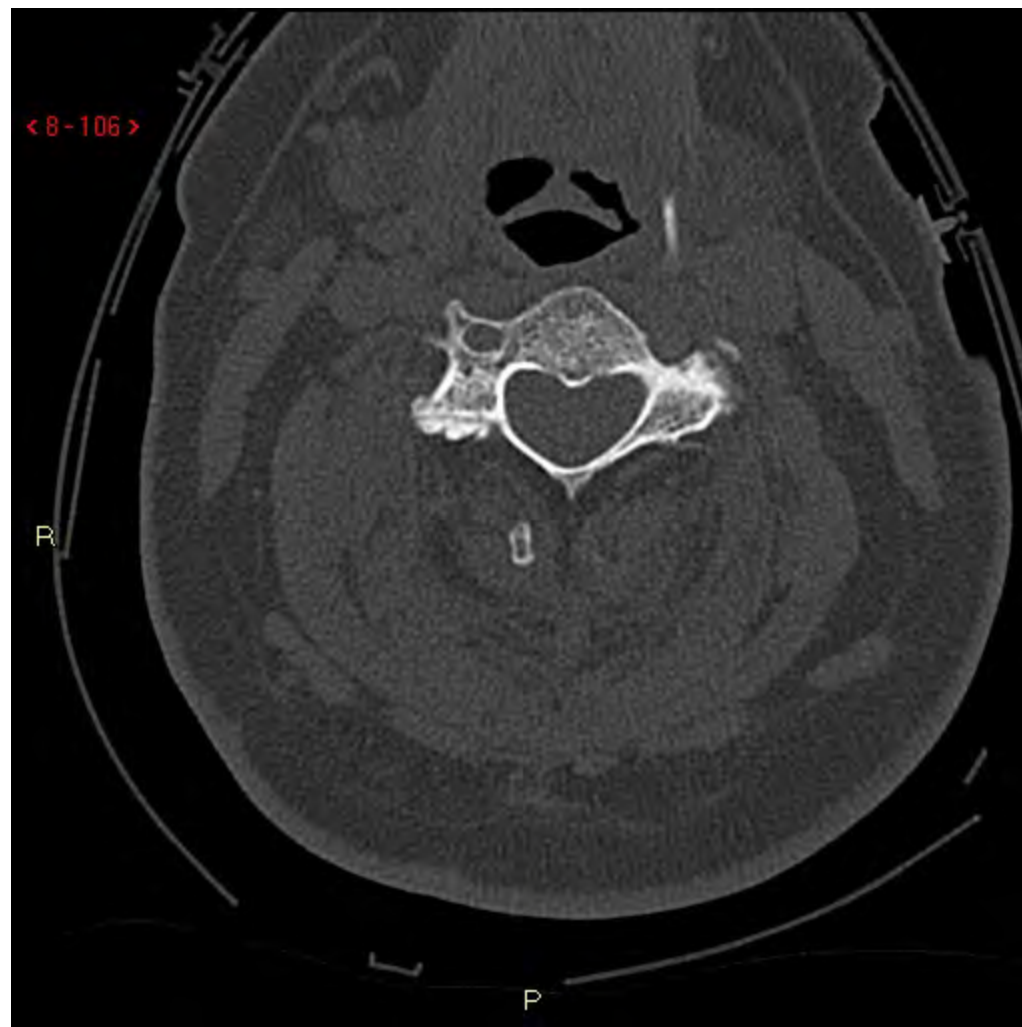




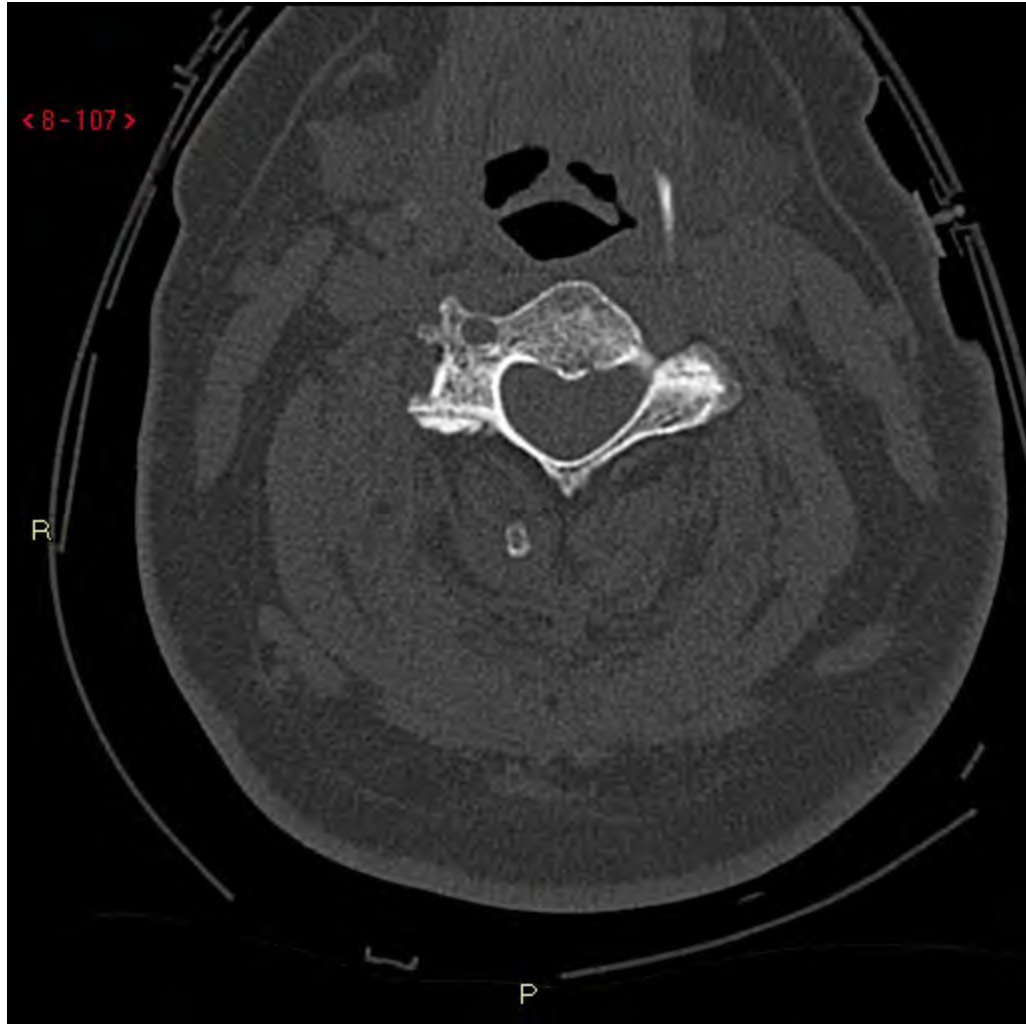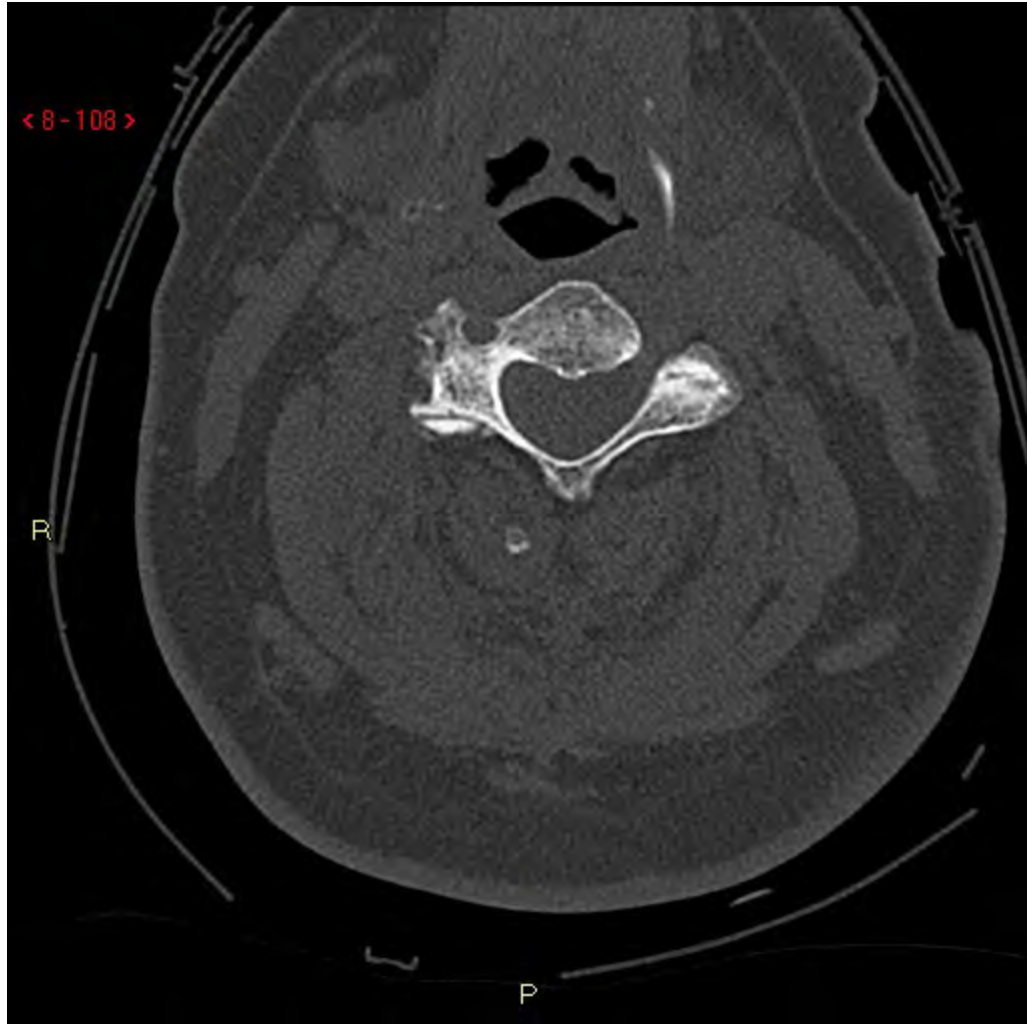


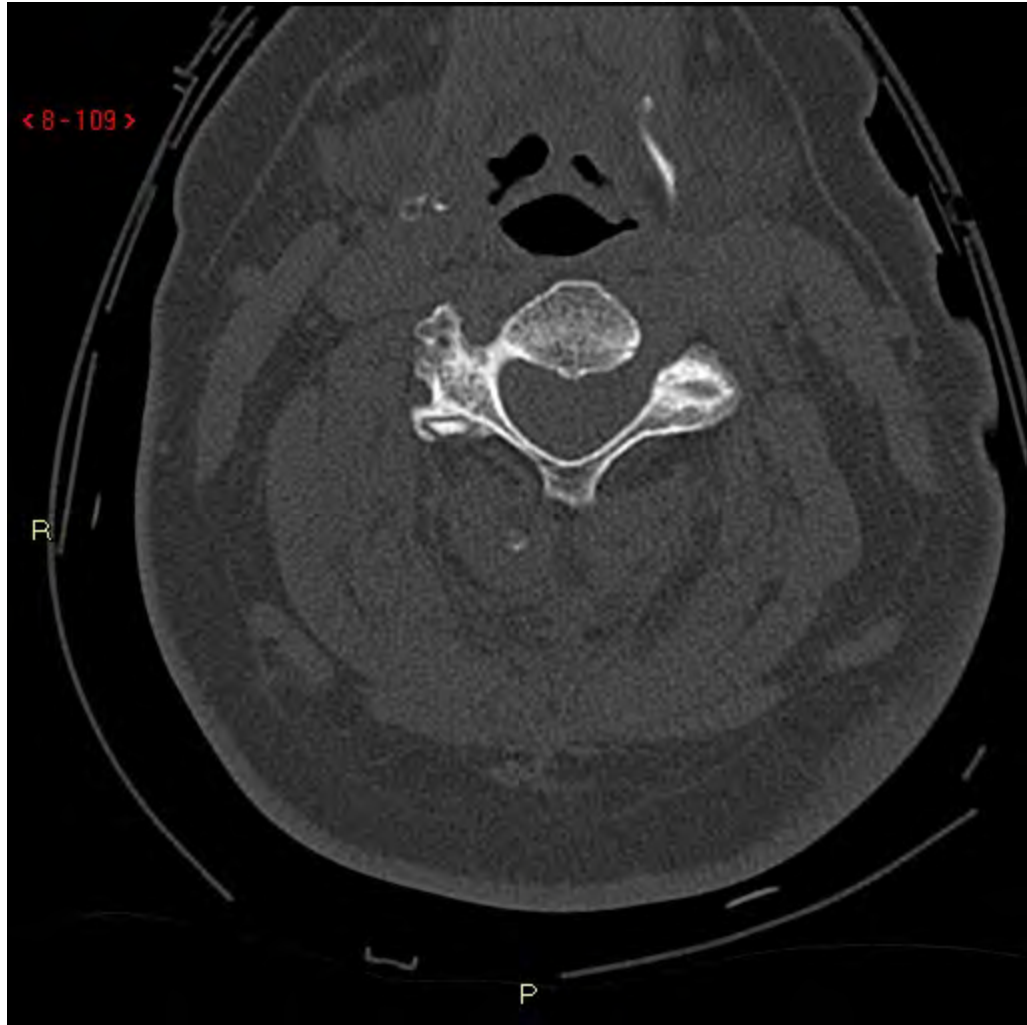


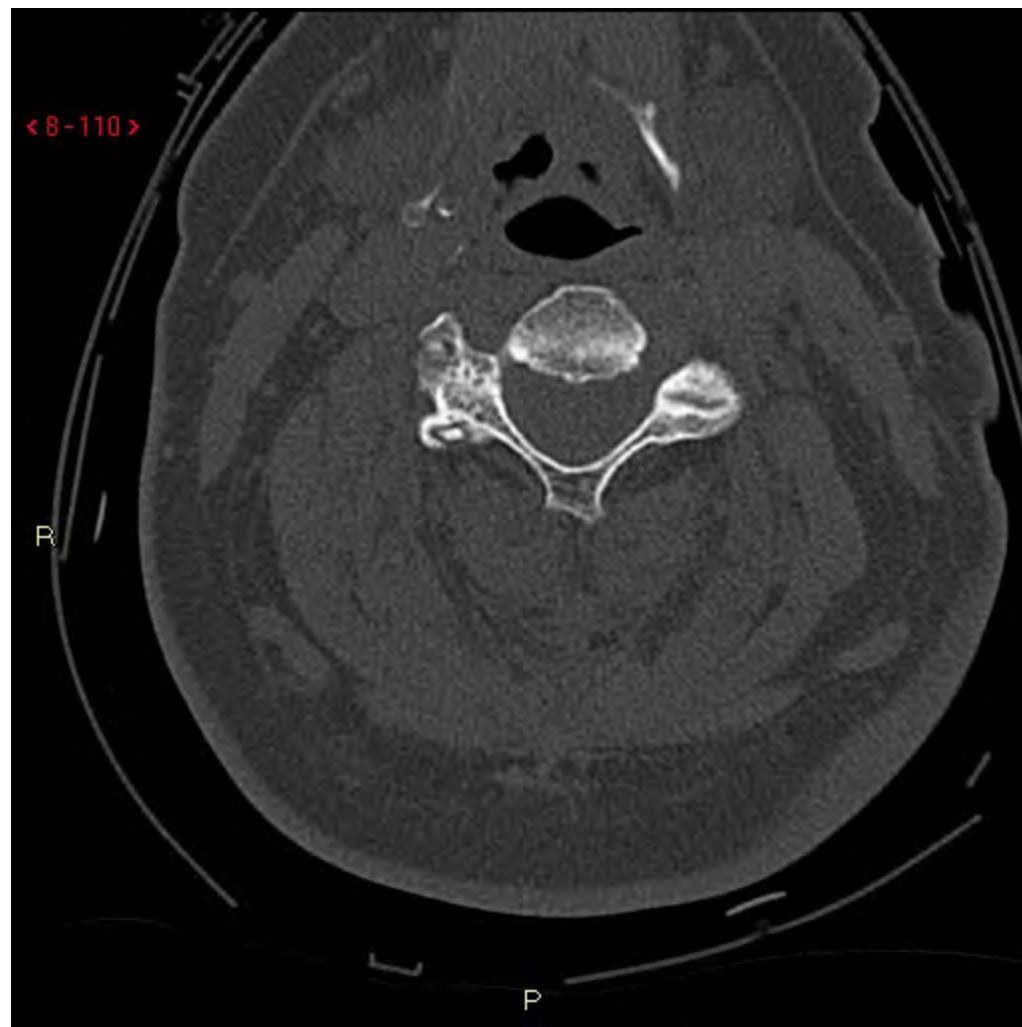


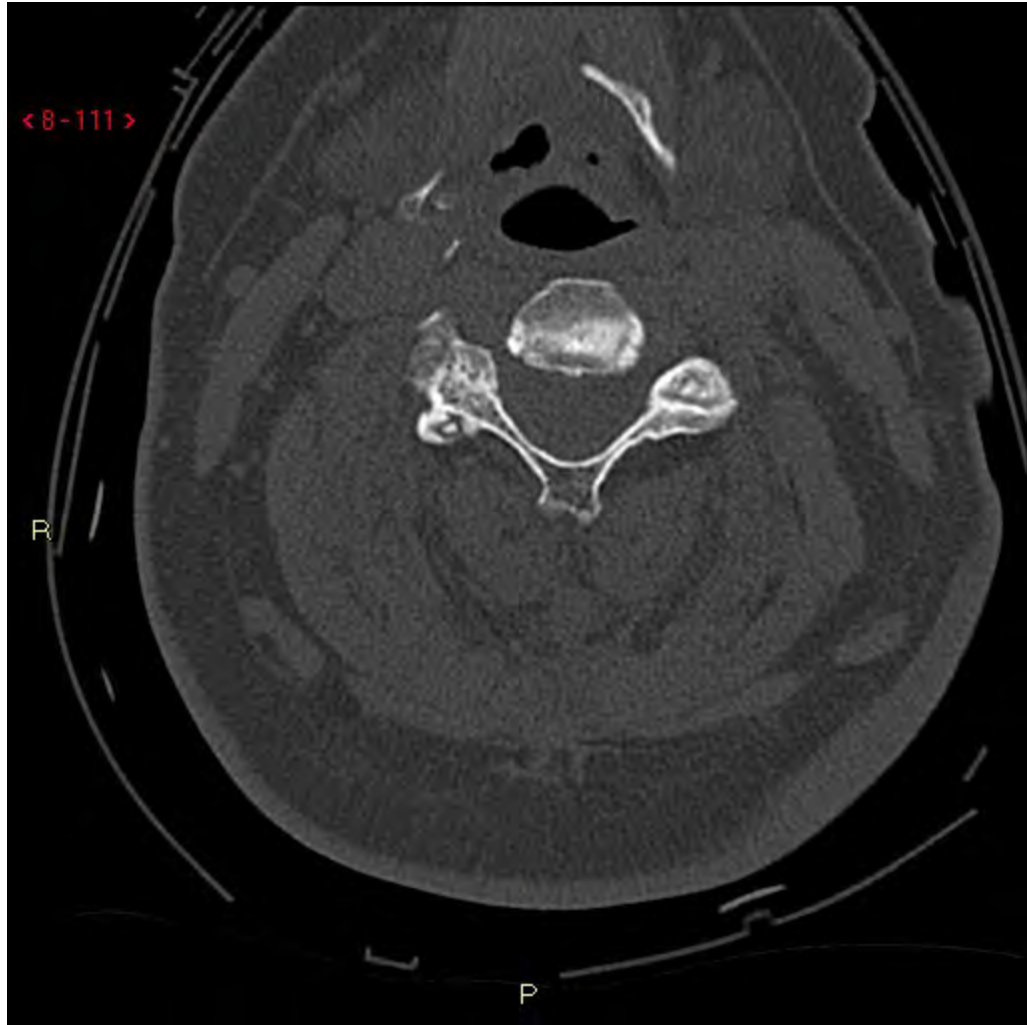




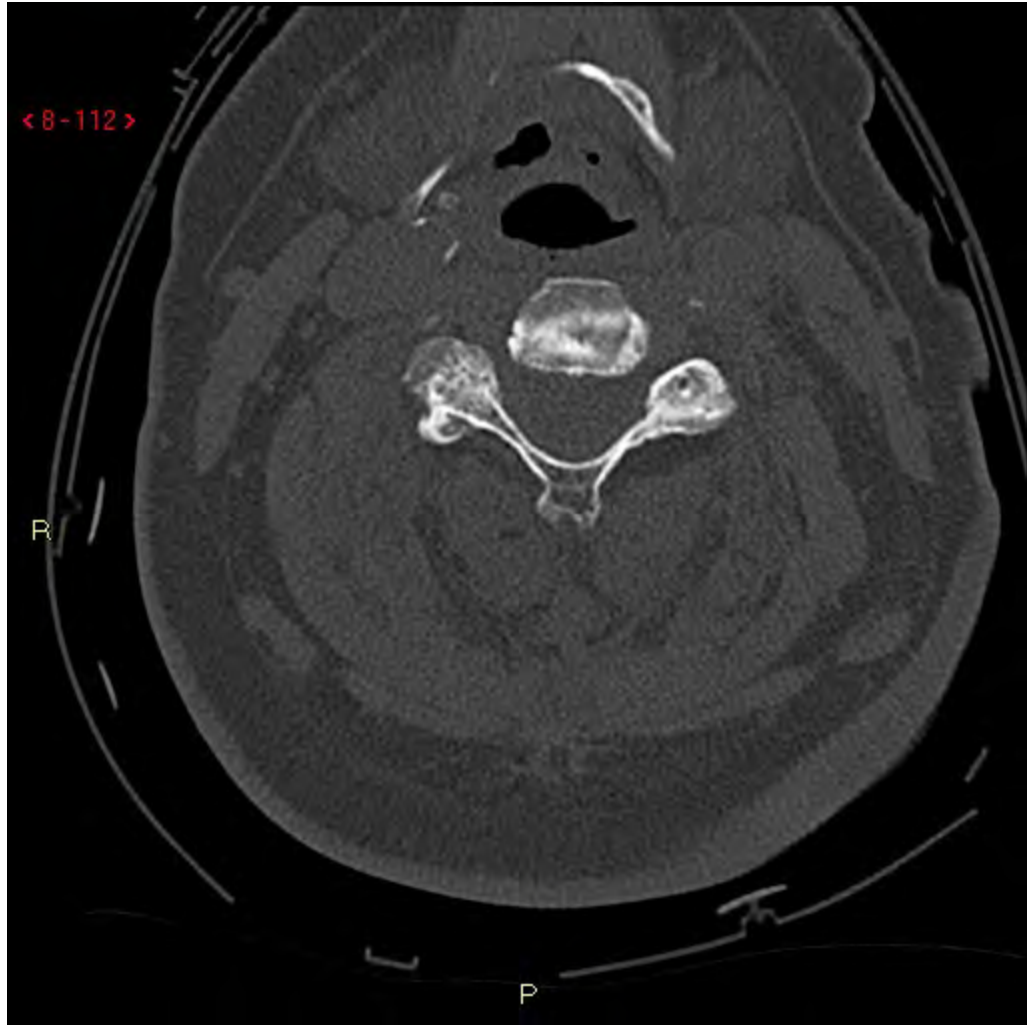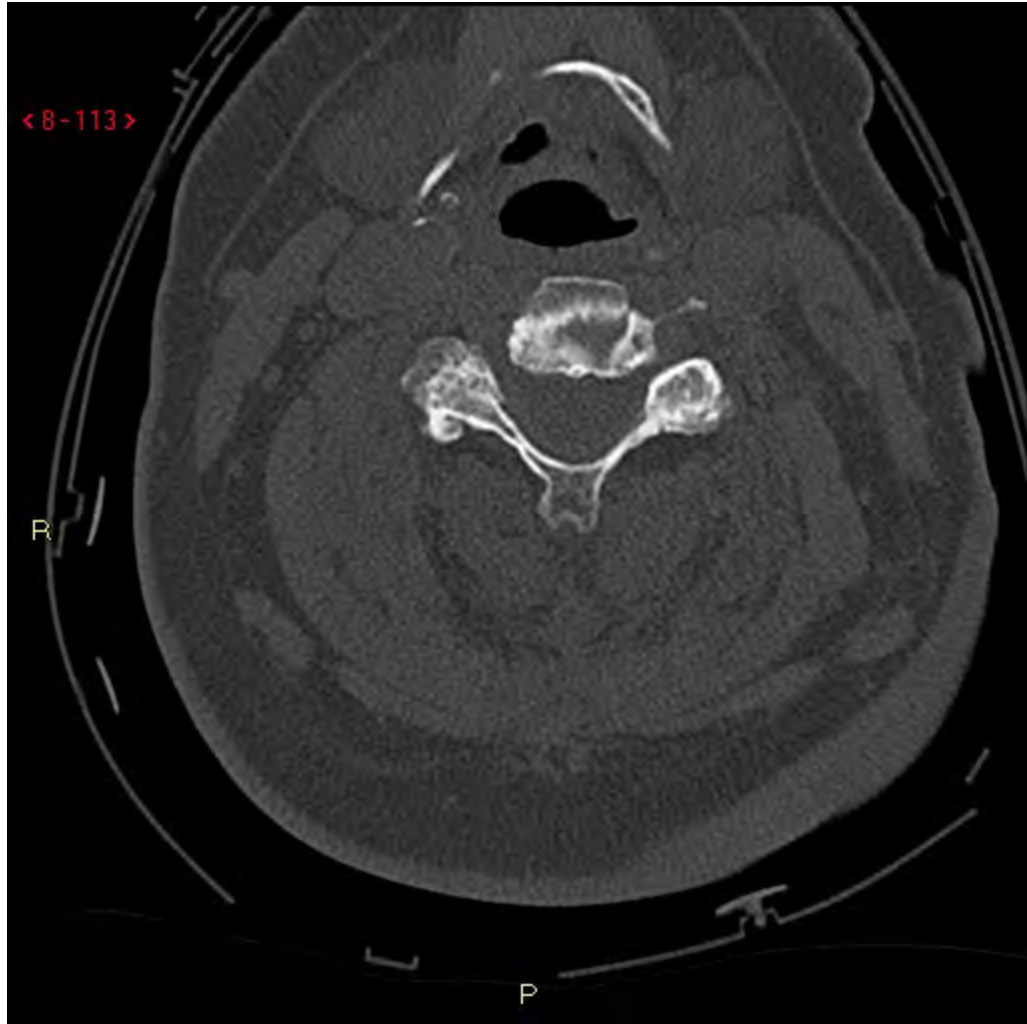


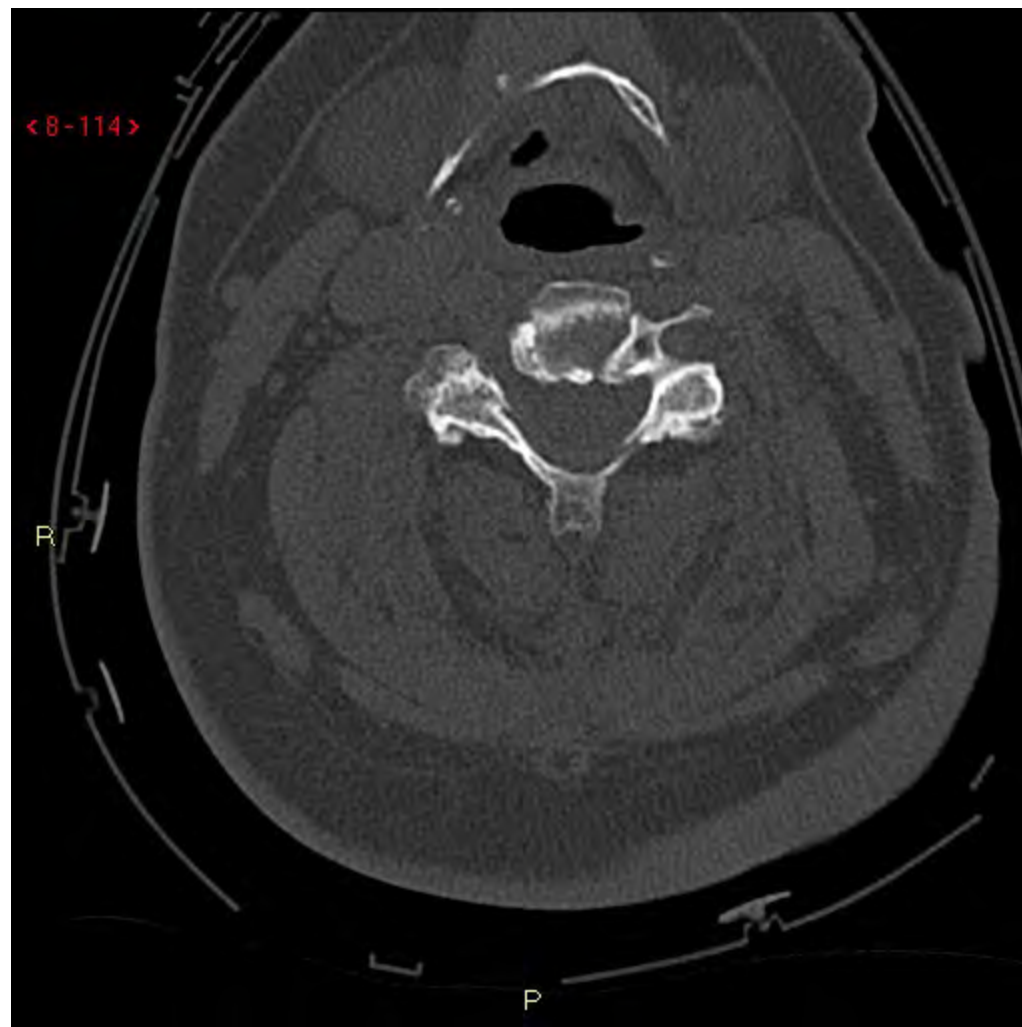


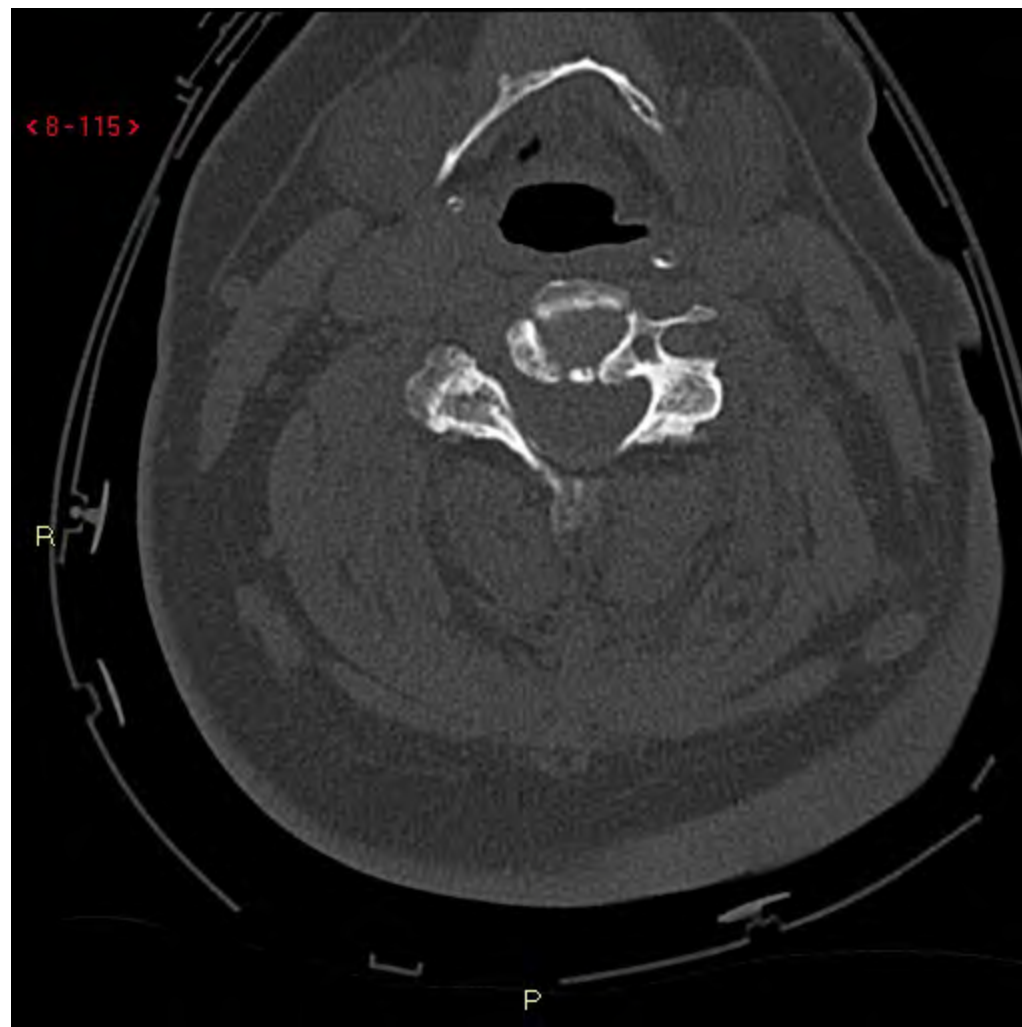


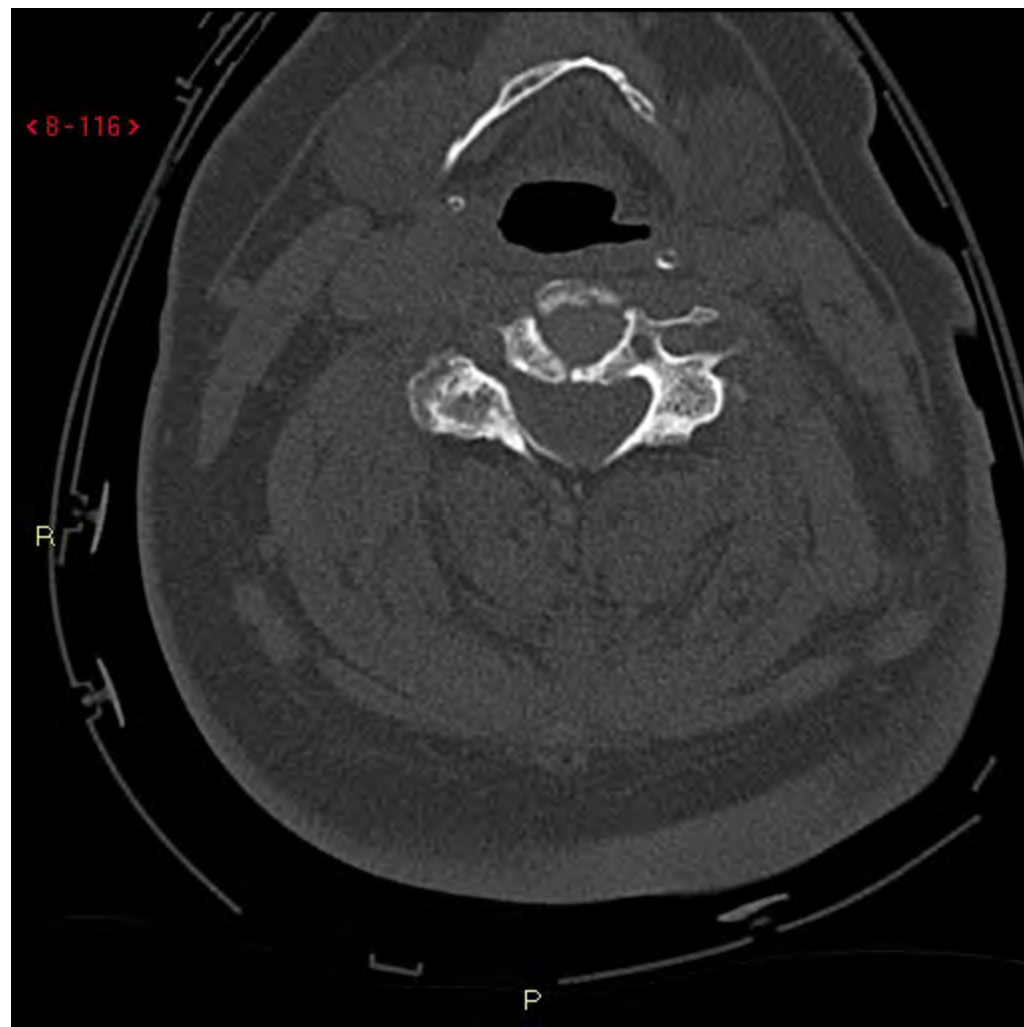


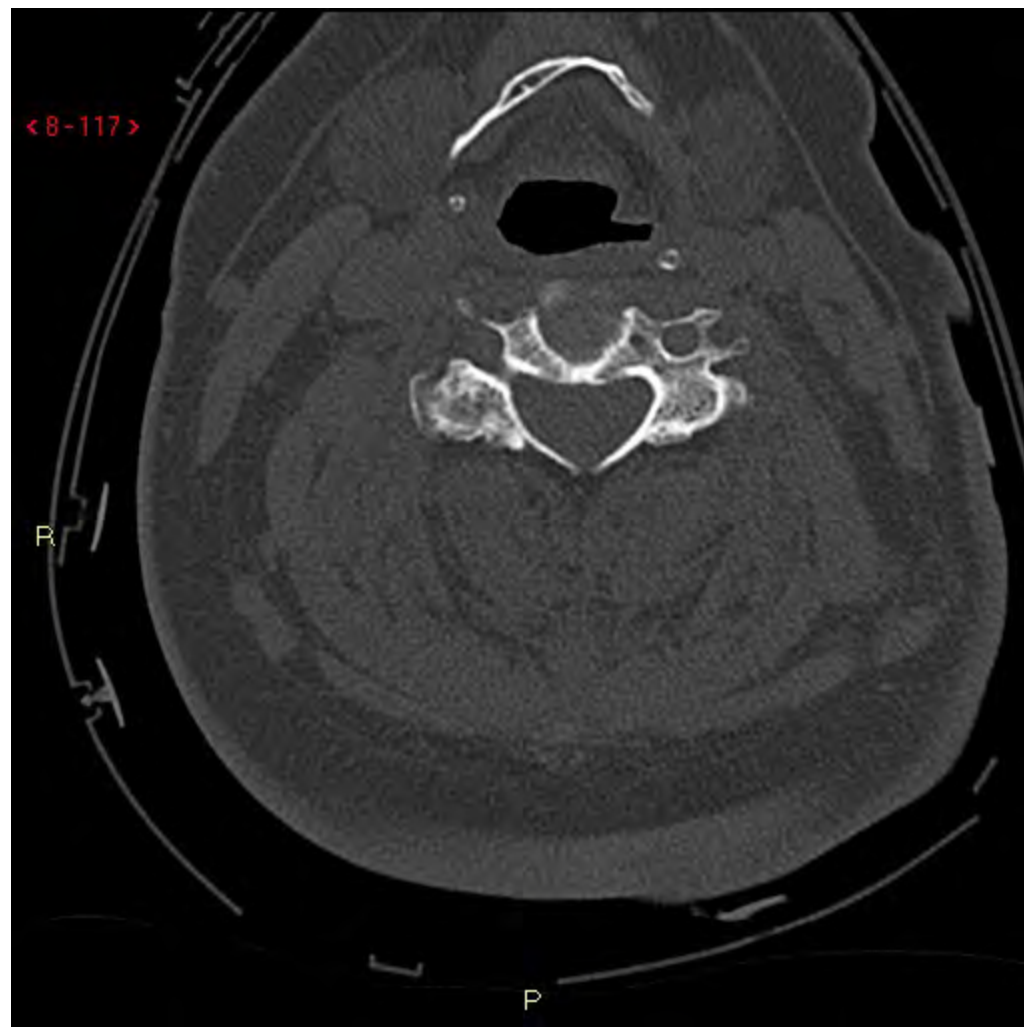


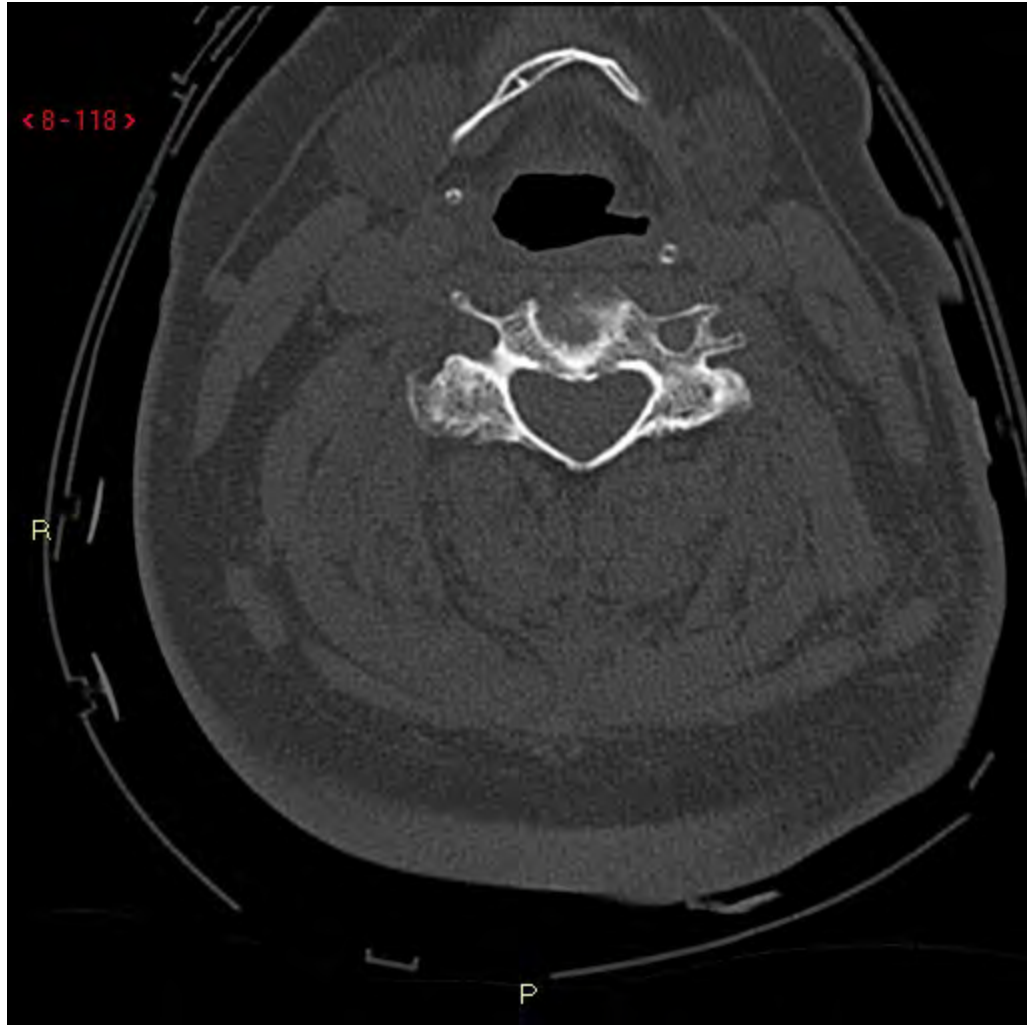


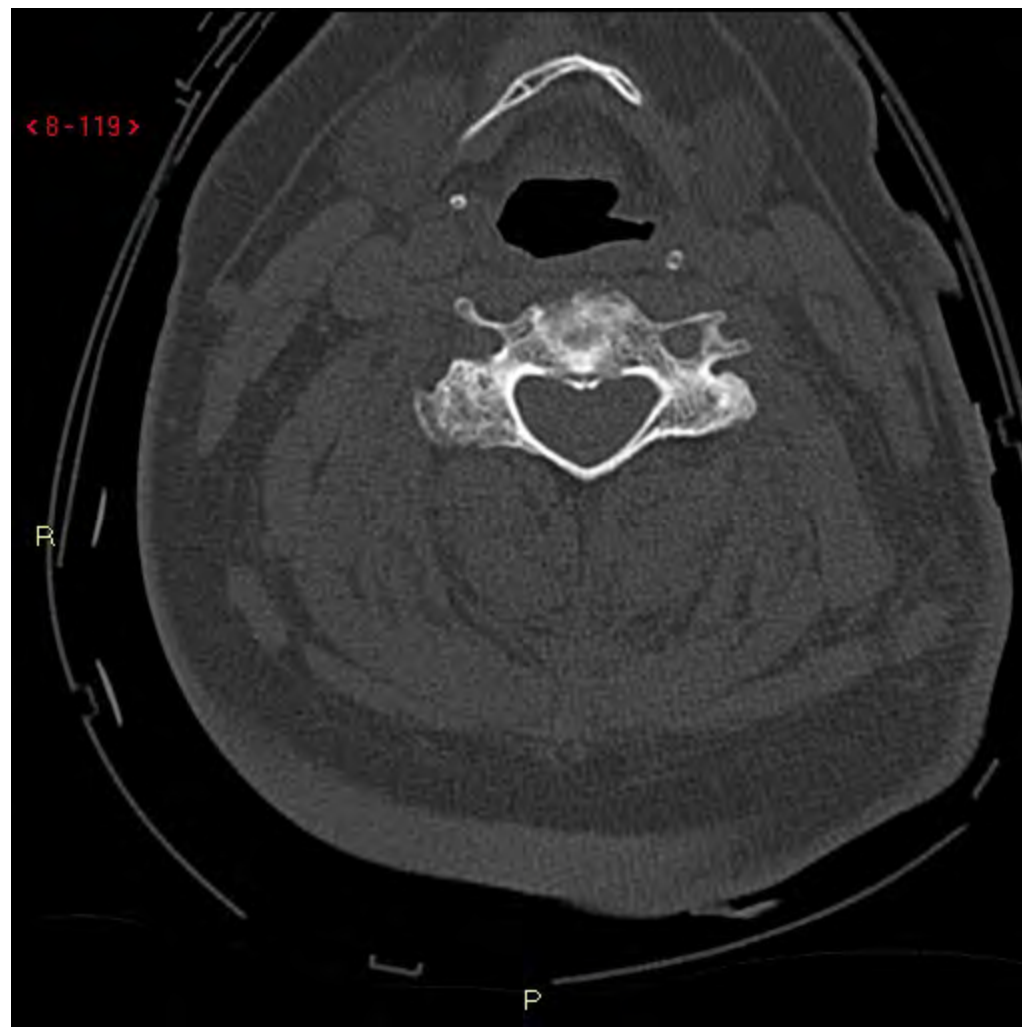




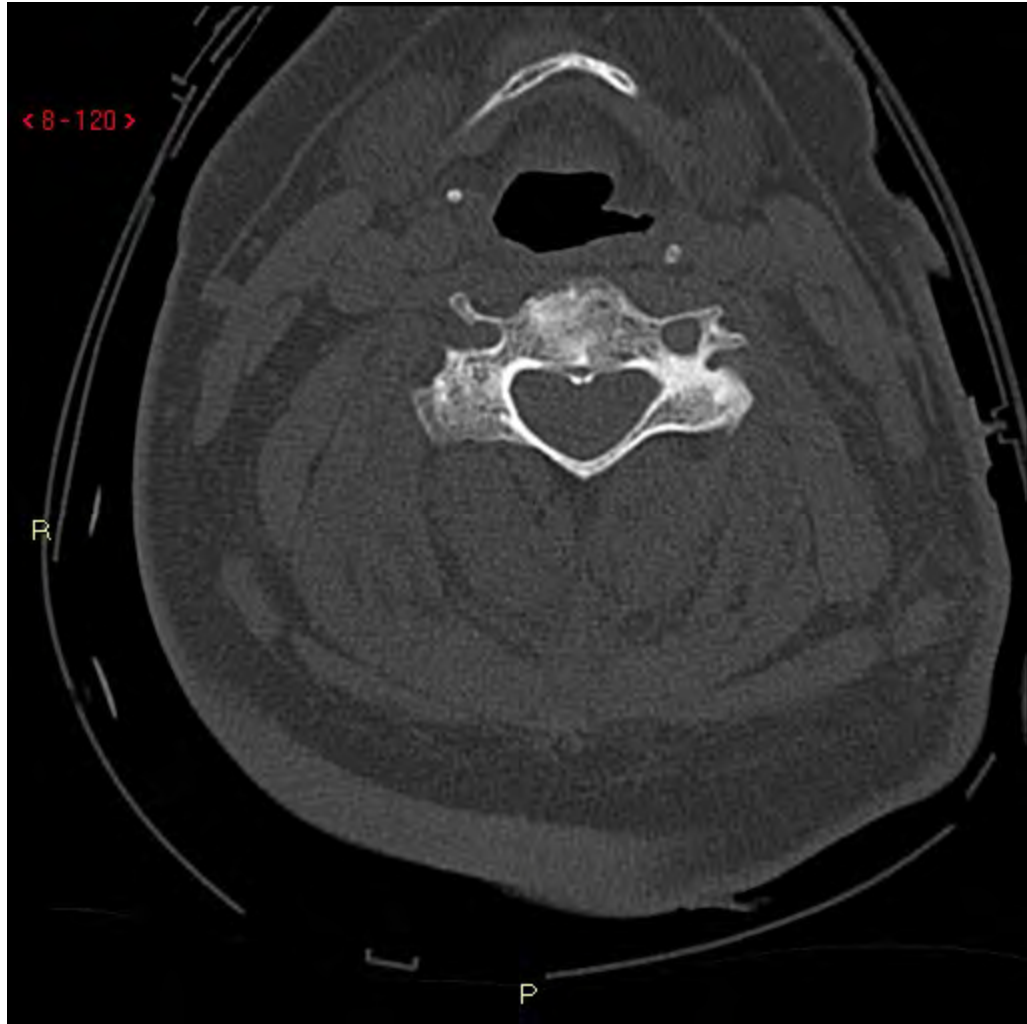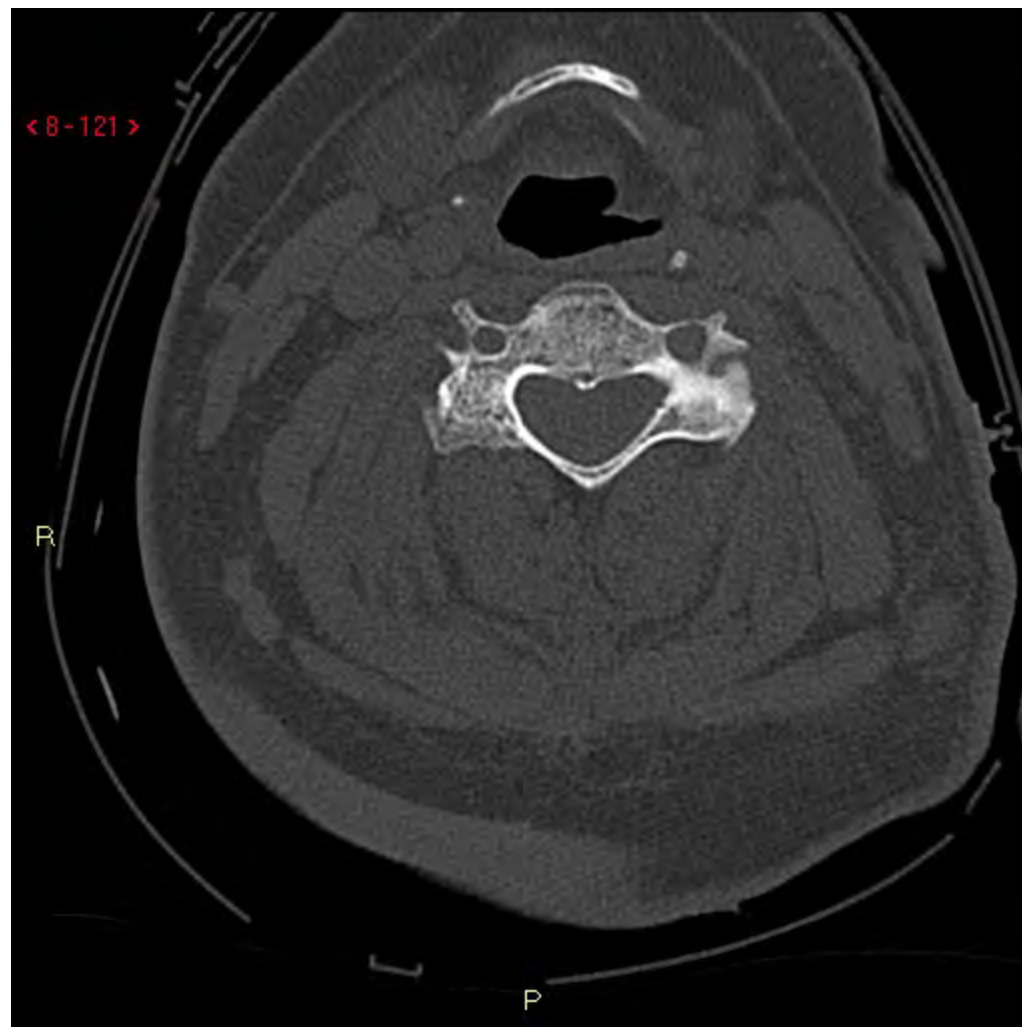


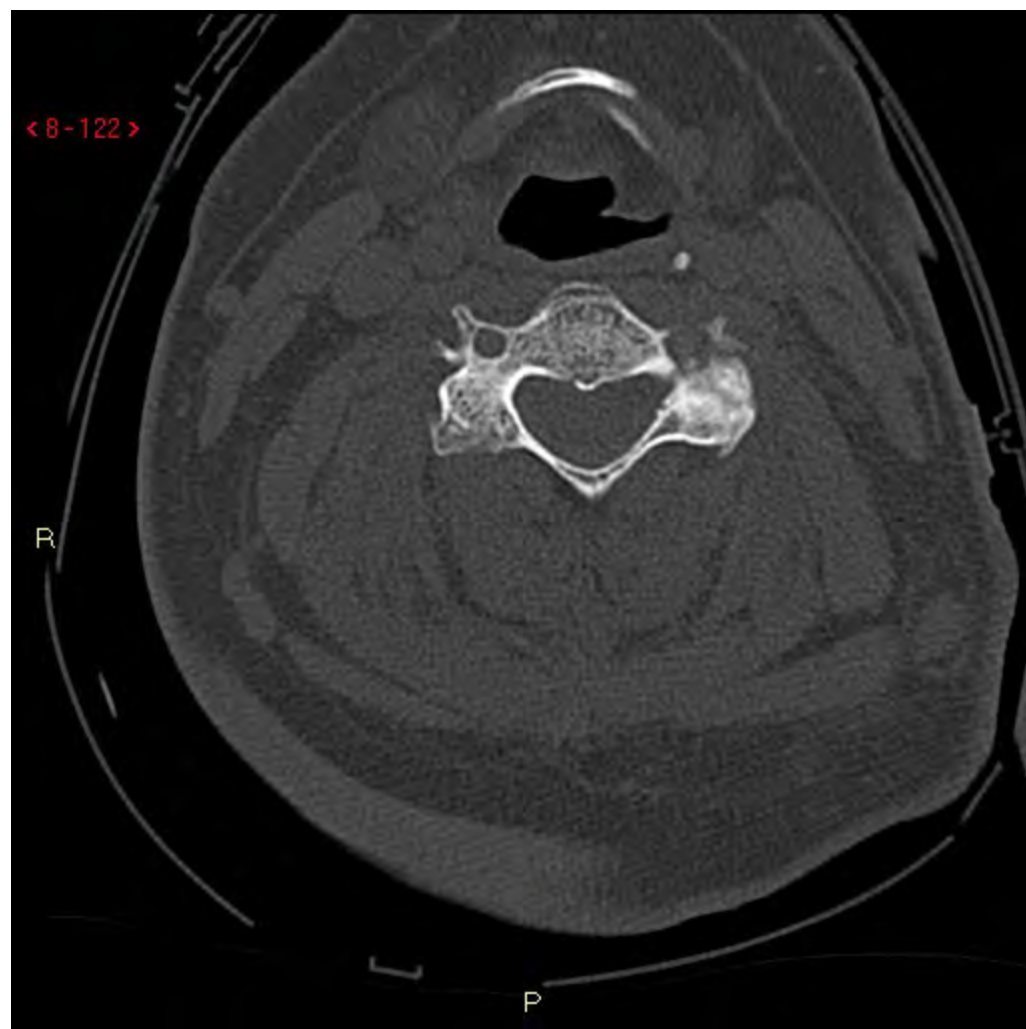


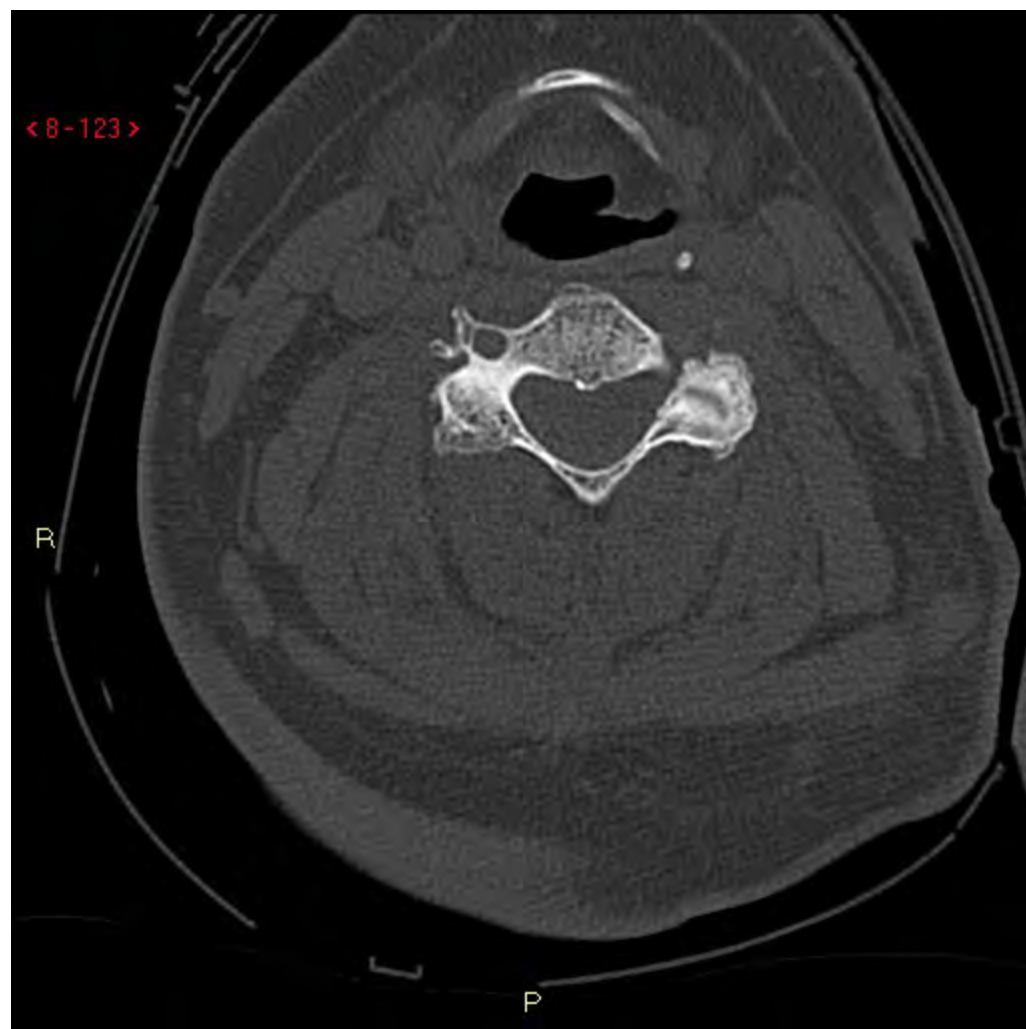


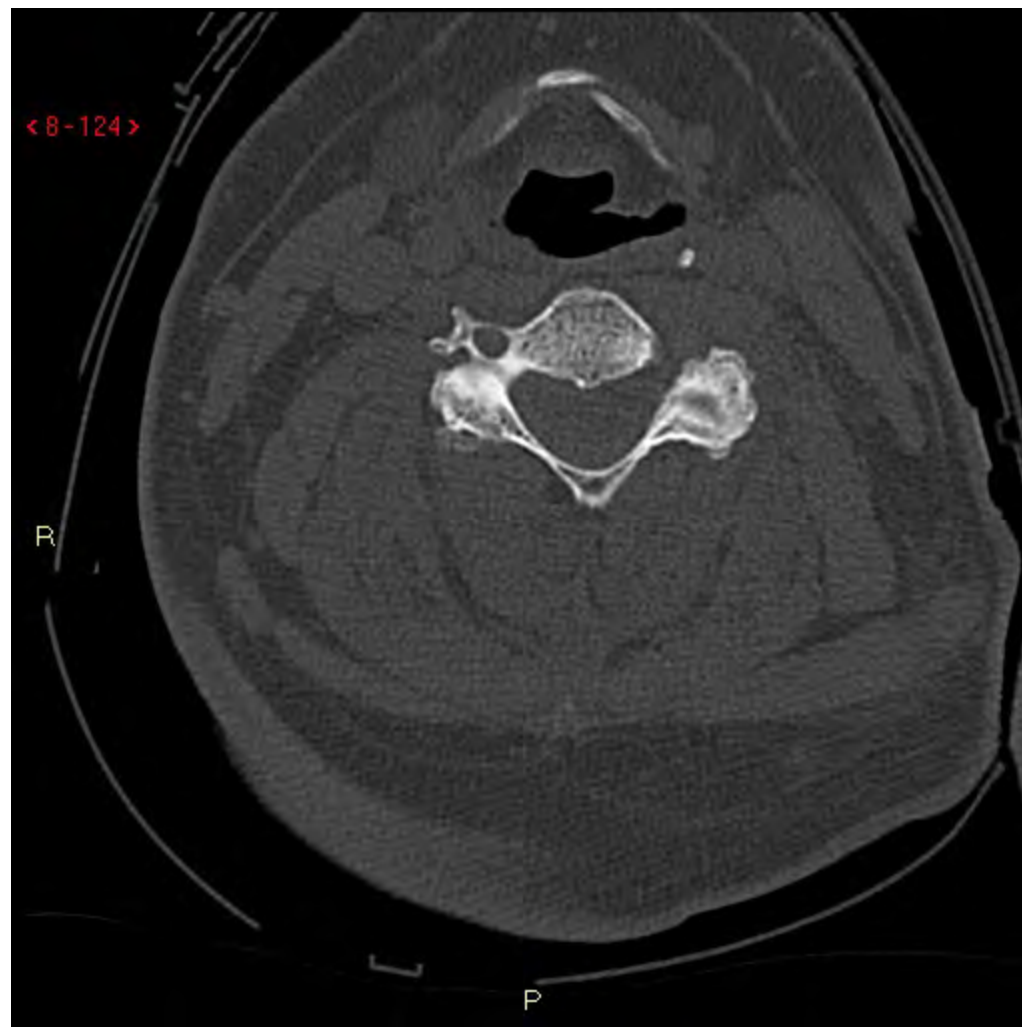


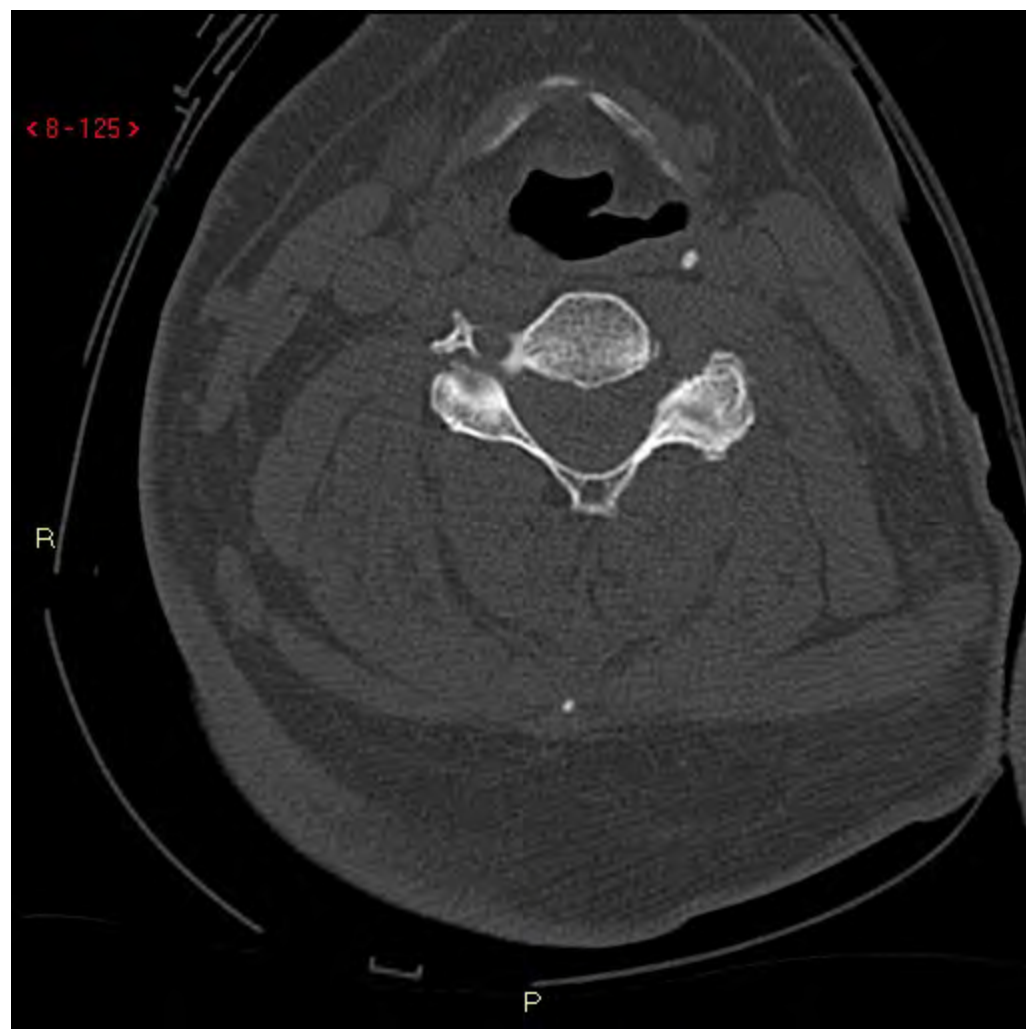


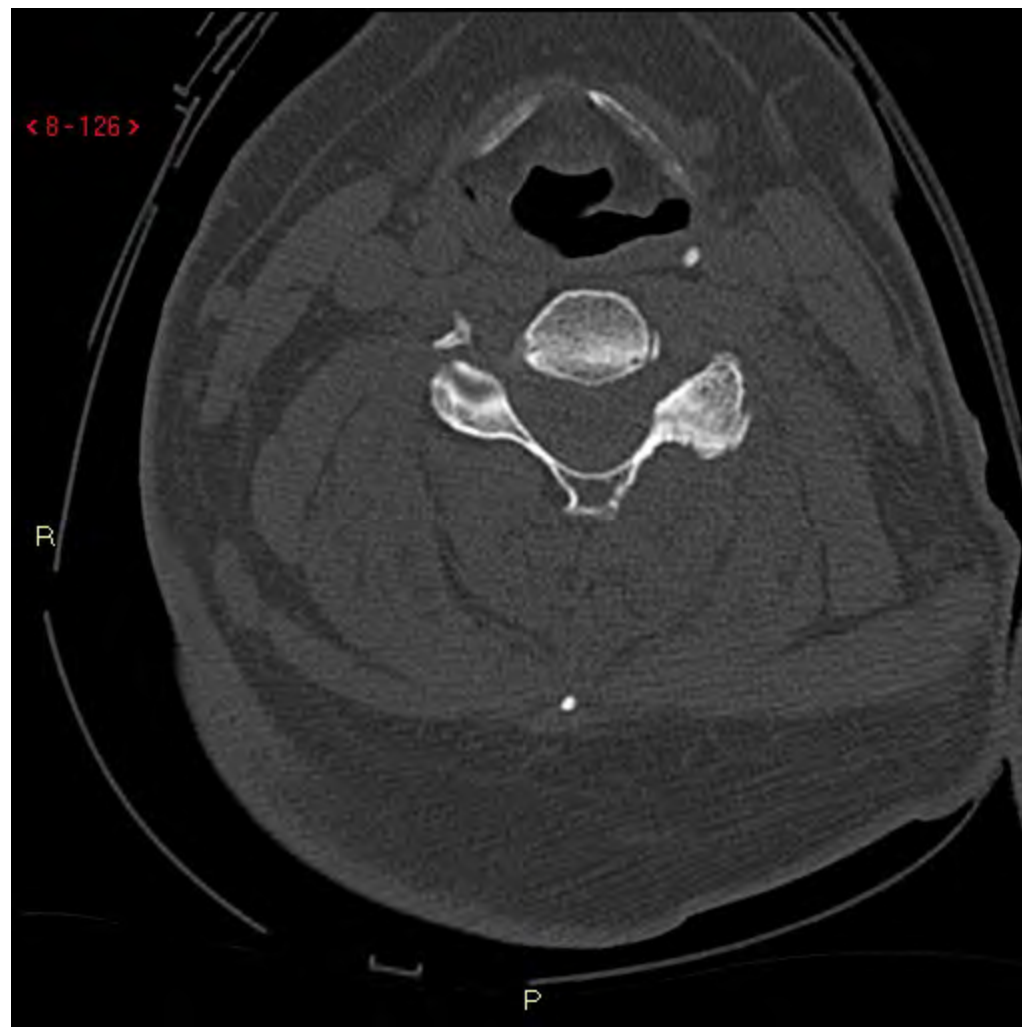










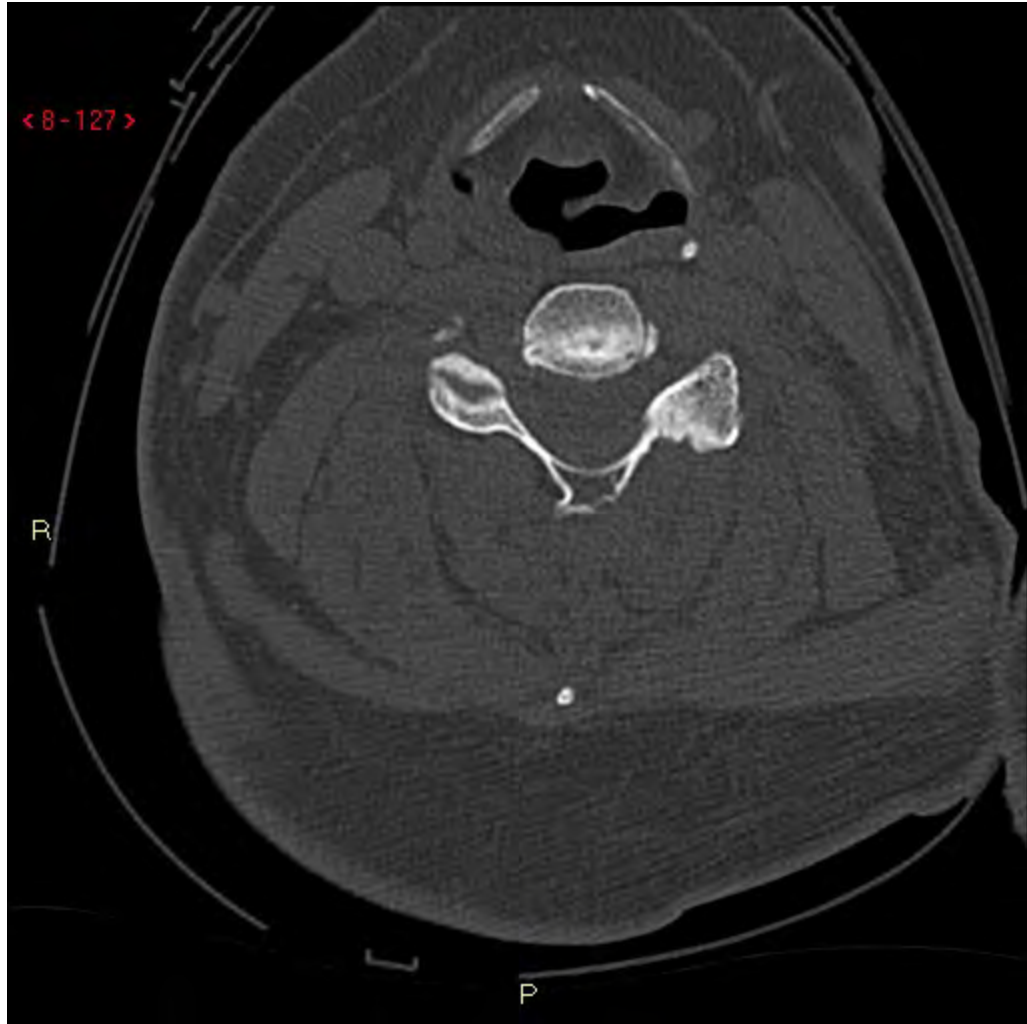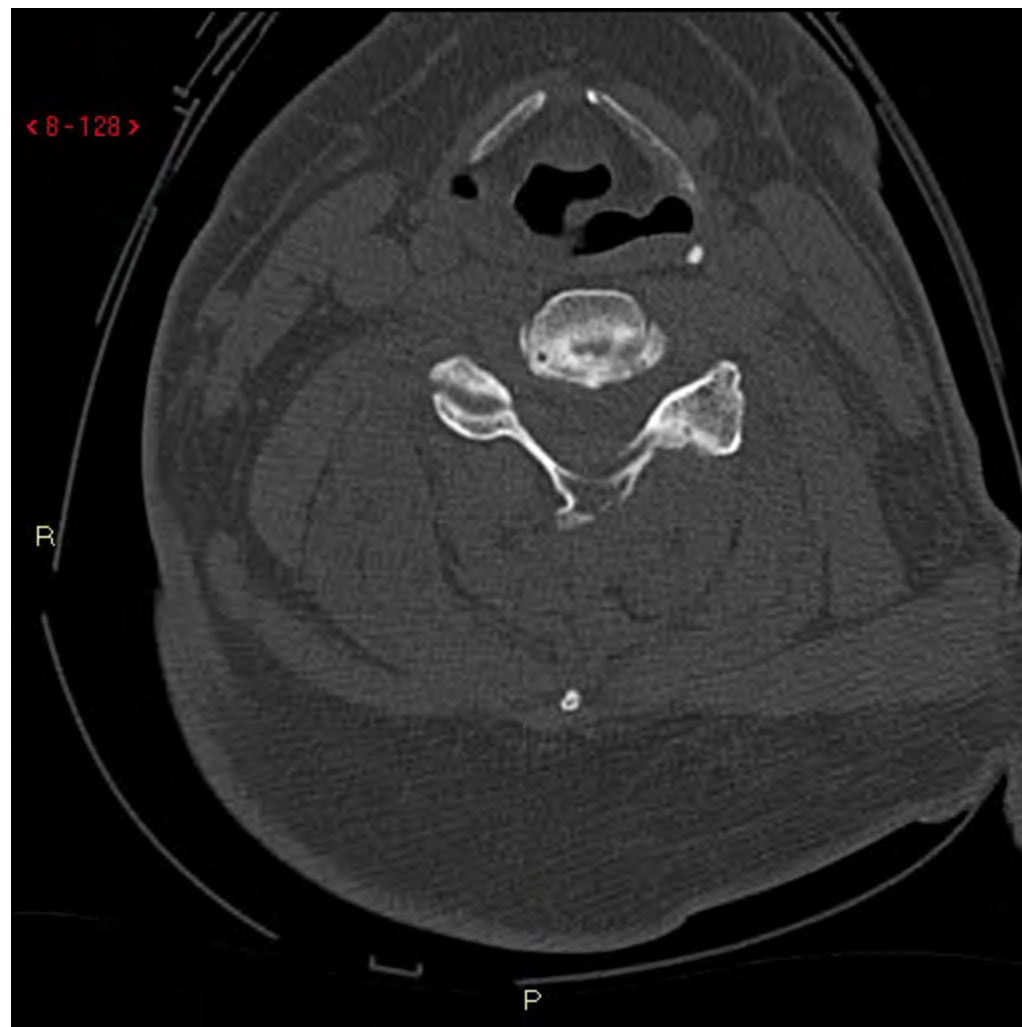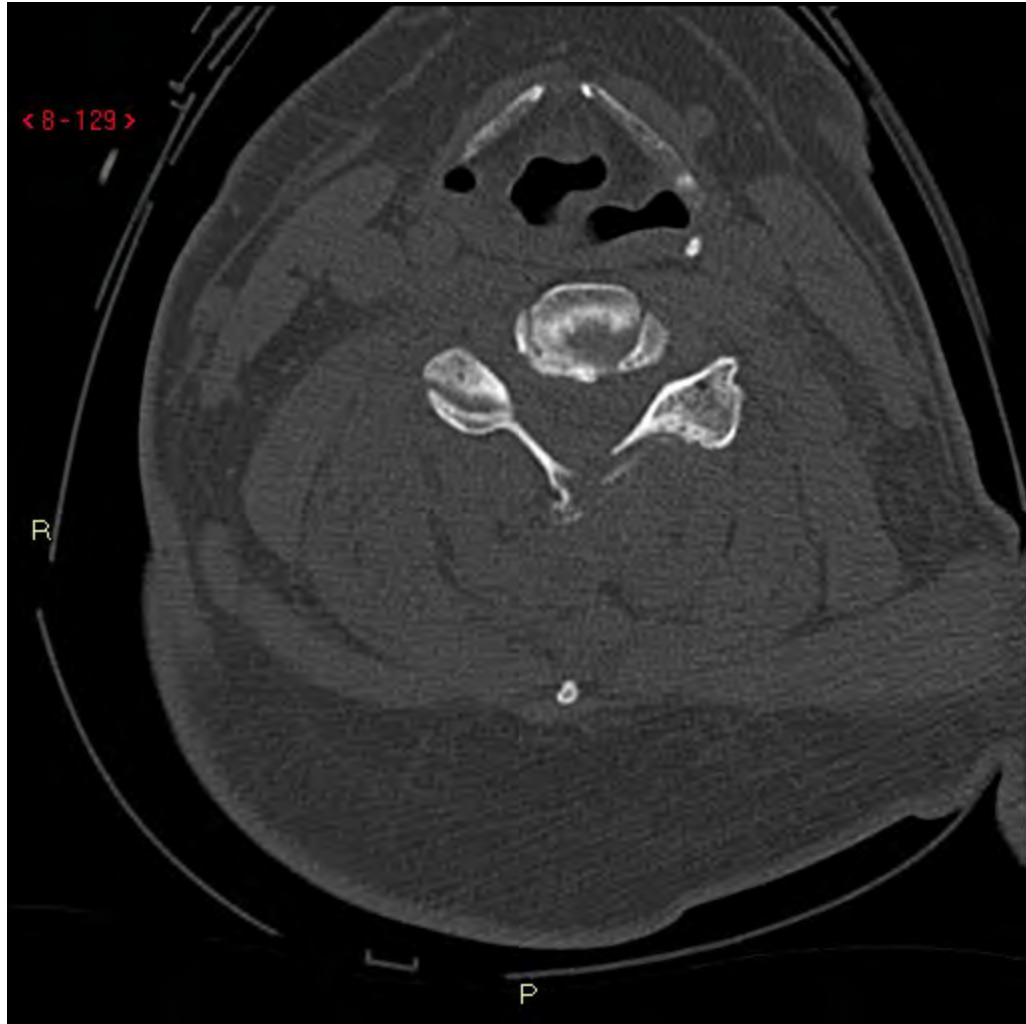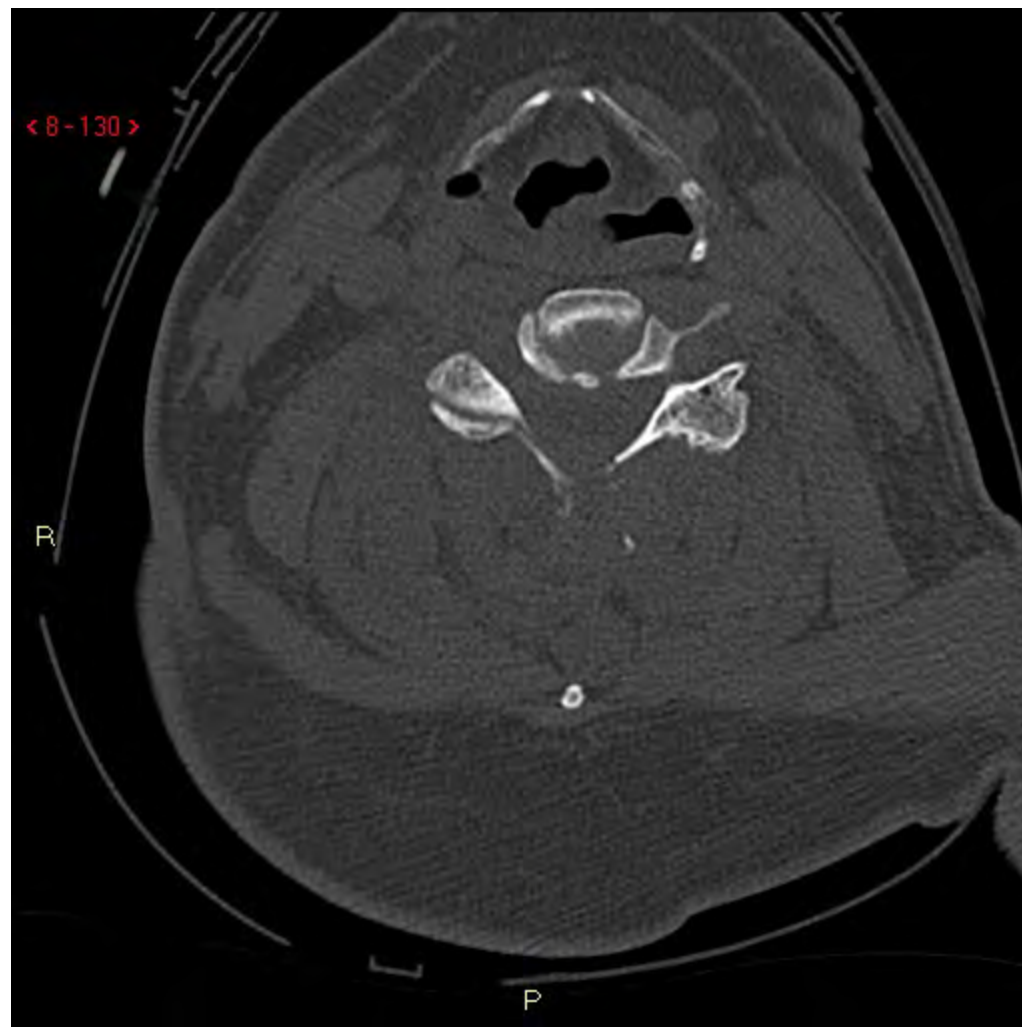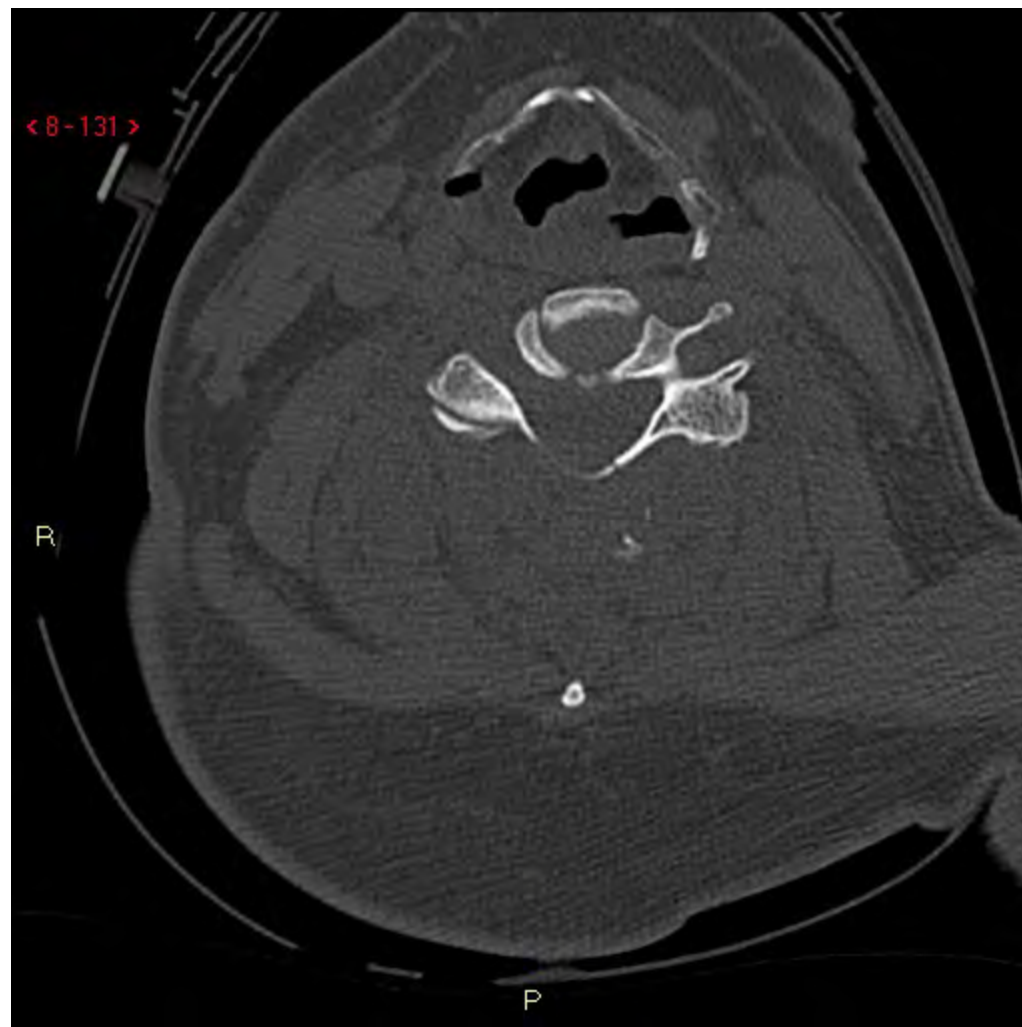














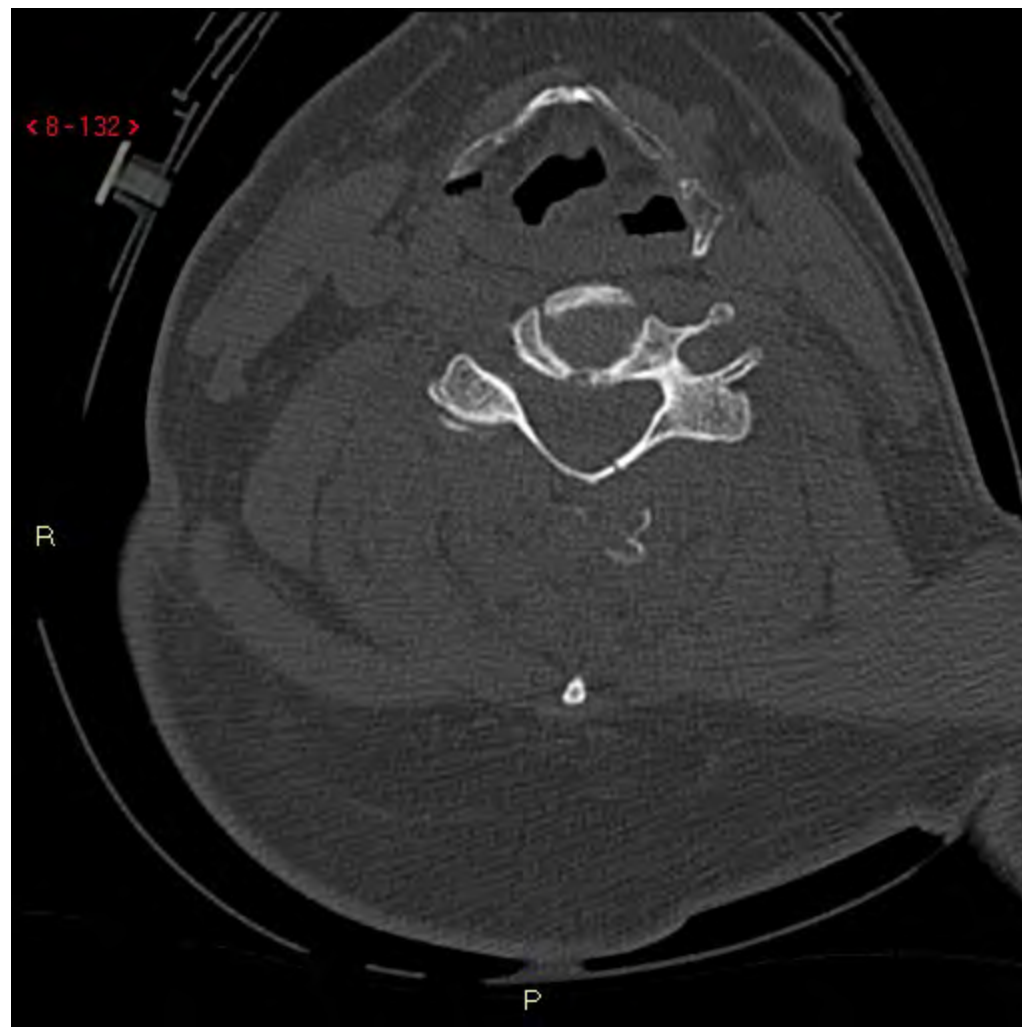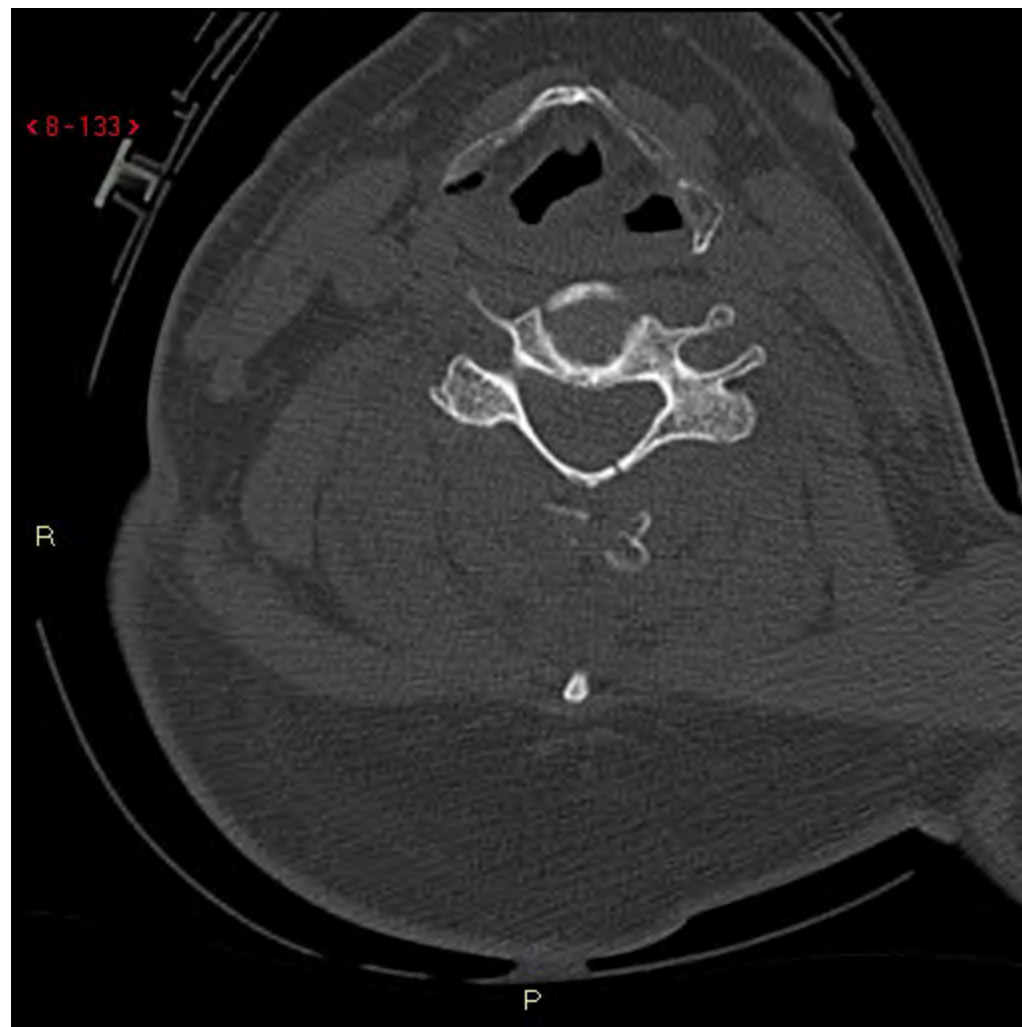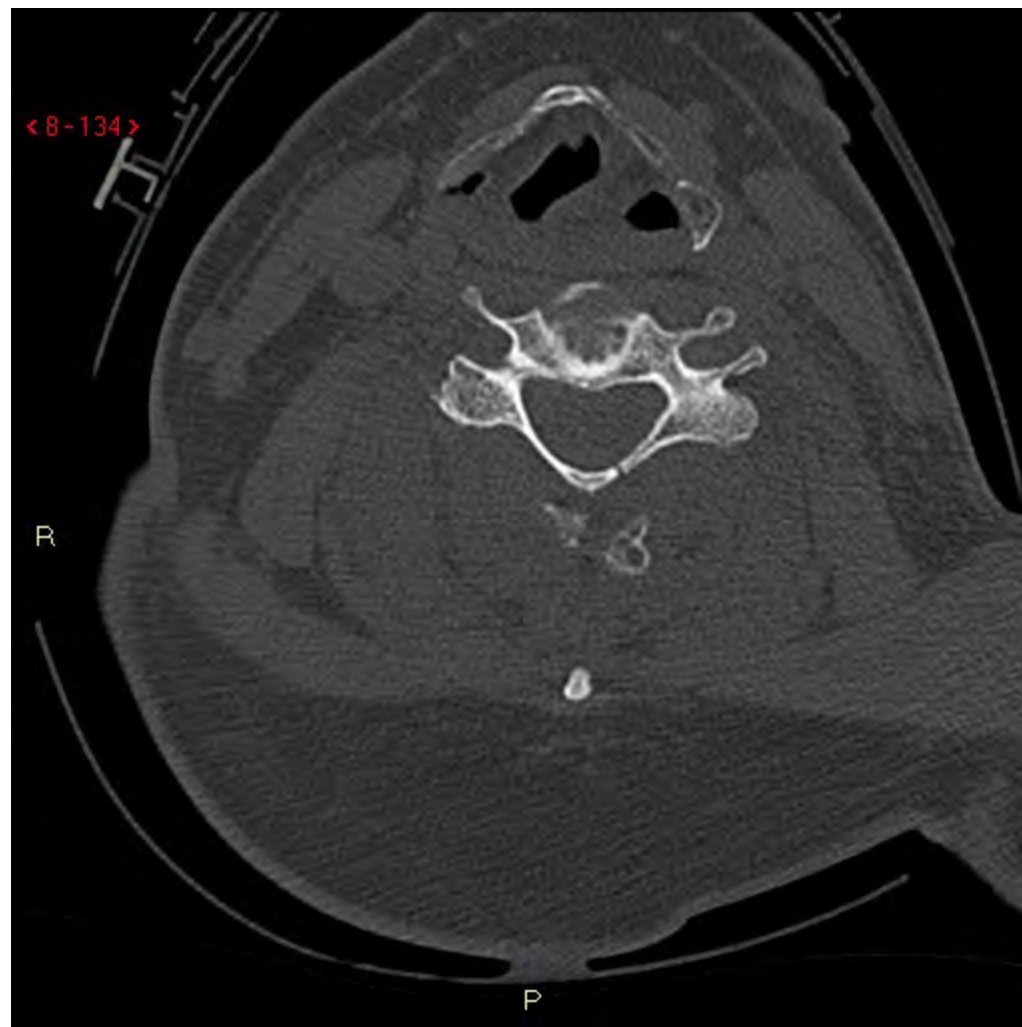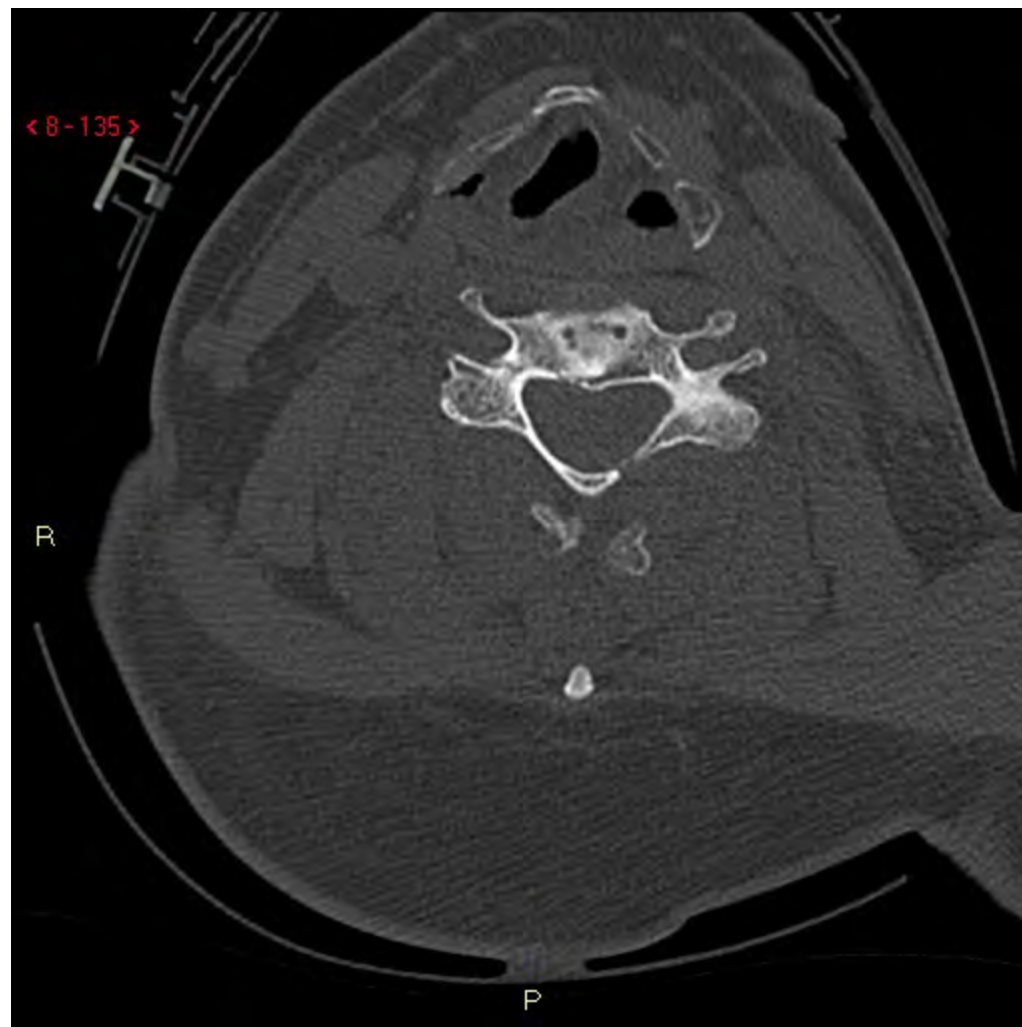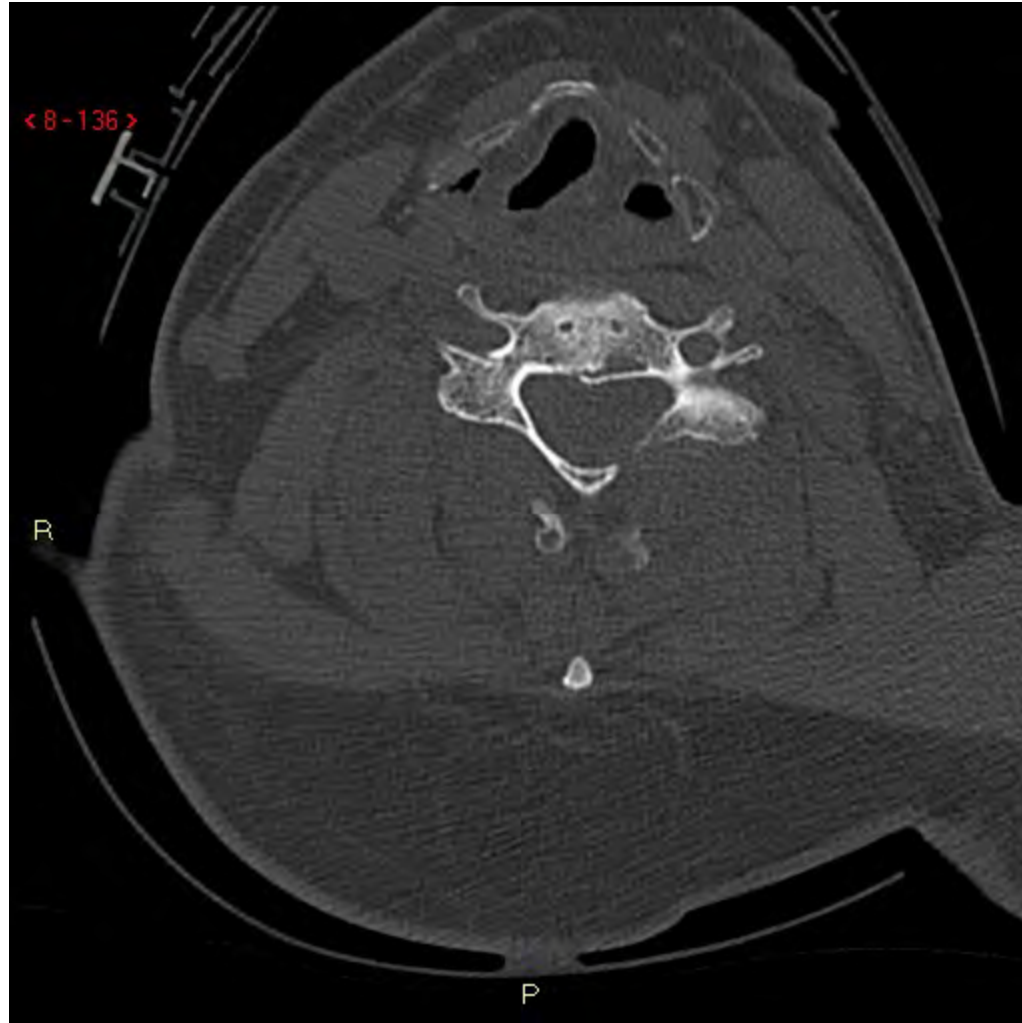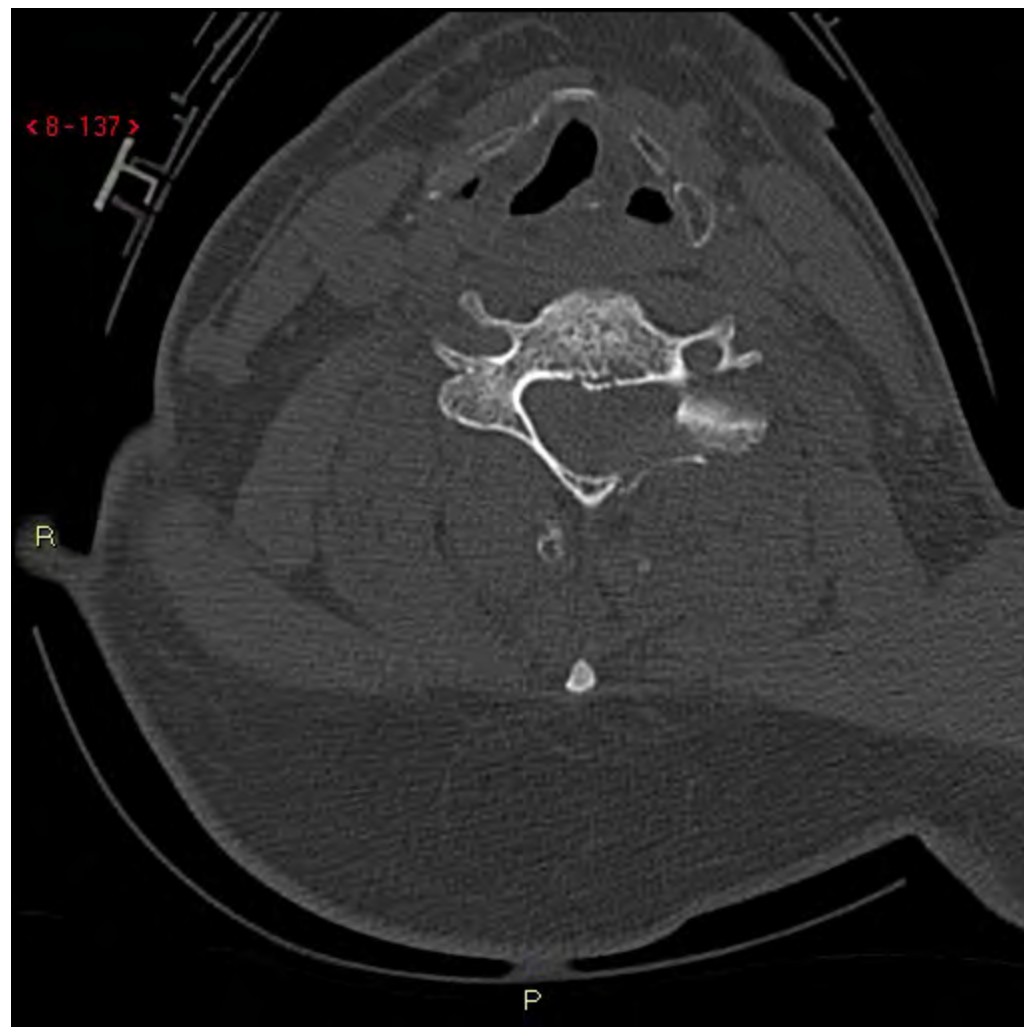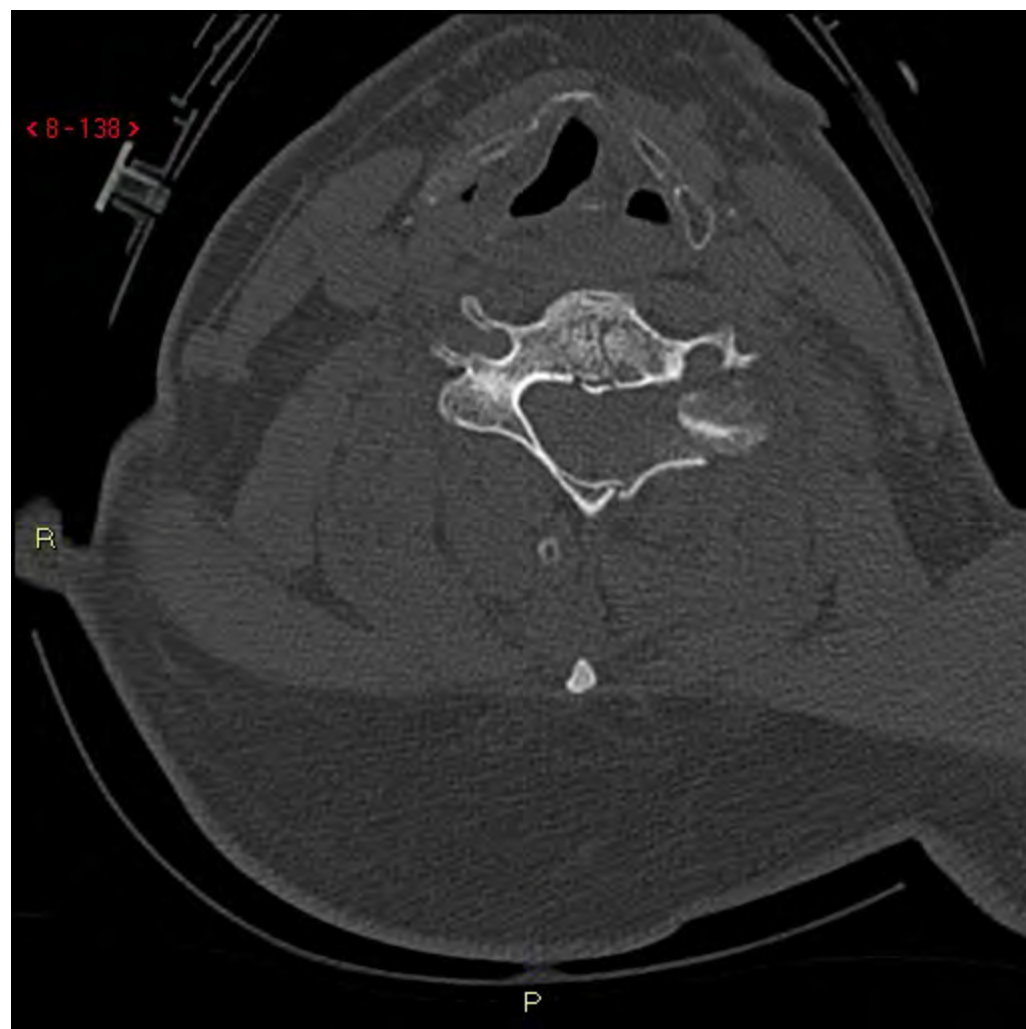


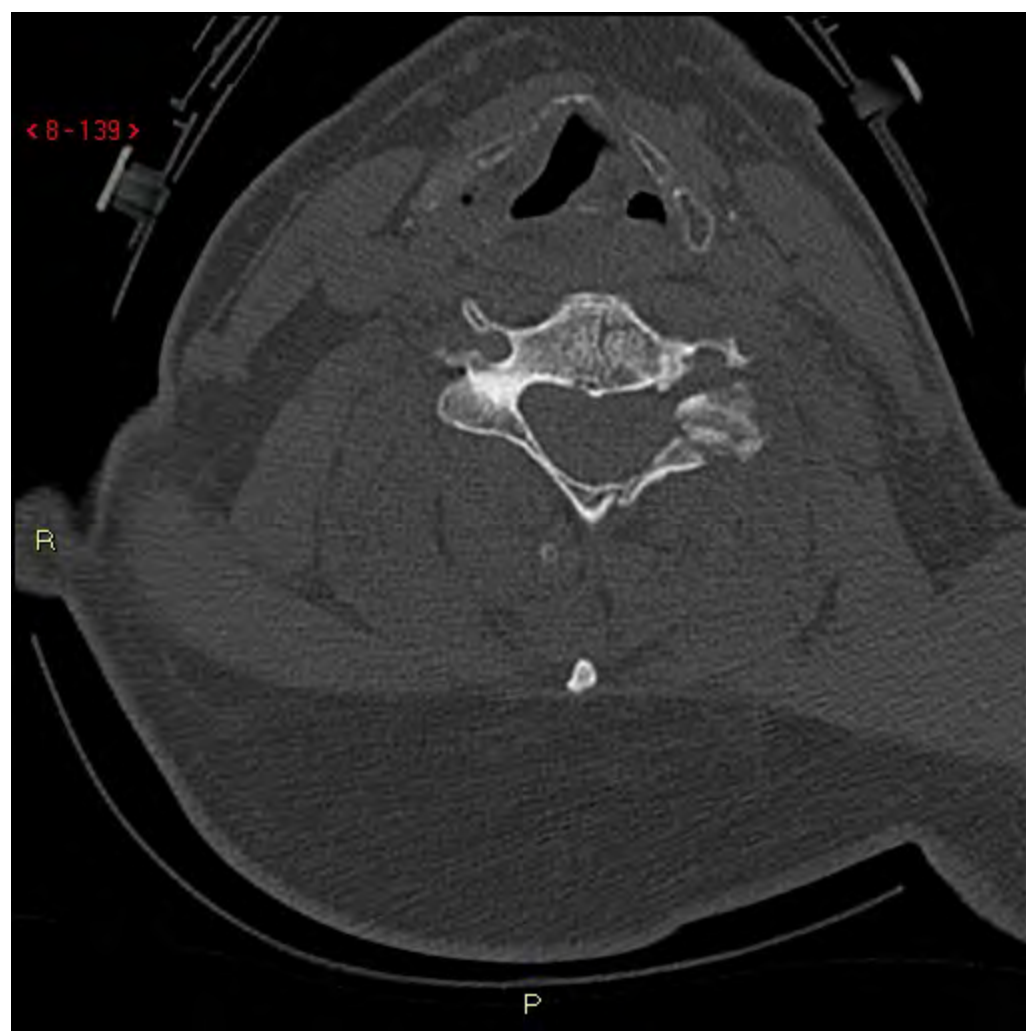


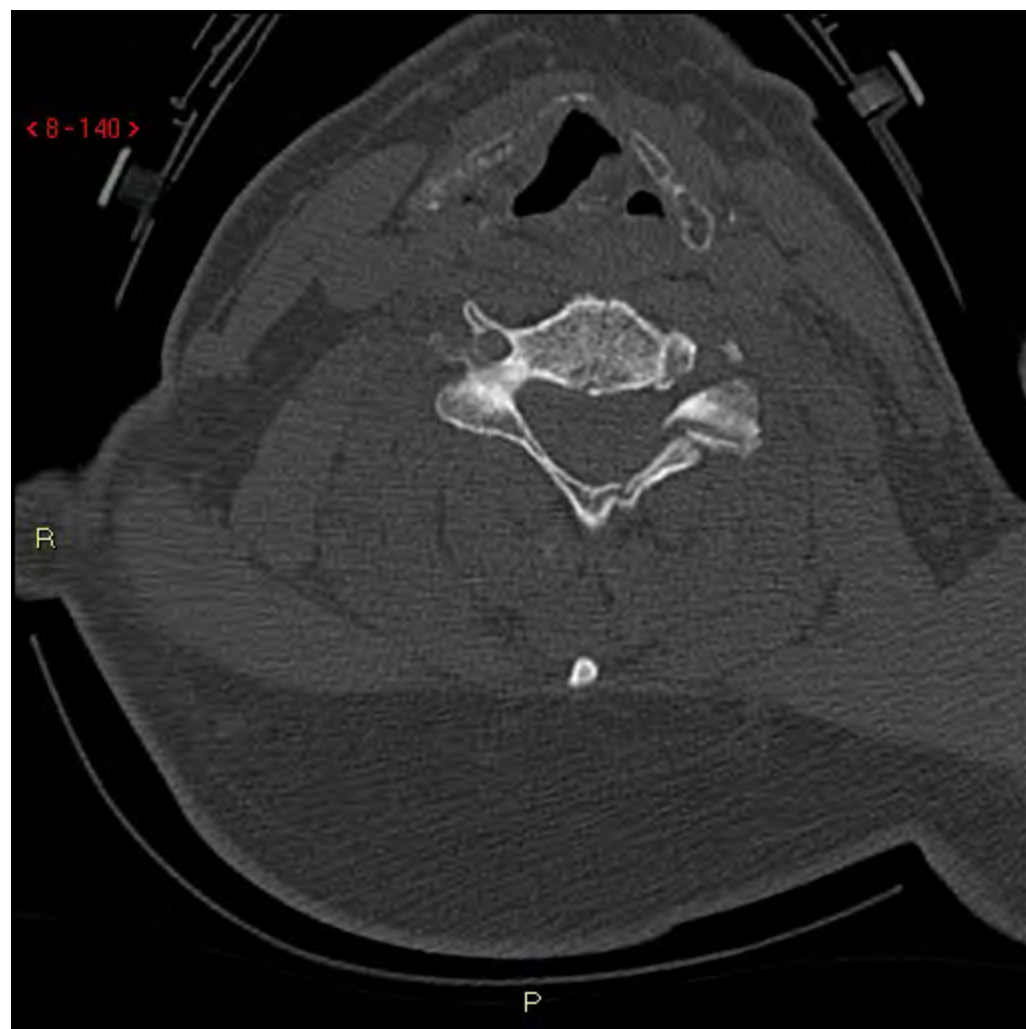


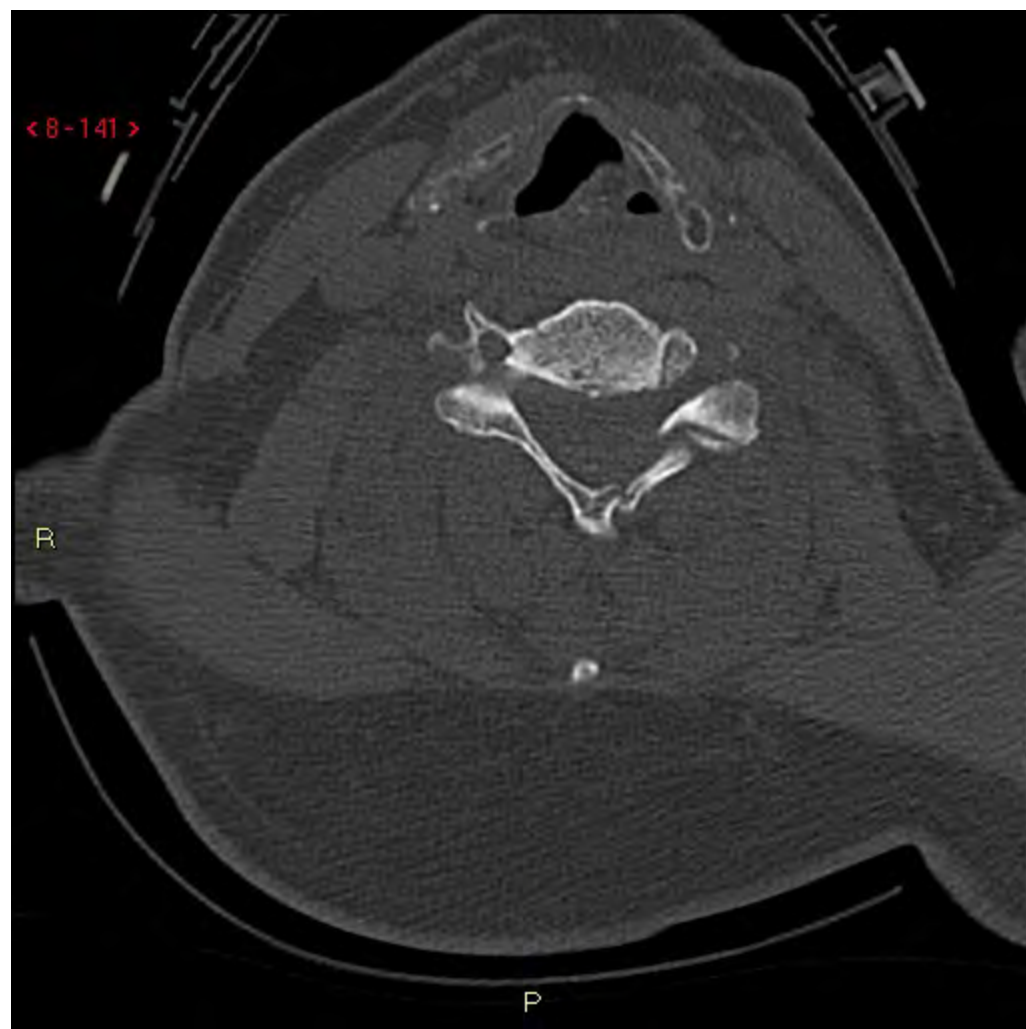


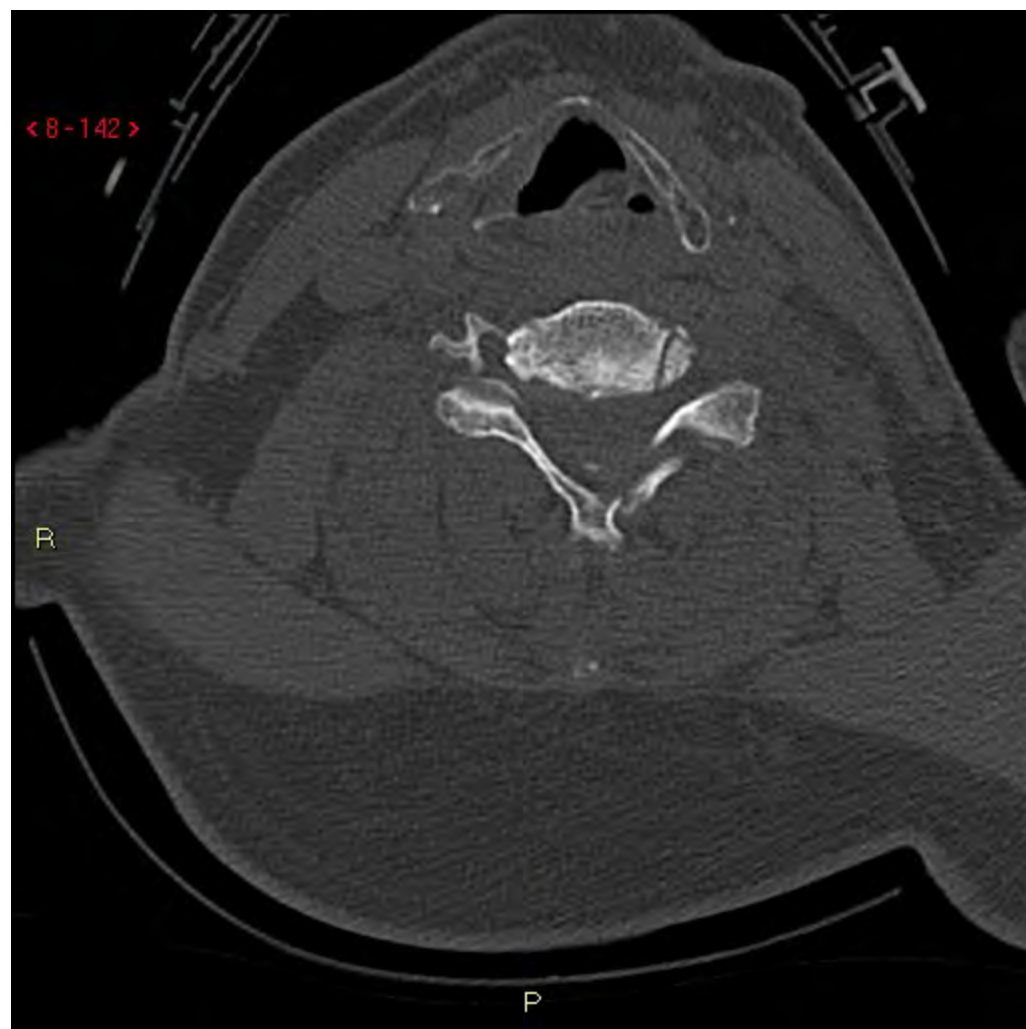








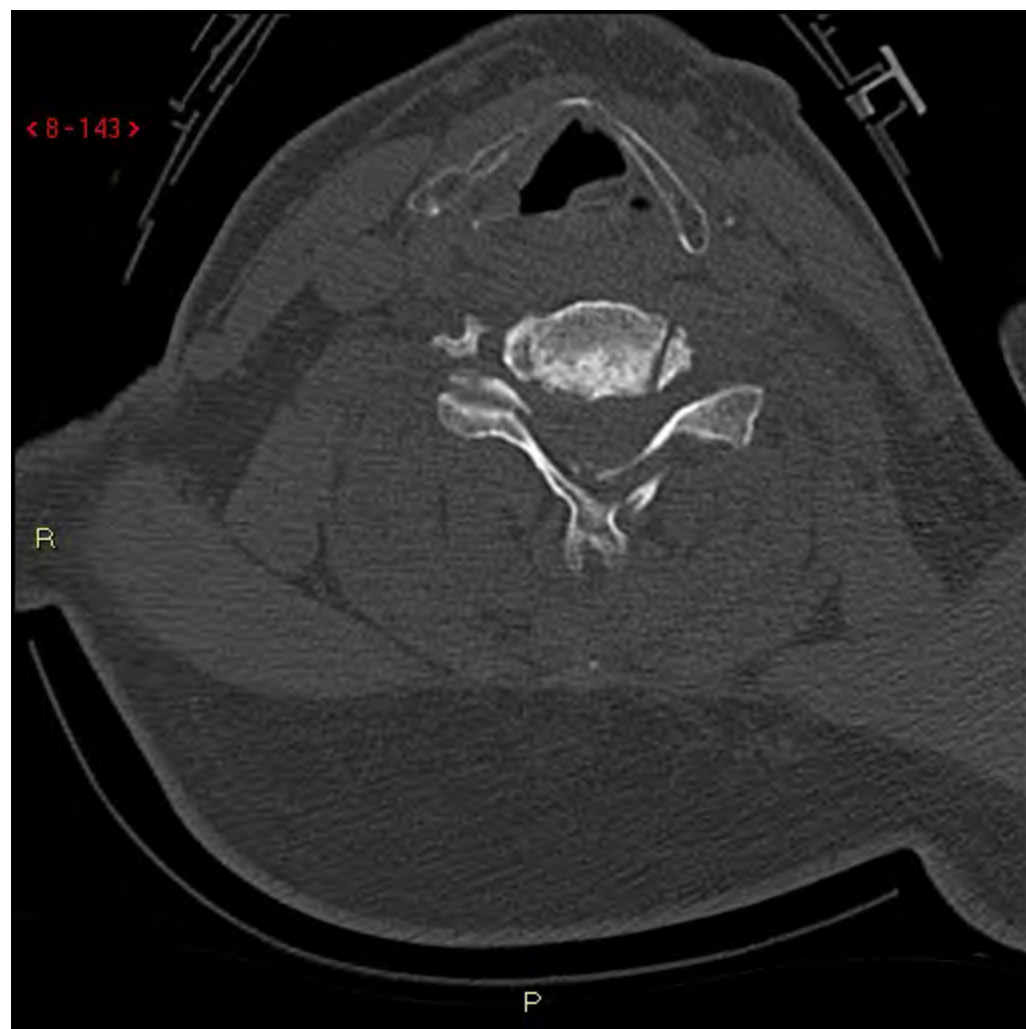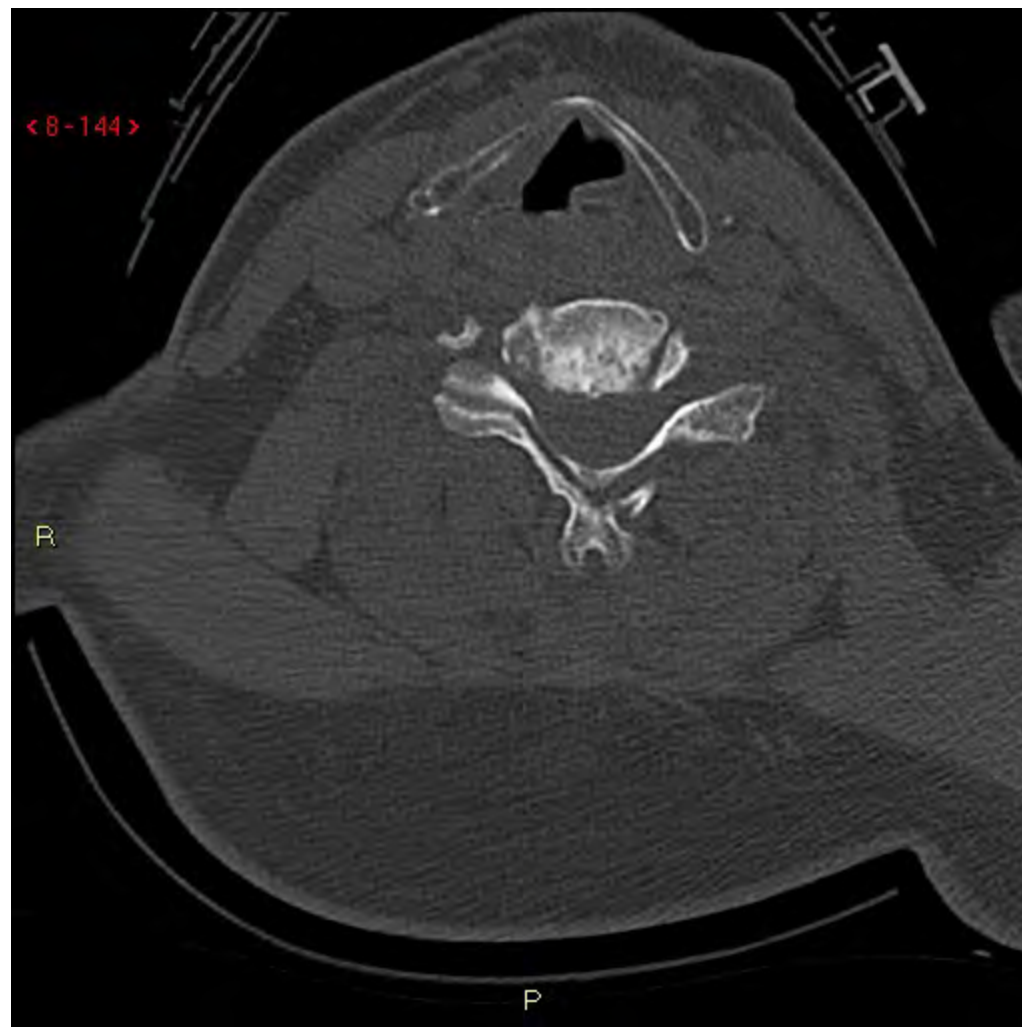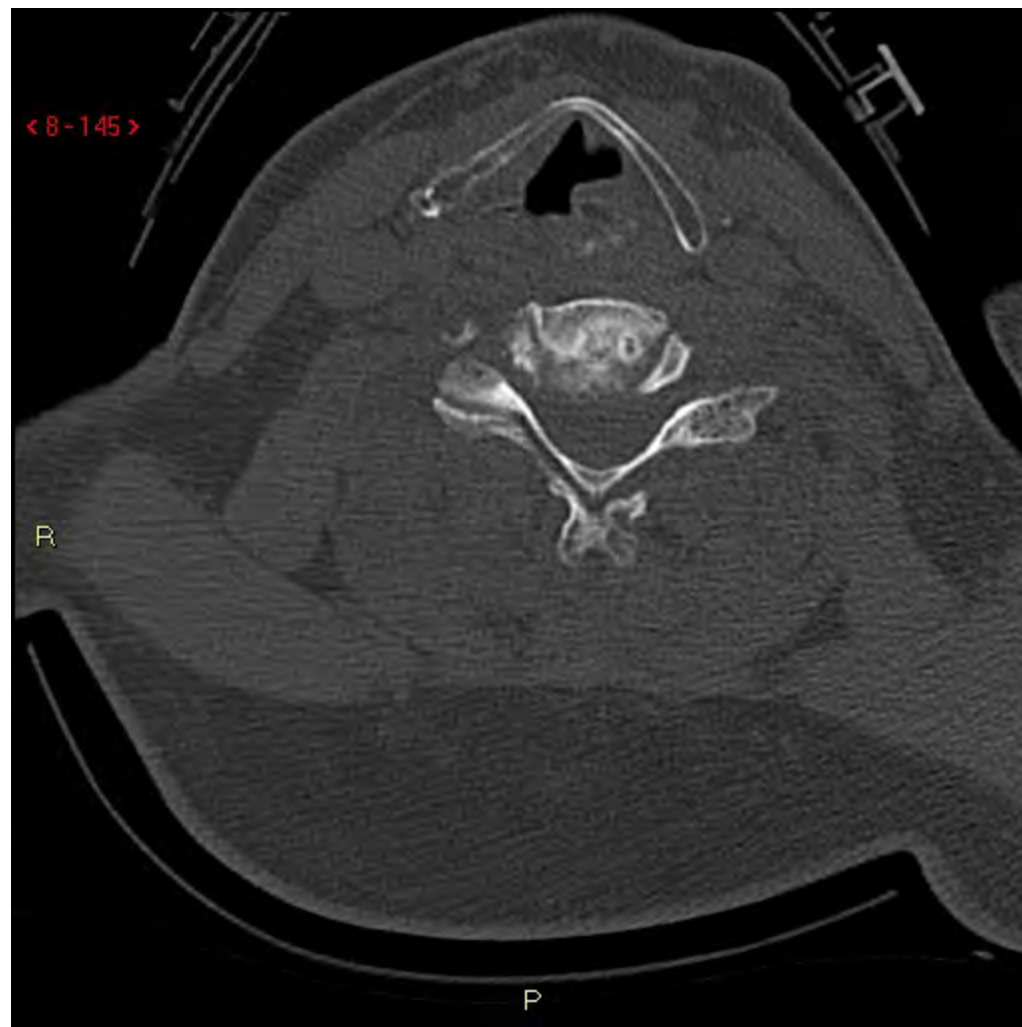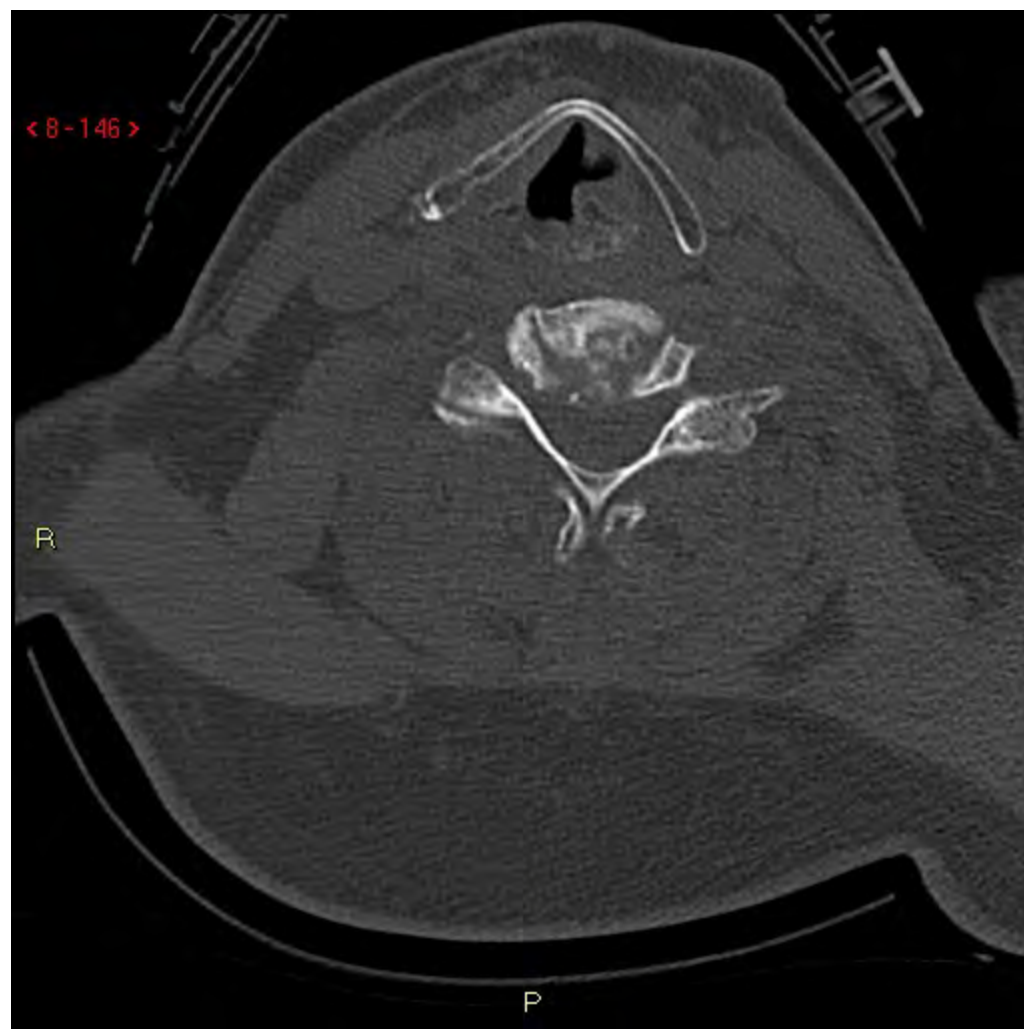


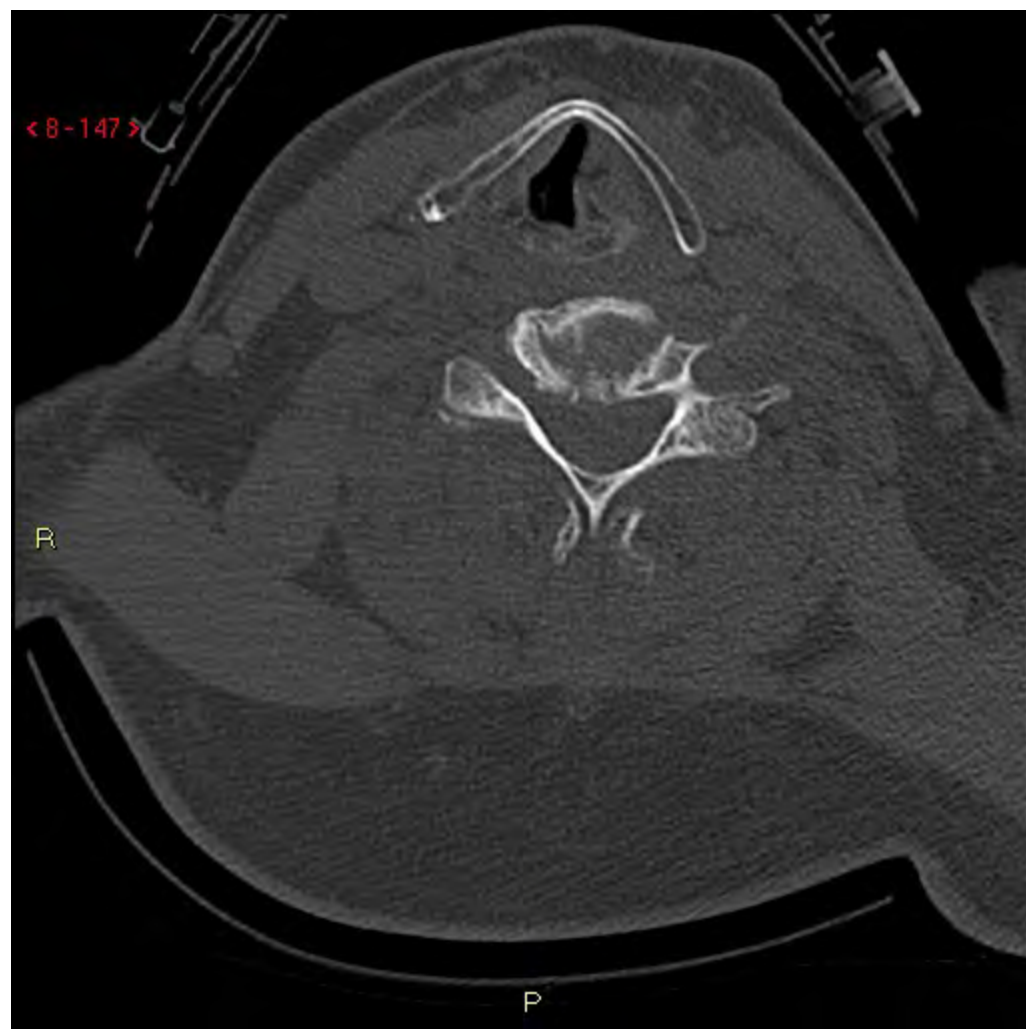


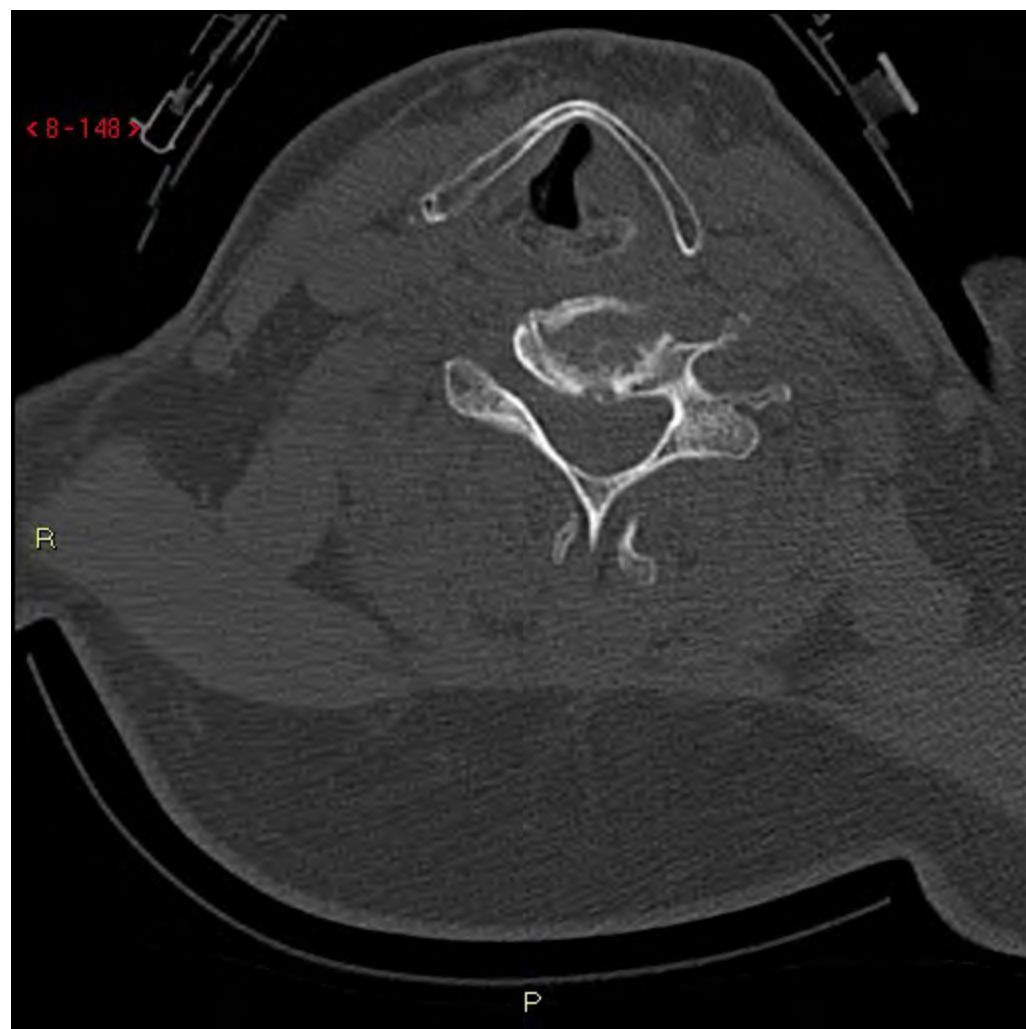


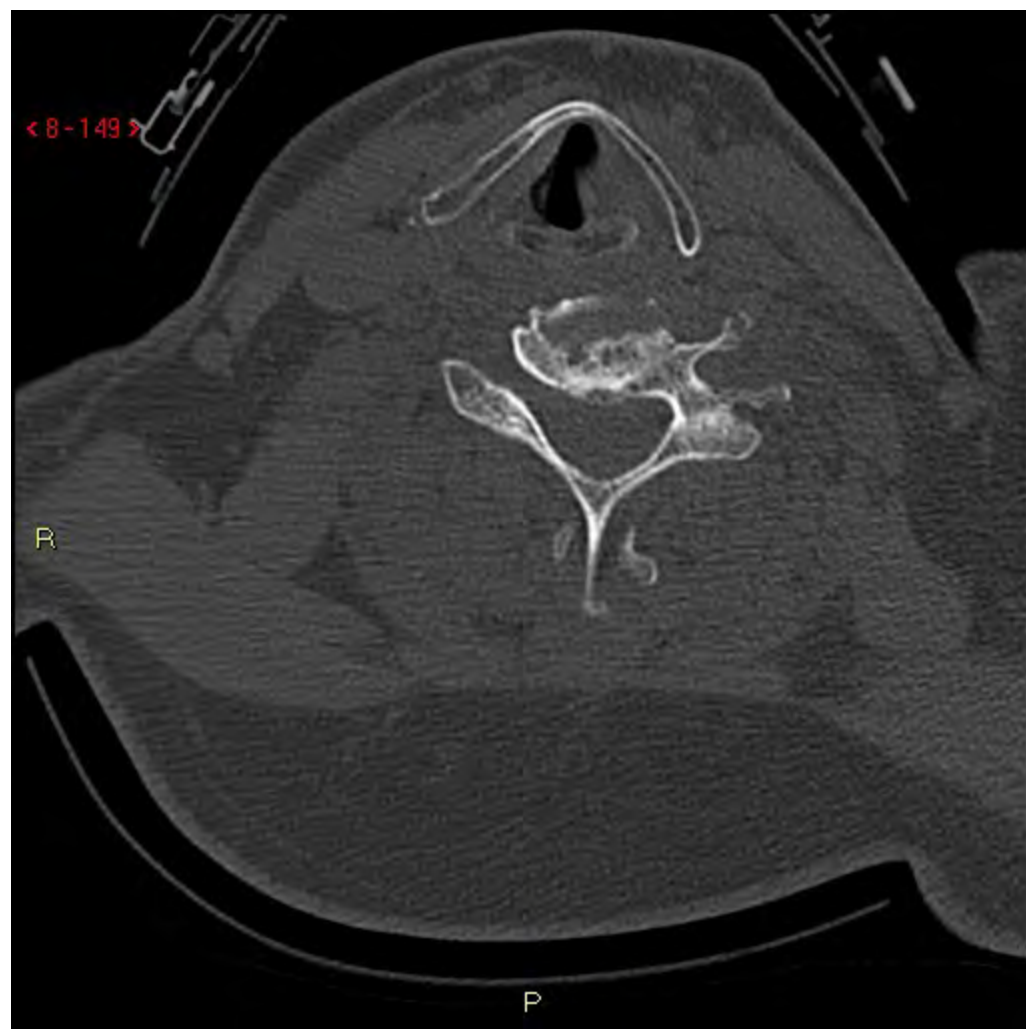


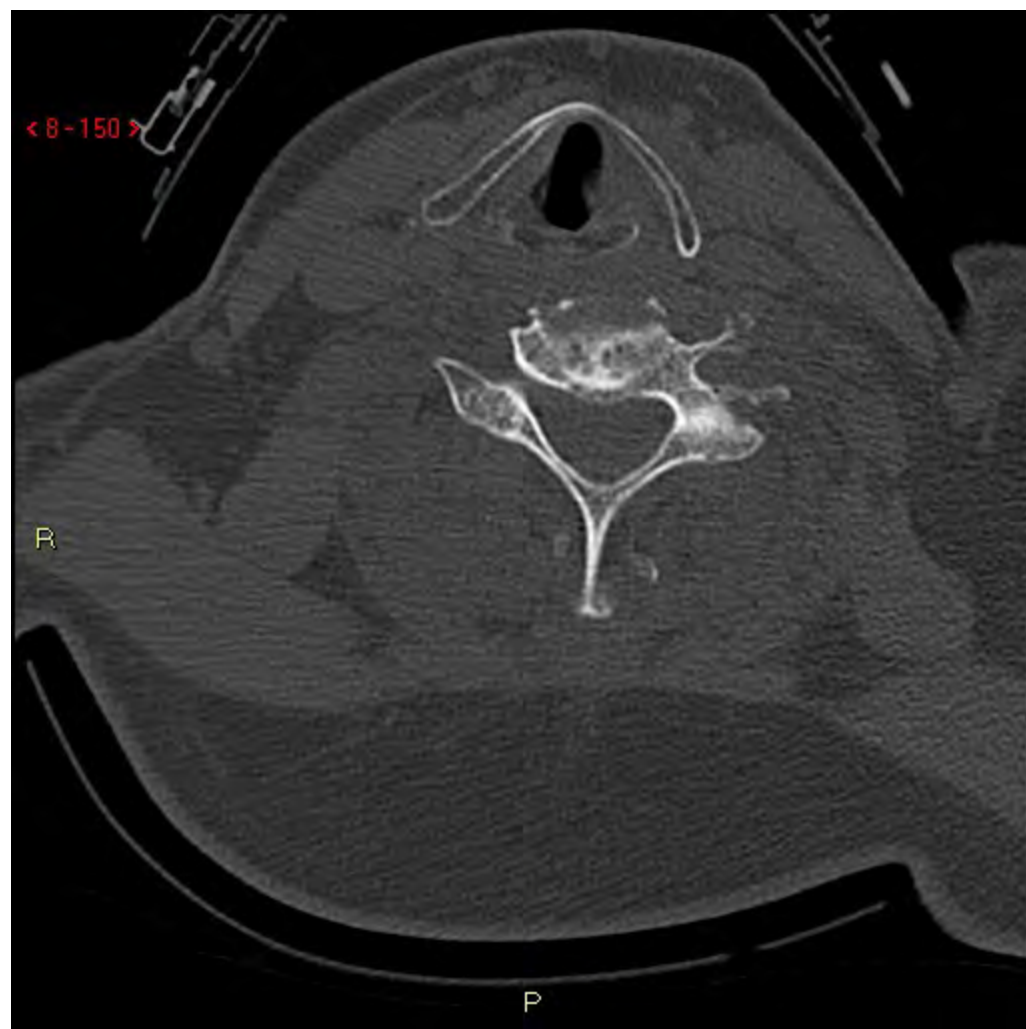


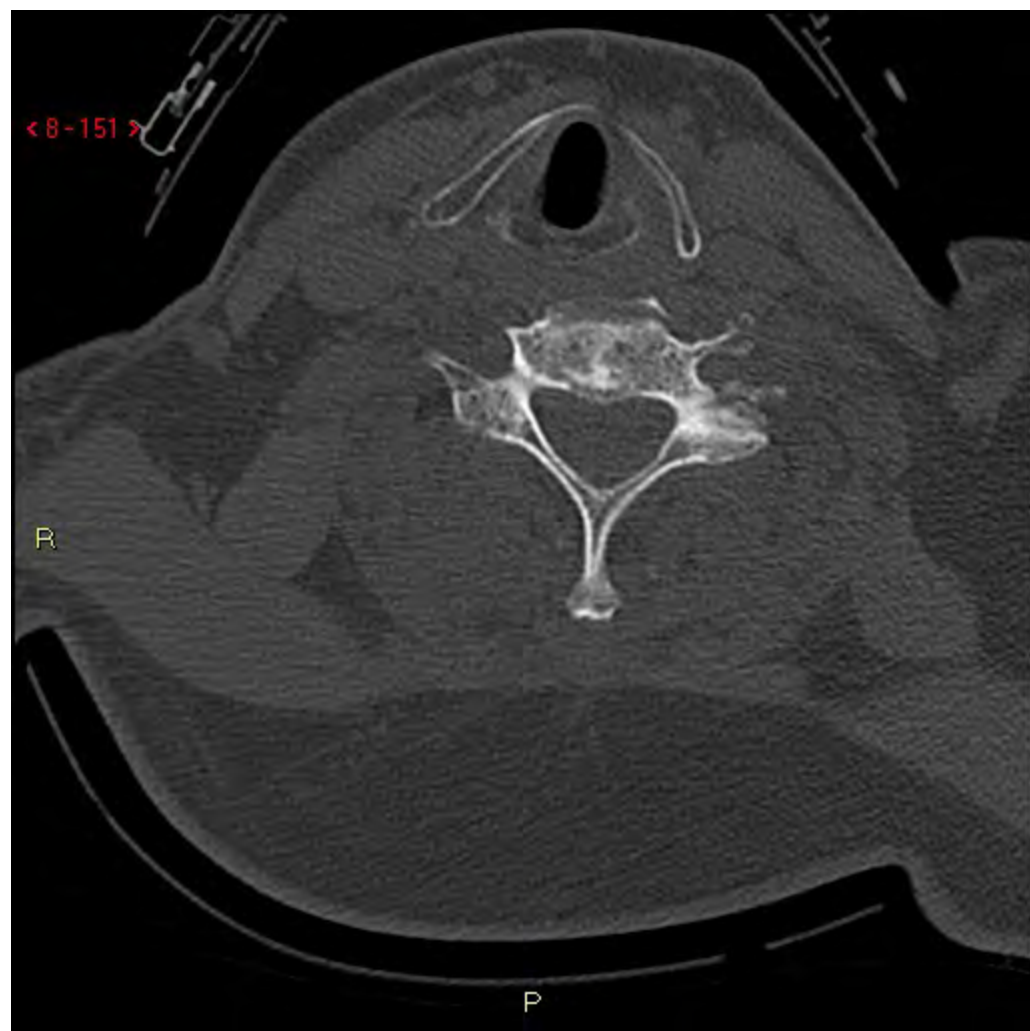


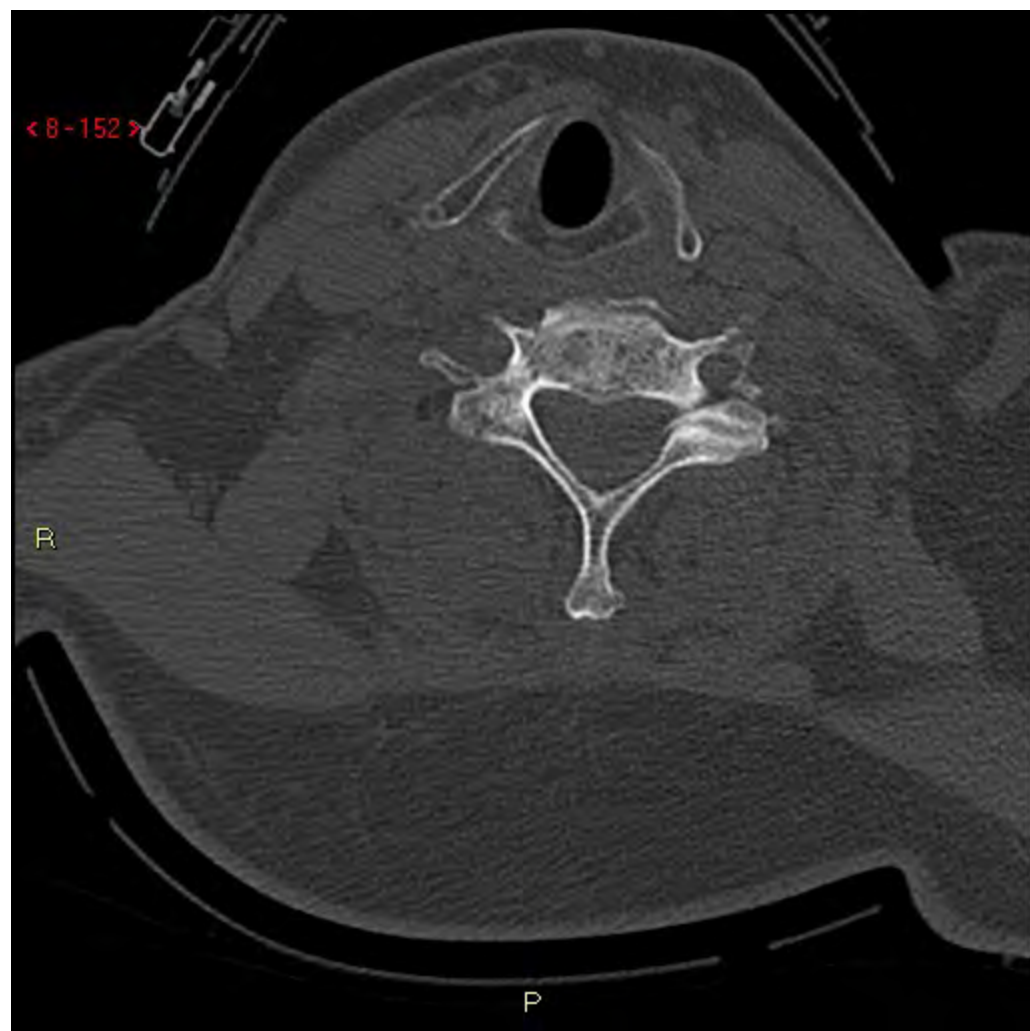


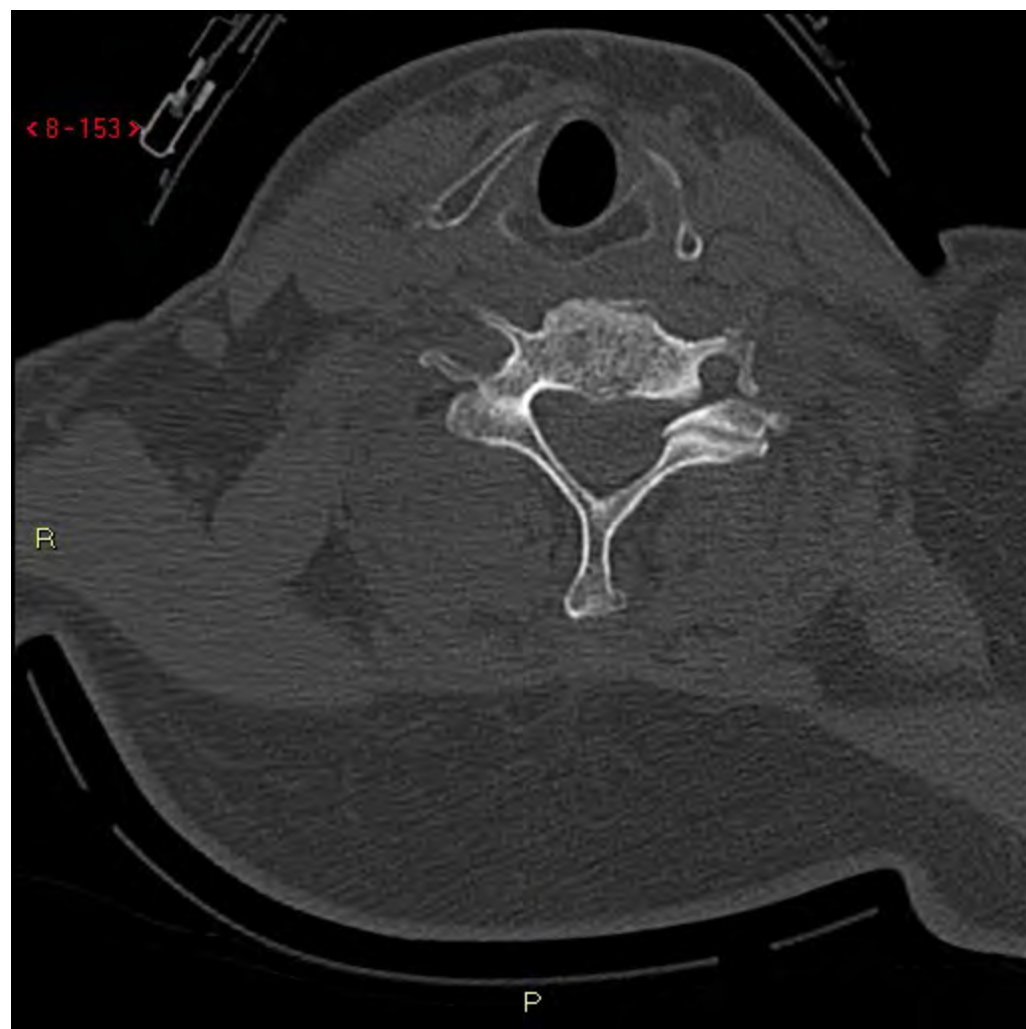




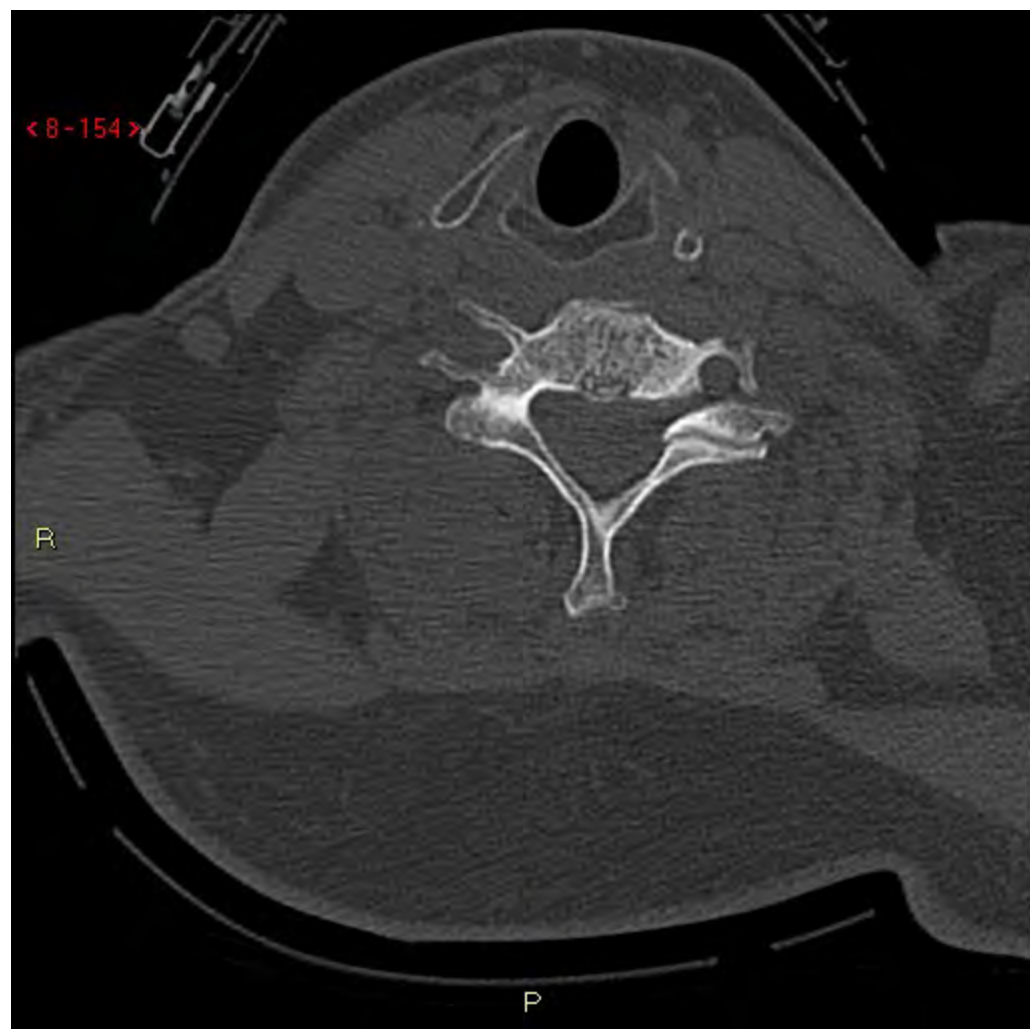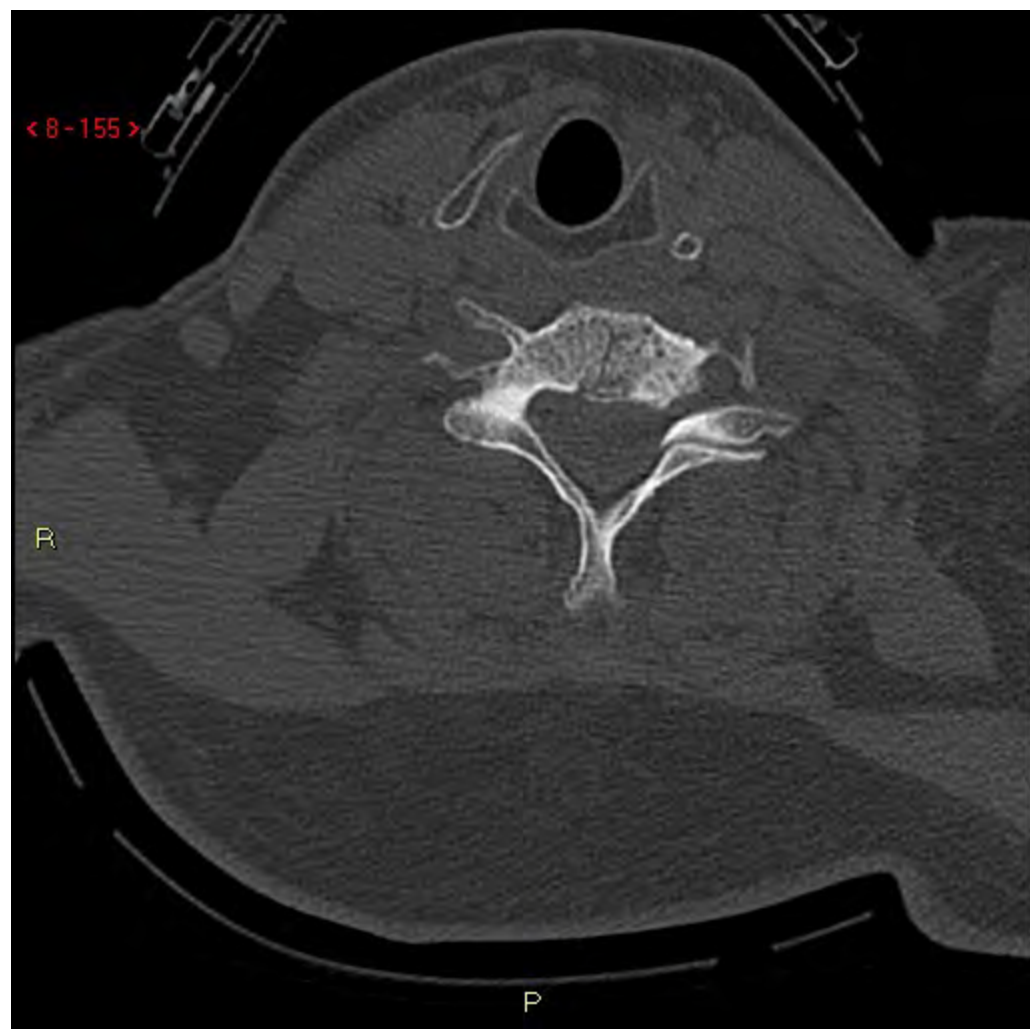


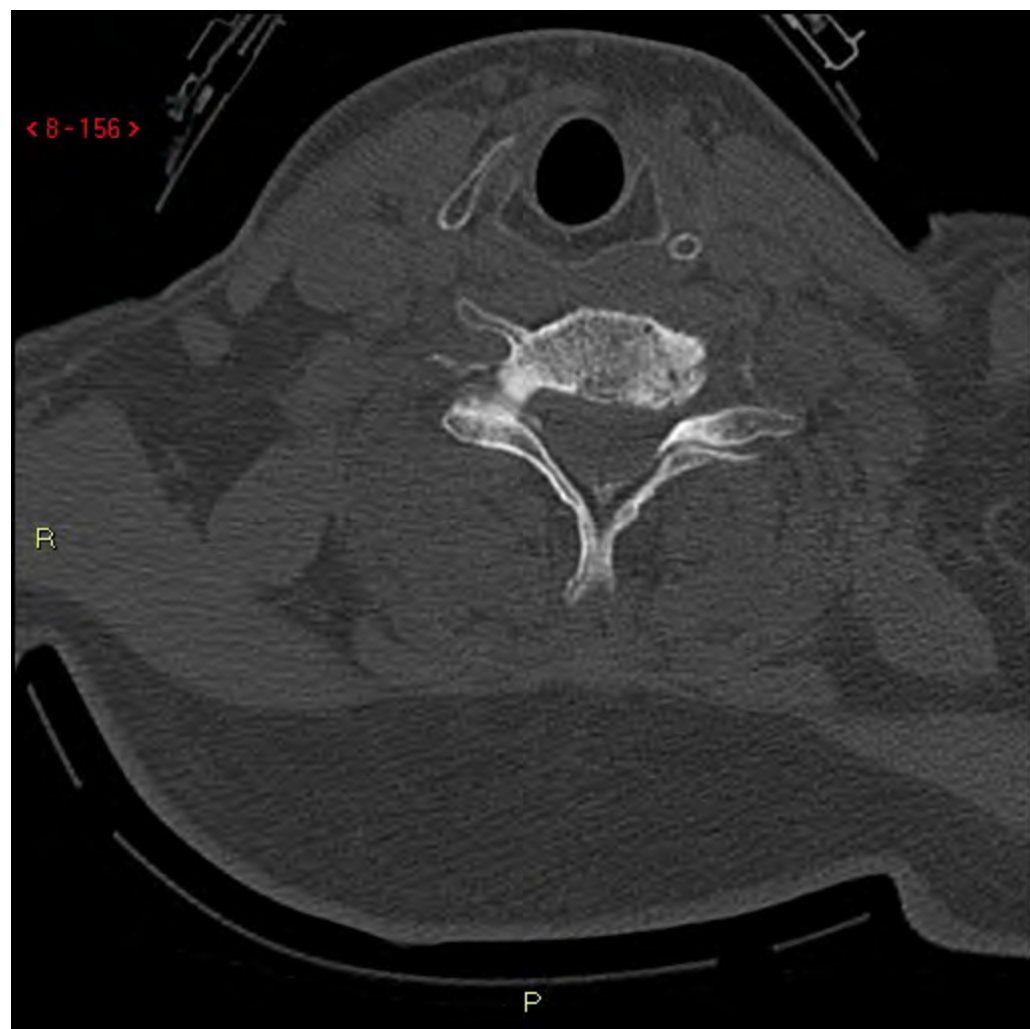






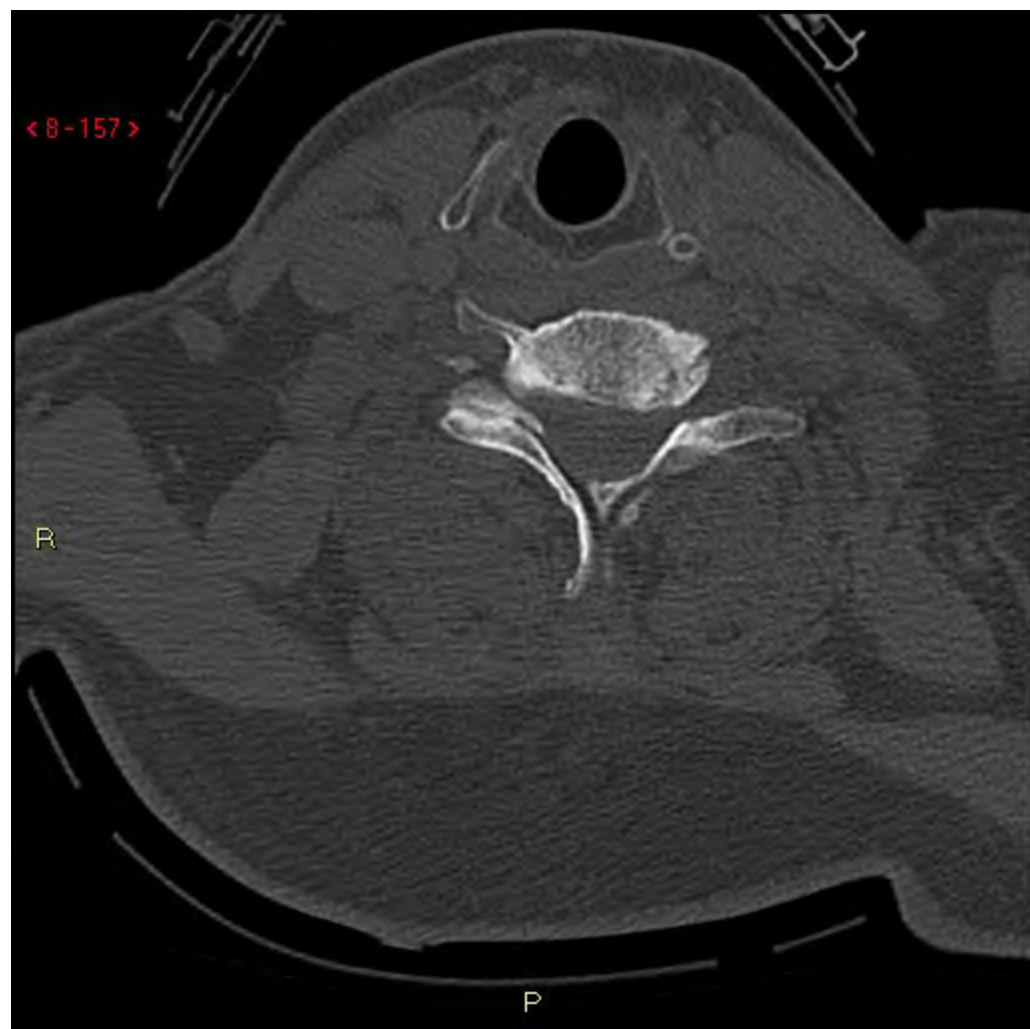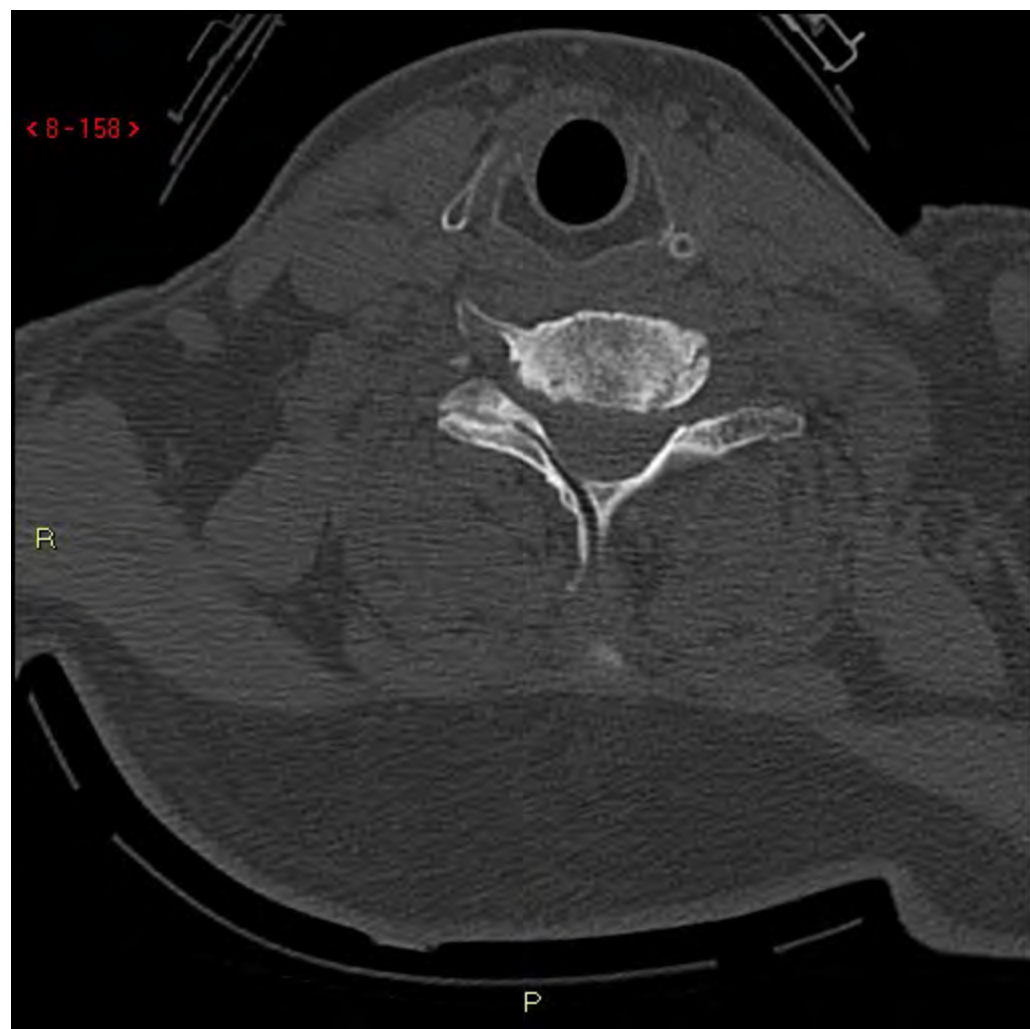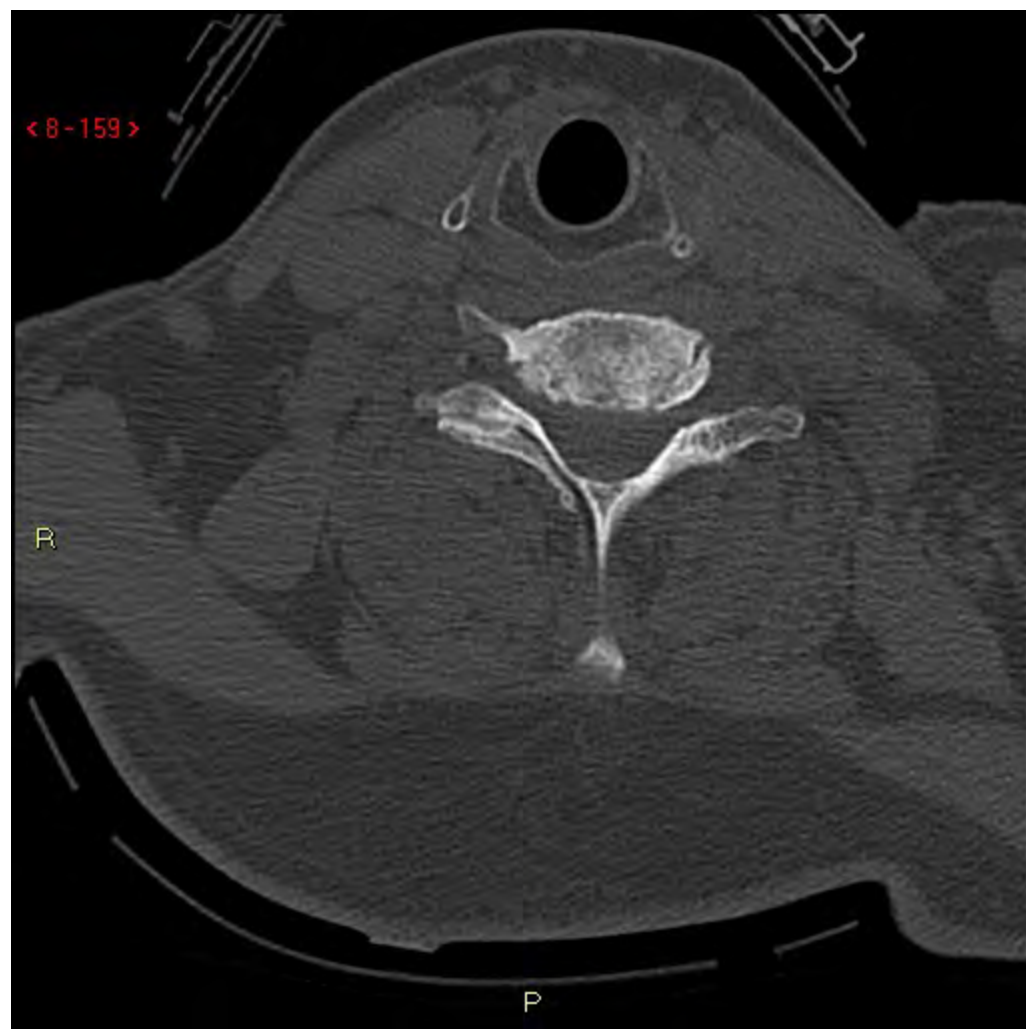


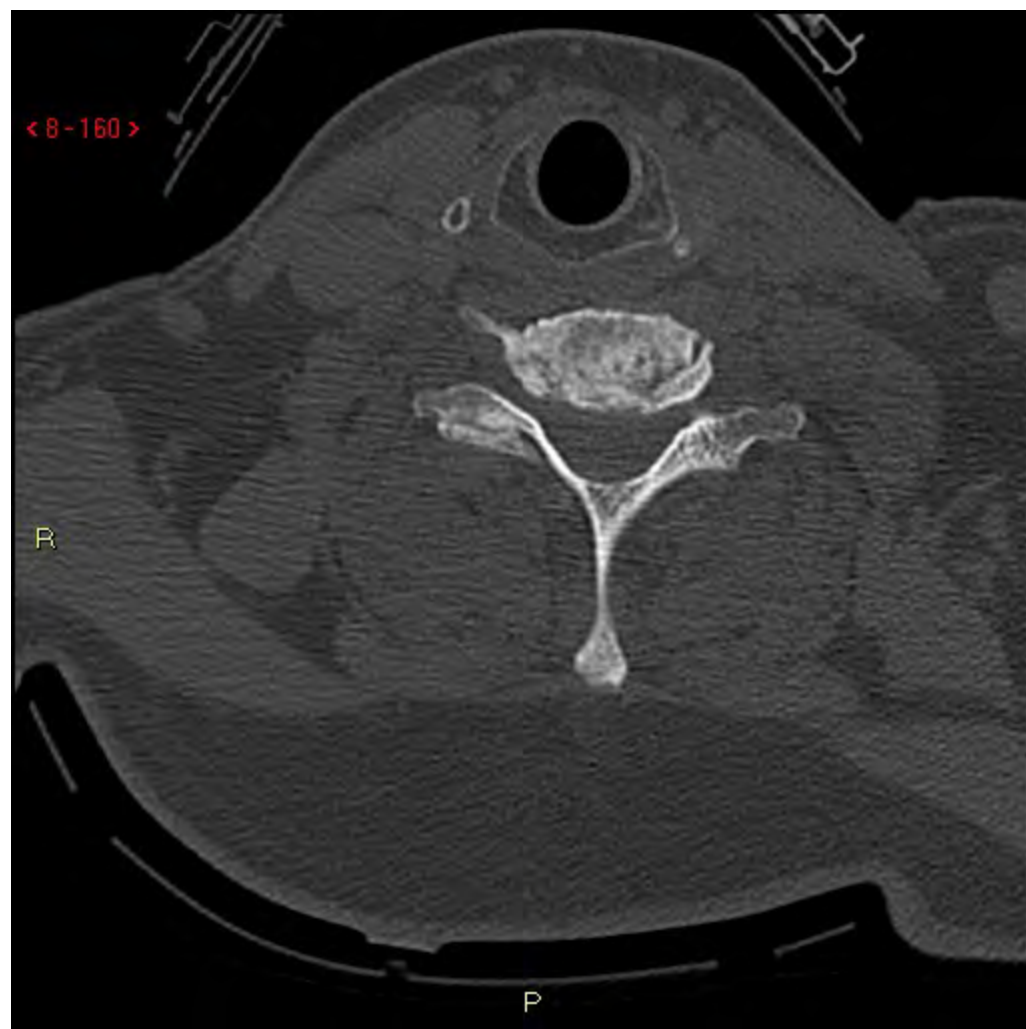




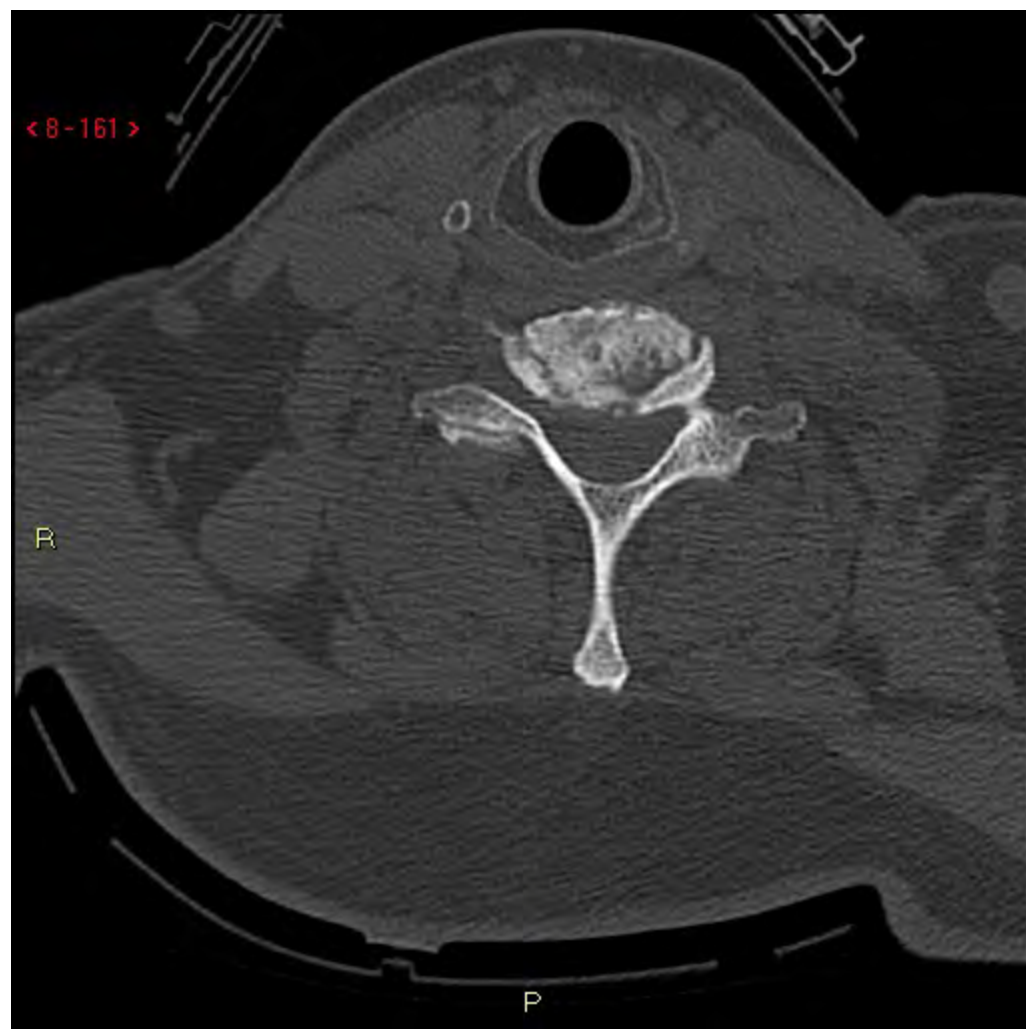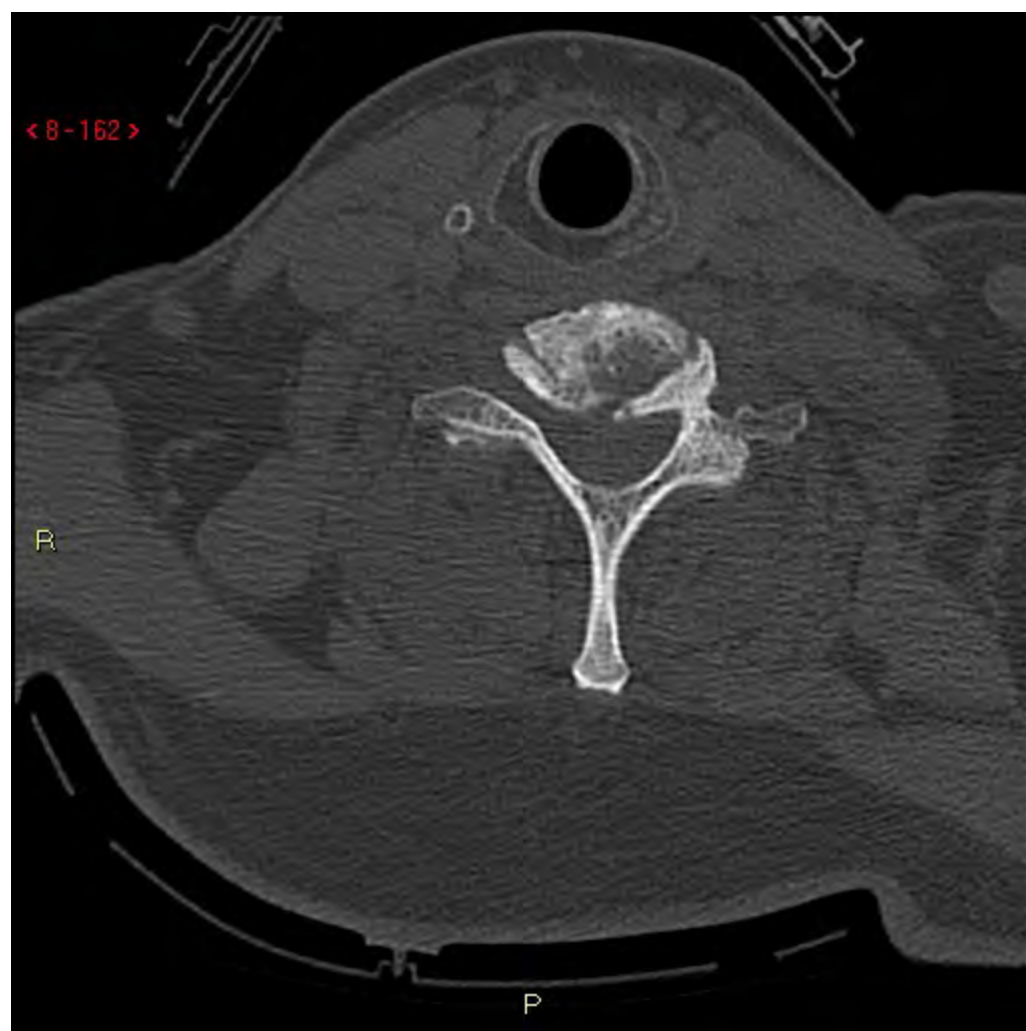






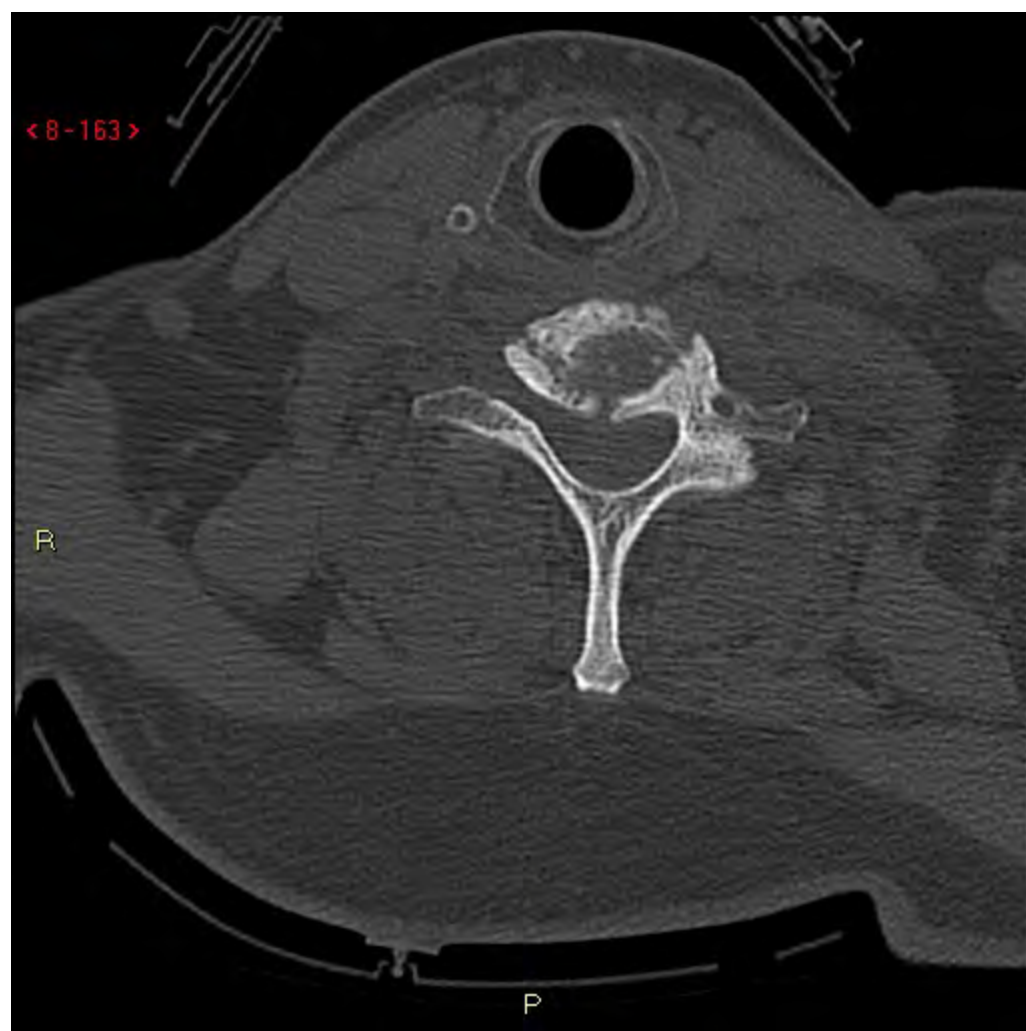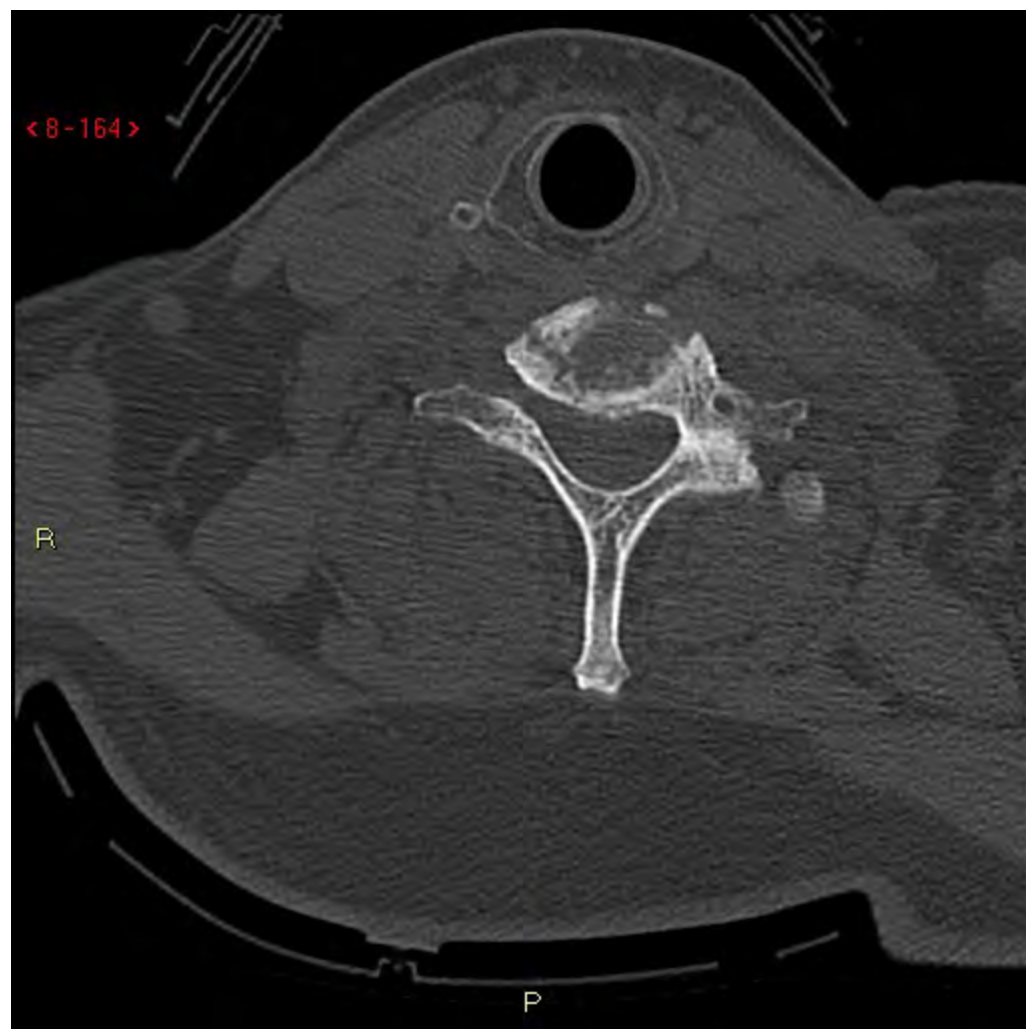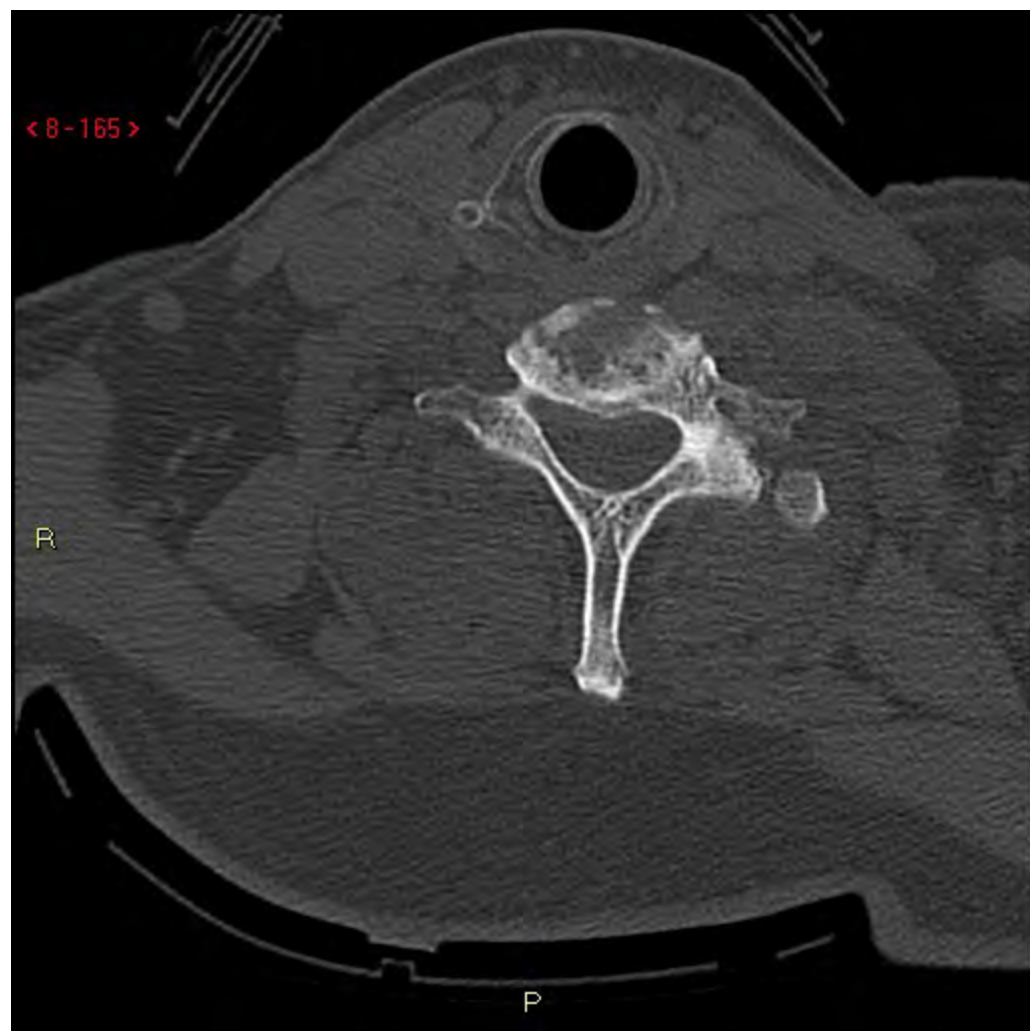








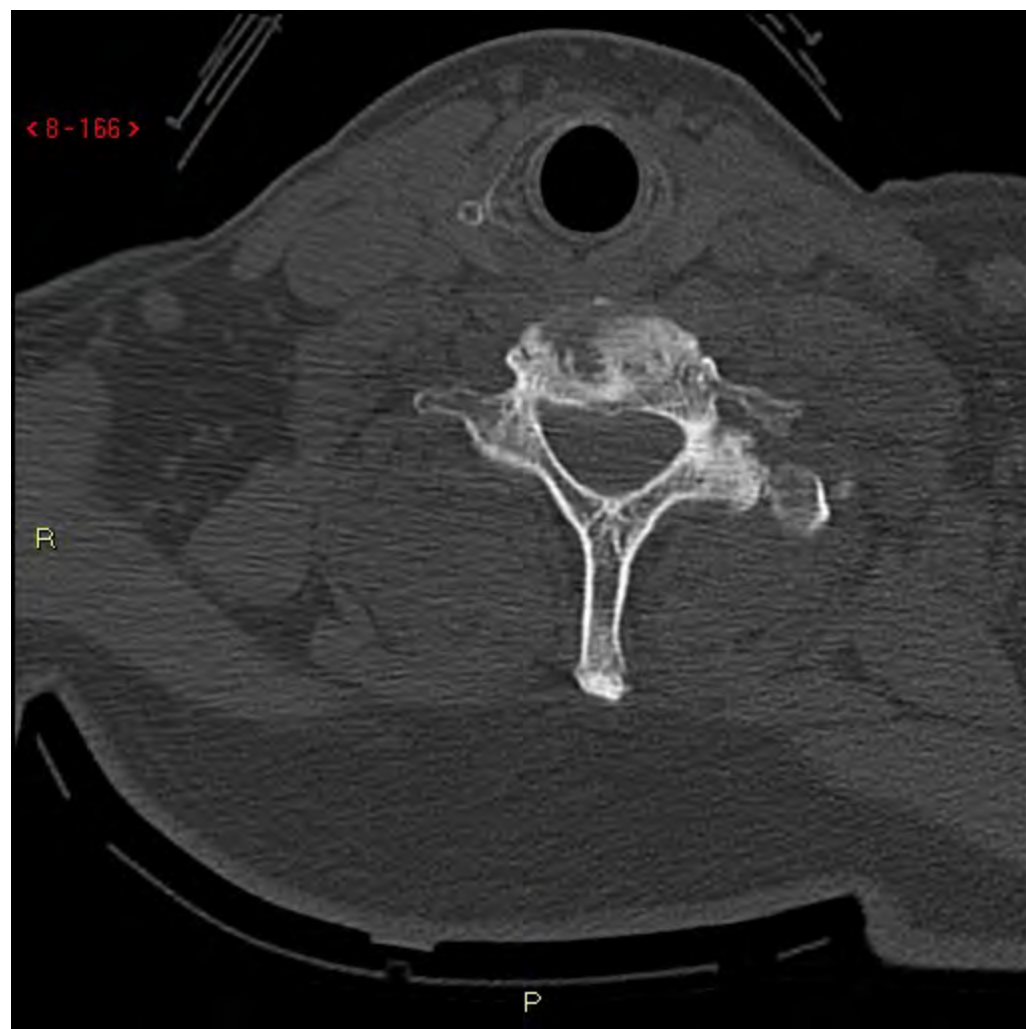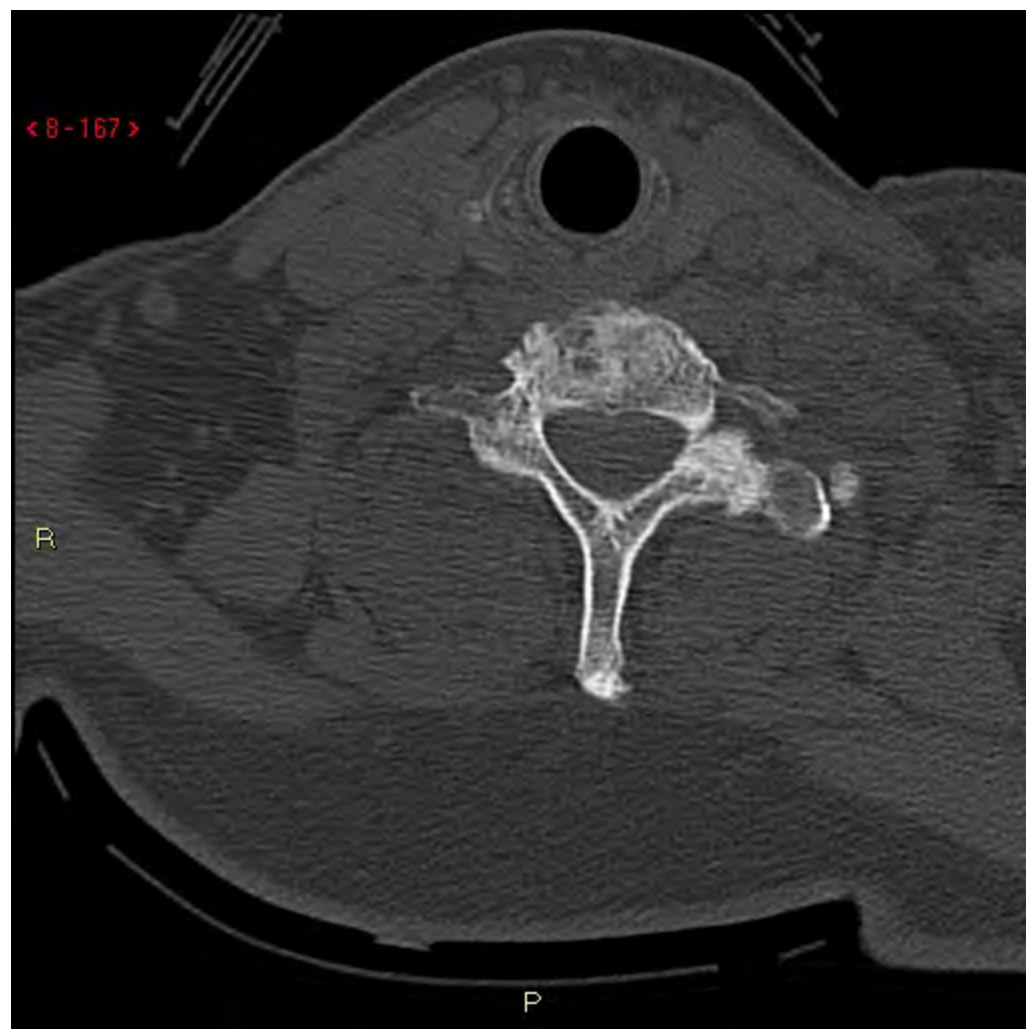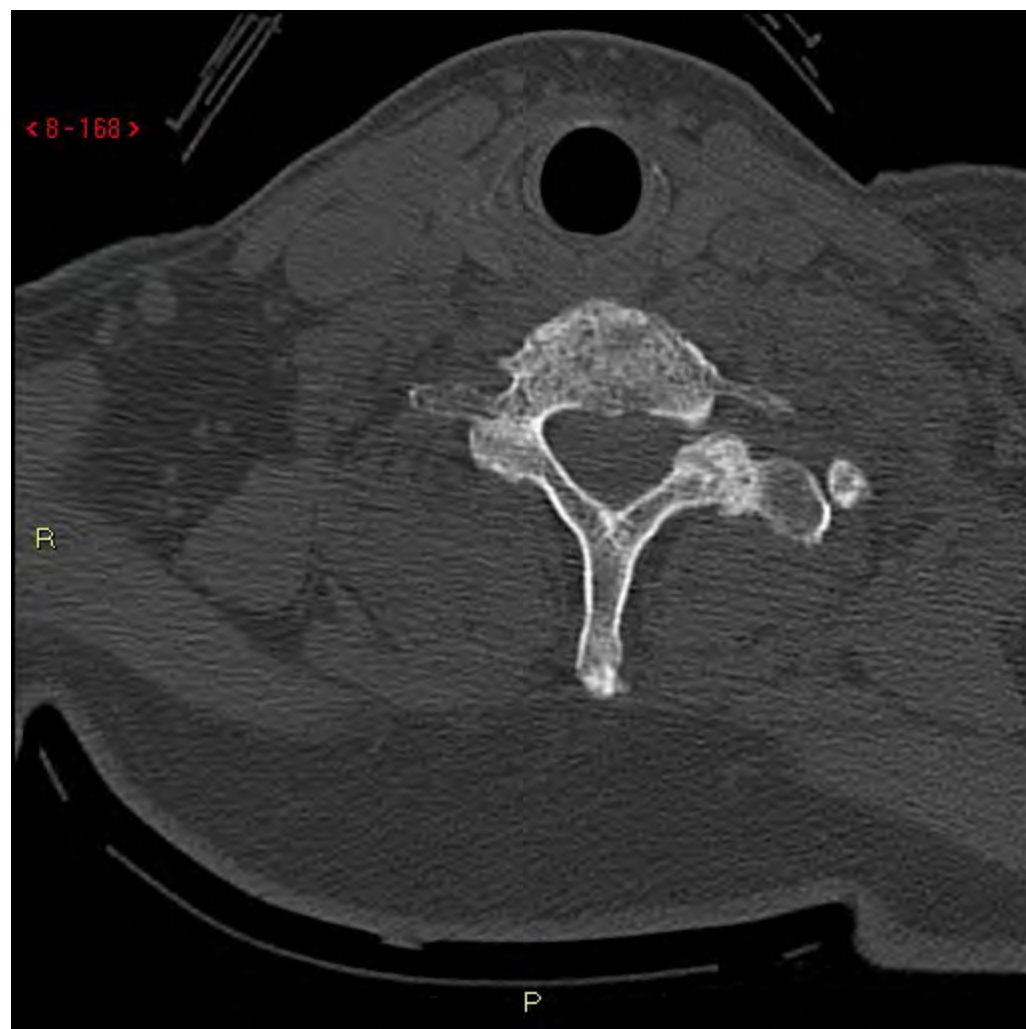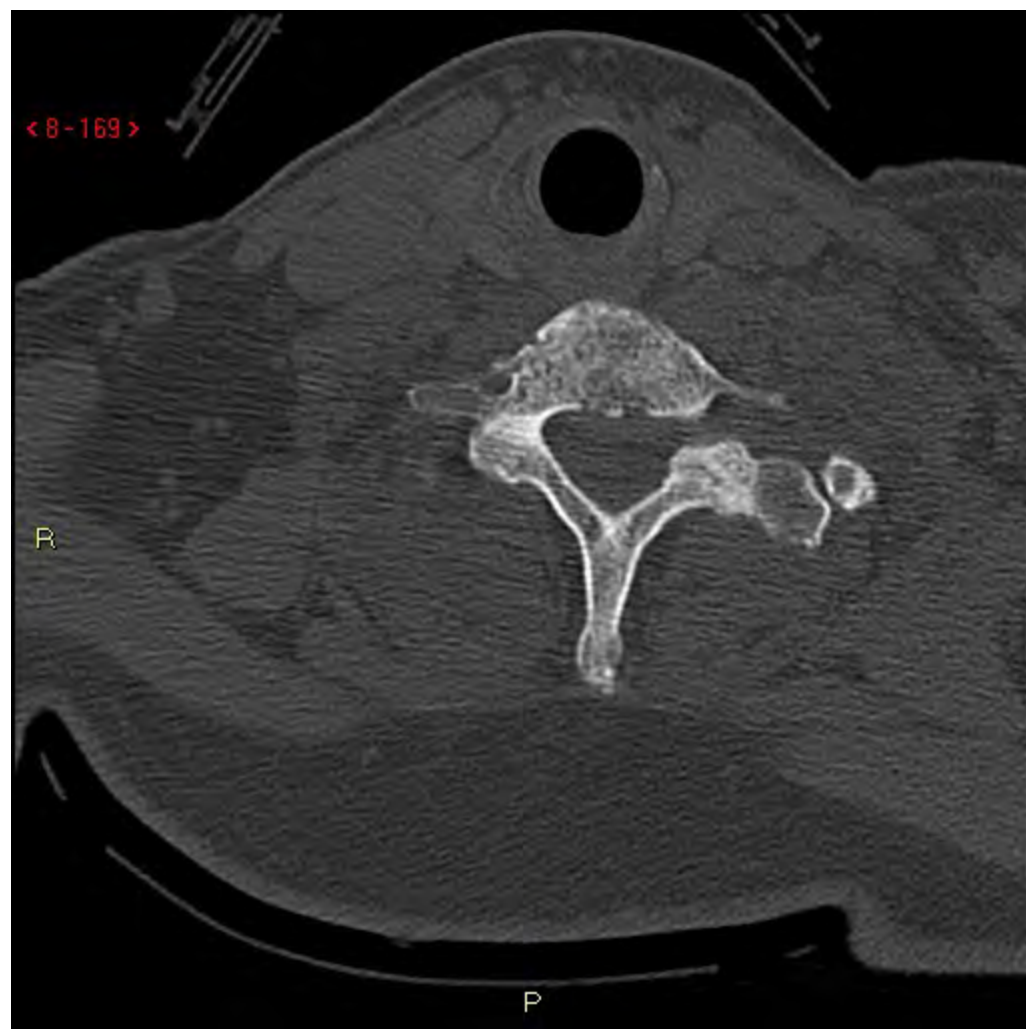


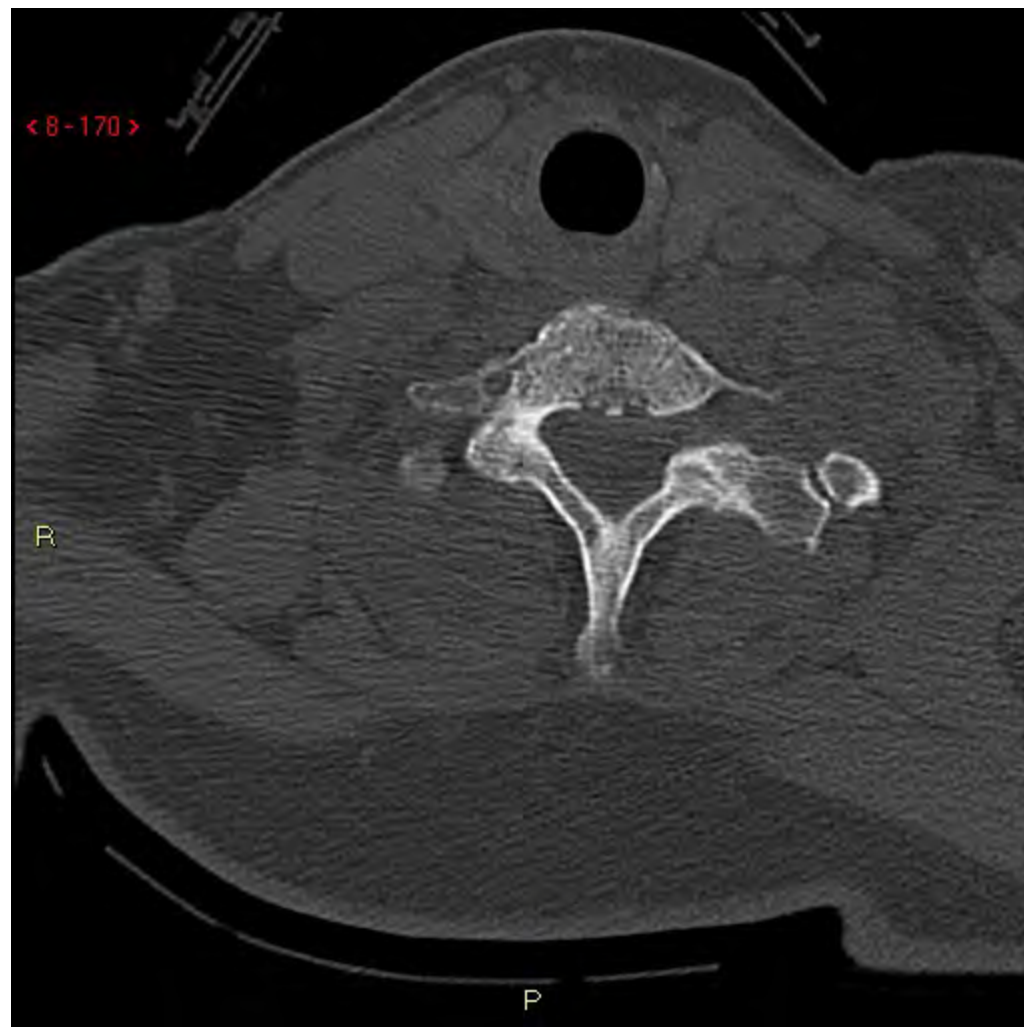


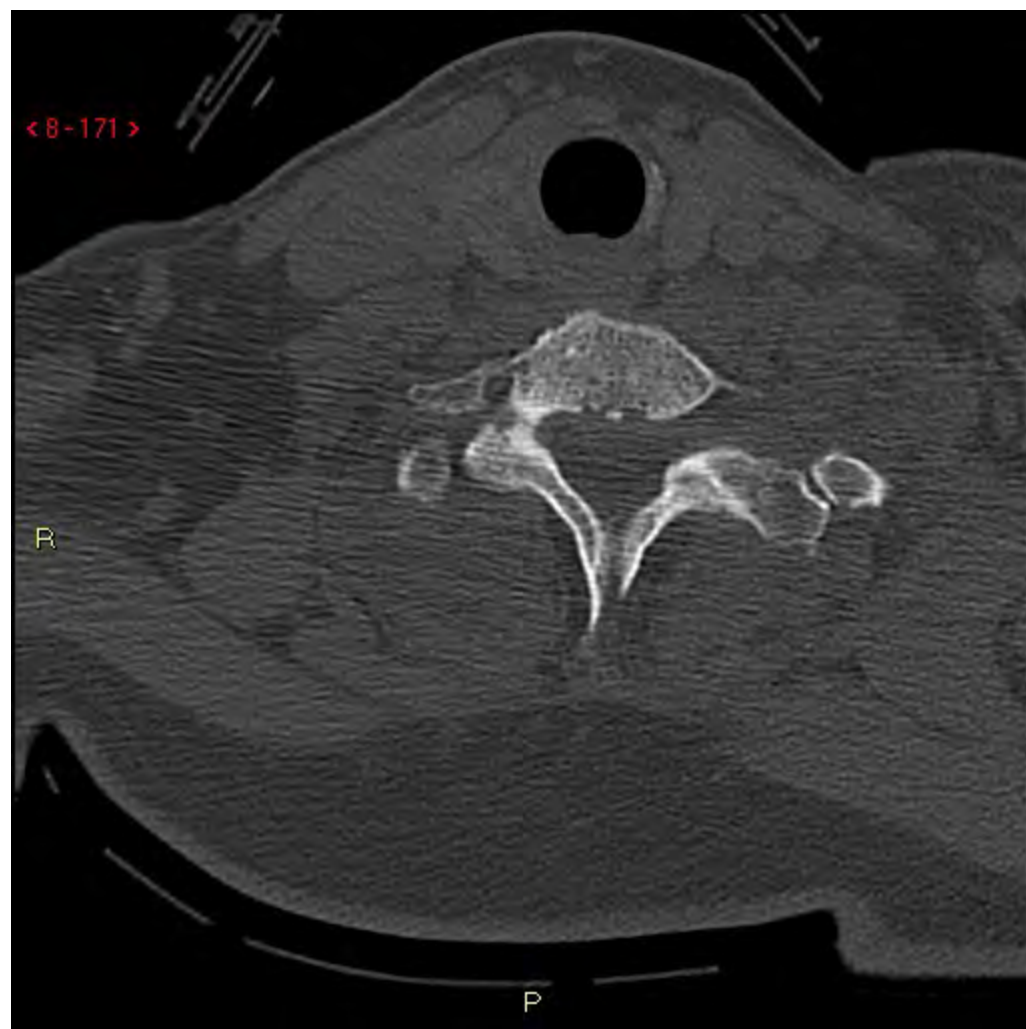








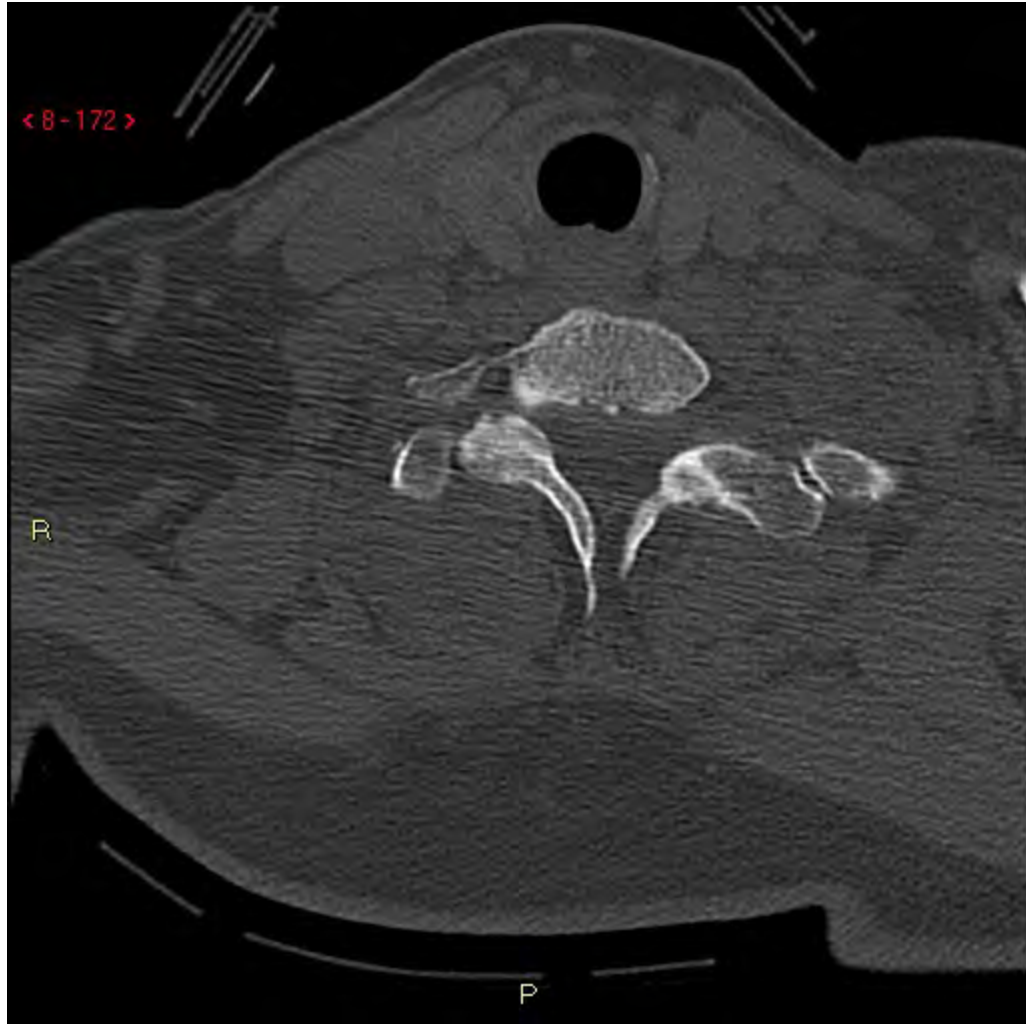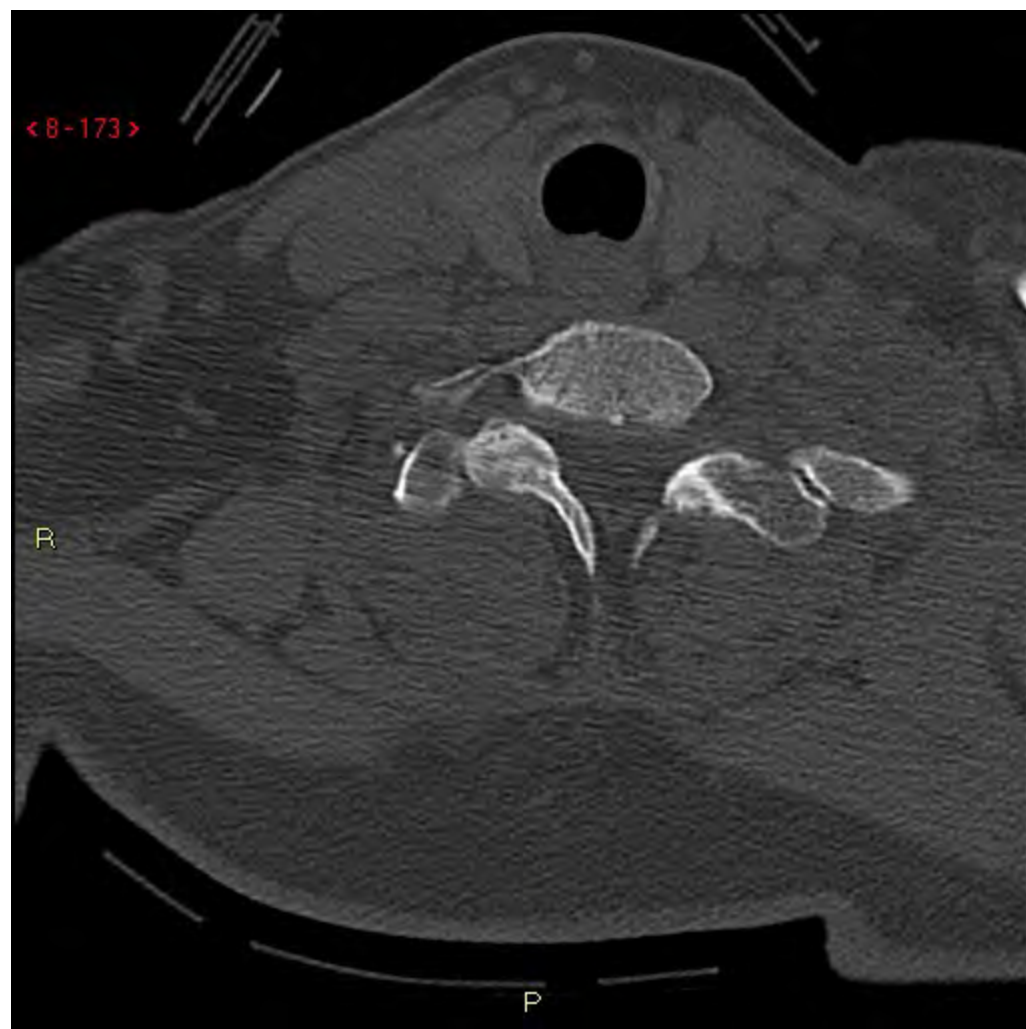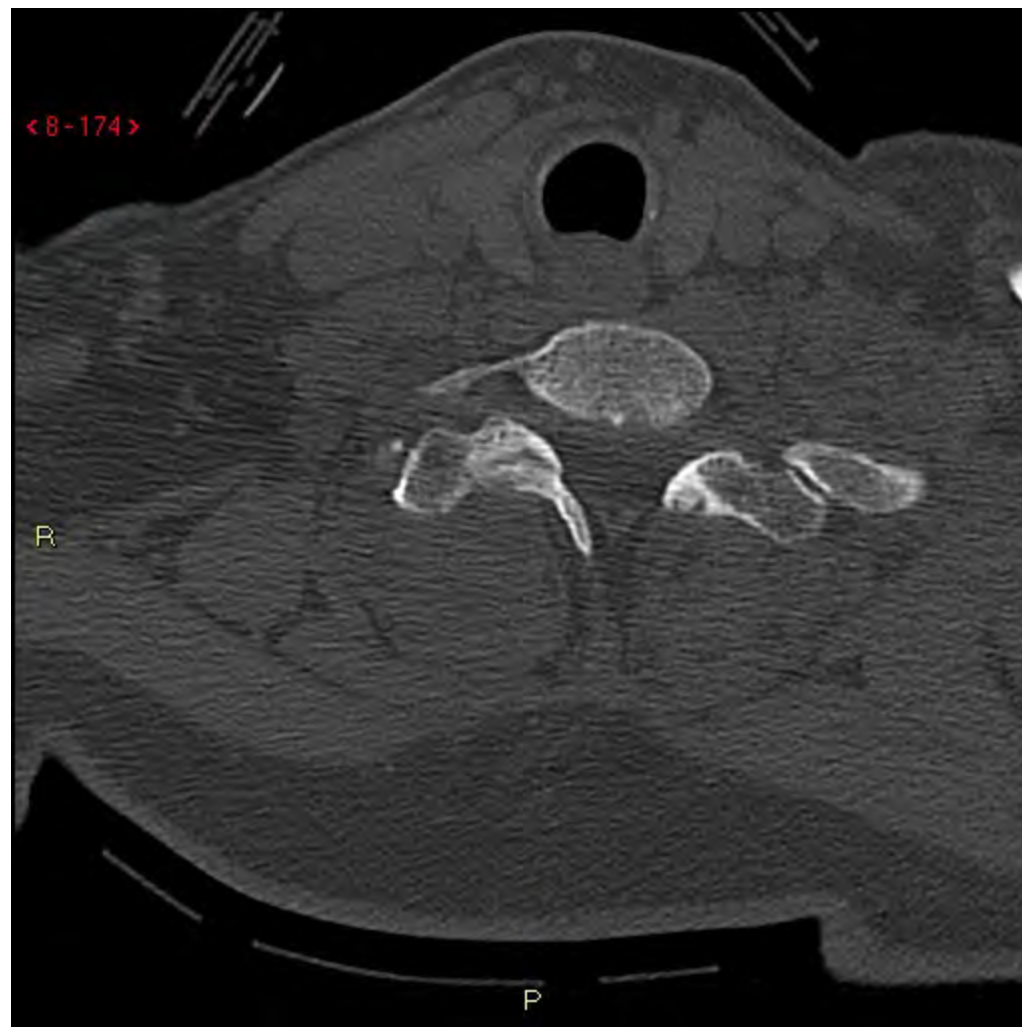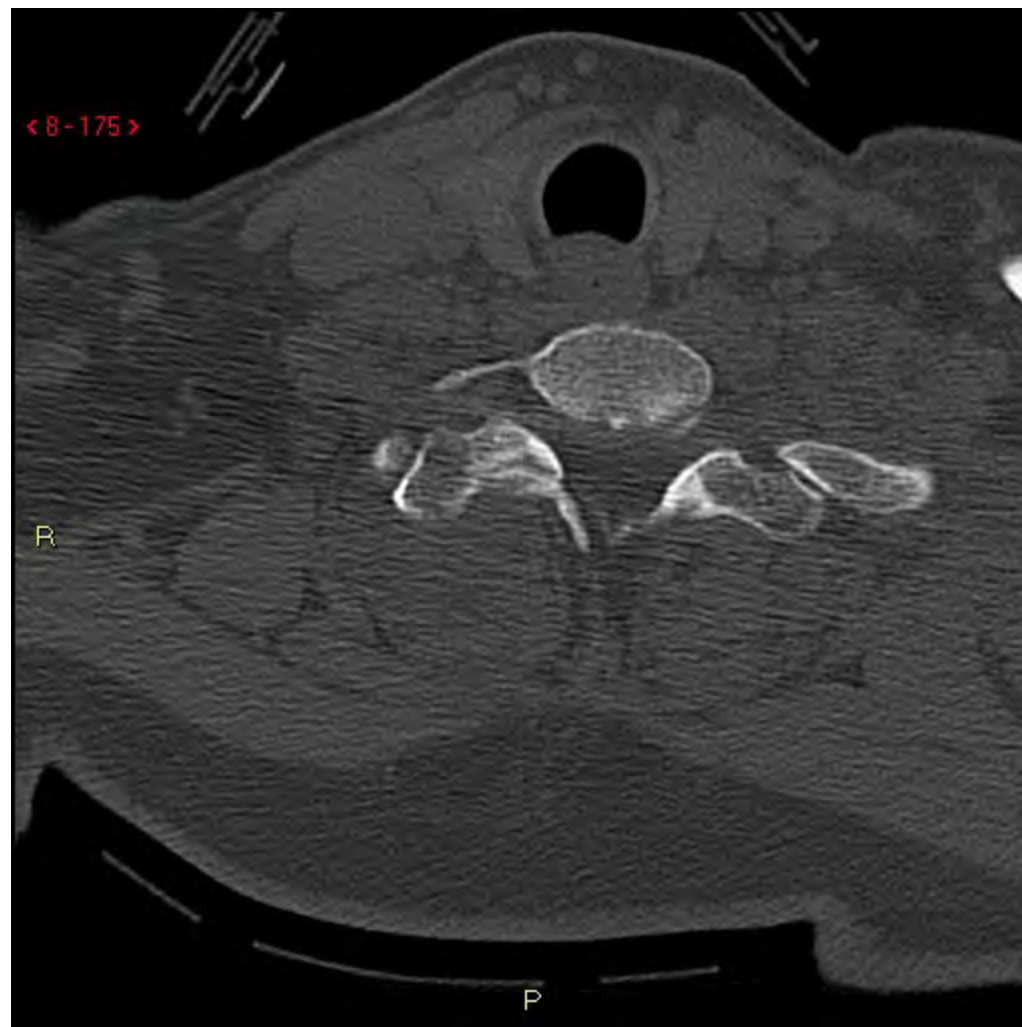

















































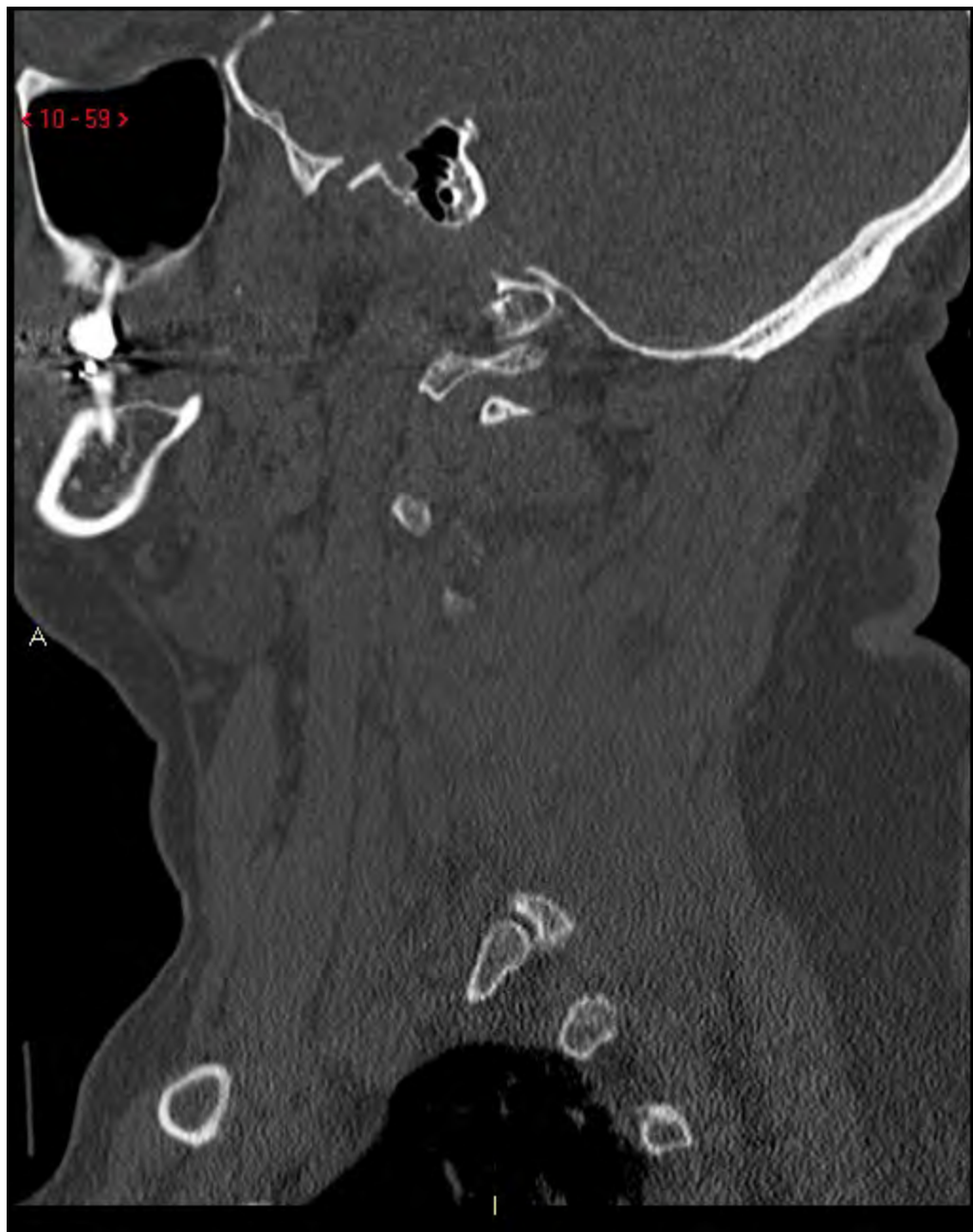


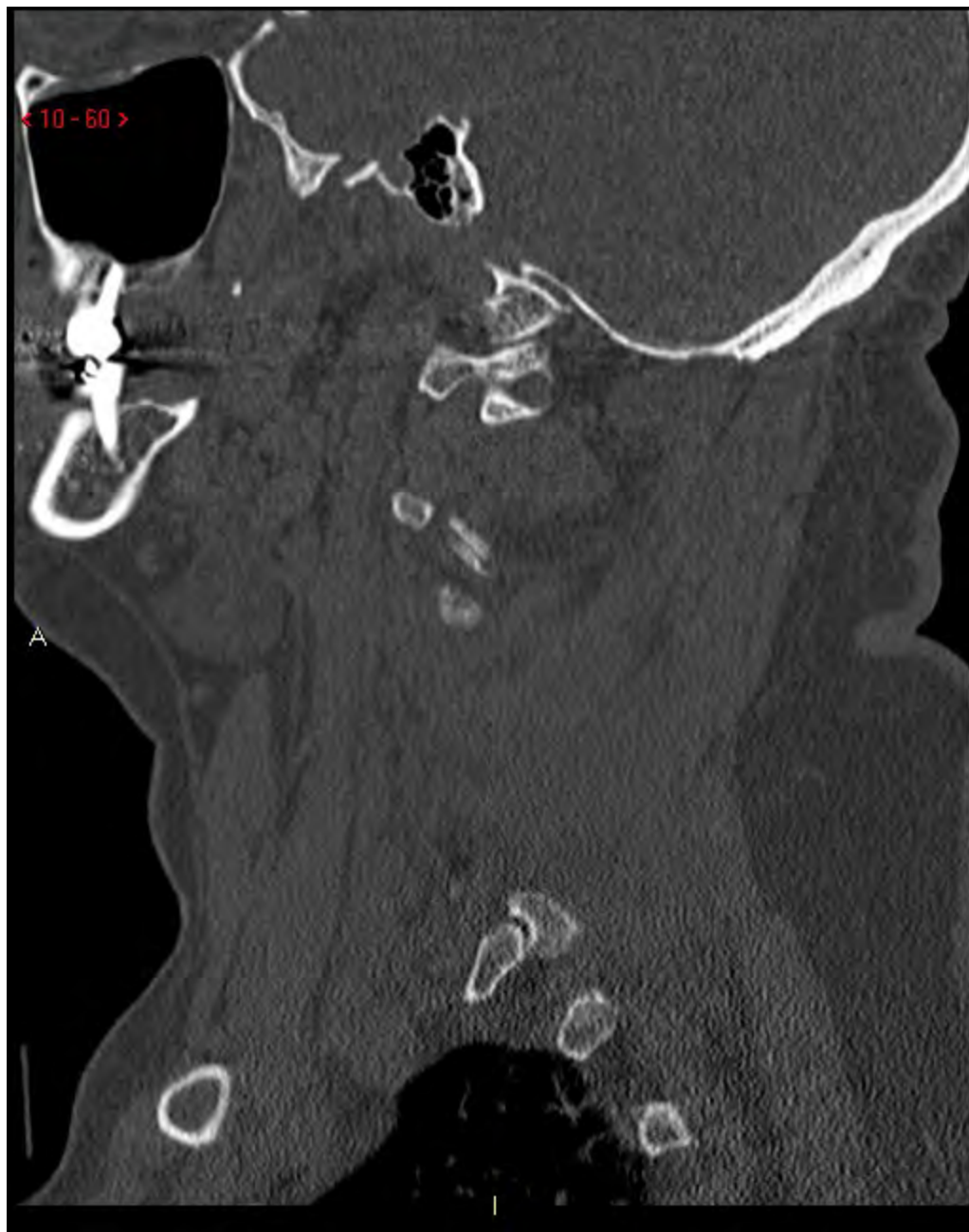


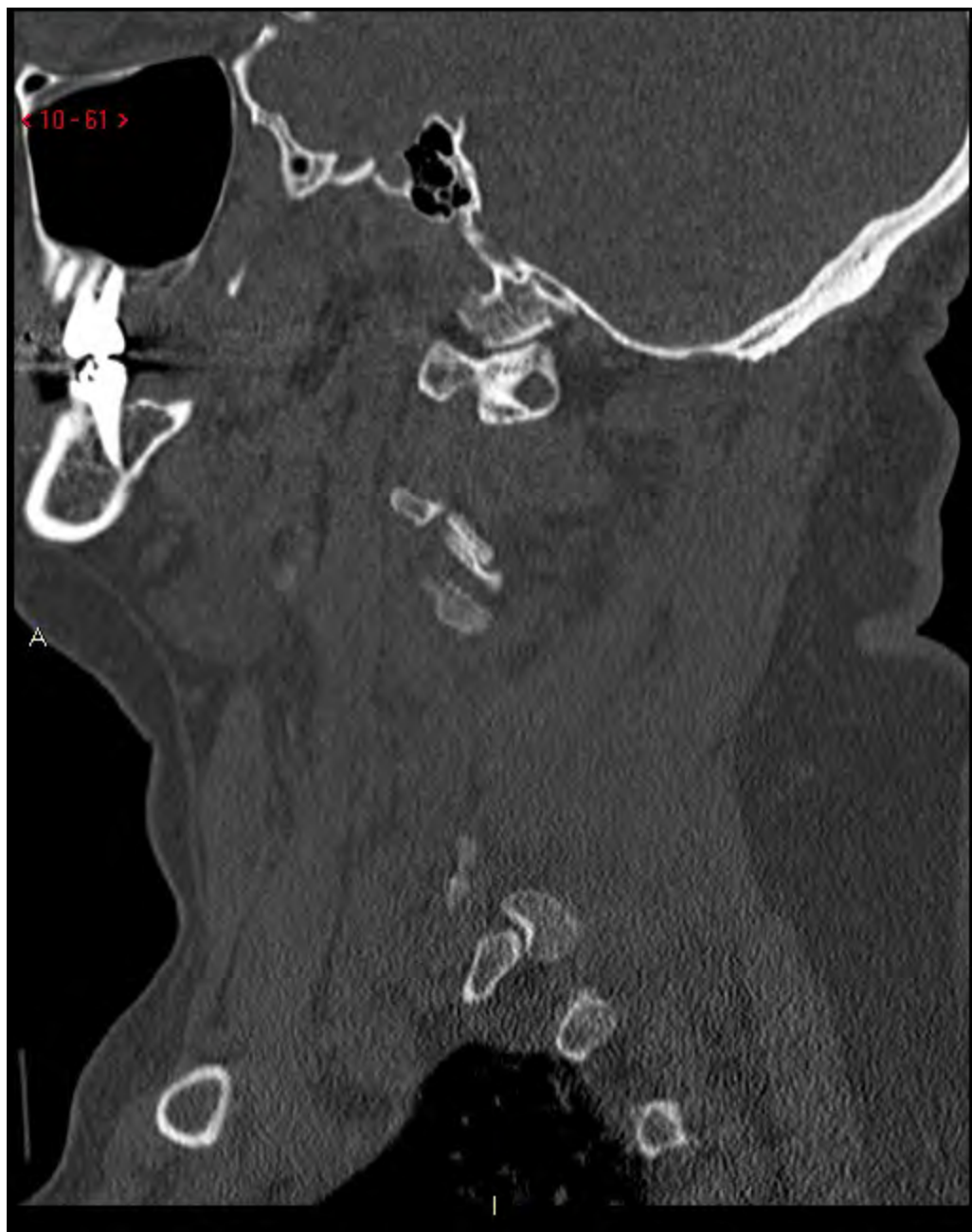


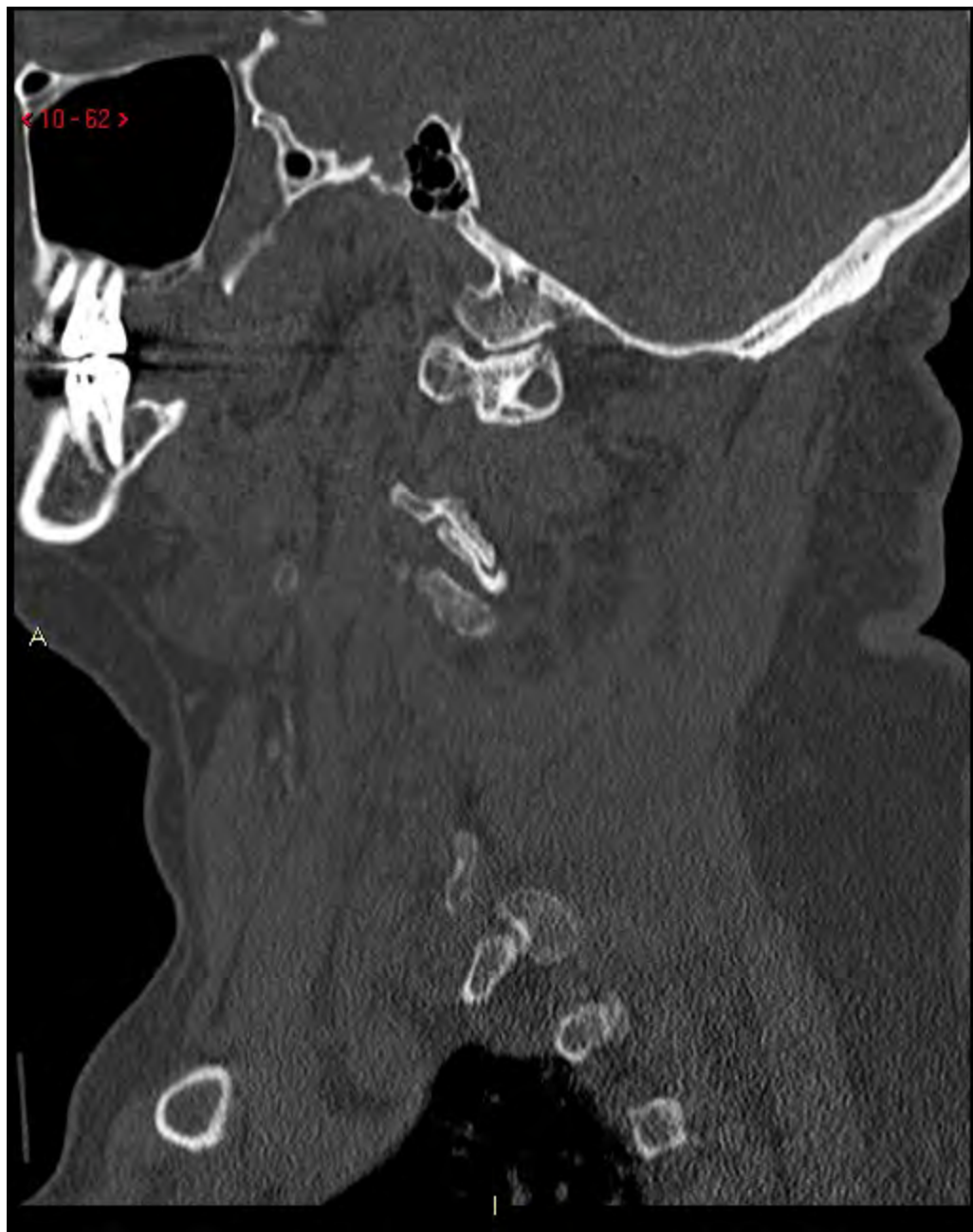


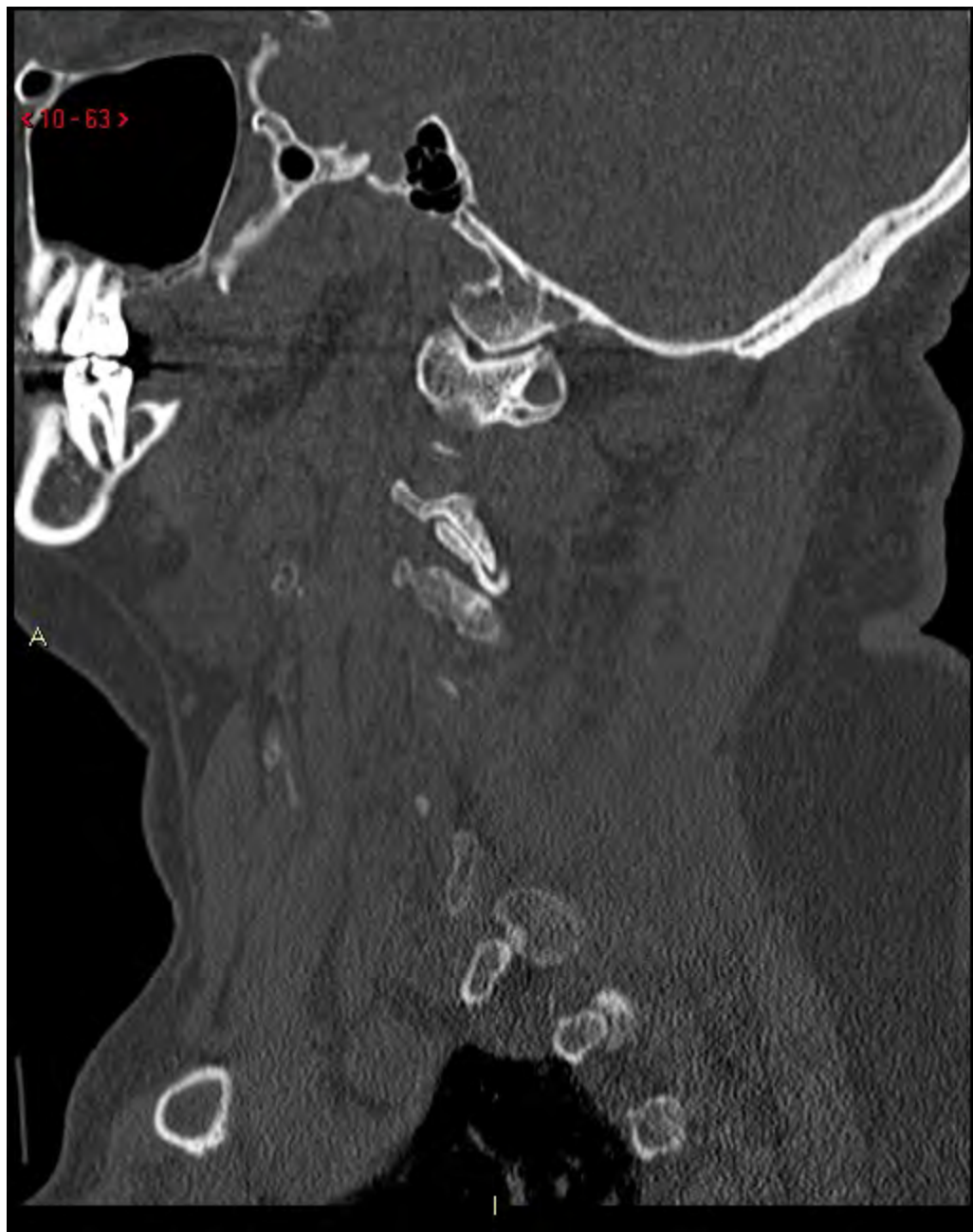


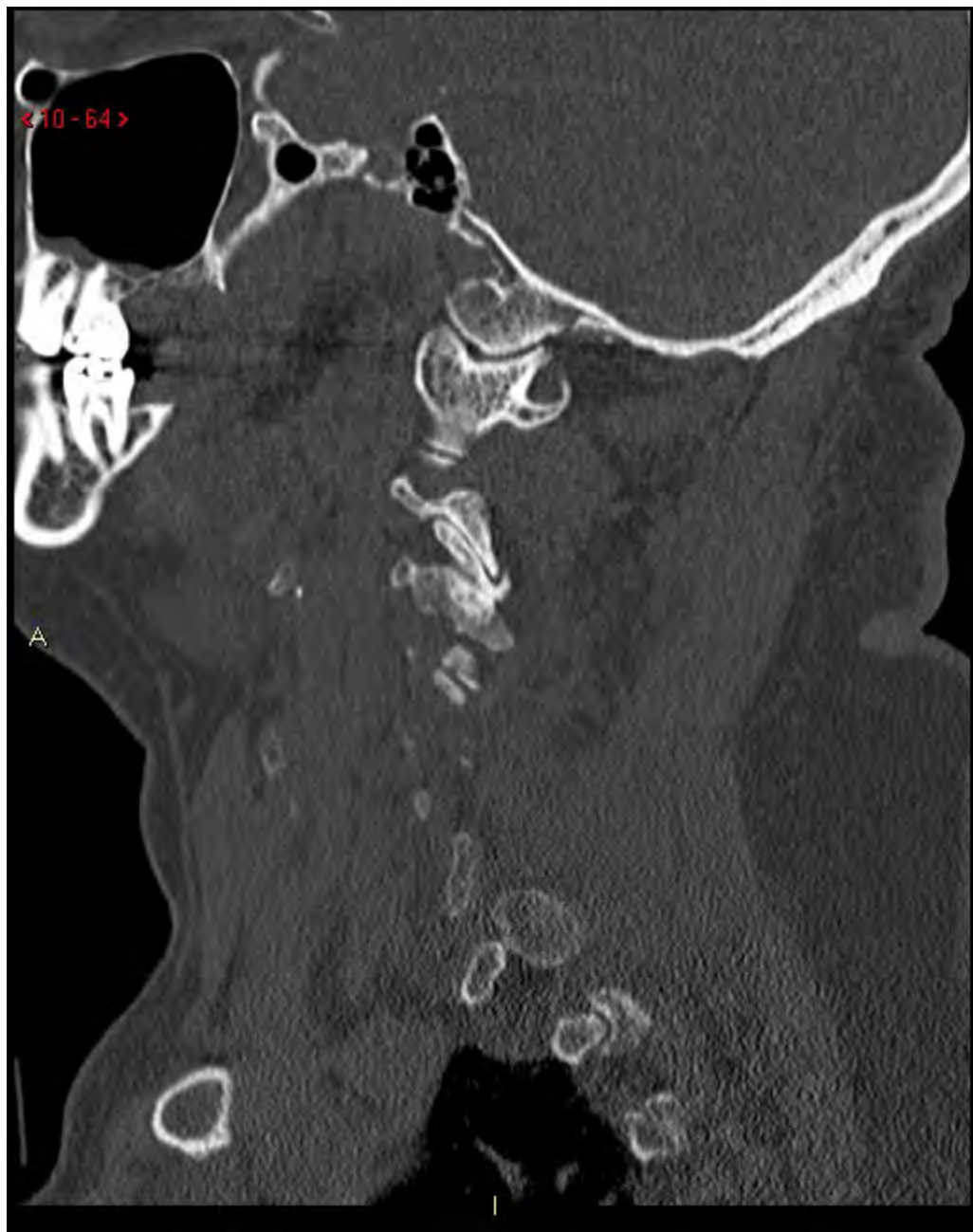


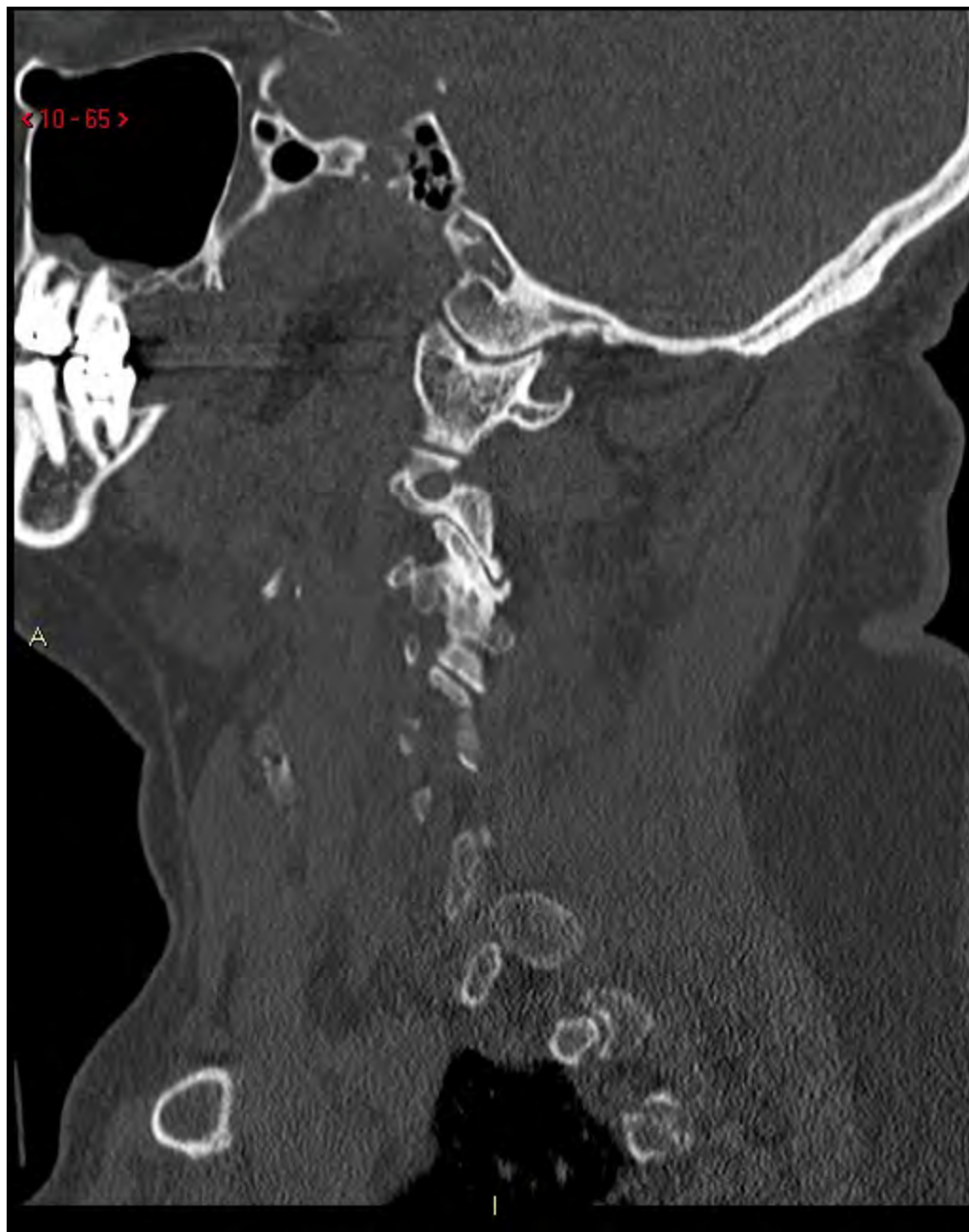


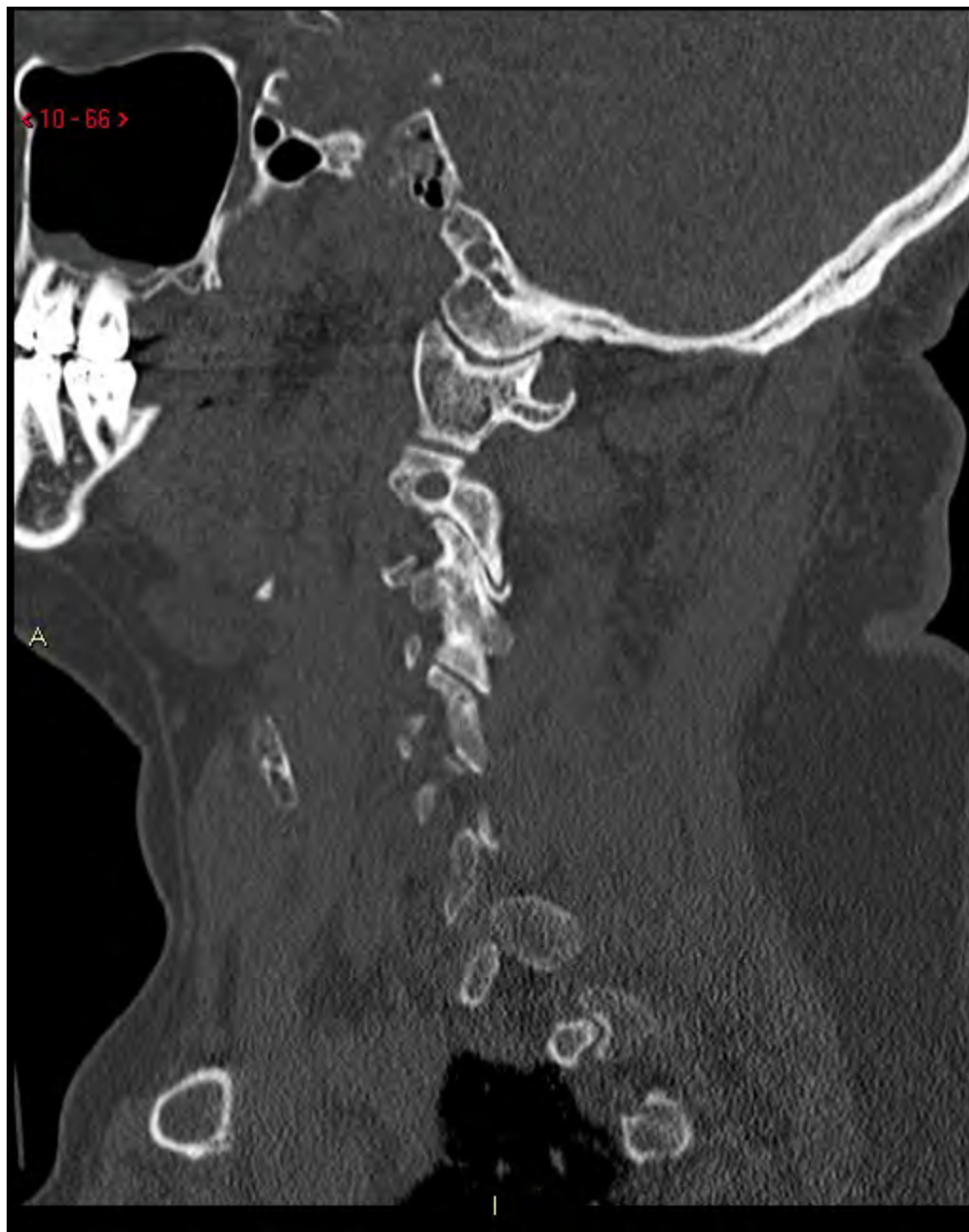


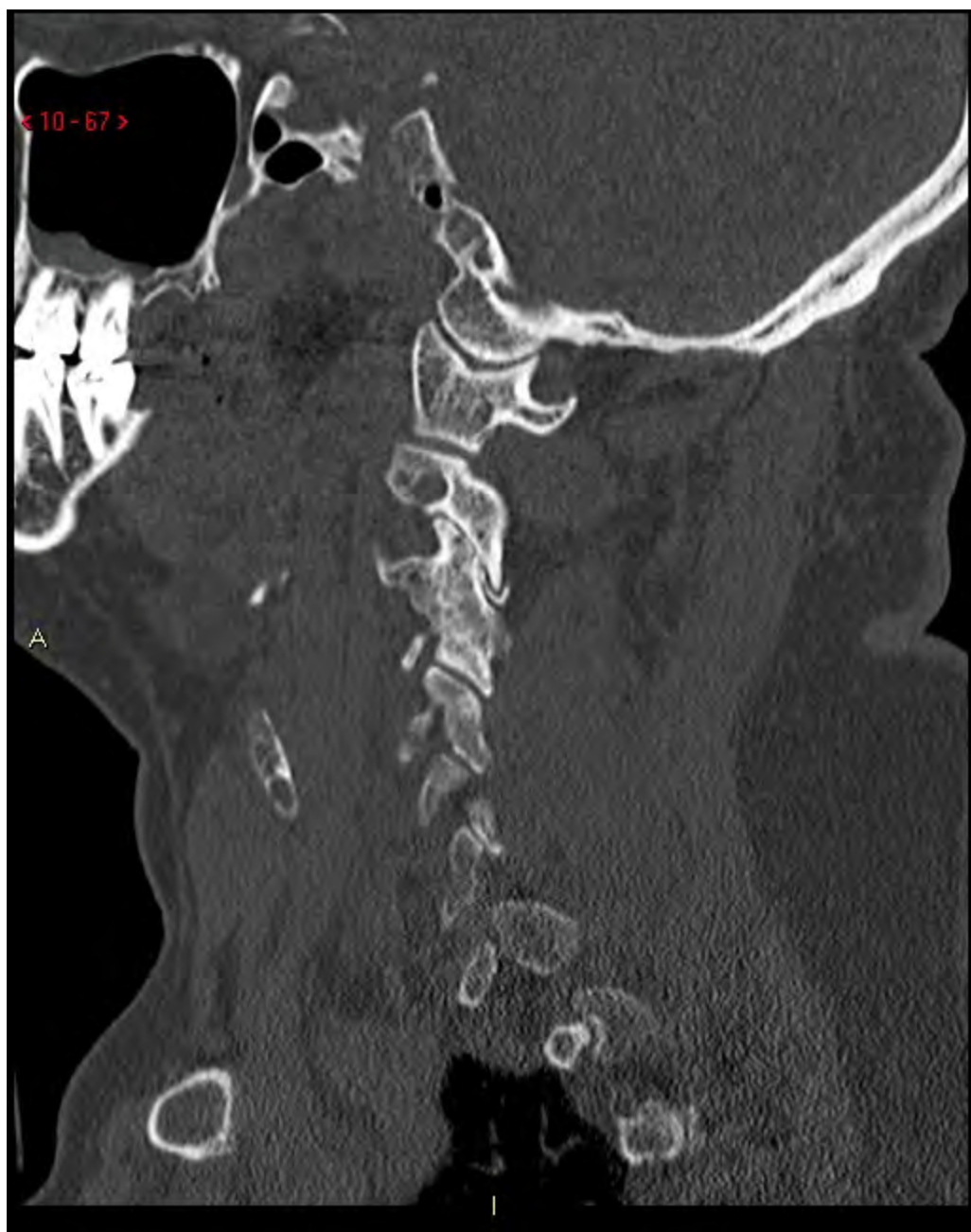


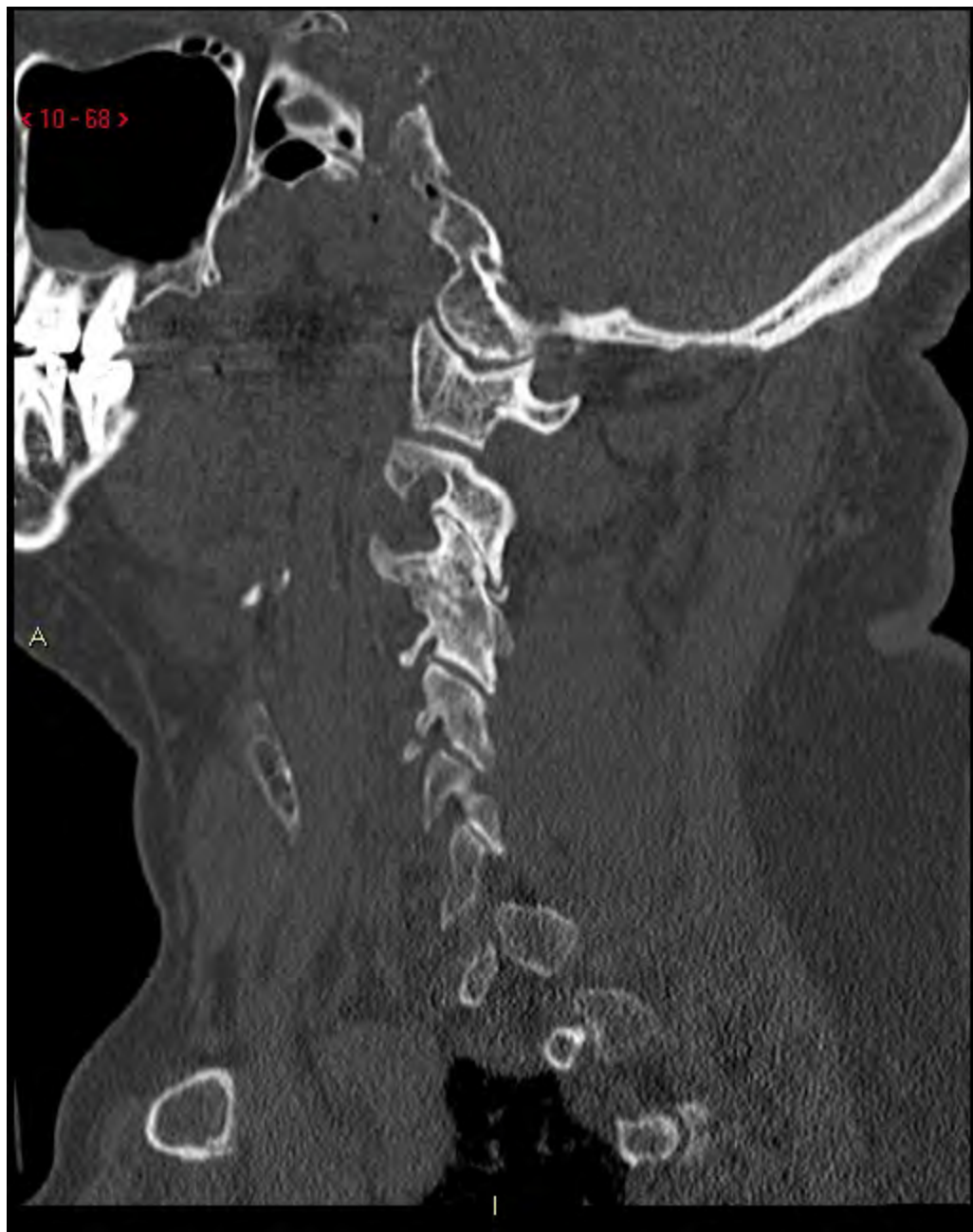


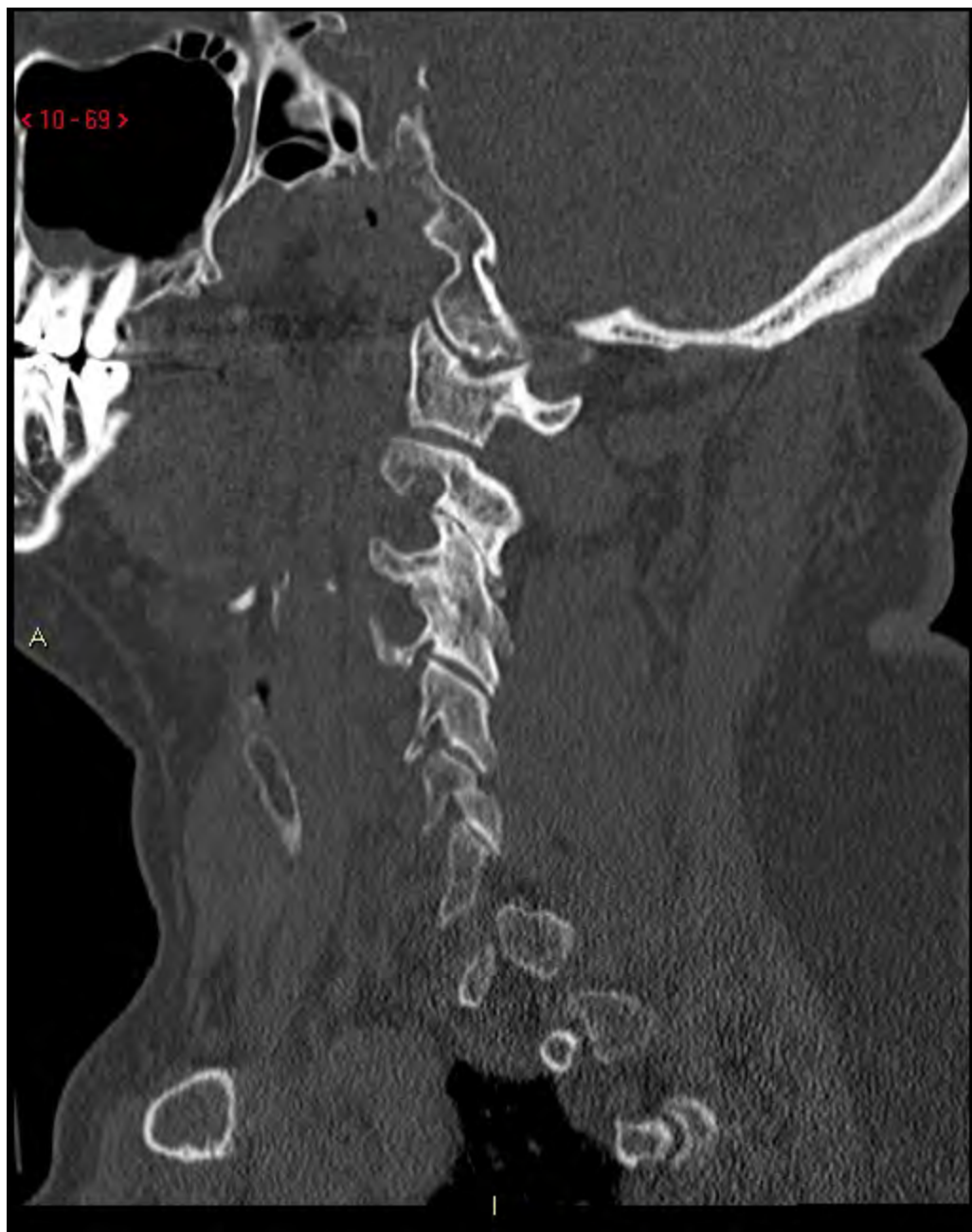


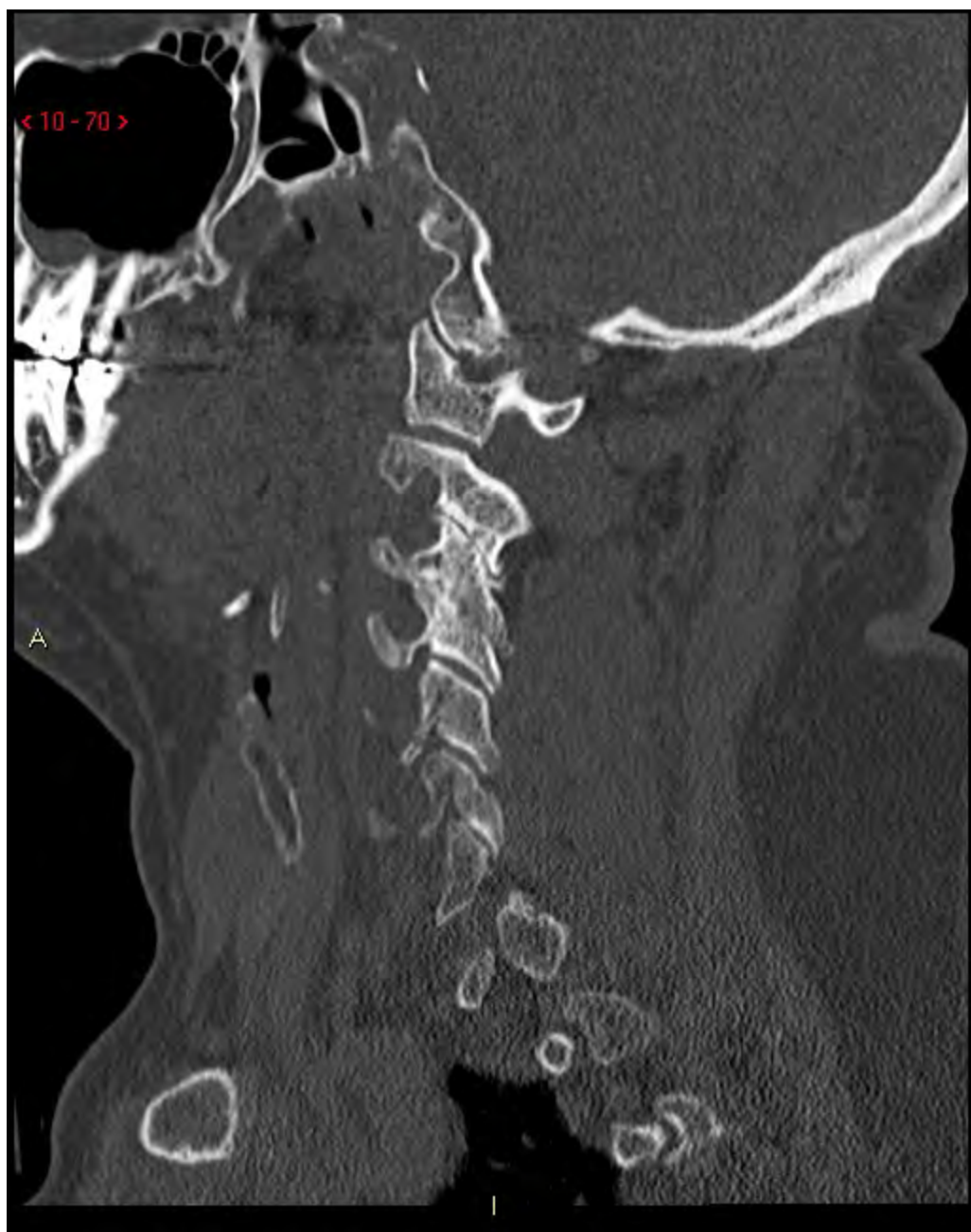


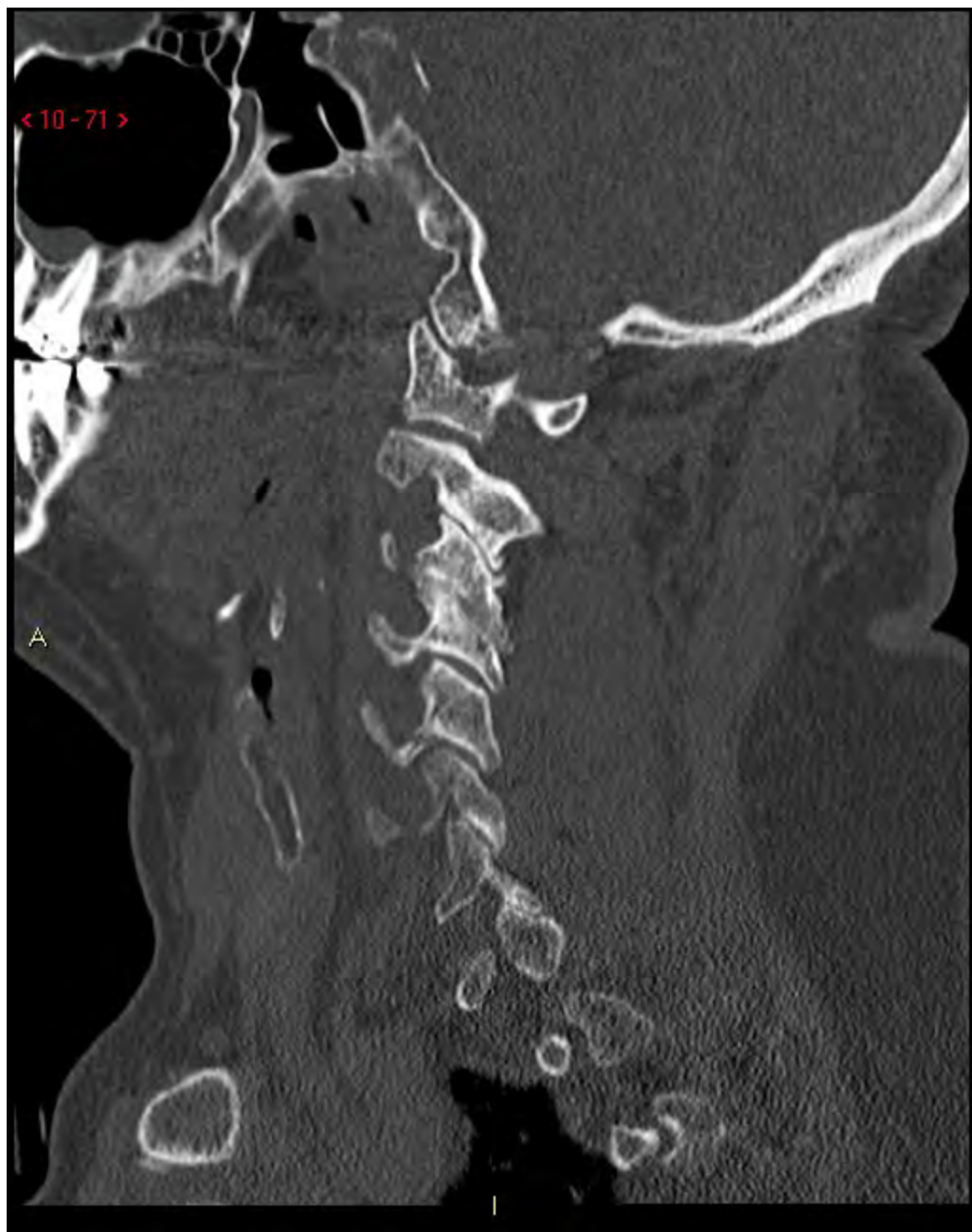


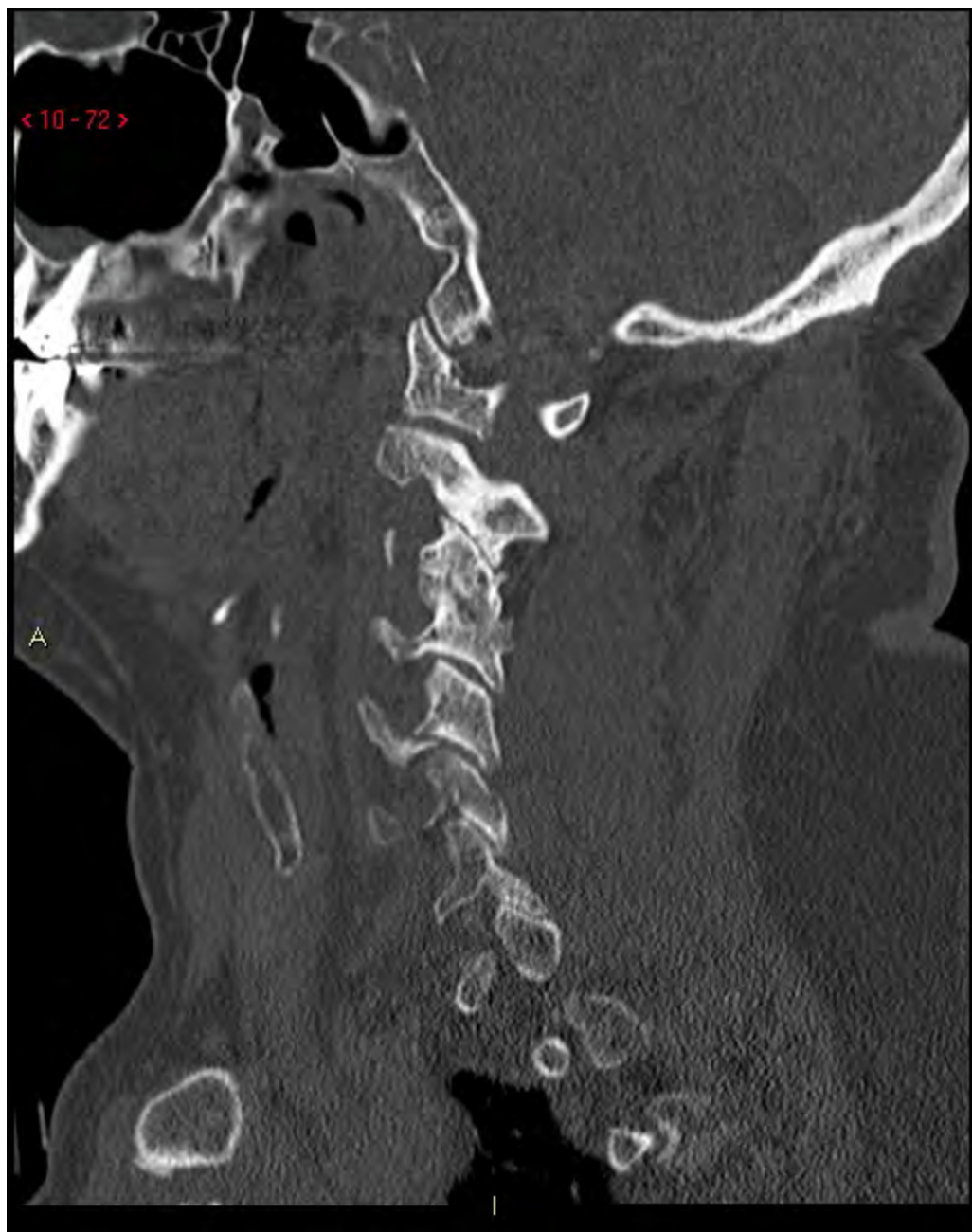


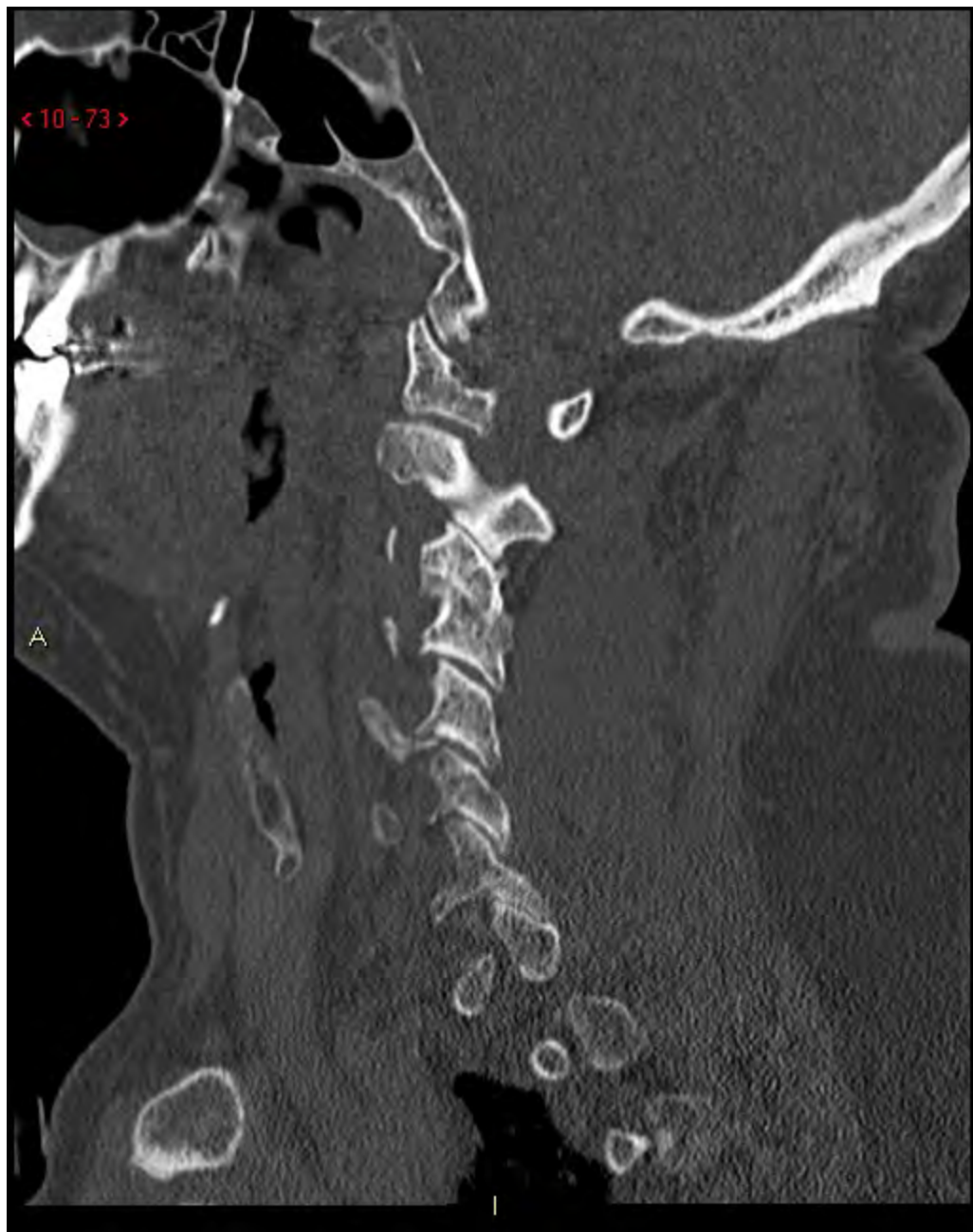


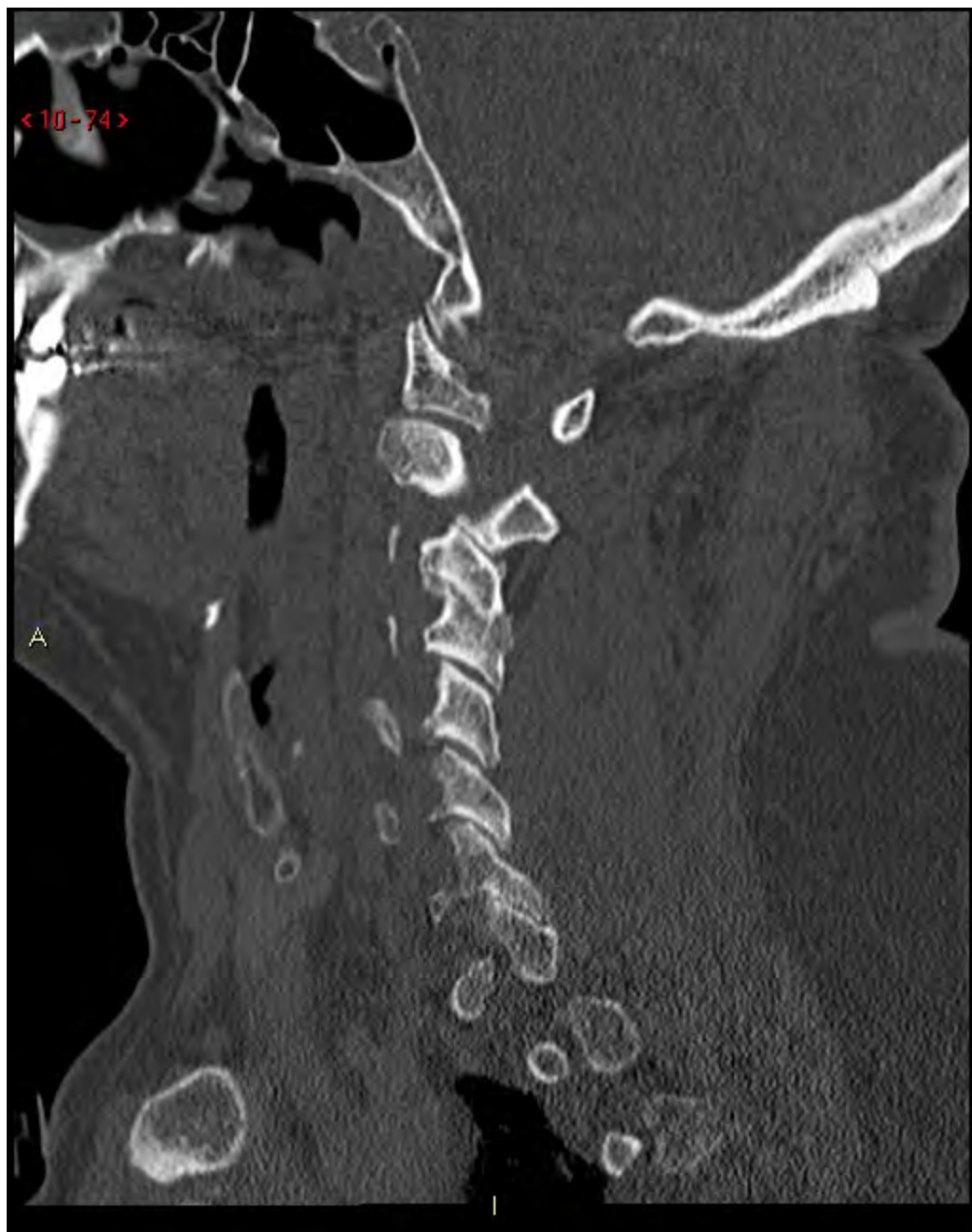


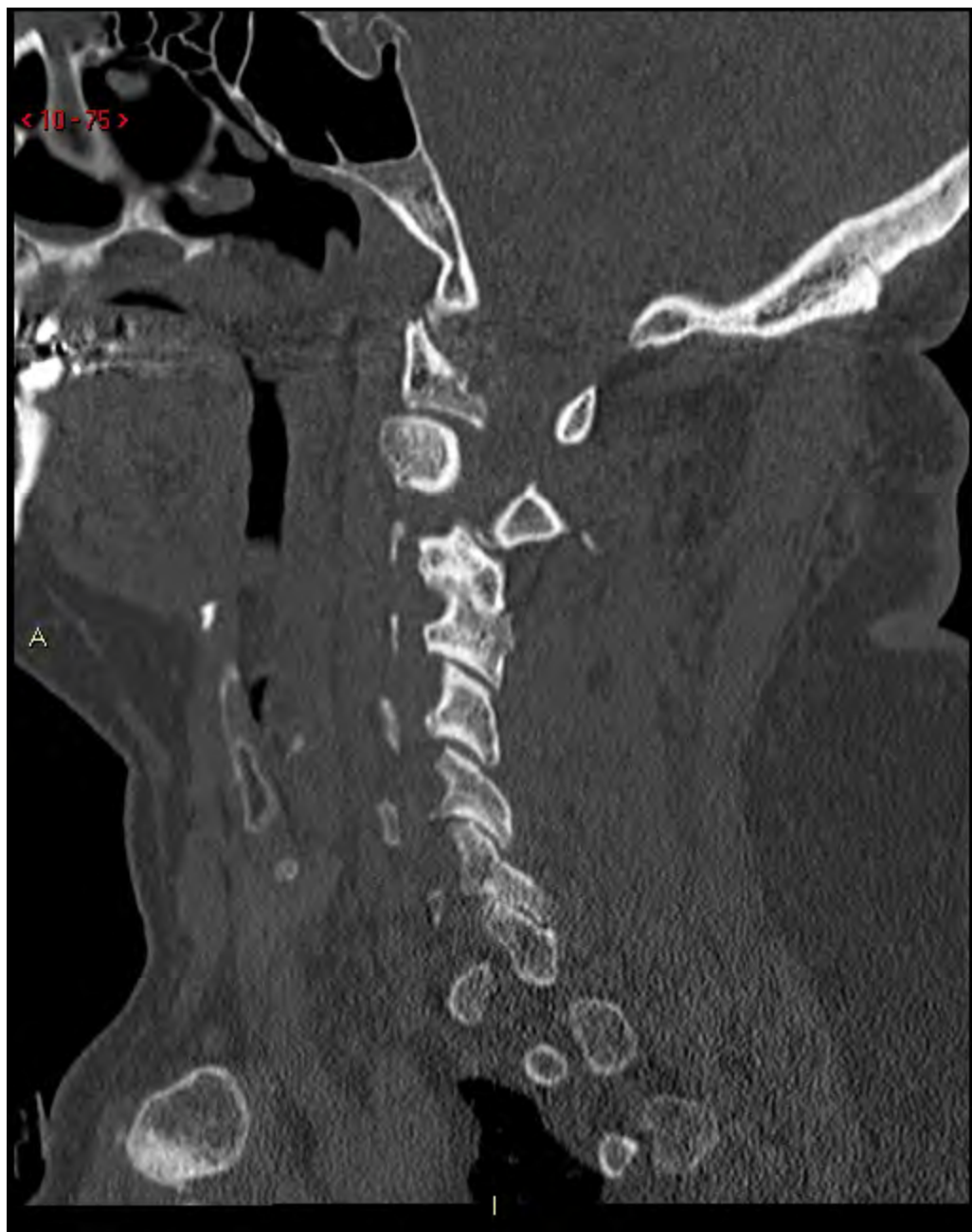


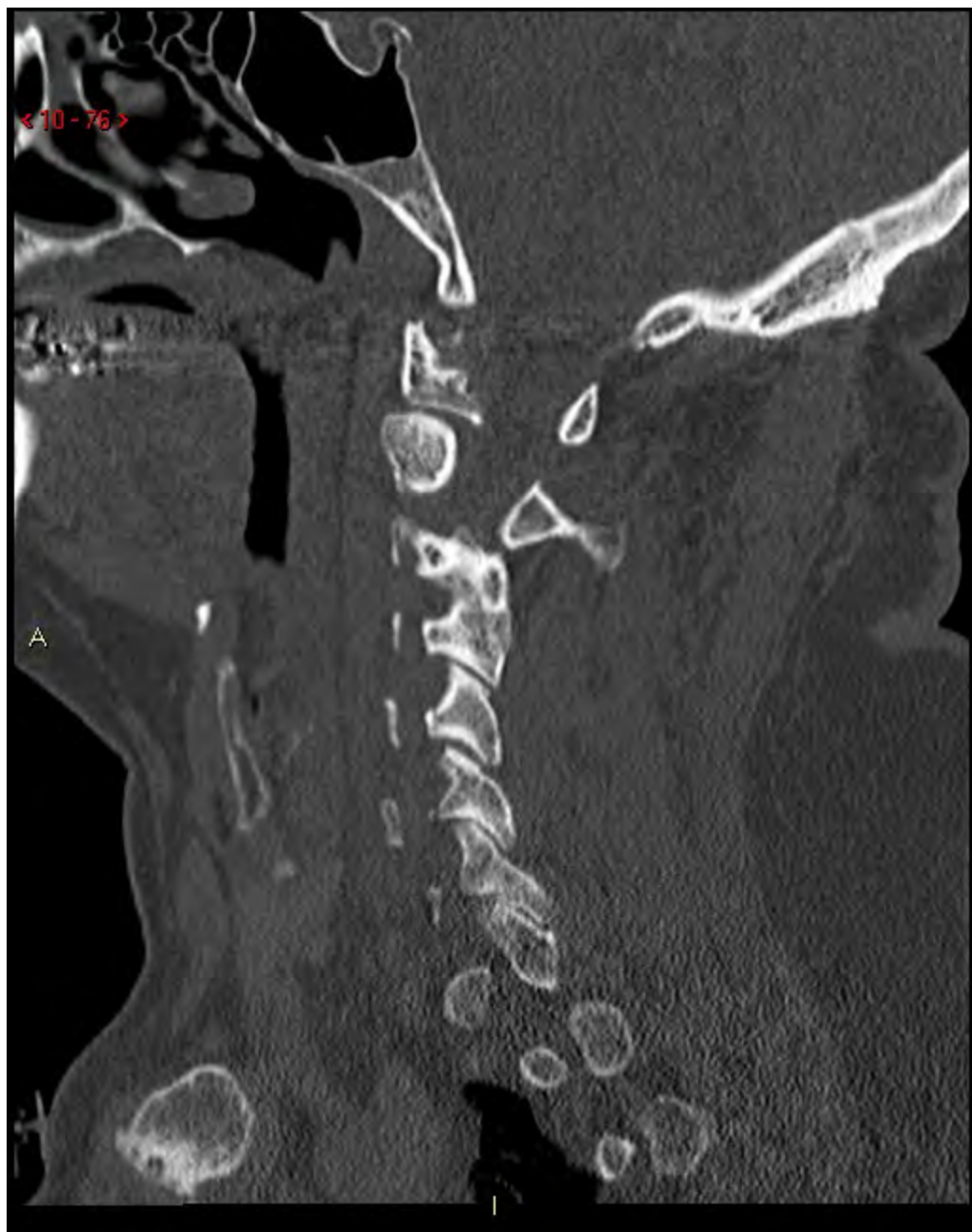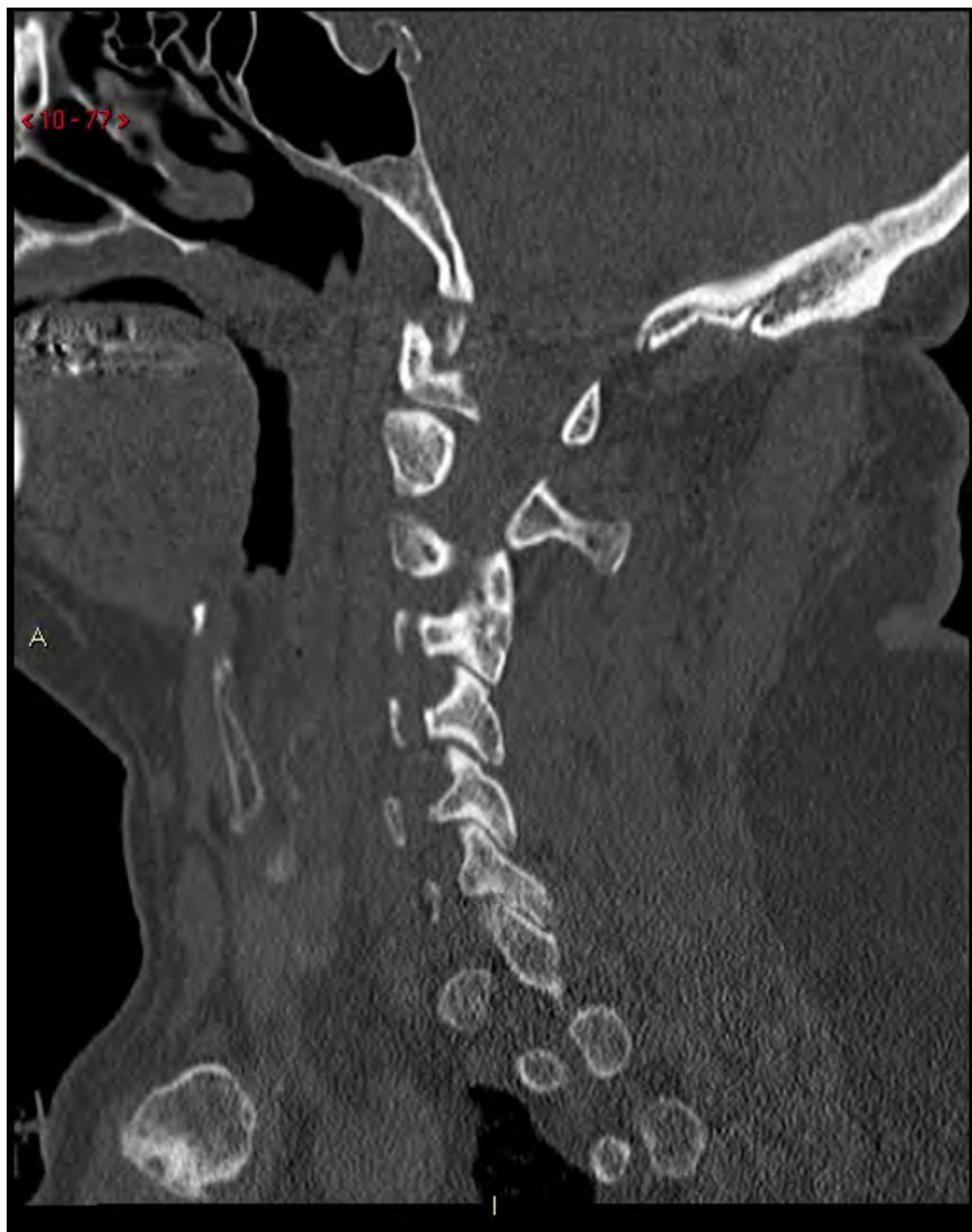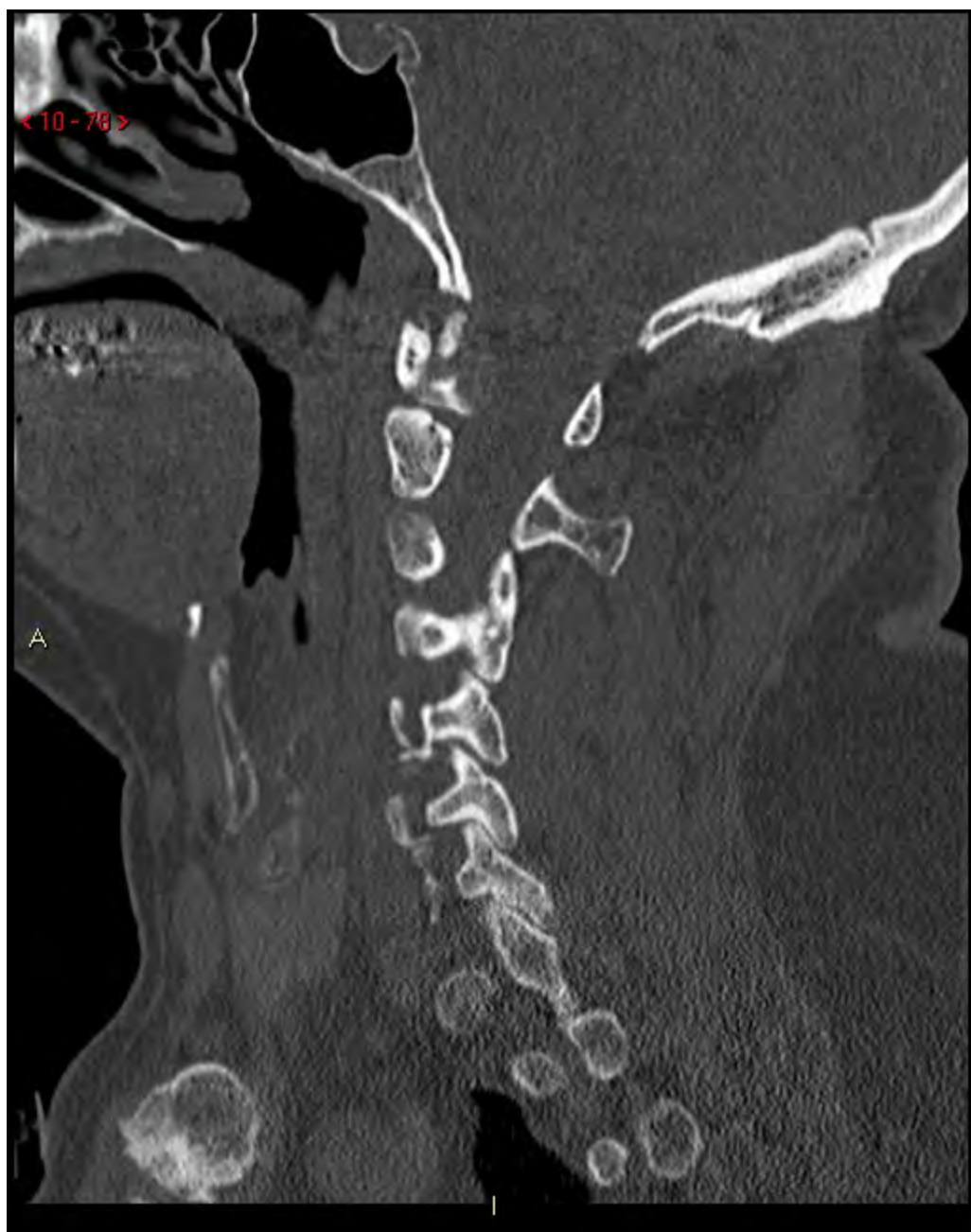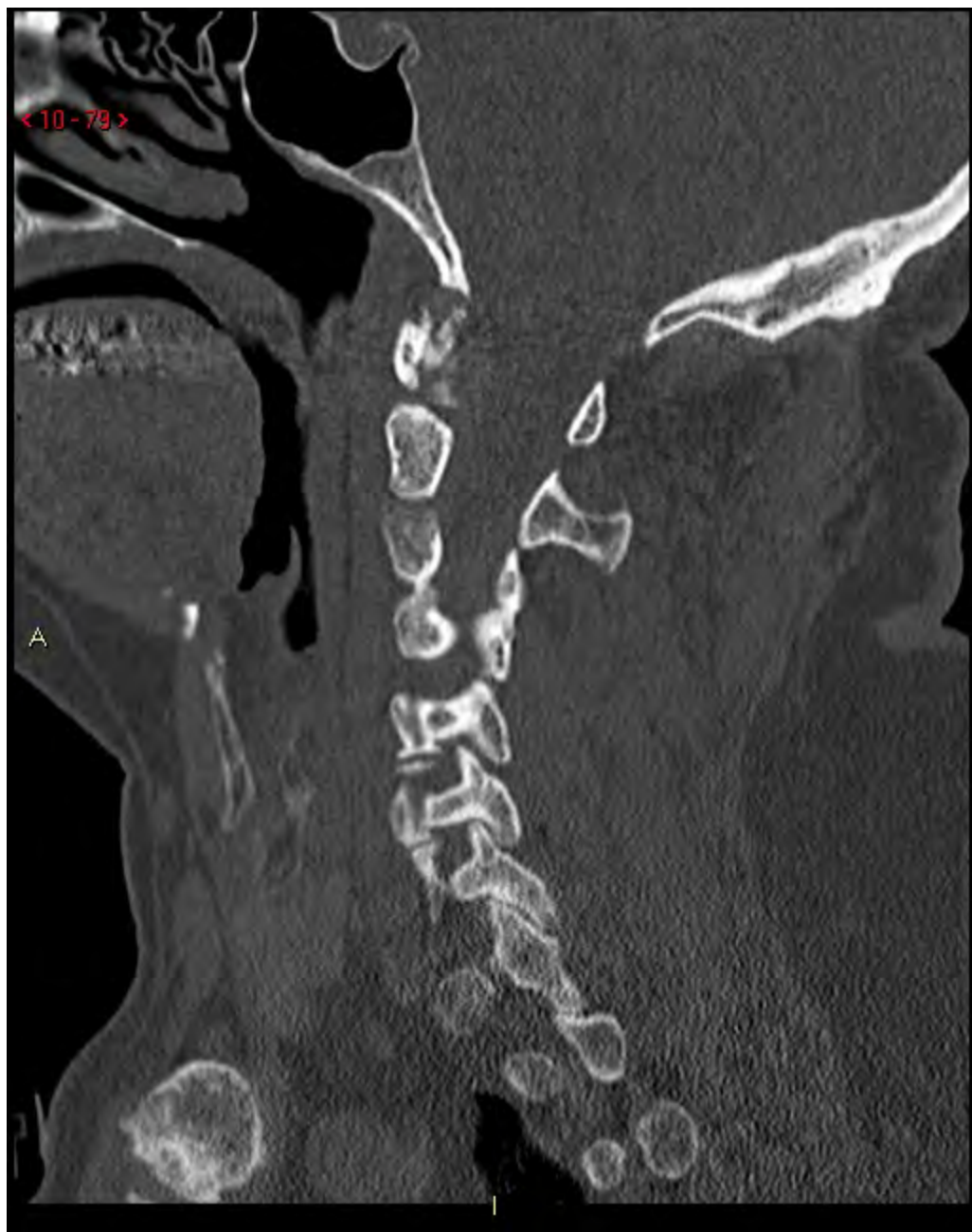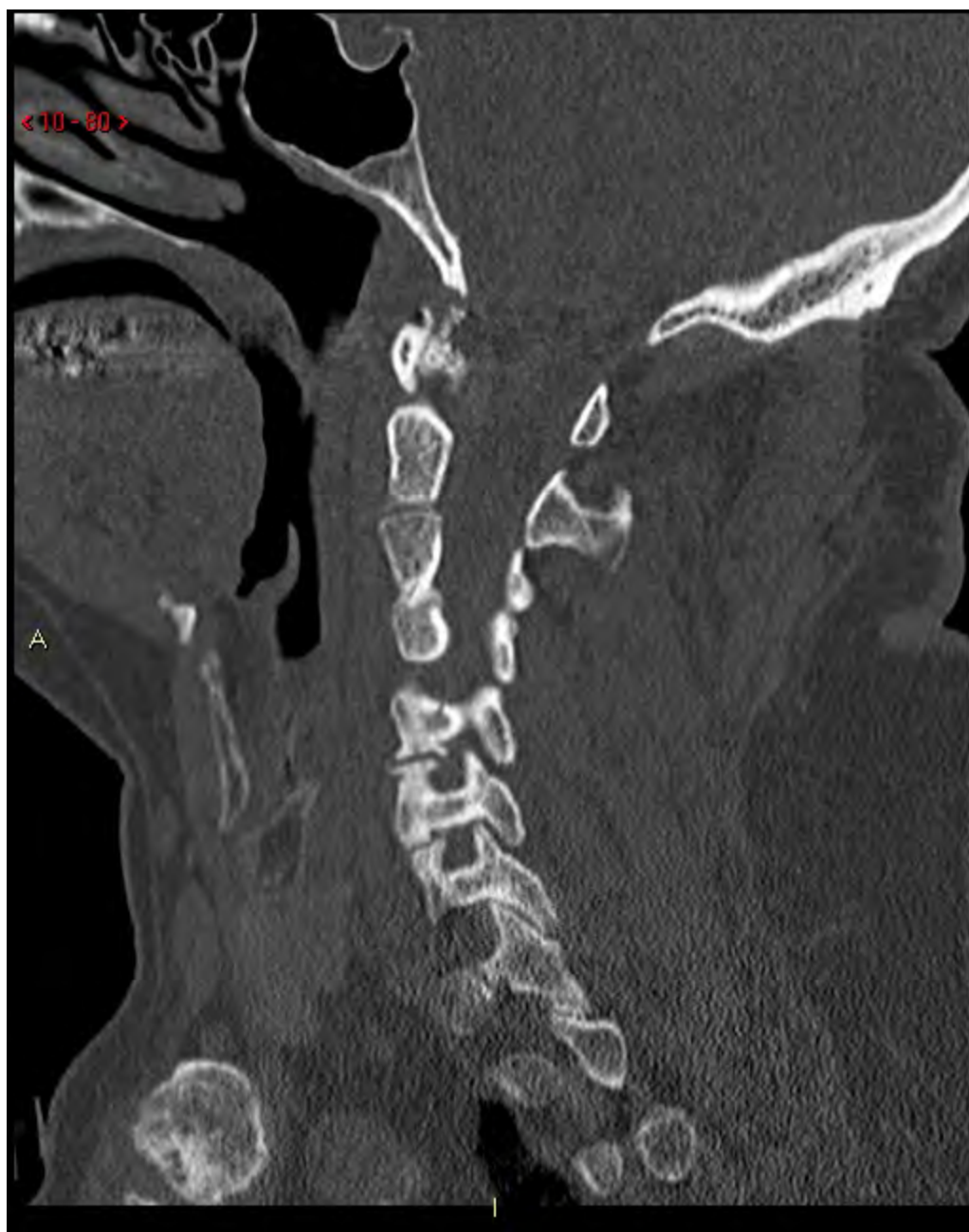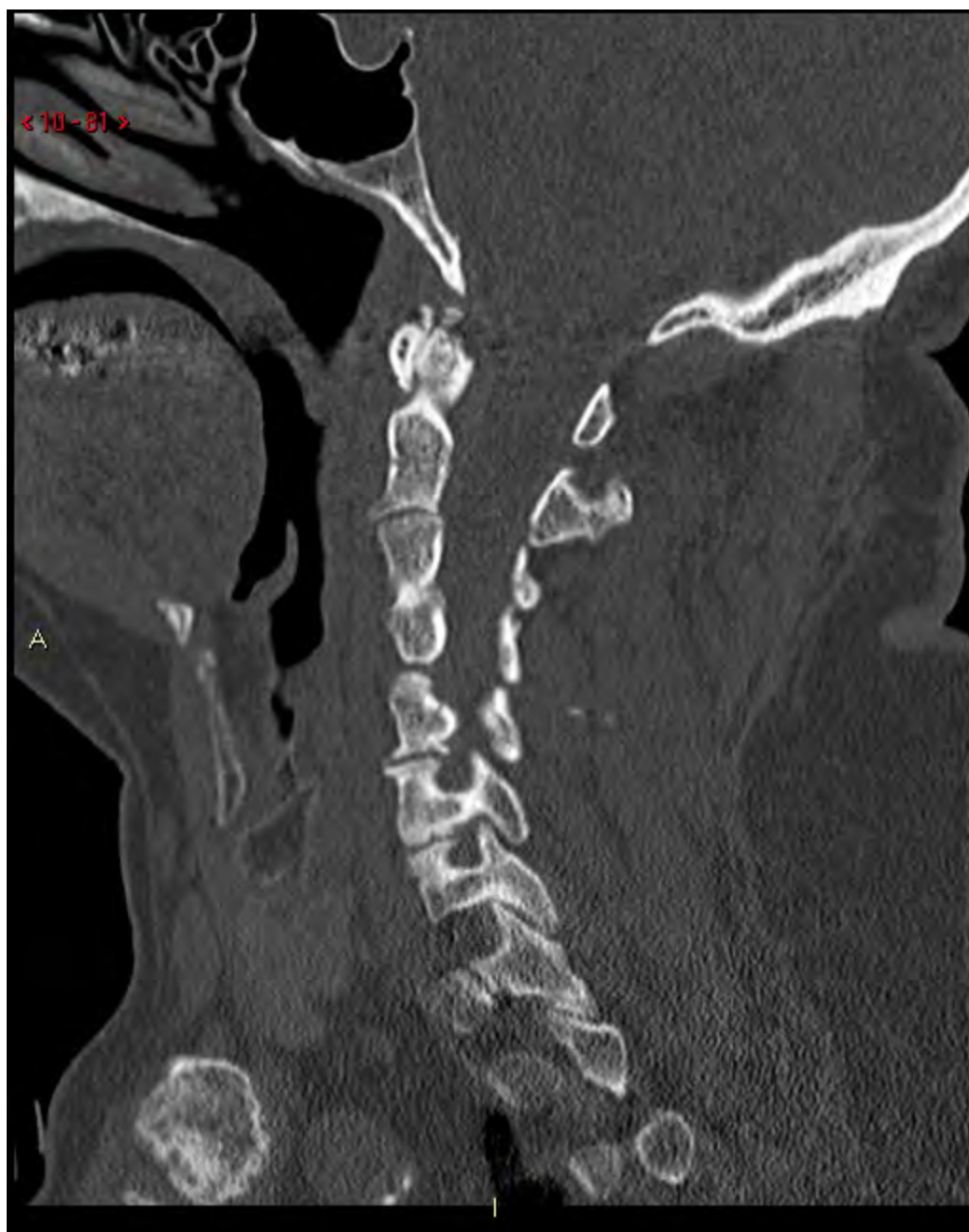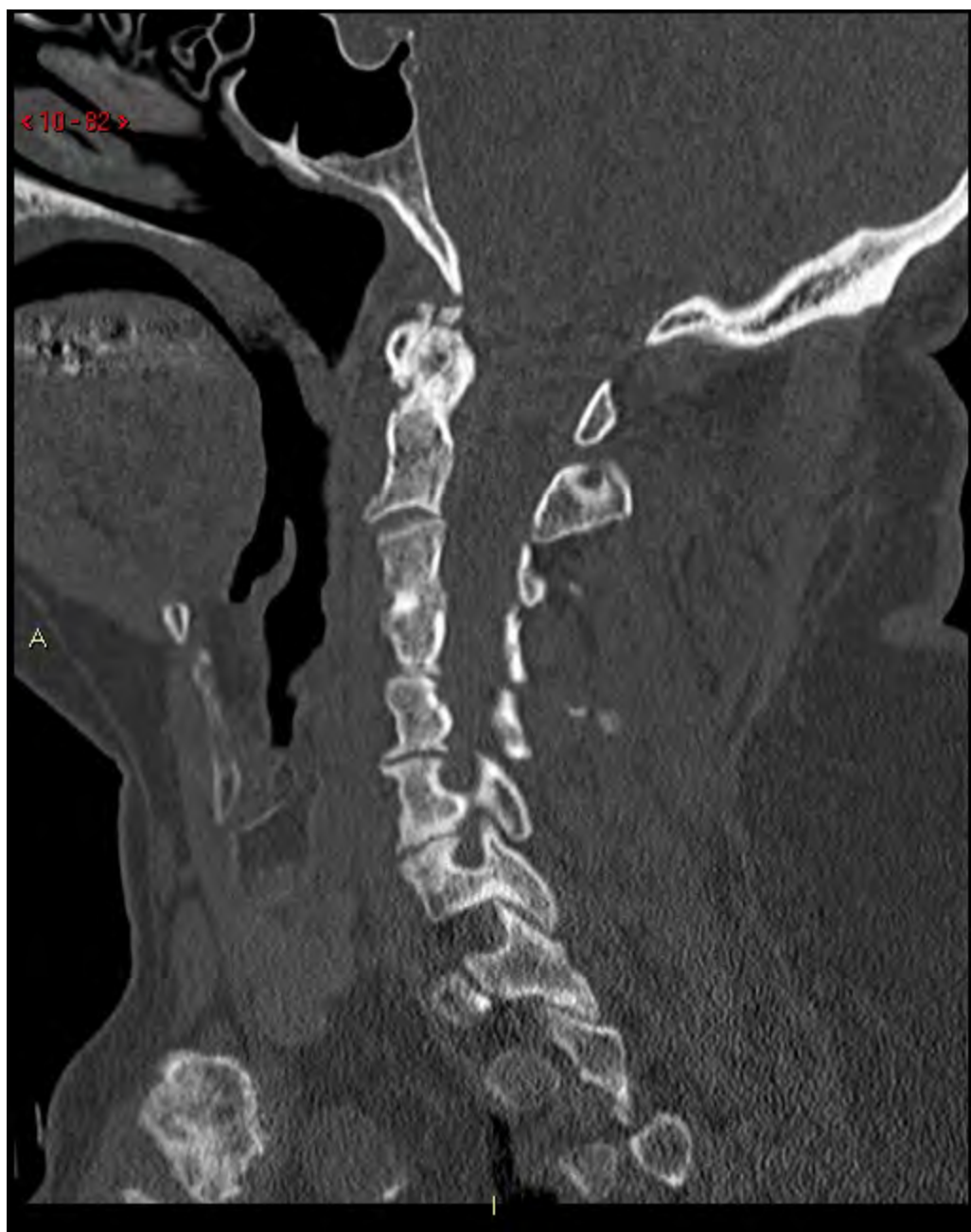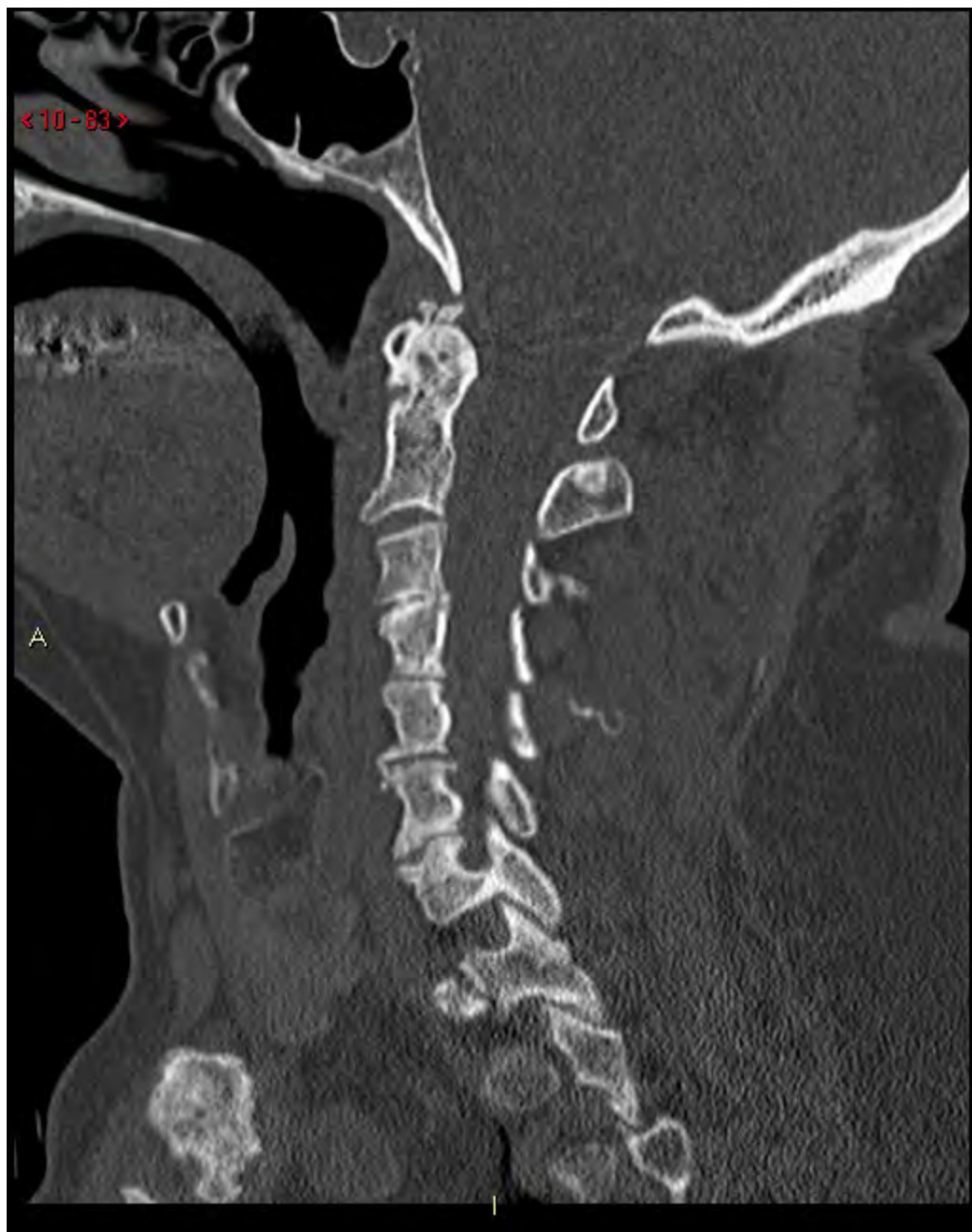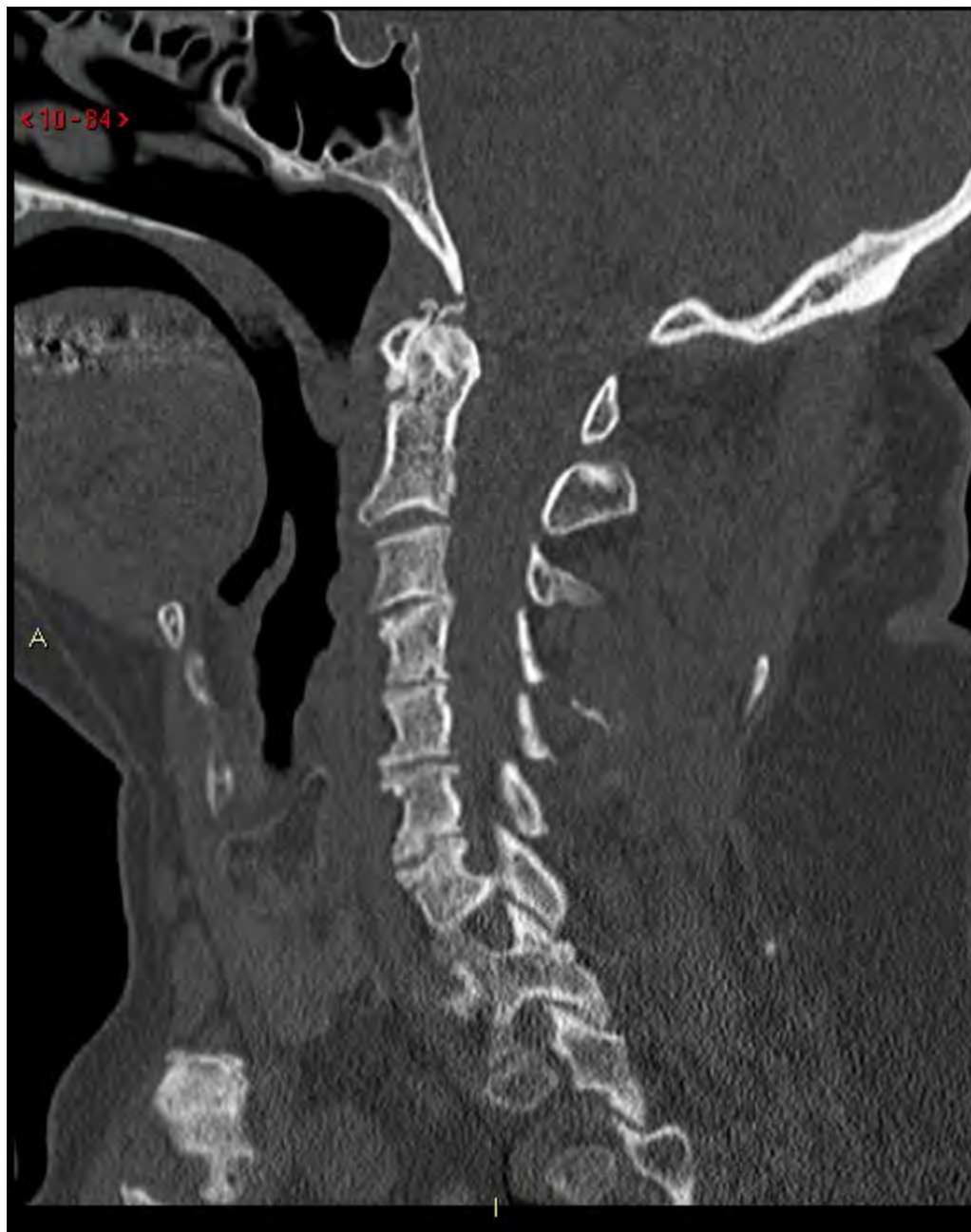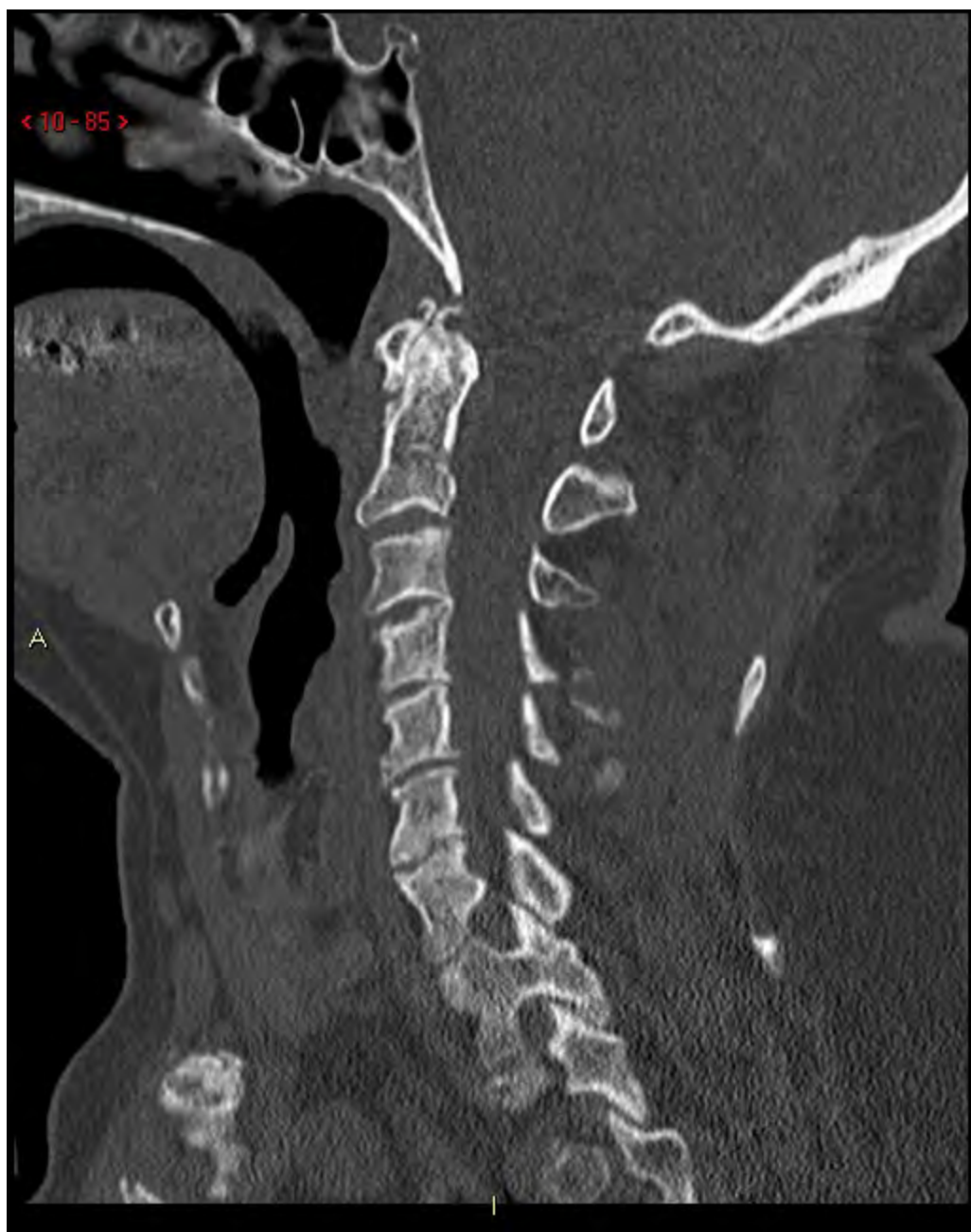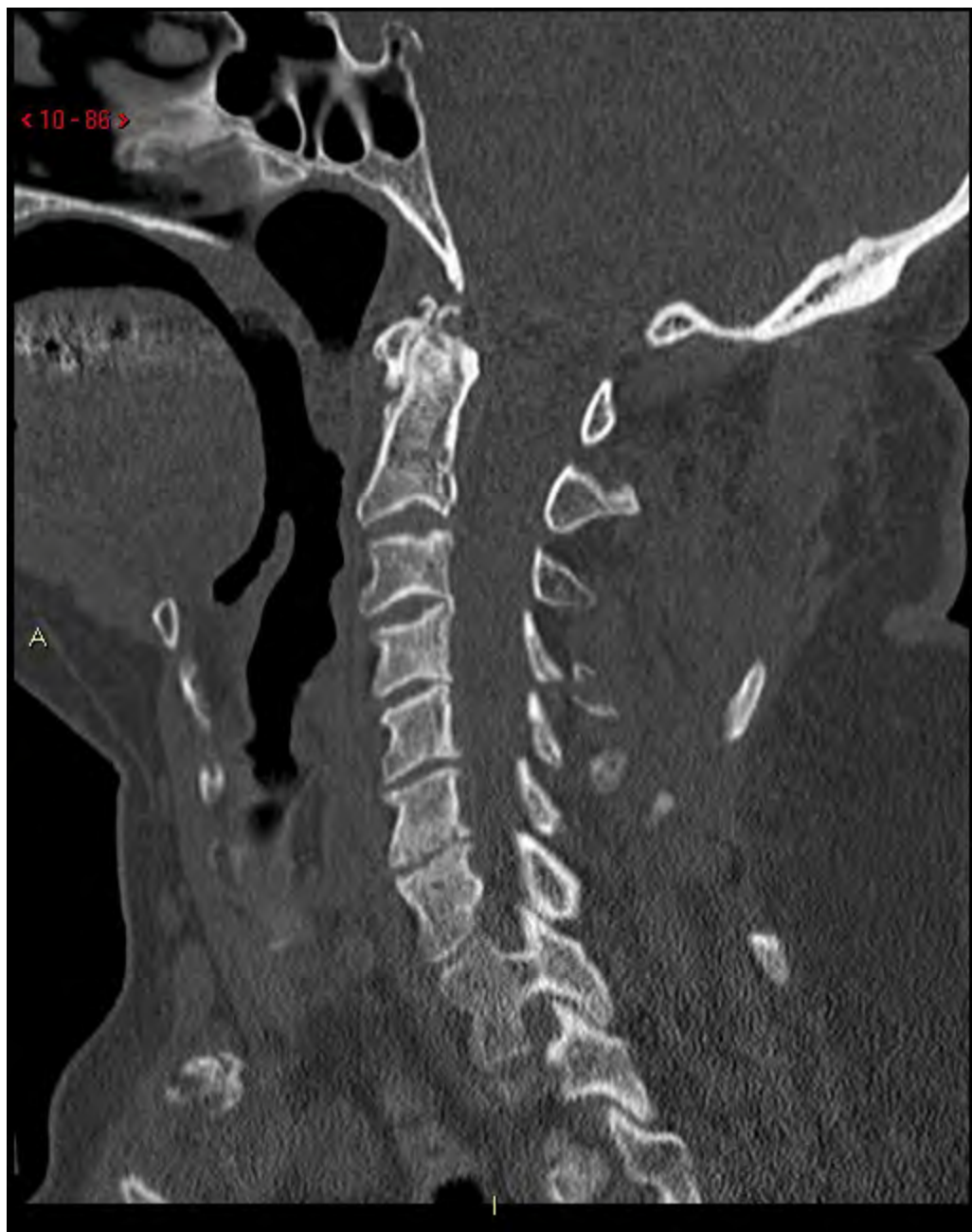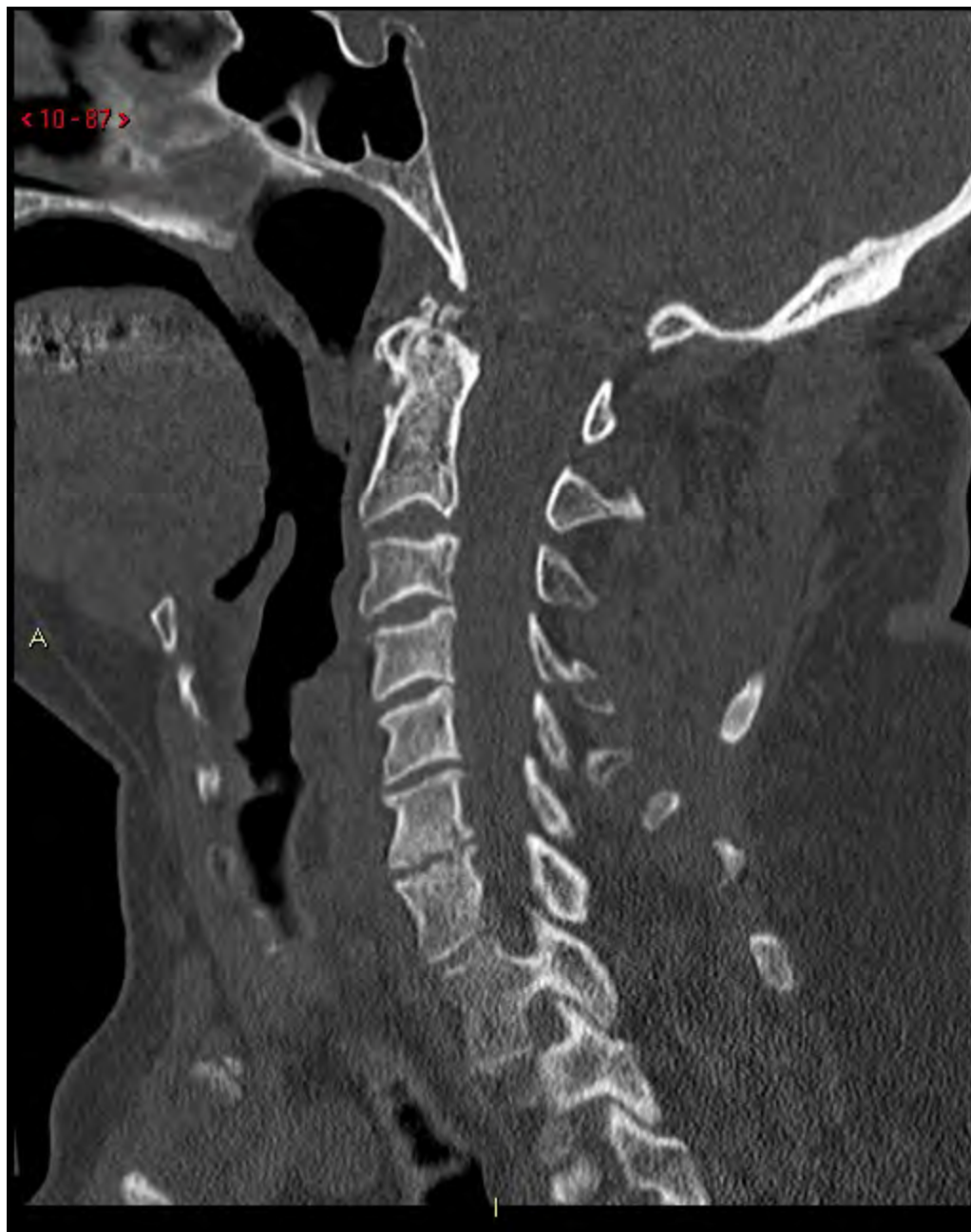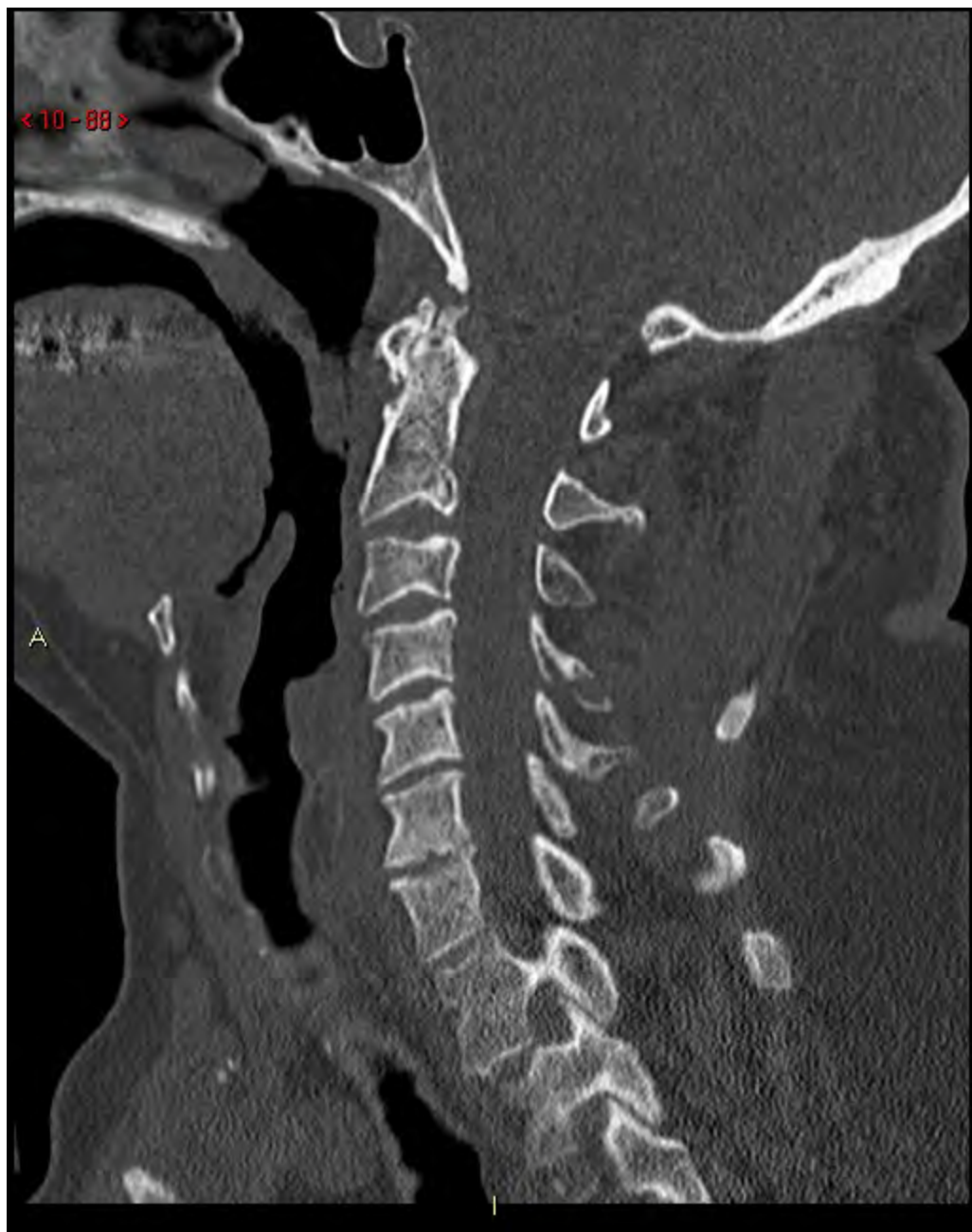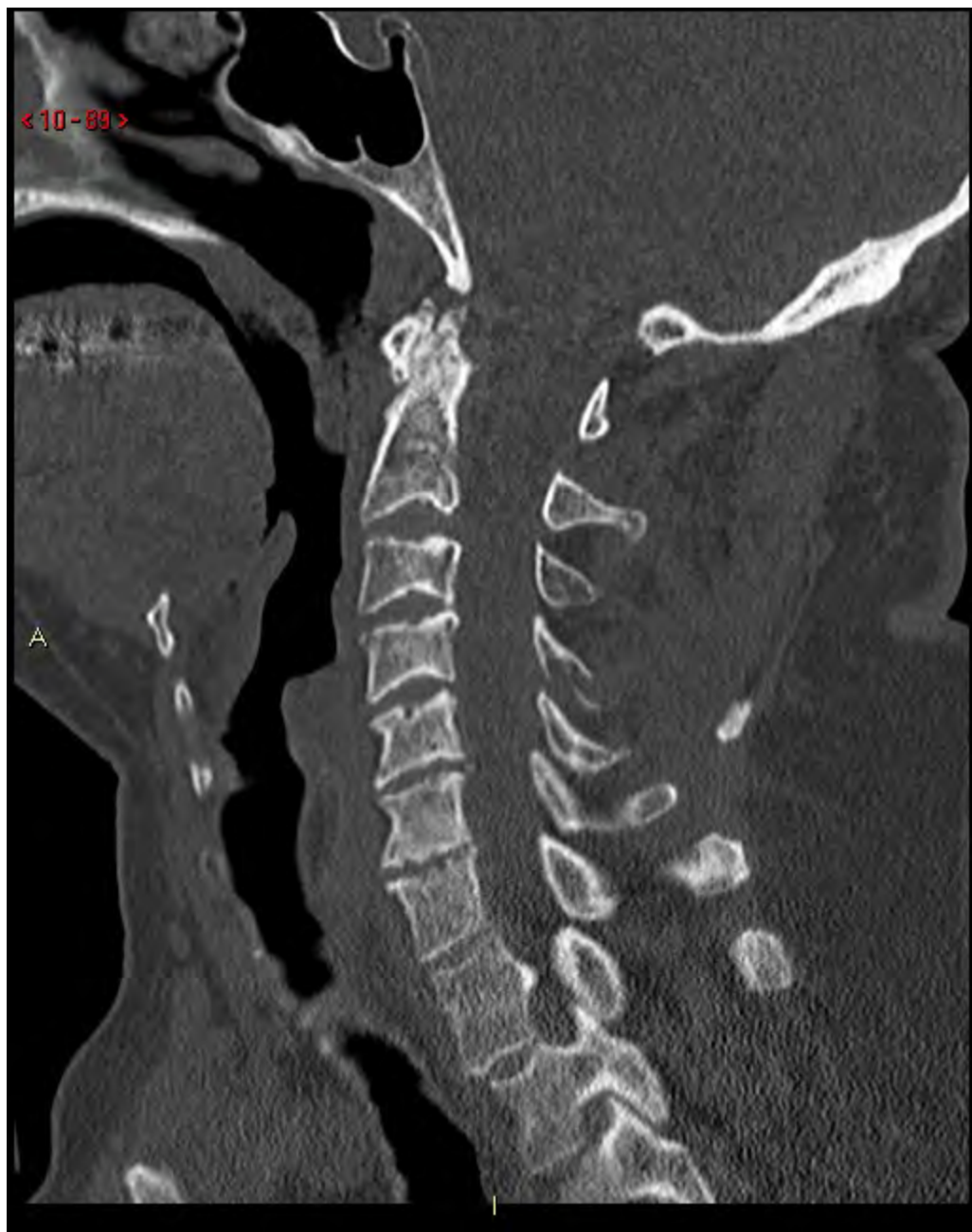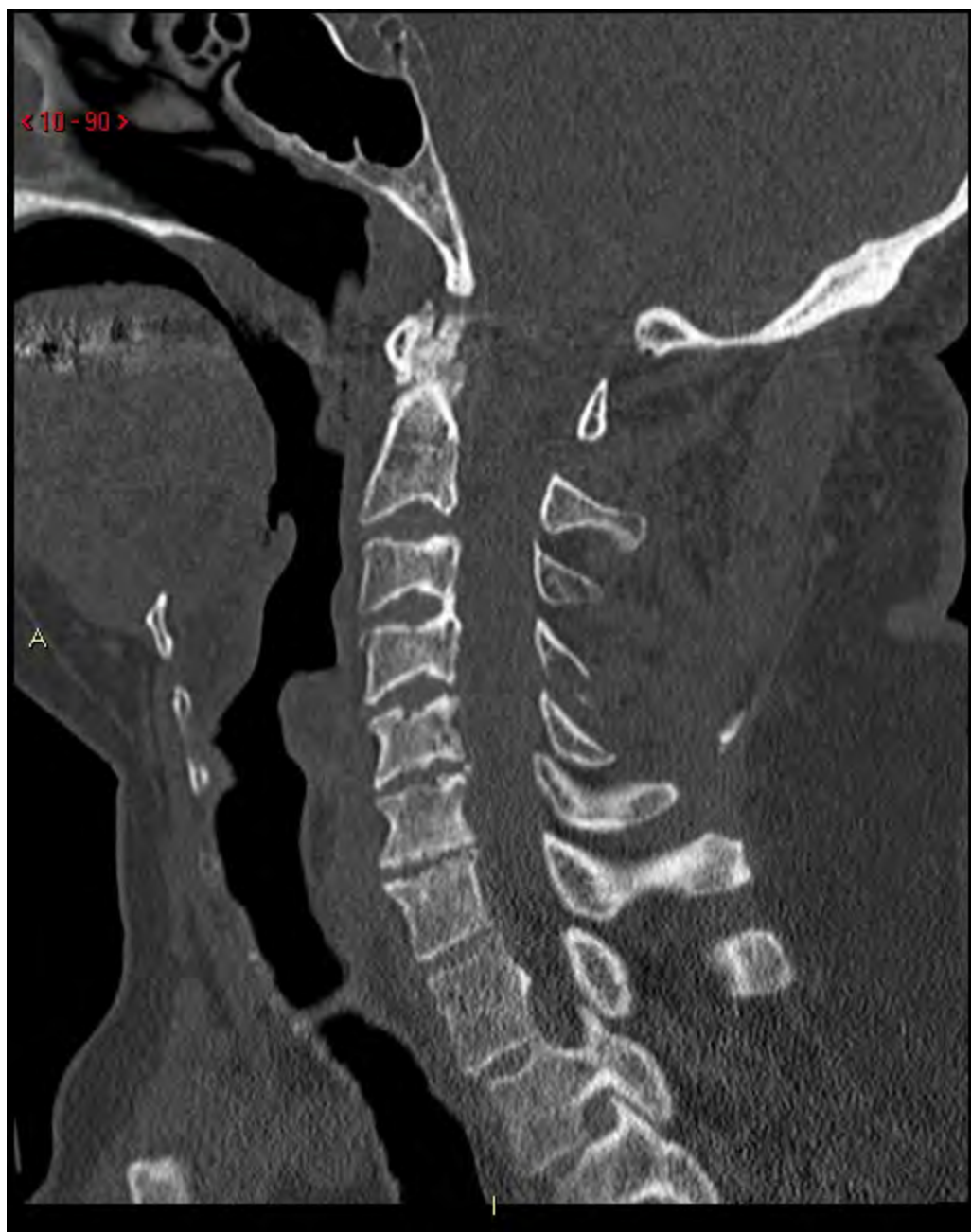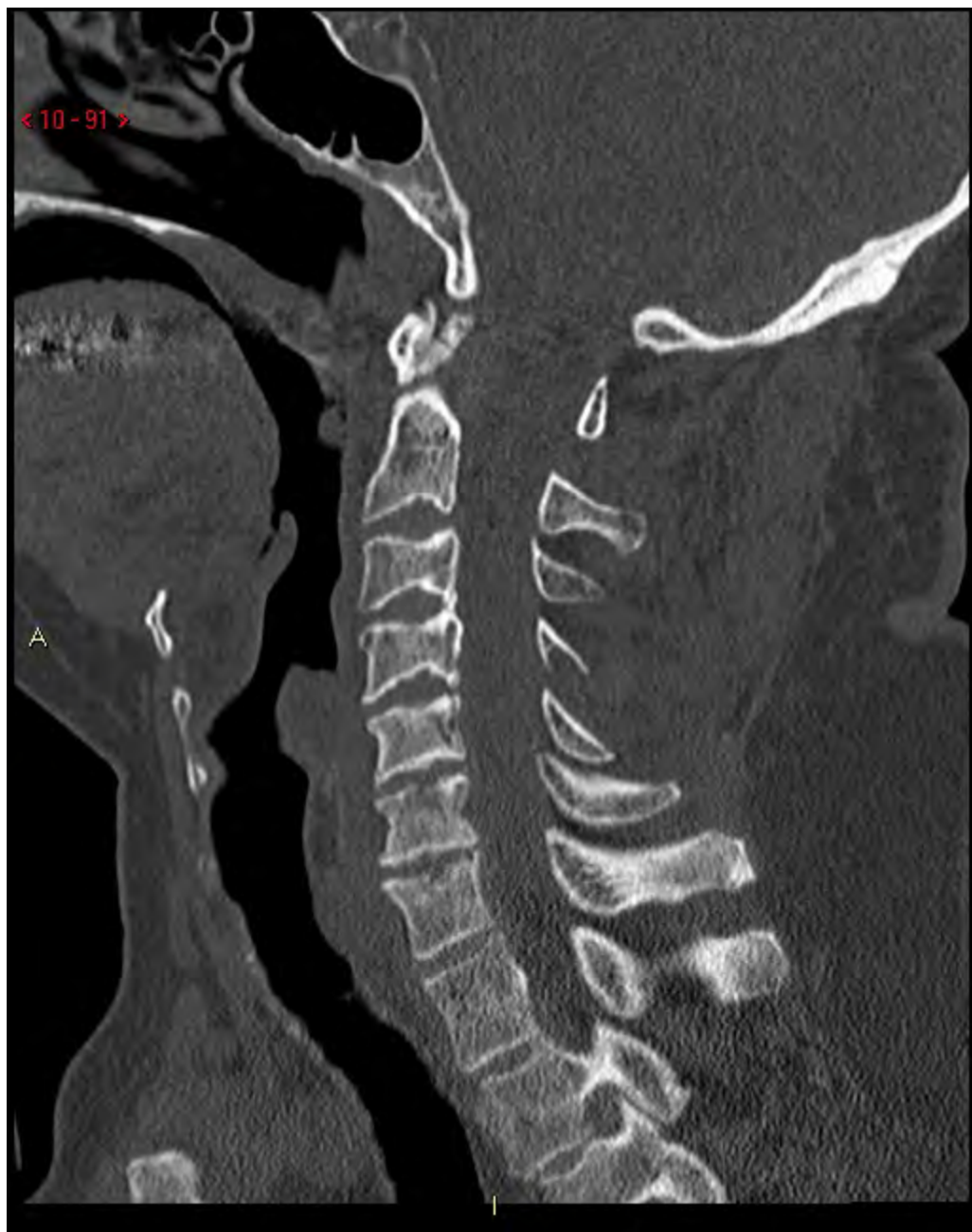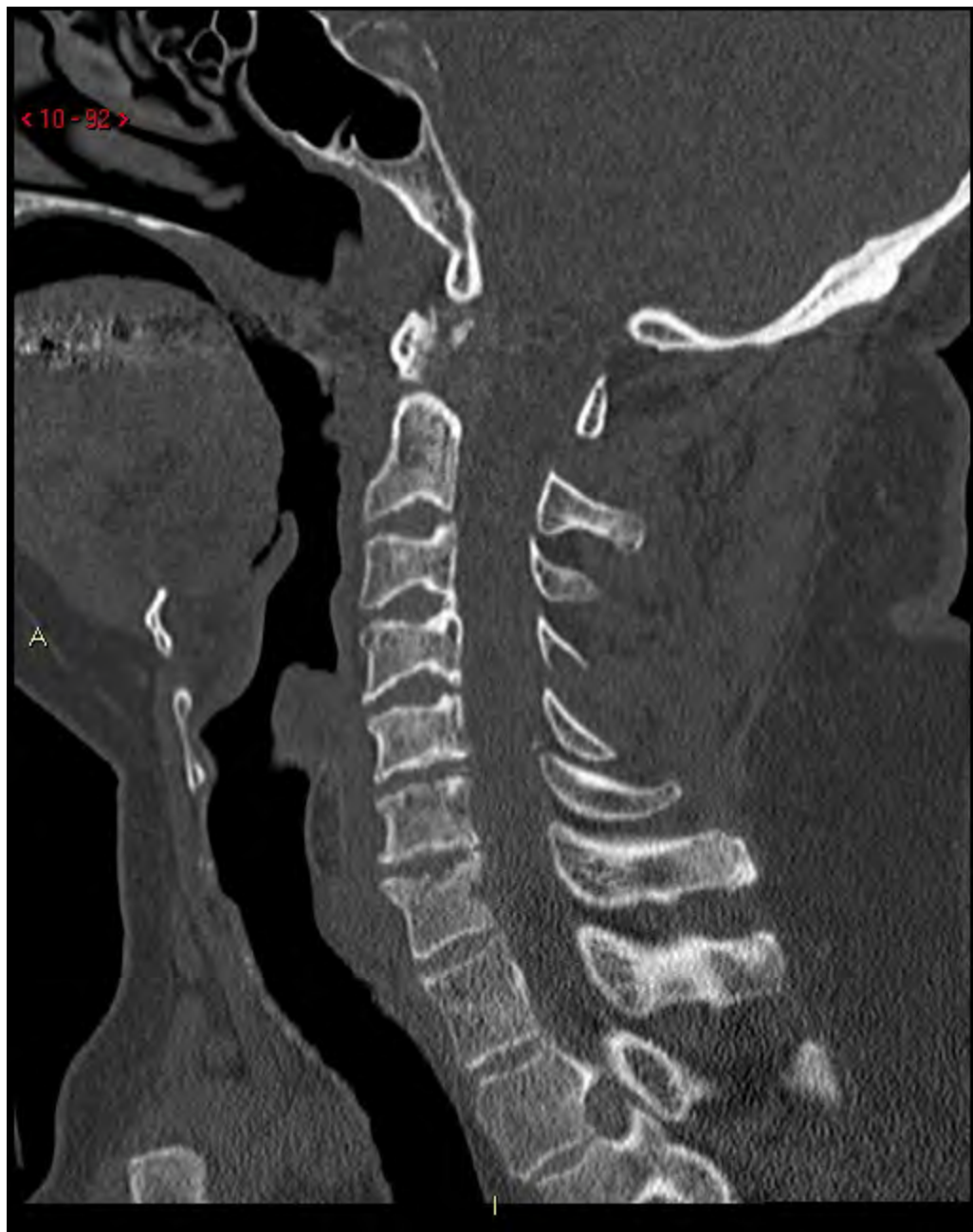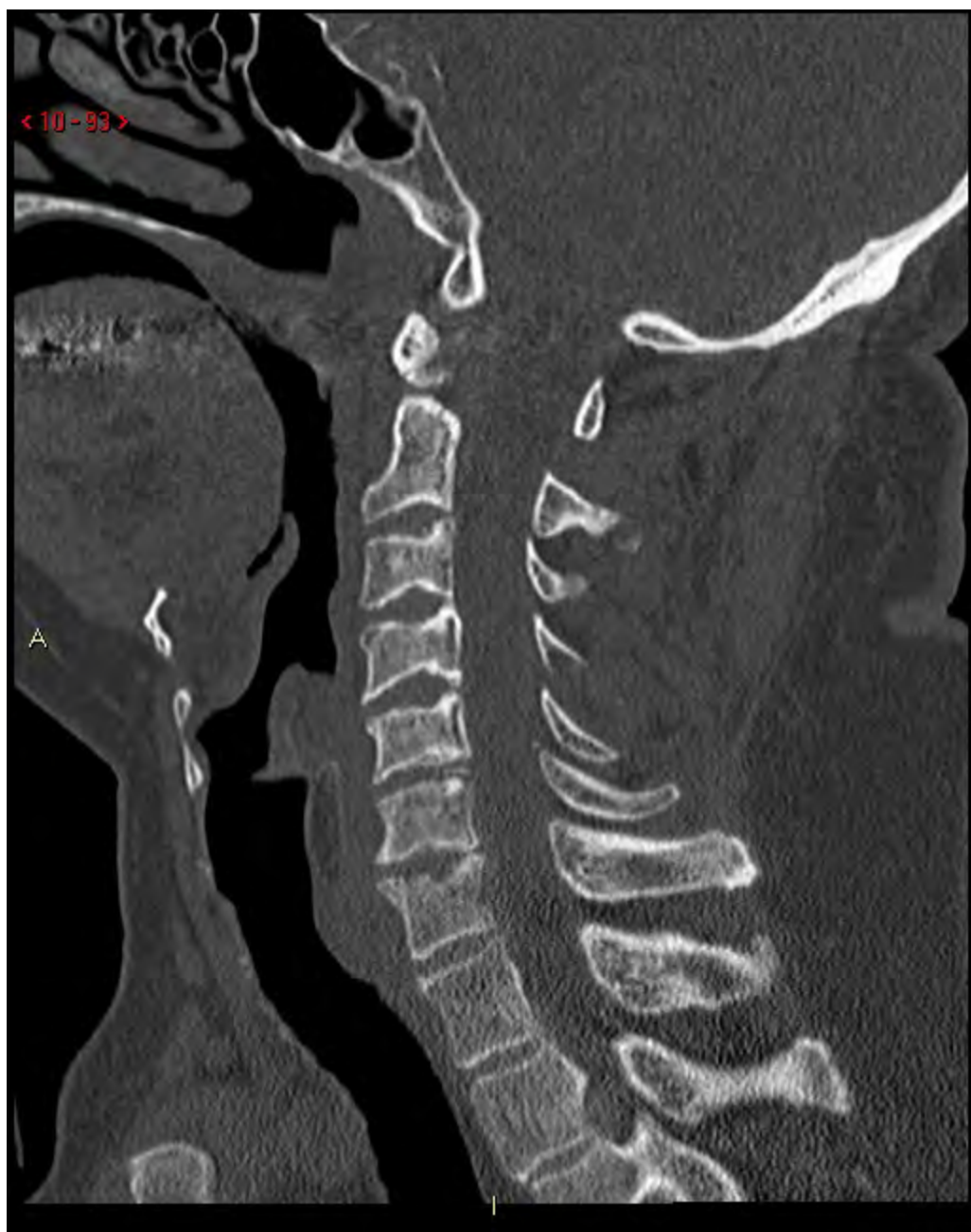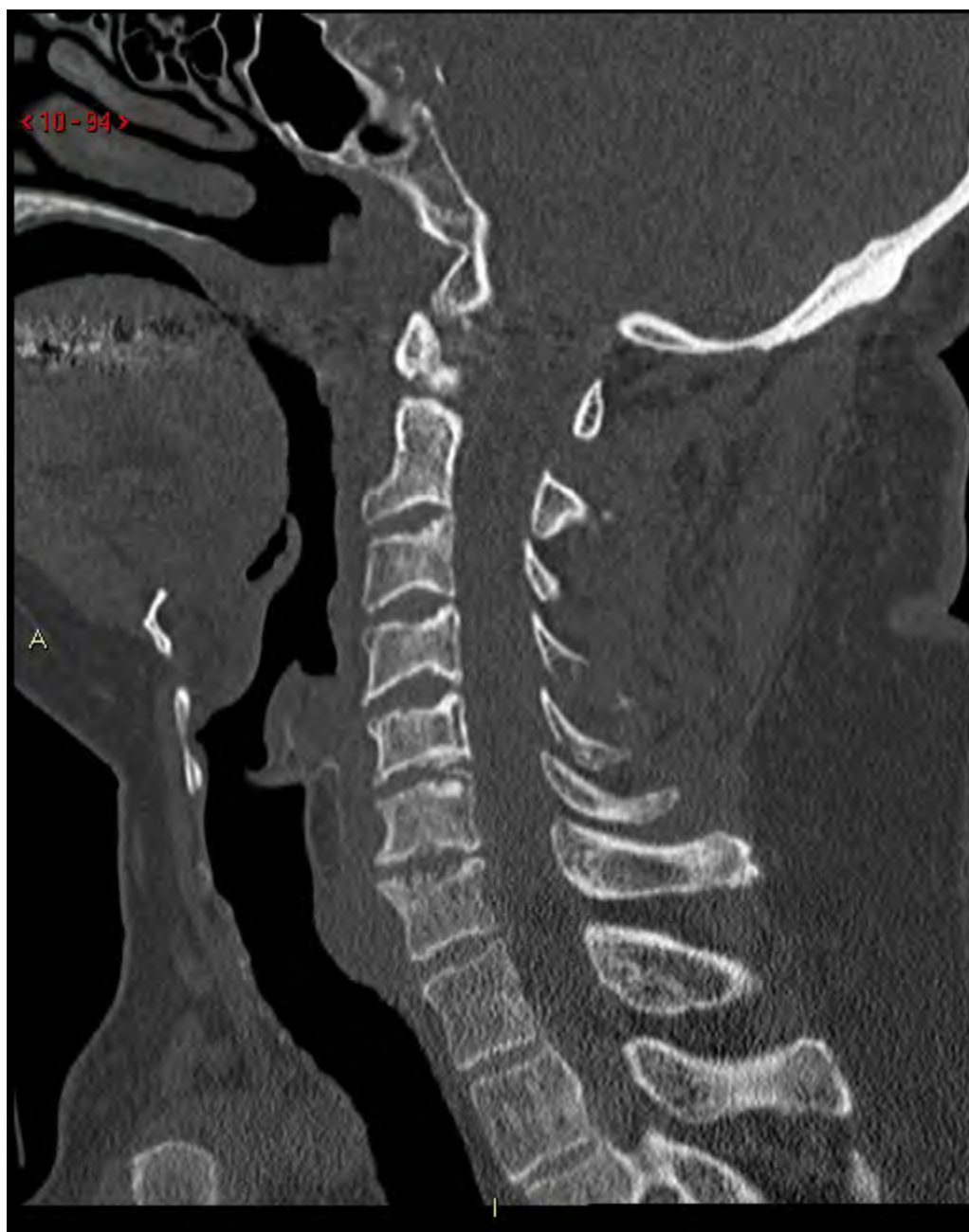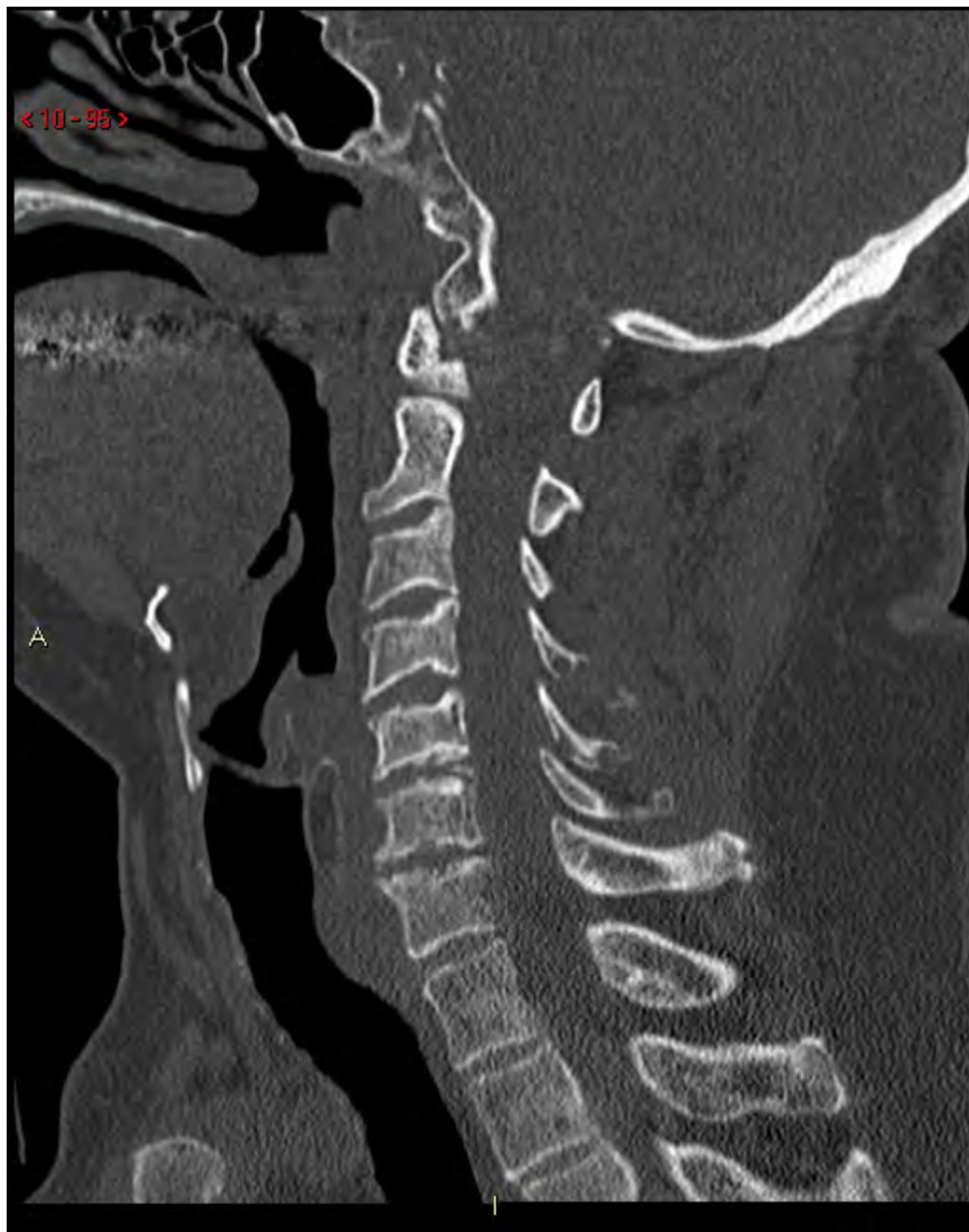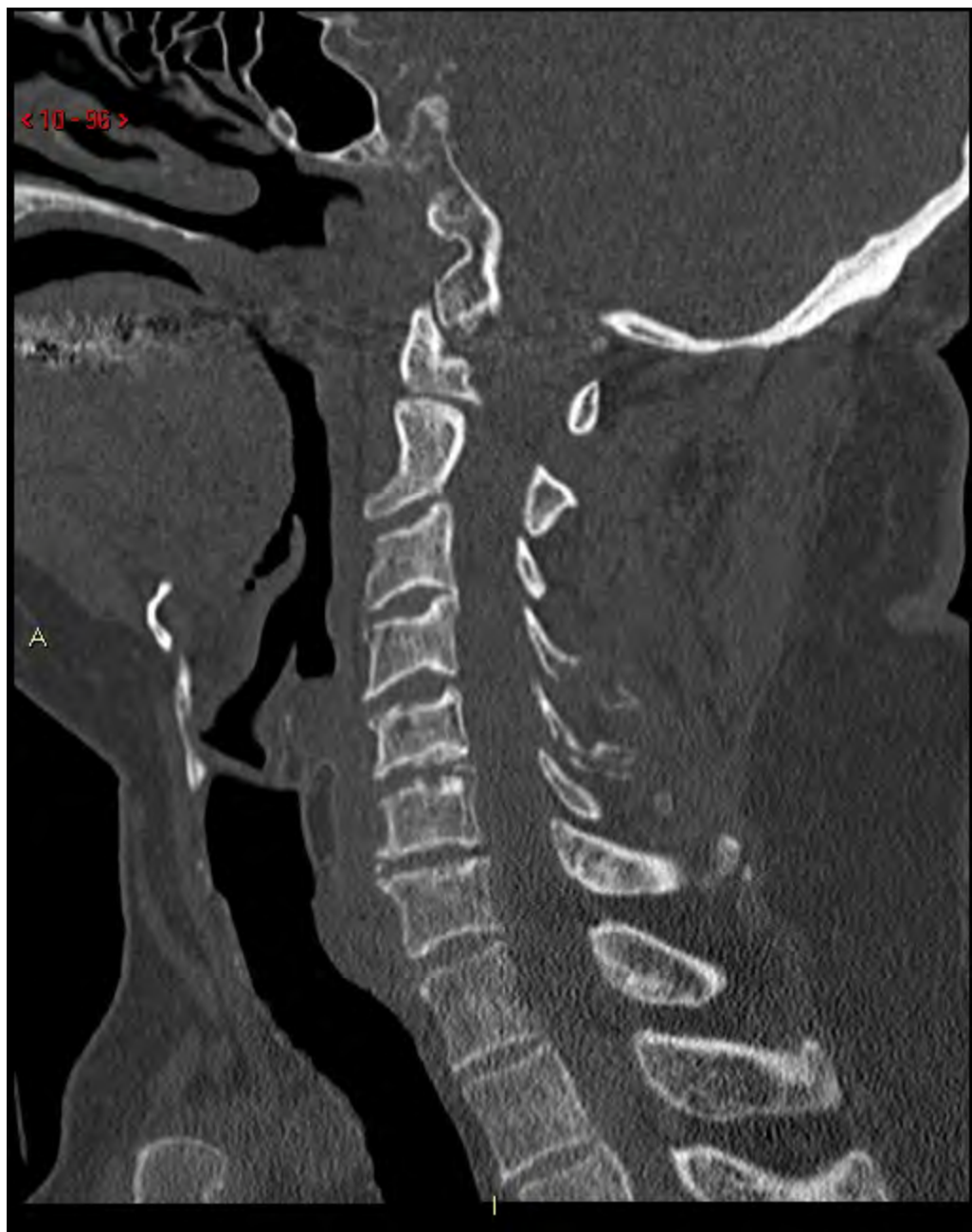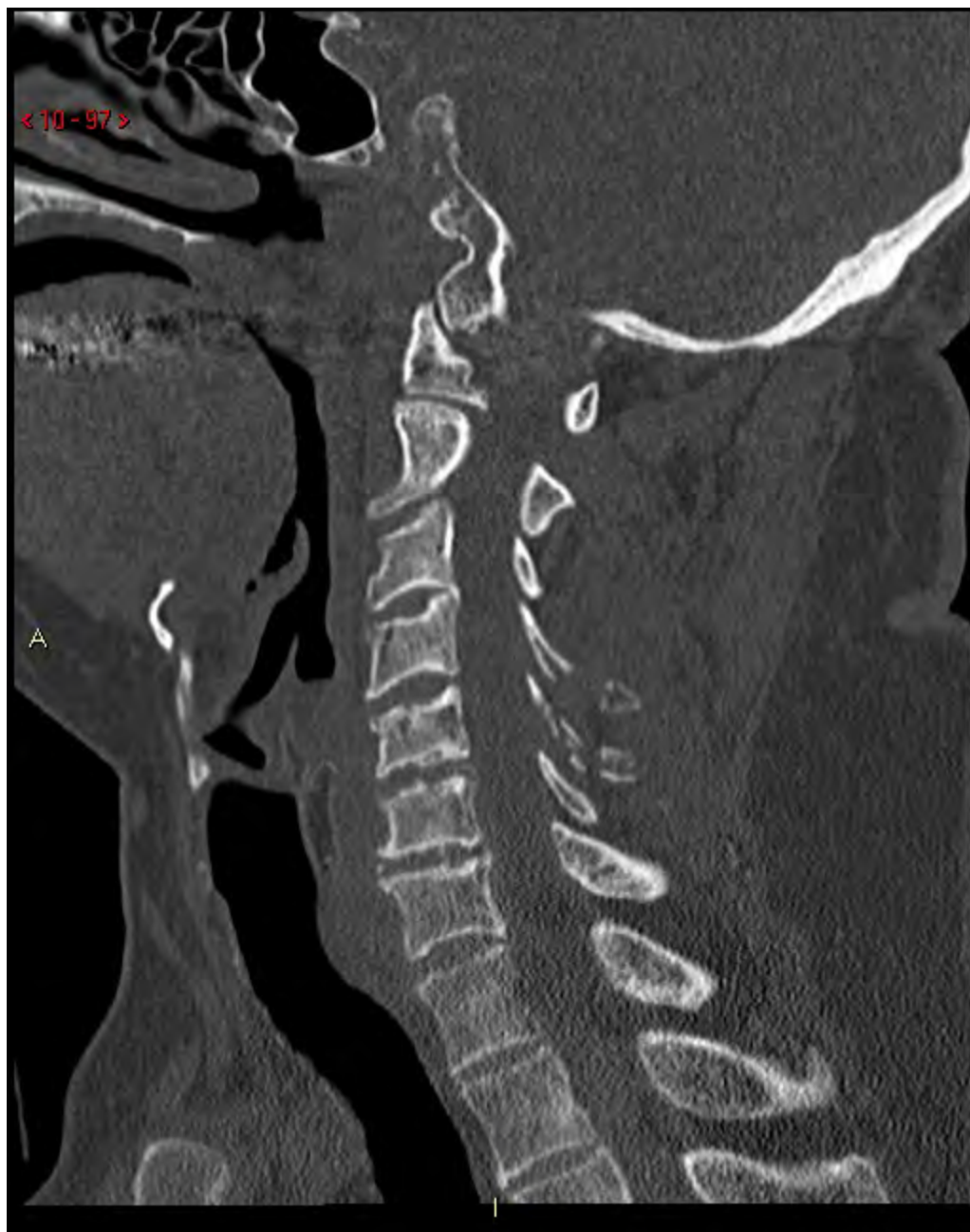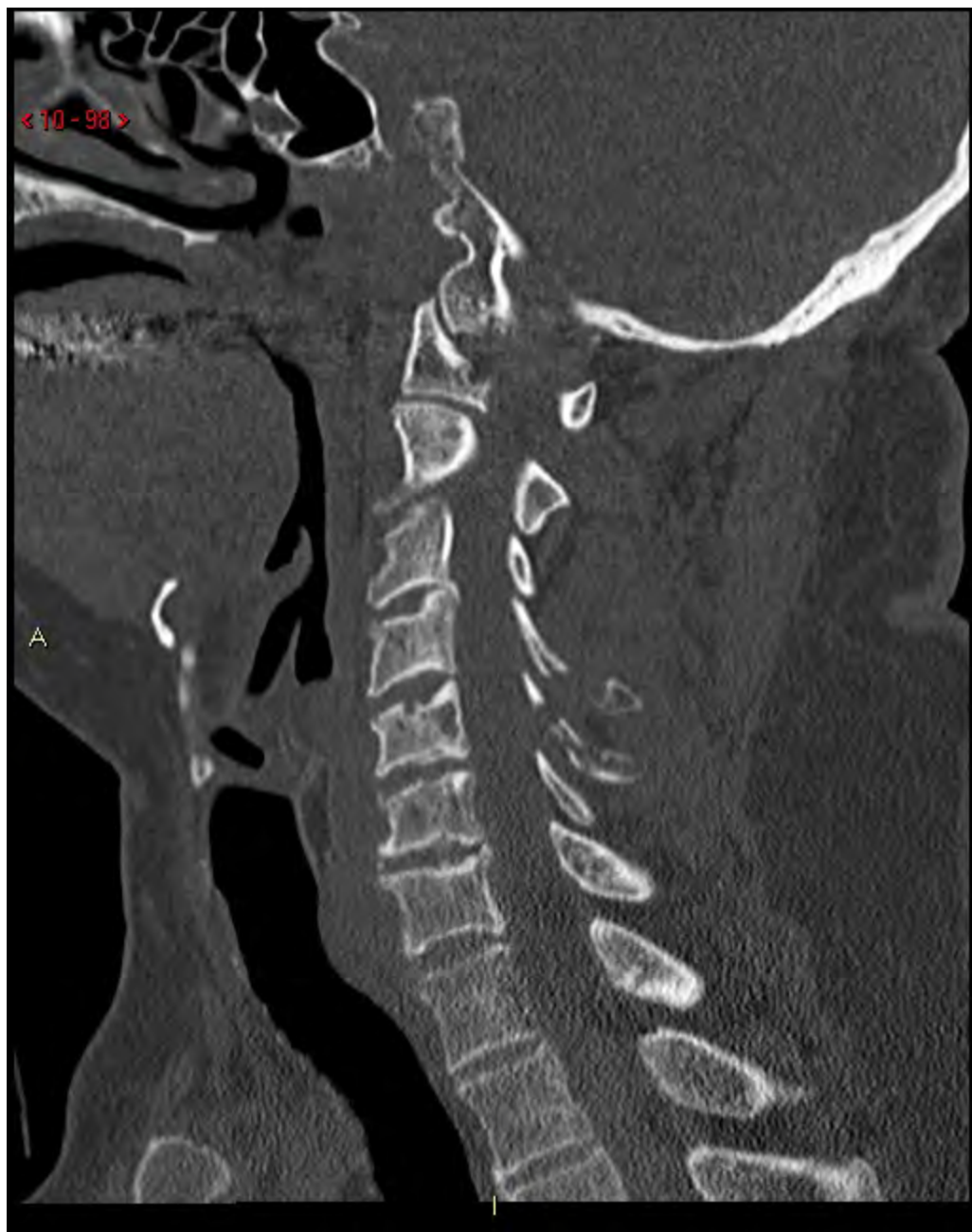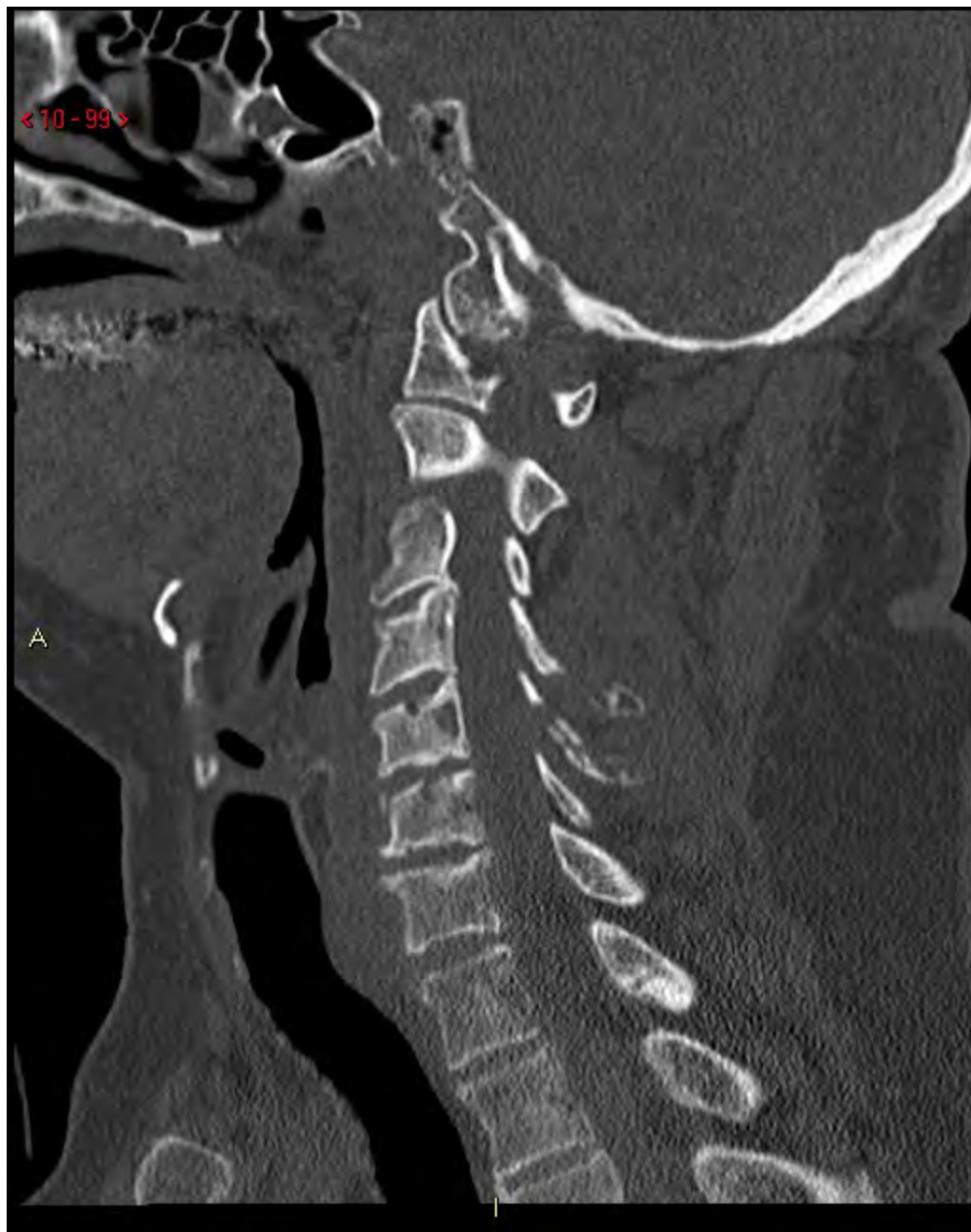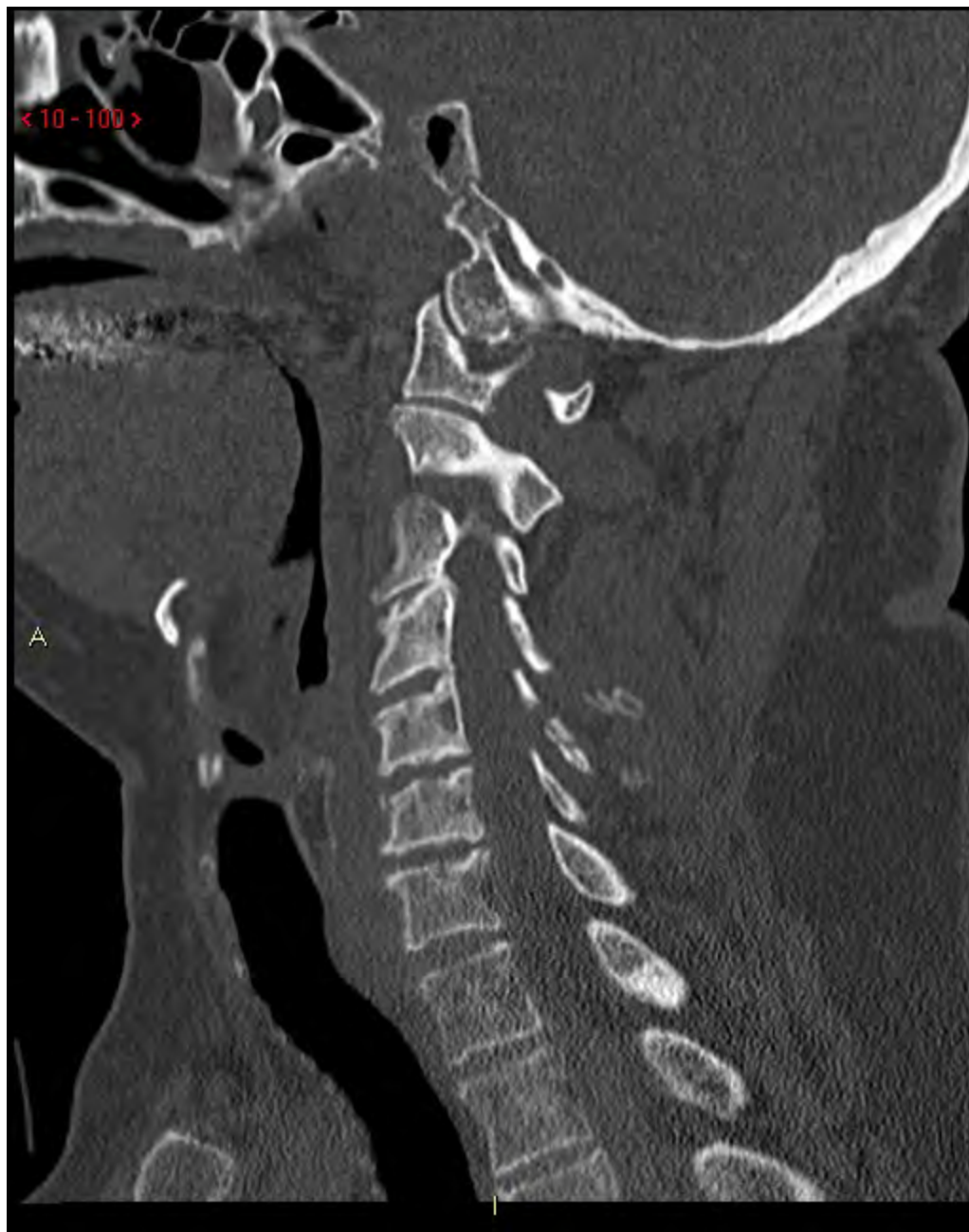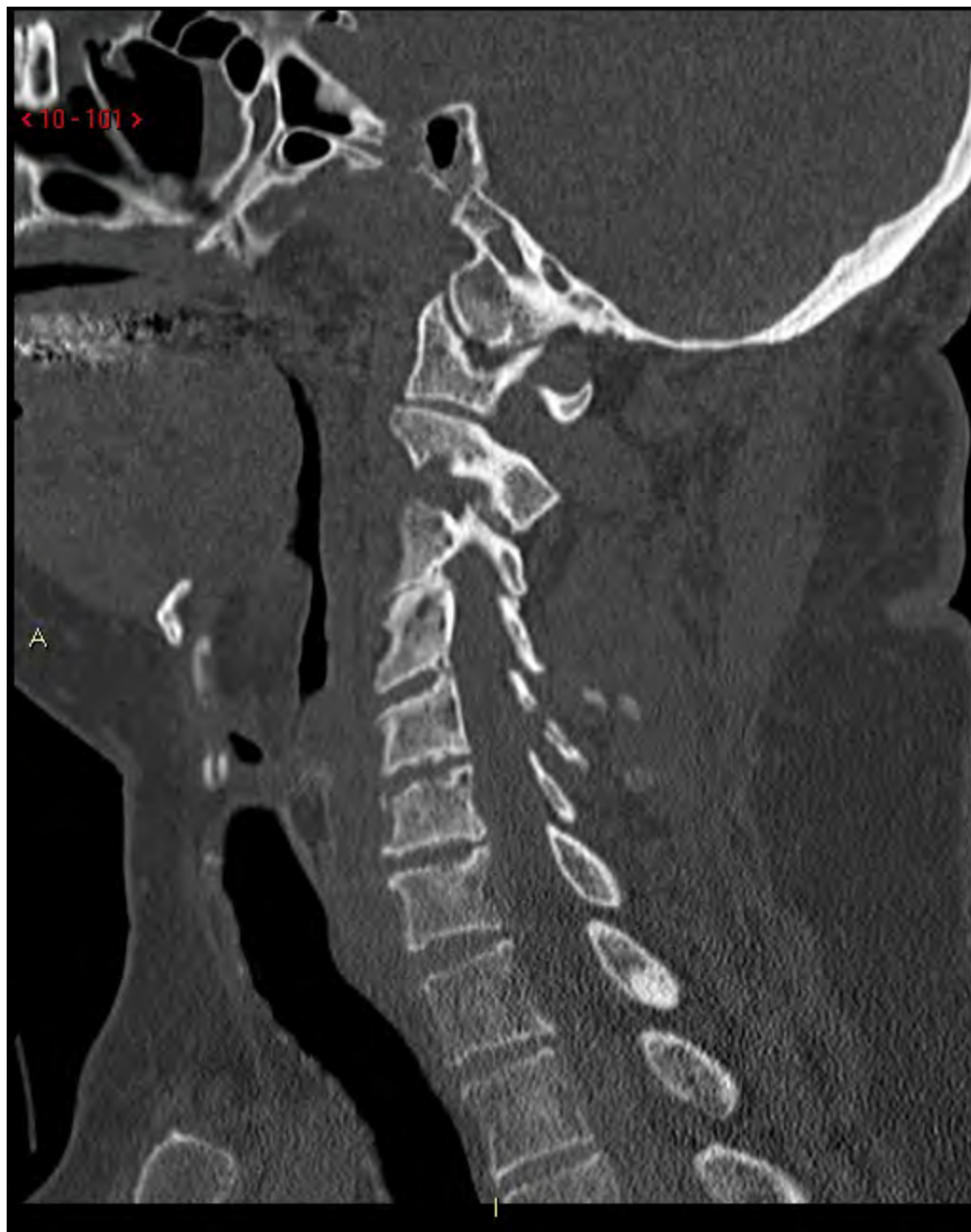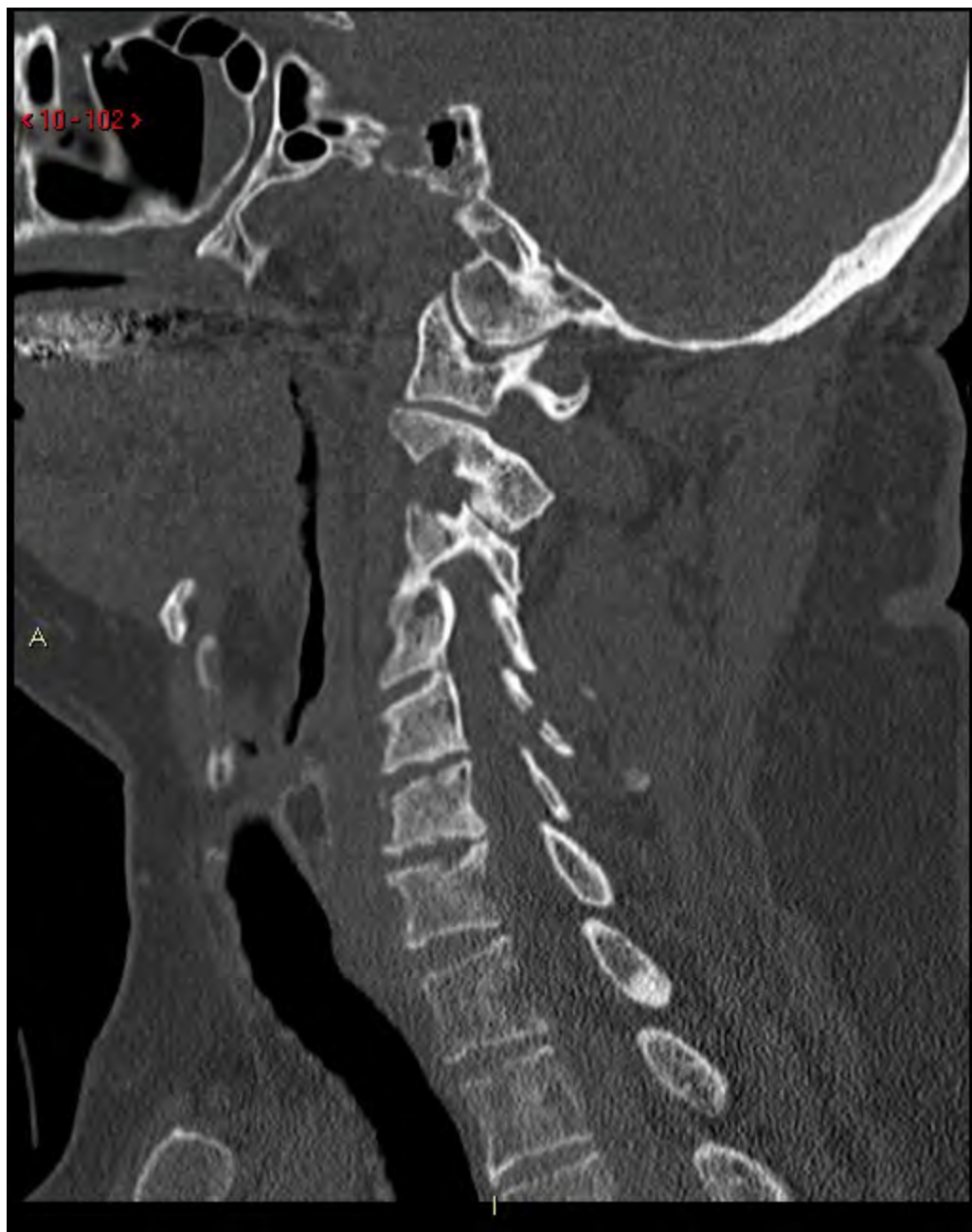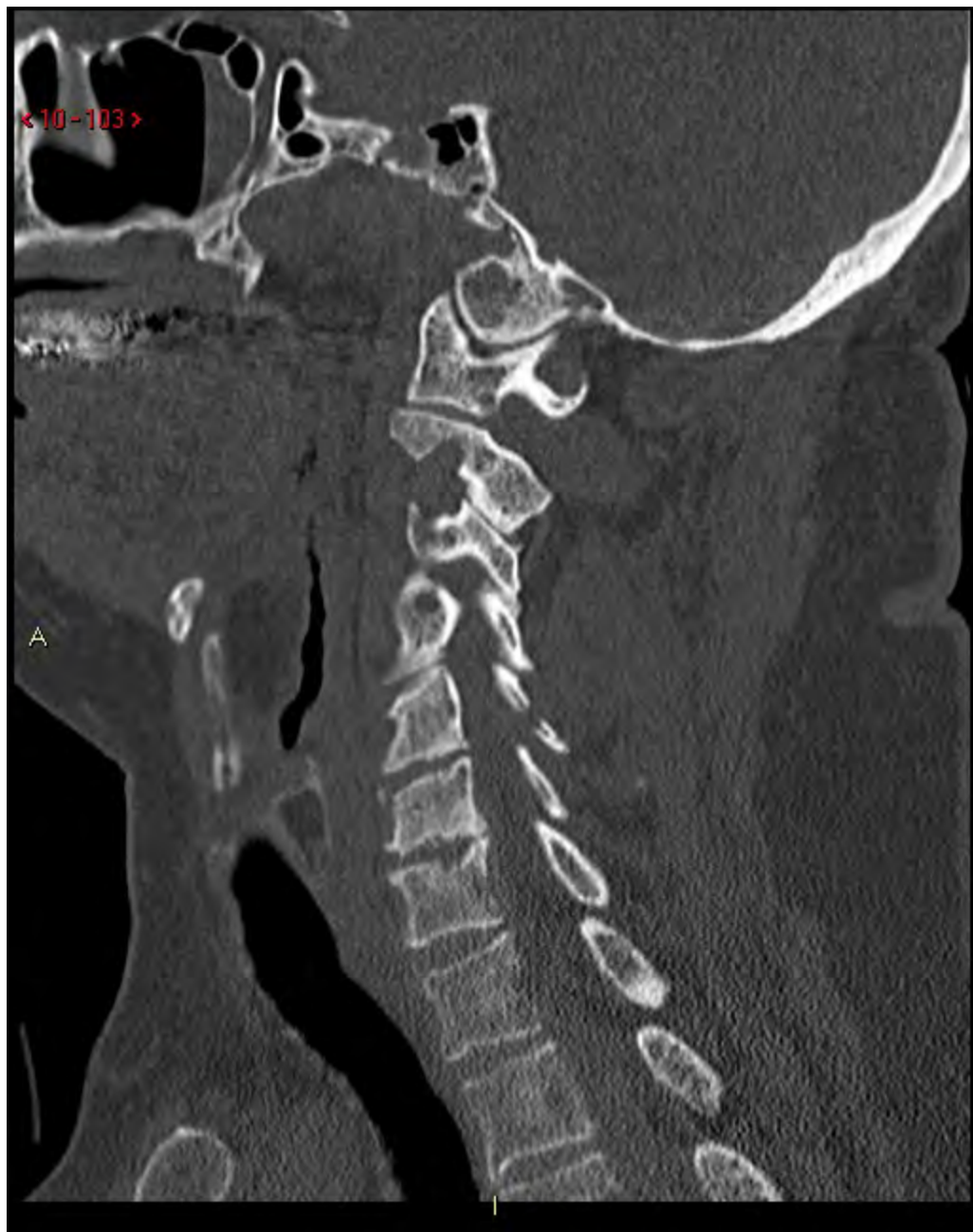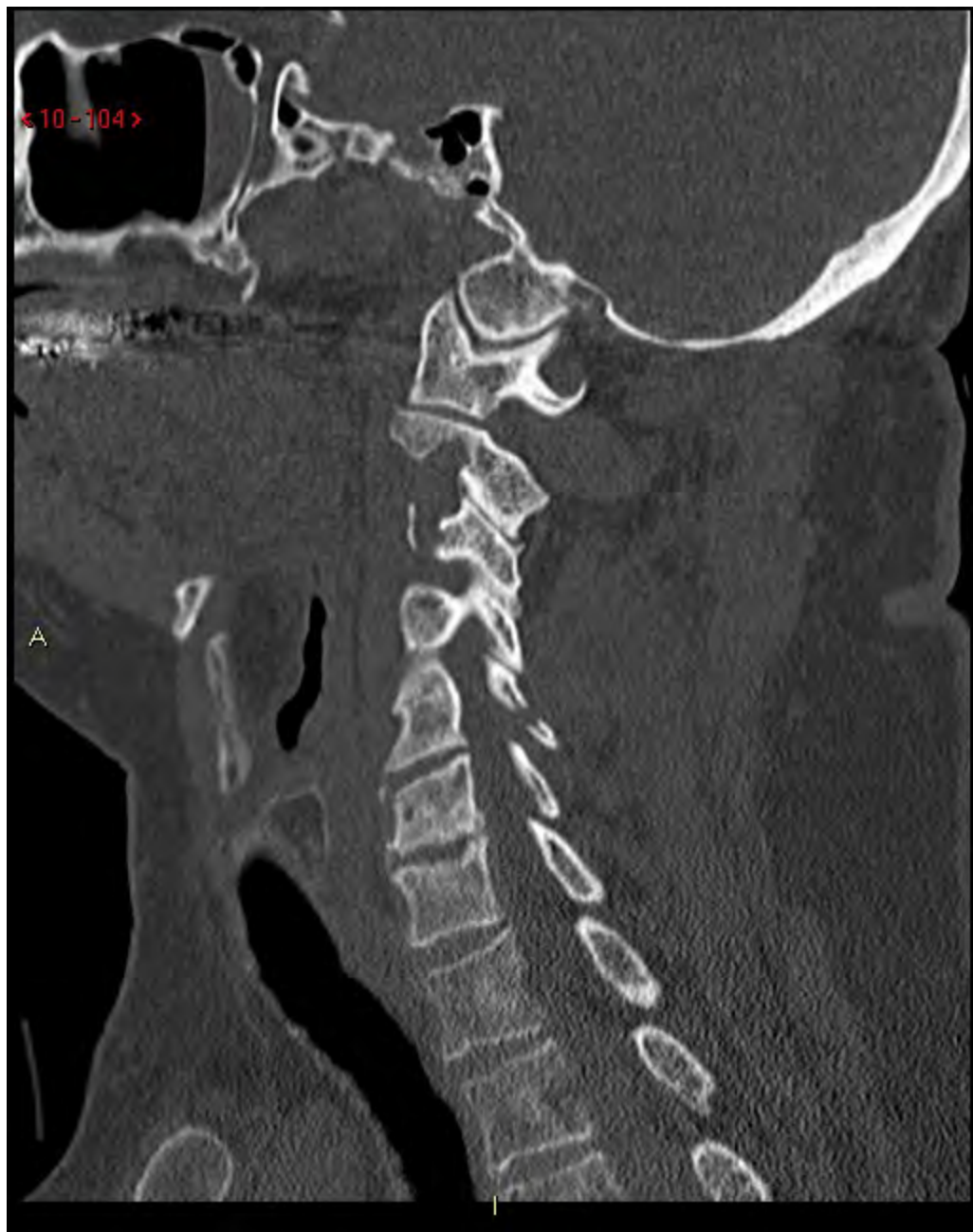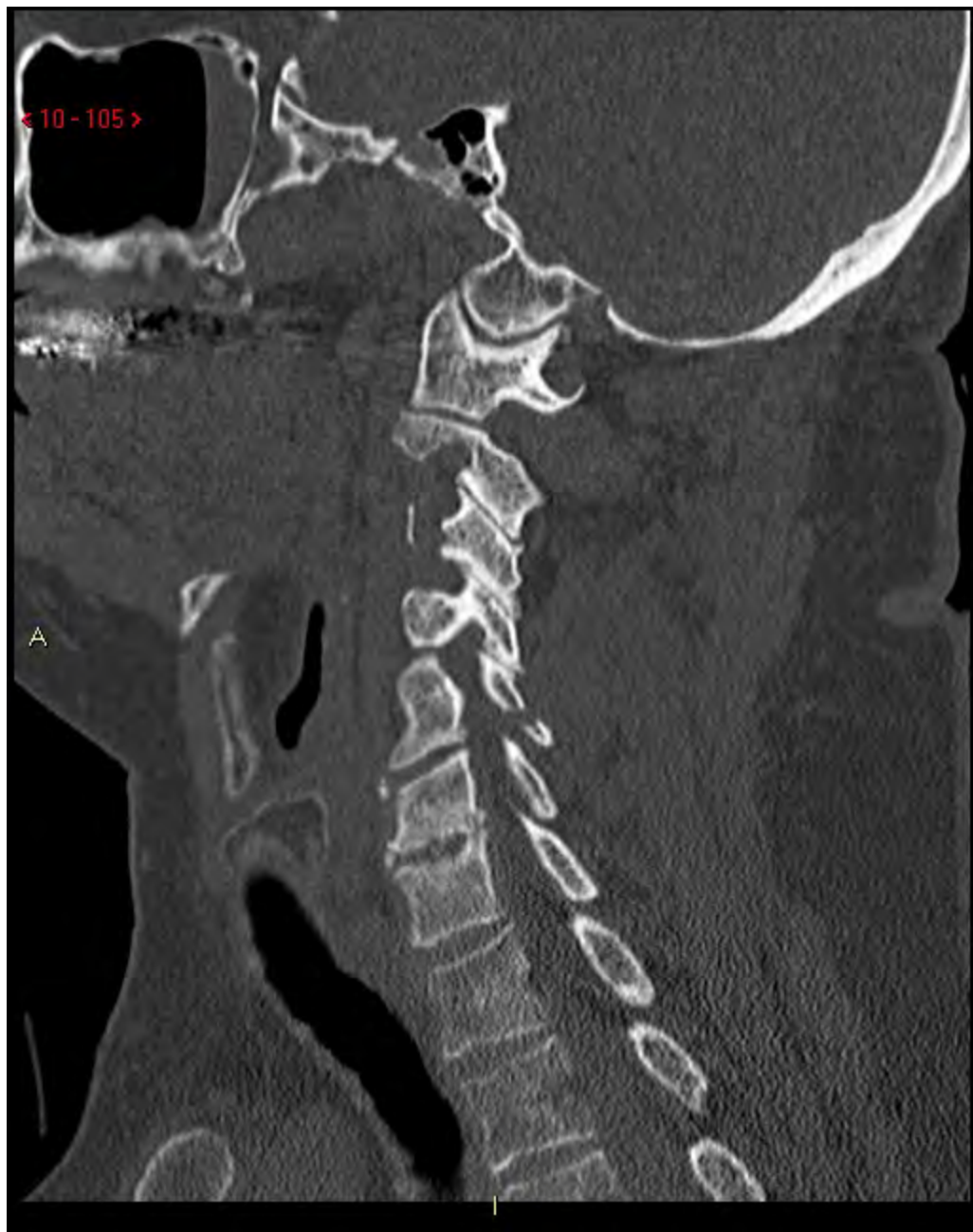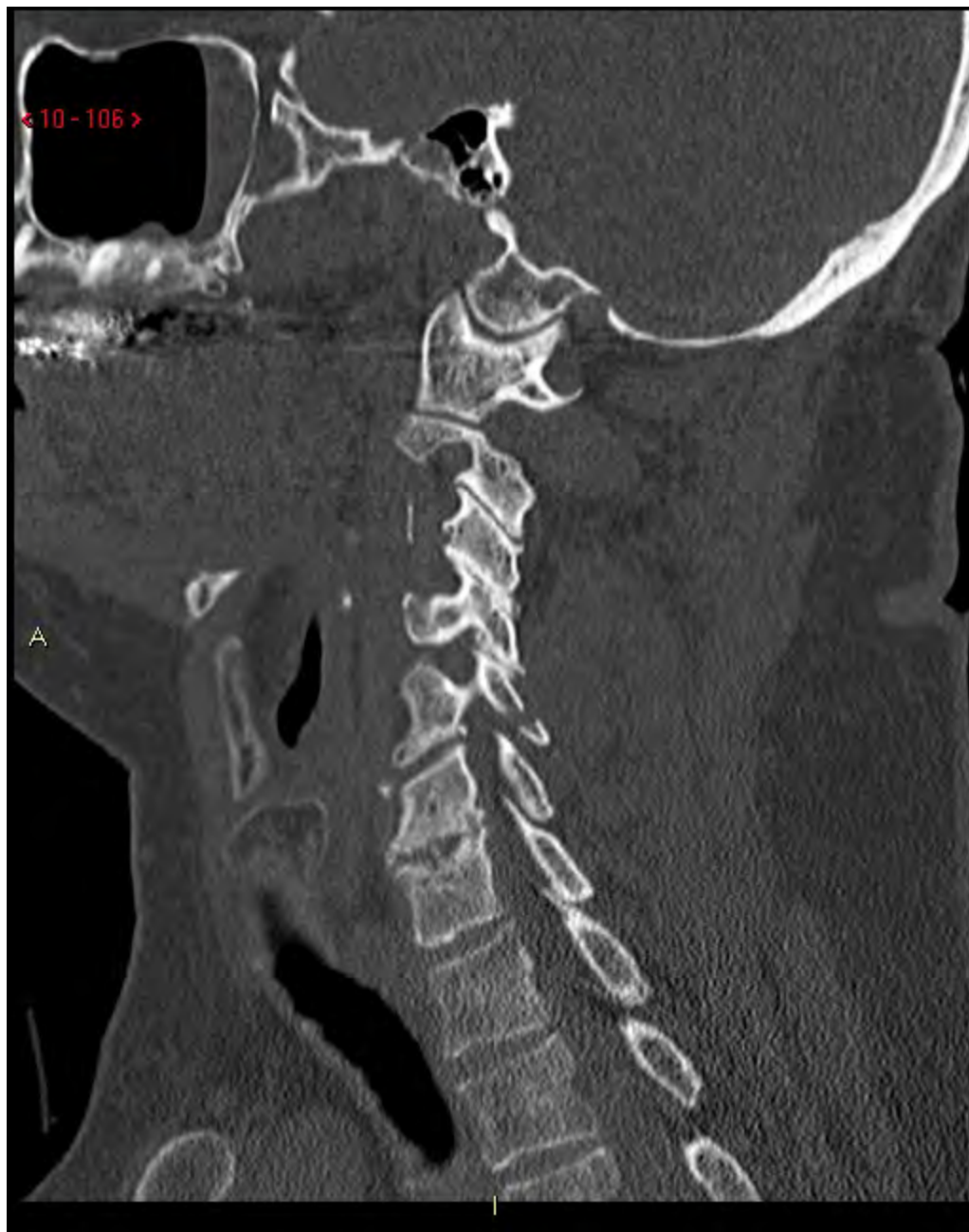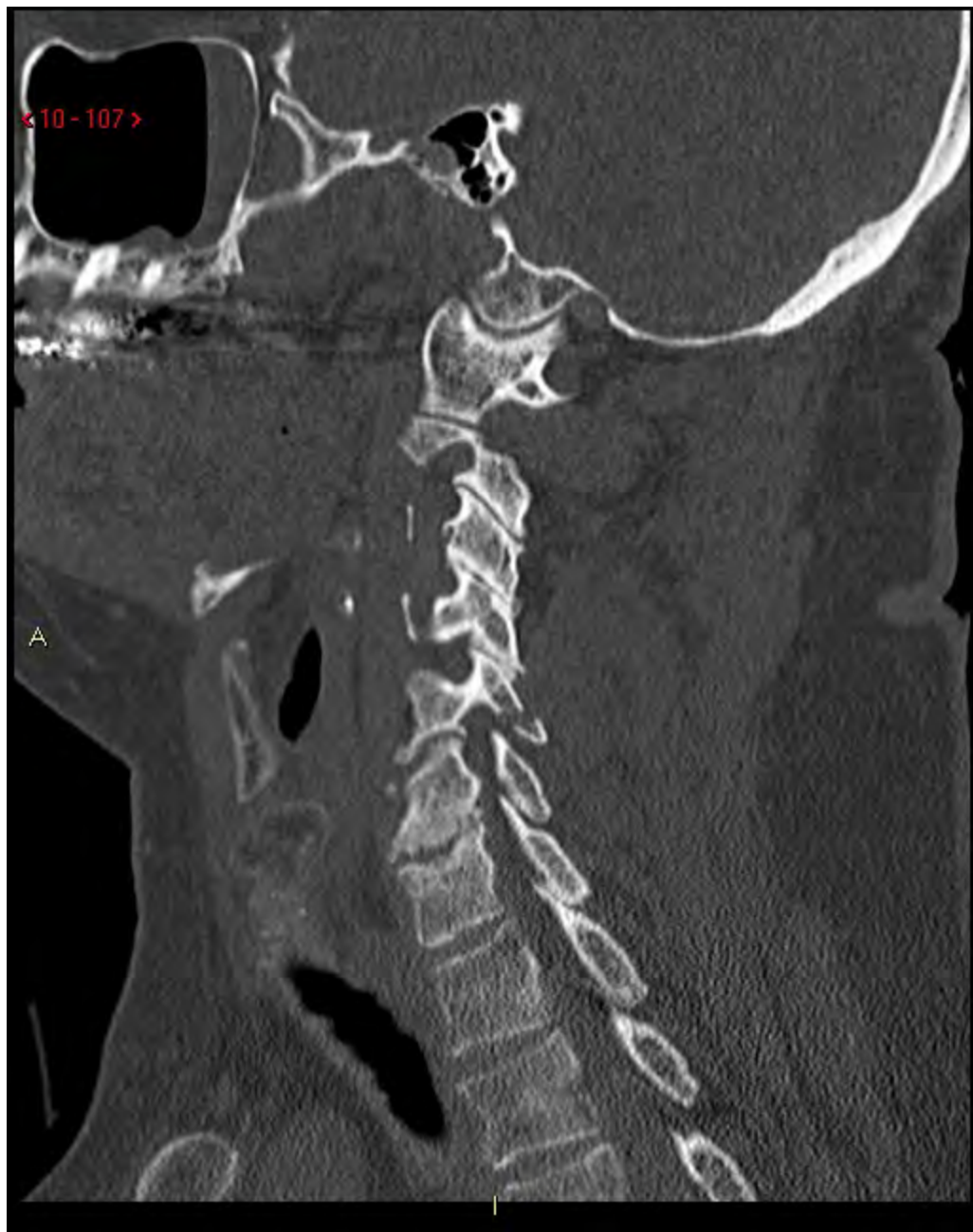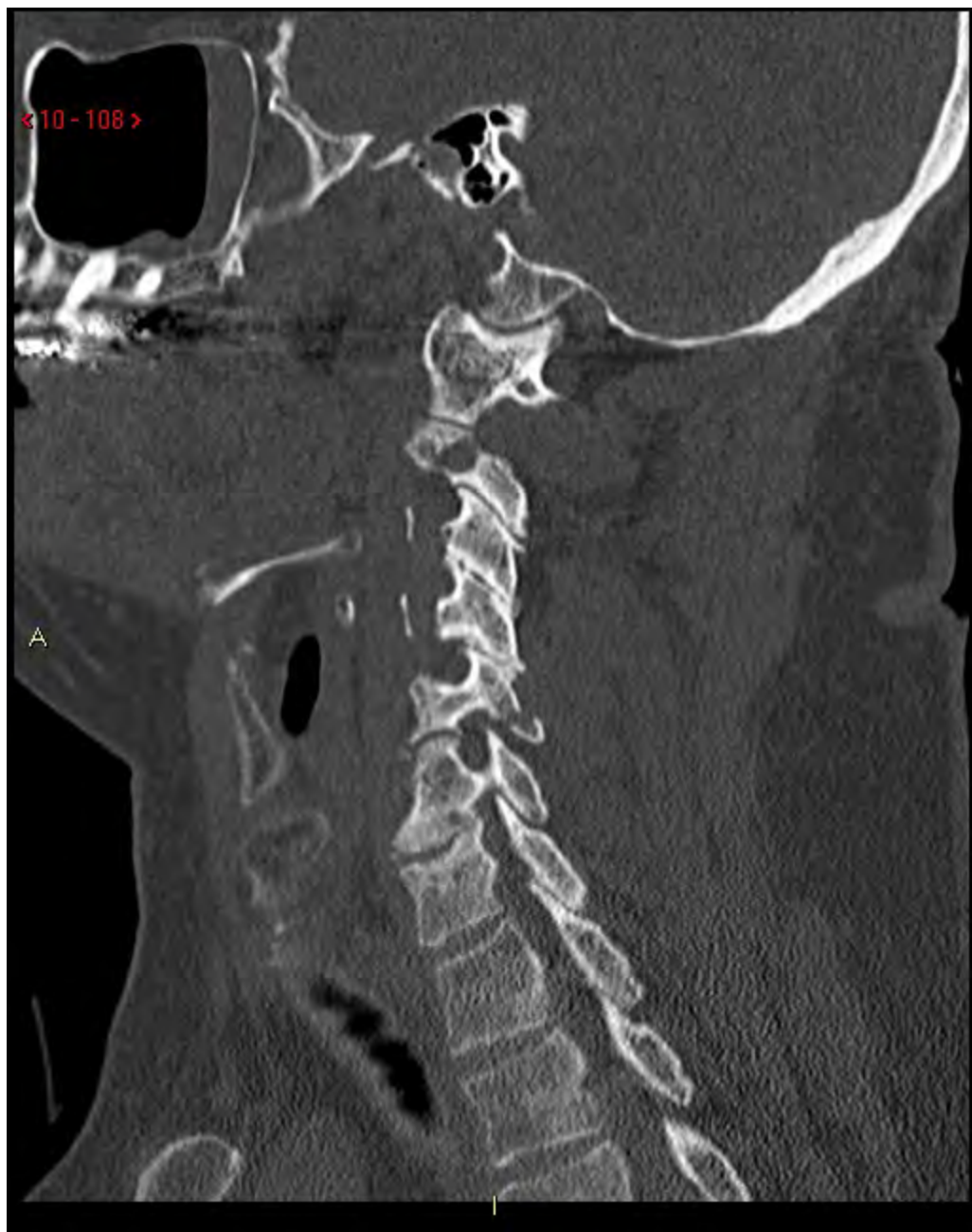
























































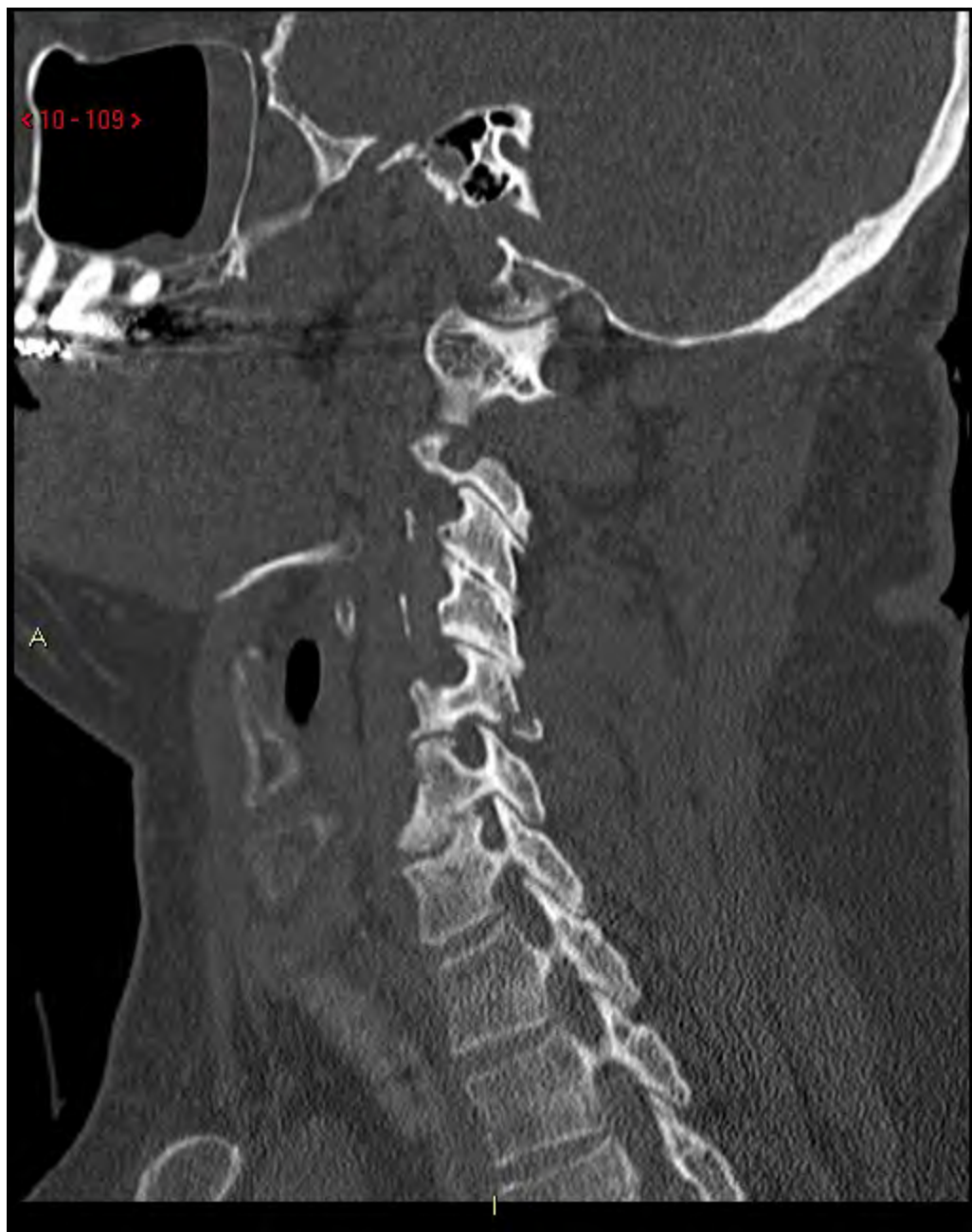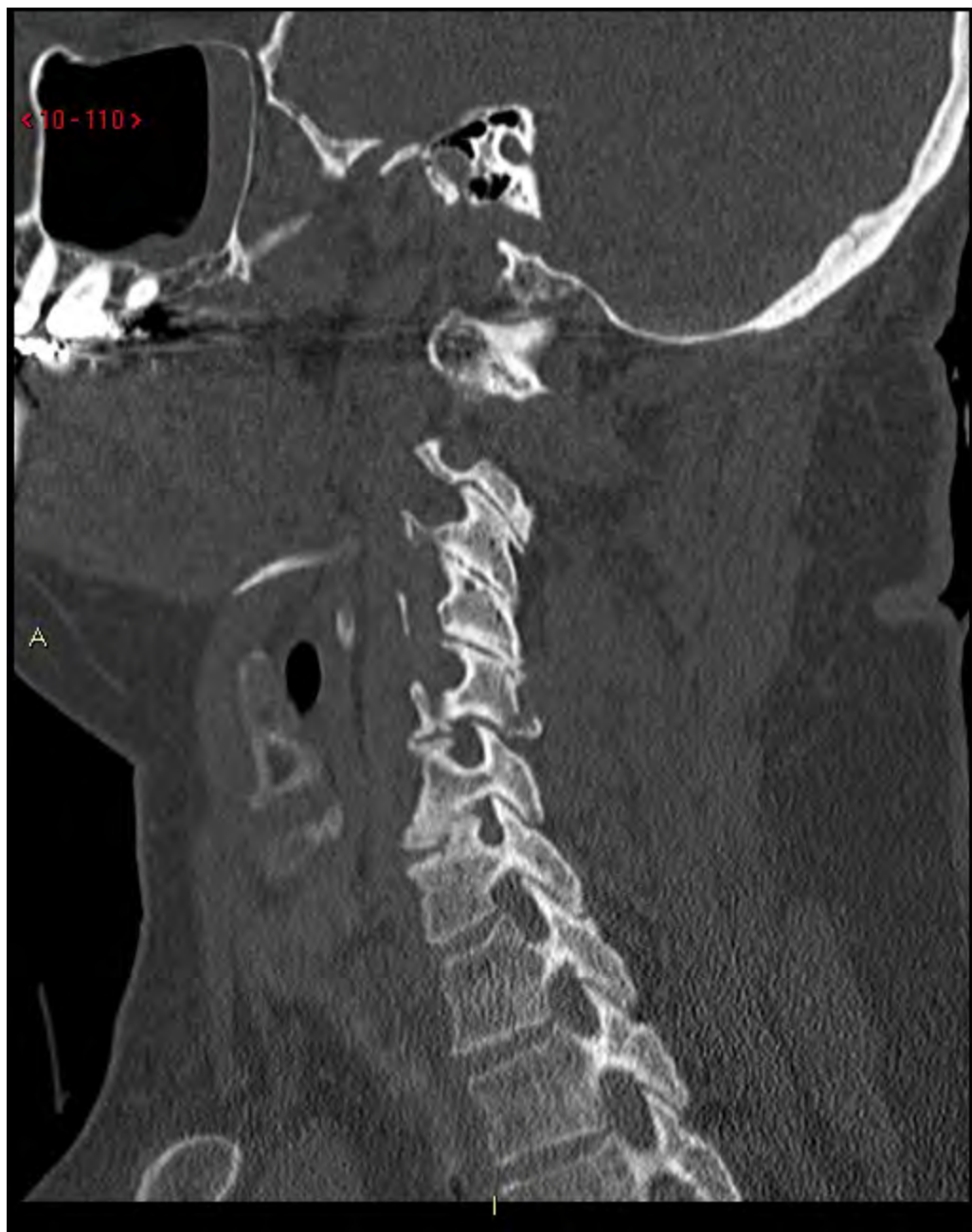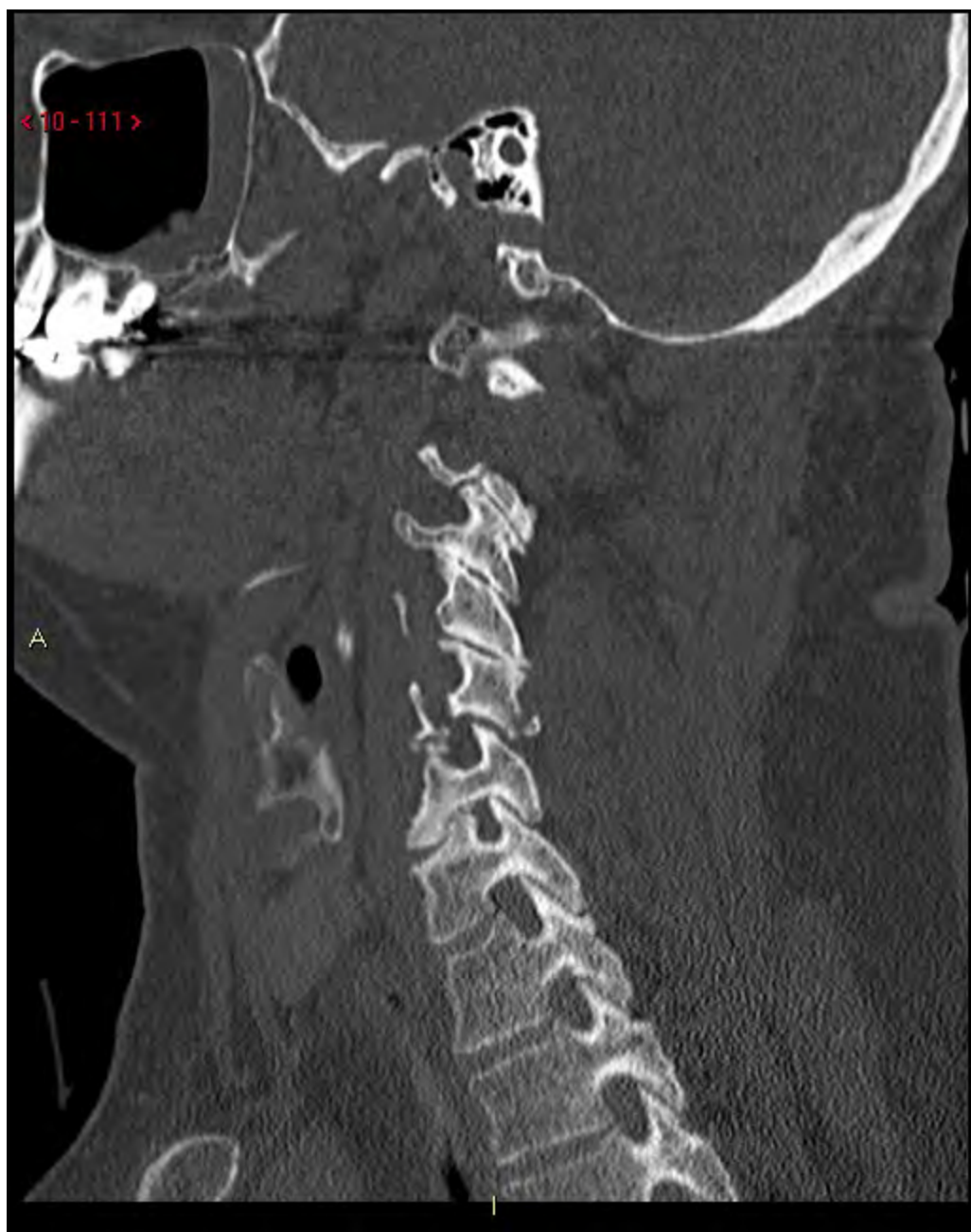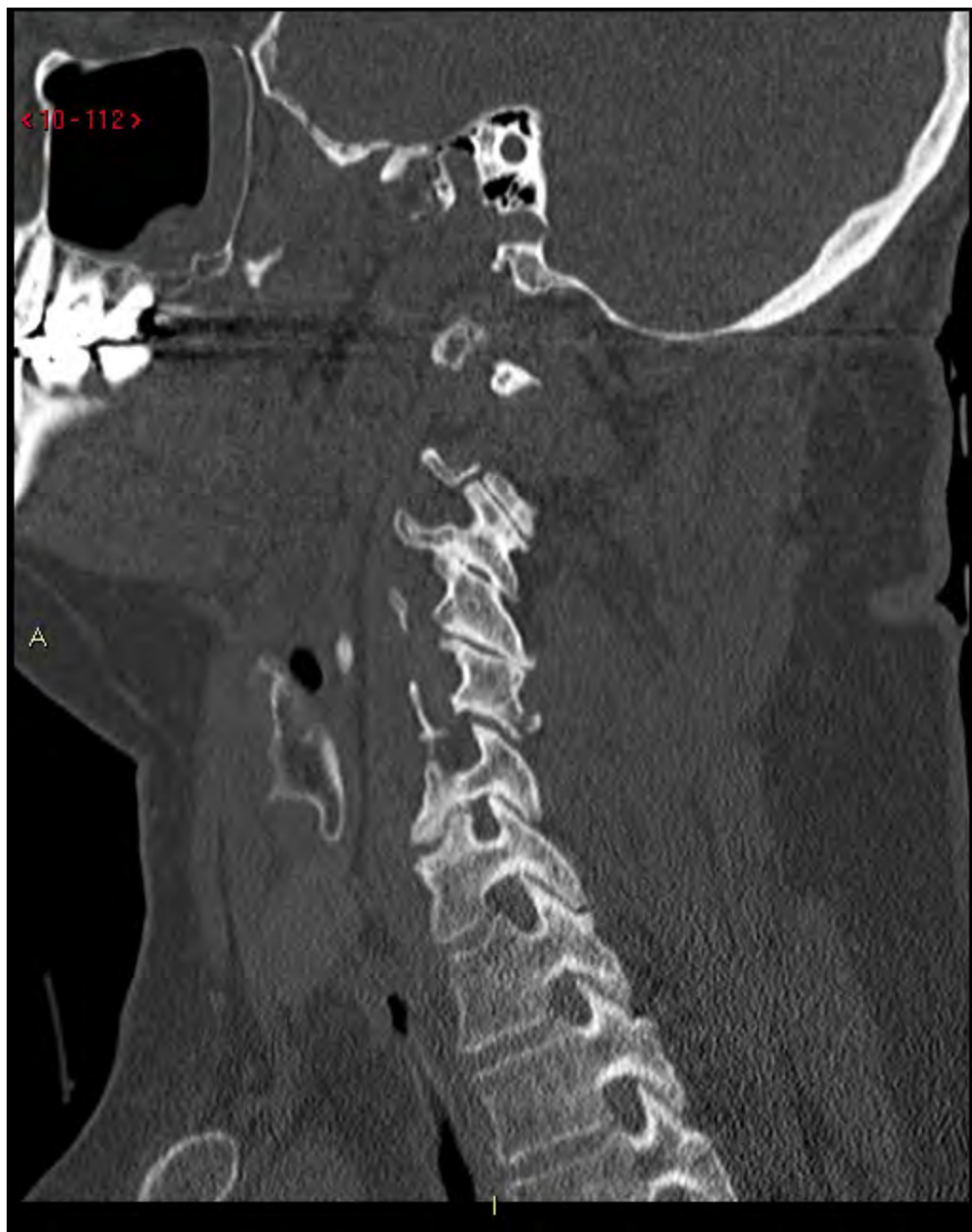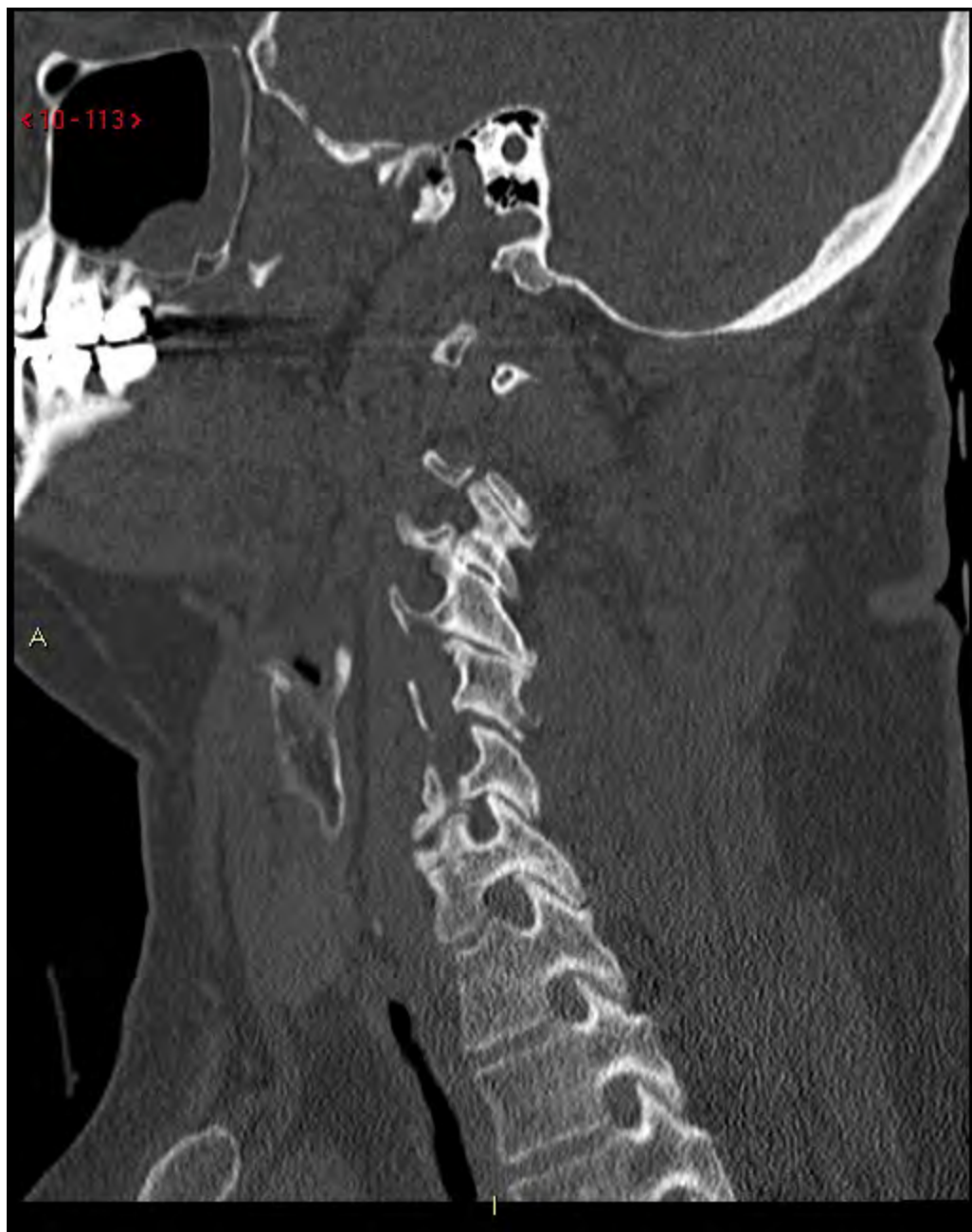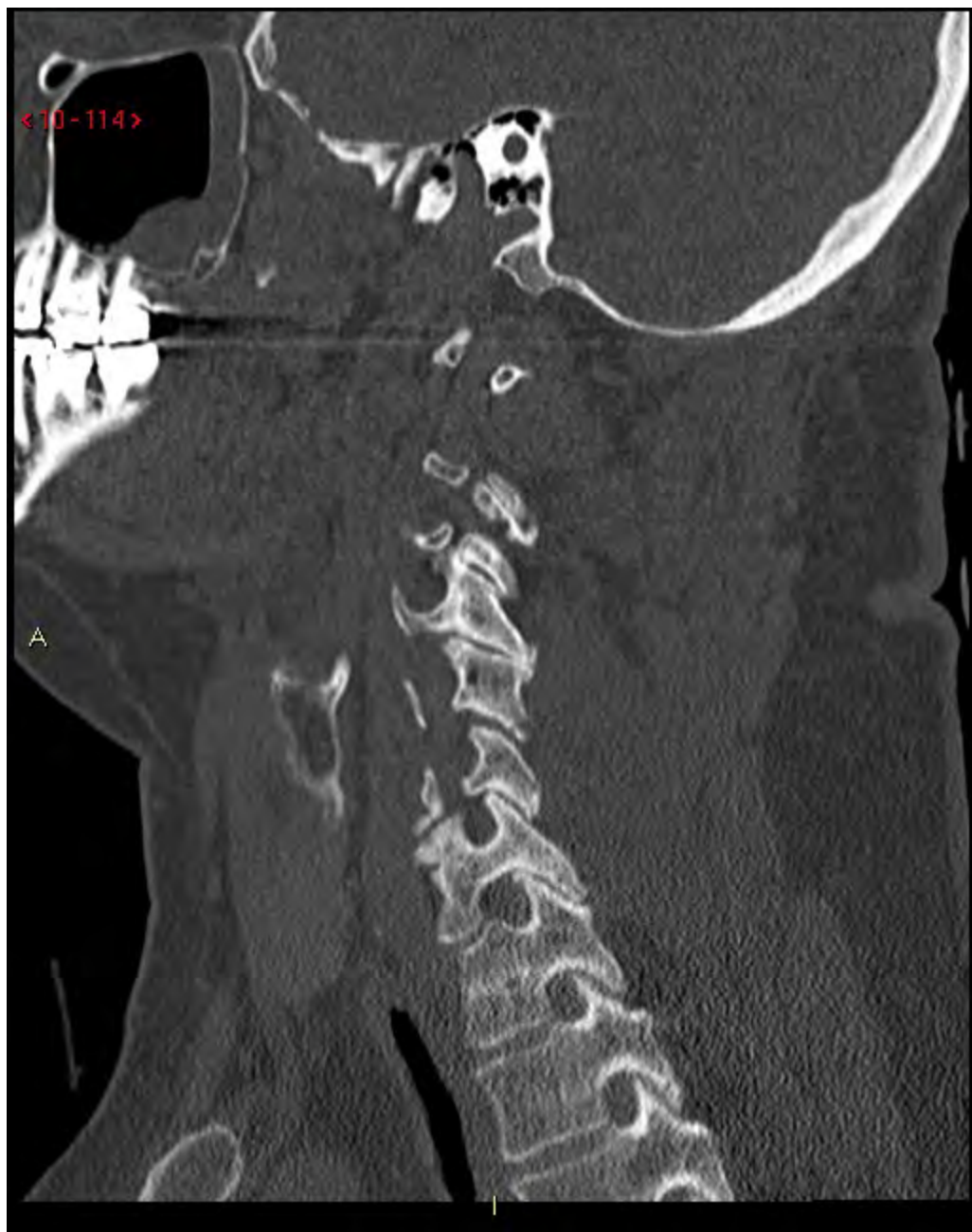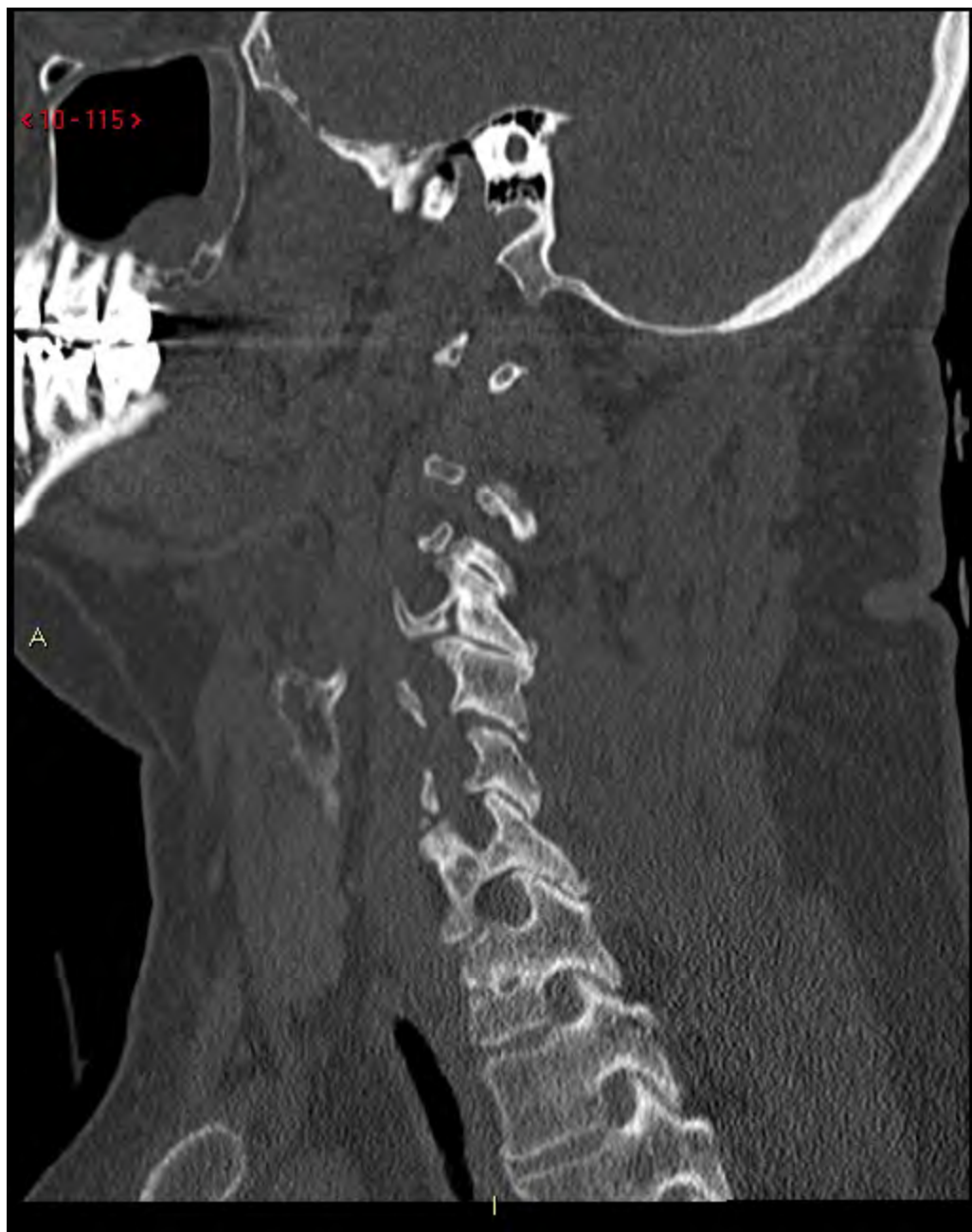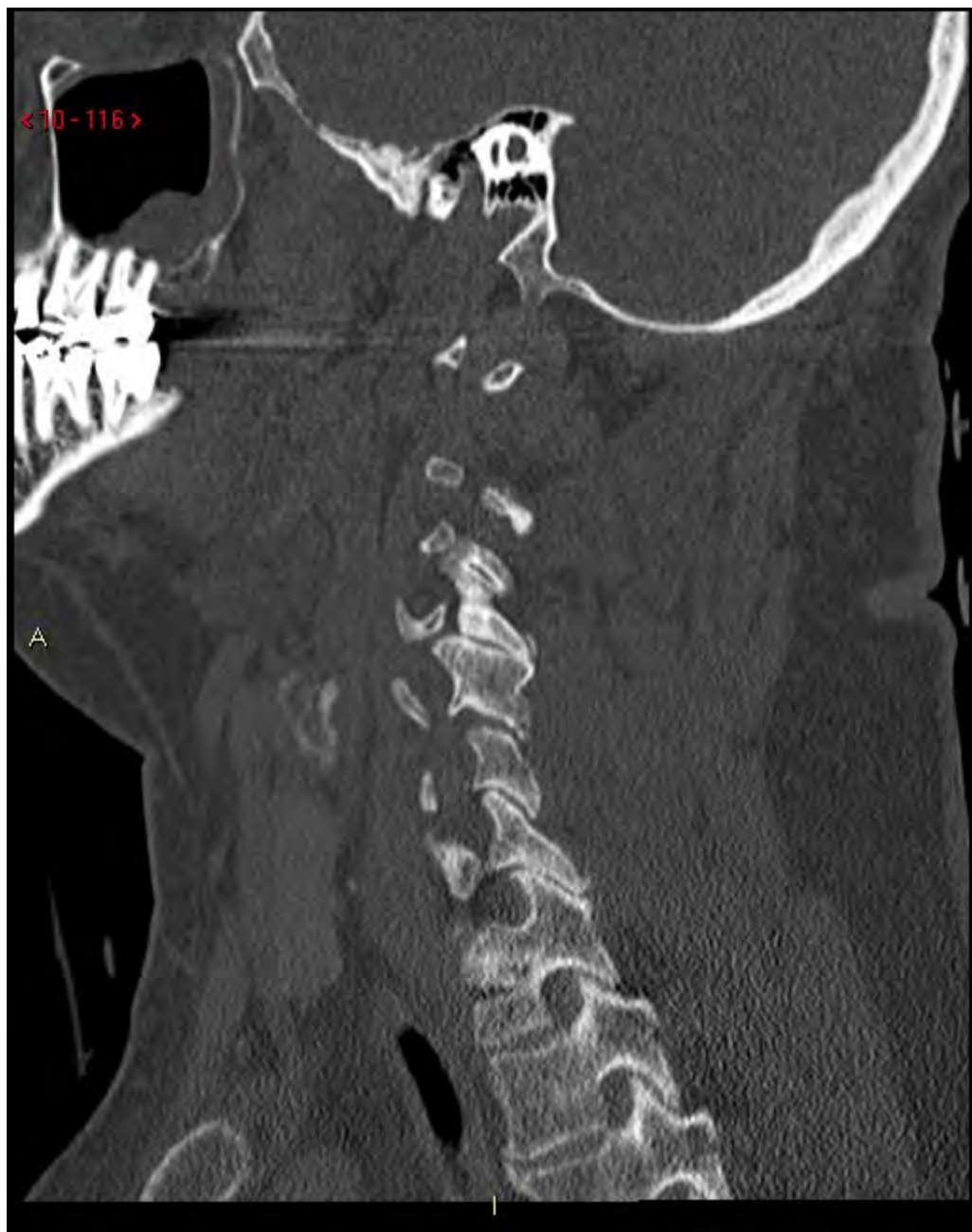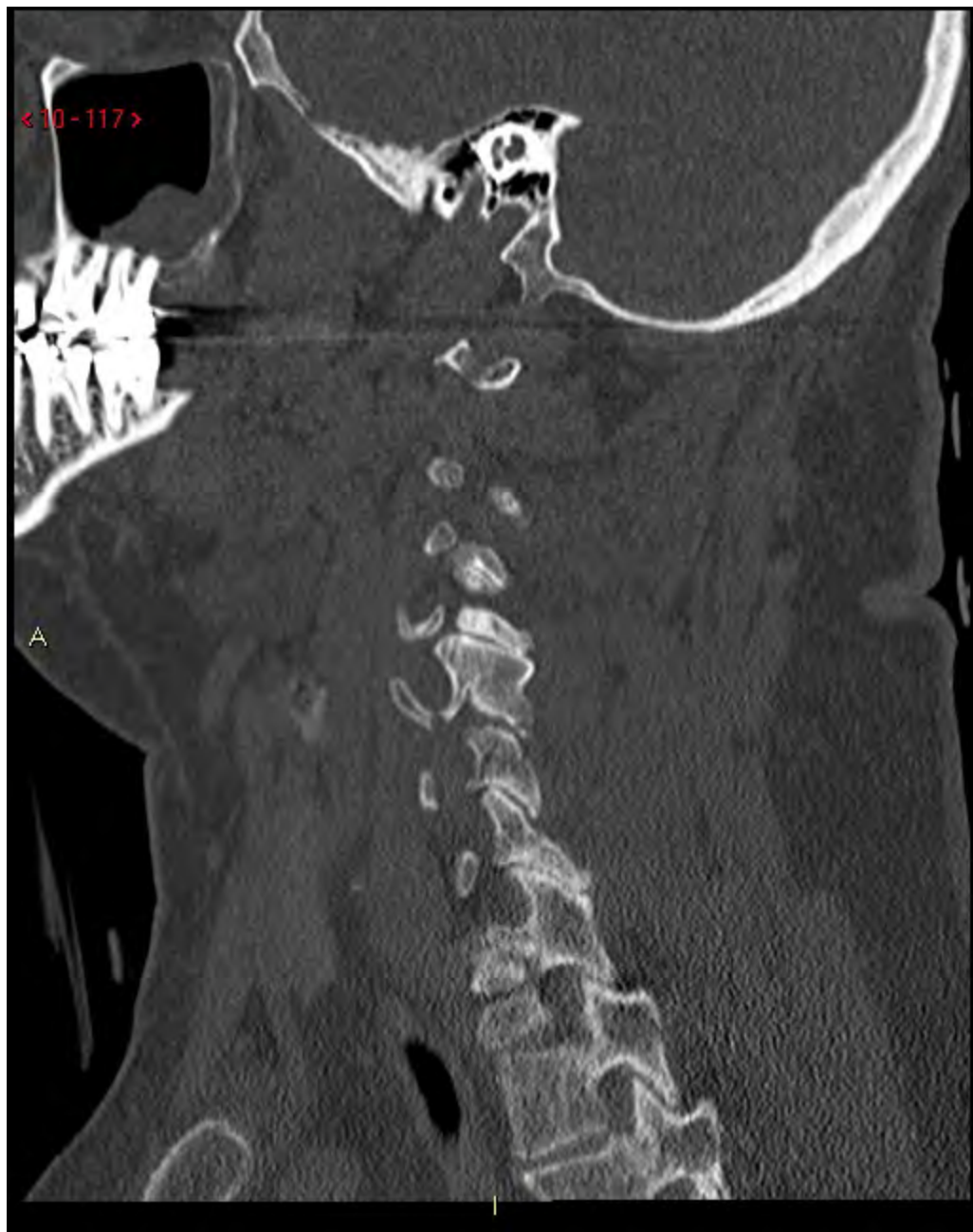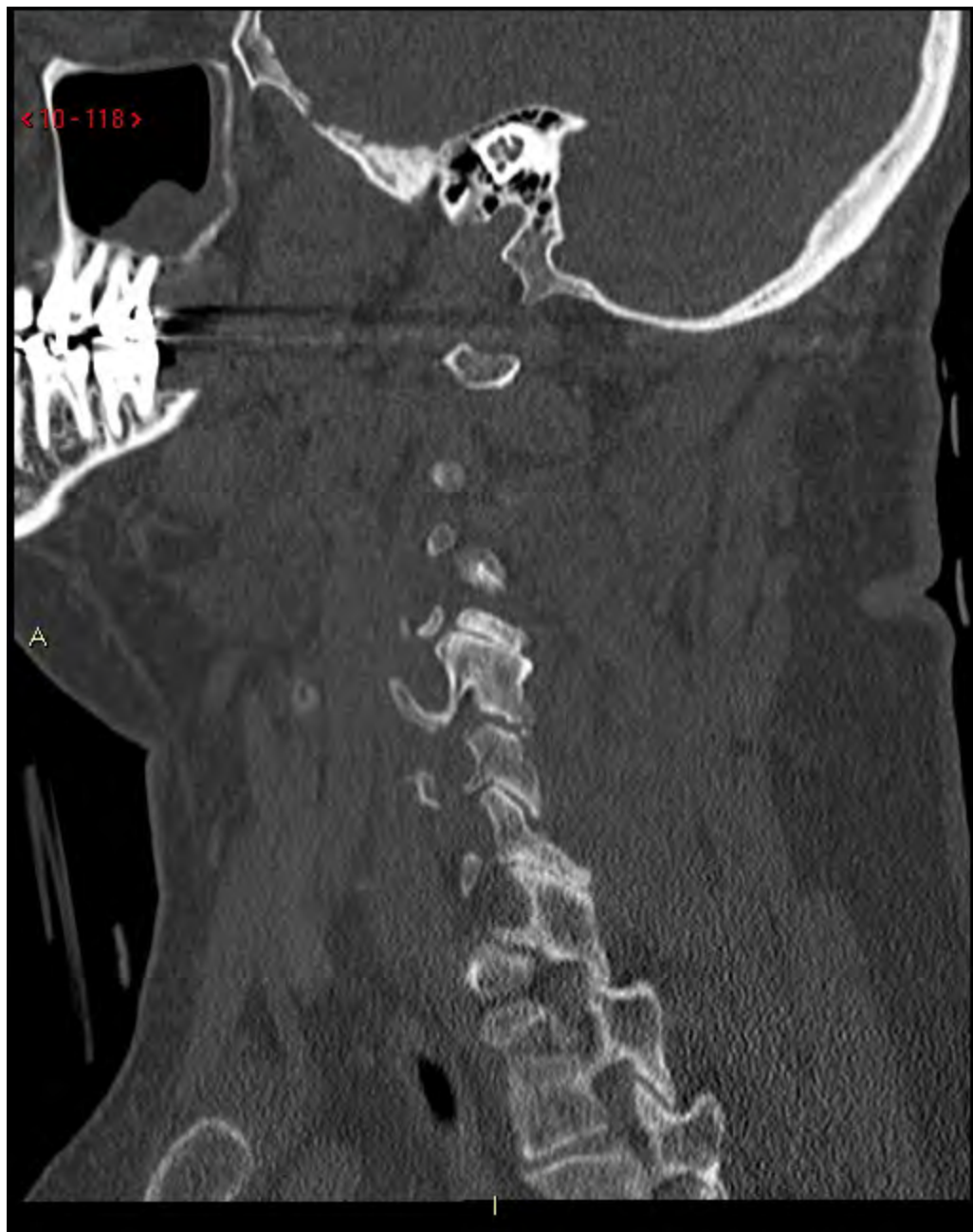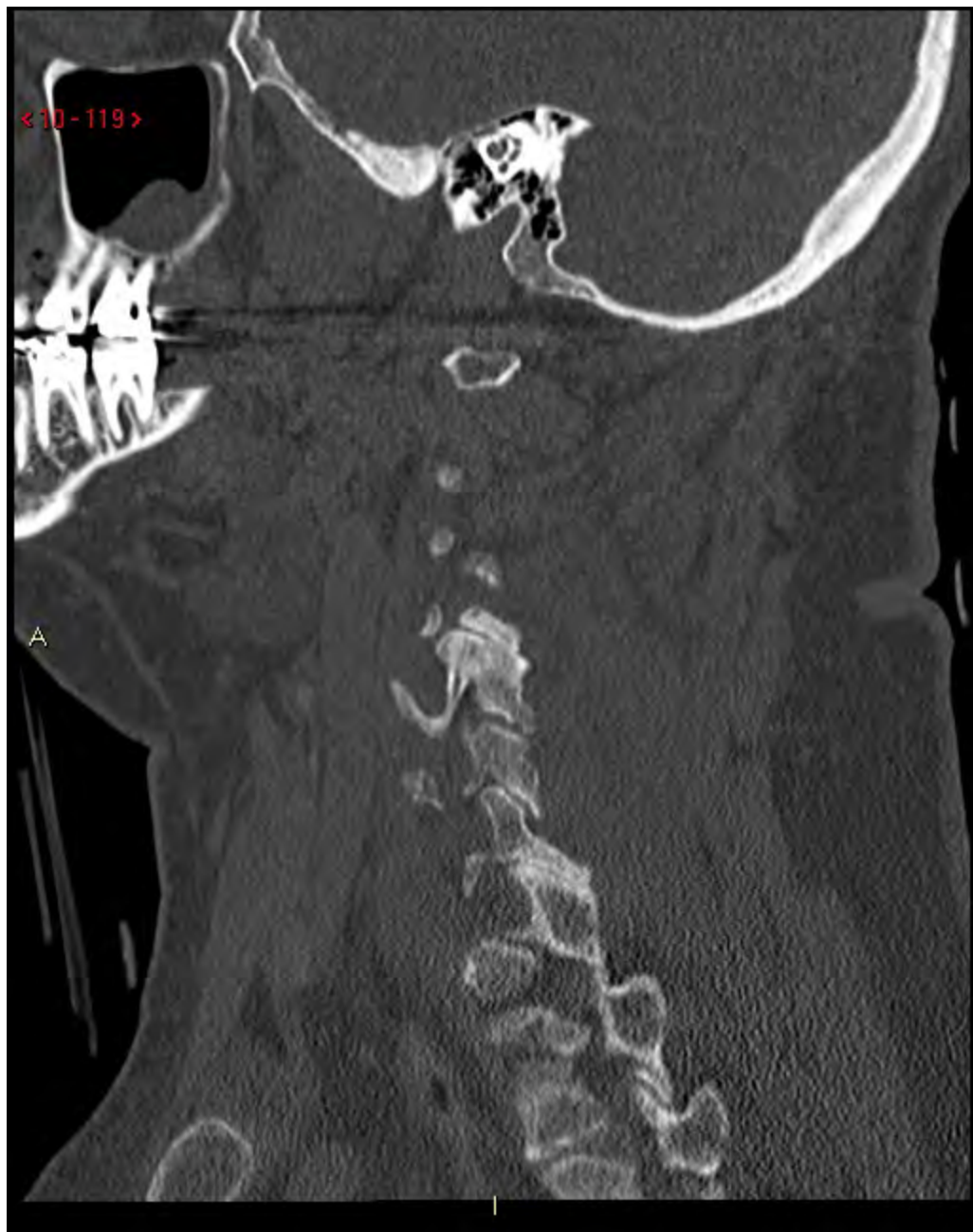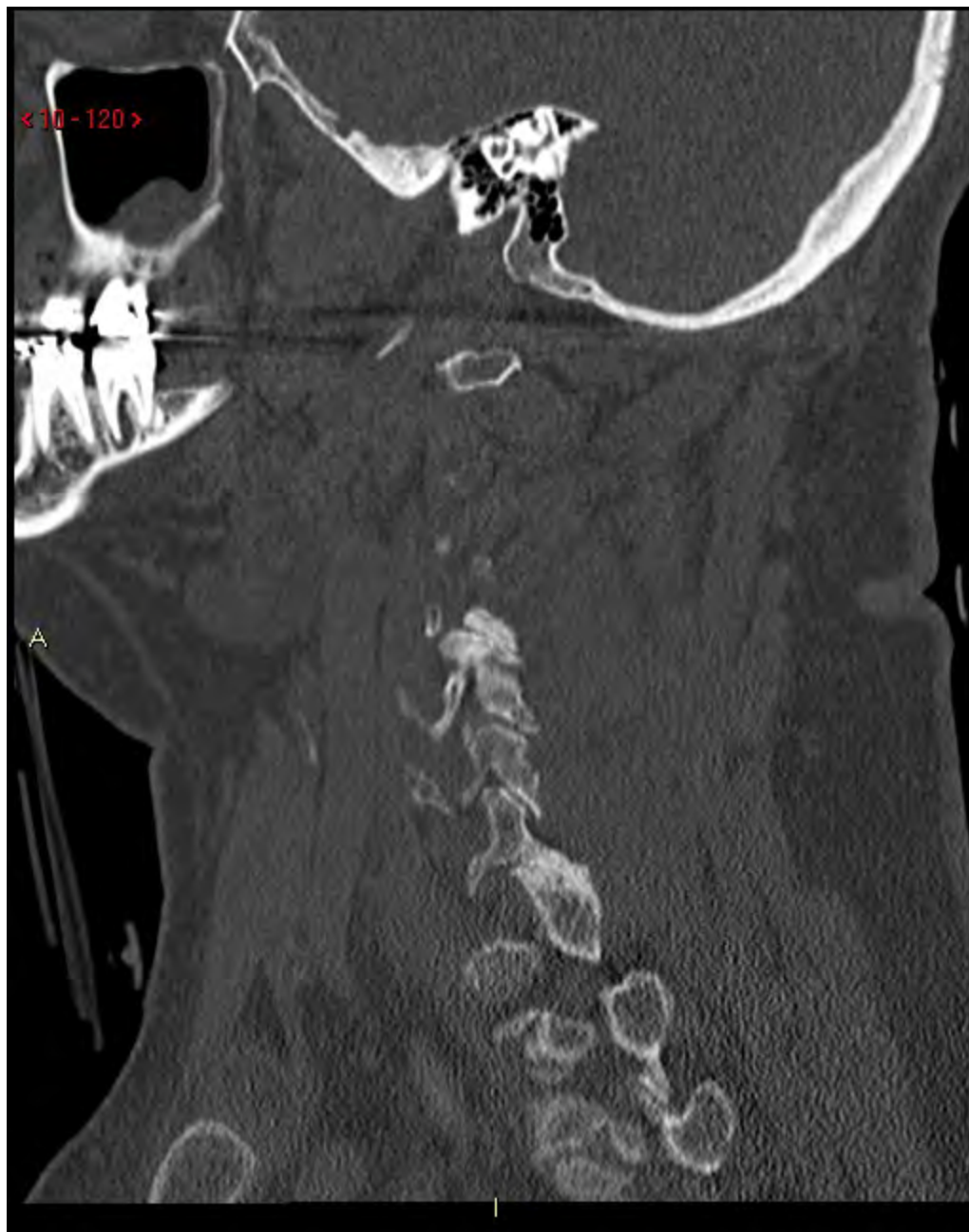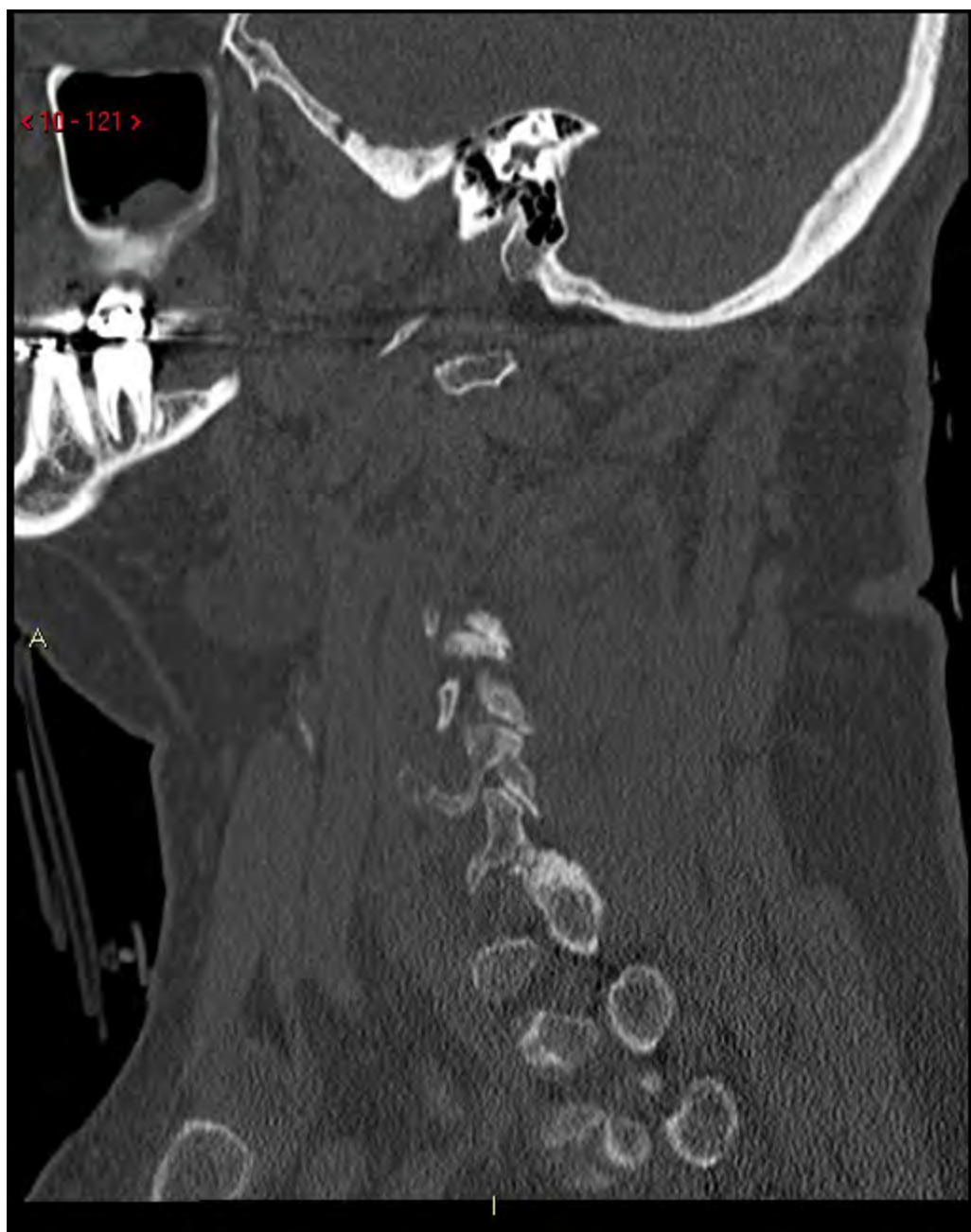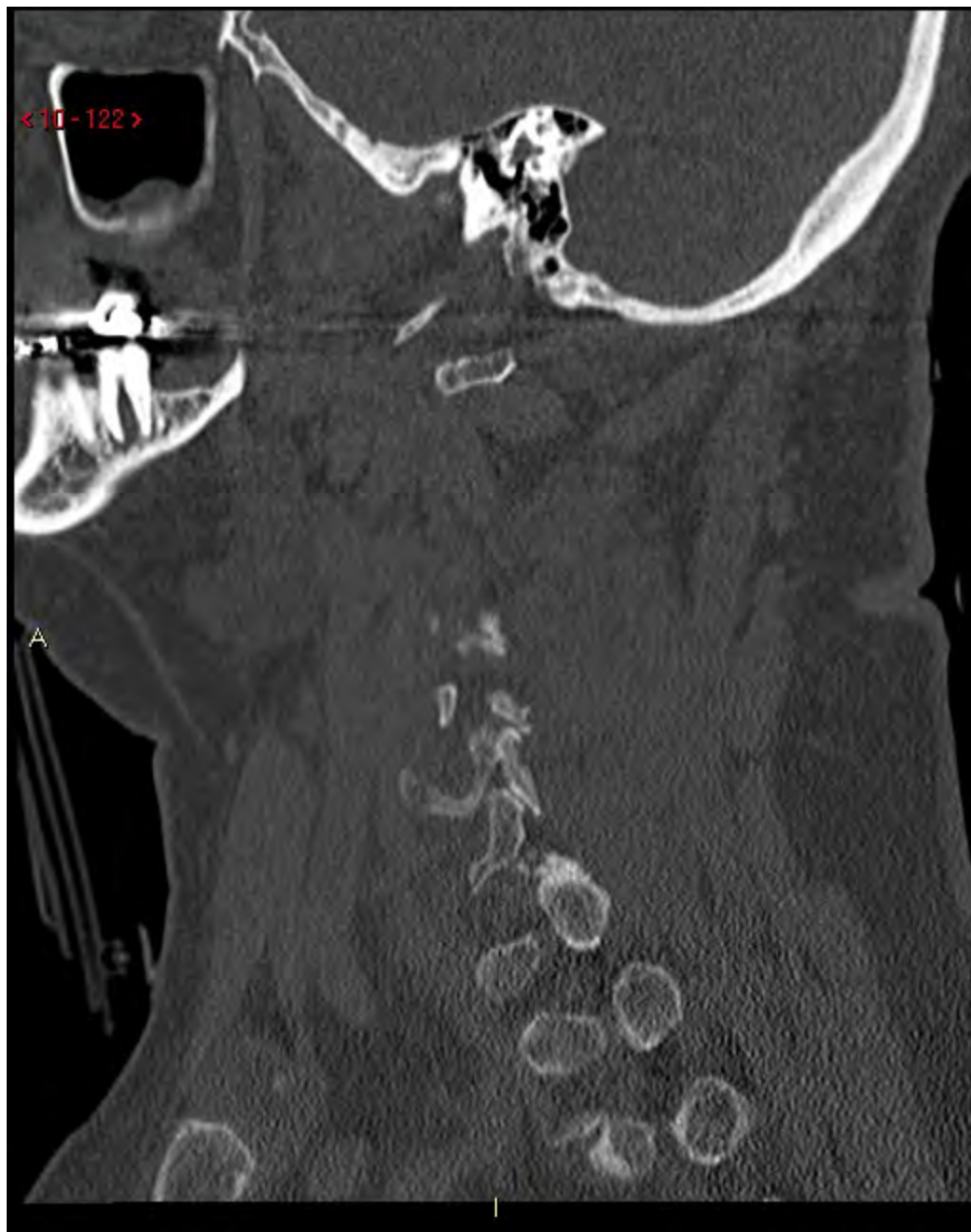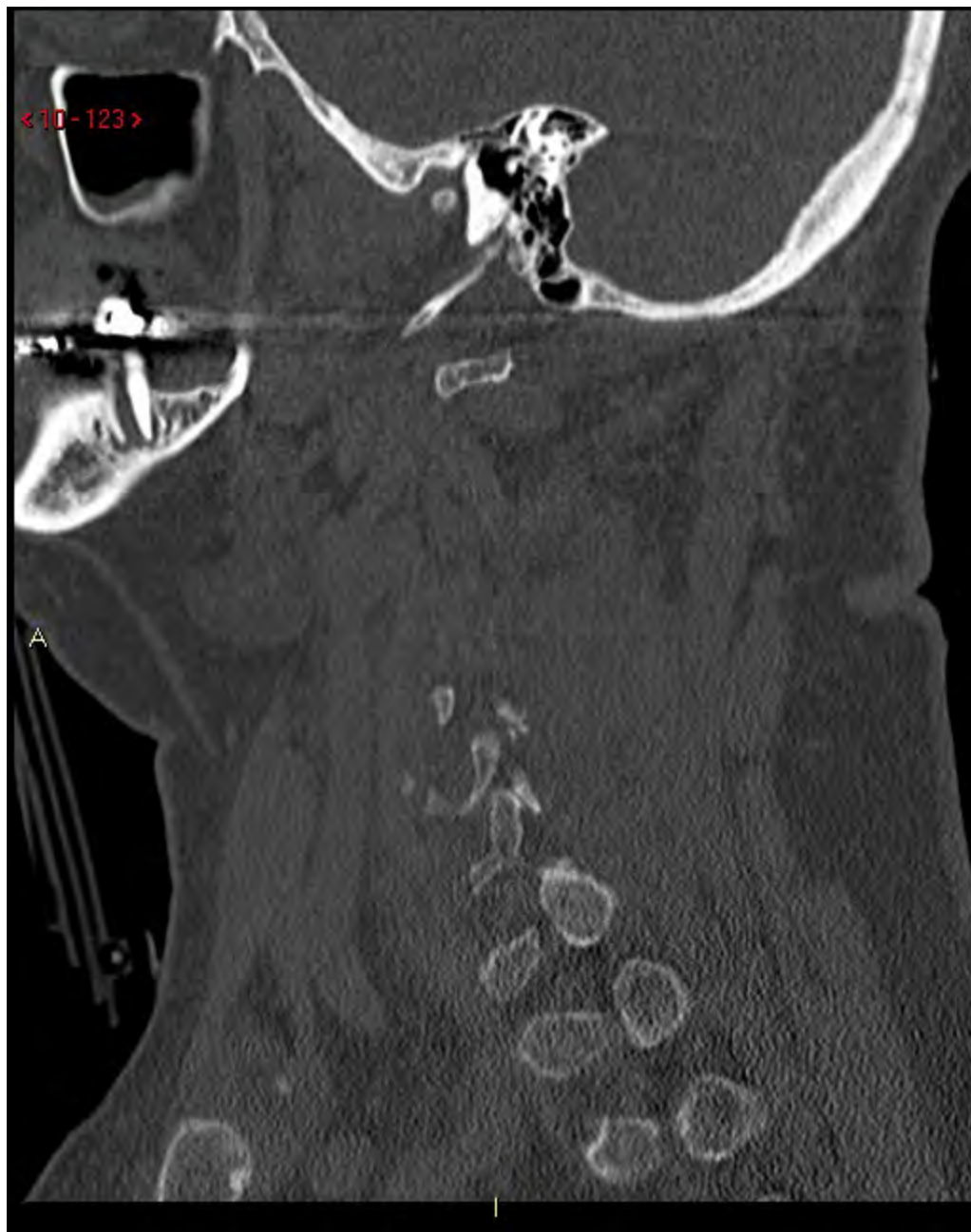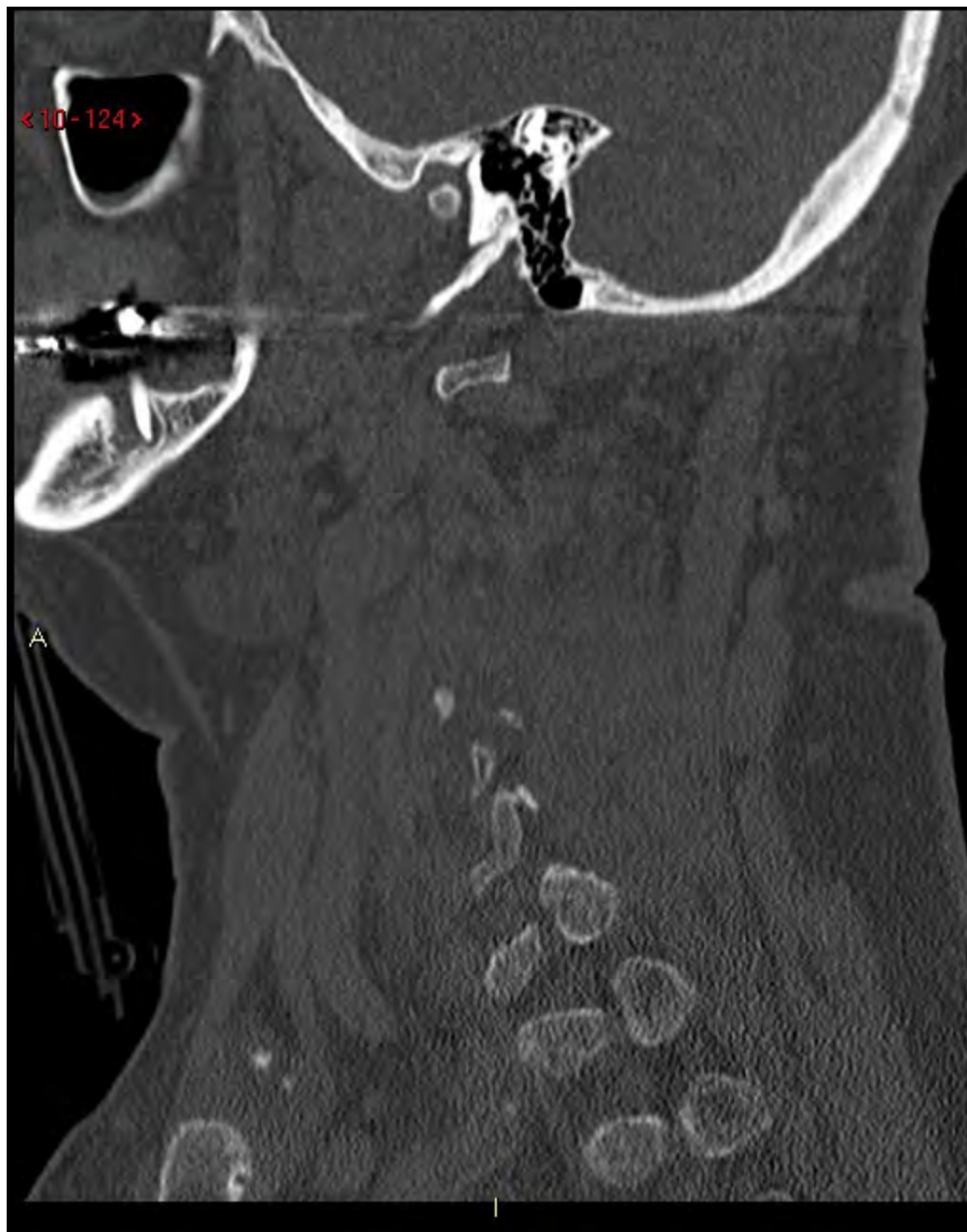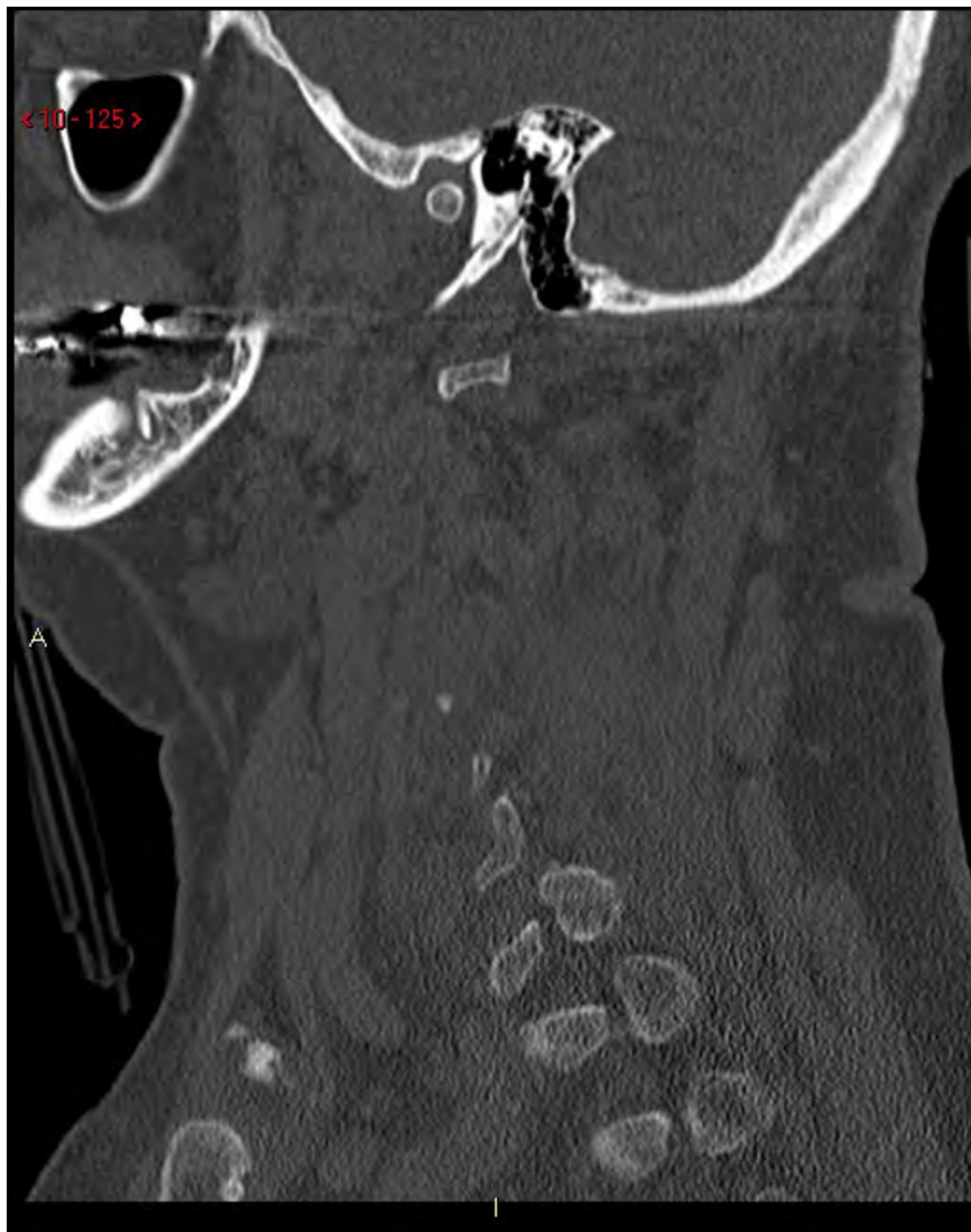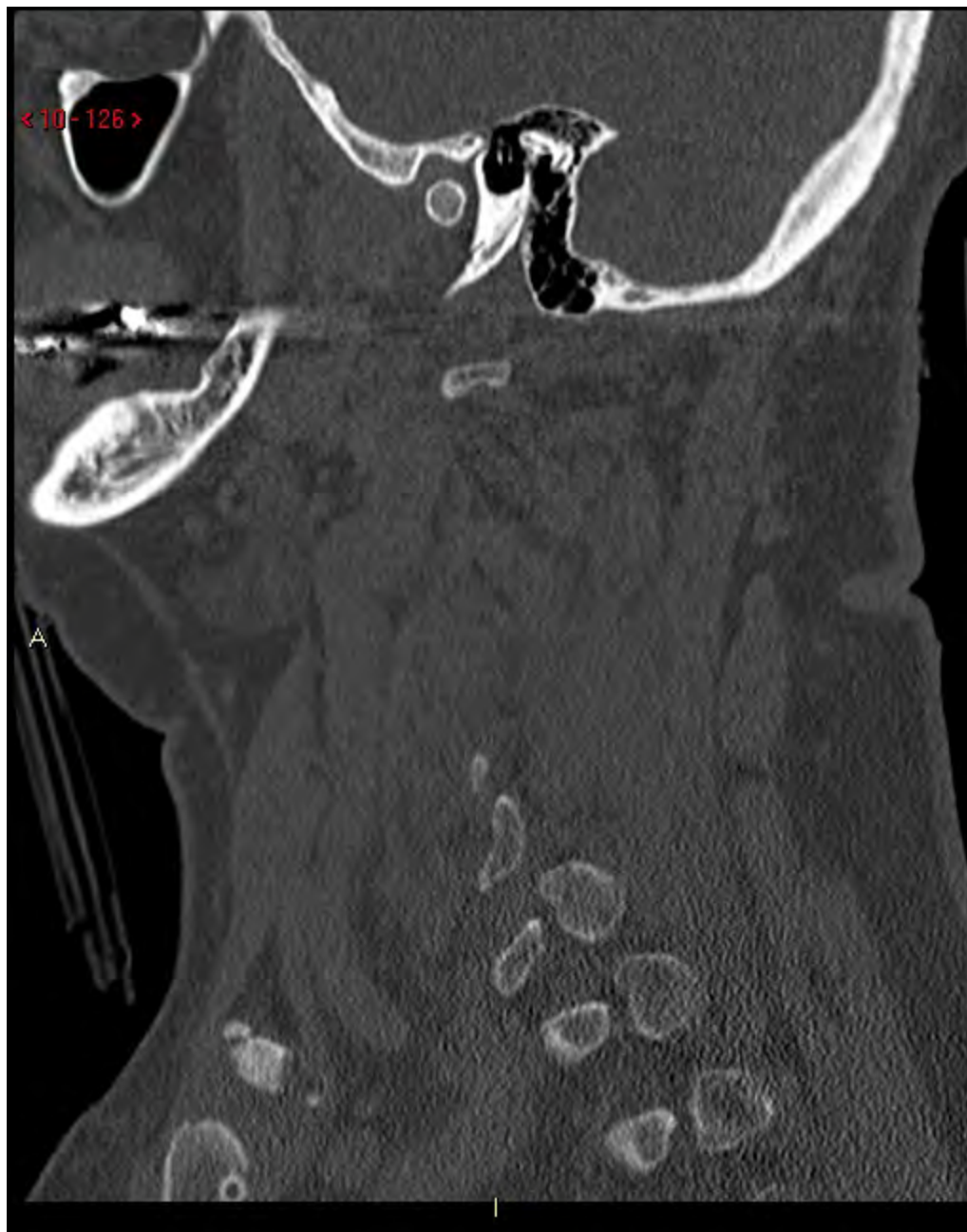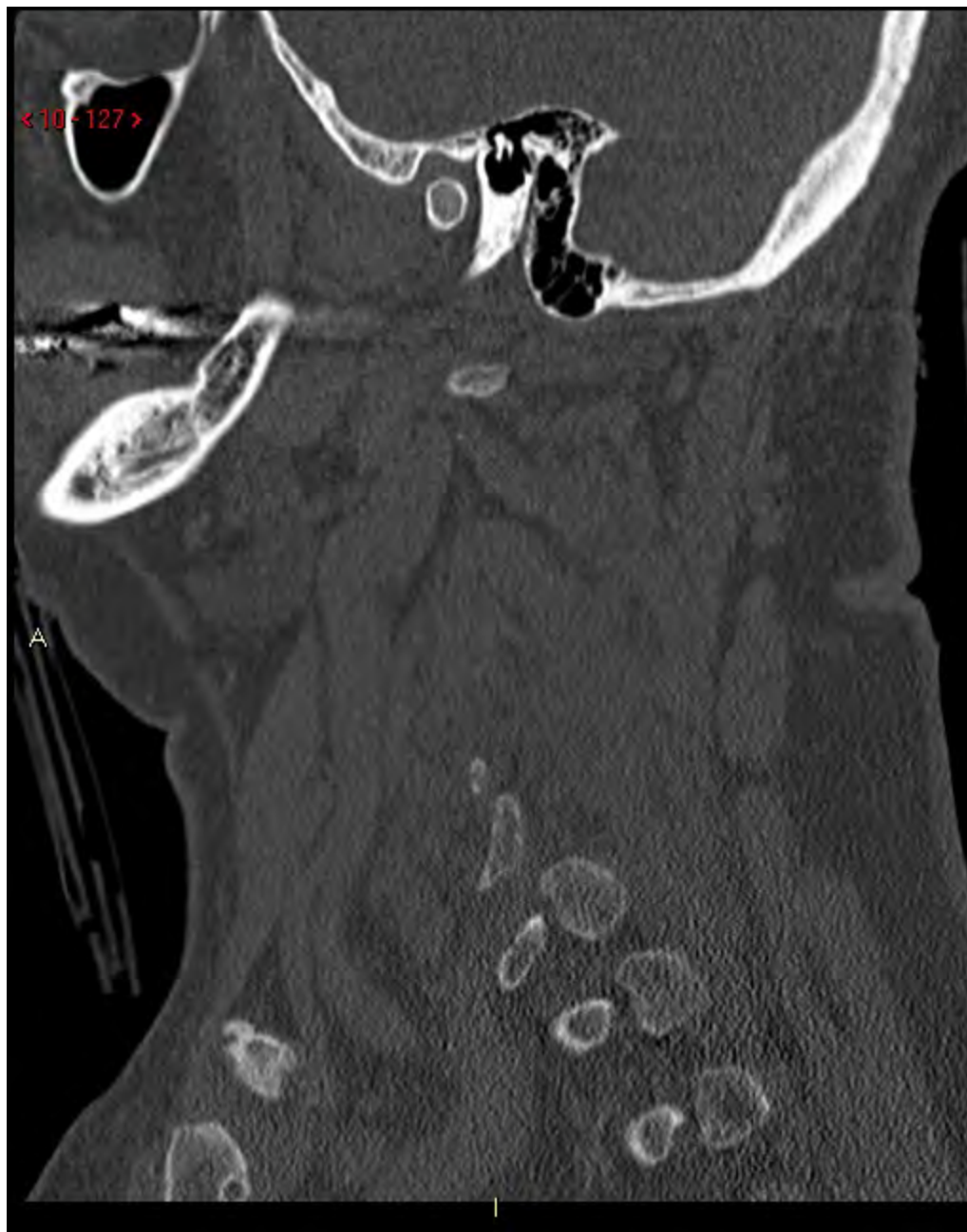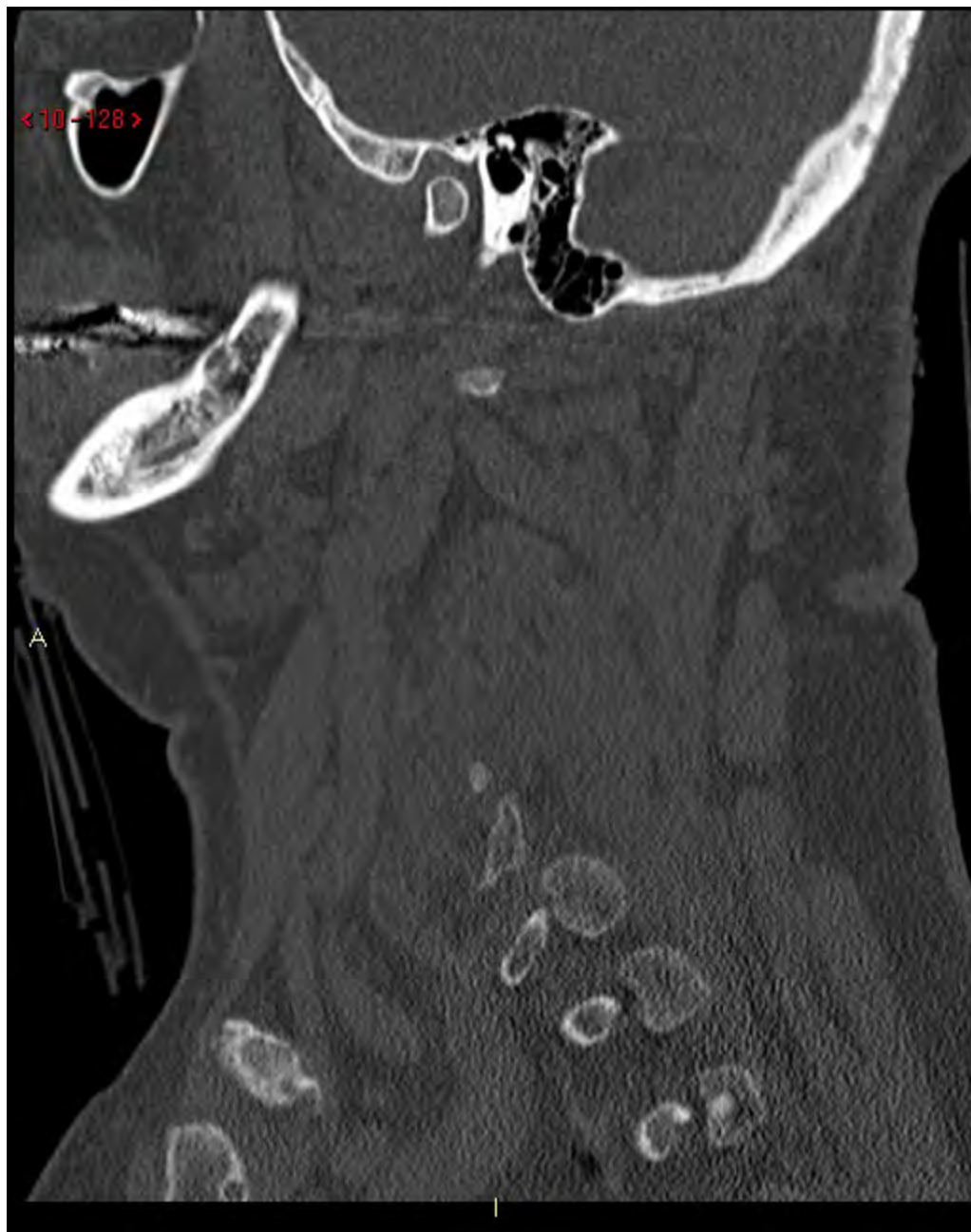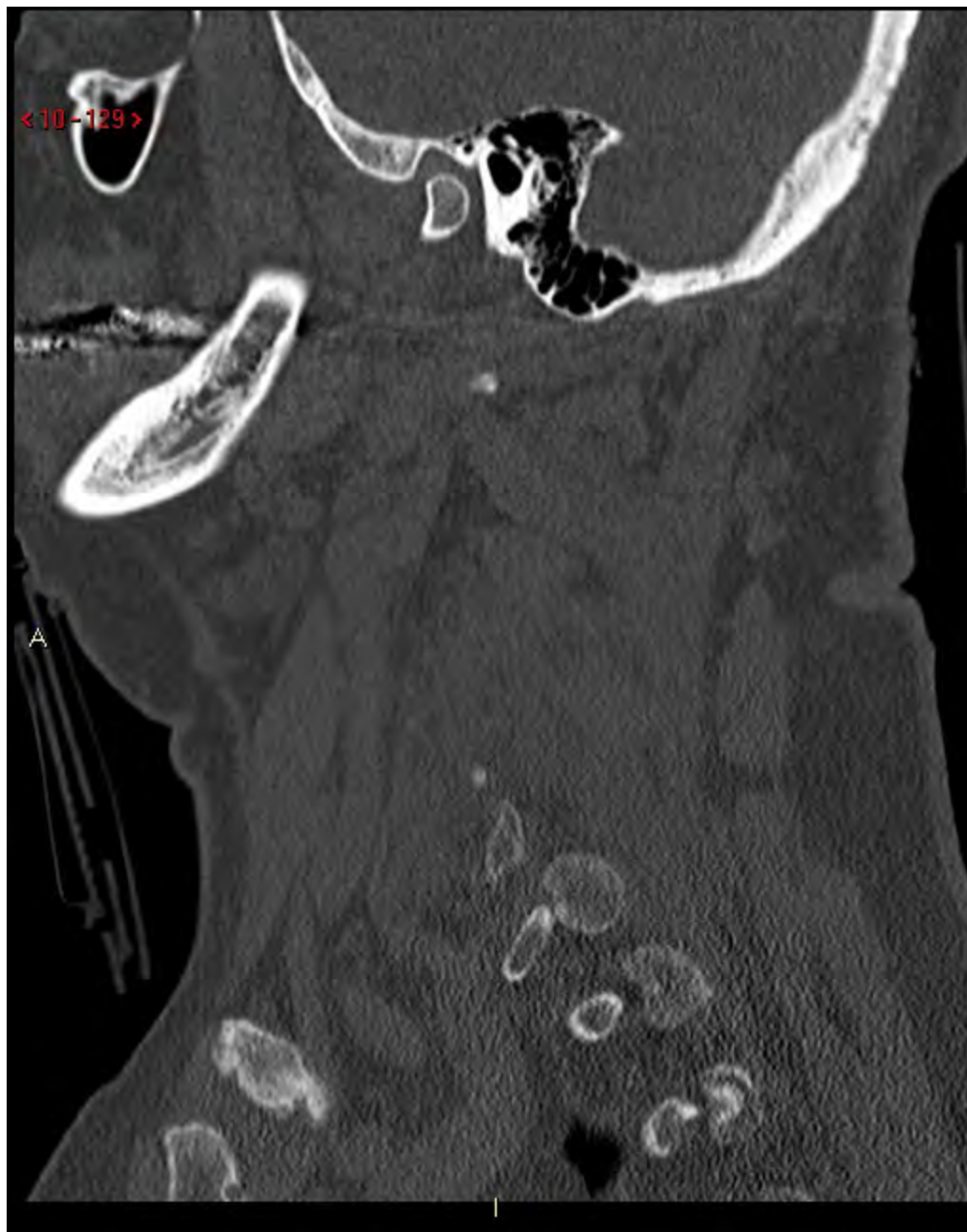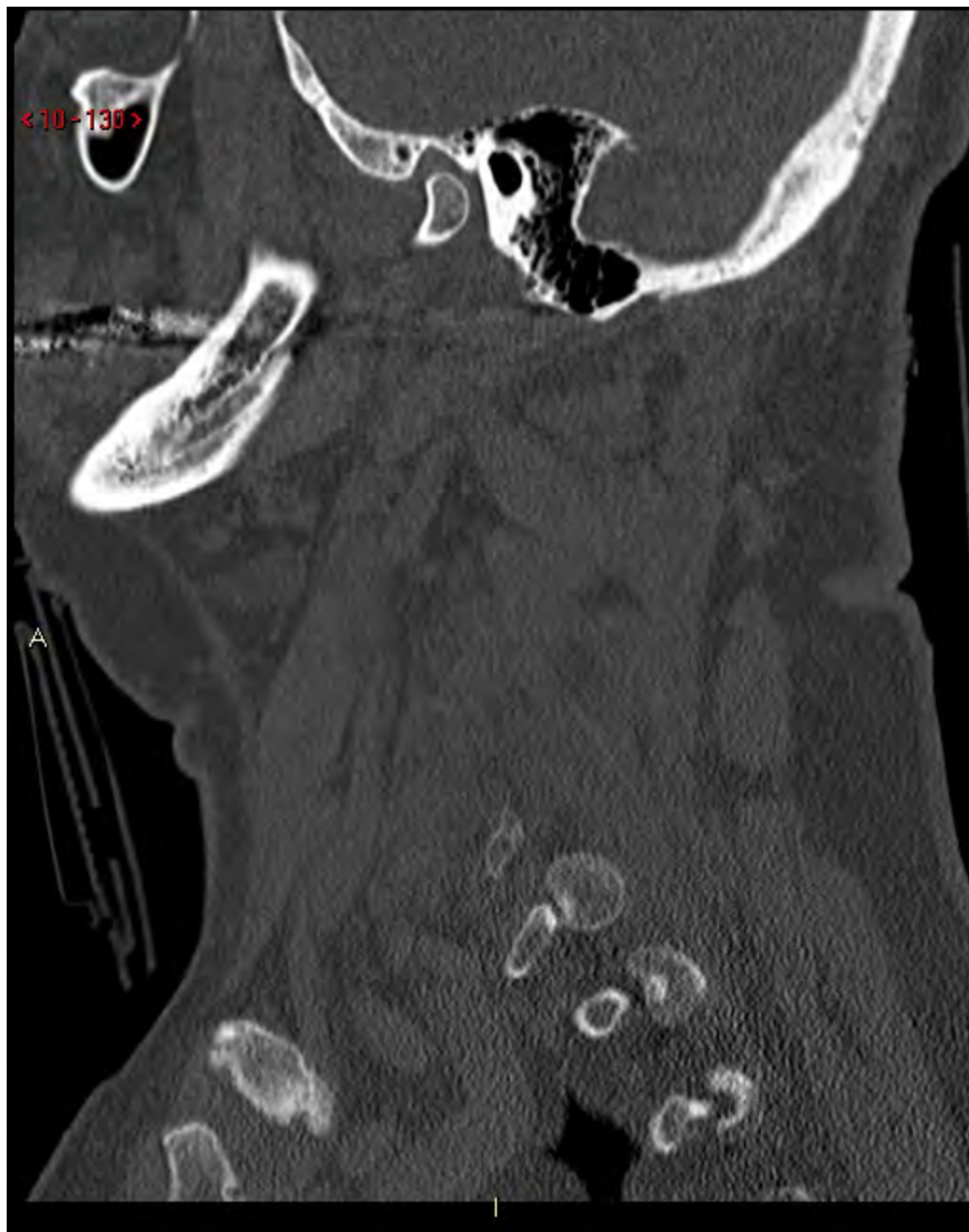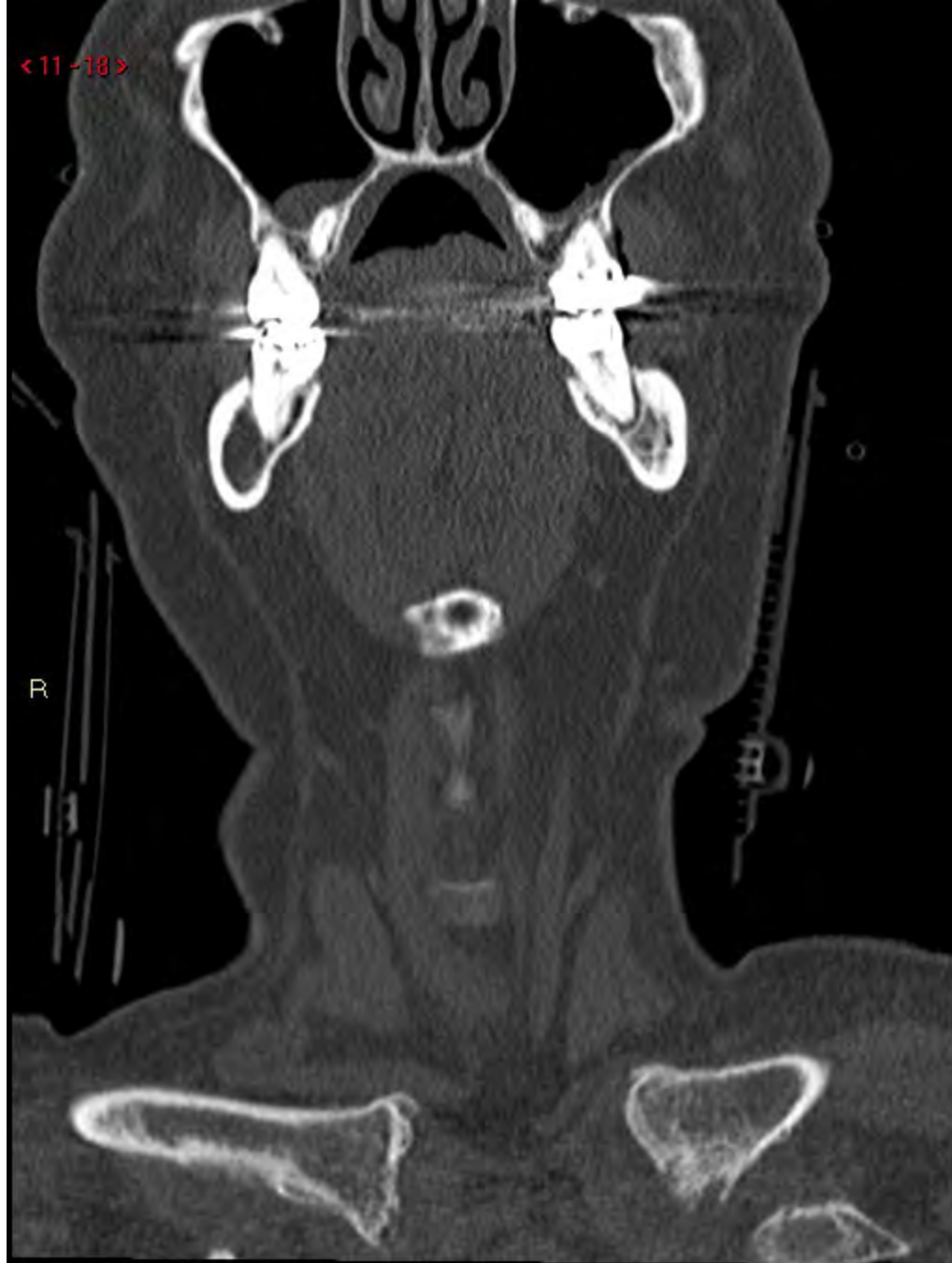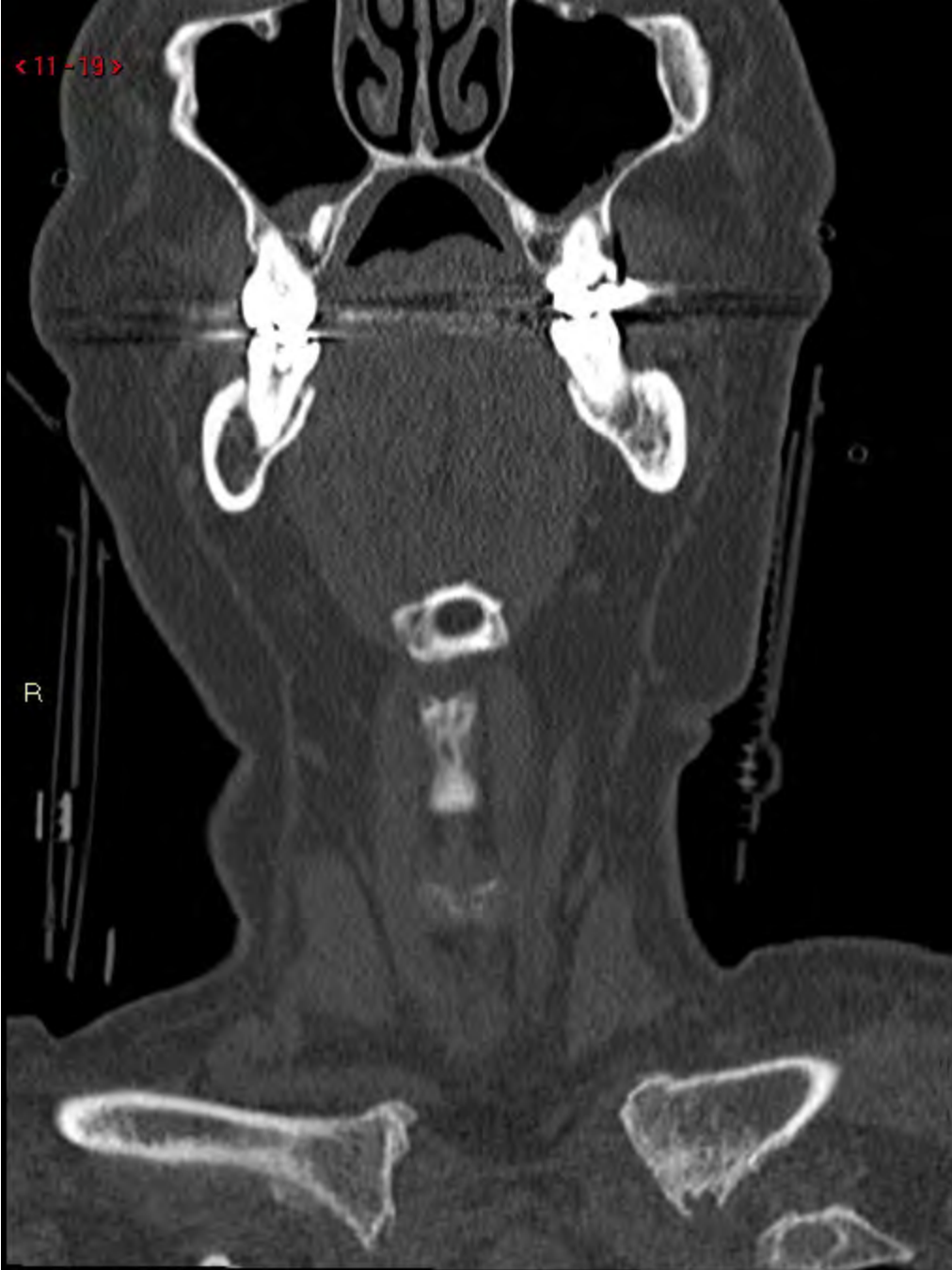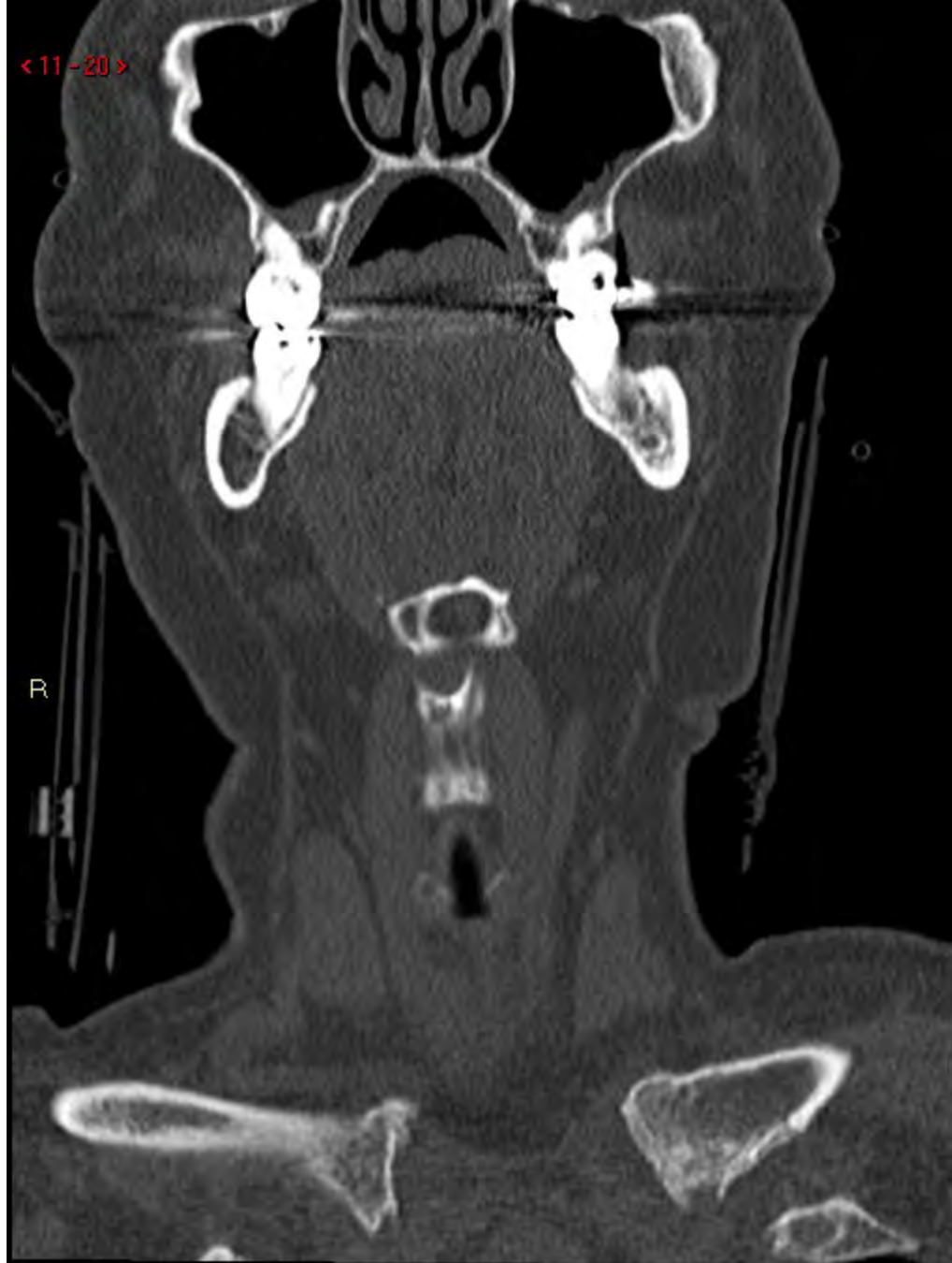< 11-18 >

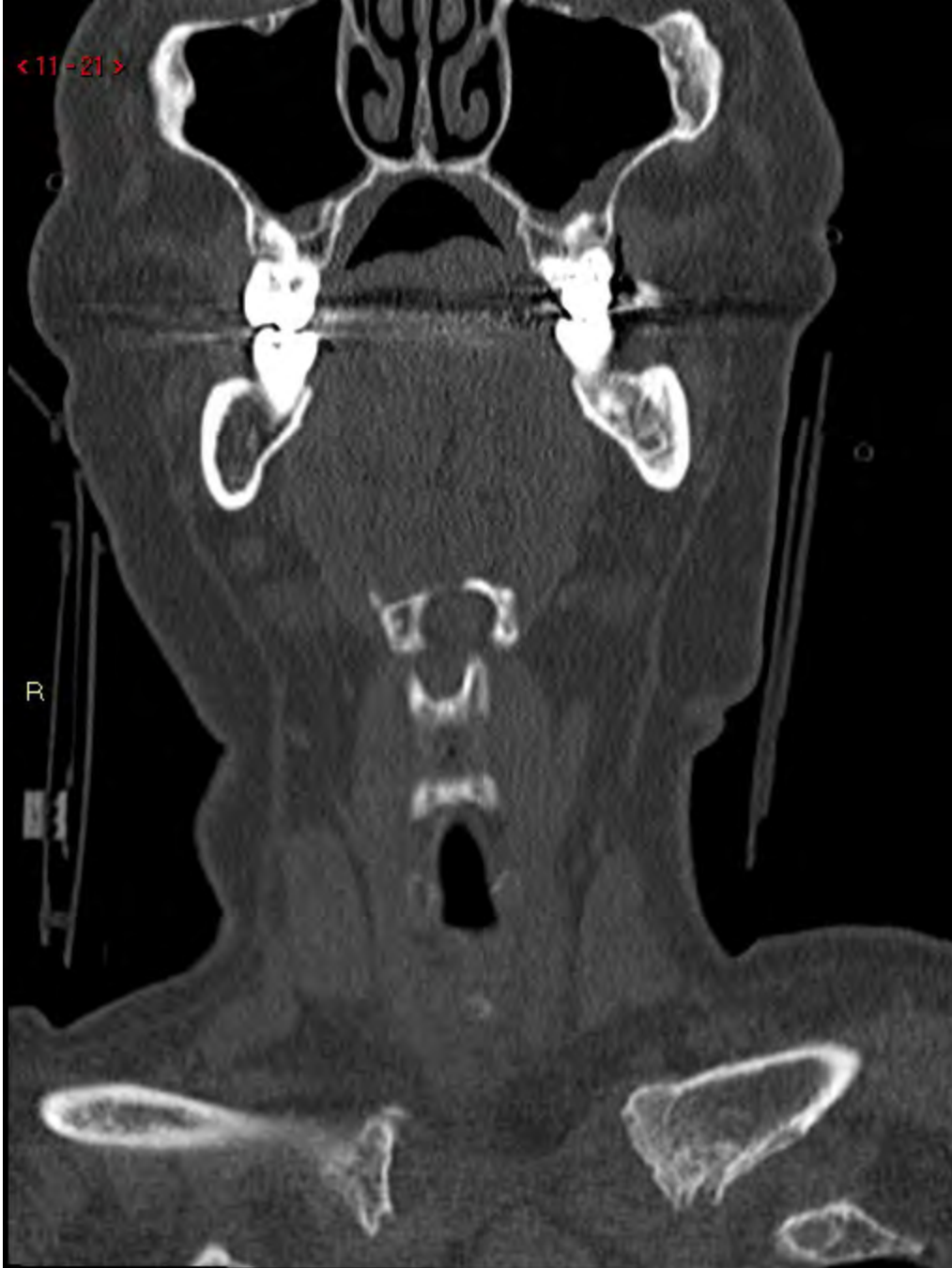

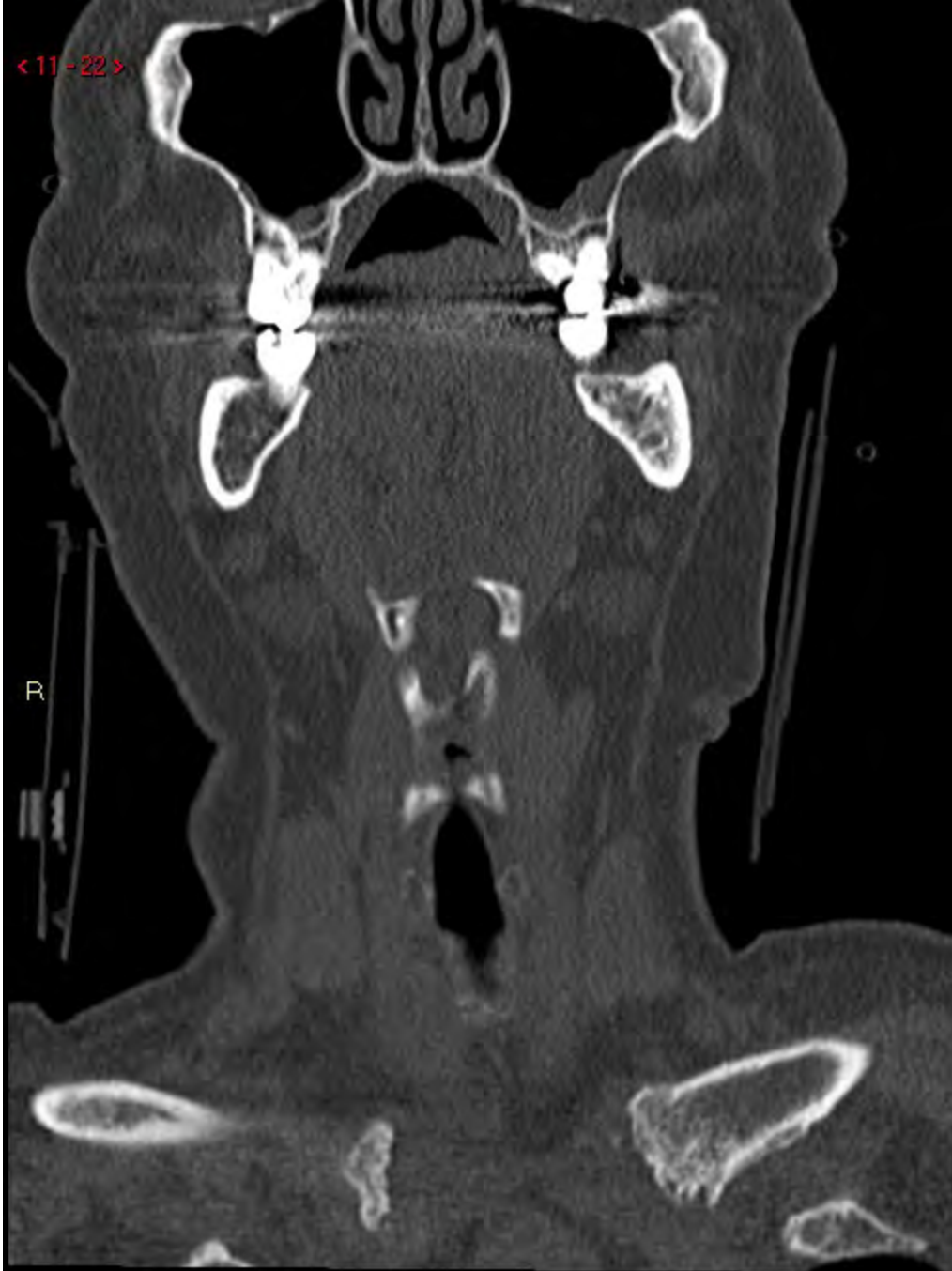<11-19>

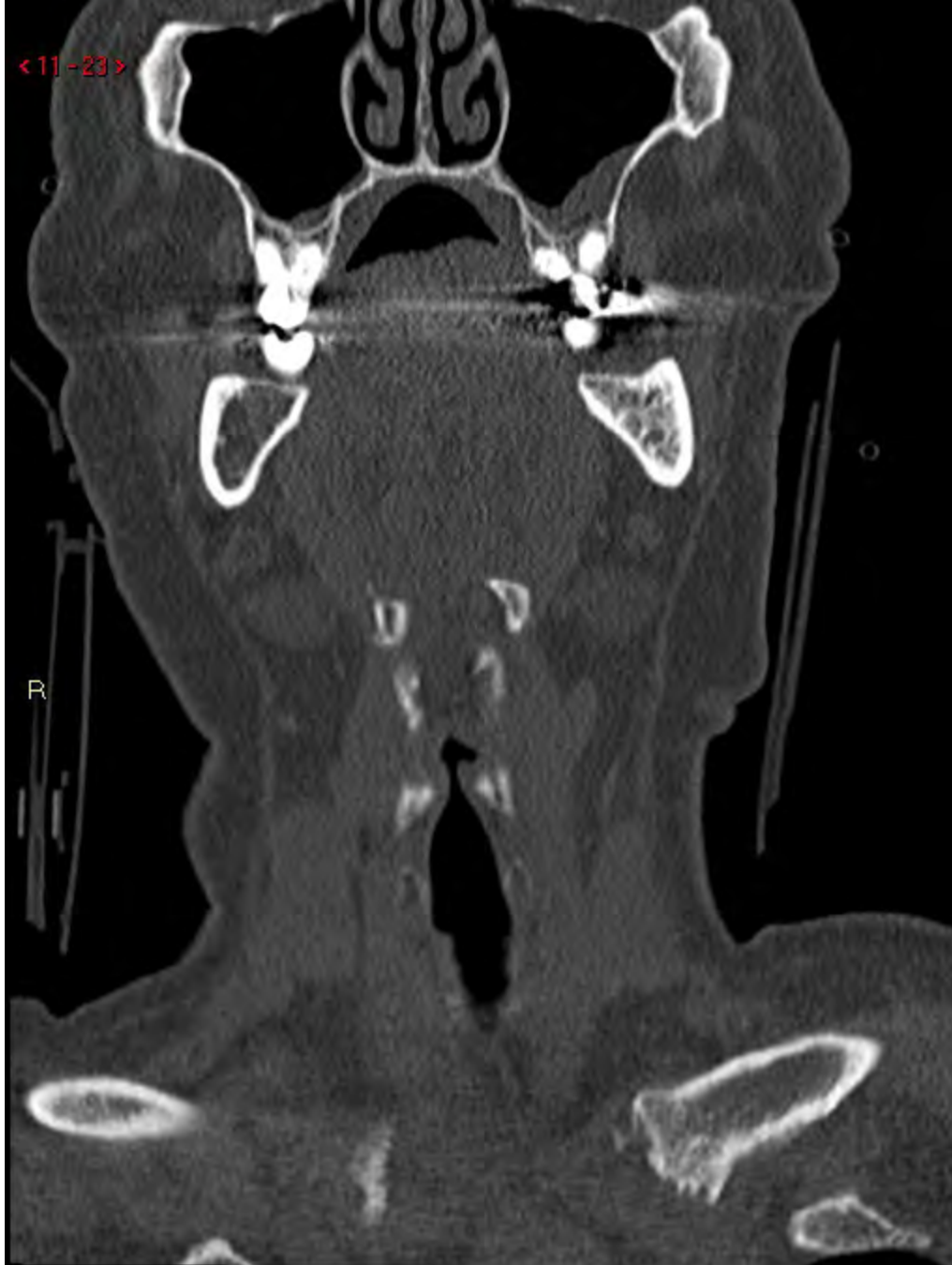

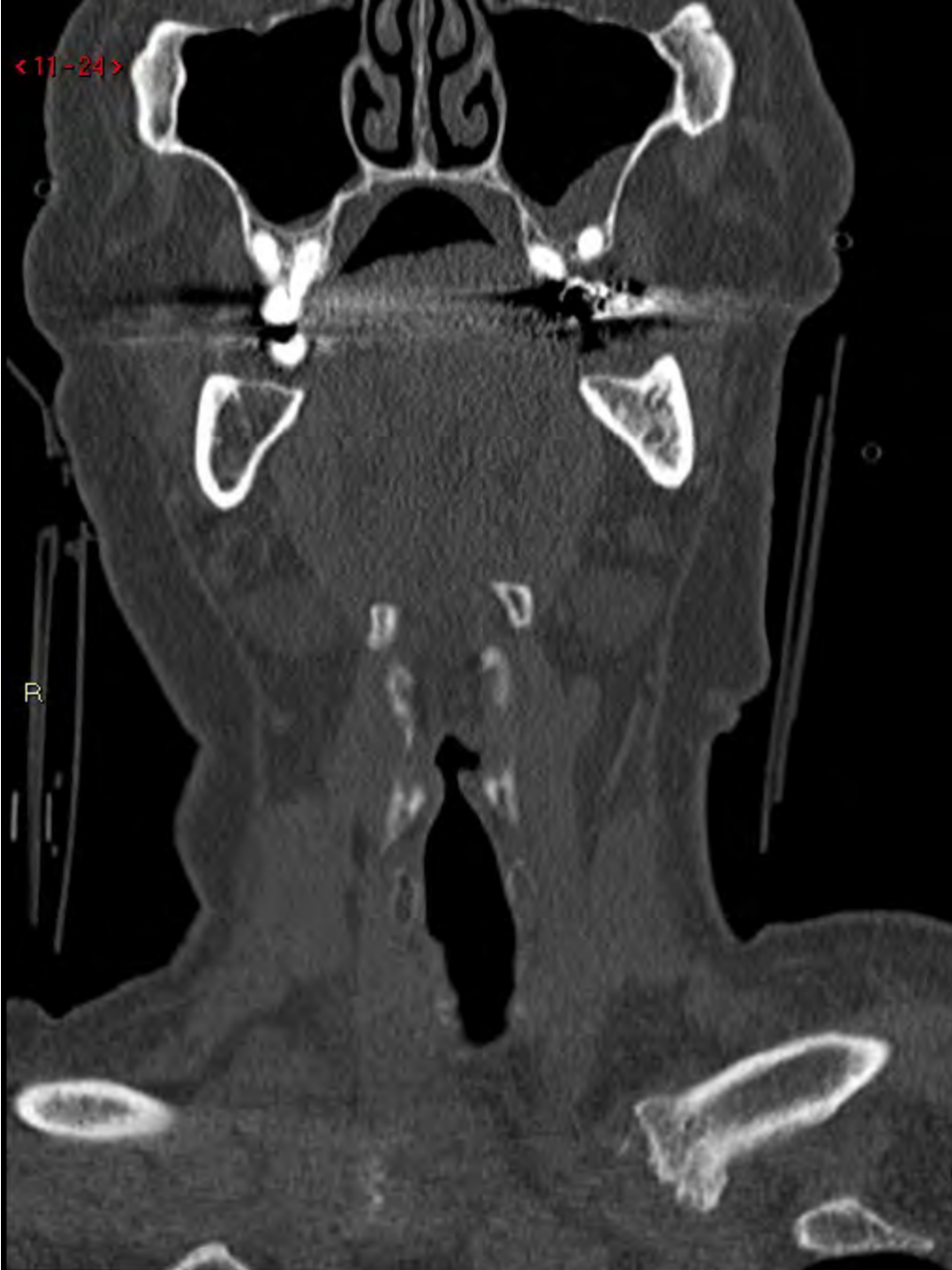< 11 - 20 >

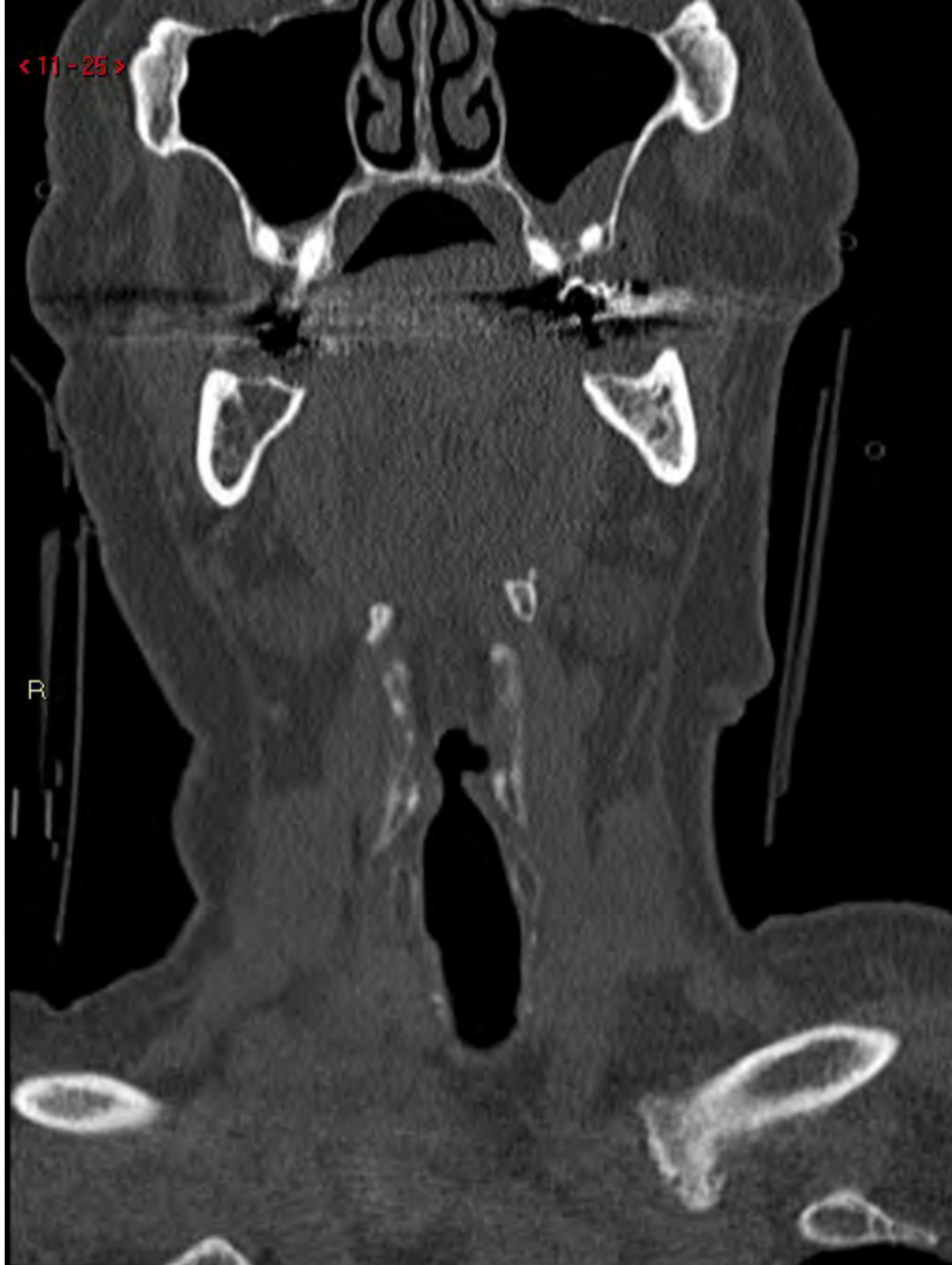


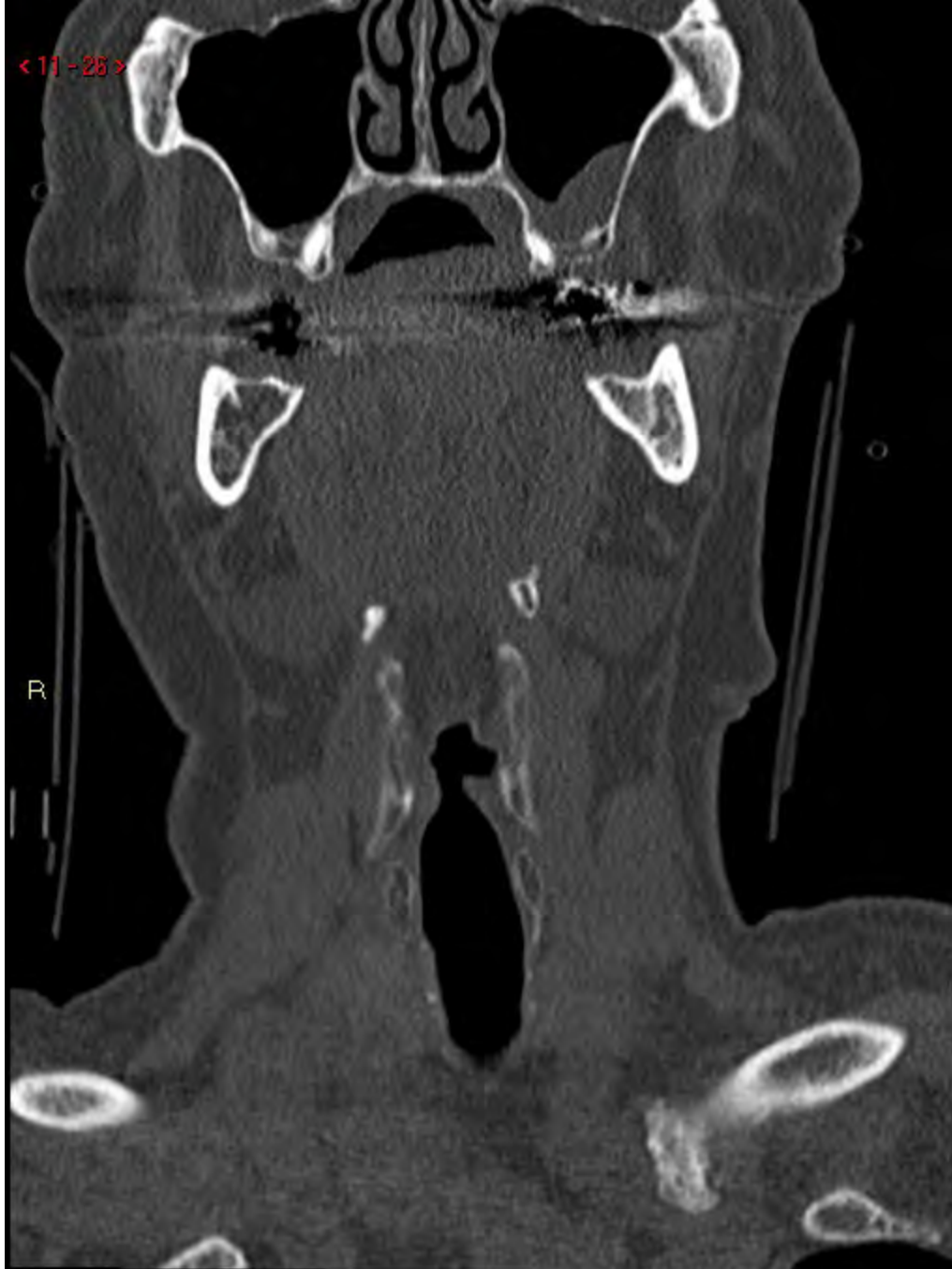




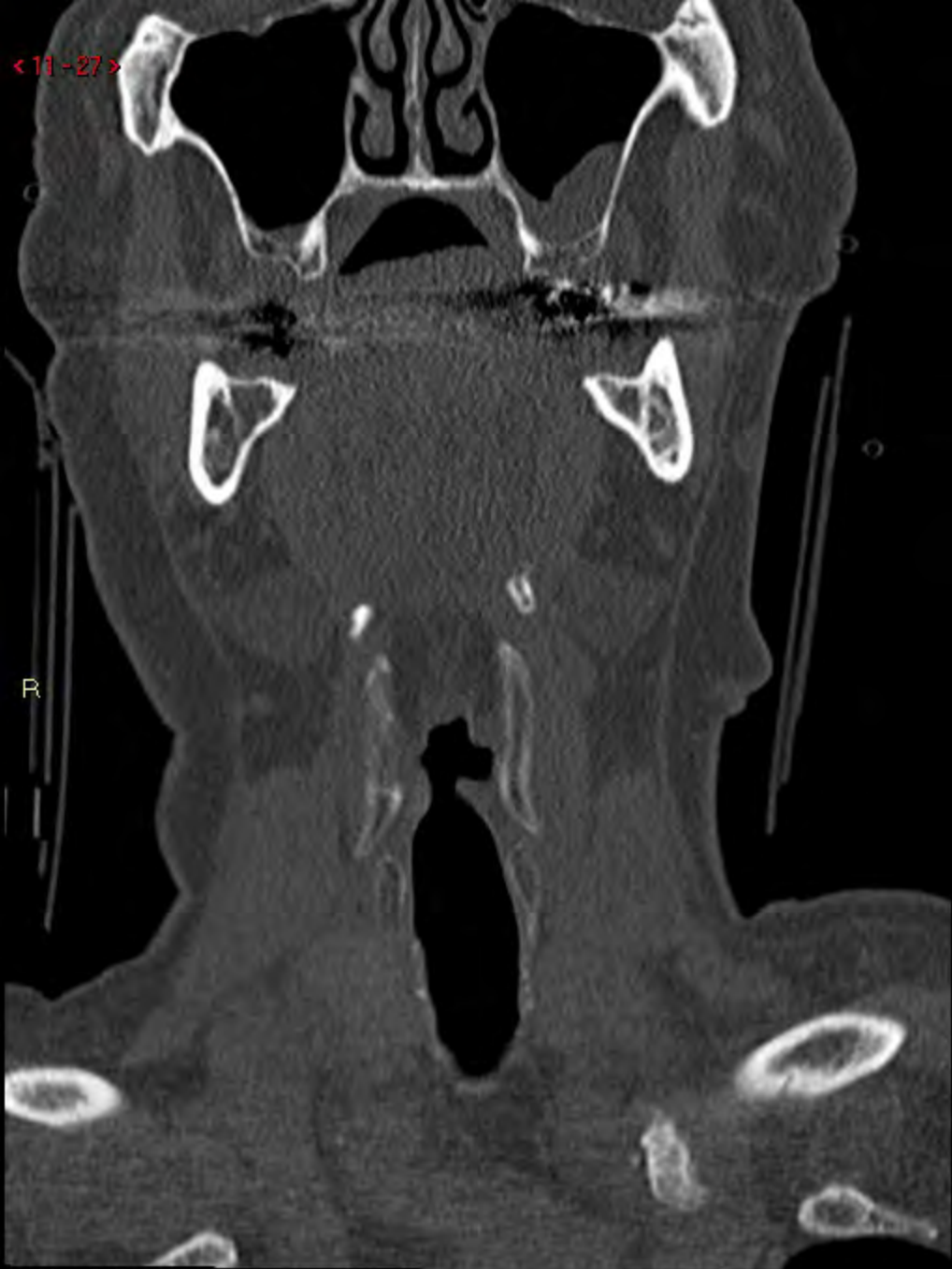




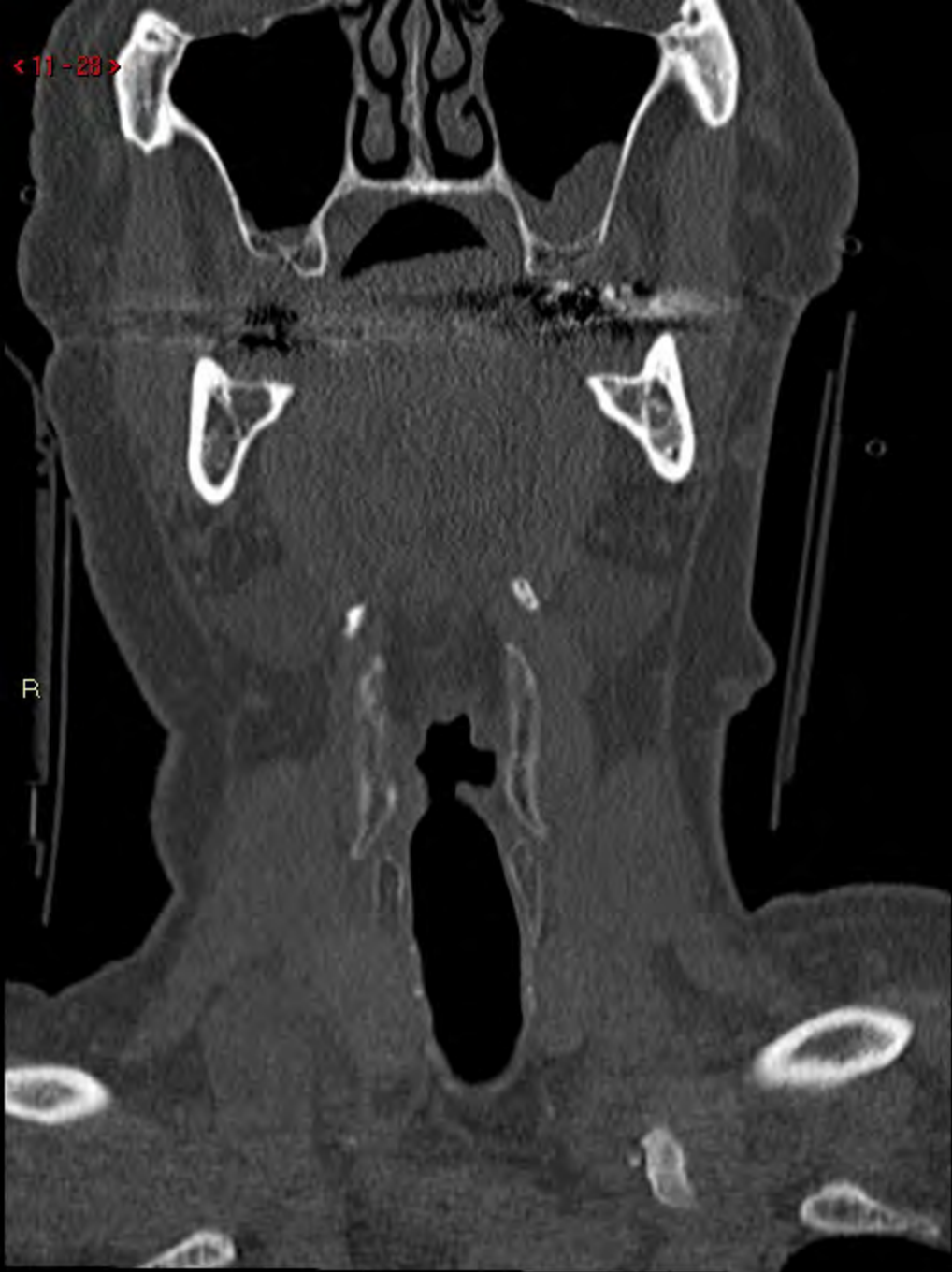
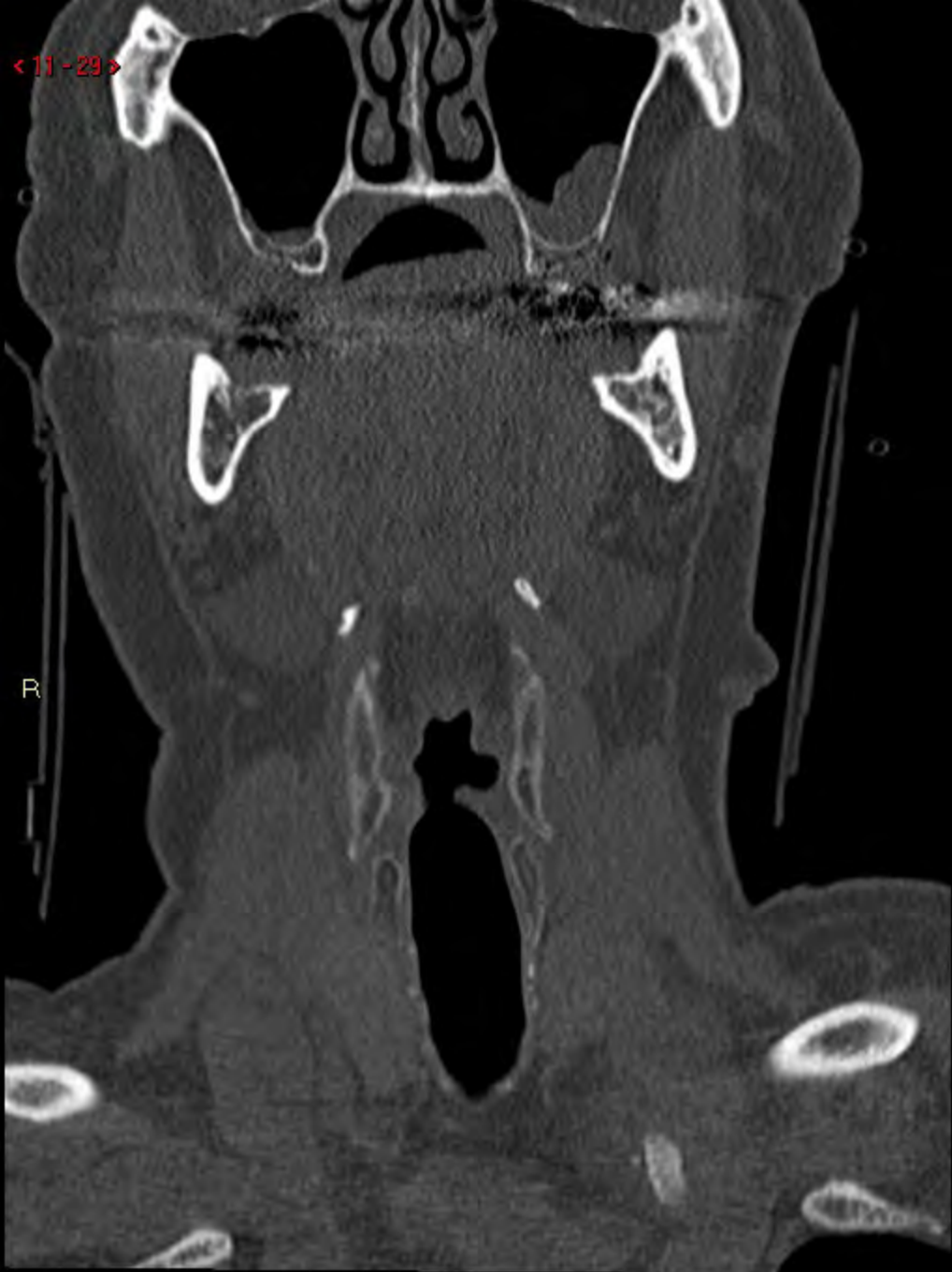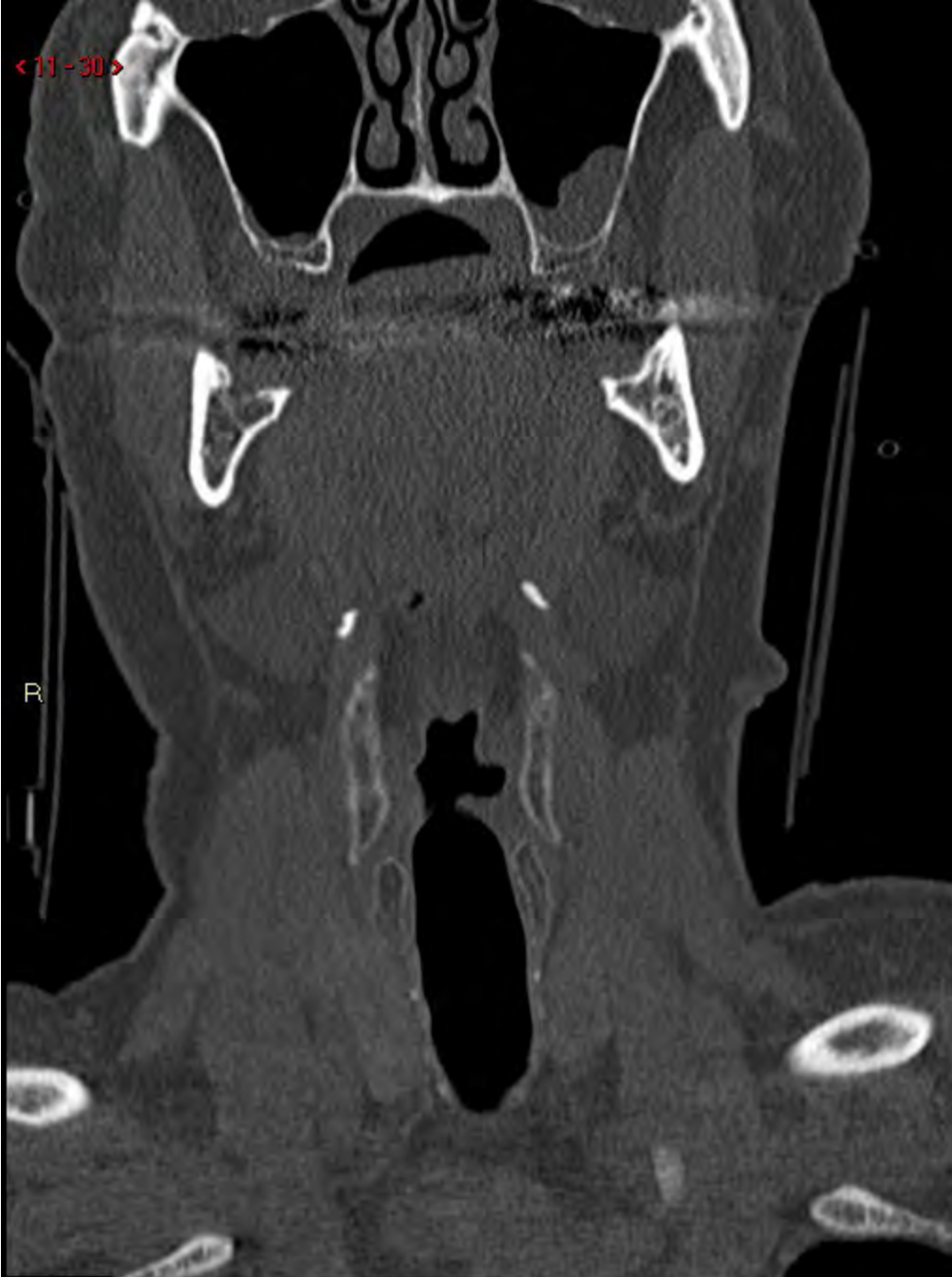< 11 - 27 >



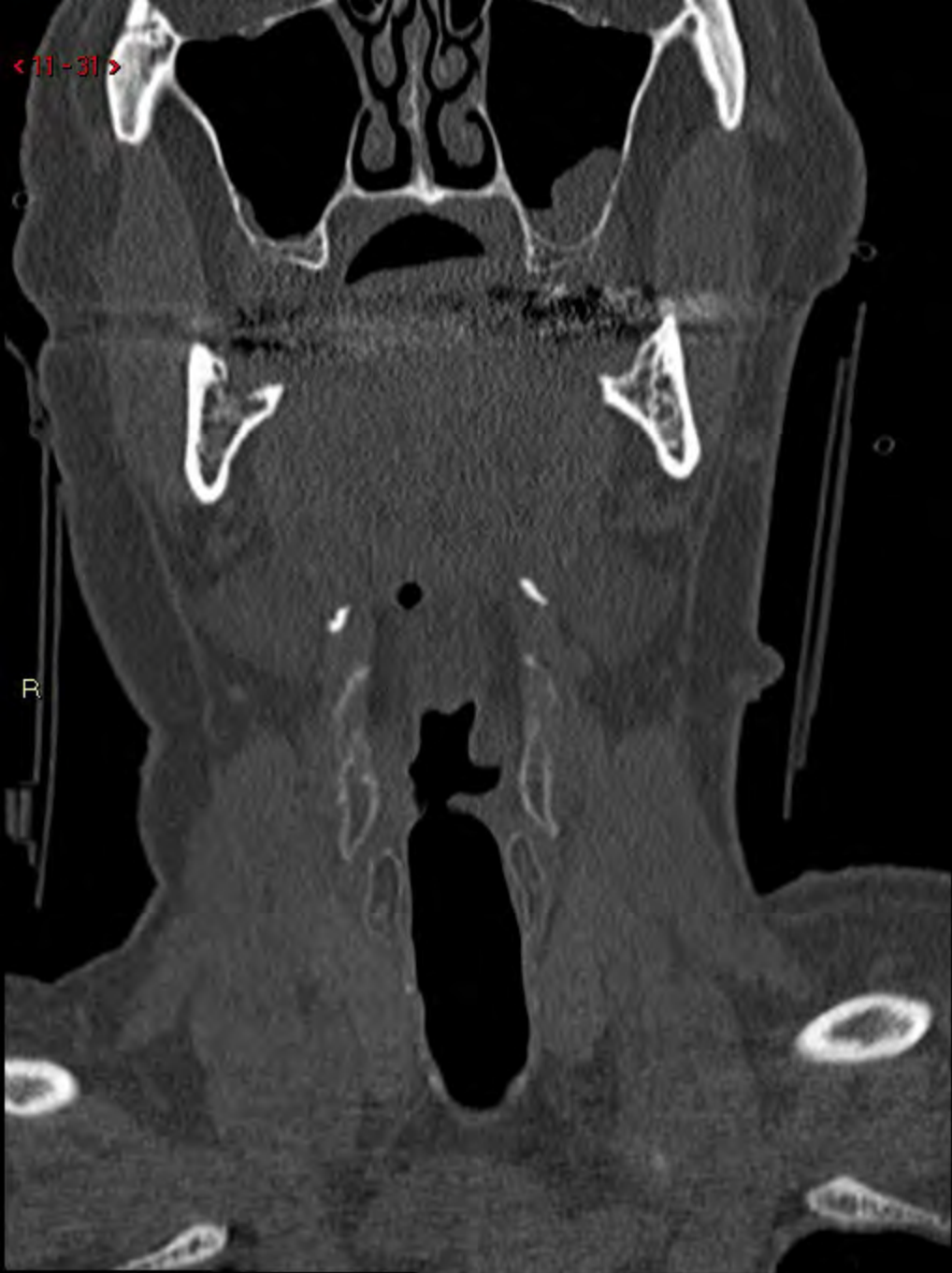< 11 - 28 >





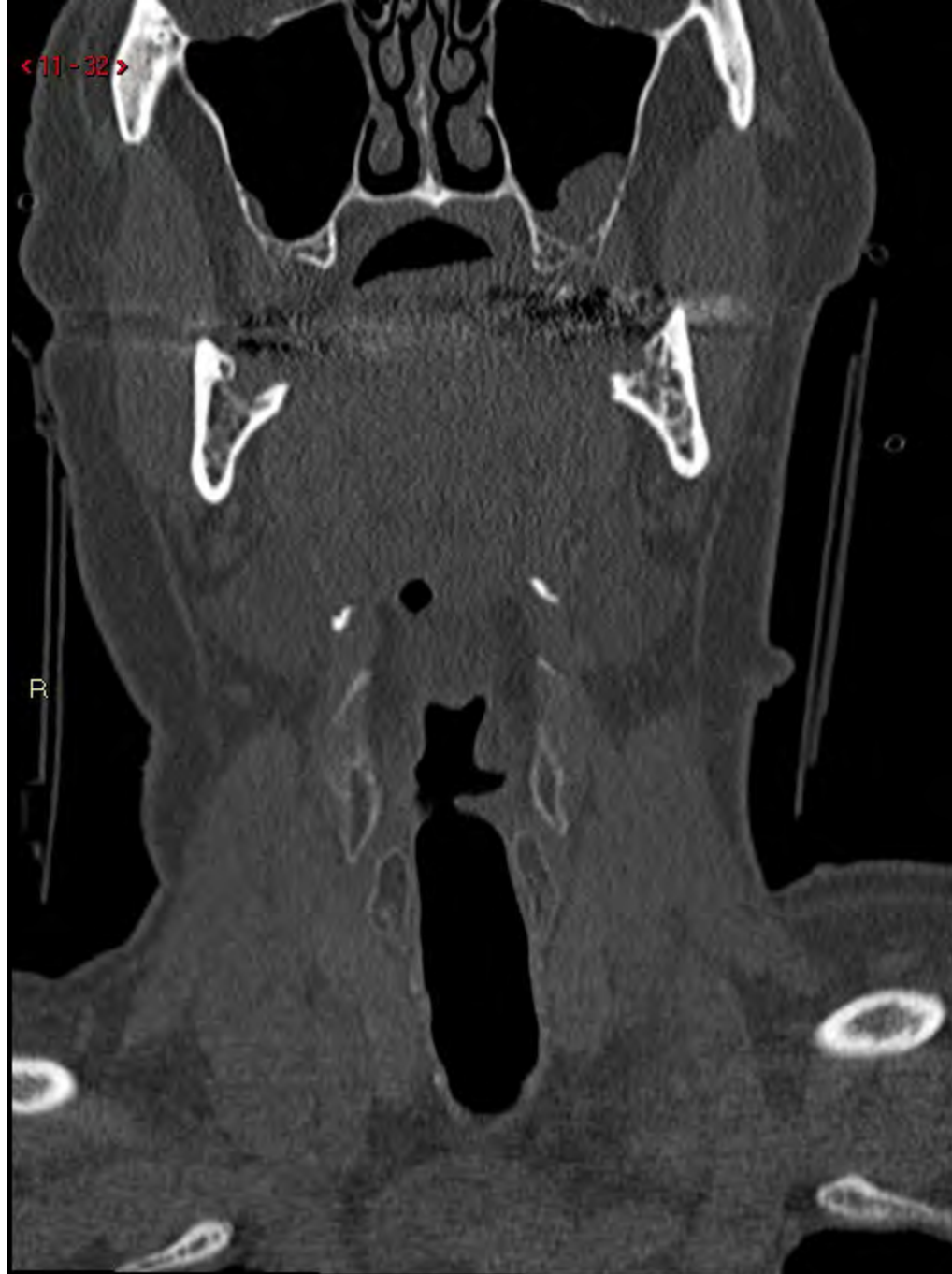

< 11 - 31 >



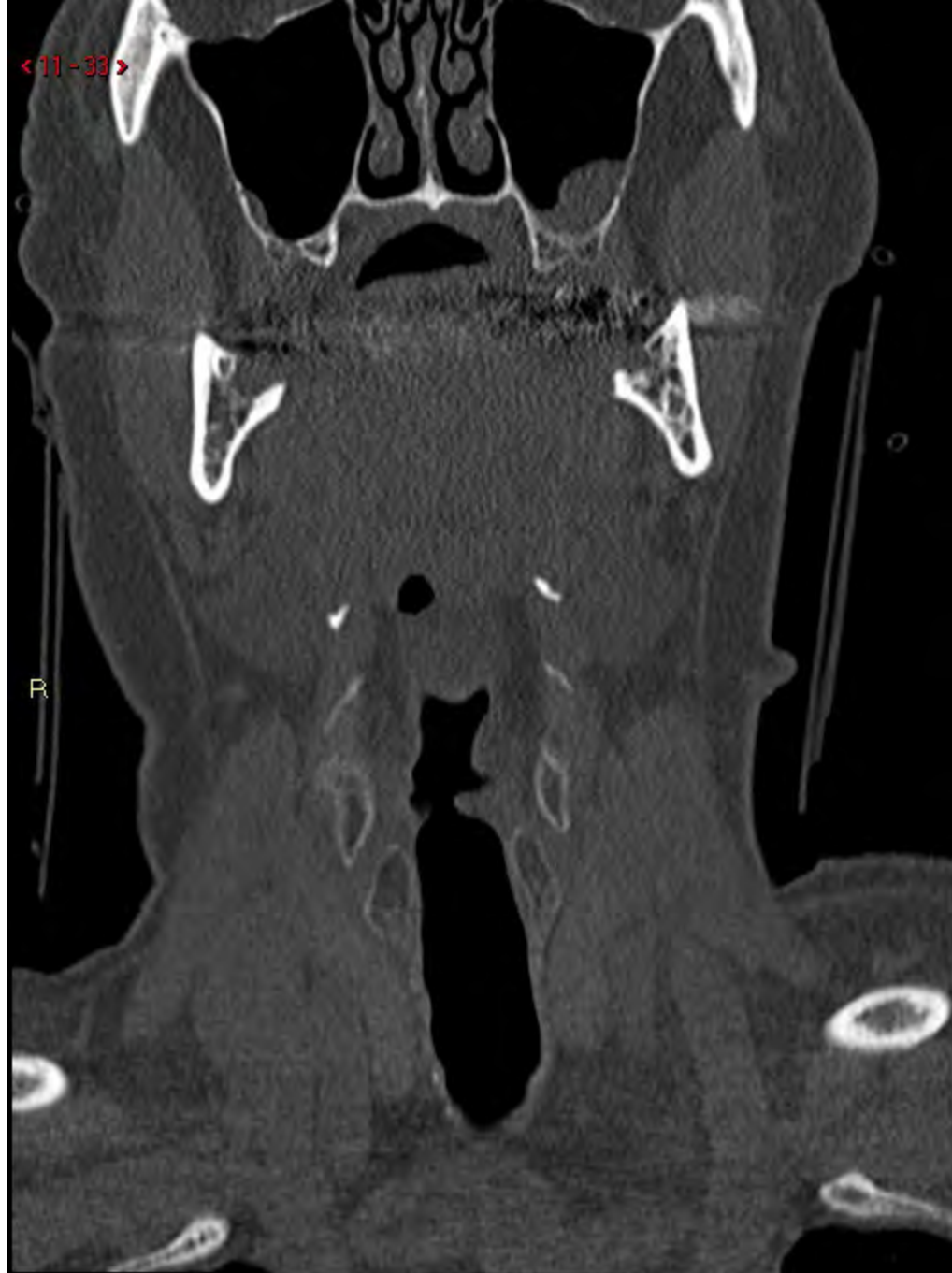<11-32>

R

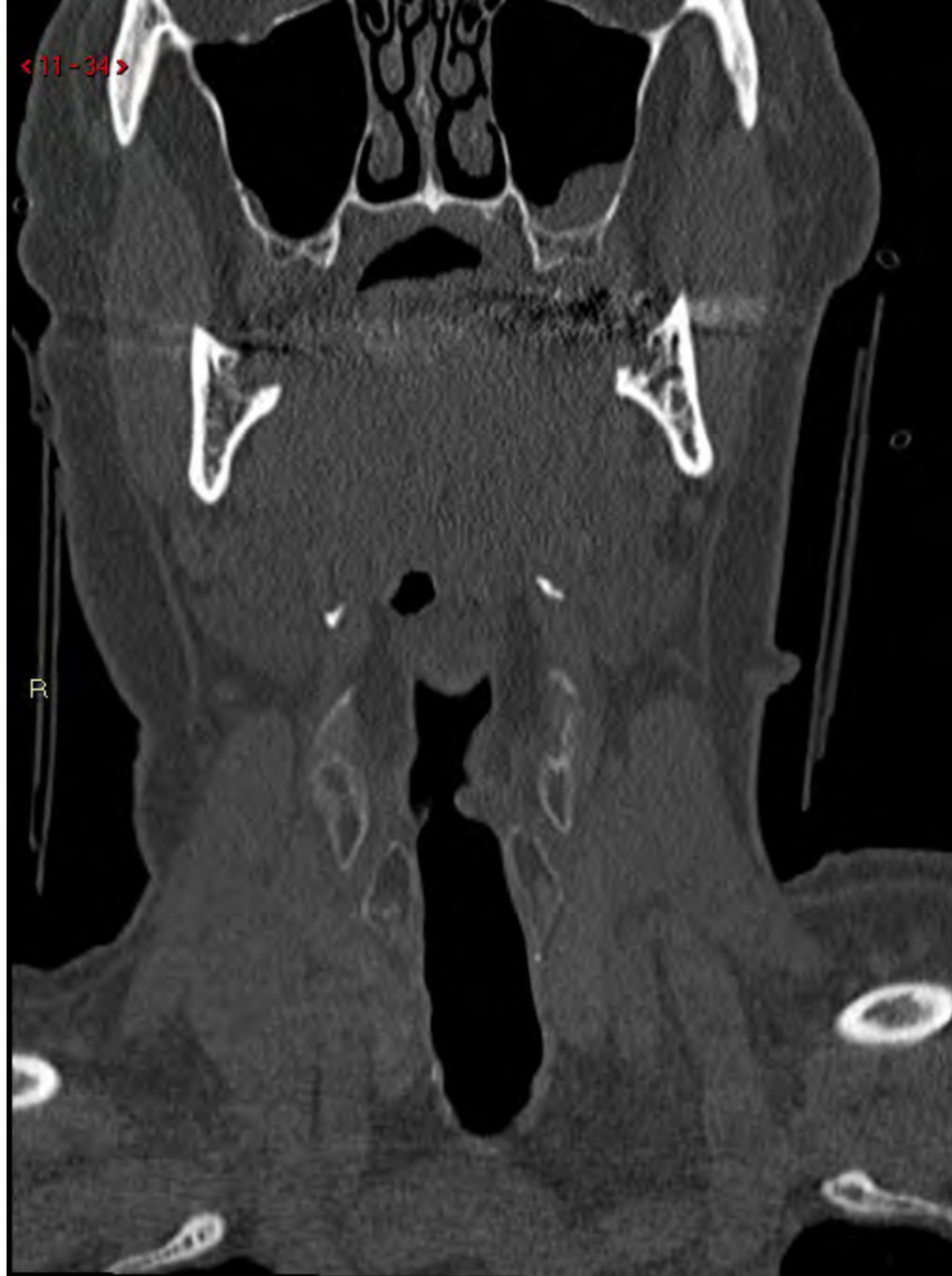

<11-33>

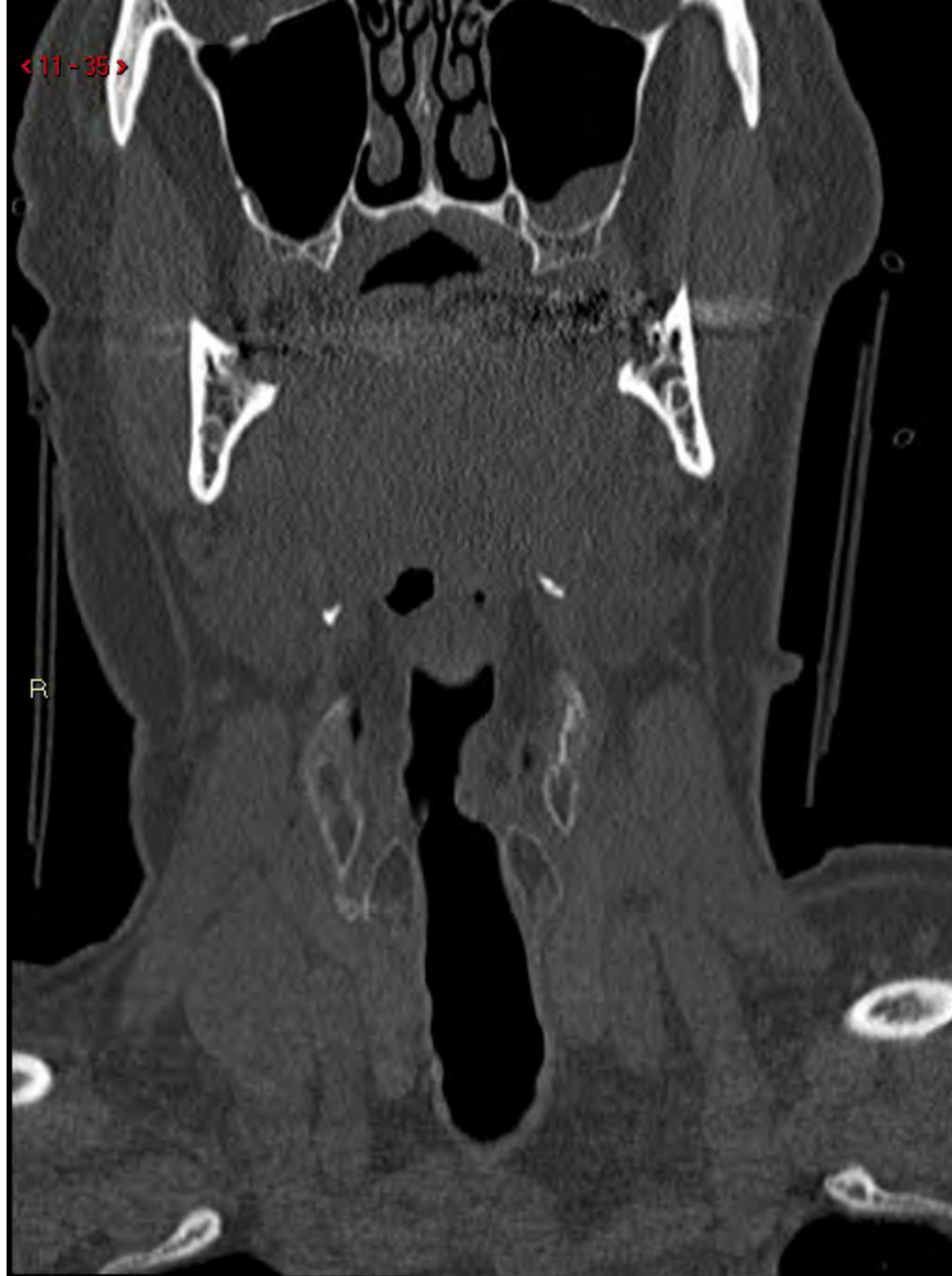R



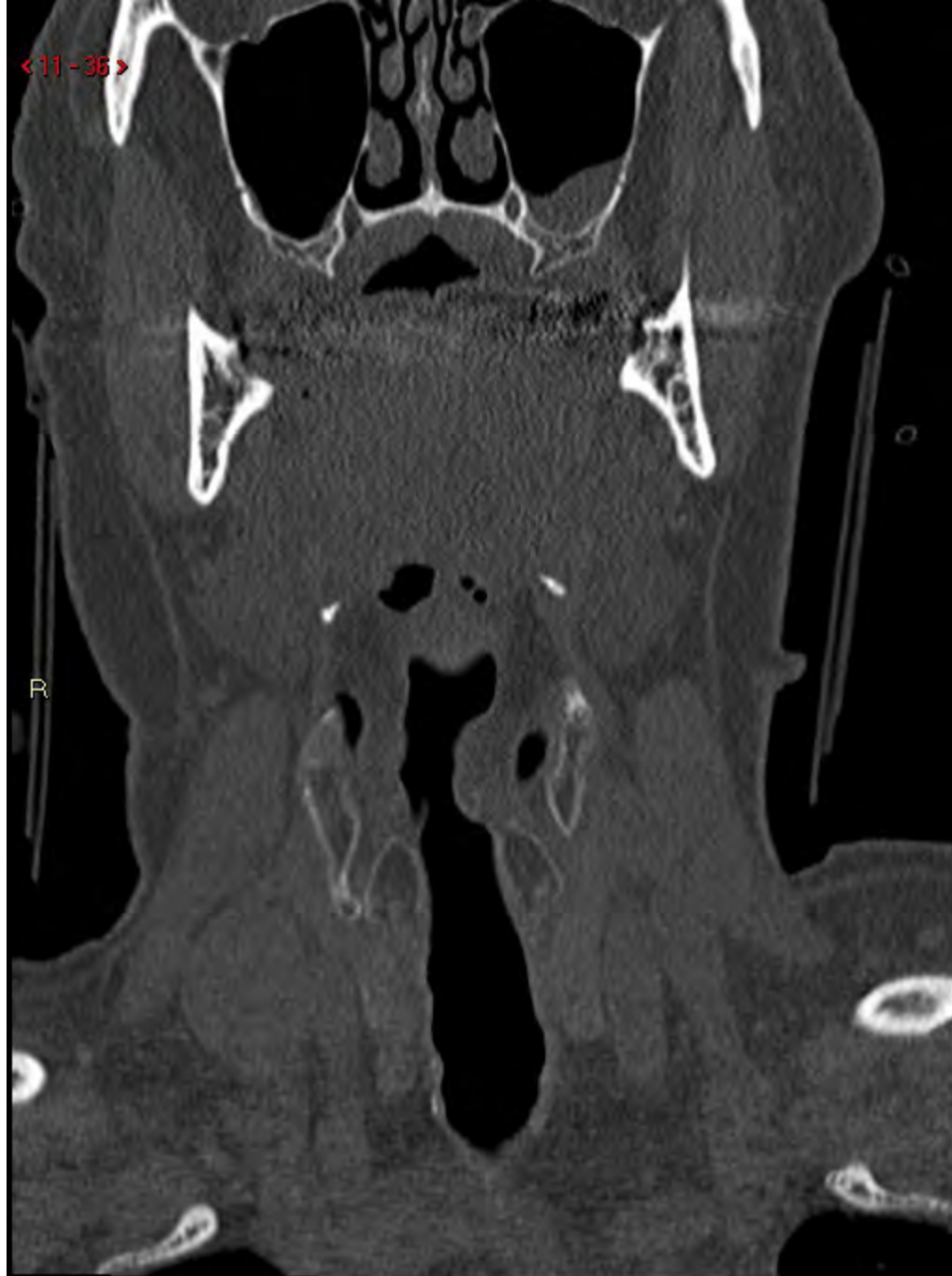<11-34>



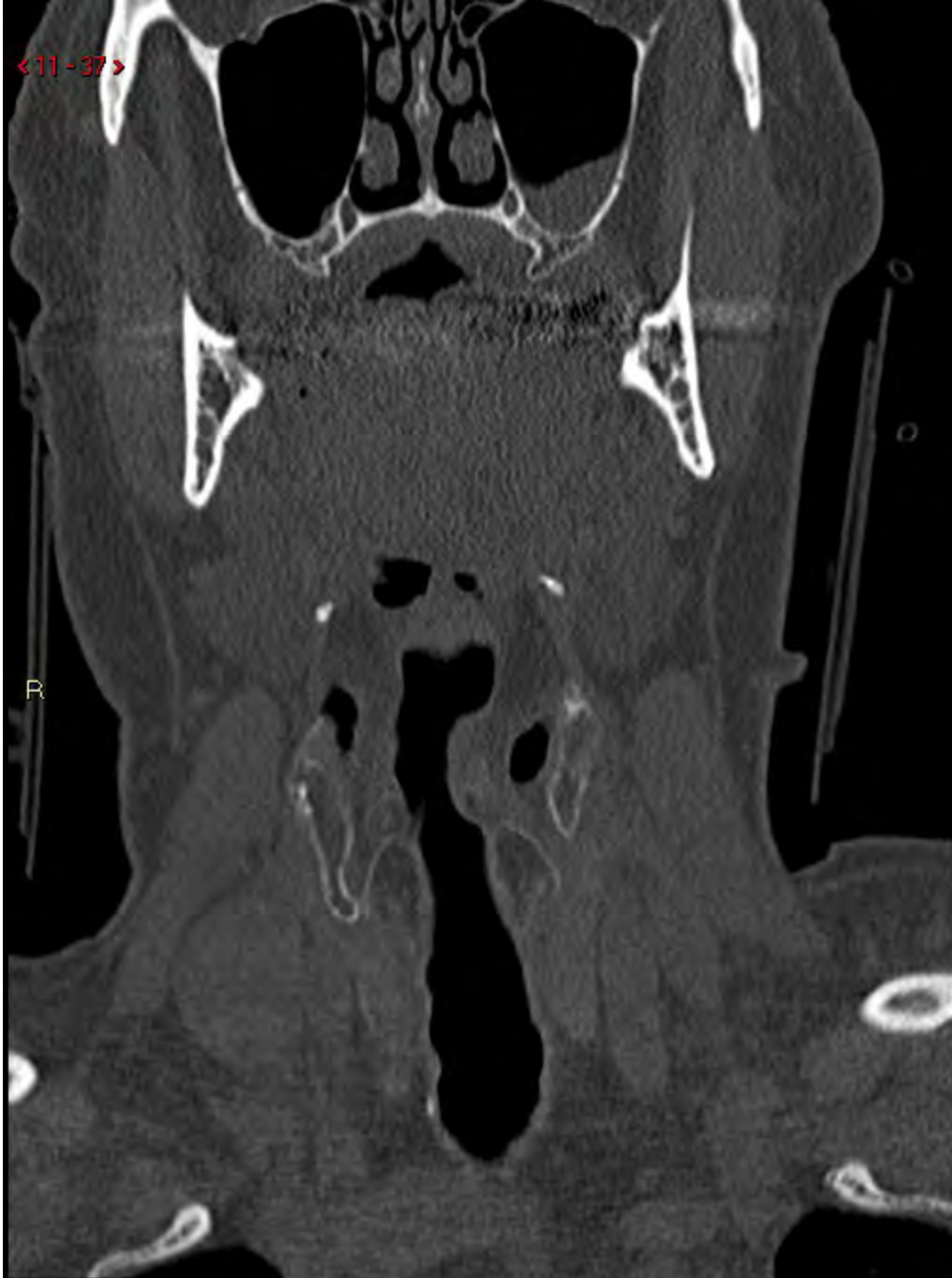< 11 - 35 >



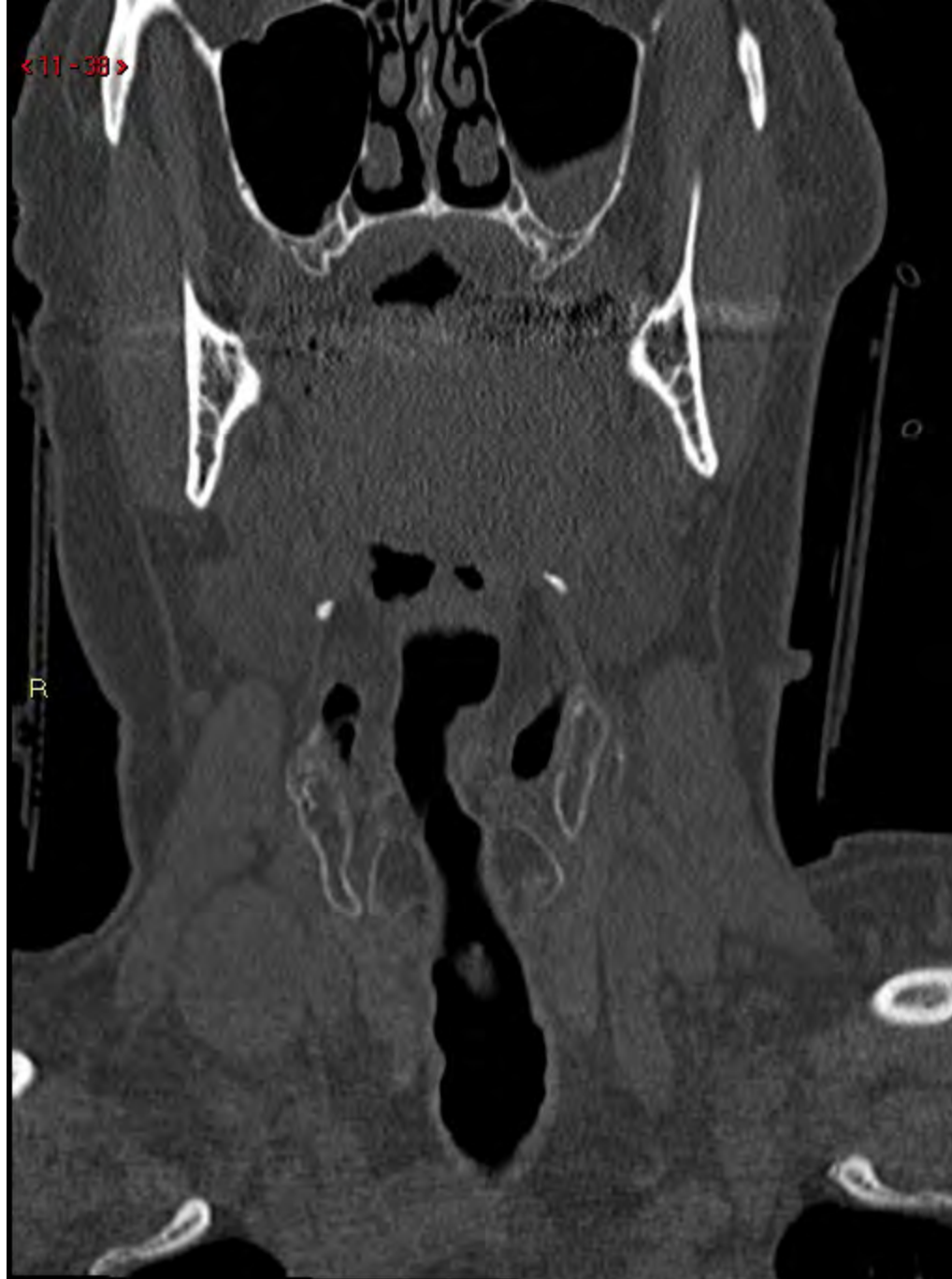<11-36>



<11-37>



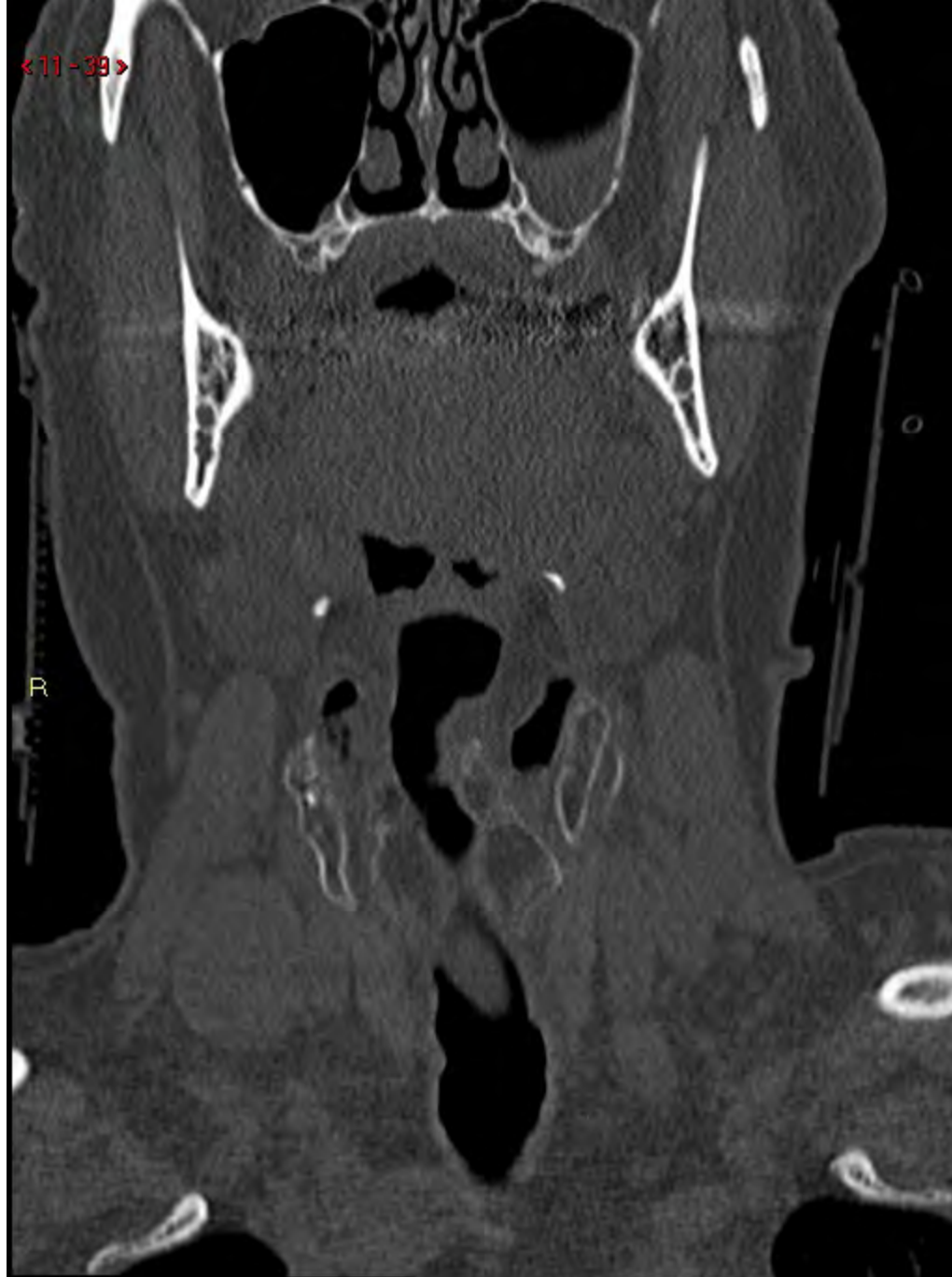<11-38>



R

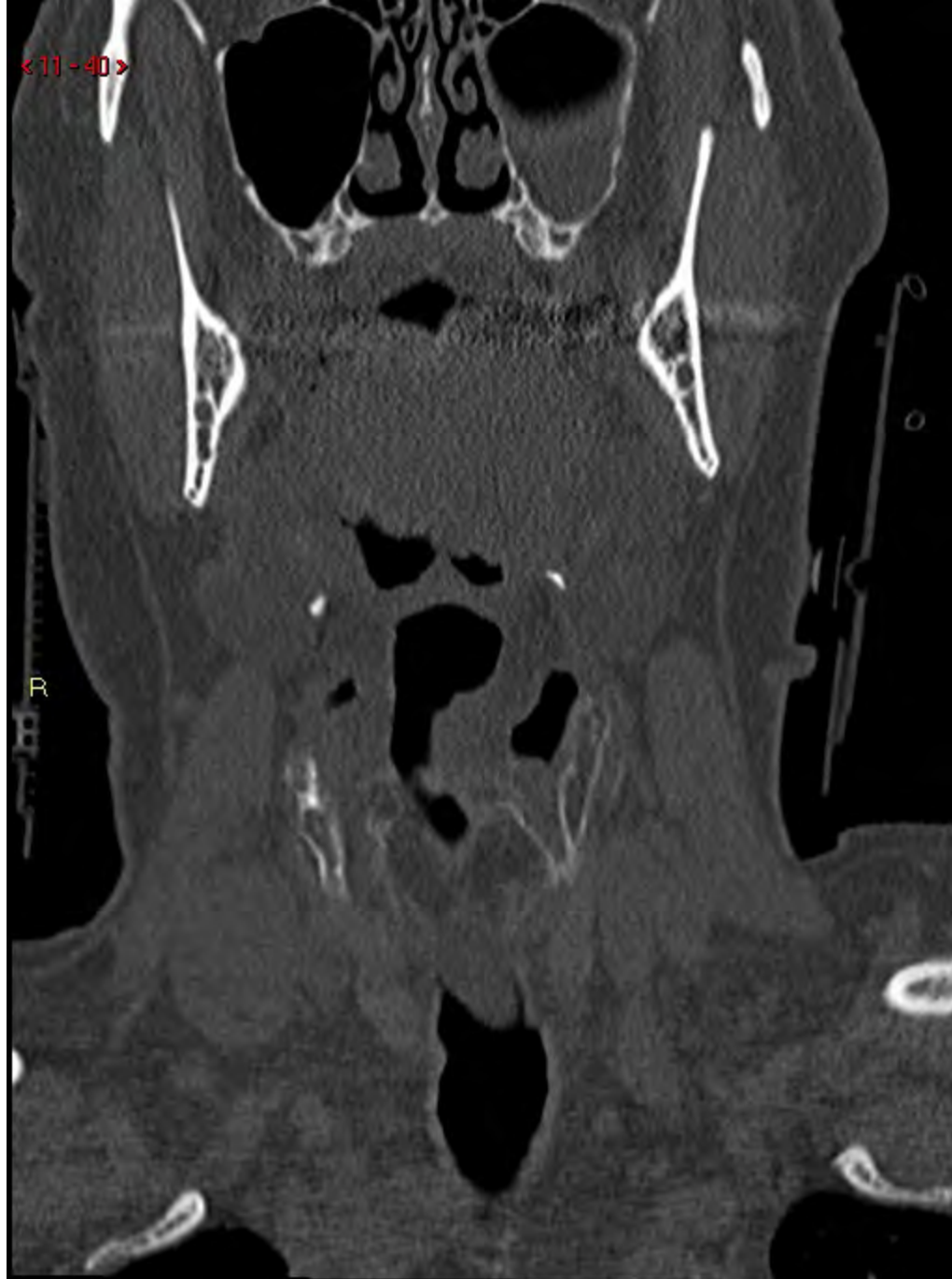<11-39>

R

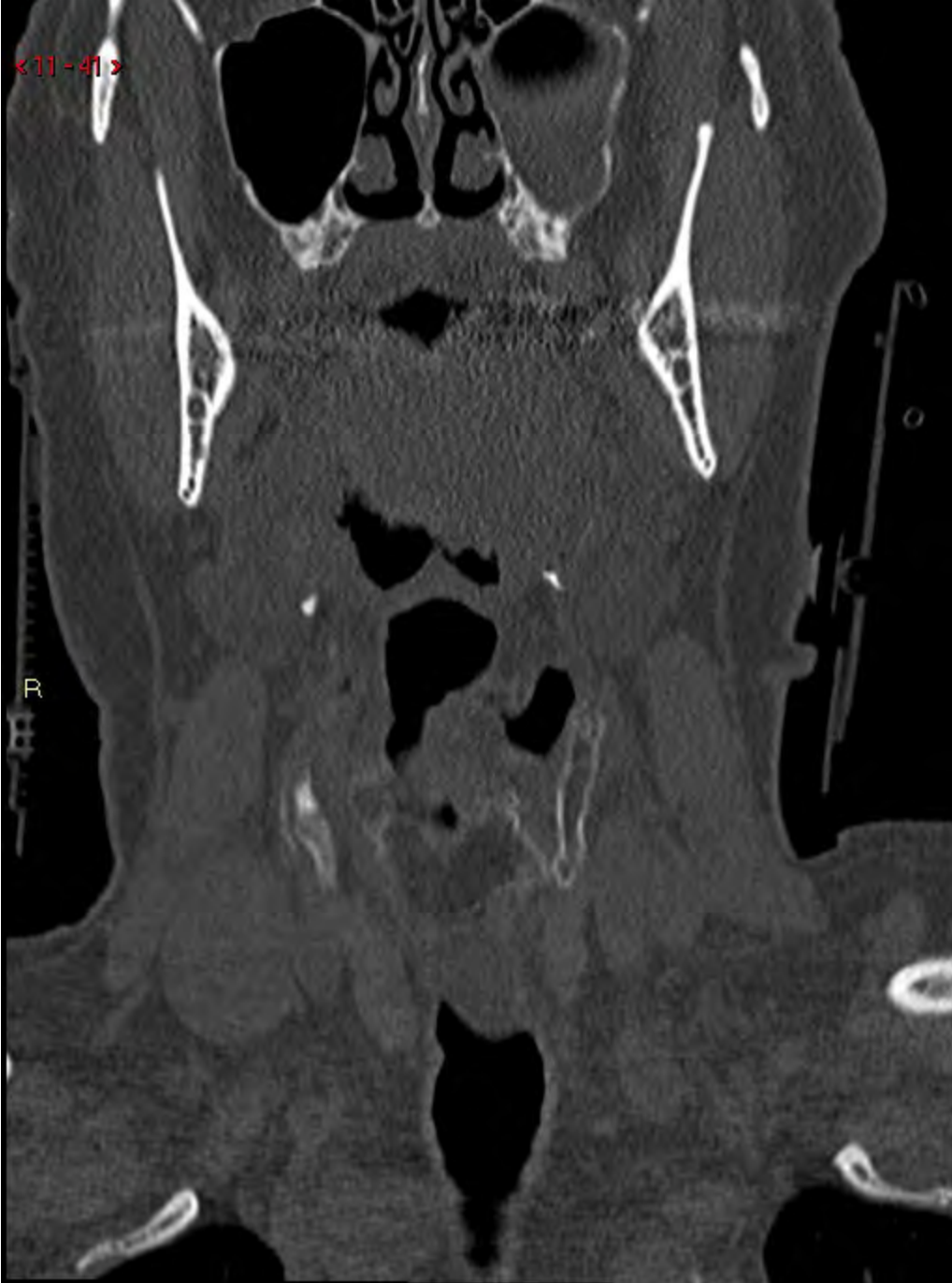

<11-40>

R

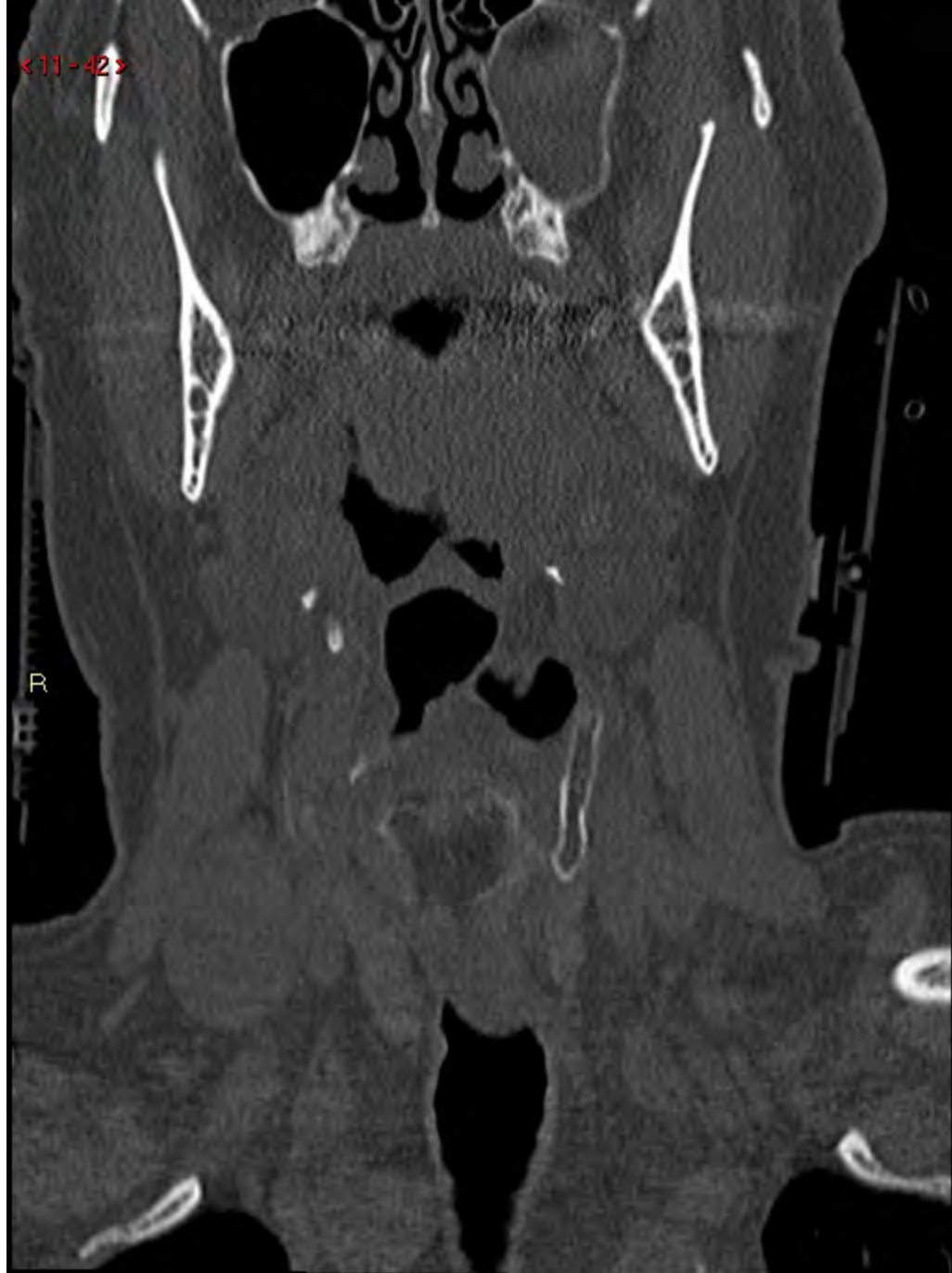

<11-41>

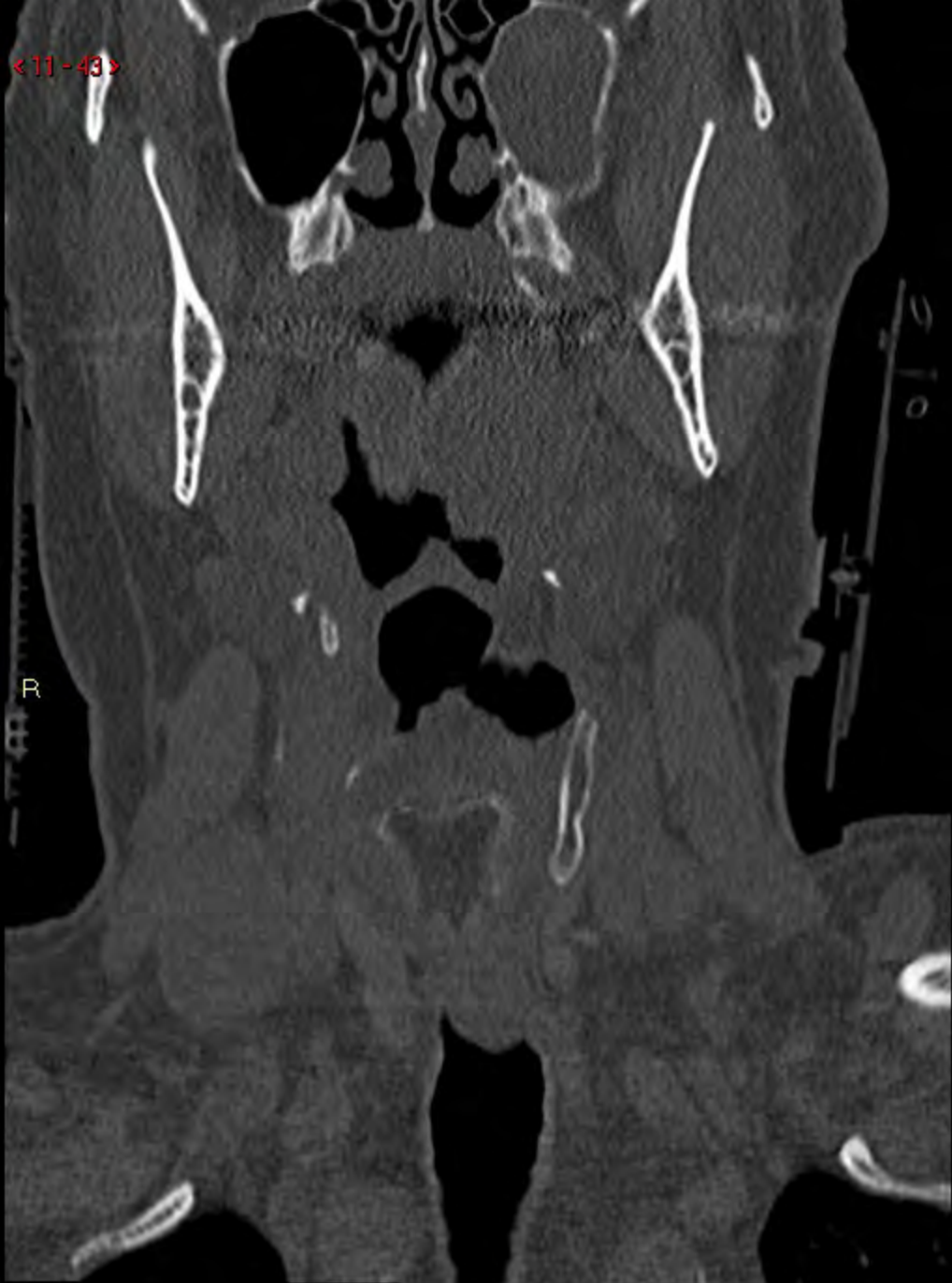

<11-42>

R

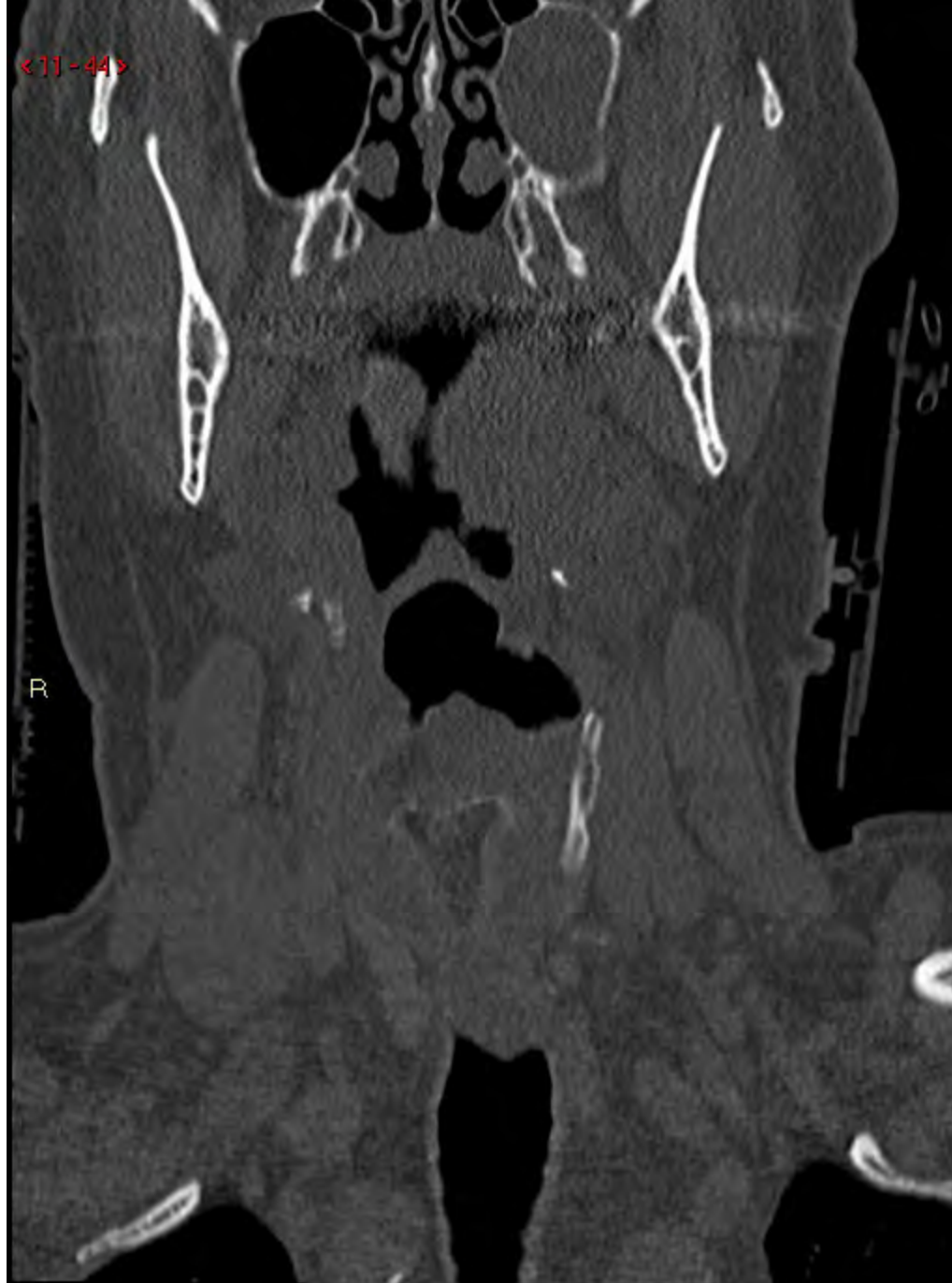

< 11 - 43 >



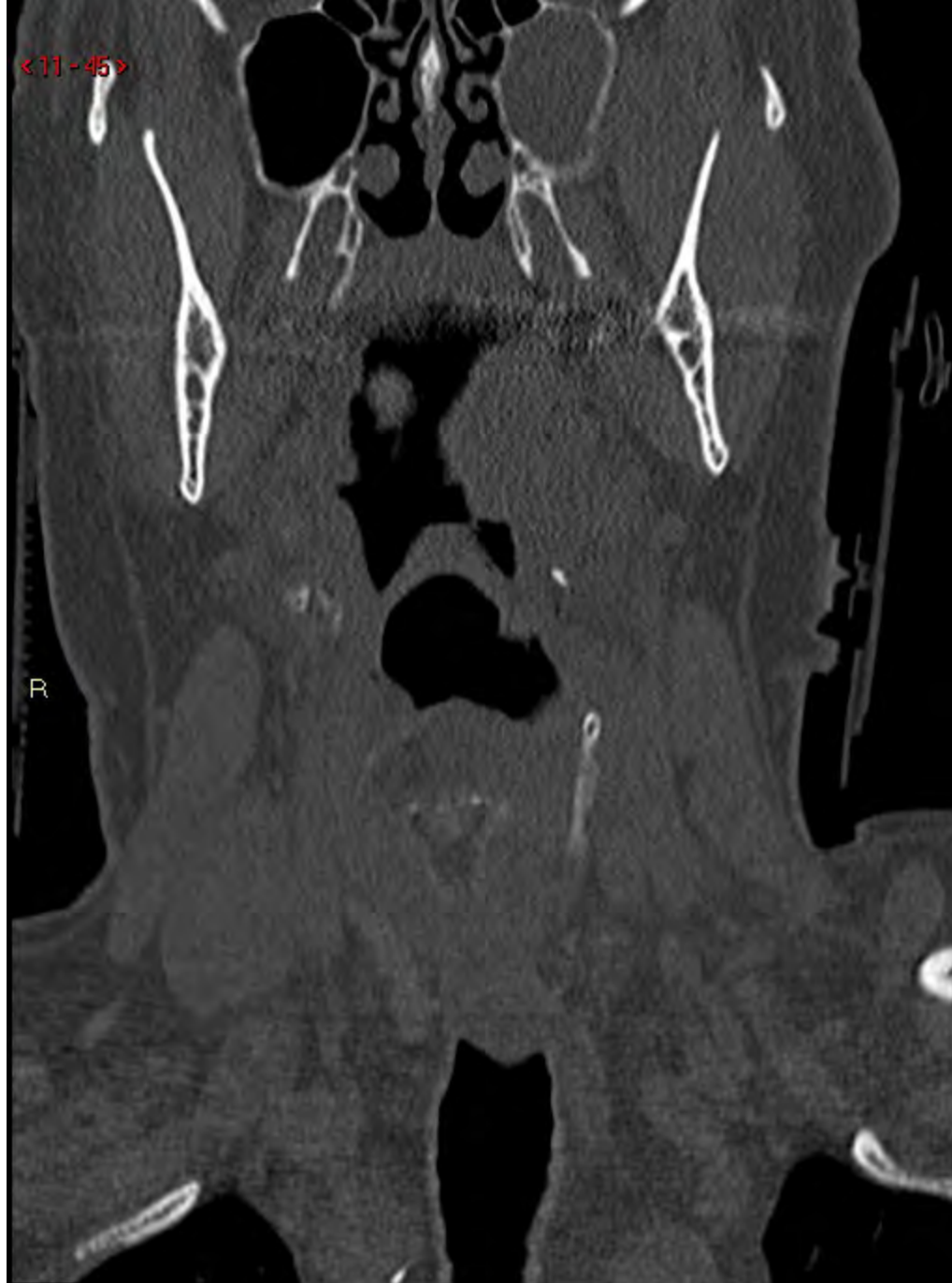< 11 - 44 >

R



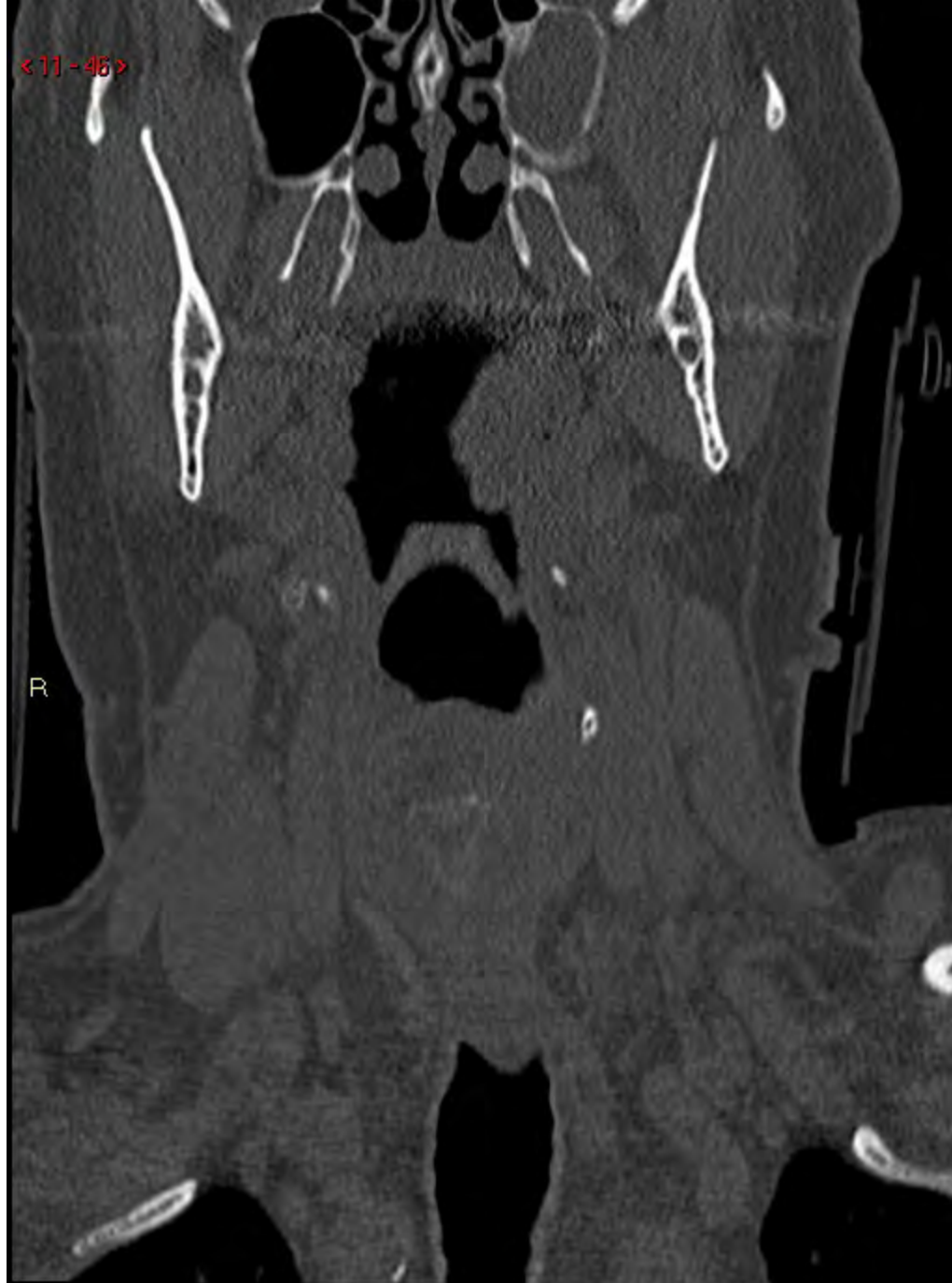<11-45>

R



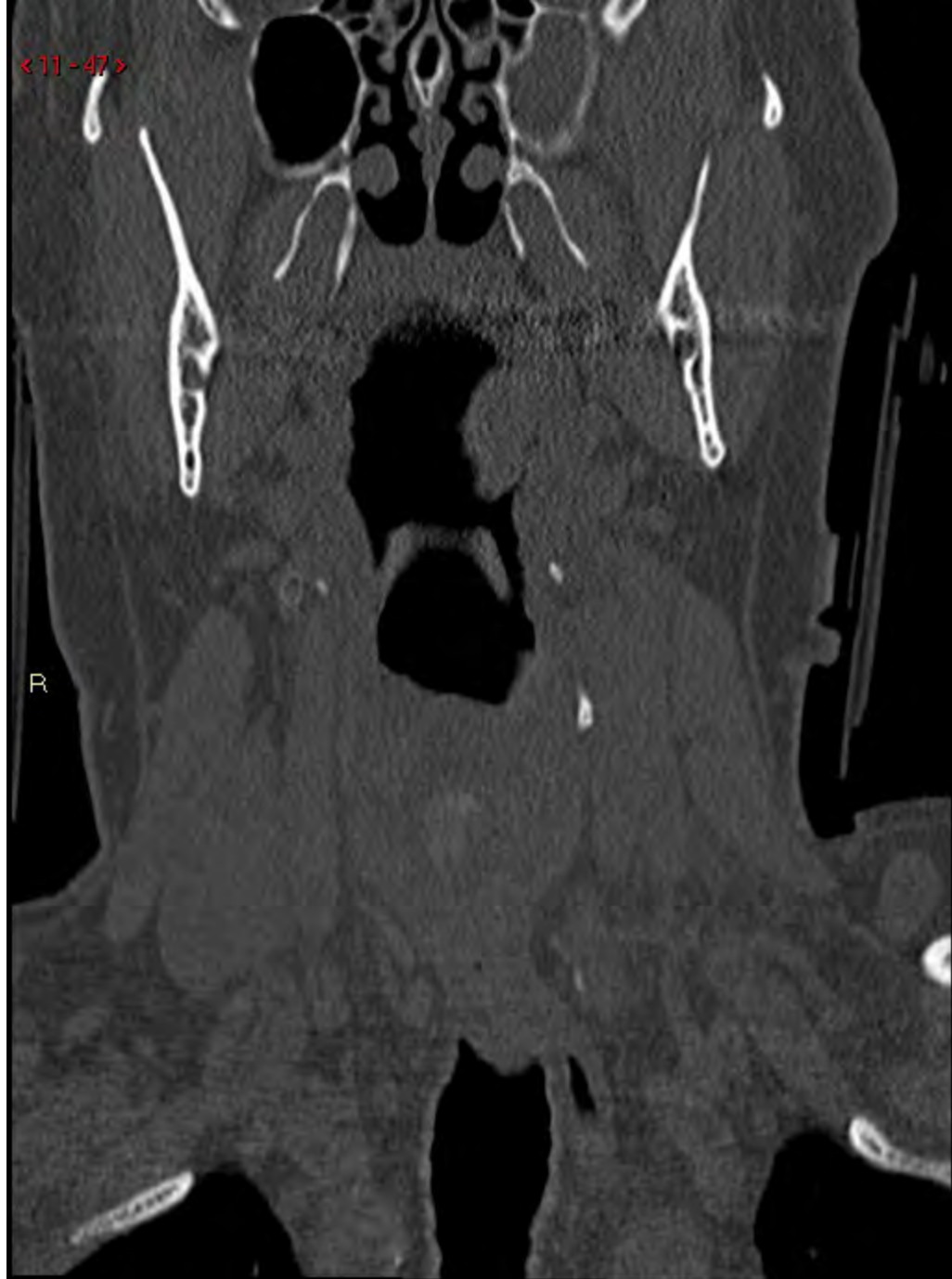
<11-46>

R



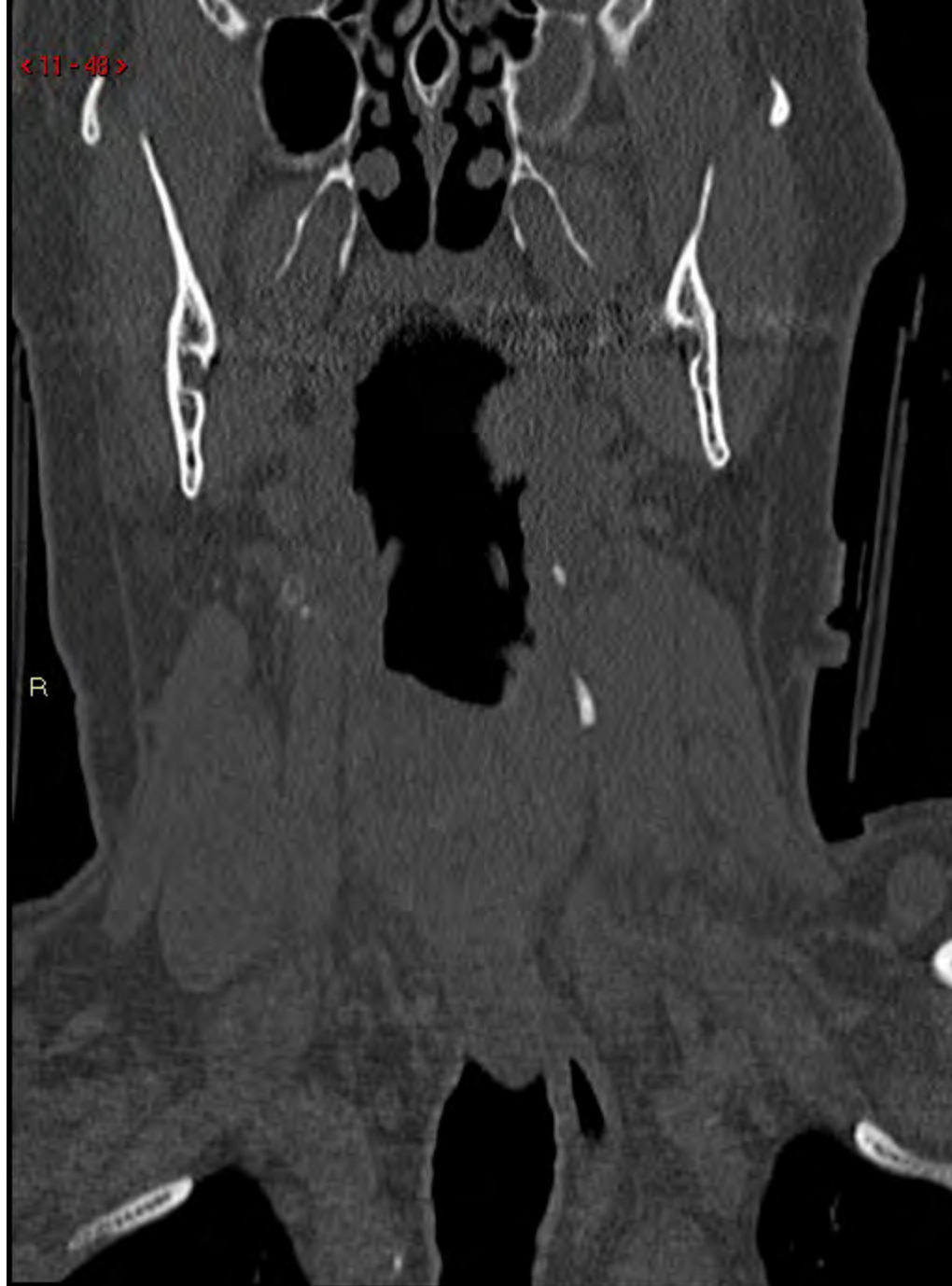
<11-47>

R



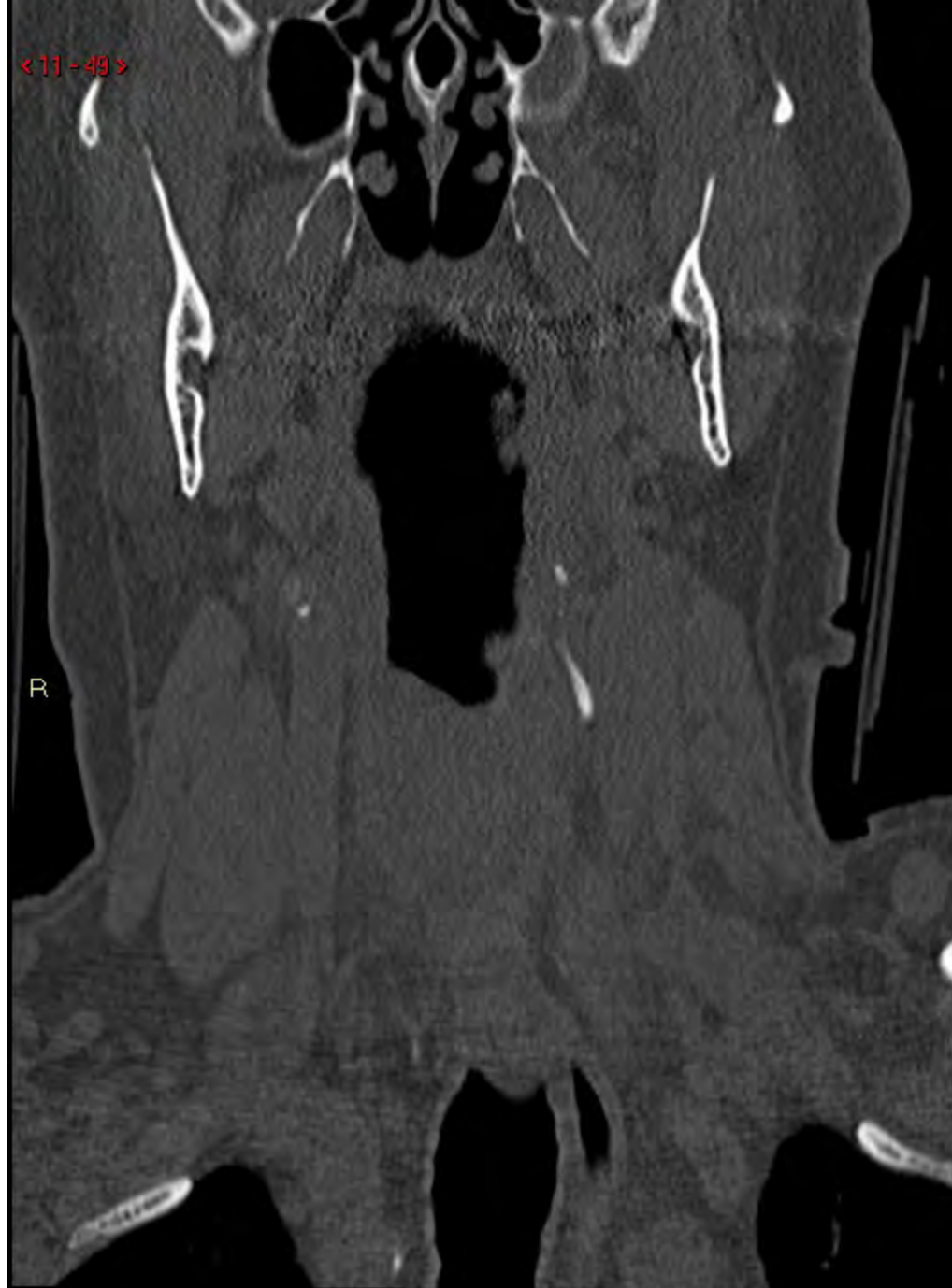< 11 - 48 >

R



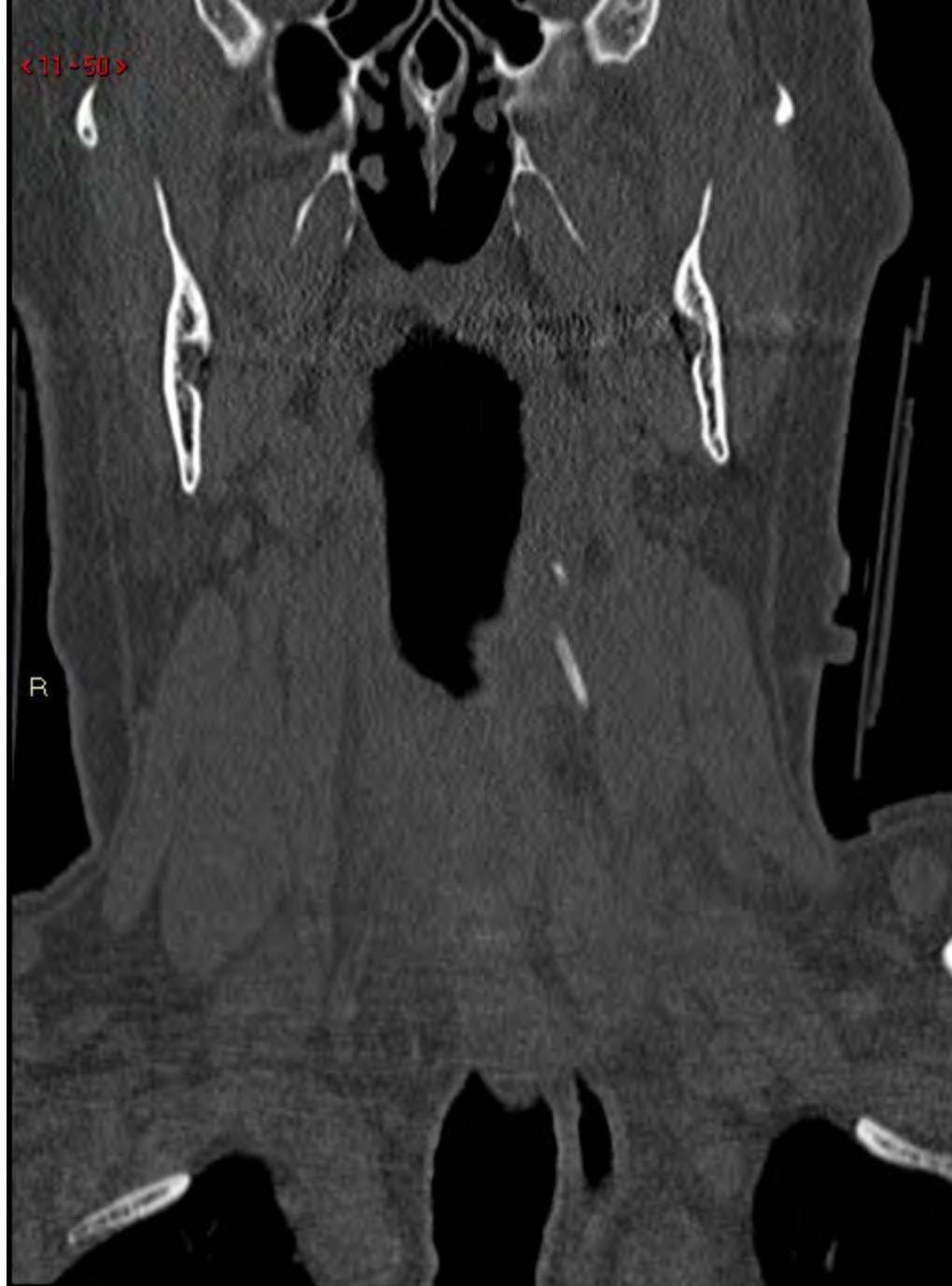
< 11 - 49 >

R



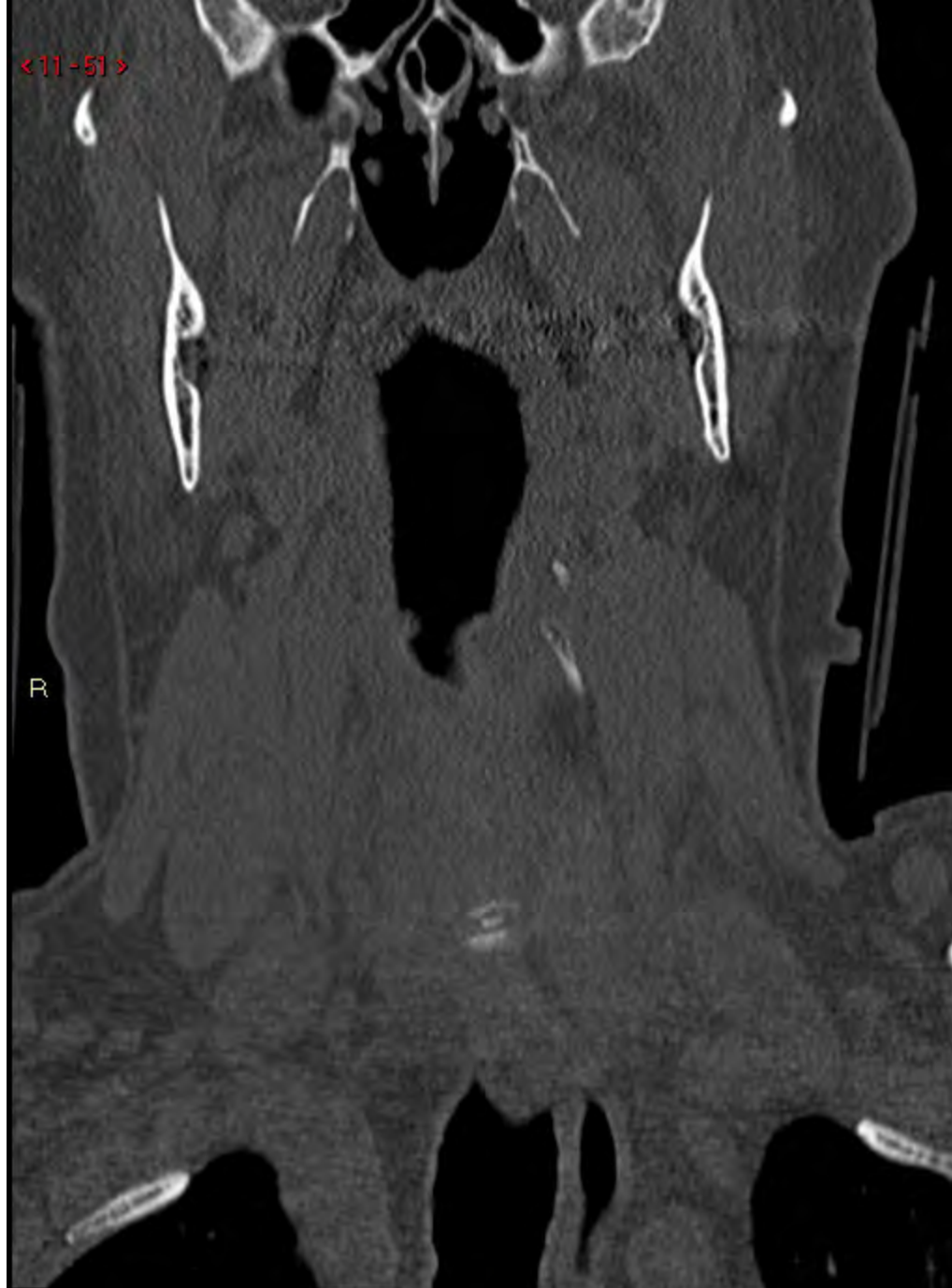<11-50>

R



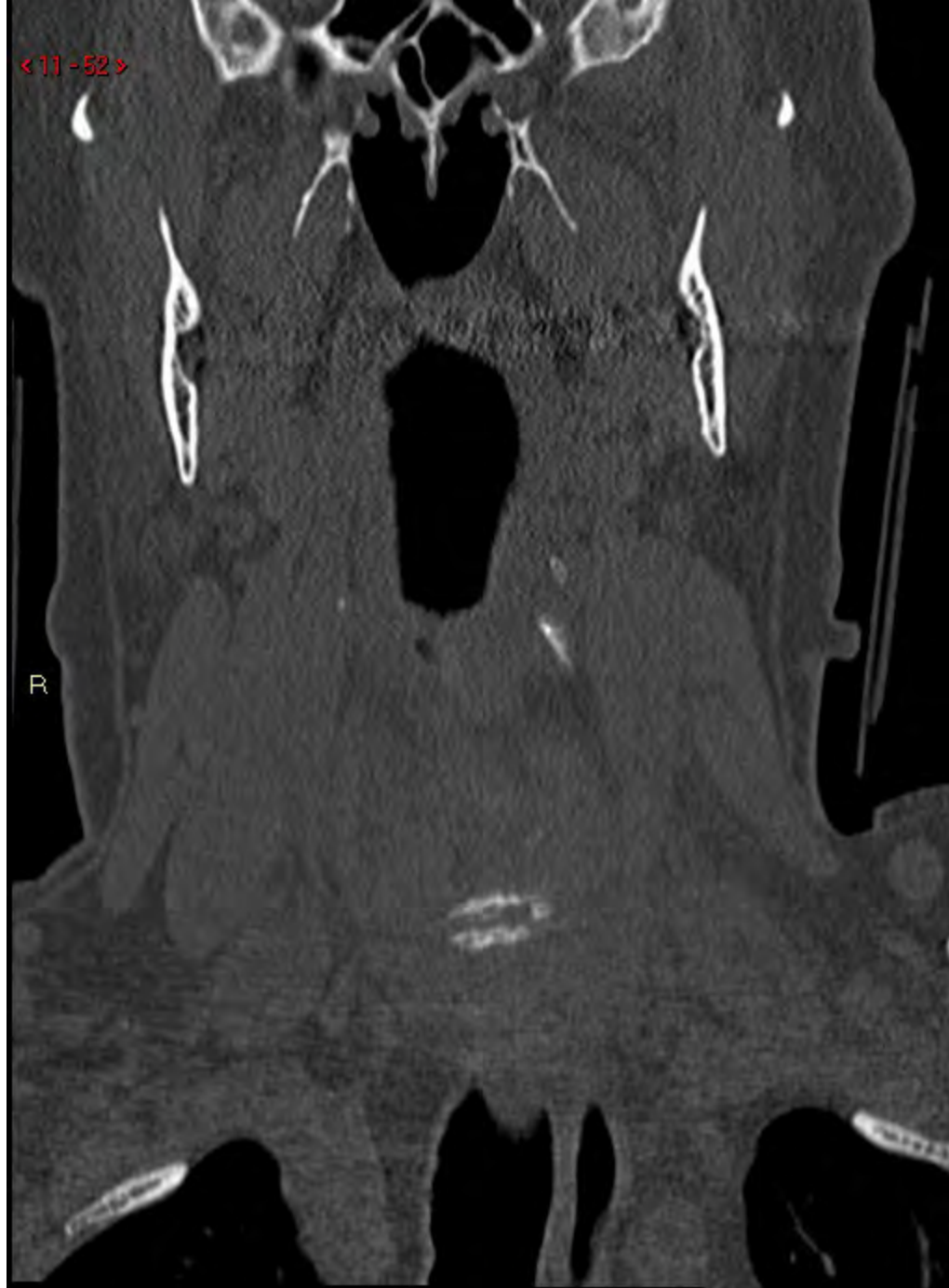<11-51>

R



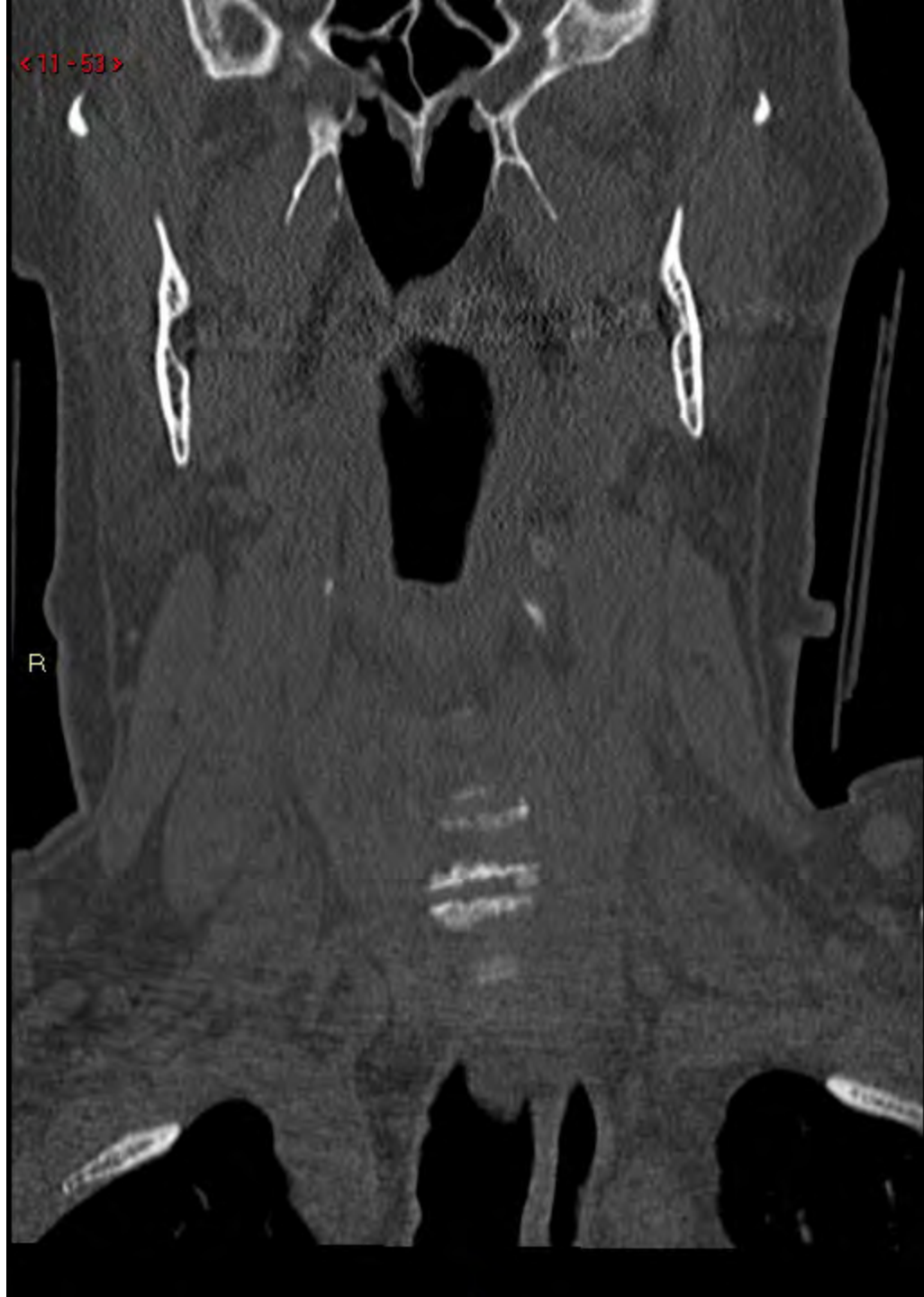
< 11 - 52 >

R



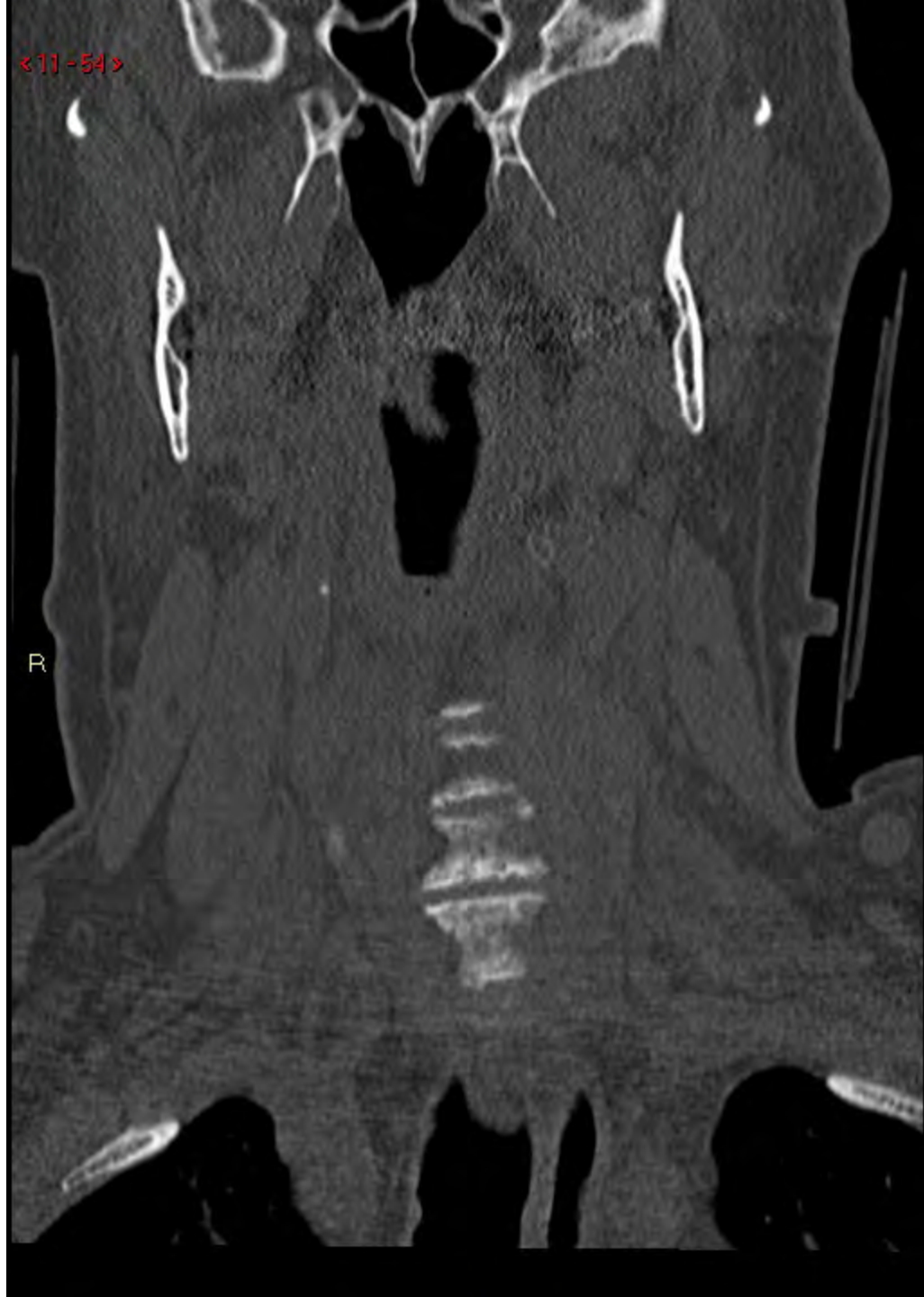
<11-53>

R



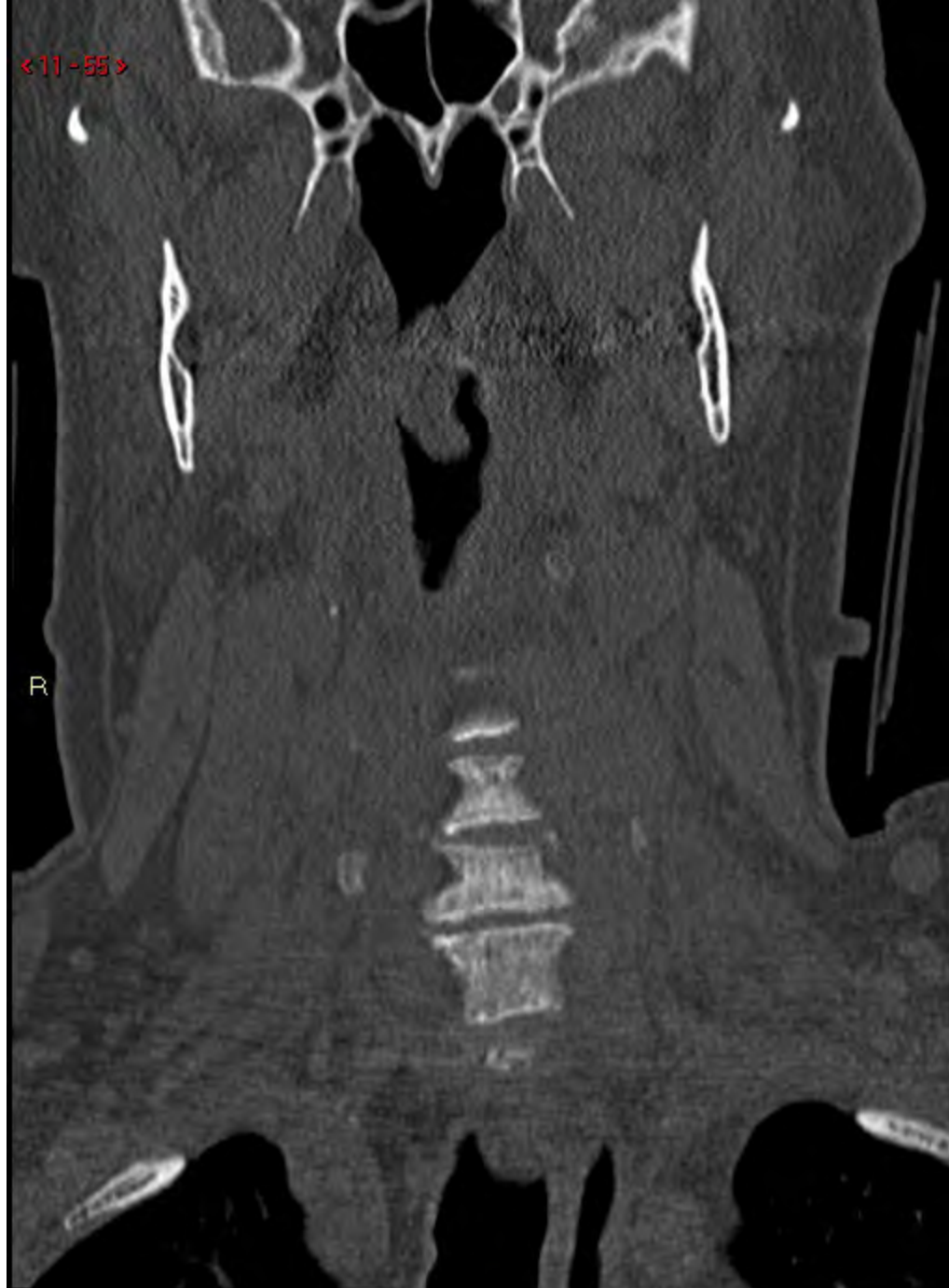
<11-54>

R

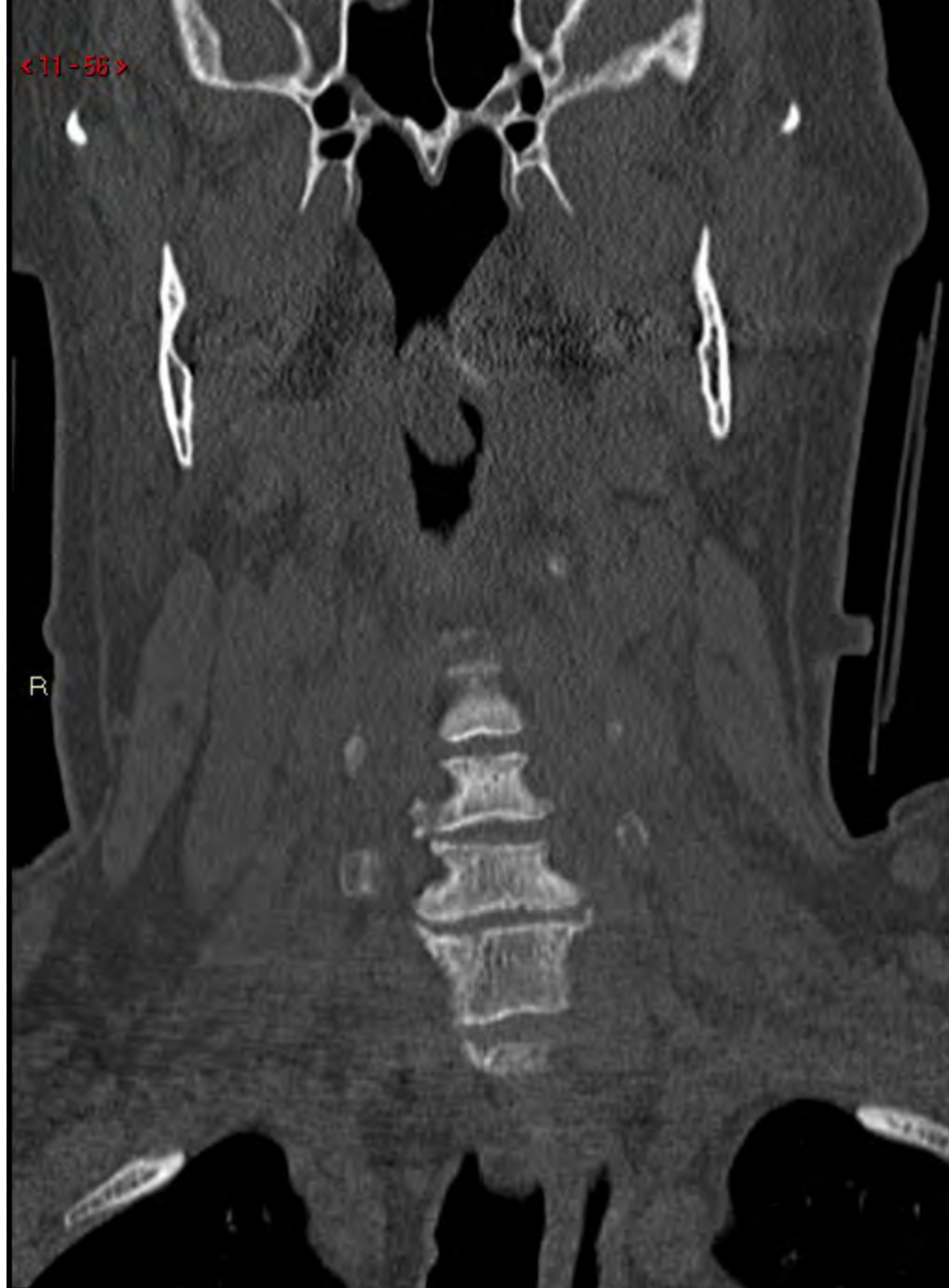

<11-55>

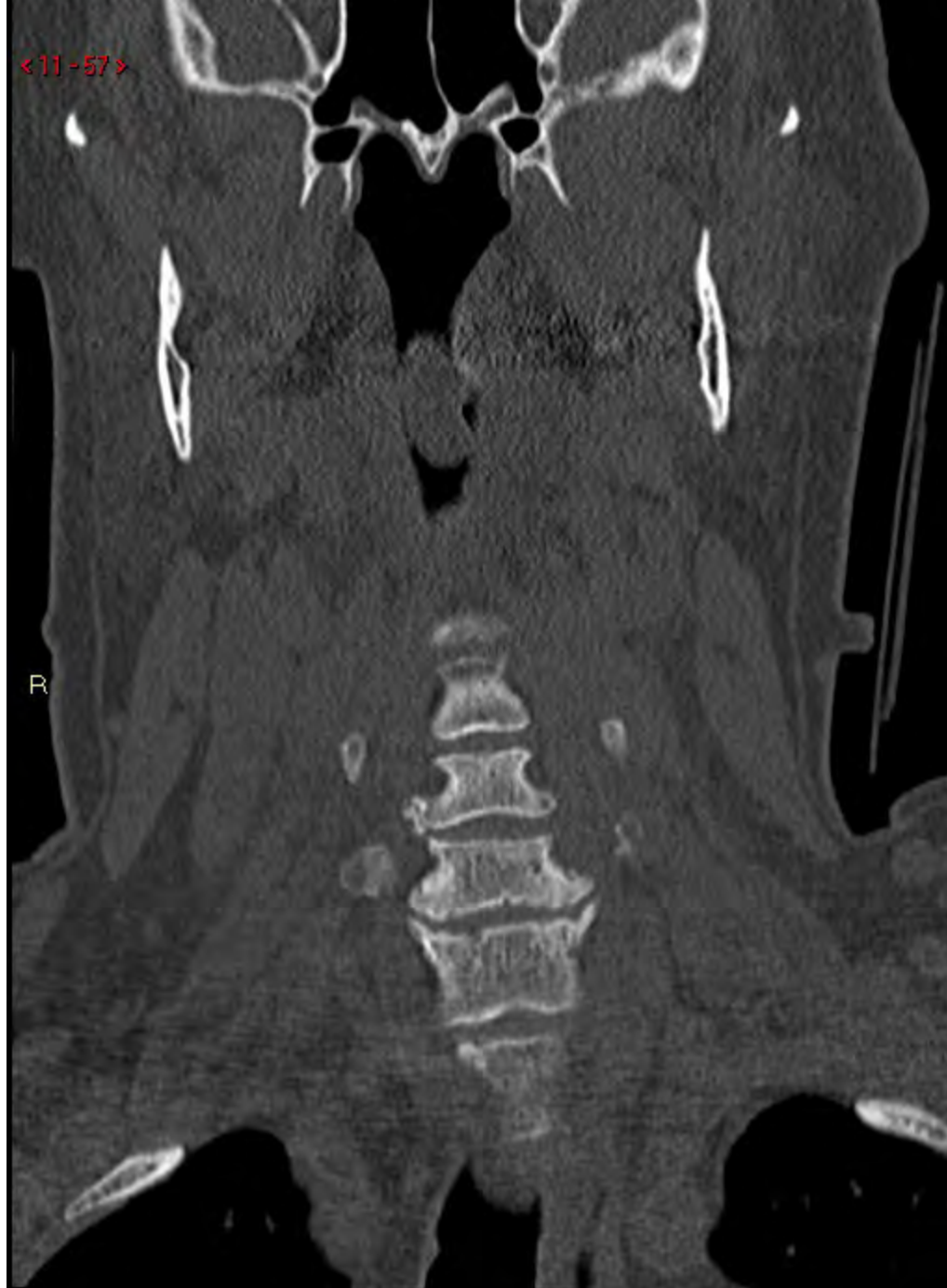R



<11-58>

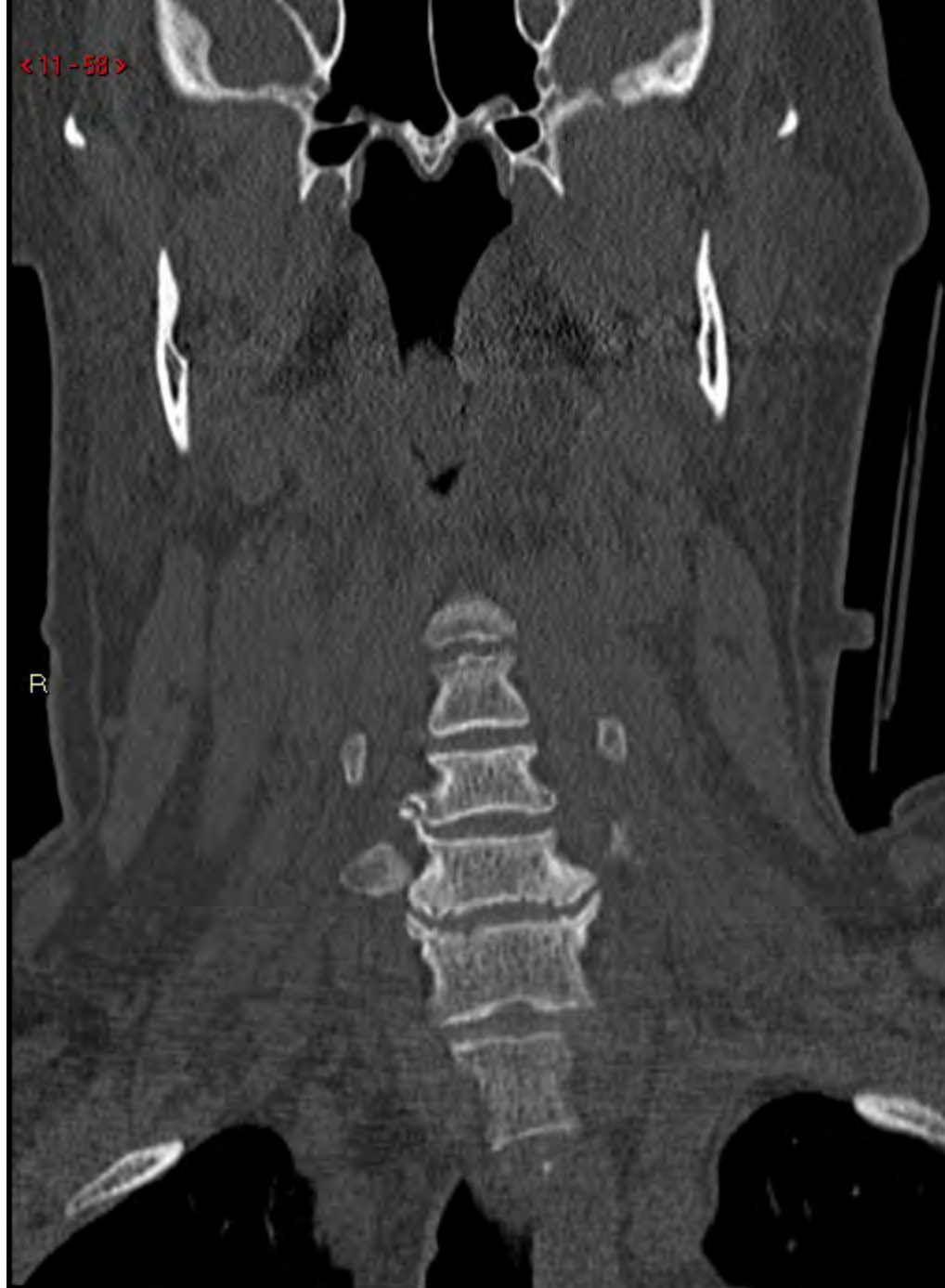

<11-57>



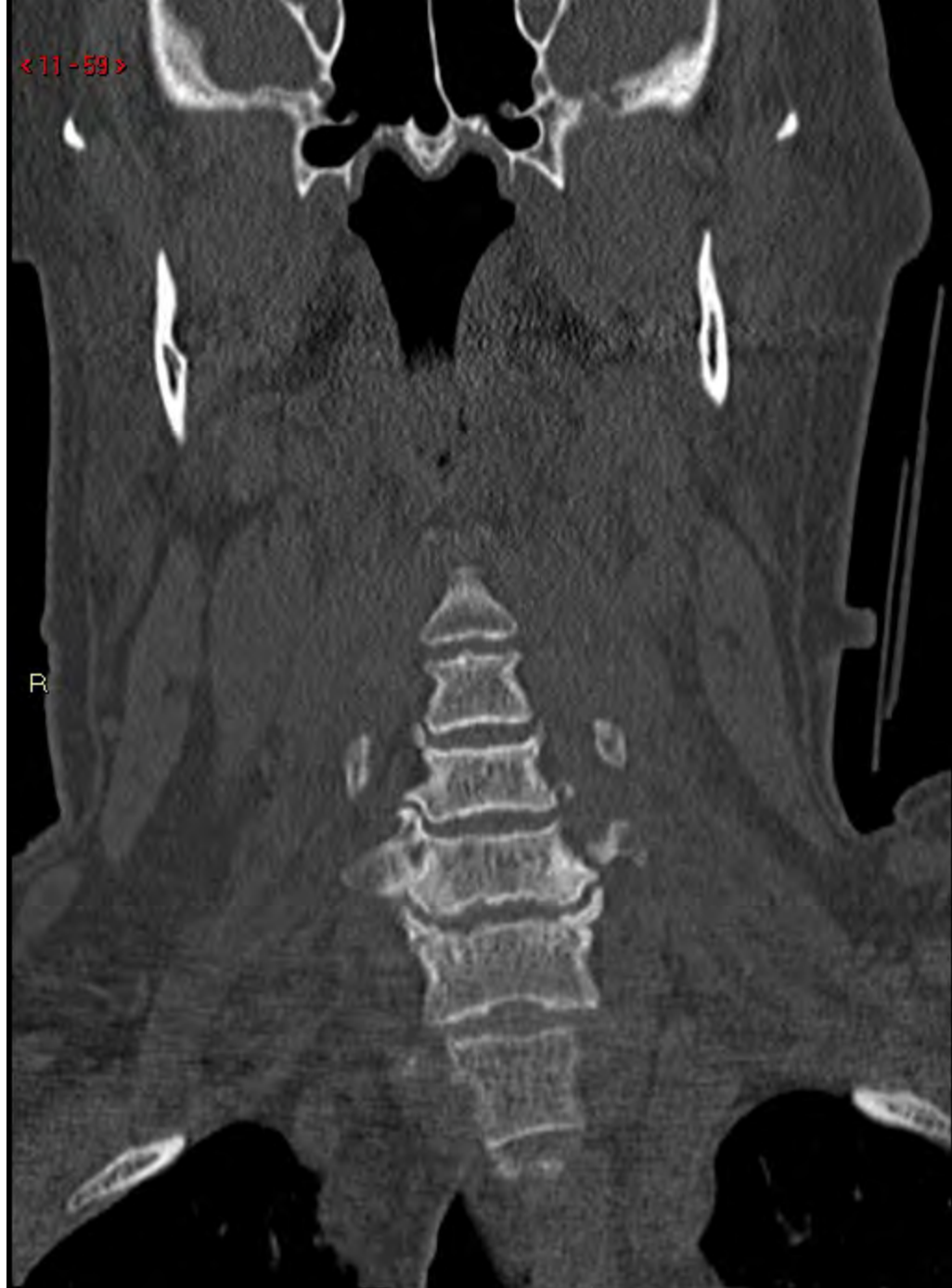< 11 - 58 >

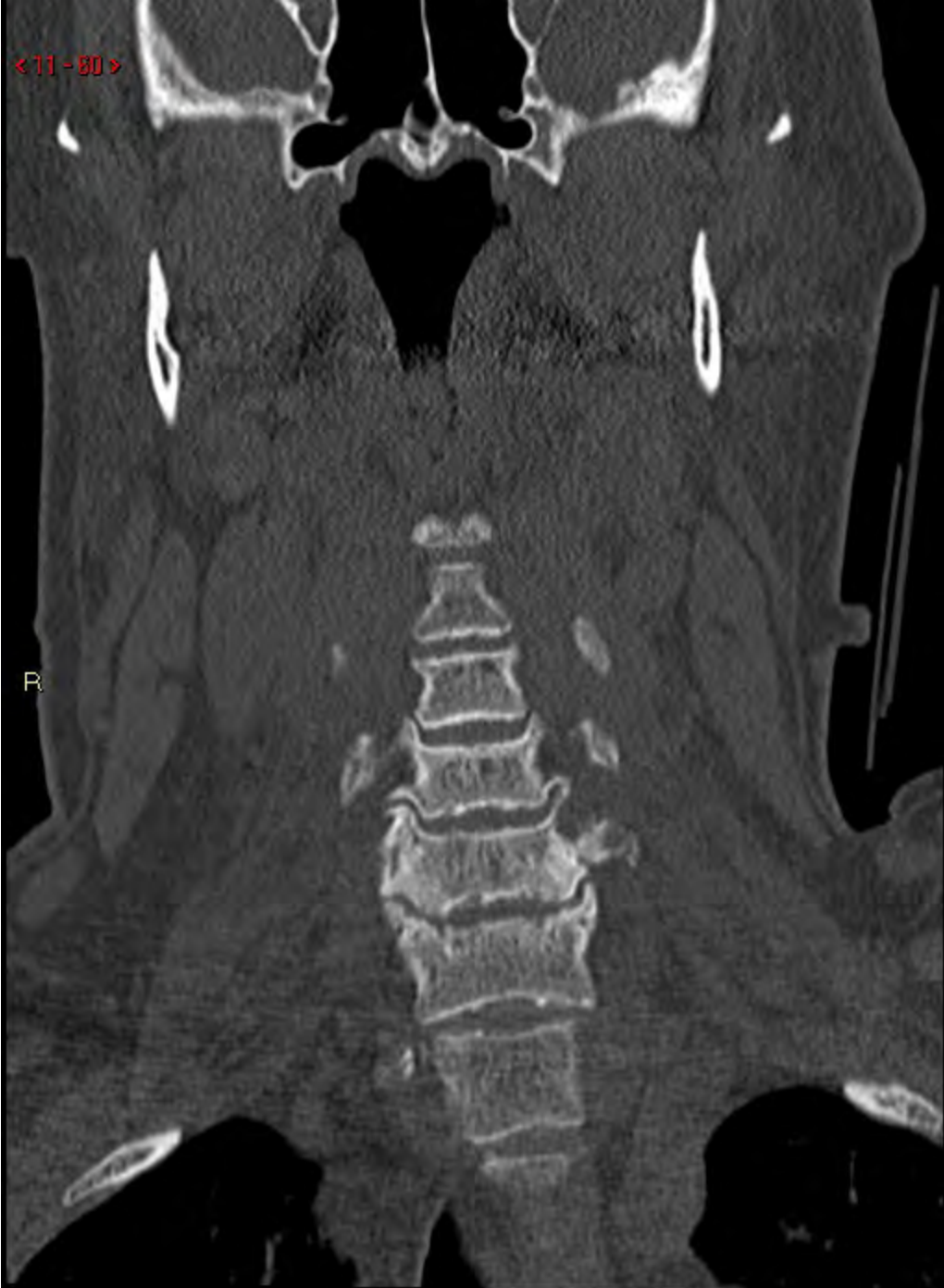R



< 11 - 59 >

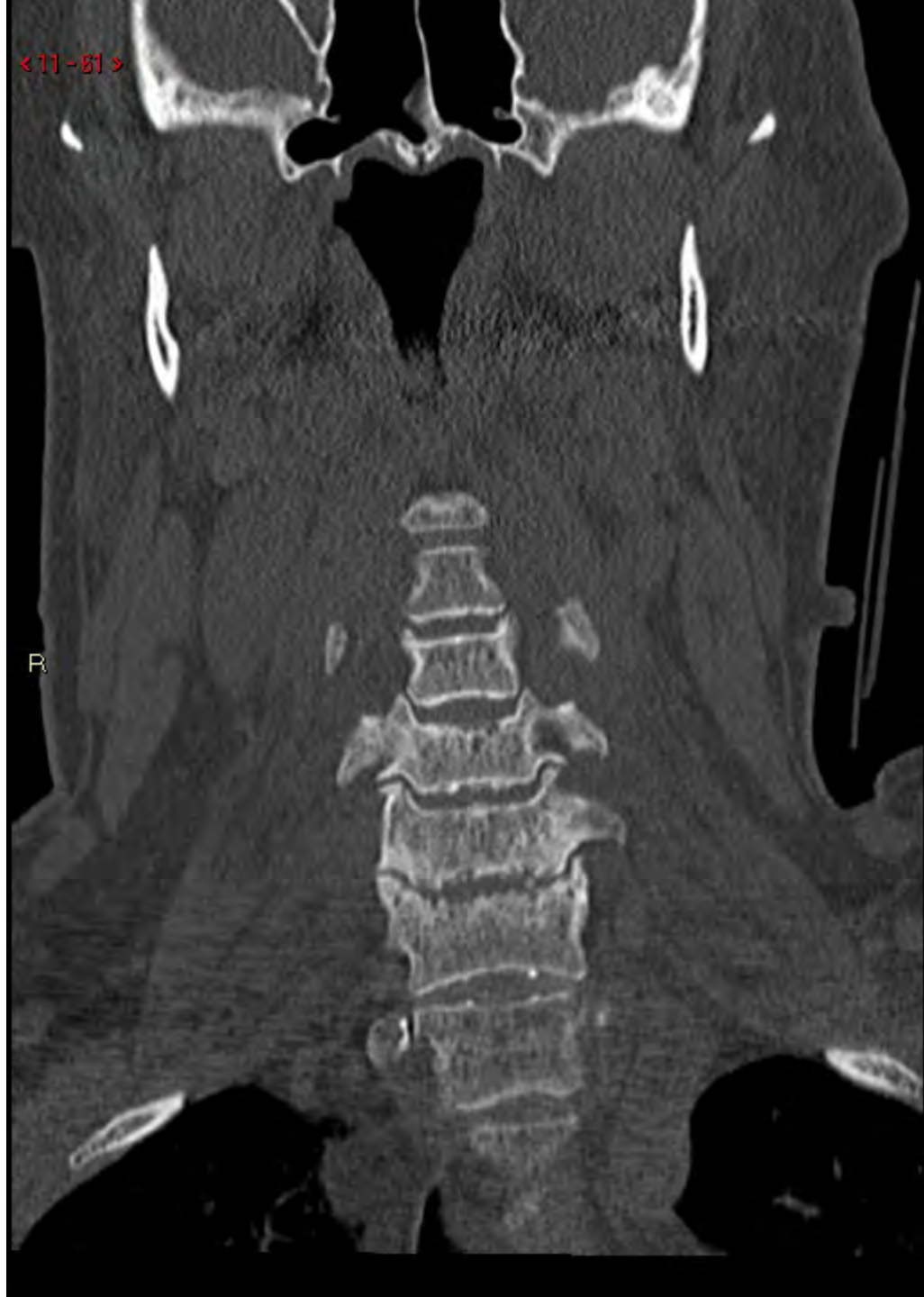R





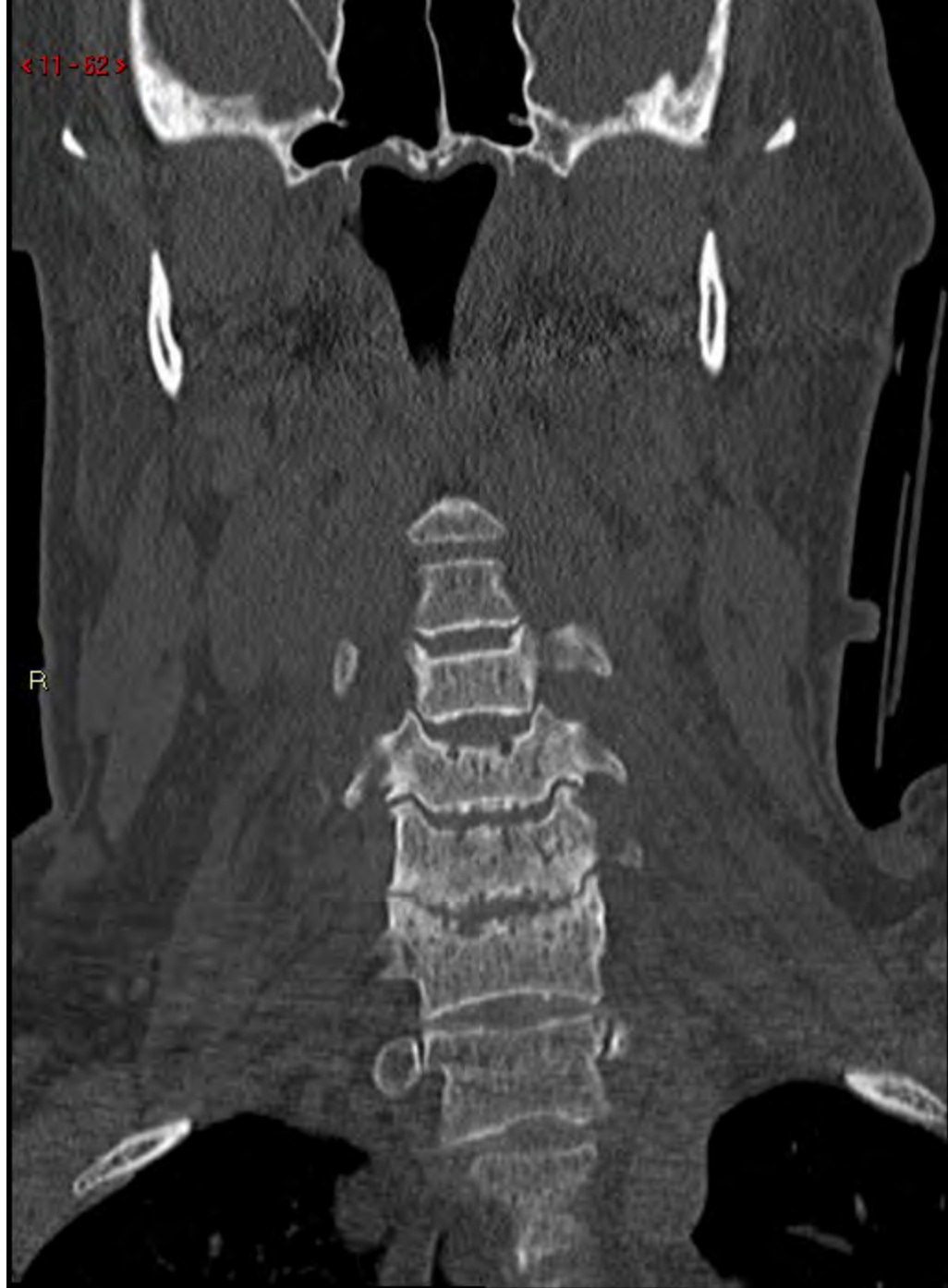<11-81>

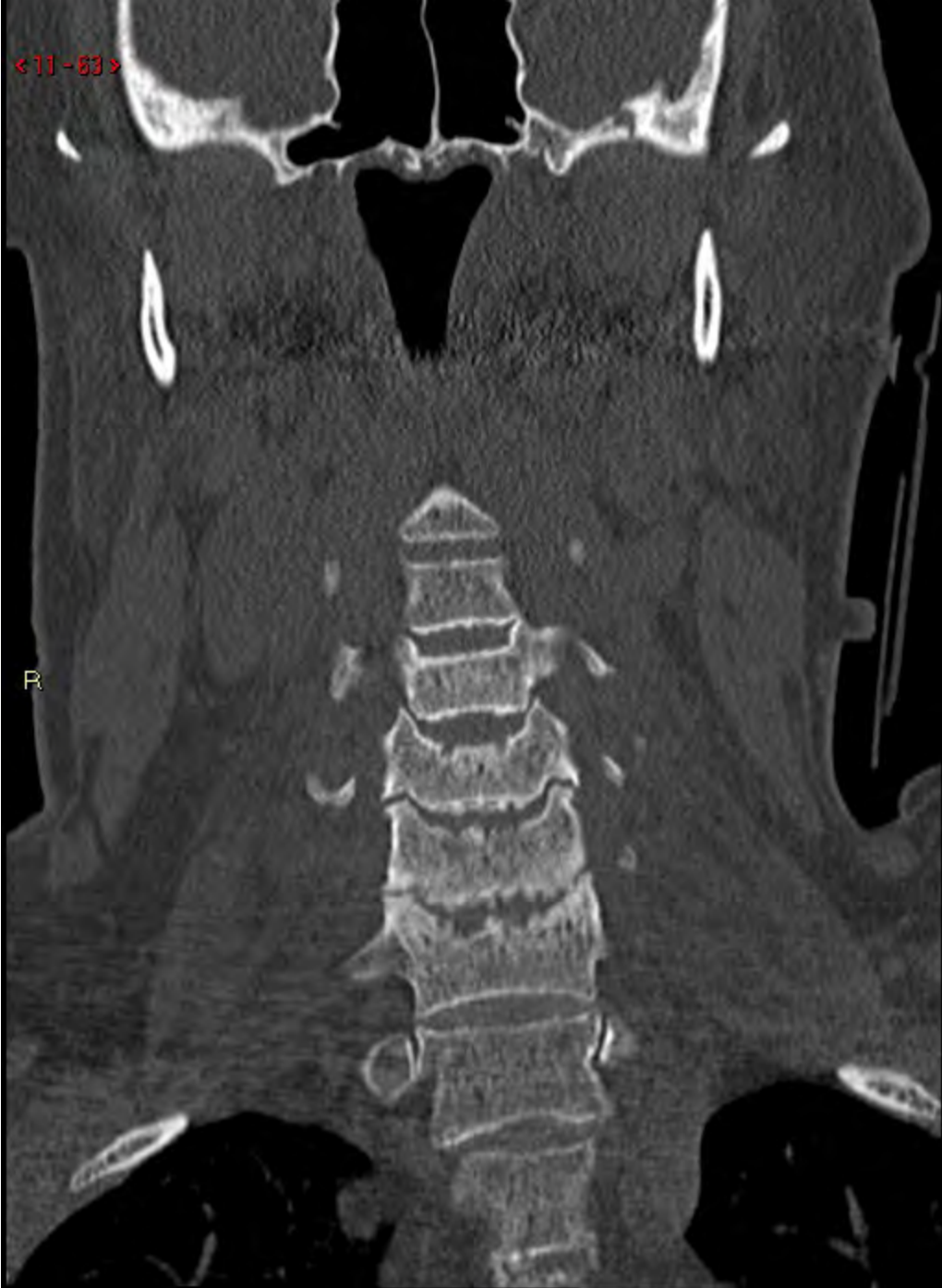R



<11-62>

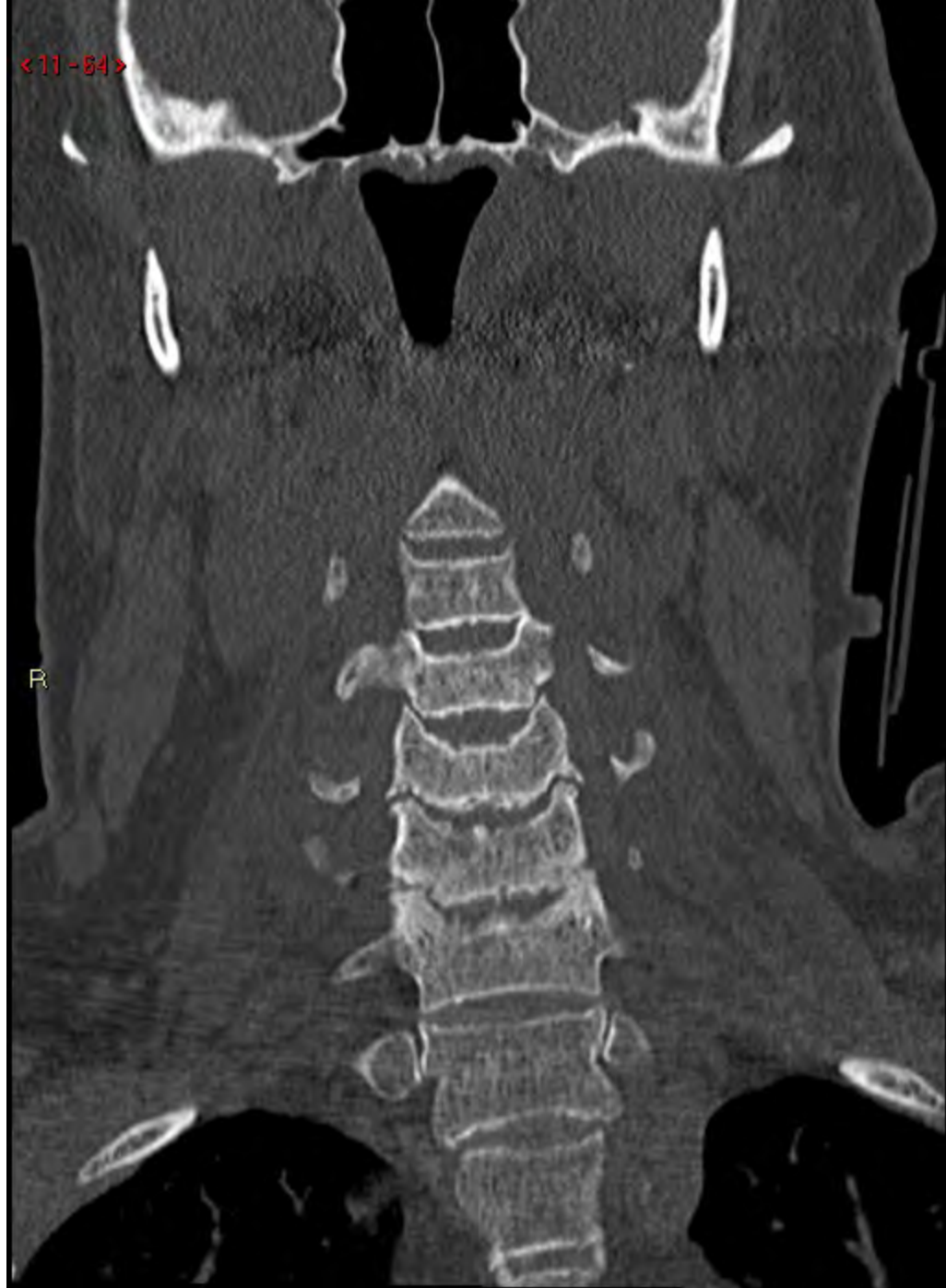R



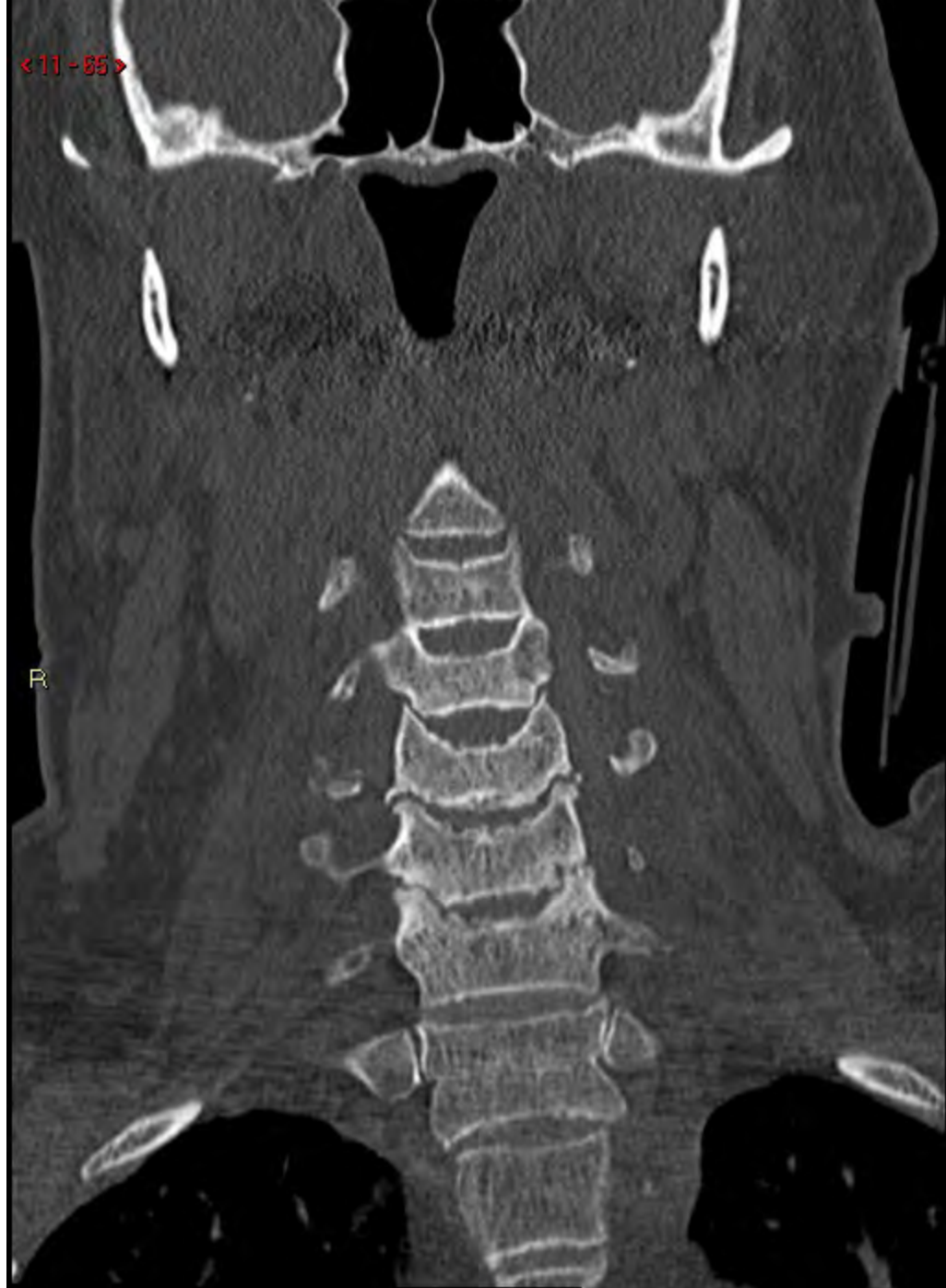

<11-84>

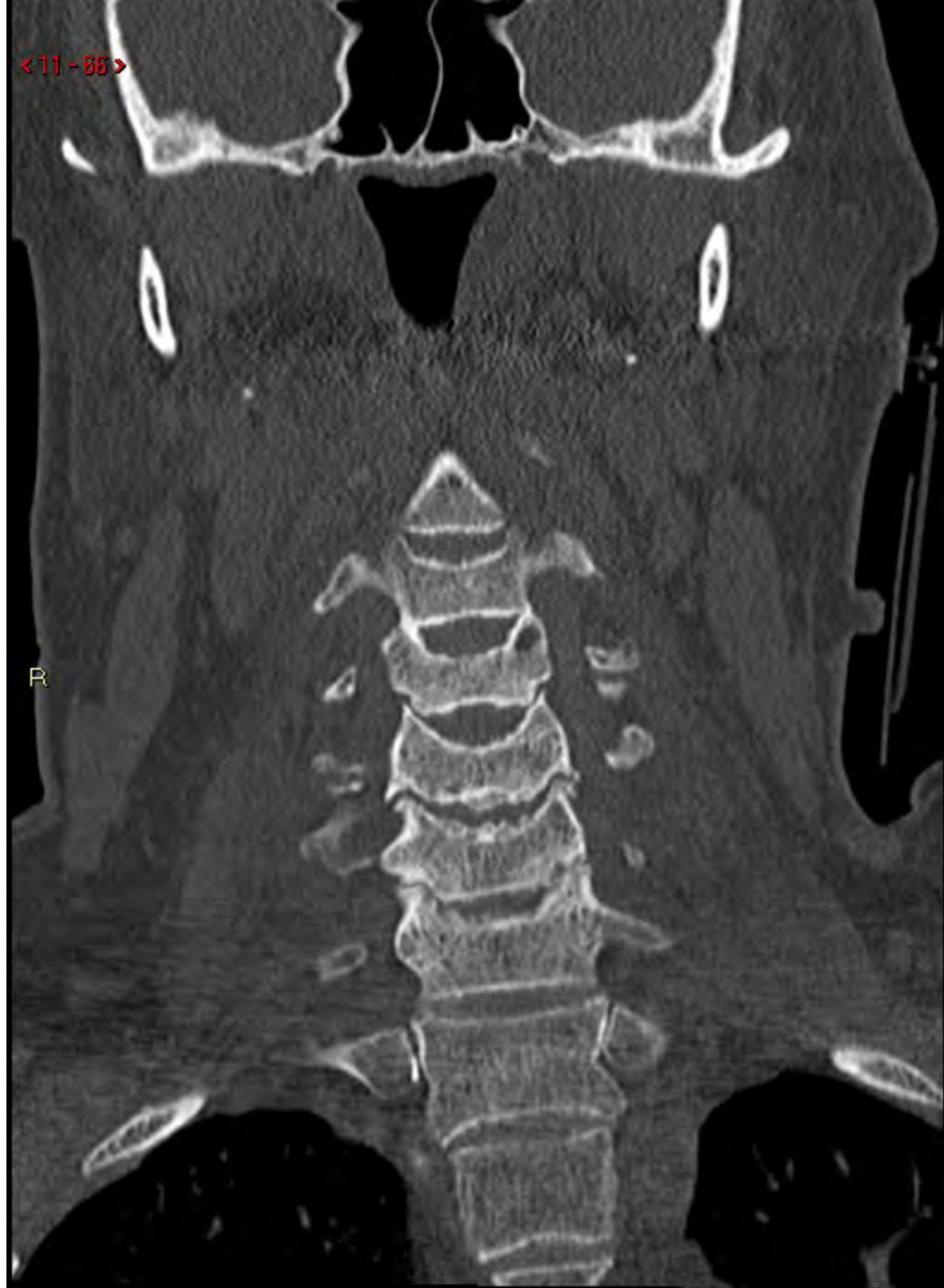R



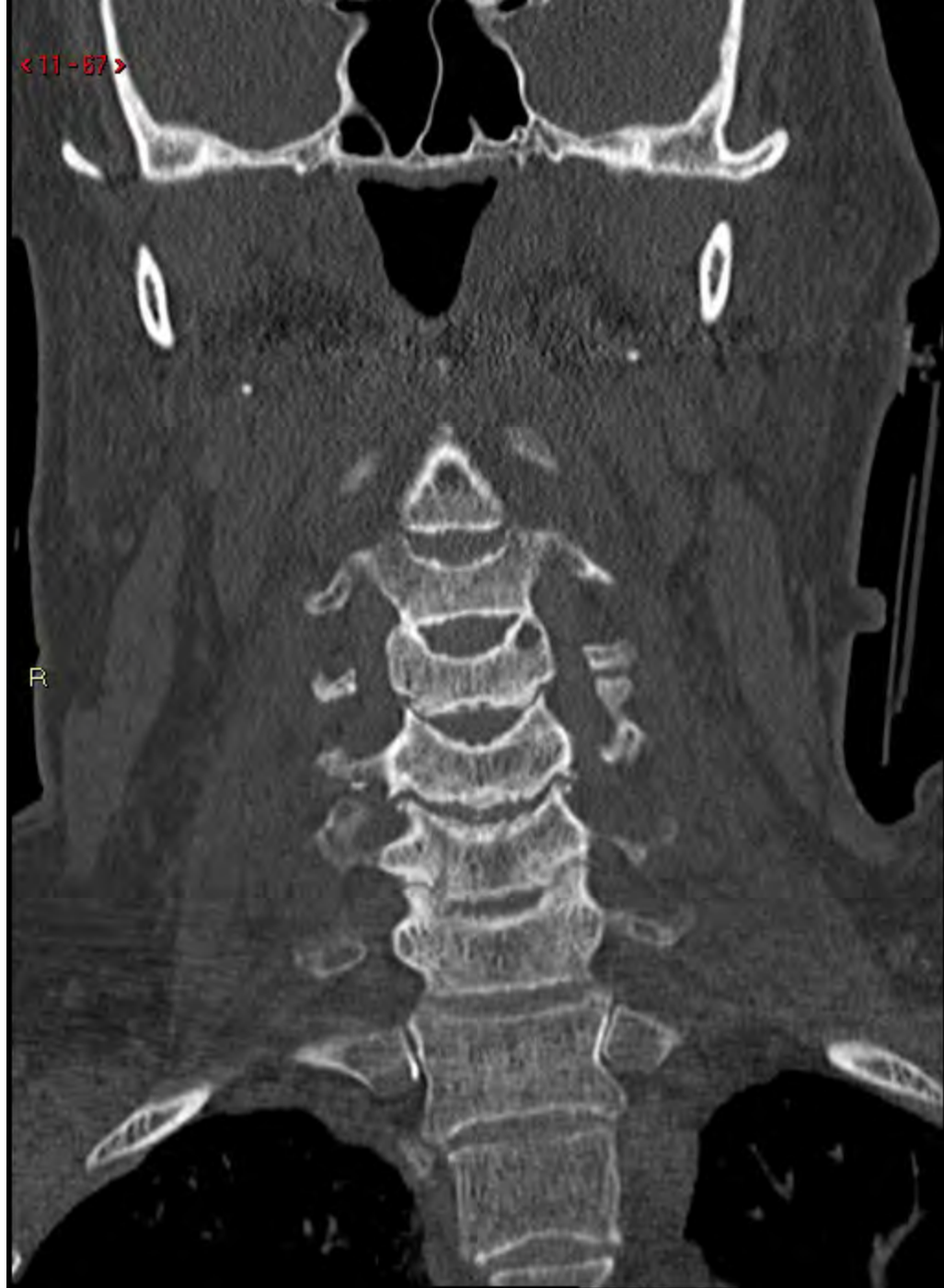< 11 - 85 >



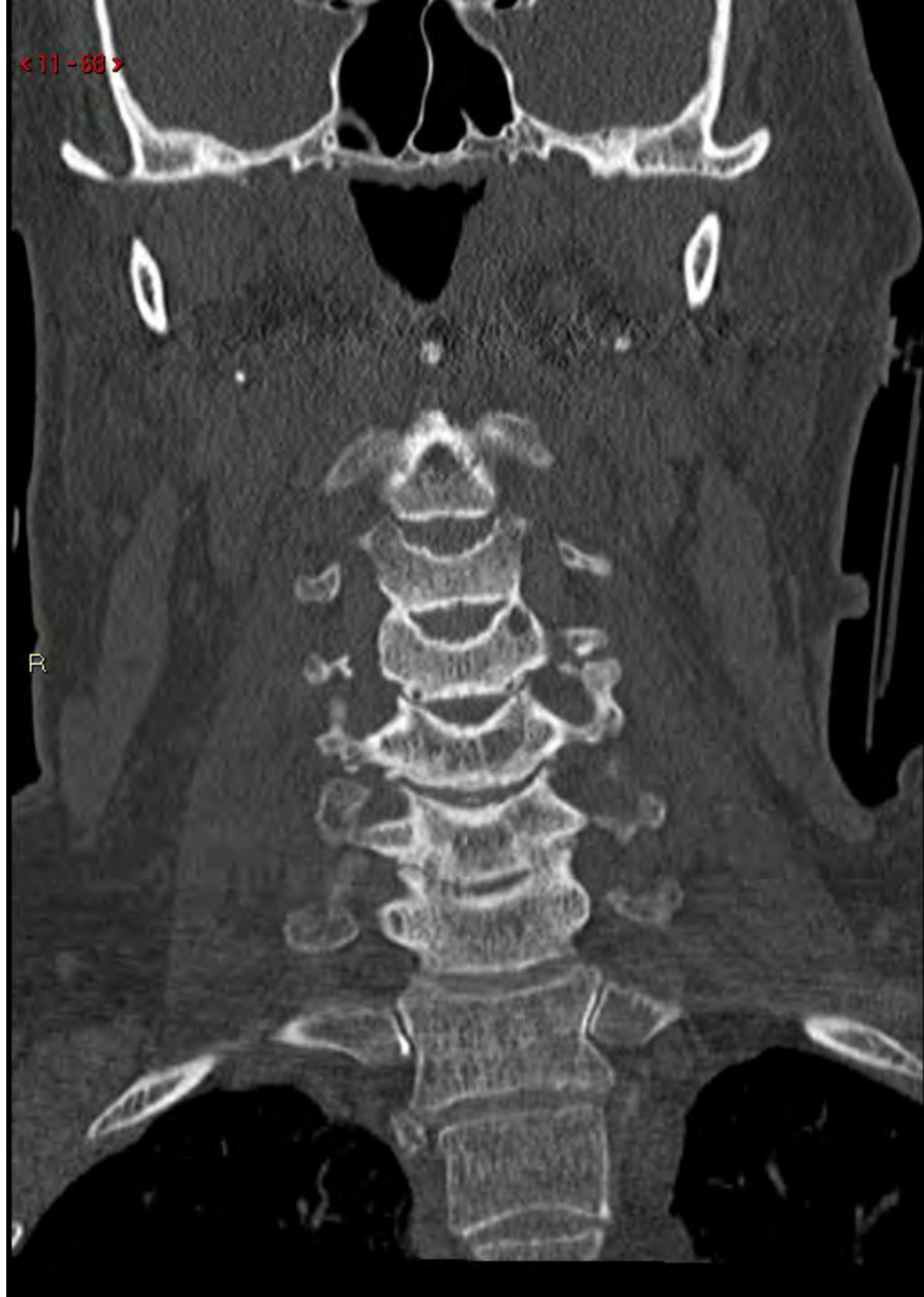<11-88>



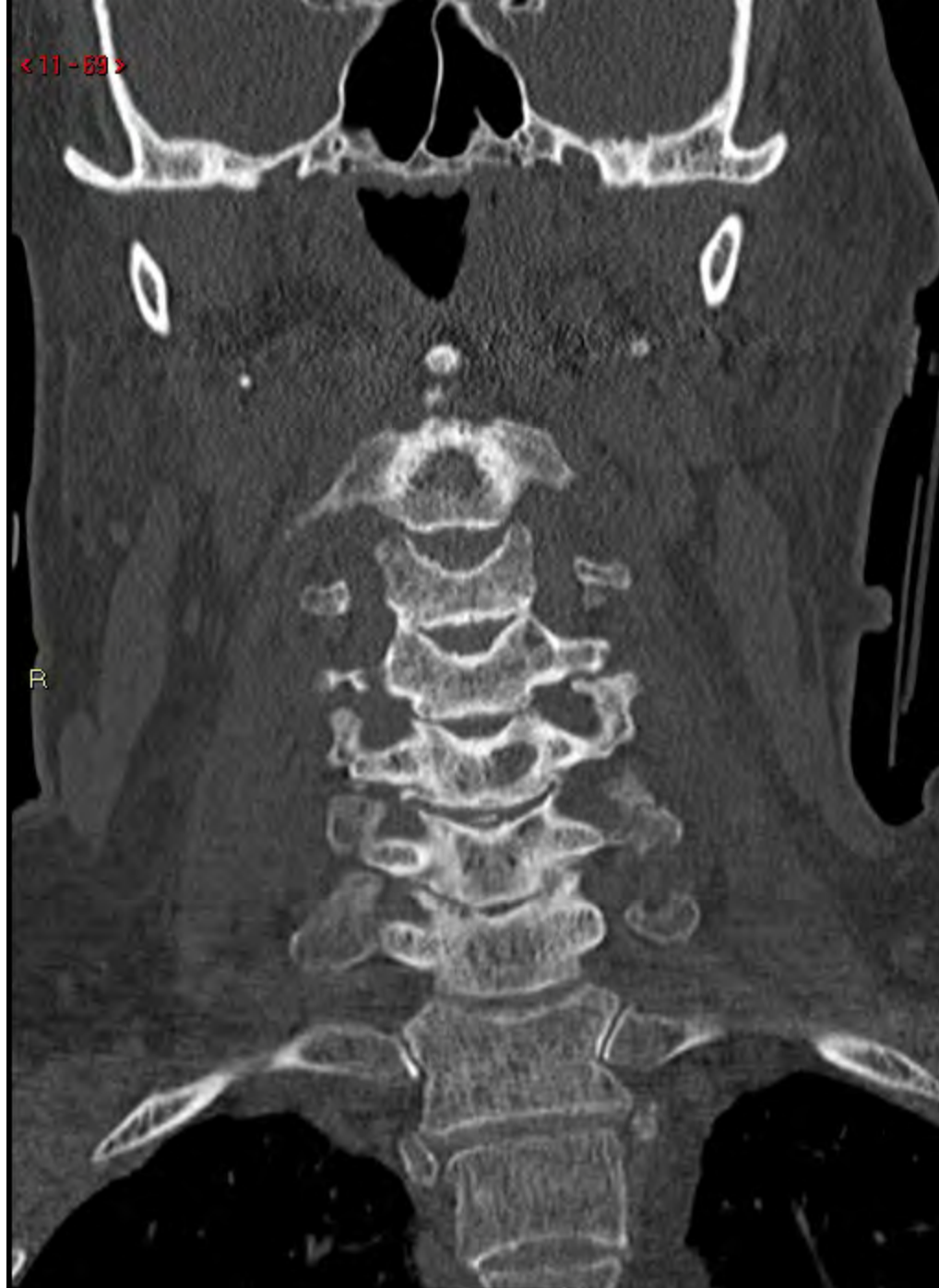<11-87>



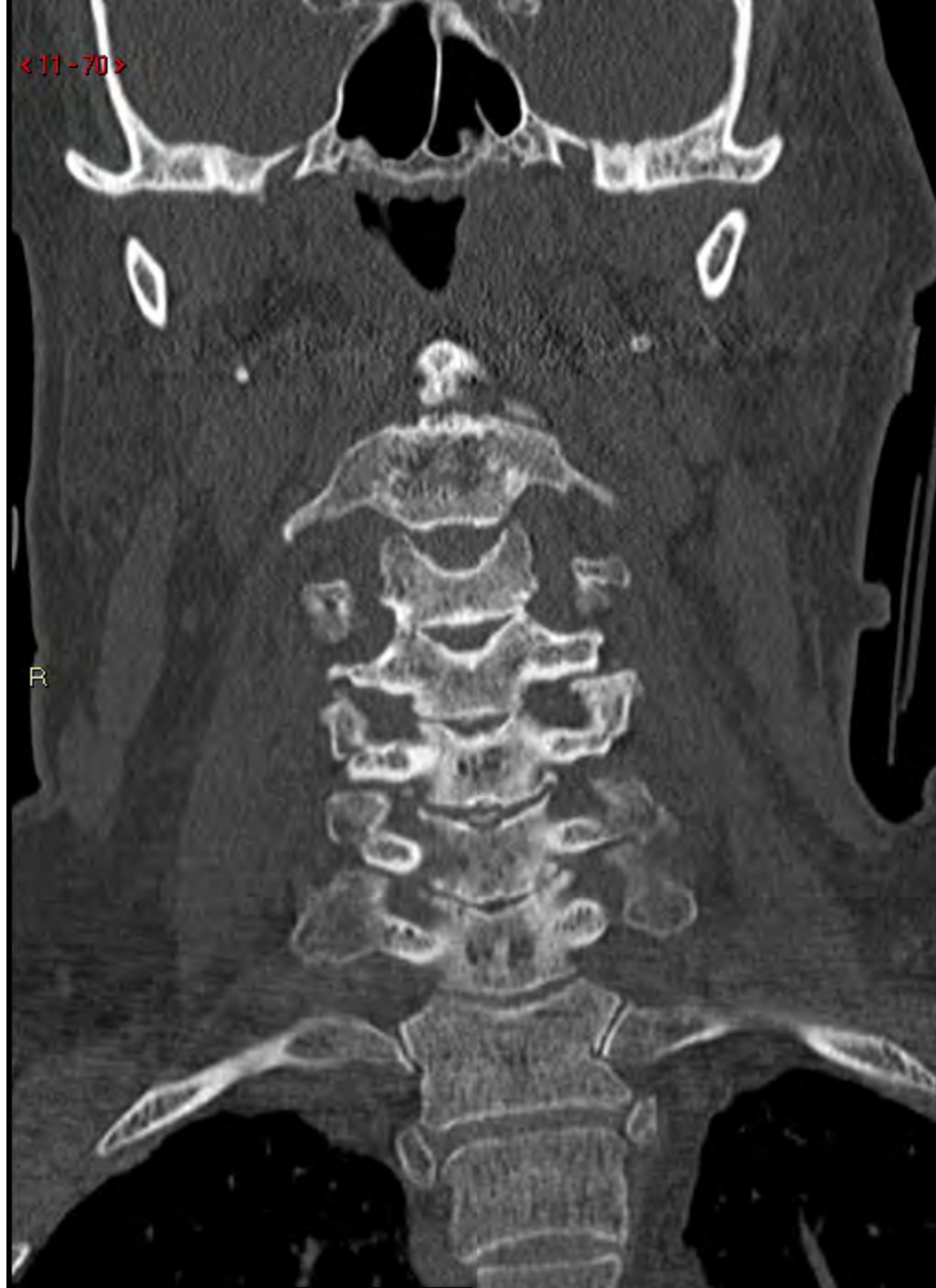<11-68>



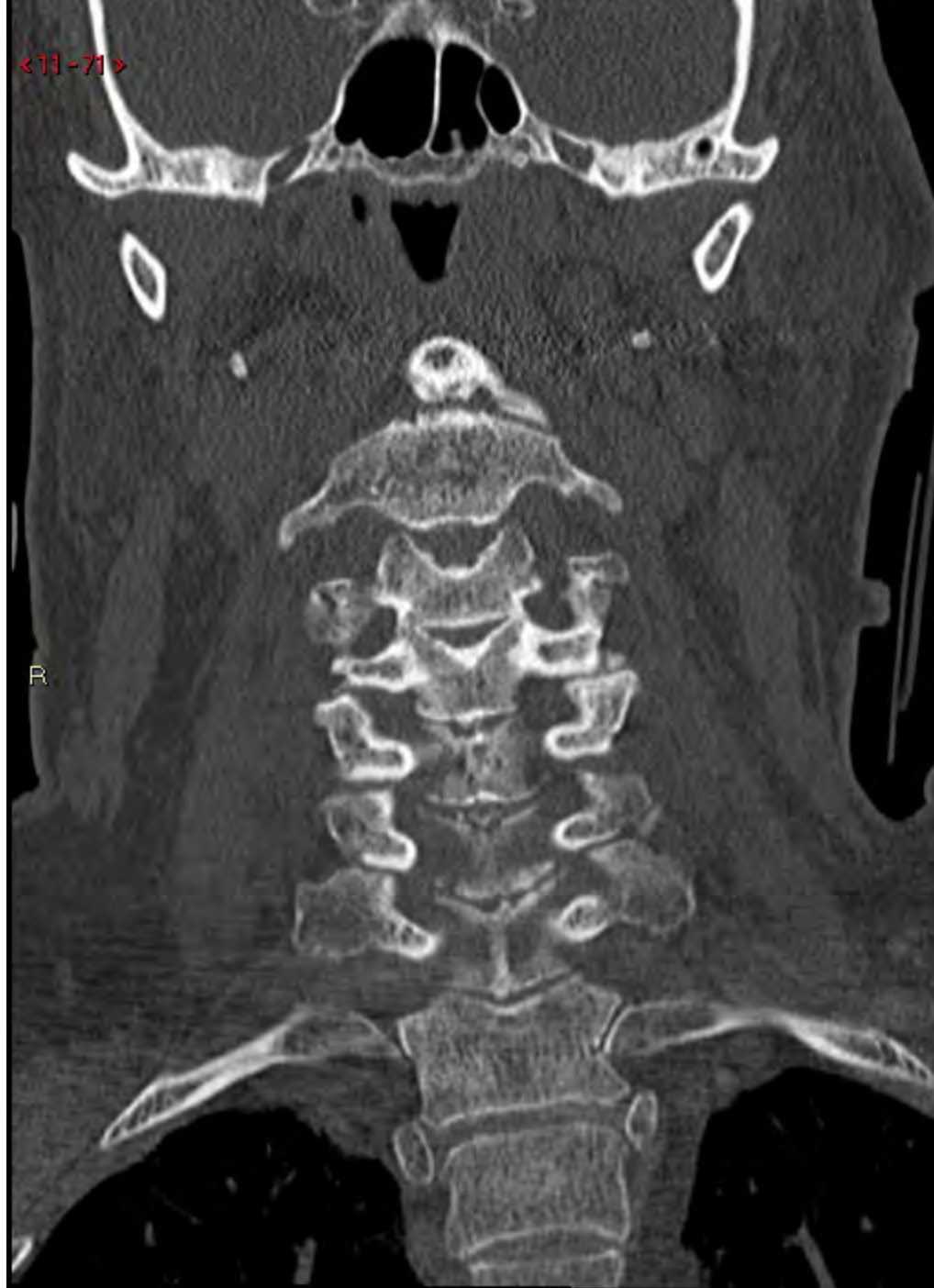<11-89>



<11-70>

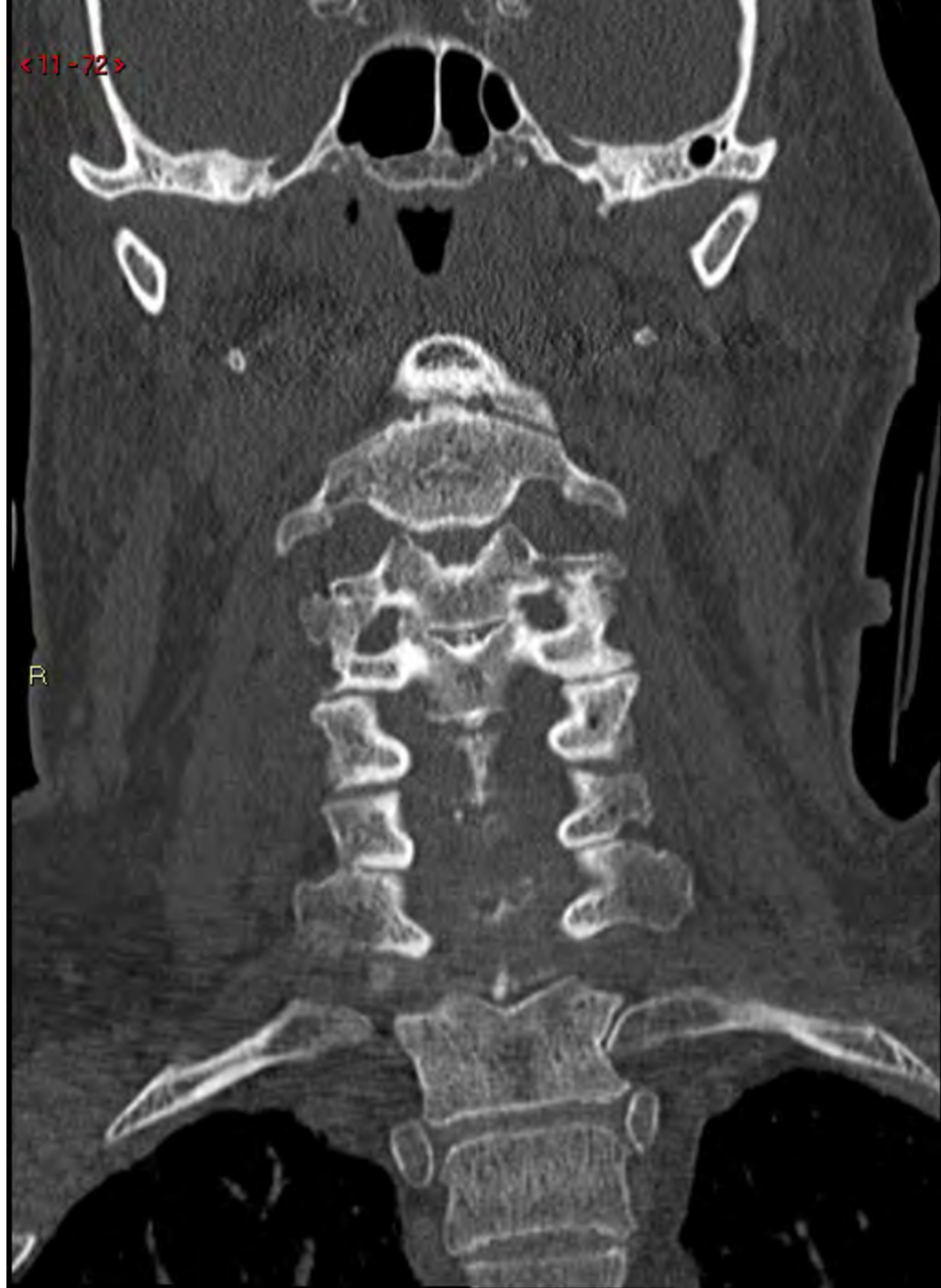

<11-71>

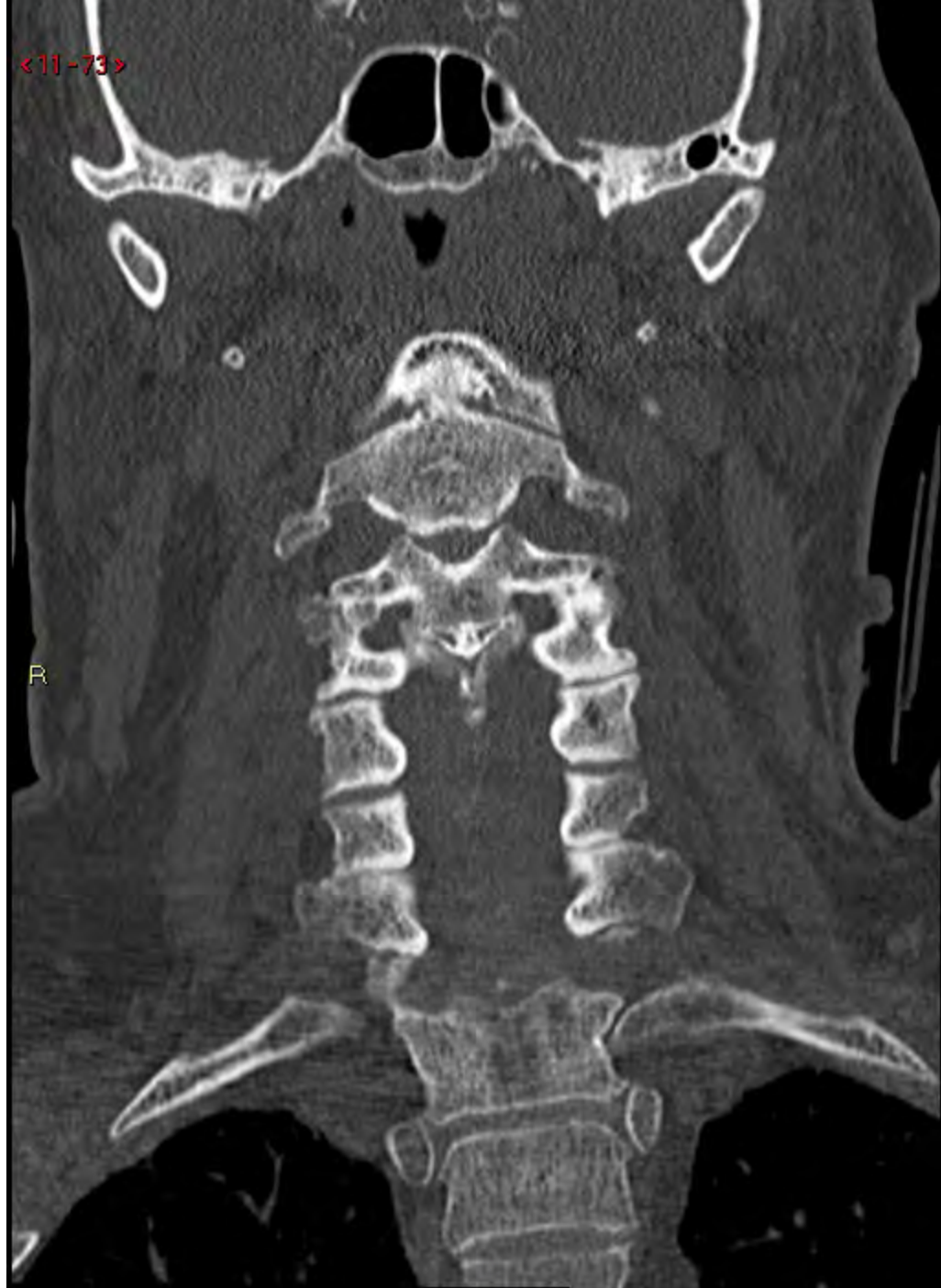

R

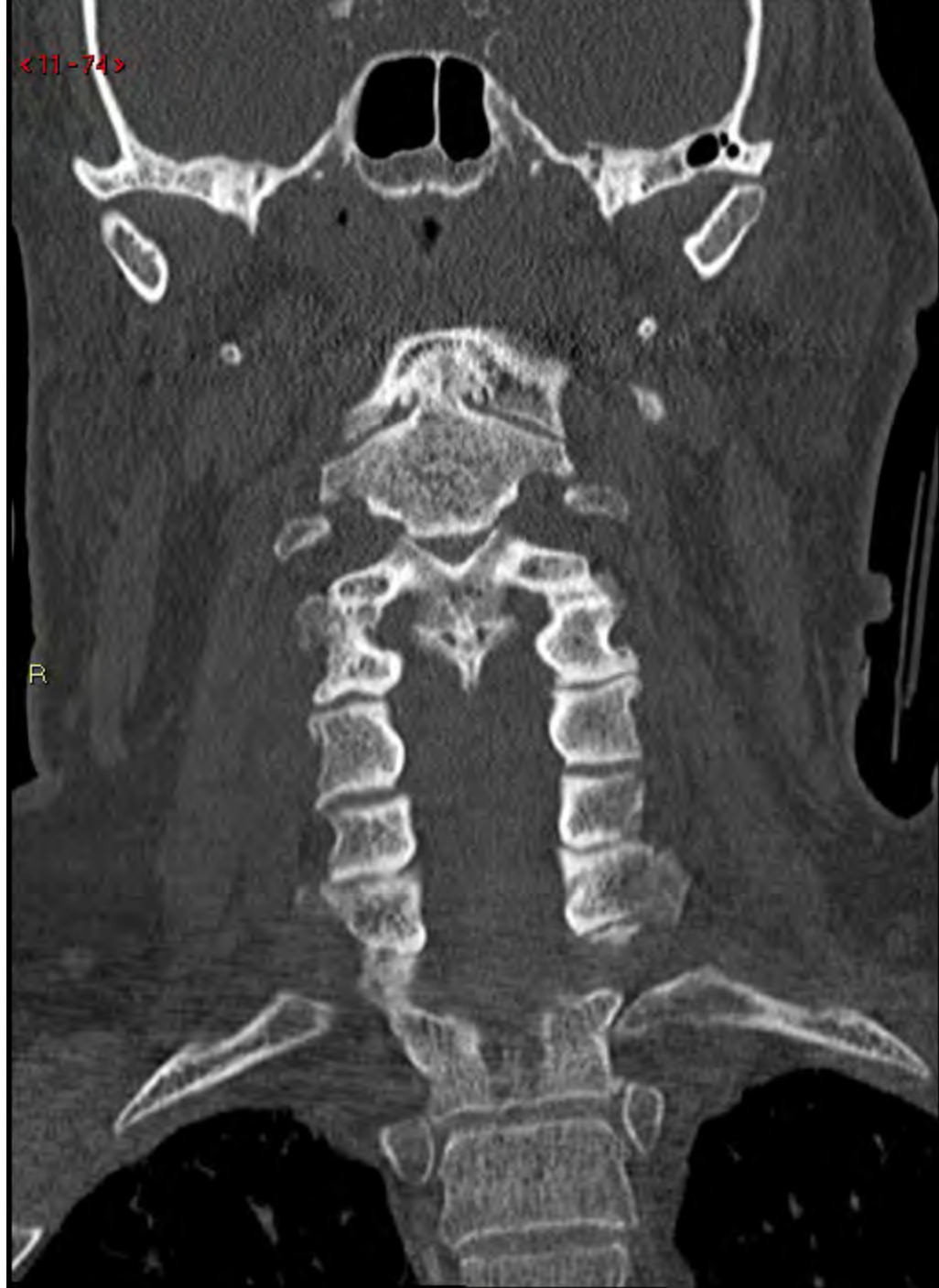<11-72>



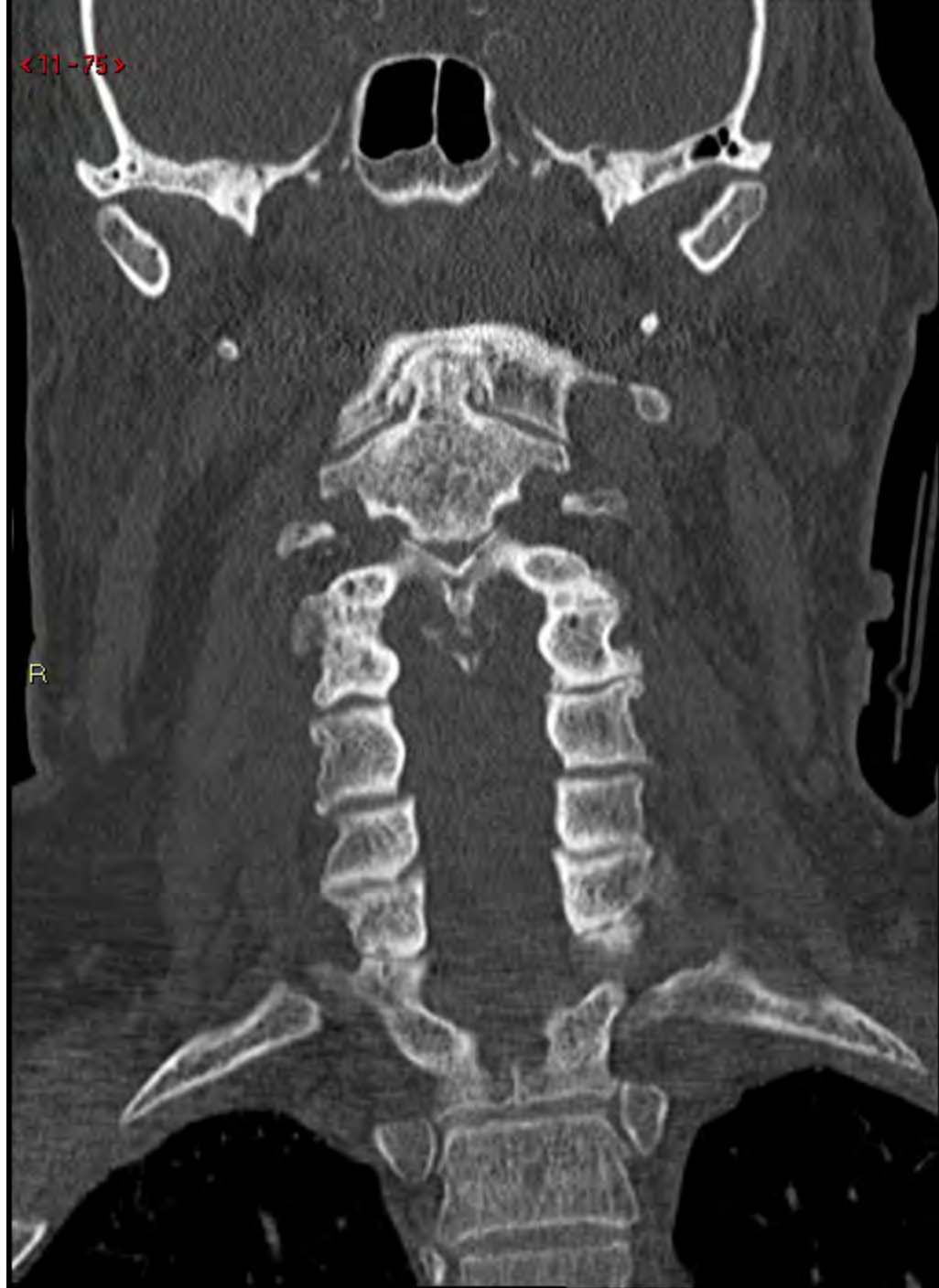<11-73>



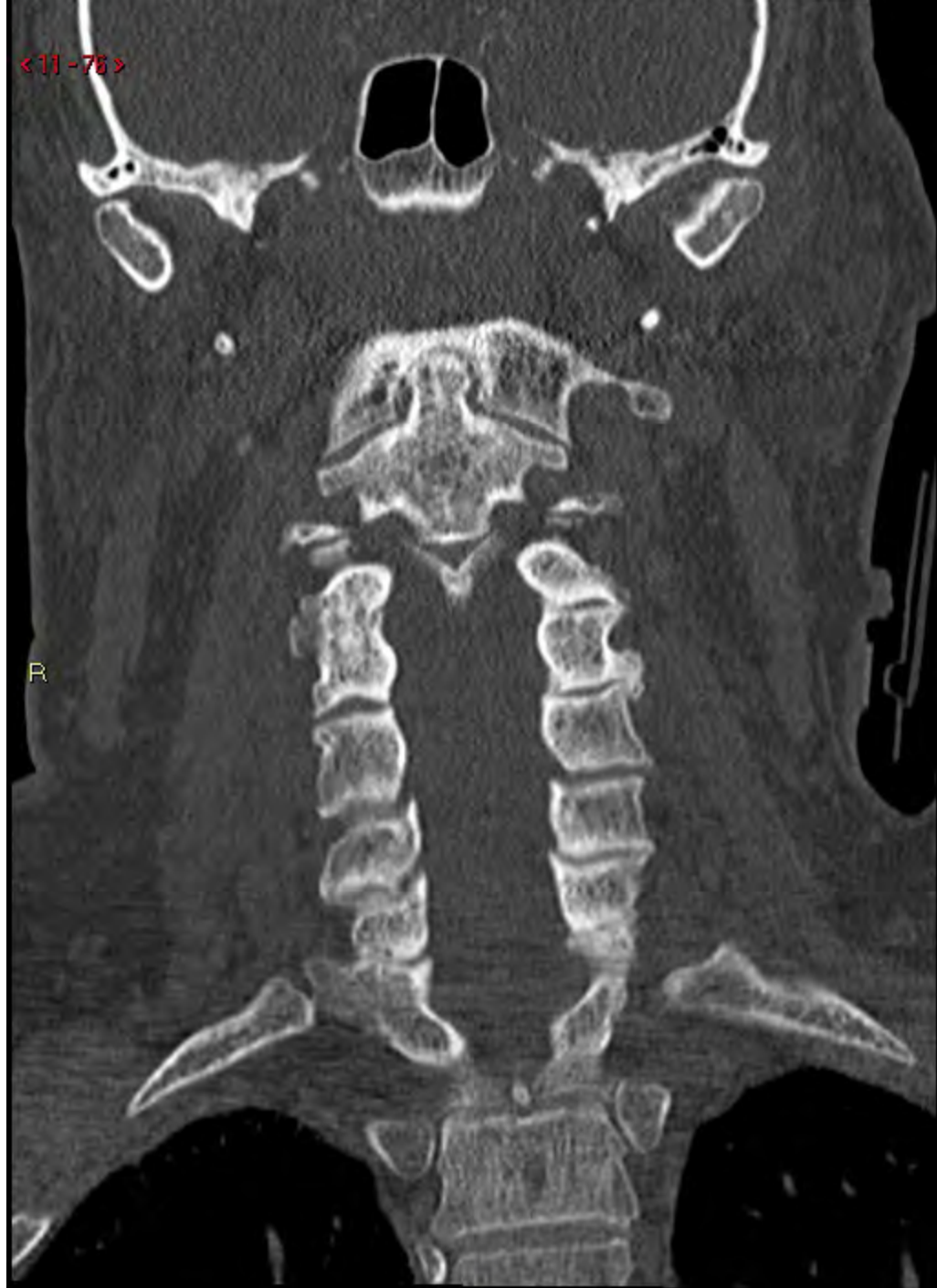<11-74>



<11-75>

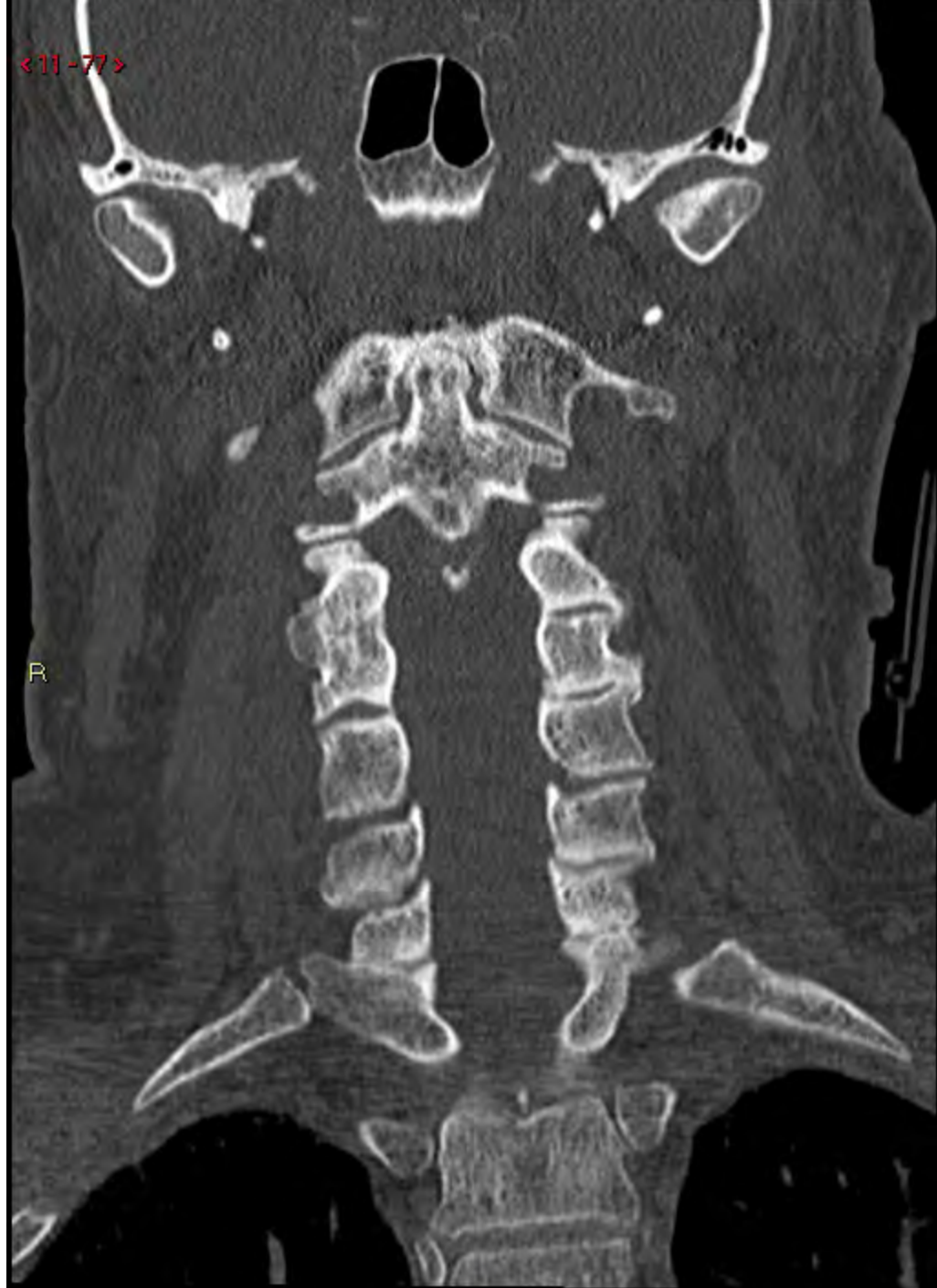

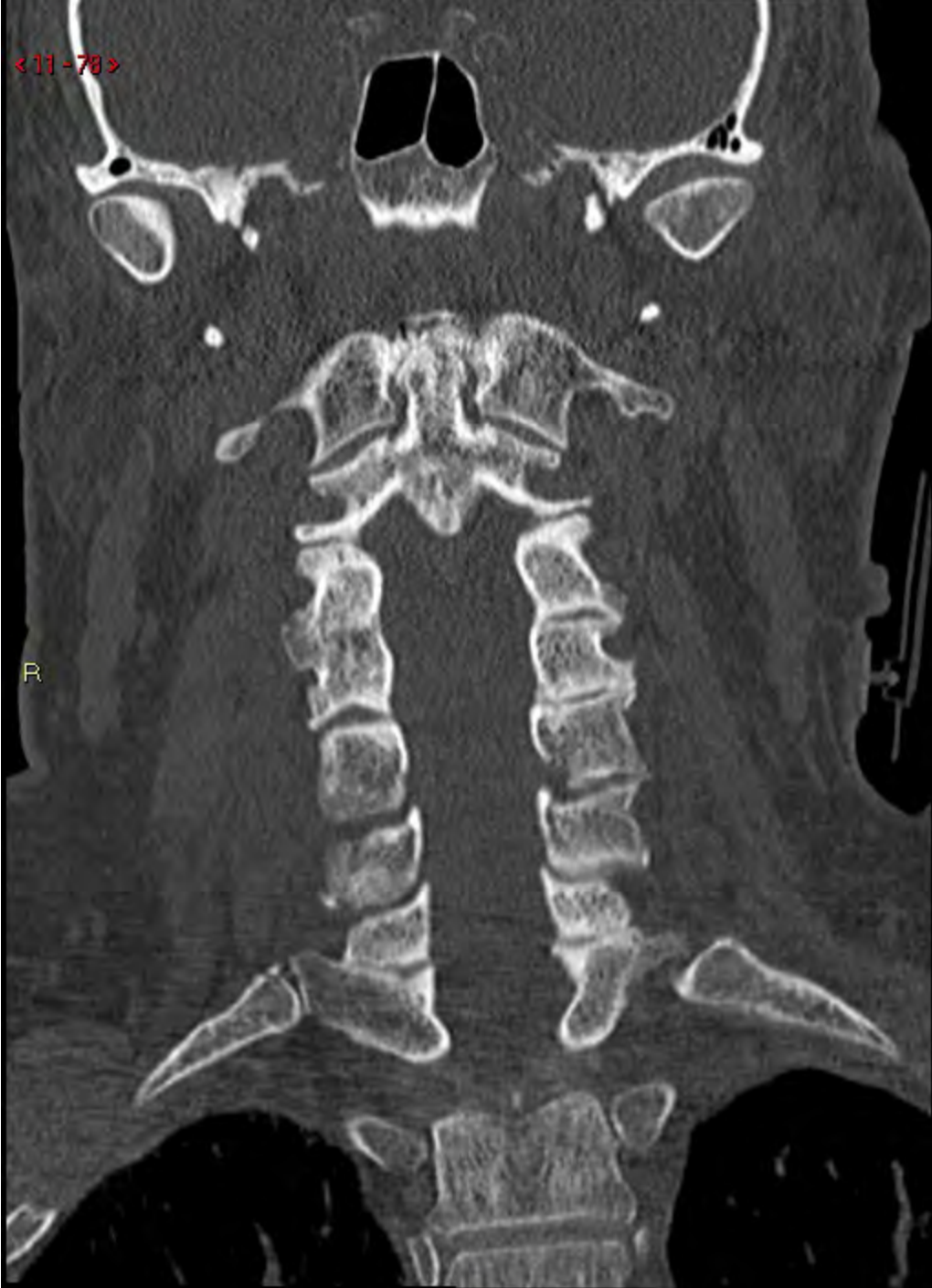<11-78>

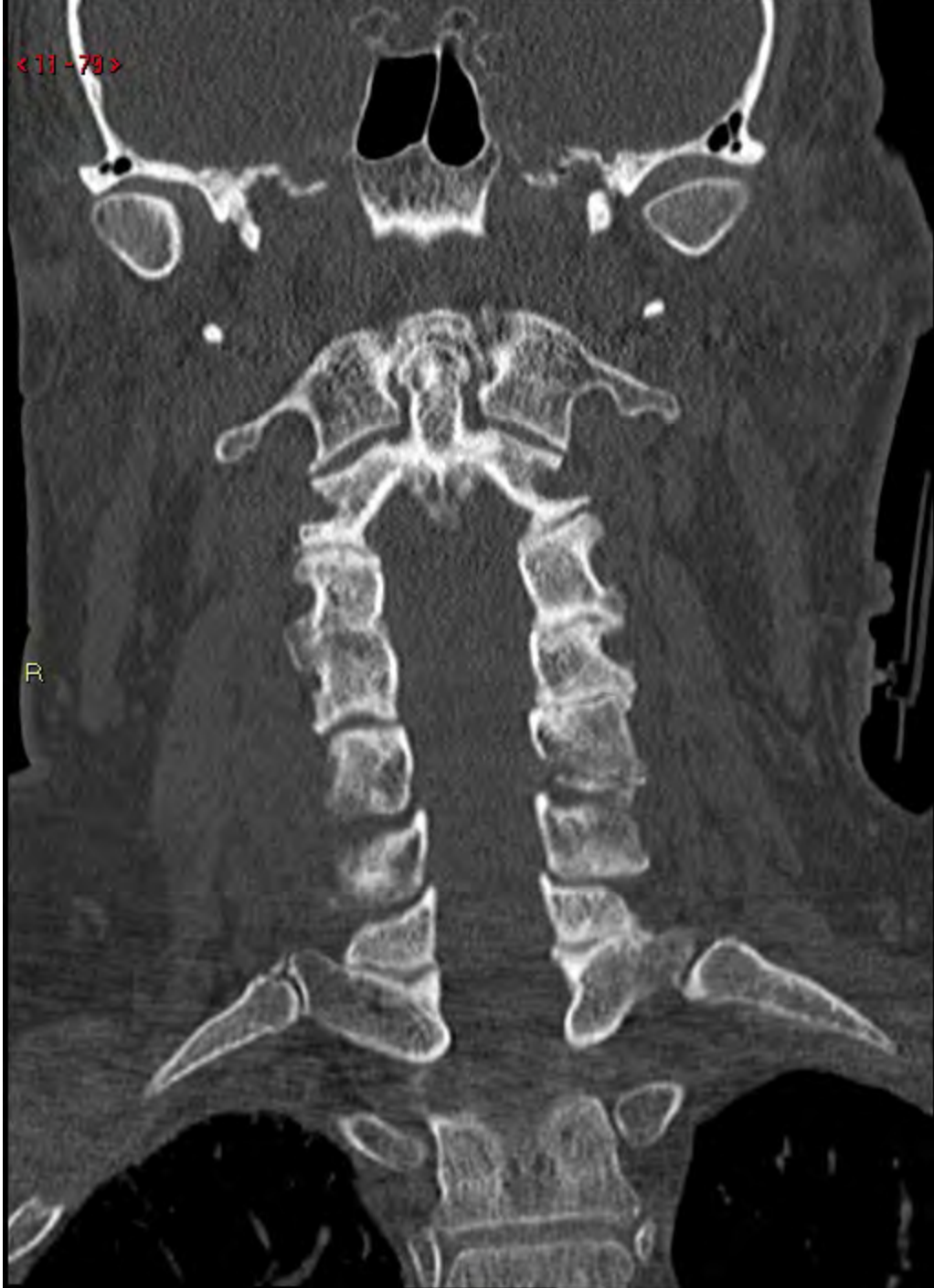

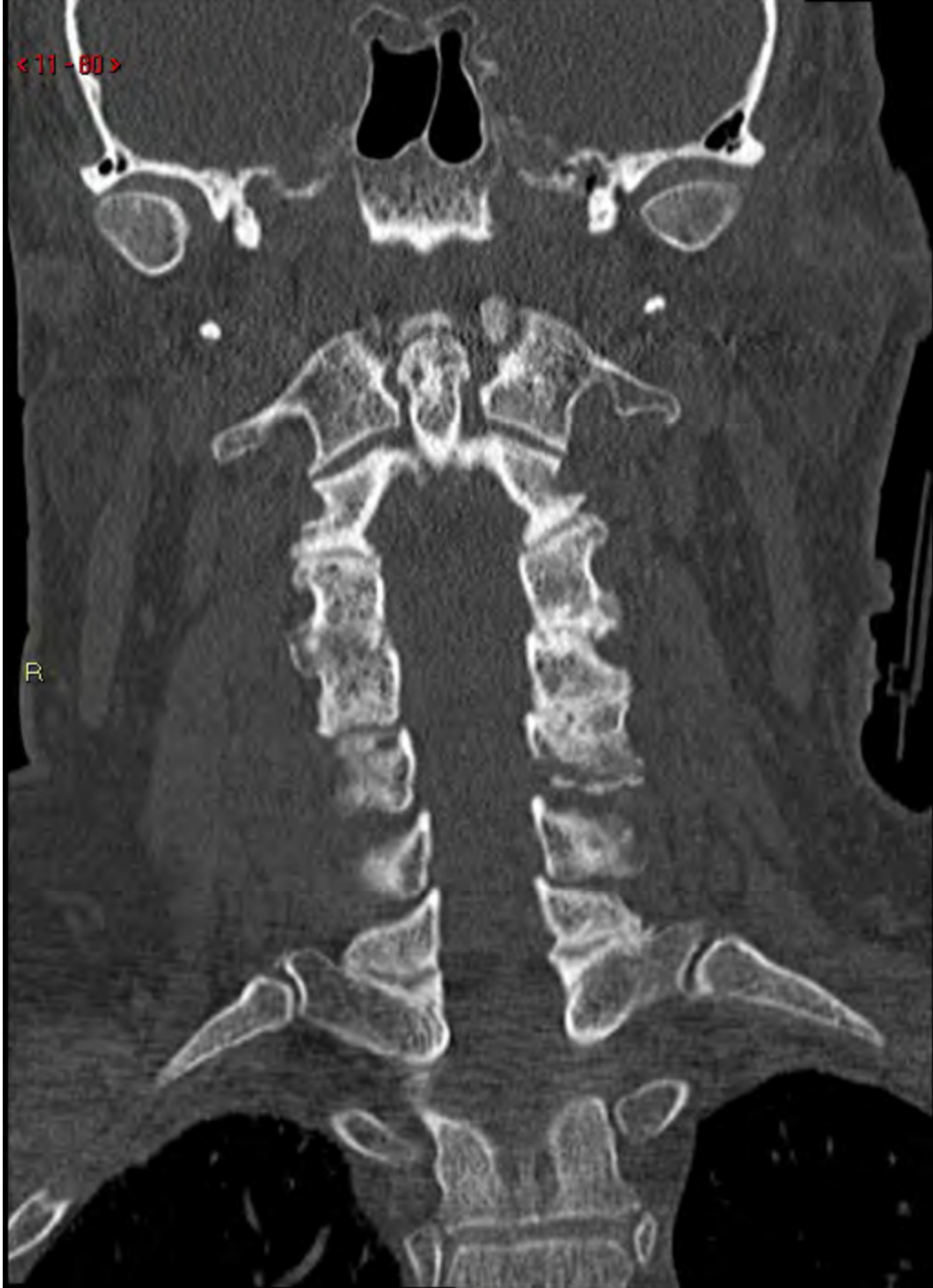<11-77>

R



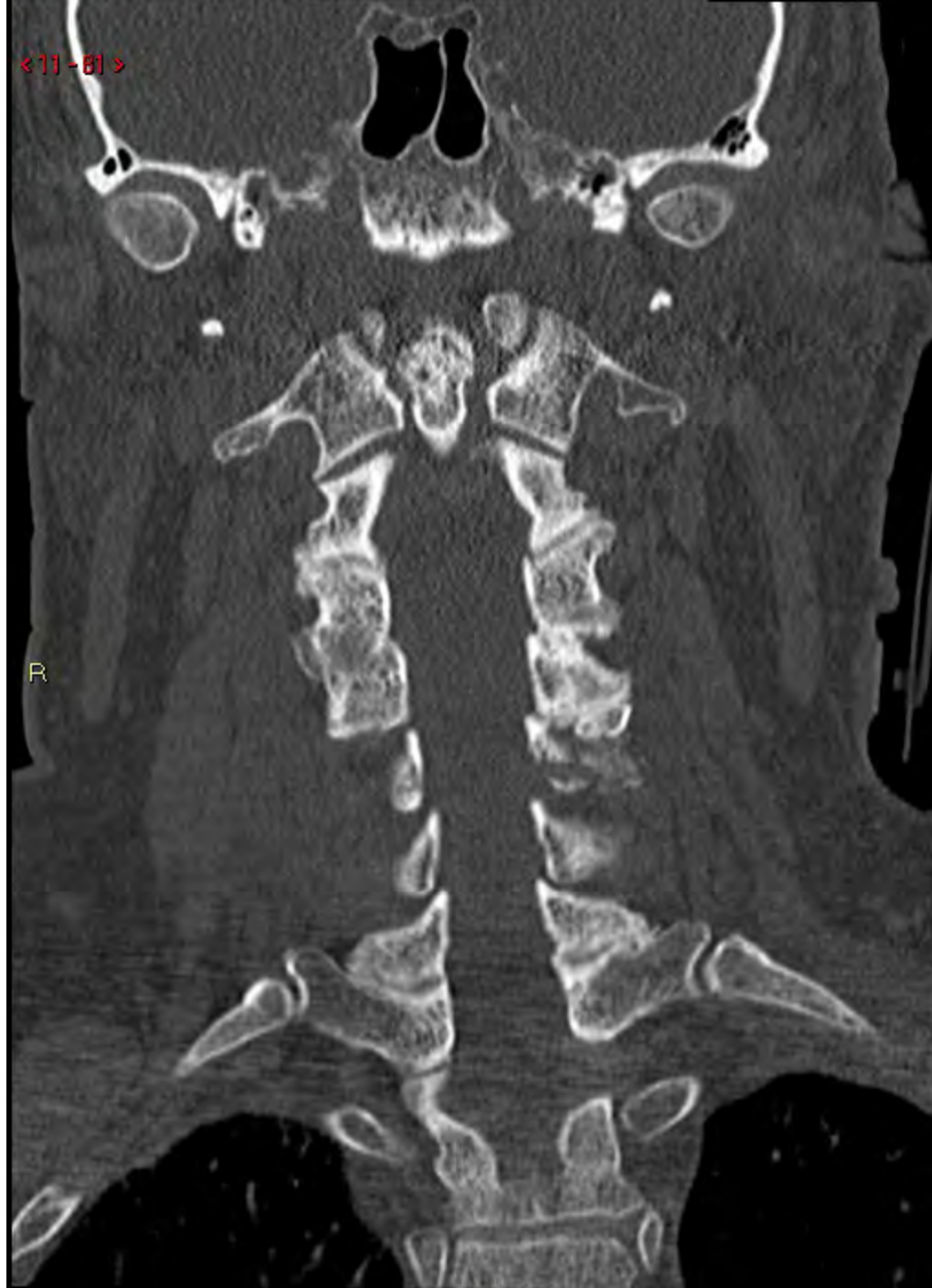





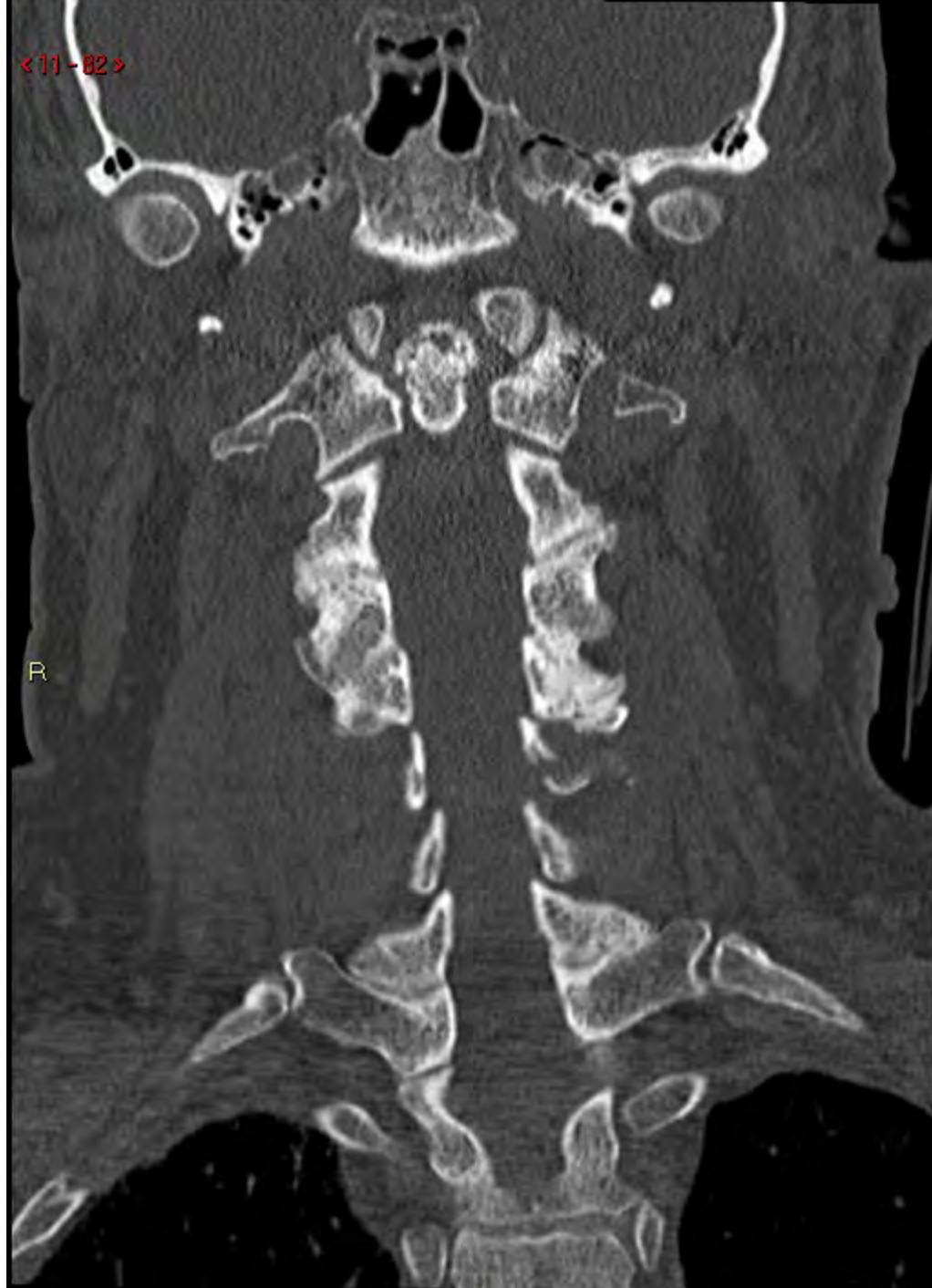<11-81>

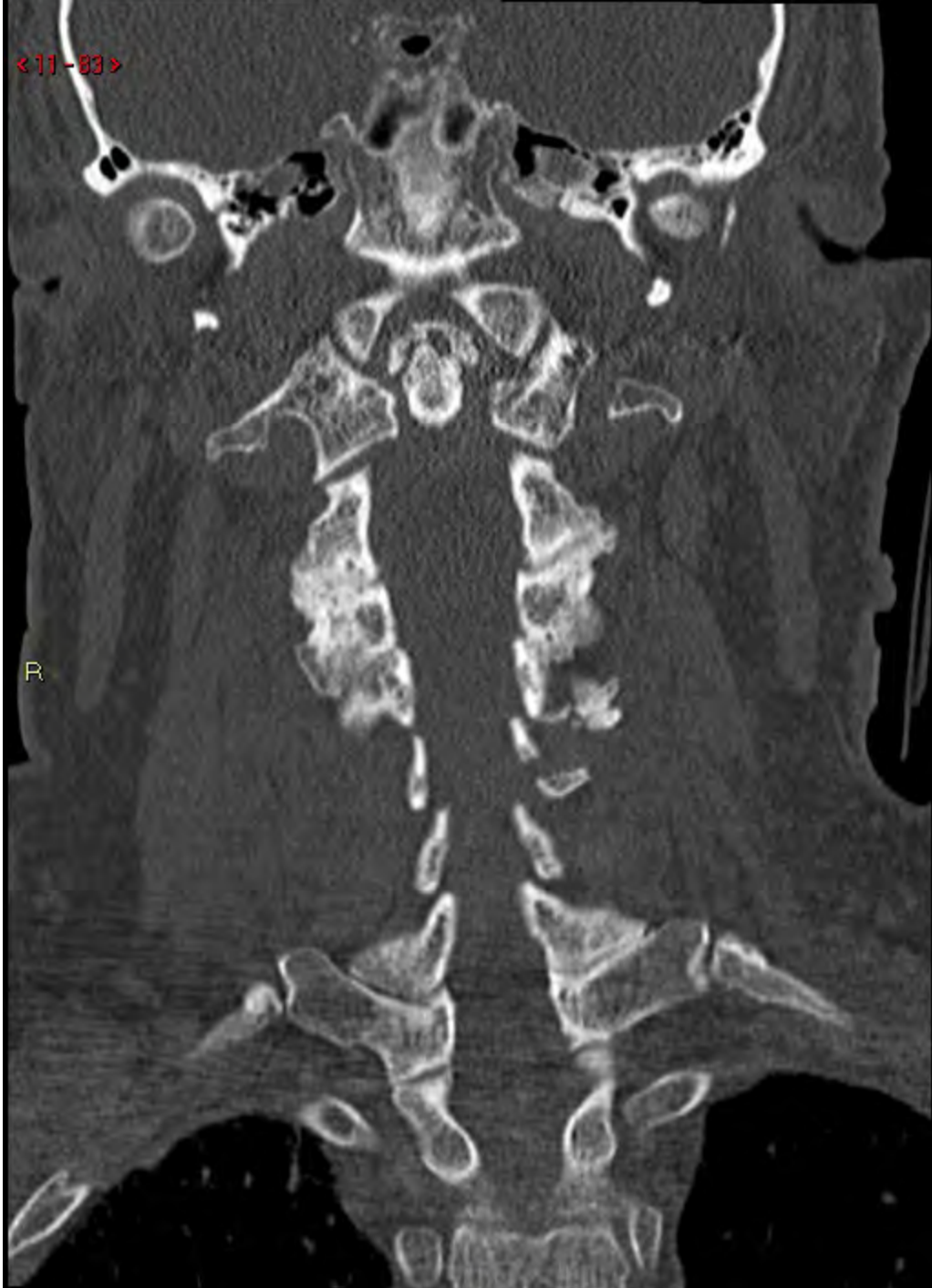R

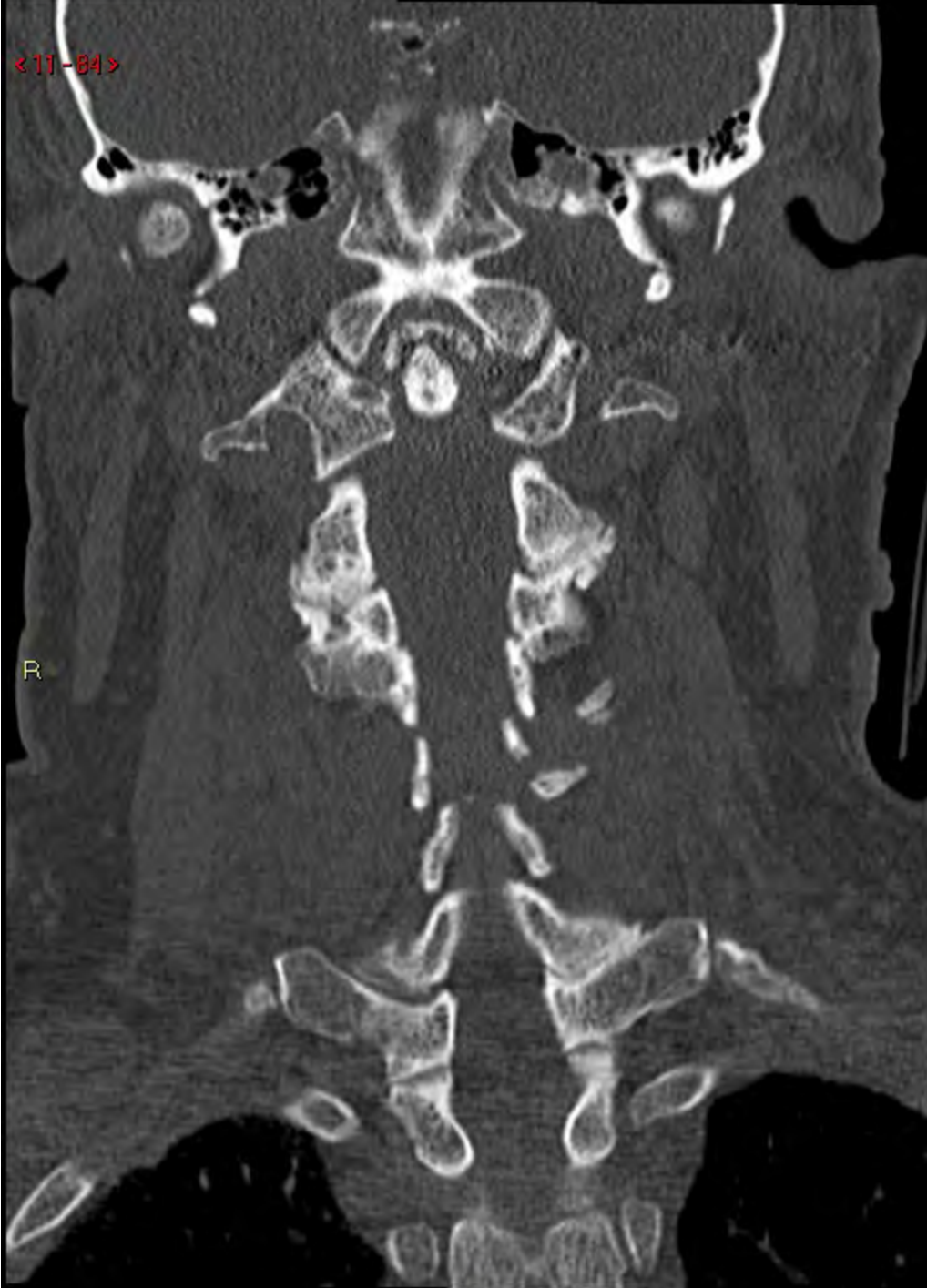

< 11 - 82 >

R

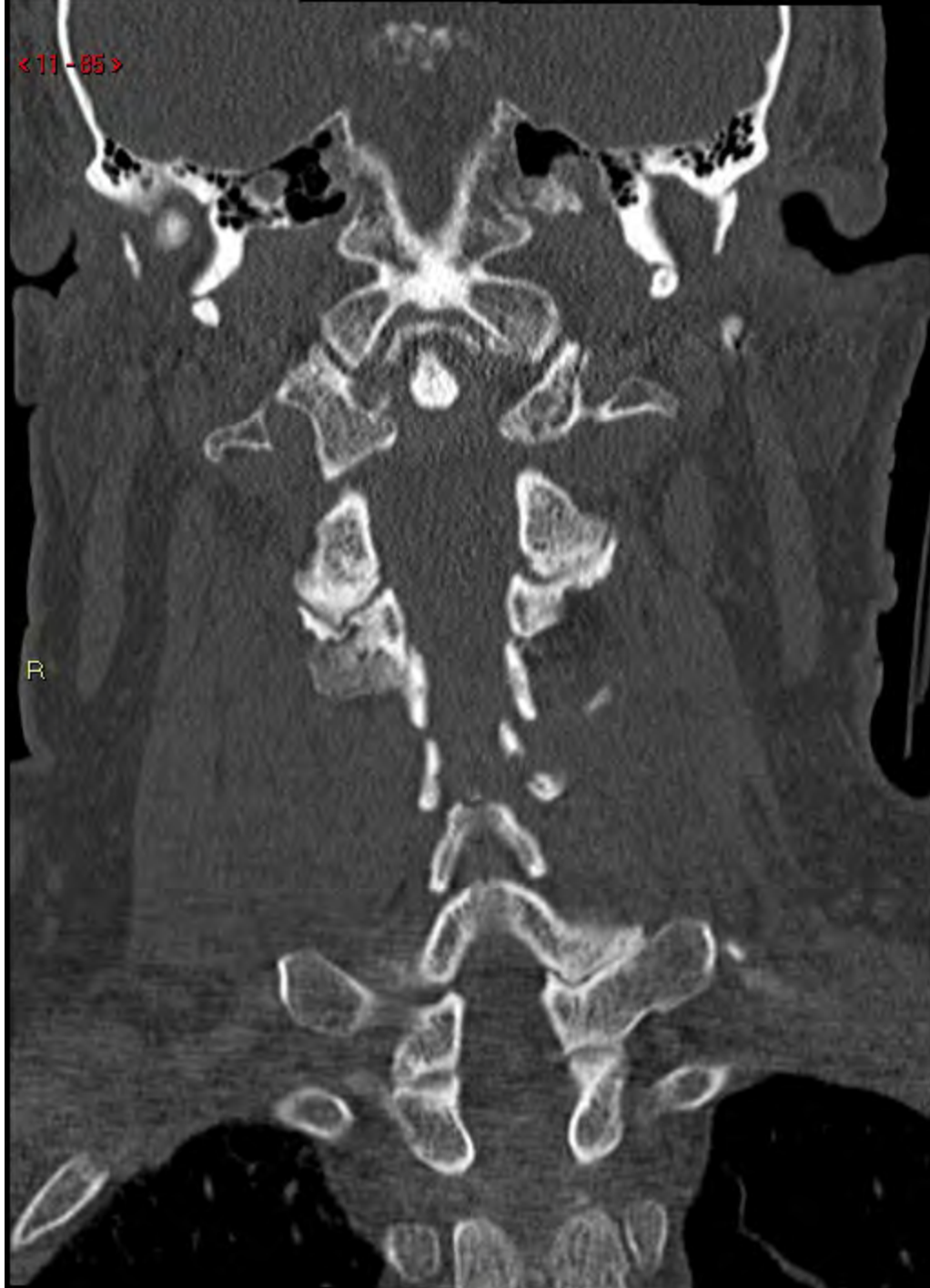





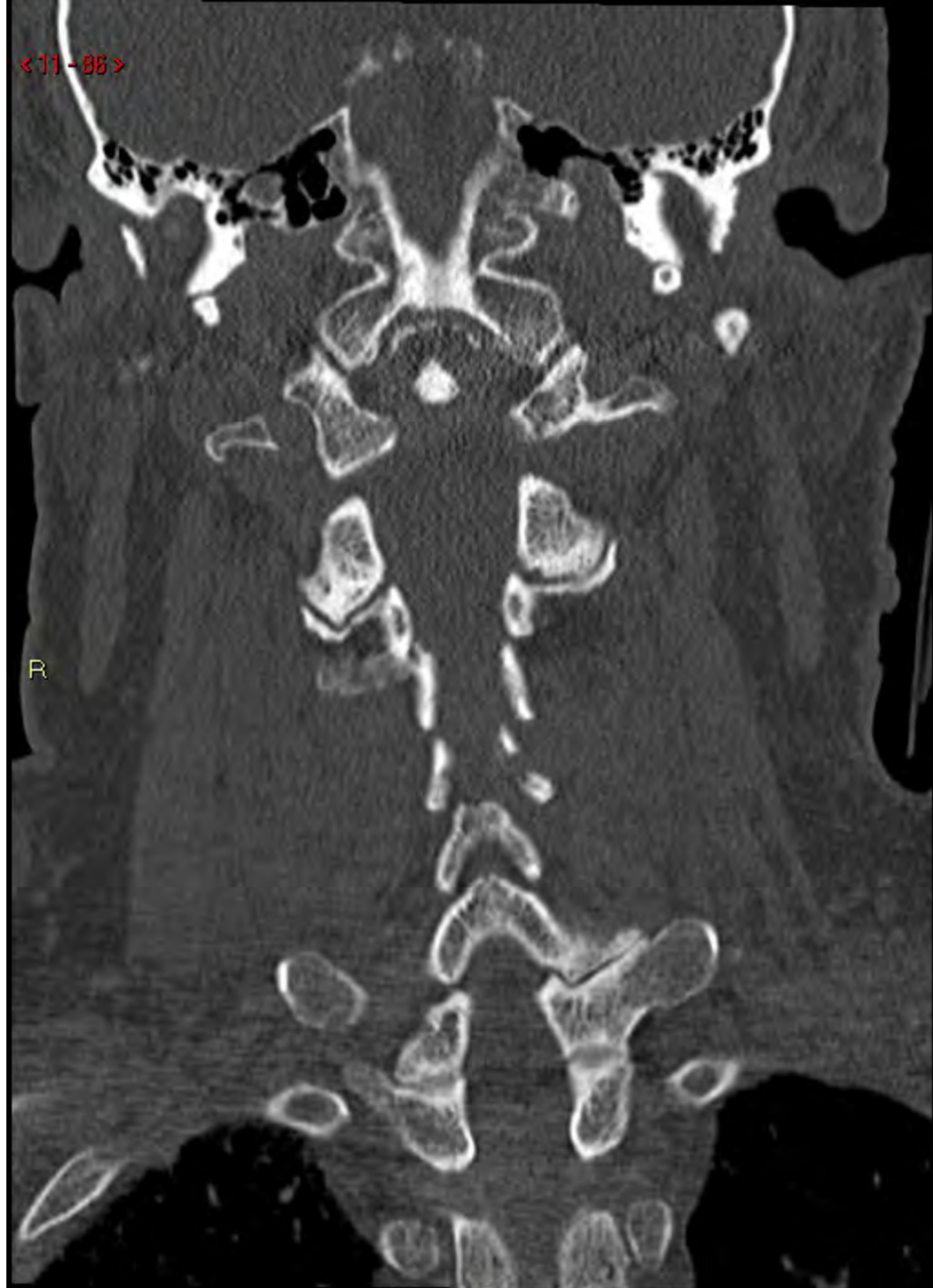
<11-05>

R



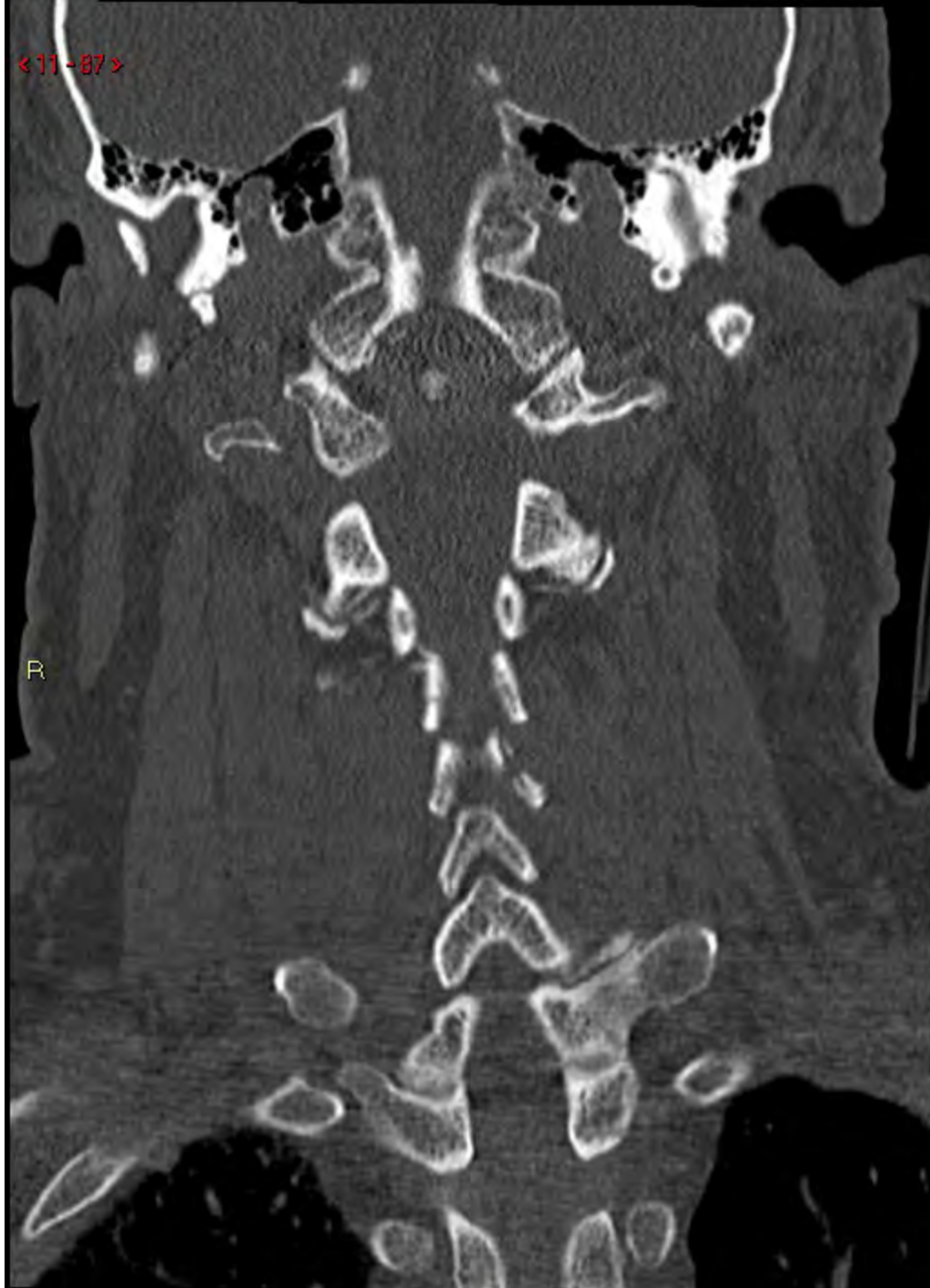
<11-88>

R



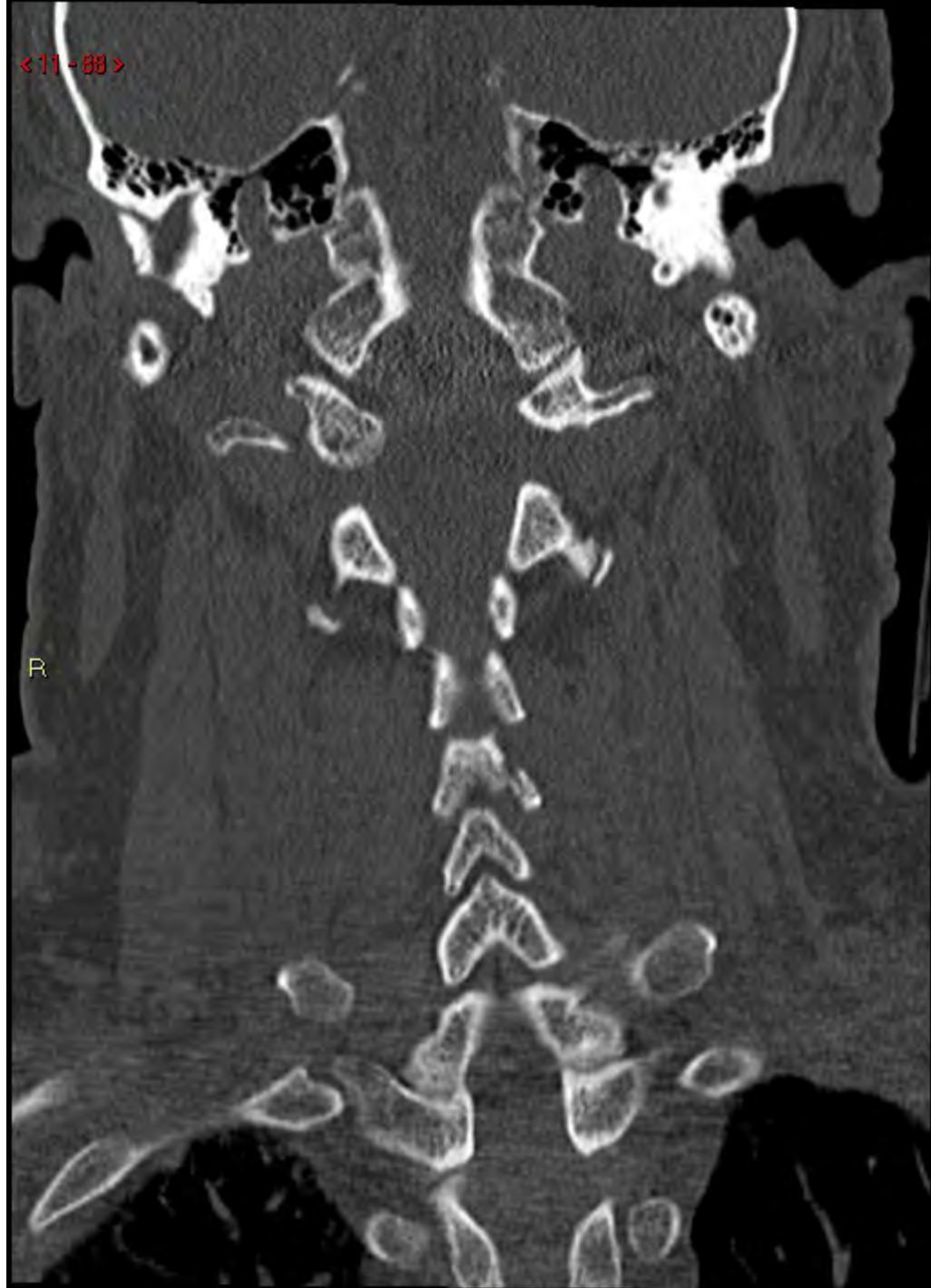
<11-87>

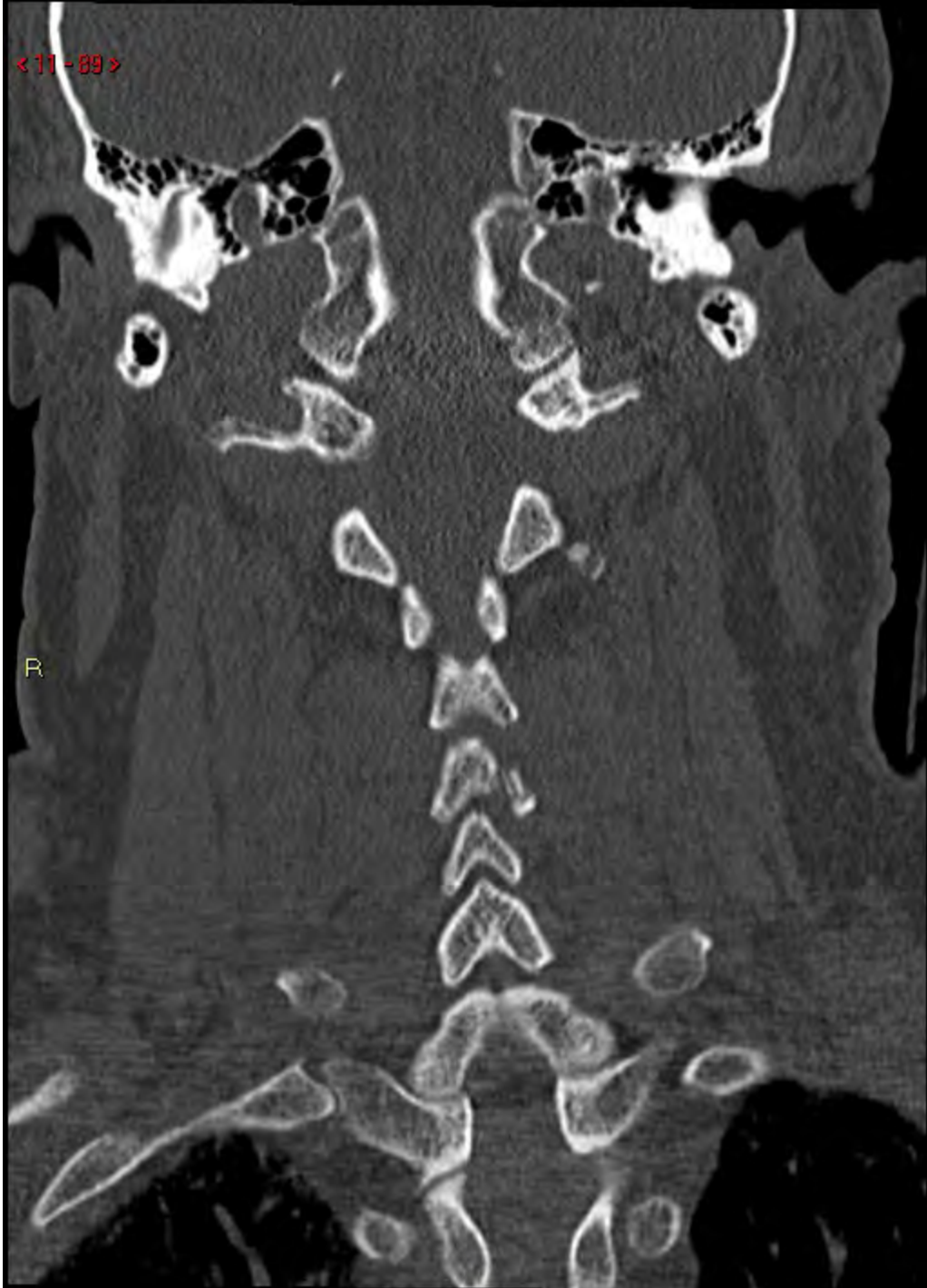R

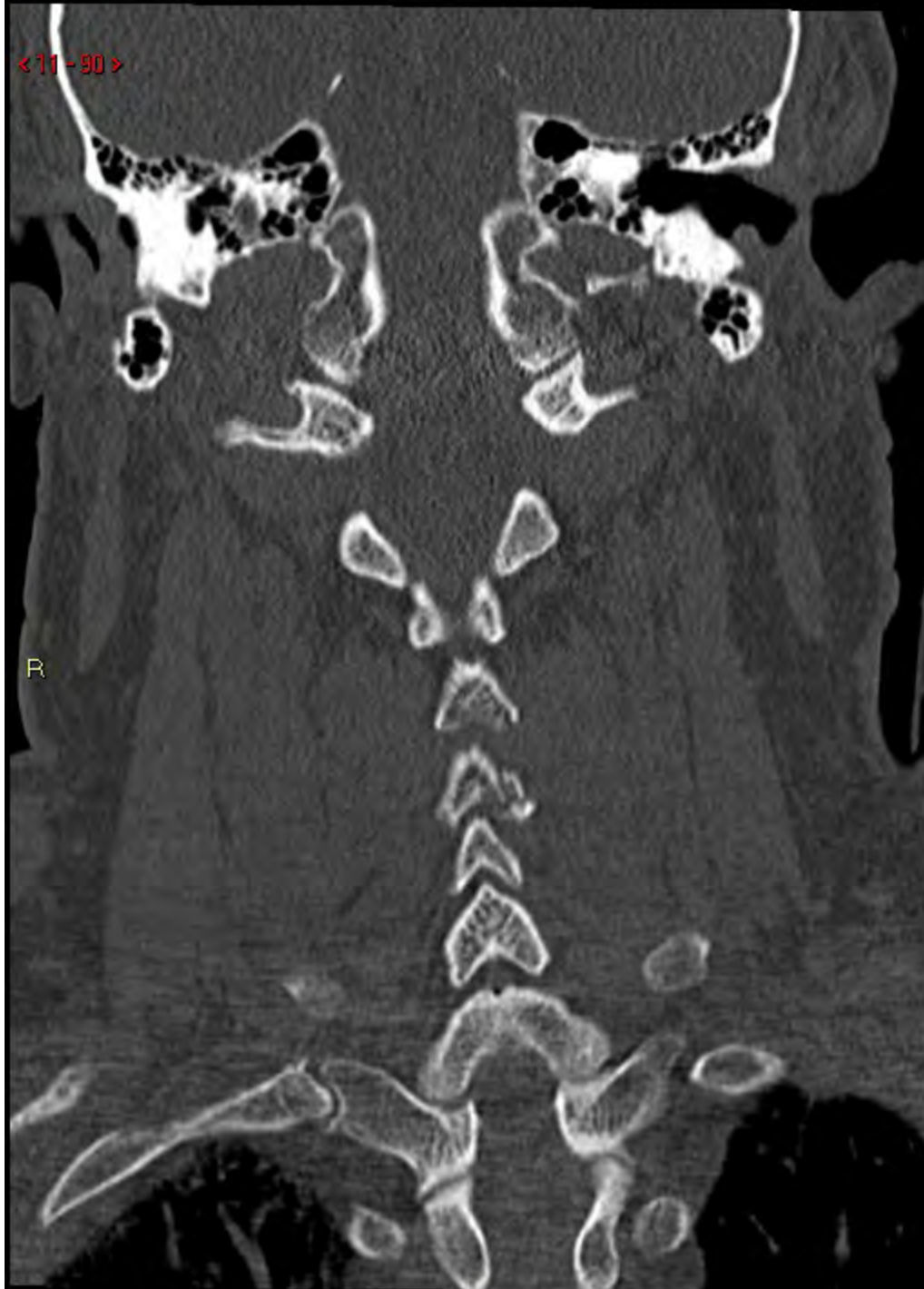

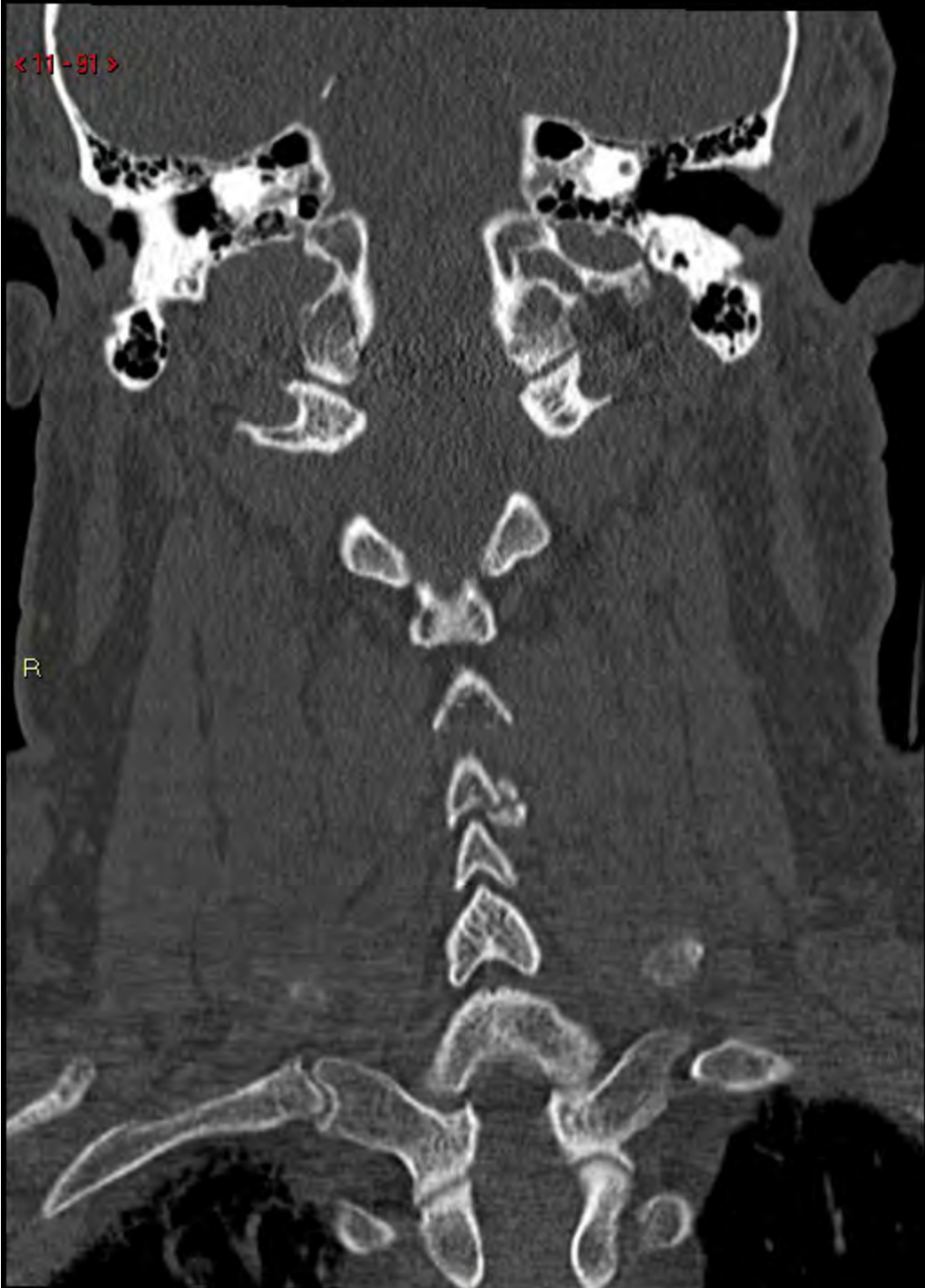< 11 - 68 >

R



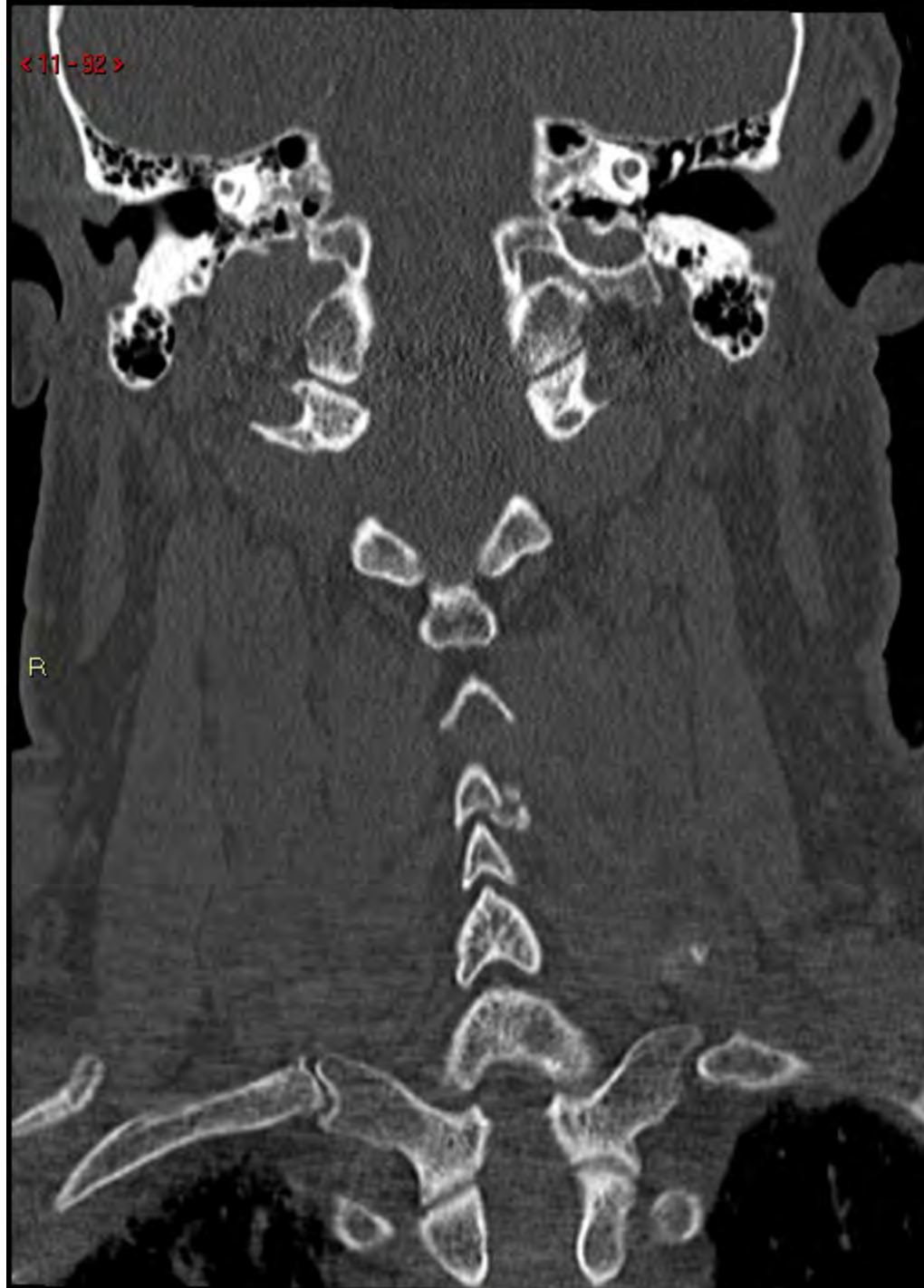






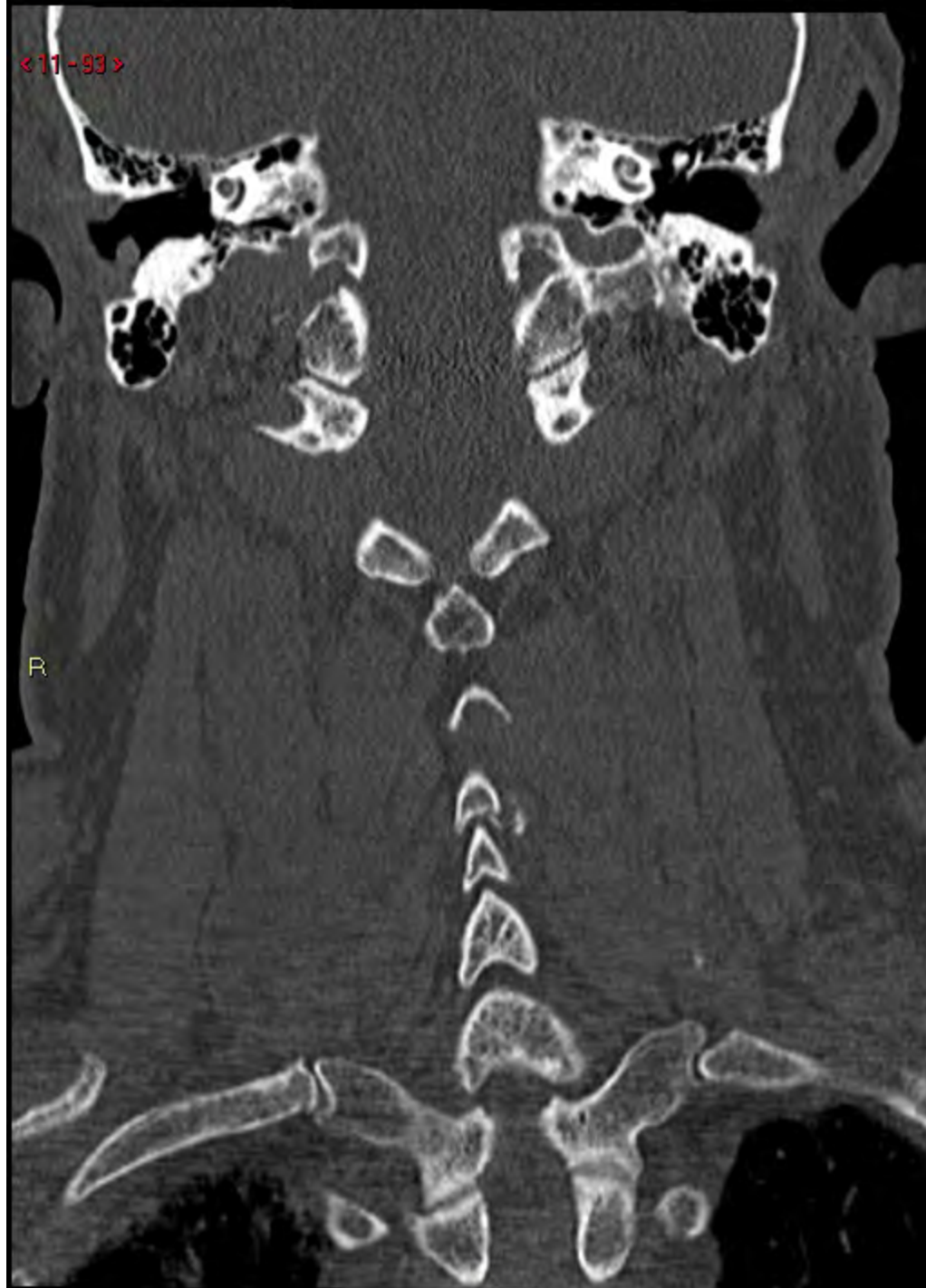< 11 - 92 >

R



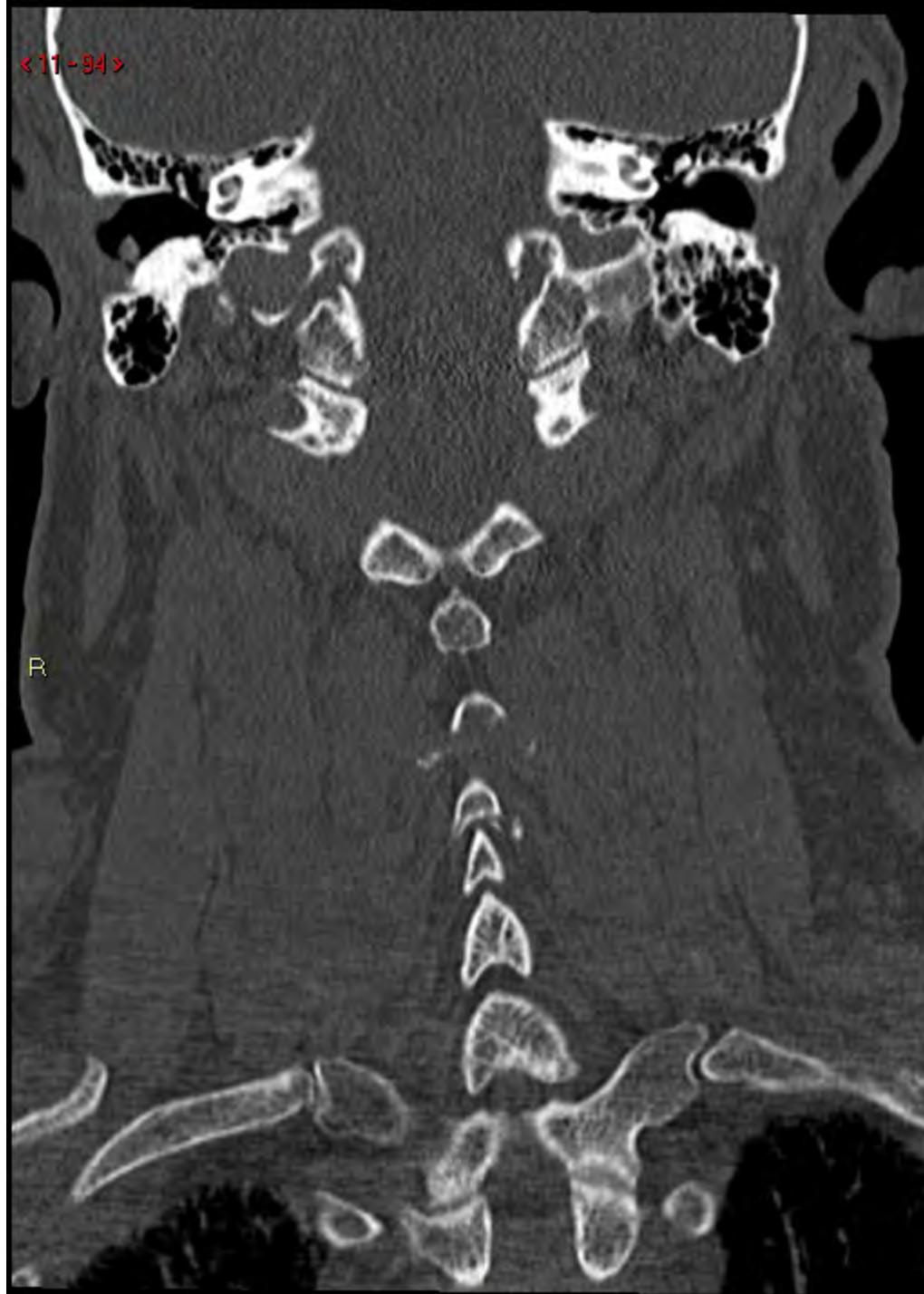<11-93>

R



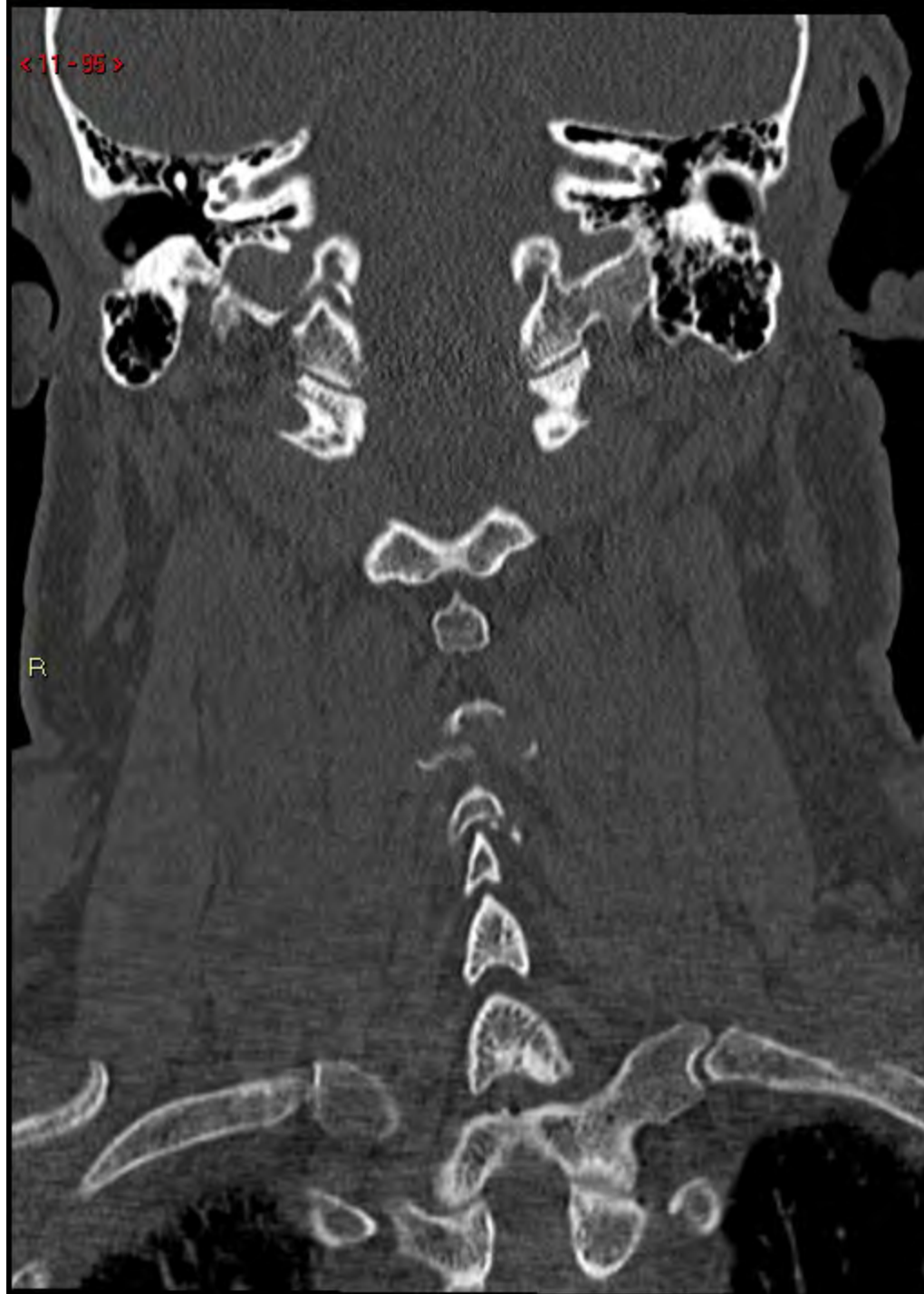
< 11 - 94 >

R



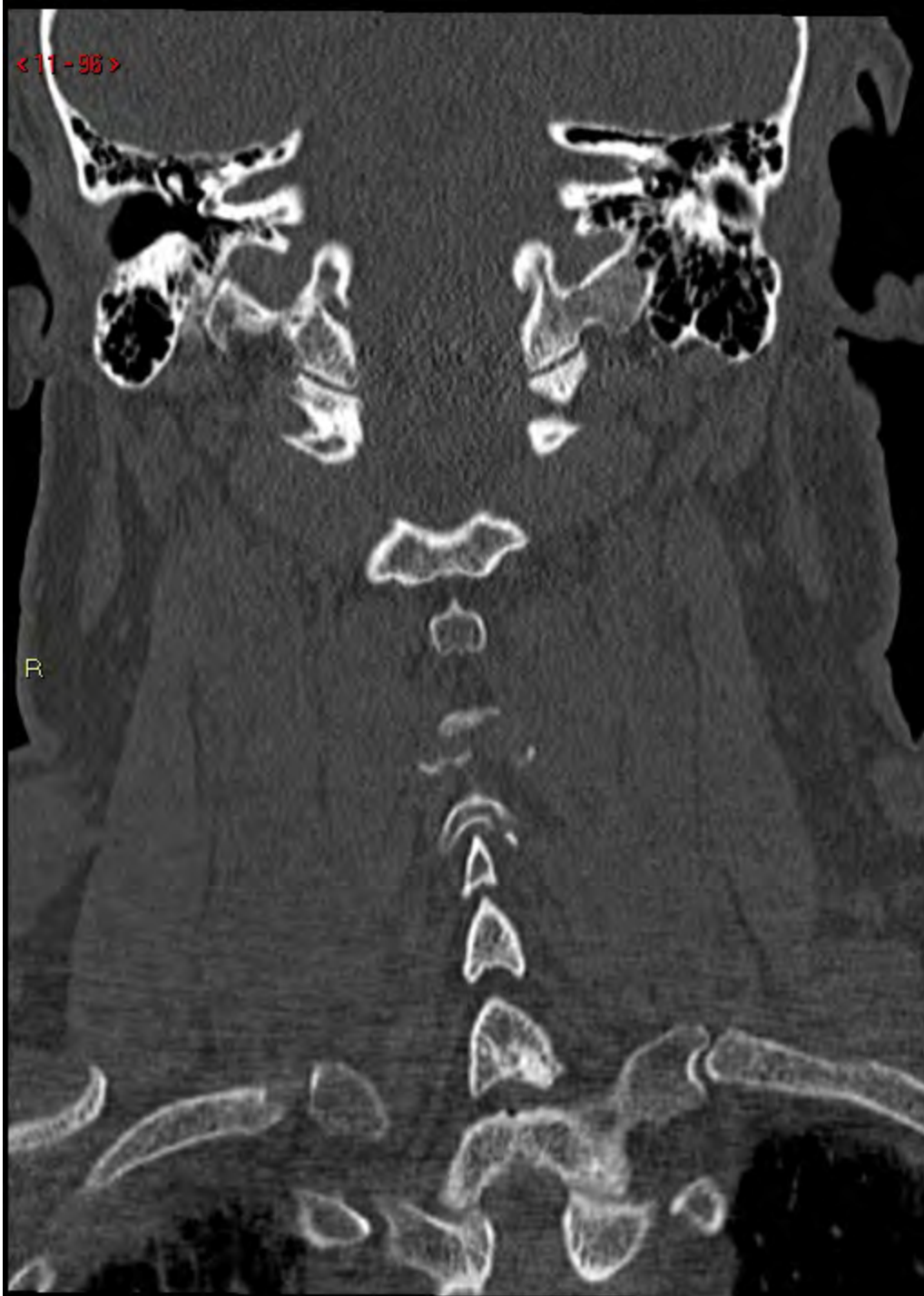
< 11 - 95 >

R



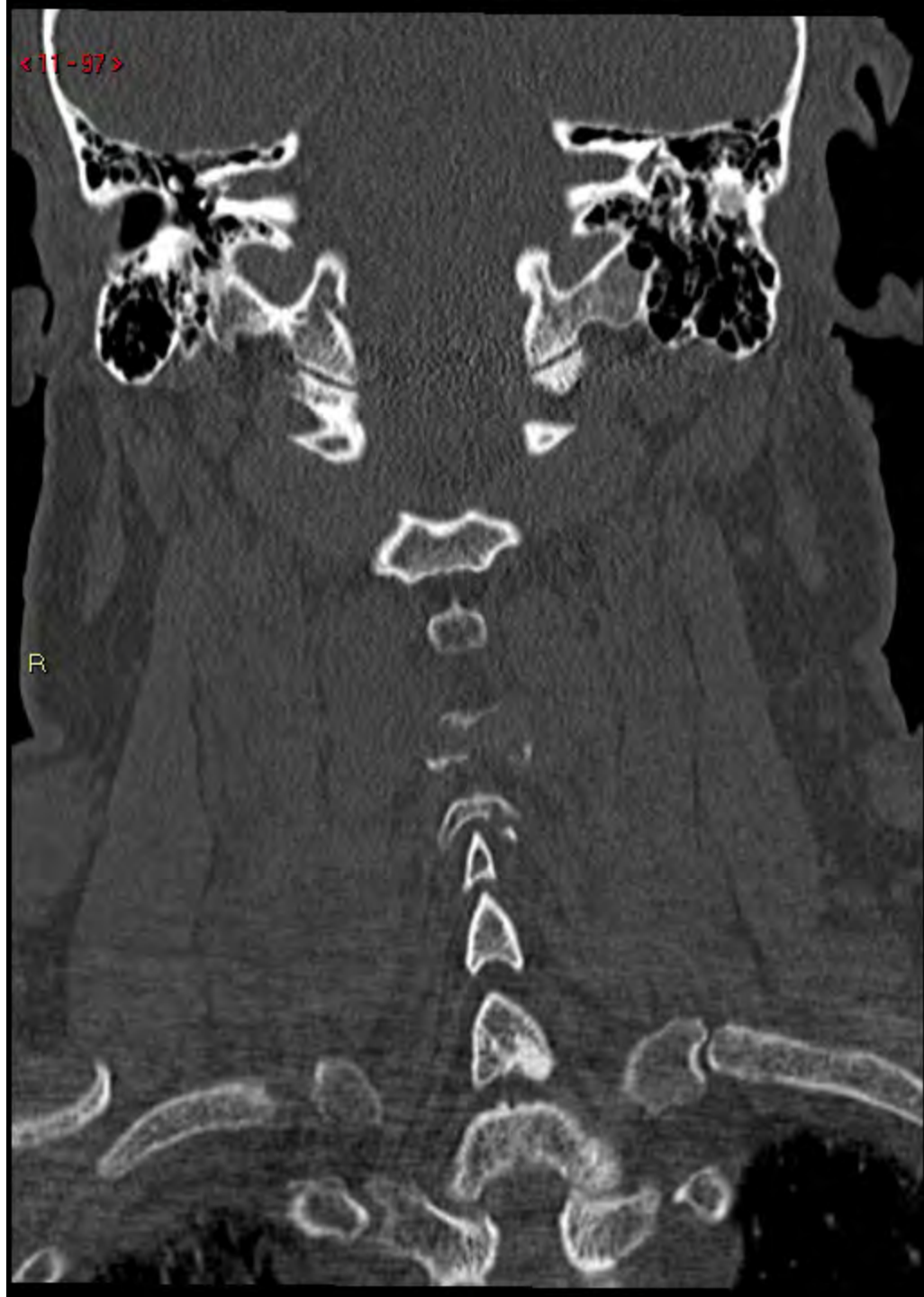< 11 - 98 >

R



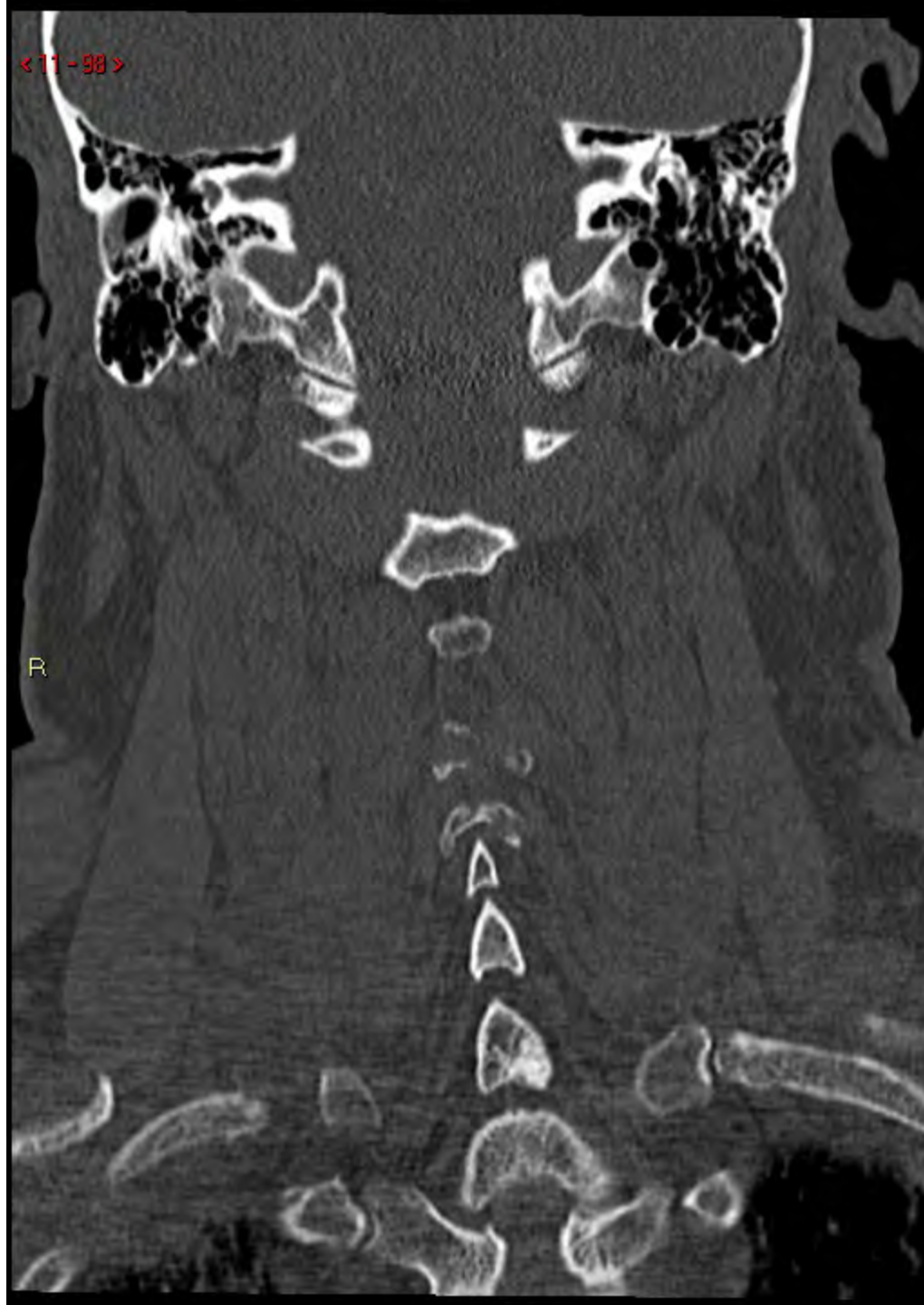<11-97>

R



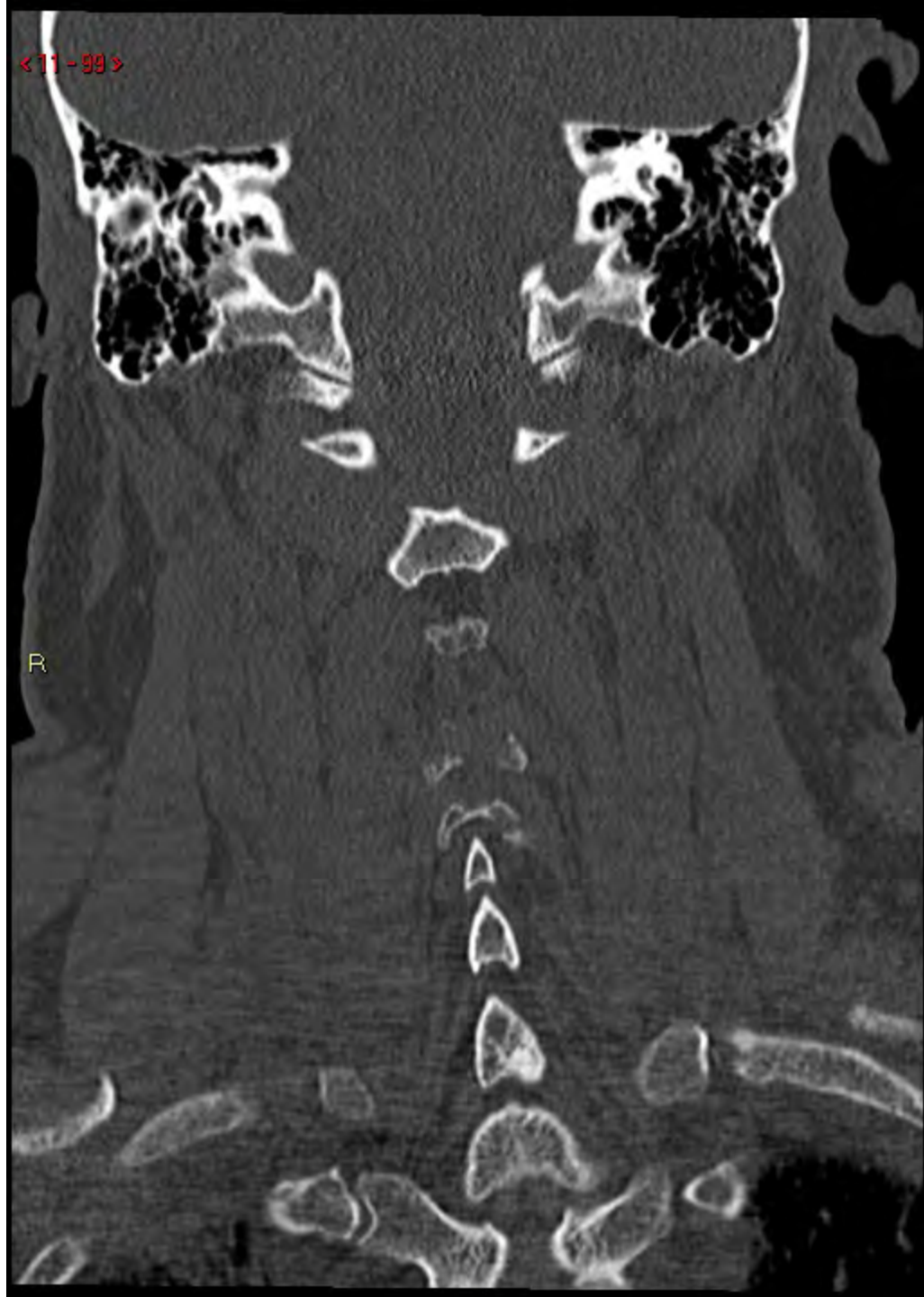< 11 - 98 >

R



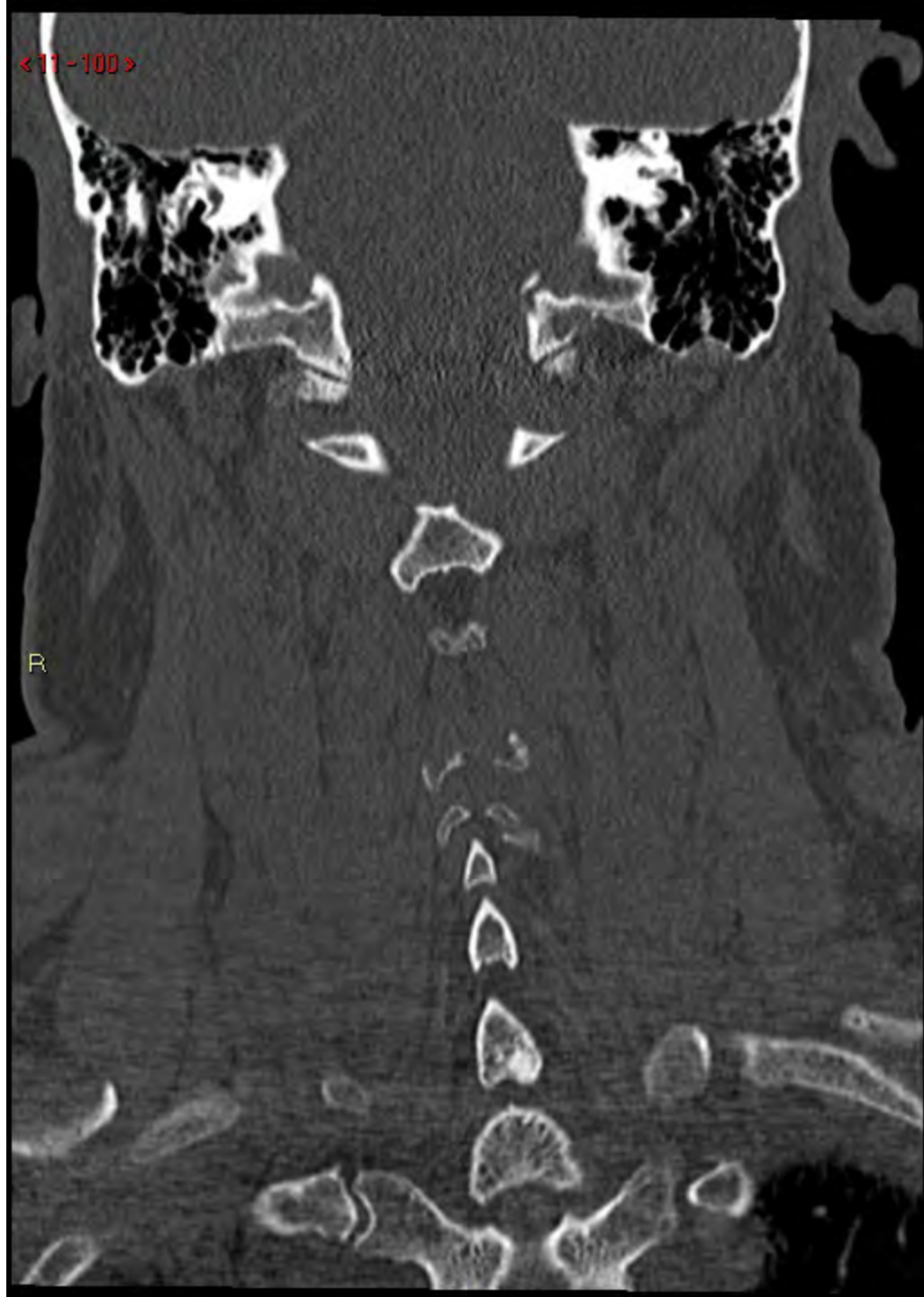< 11 - 99 >

R



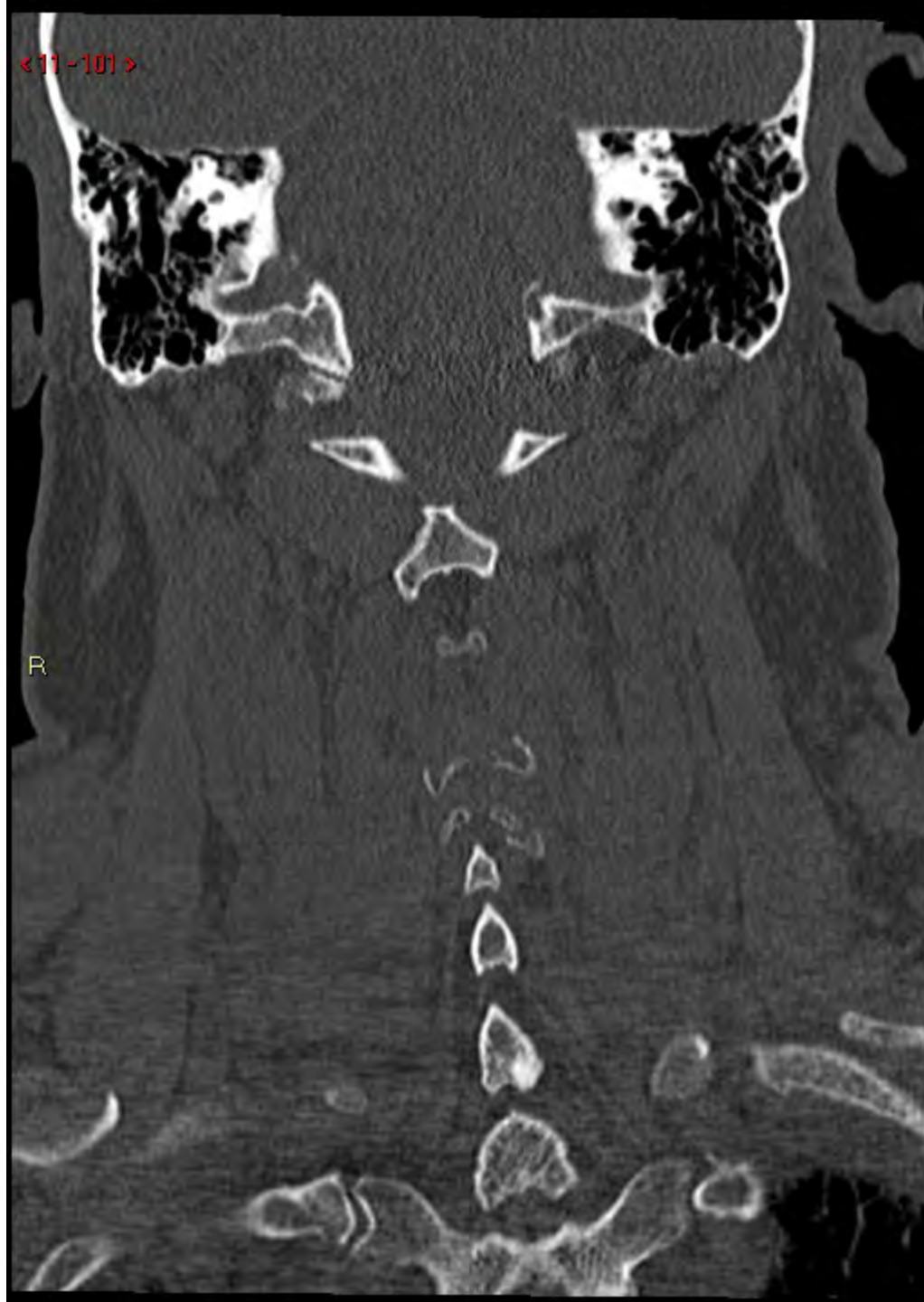< 11 - 100 >

R



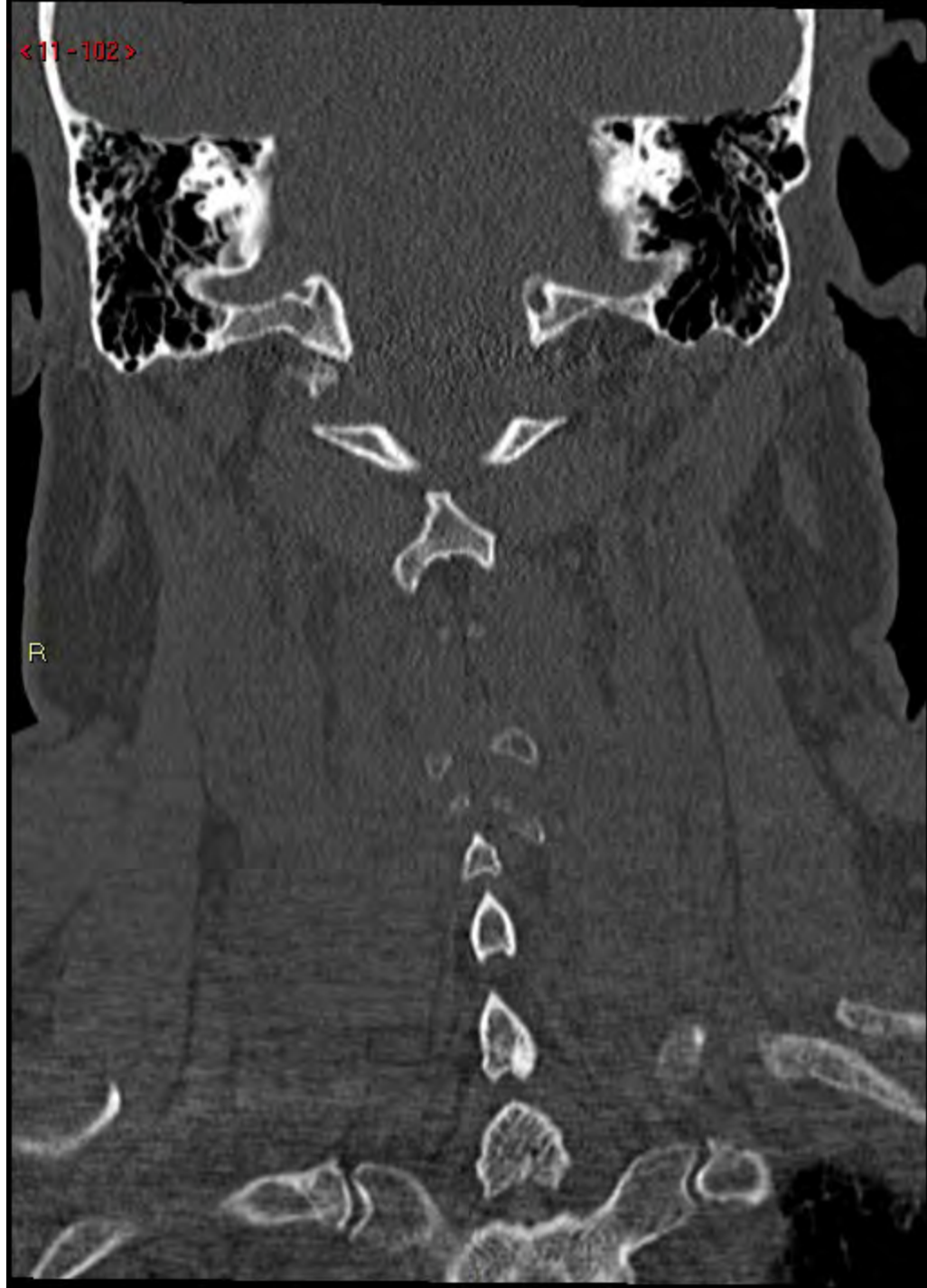
<11-101>

R



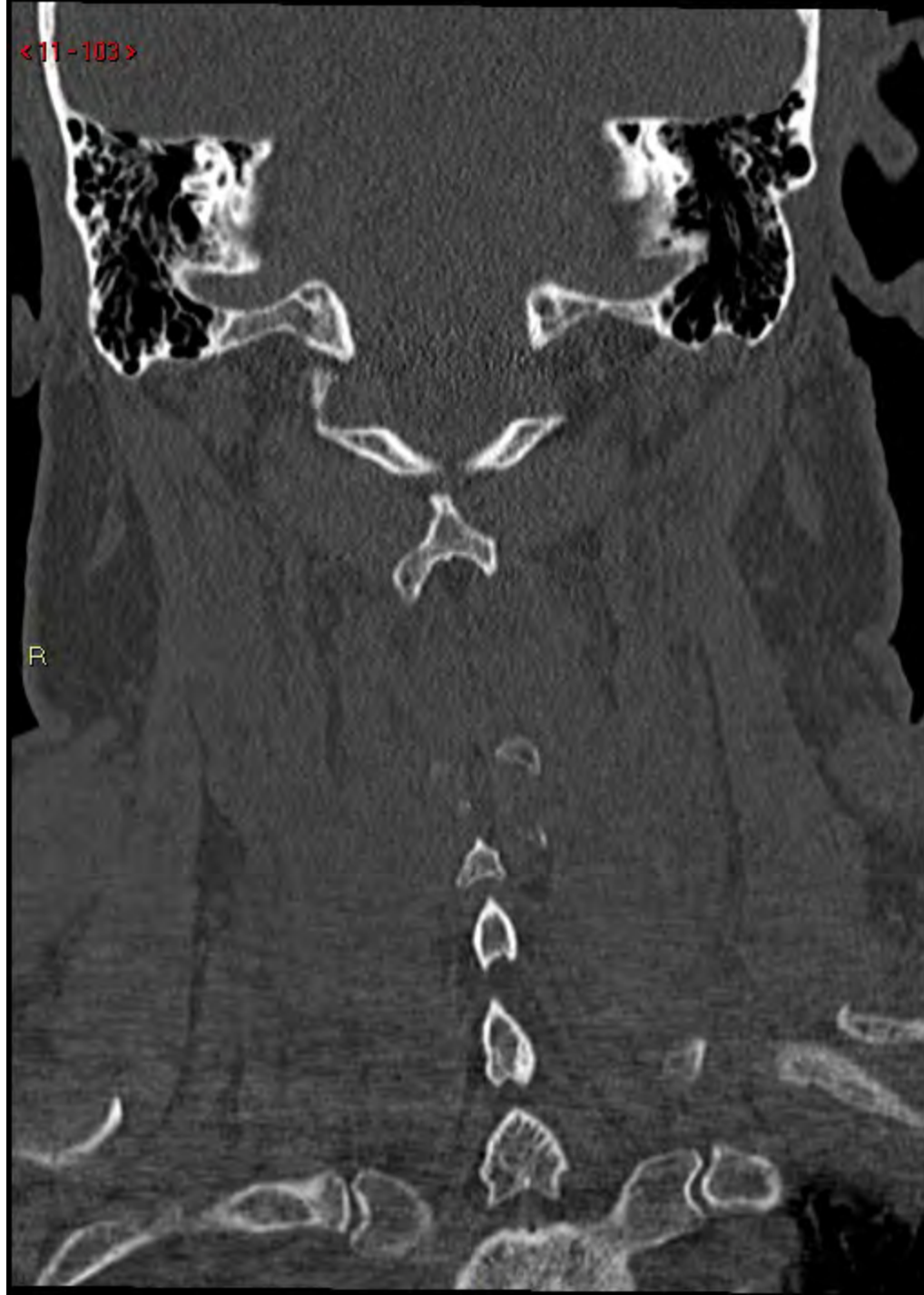<11-102>

R



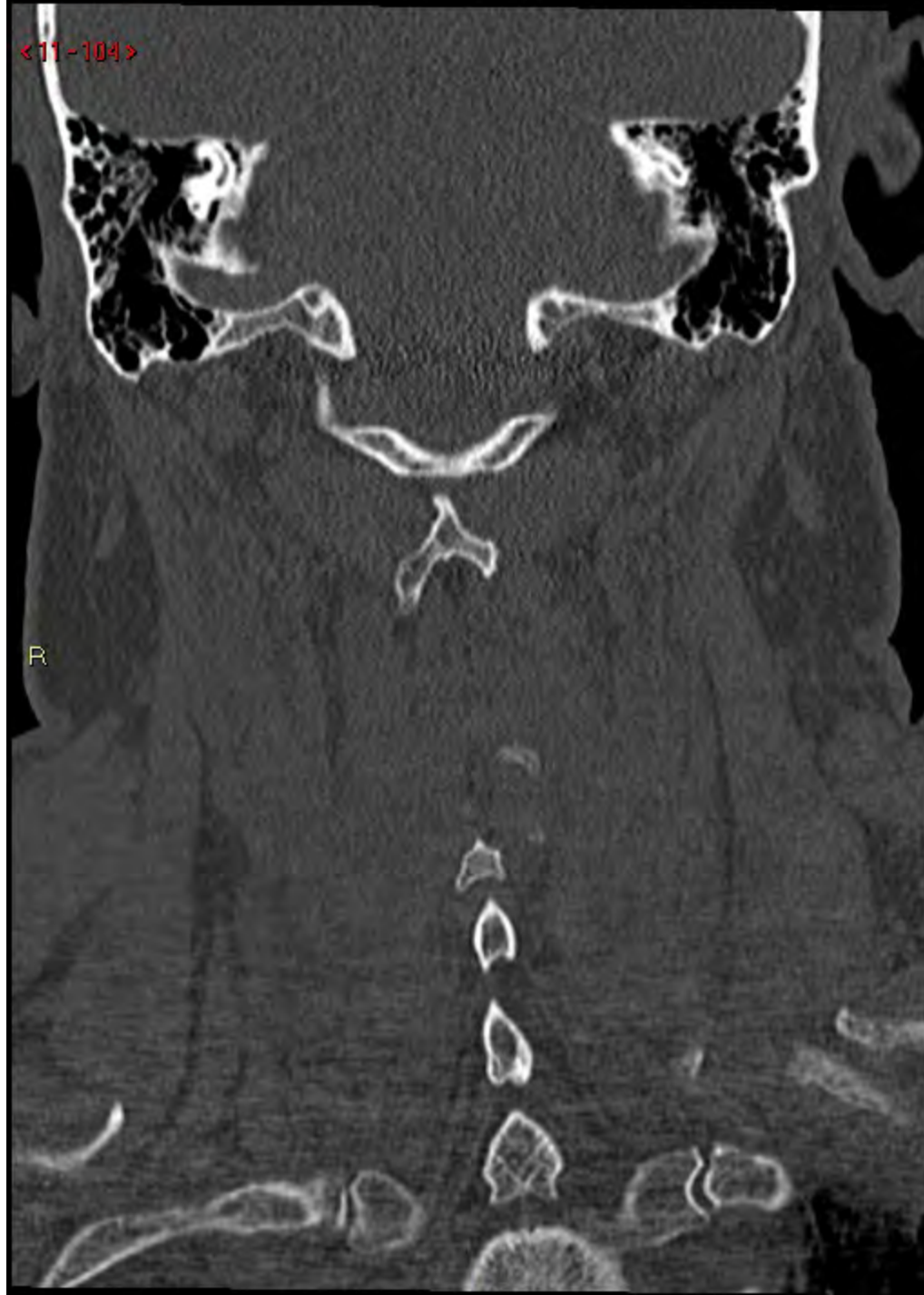<11-103>

R



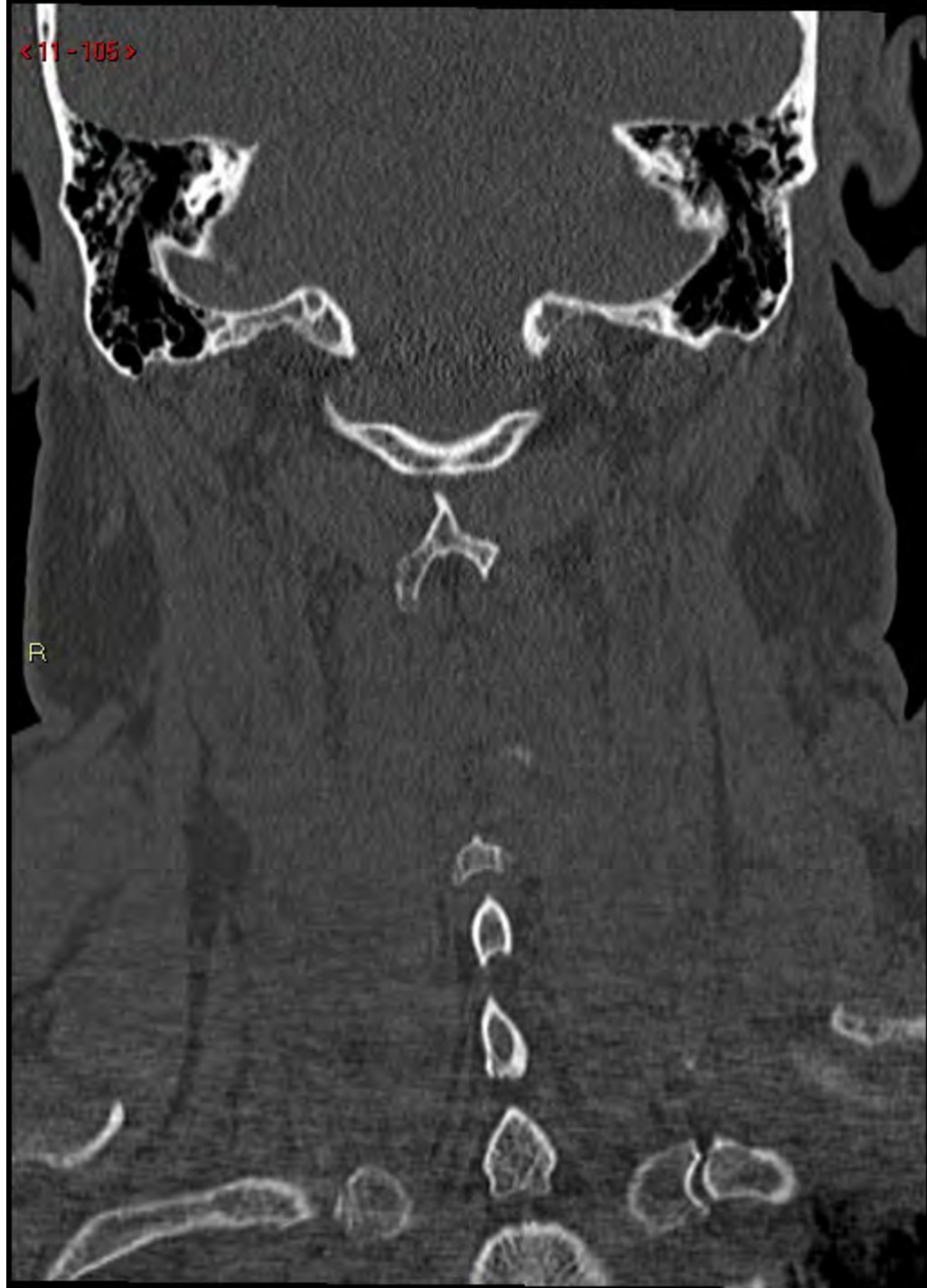<11-104>

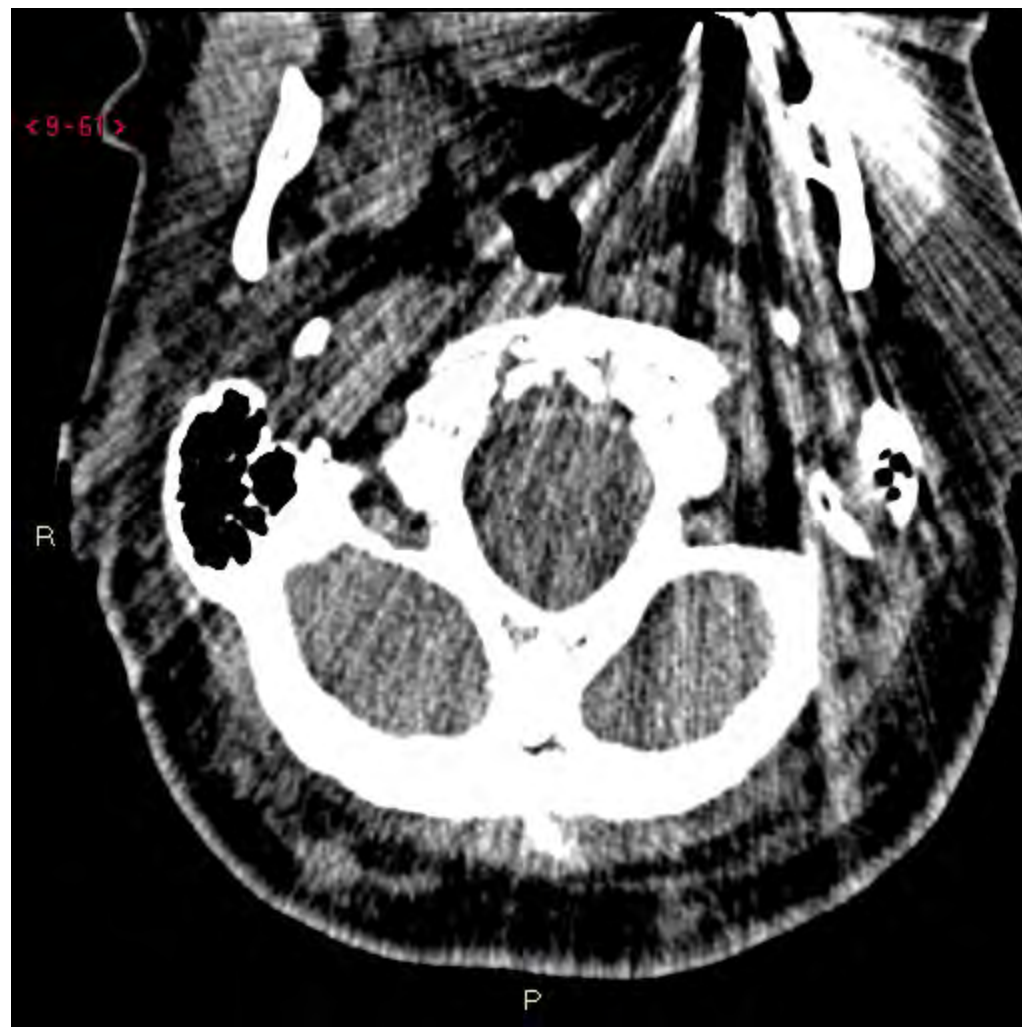
R

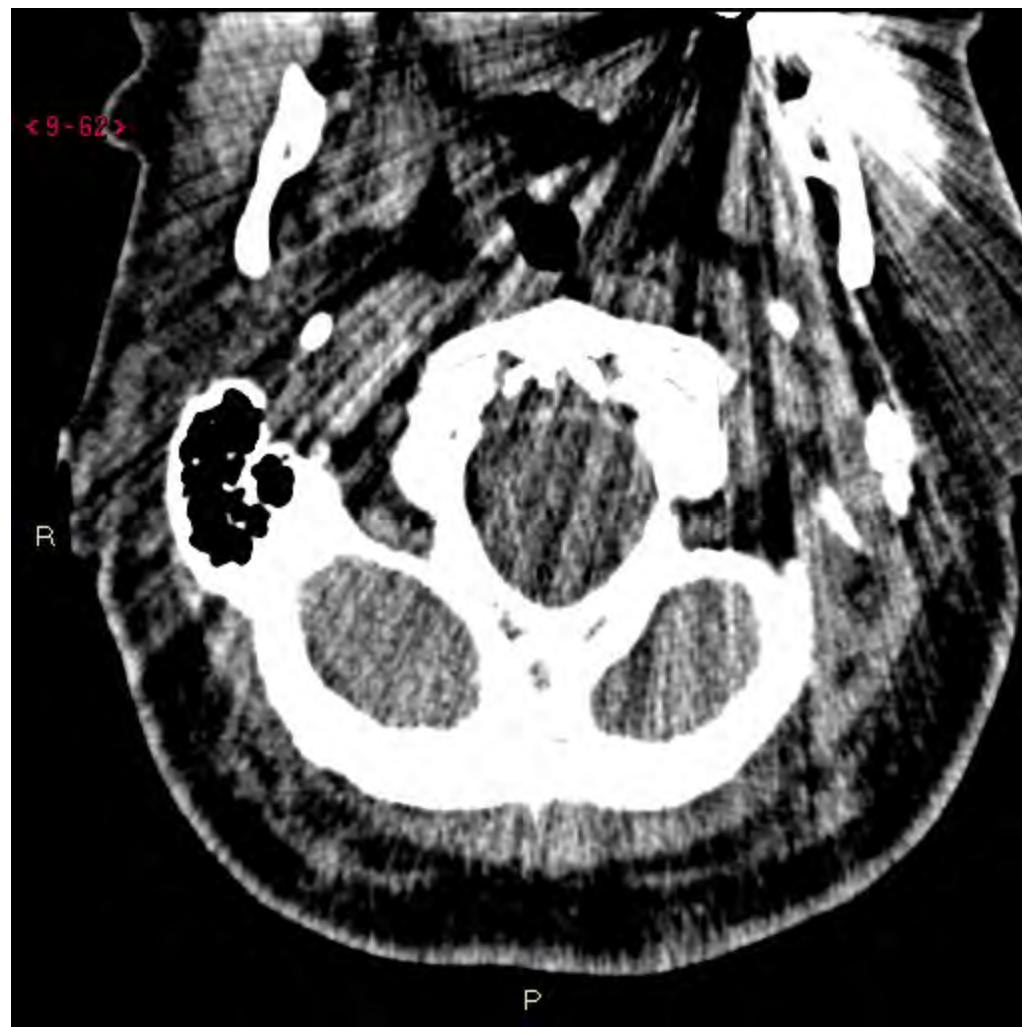

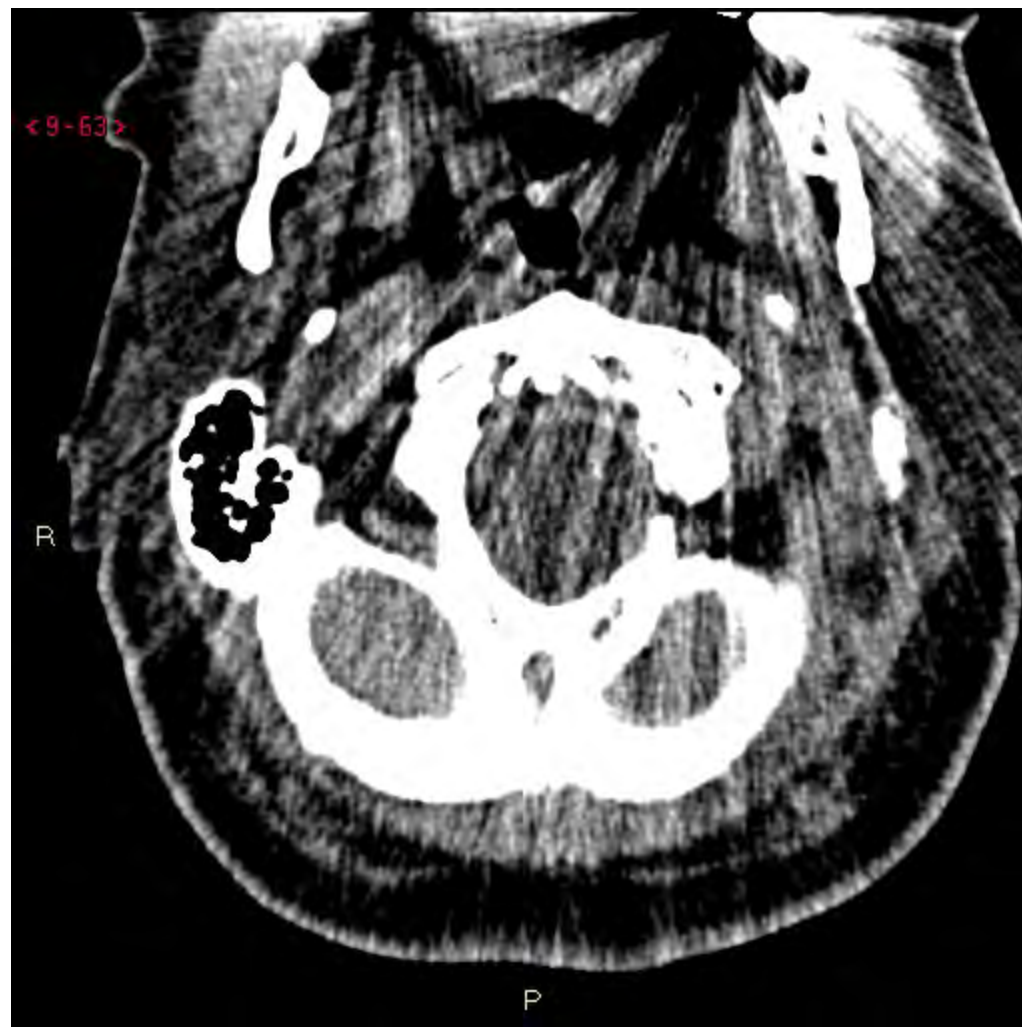<11-105>

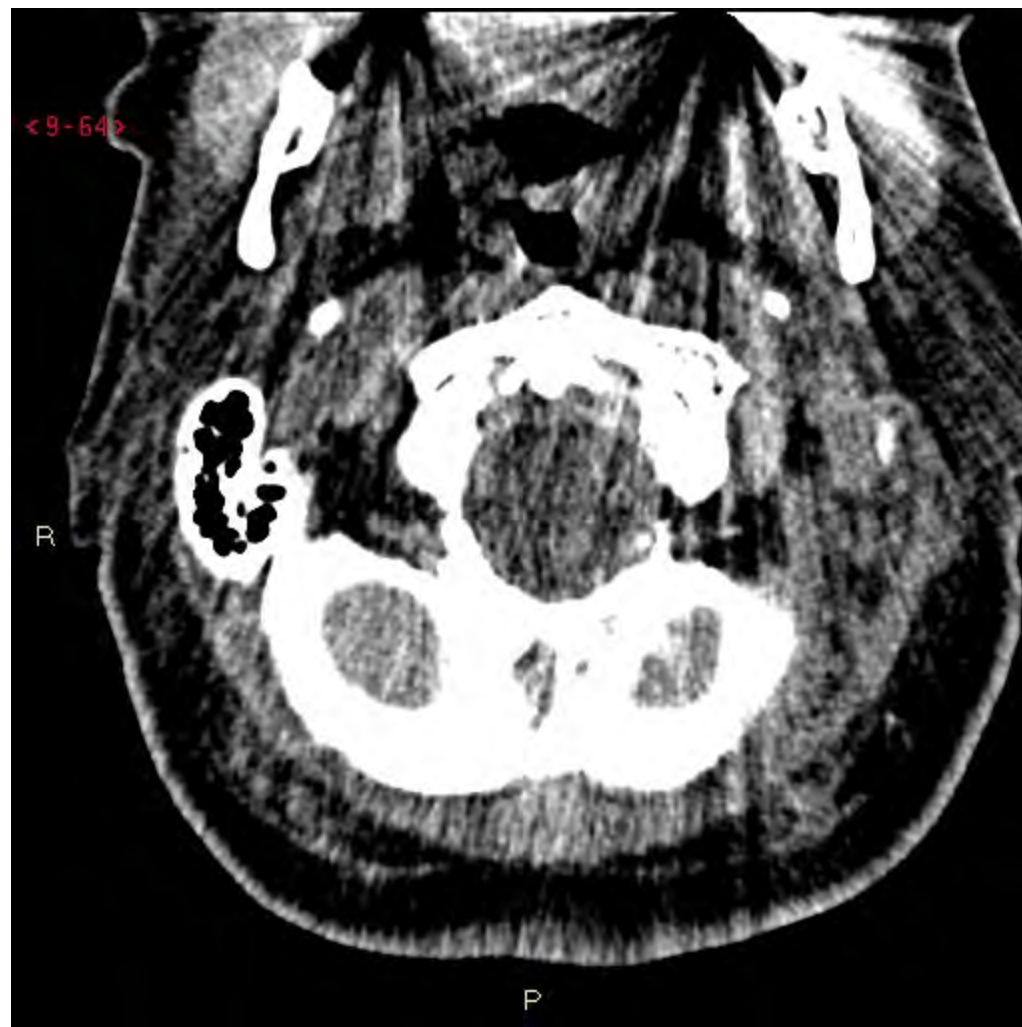R

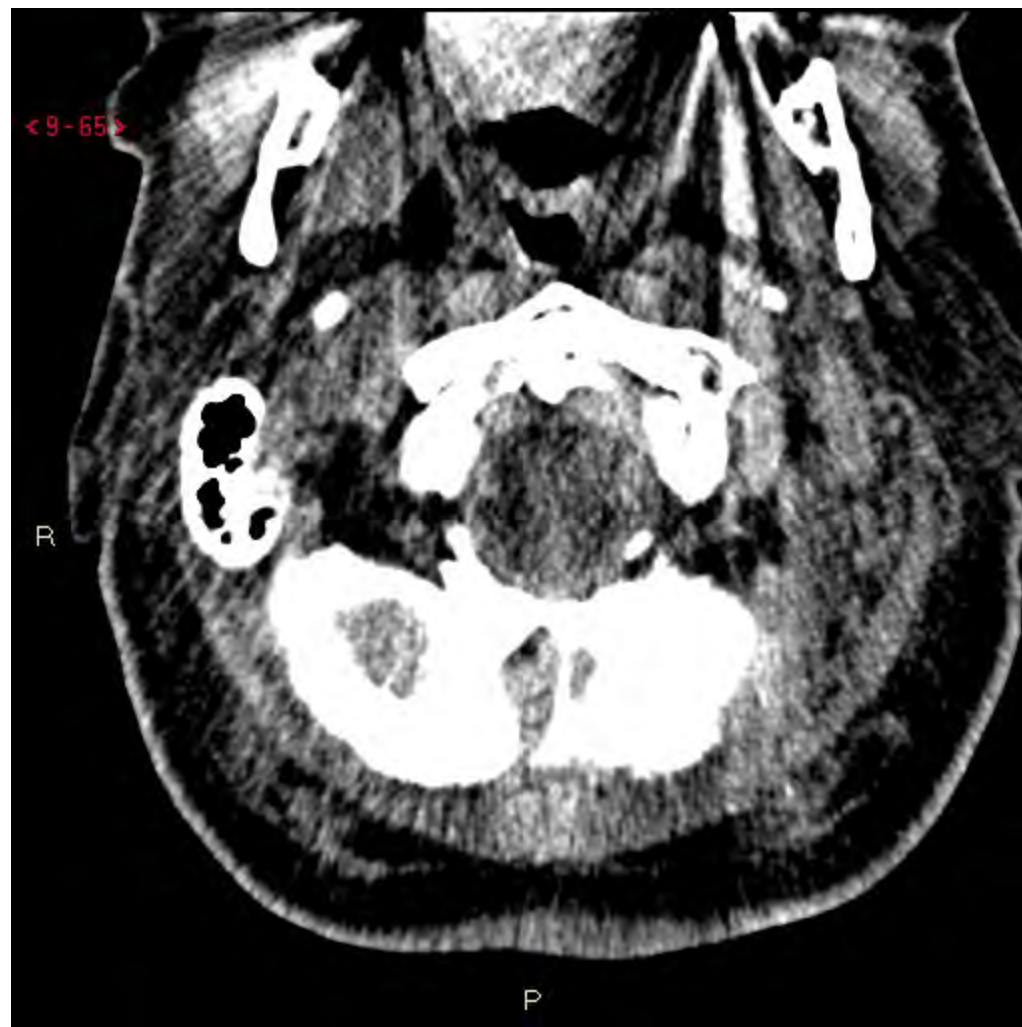


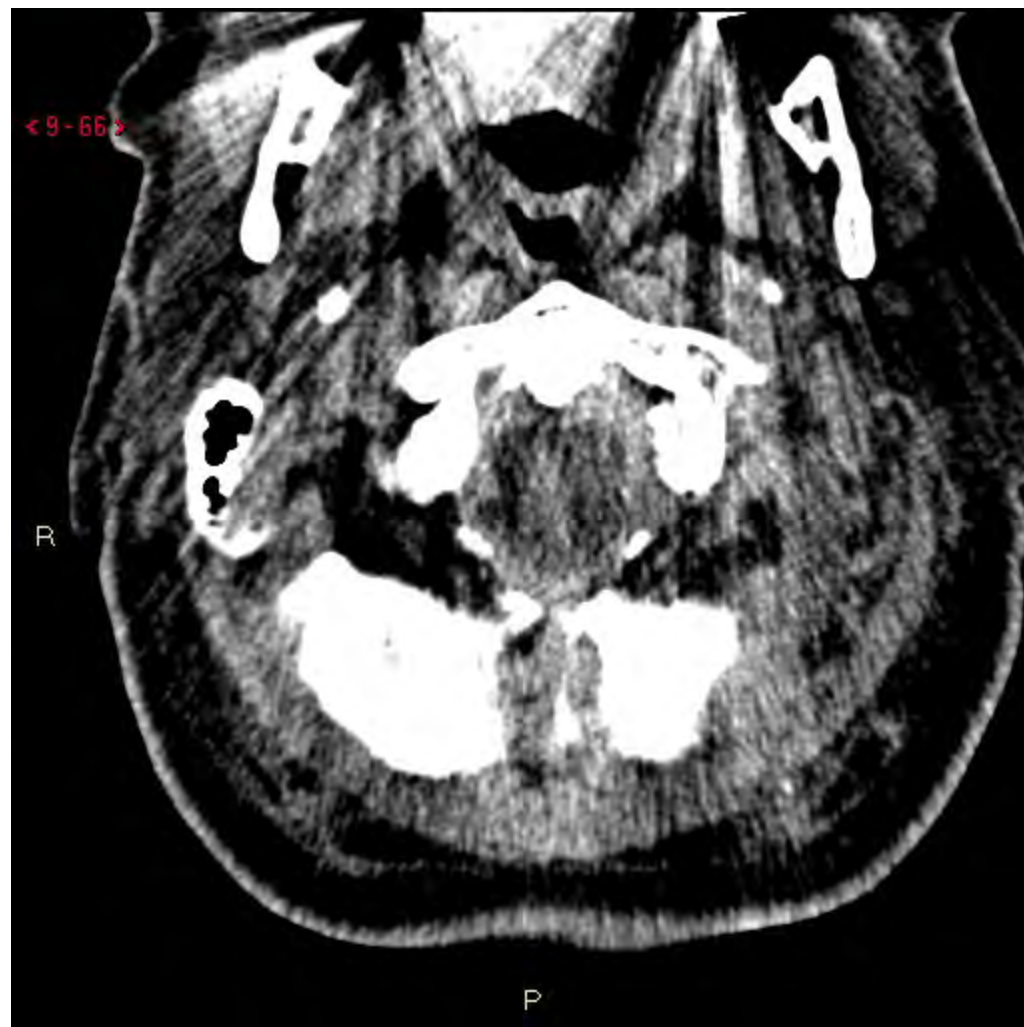


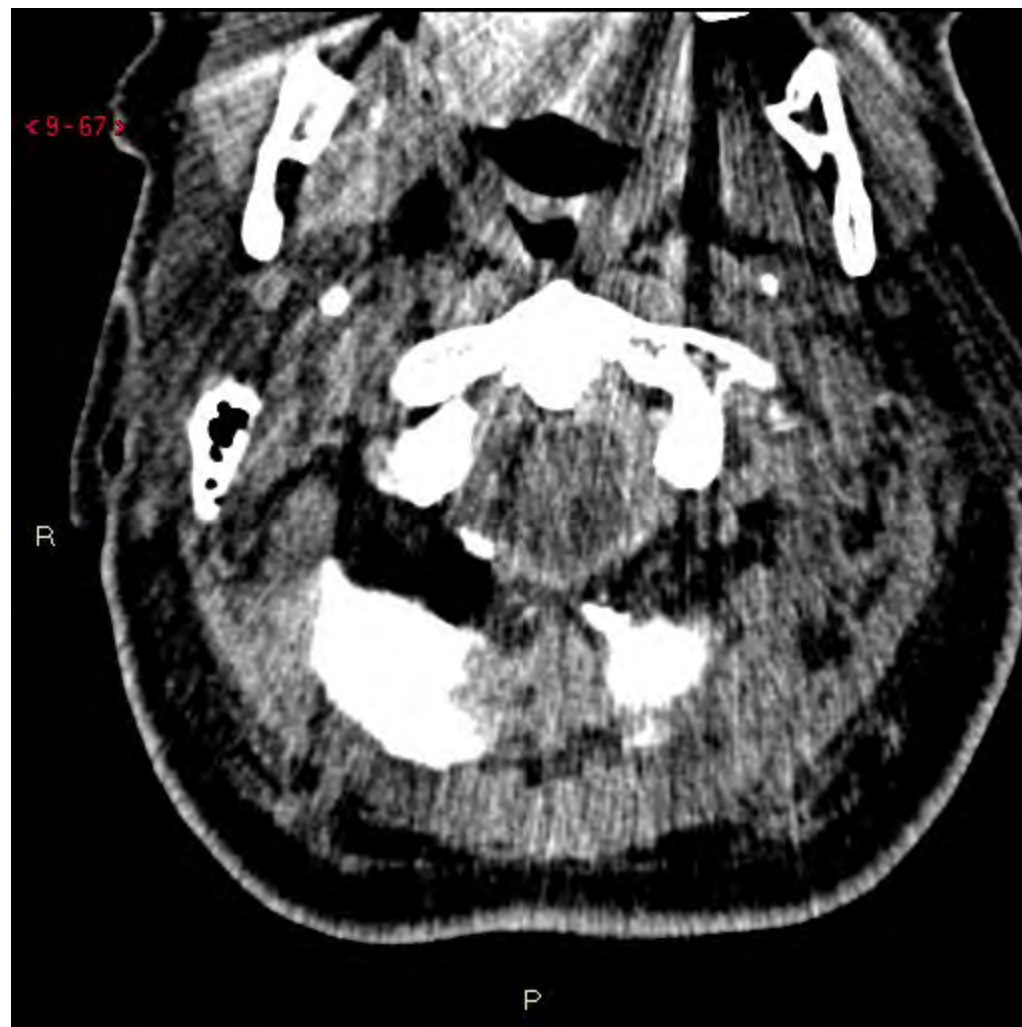


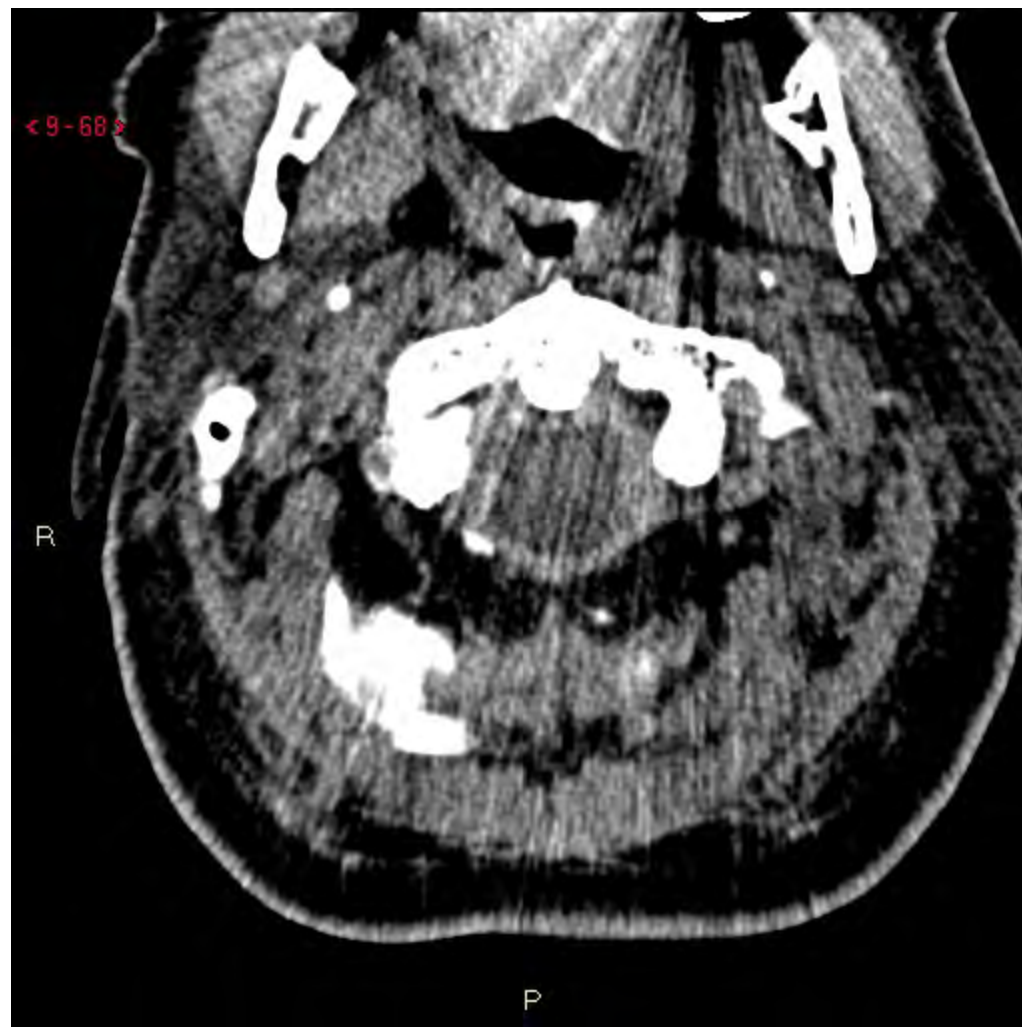


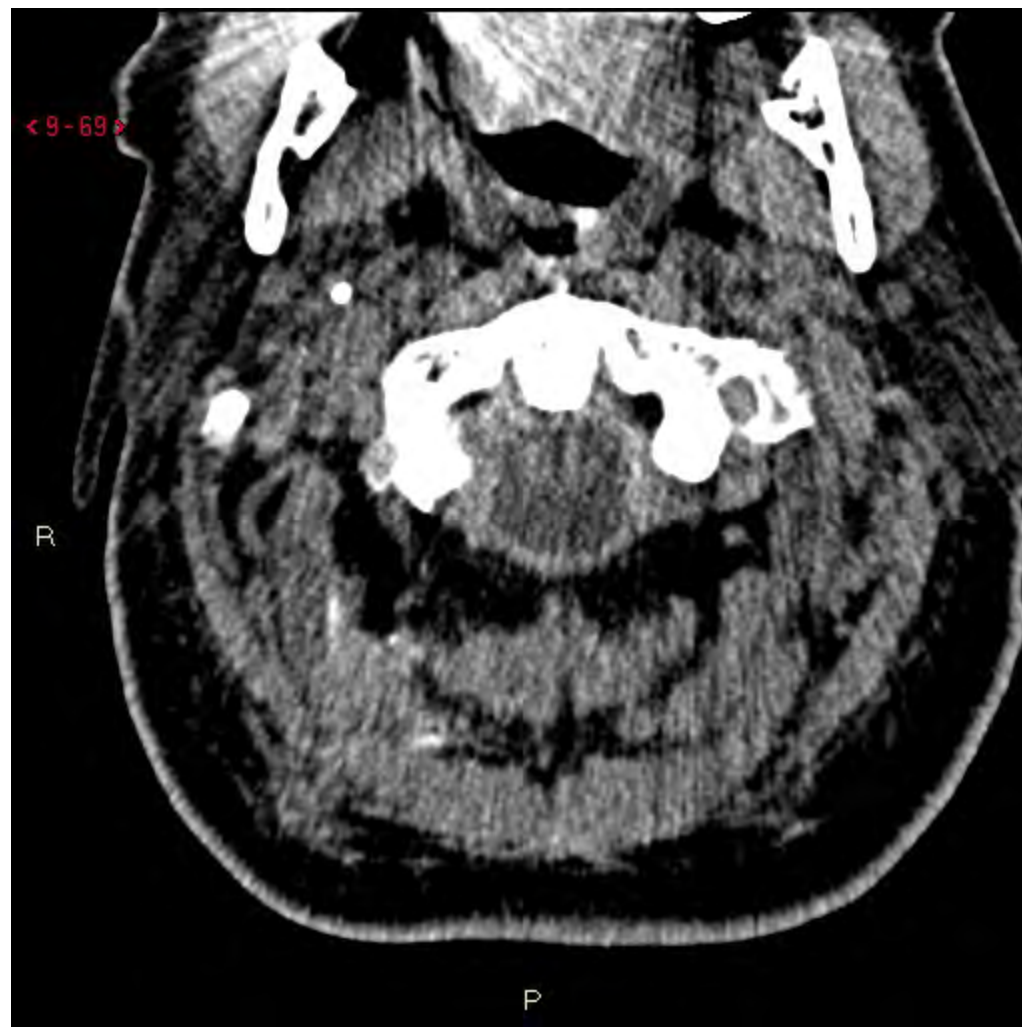


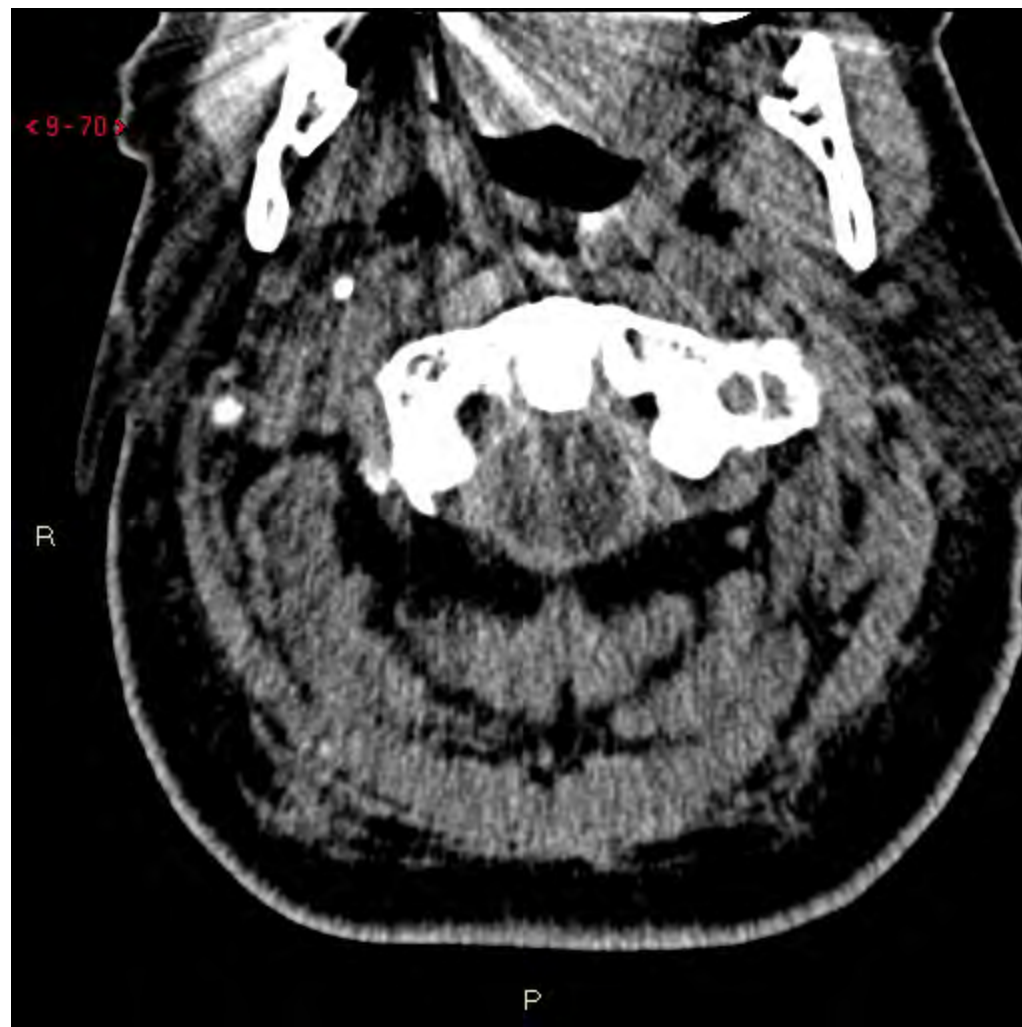


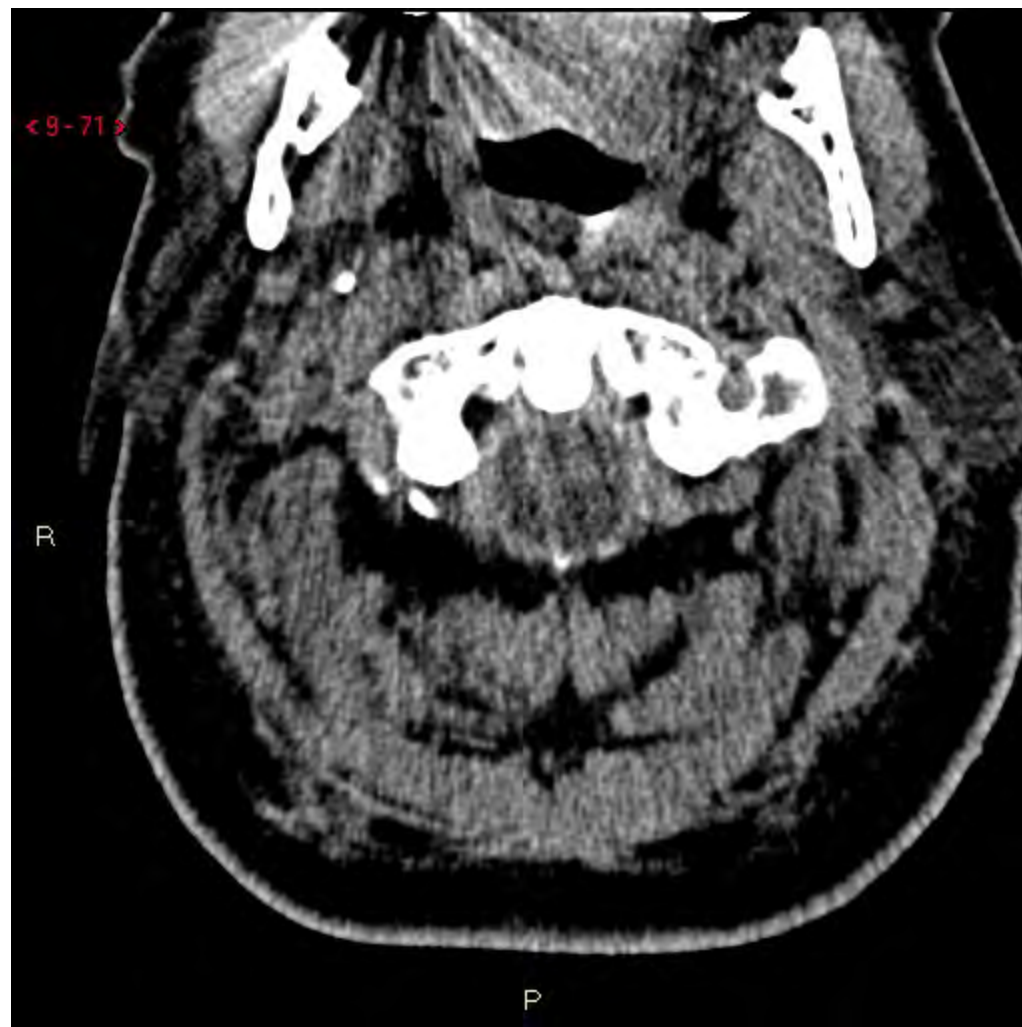


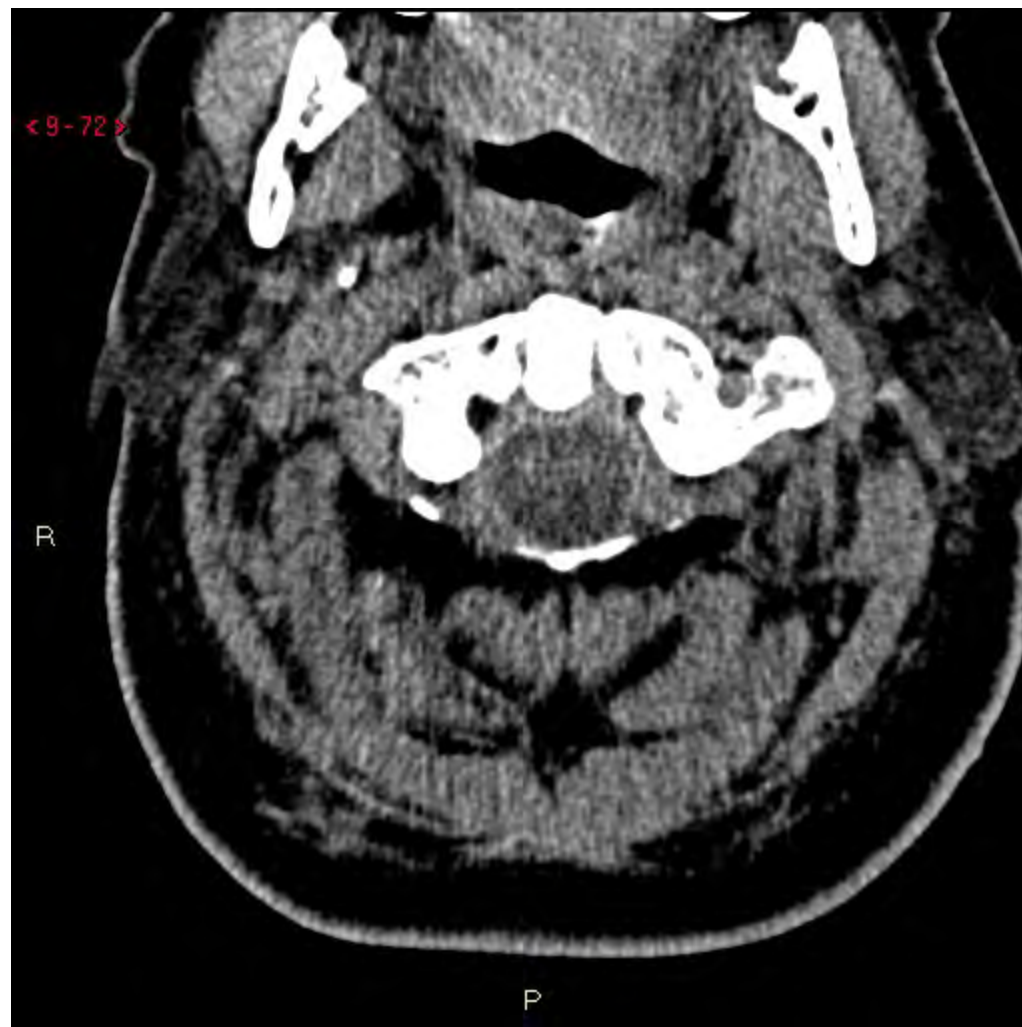


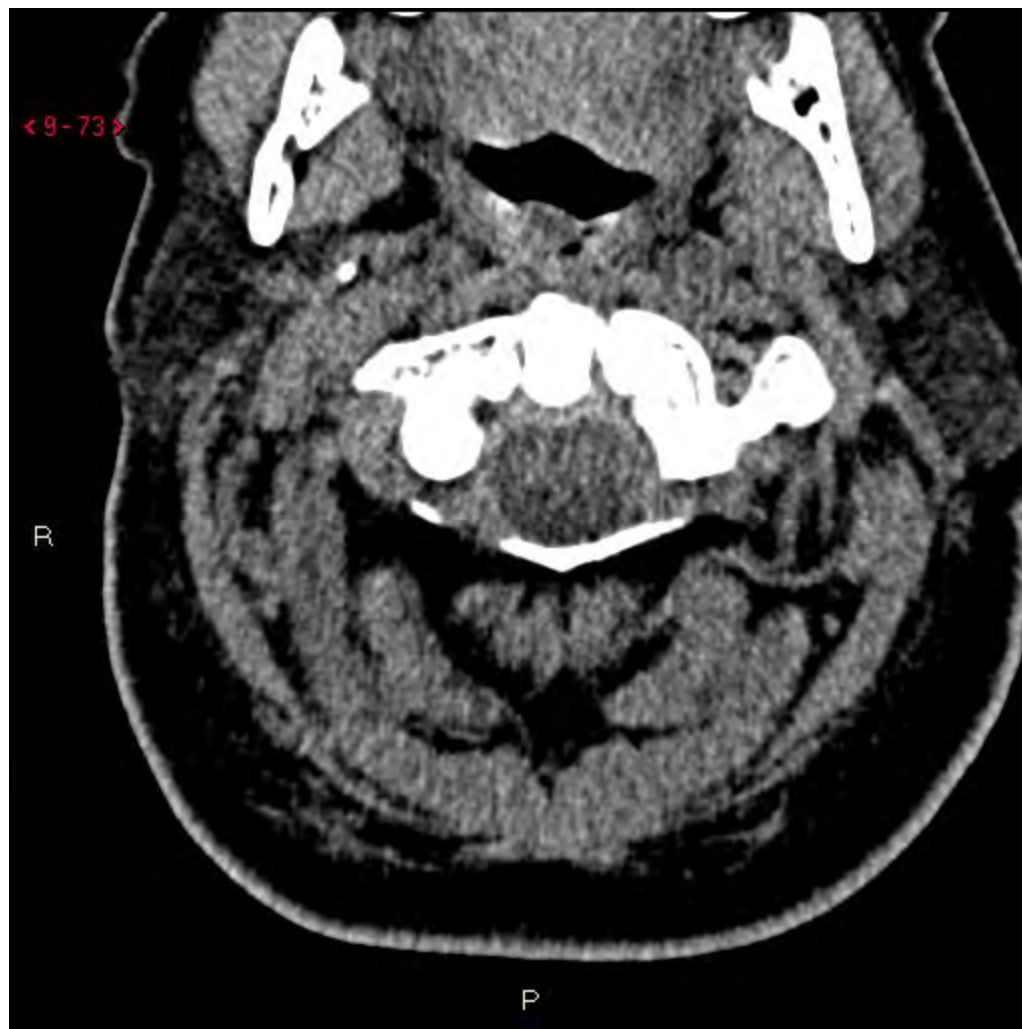


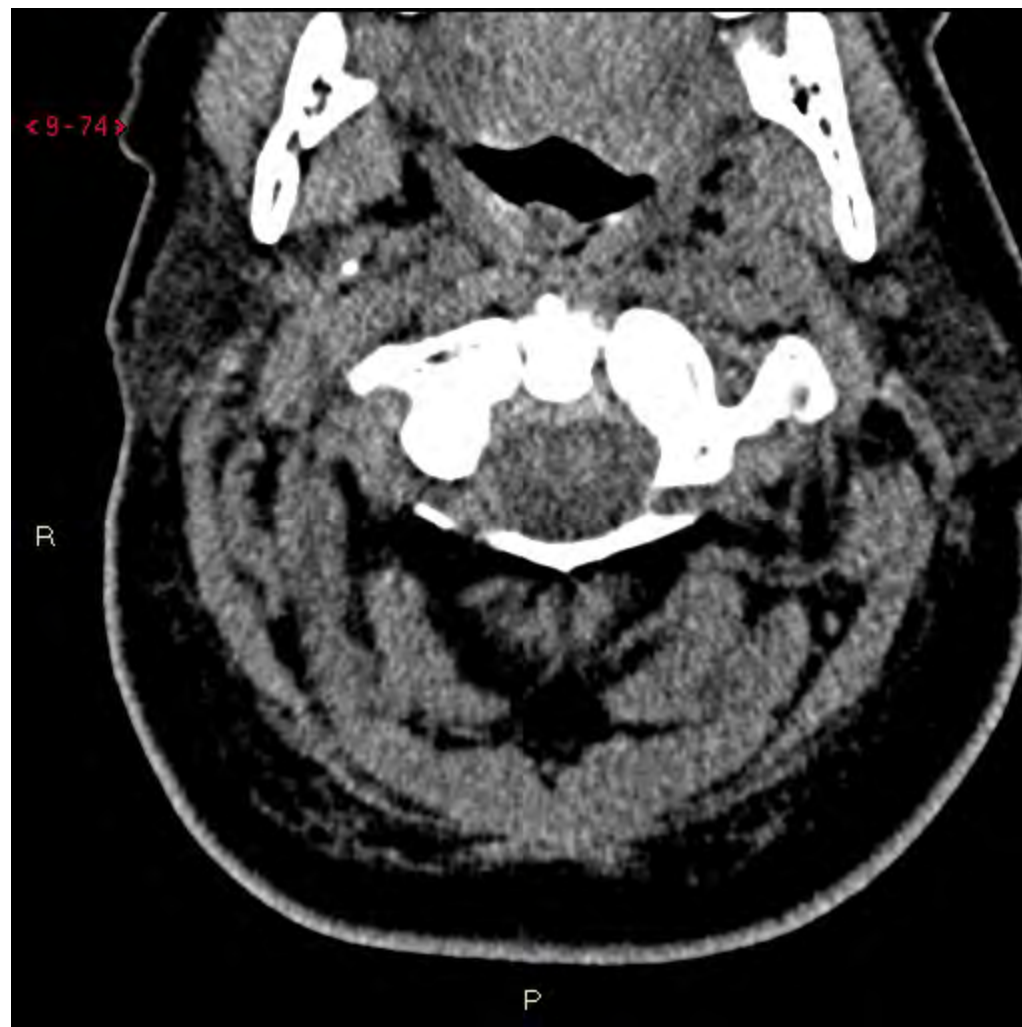


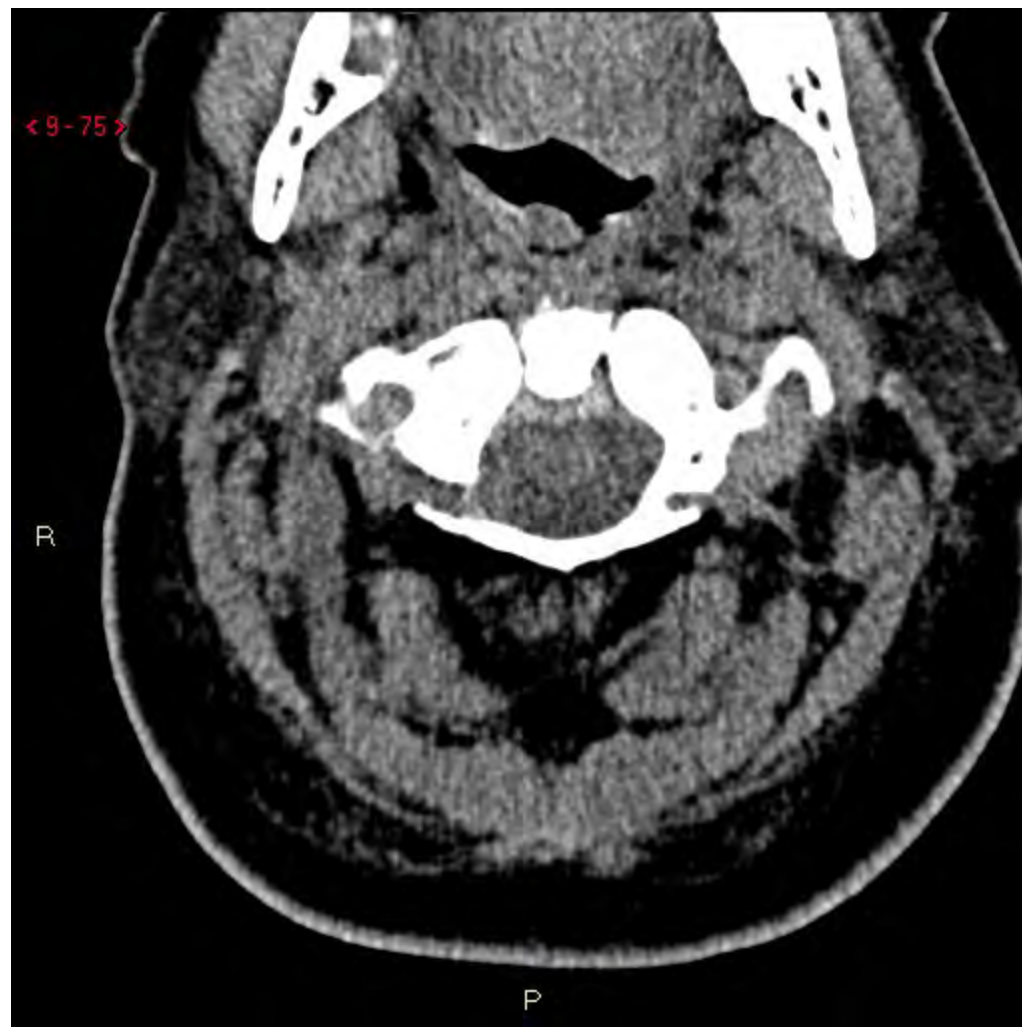


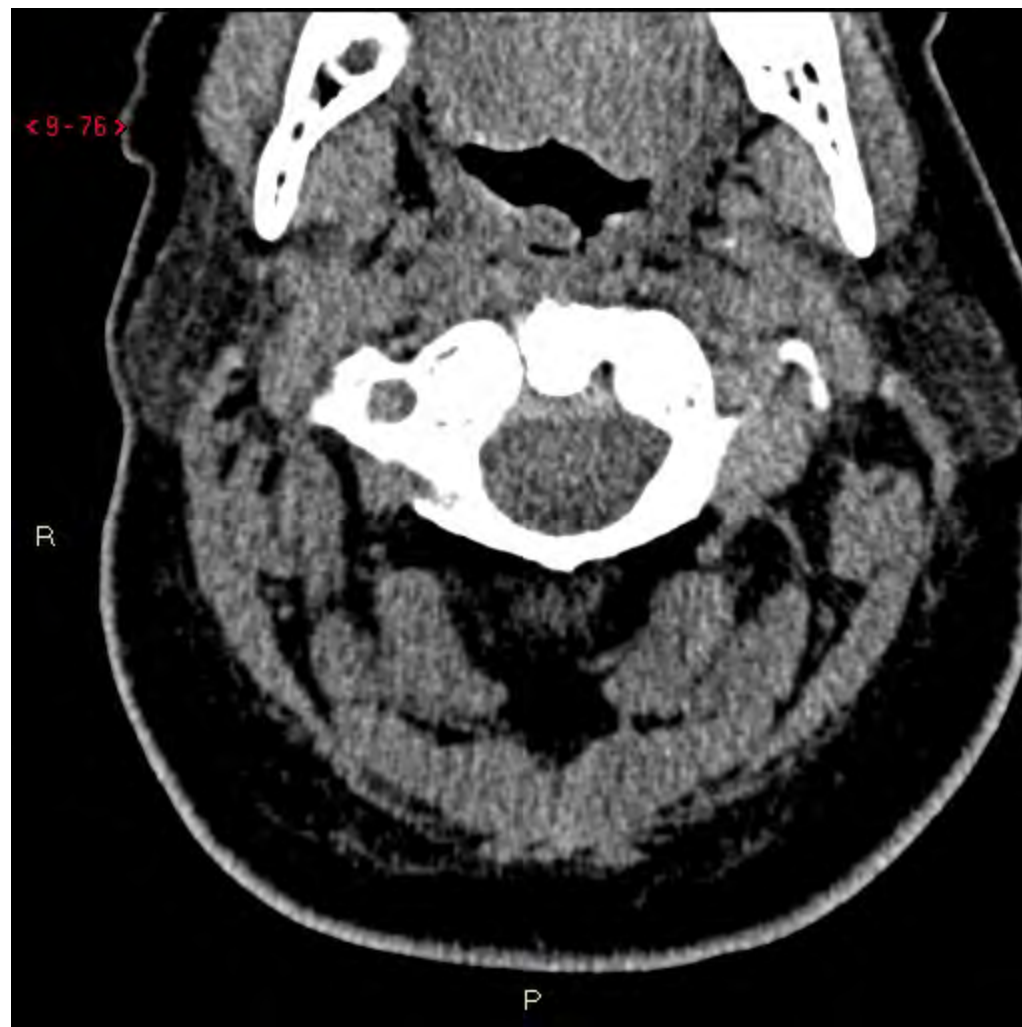


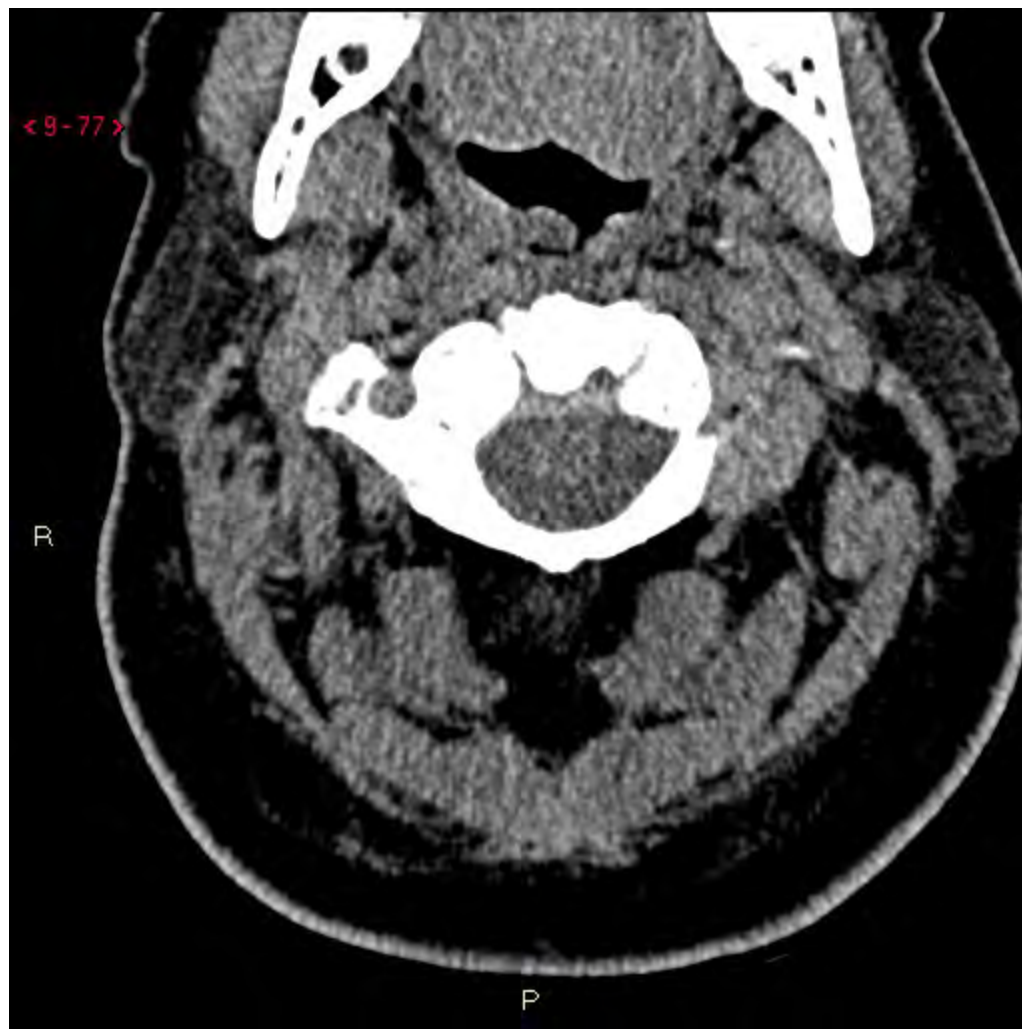


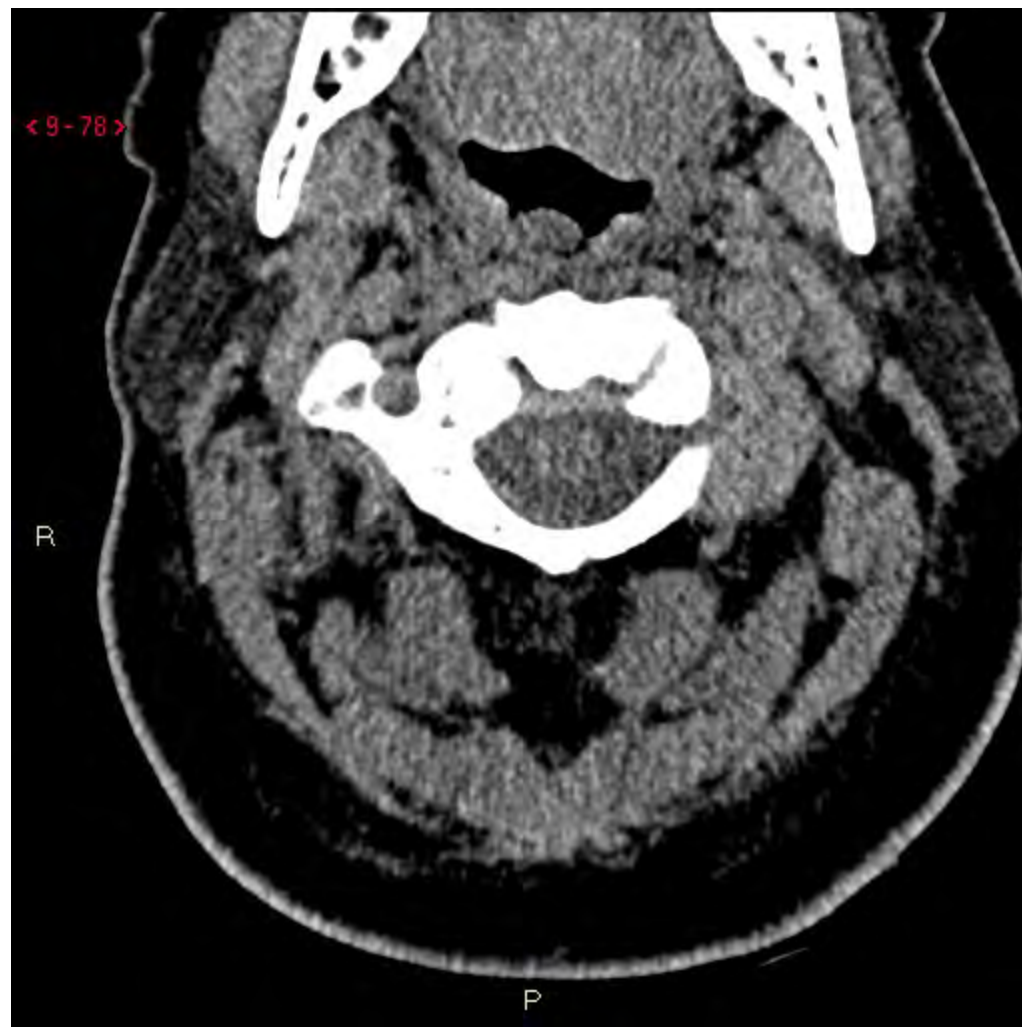


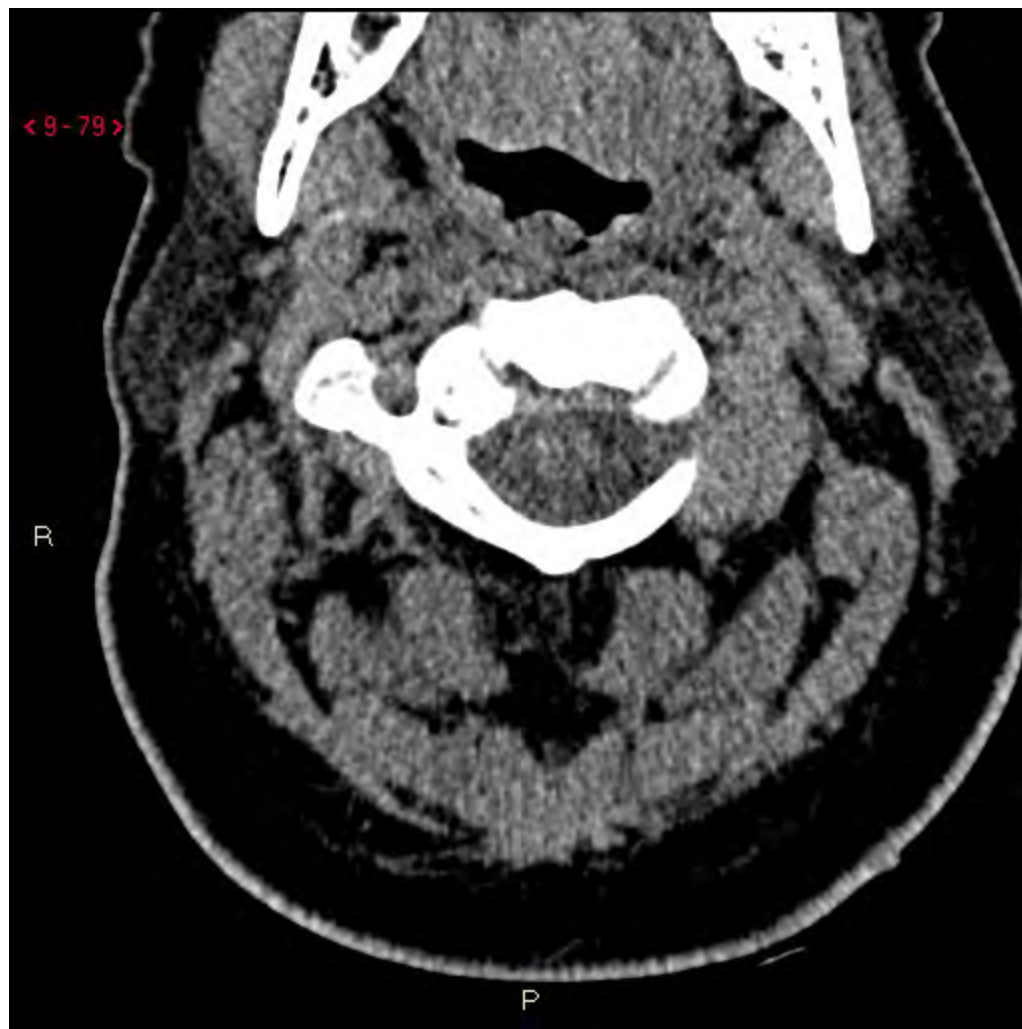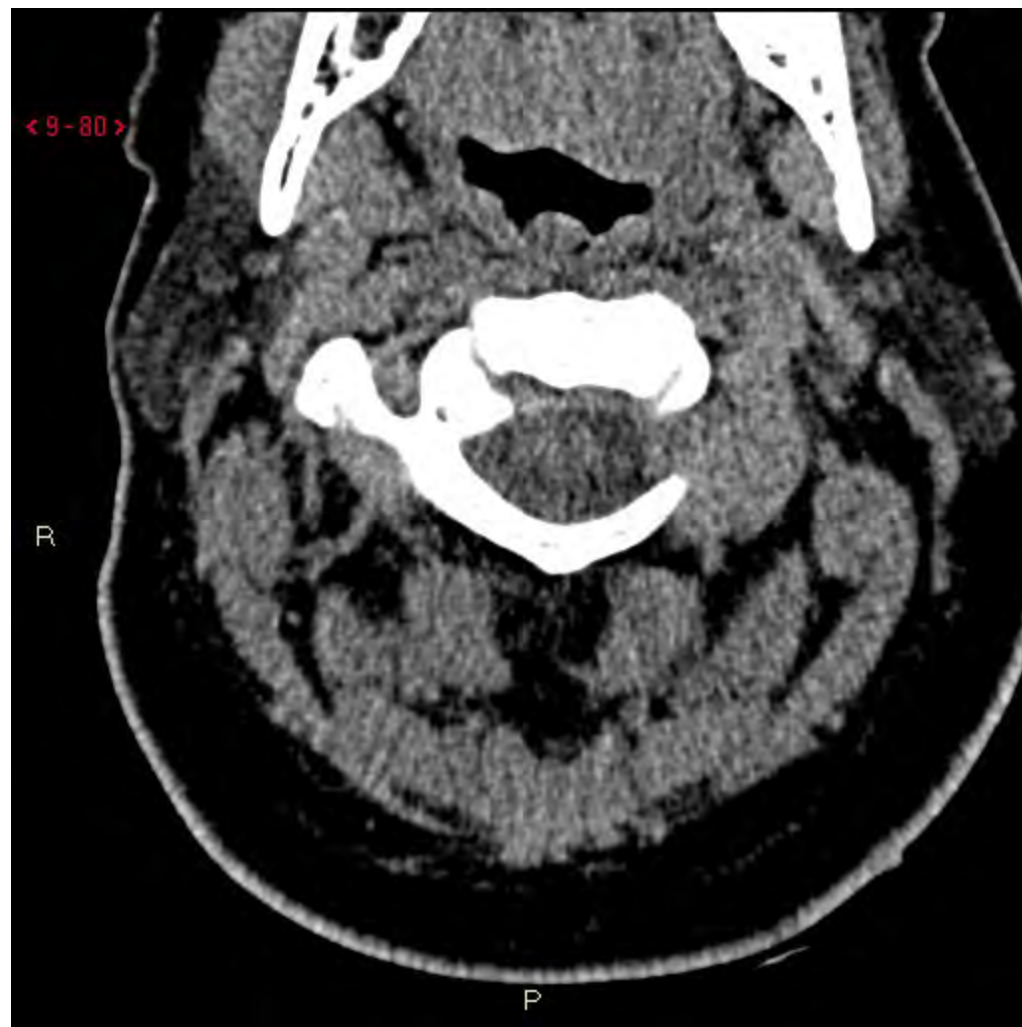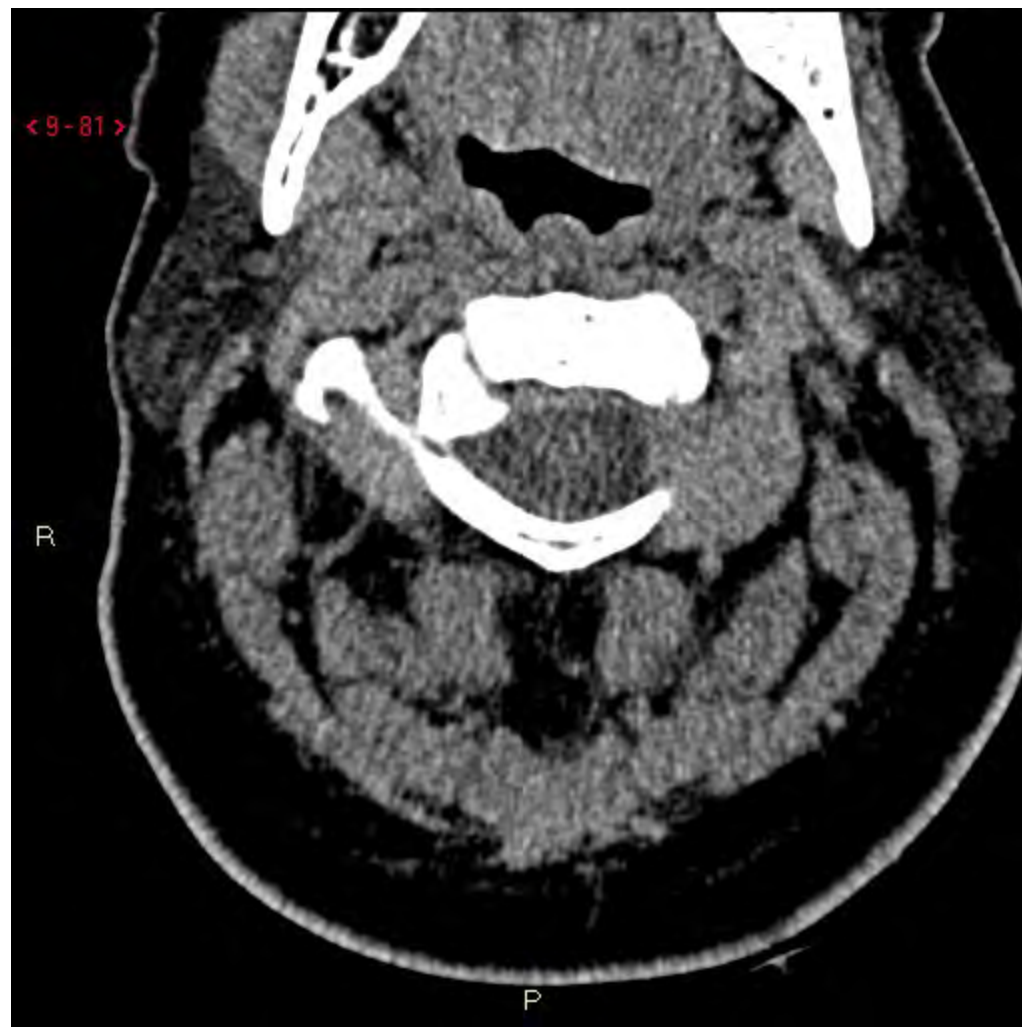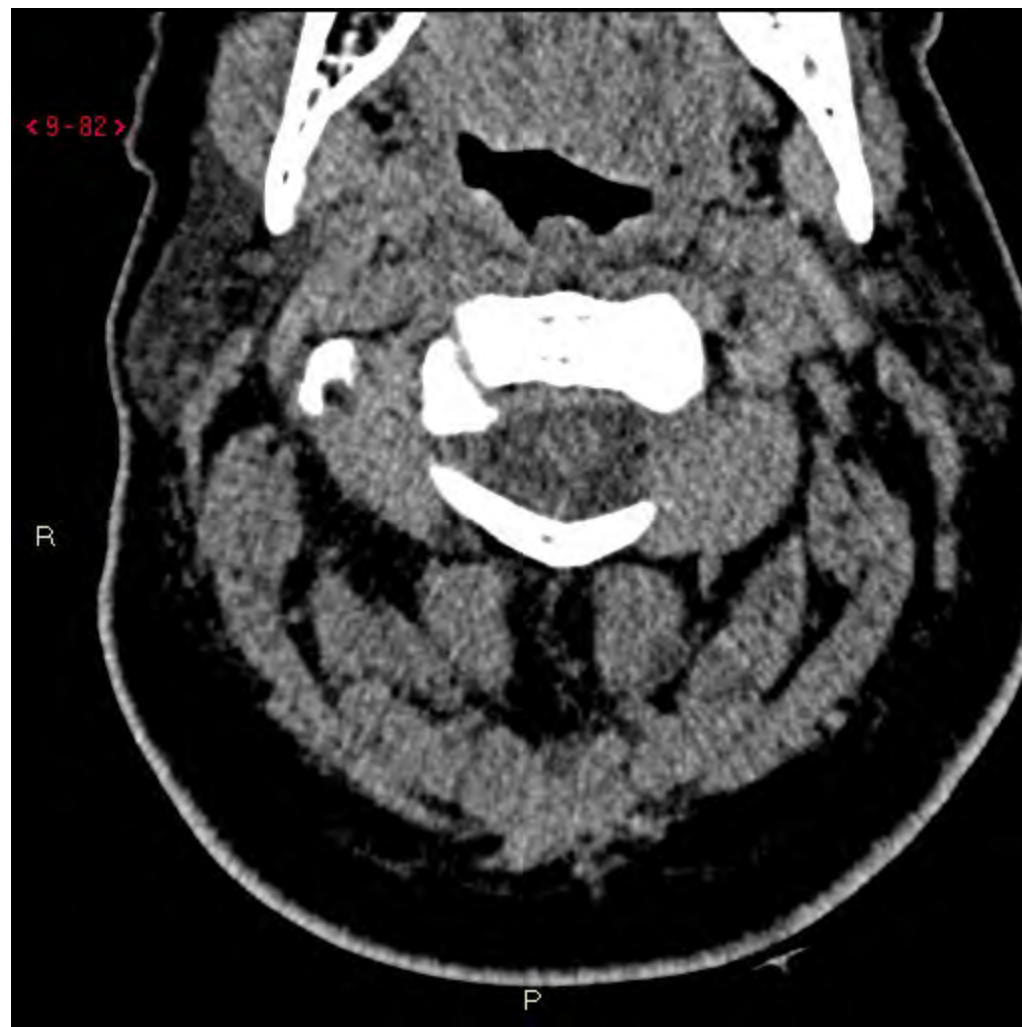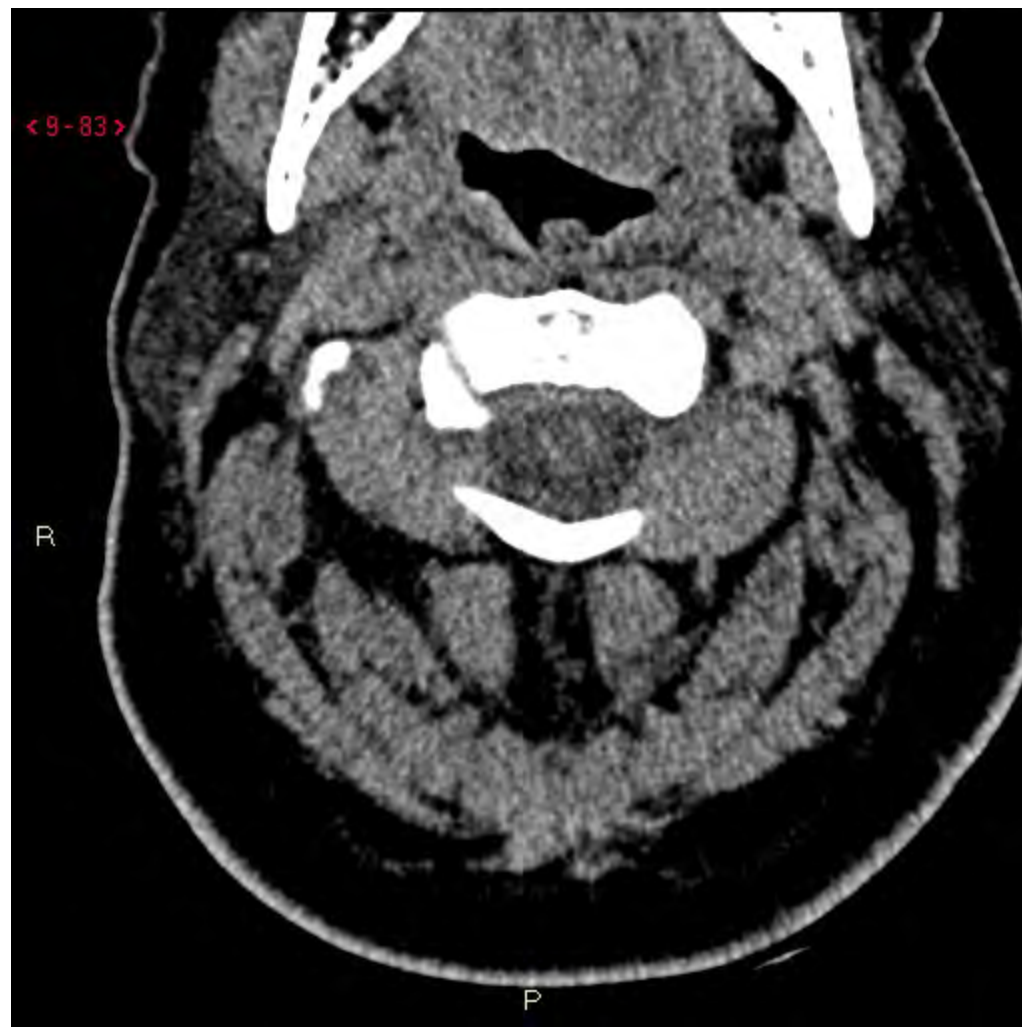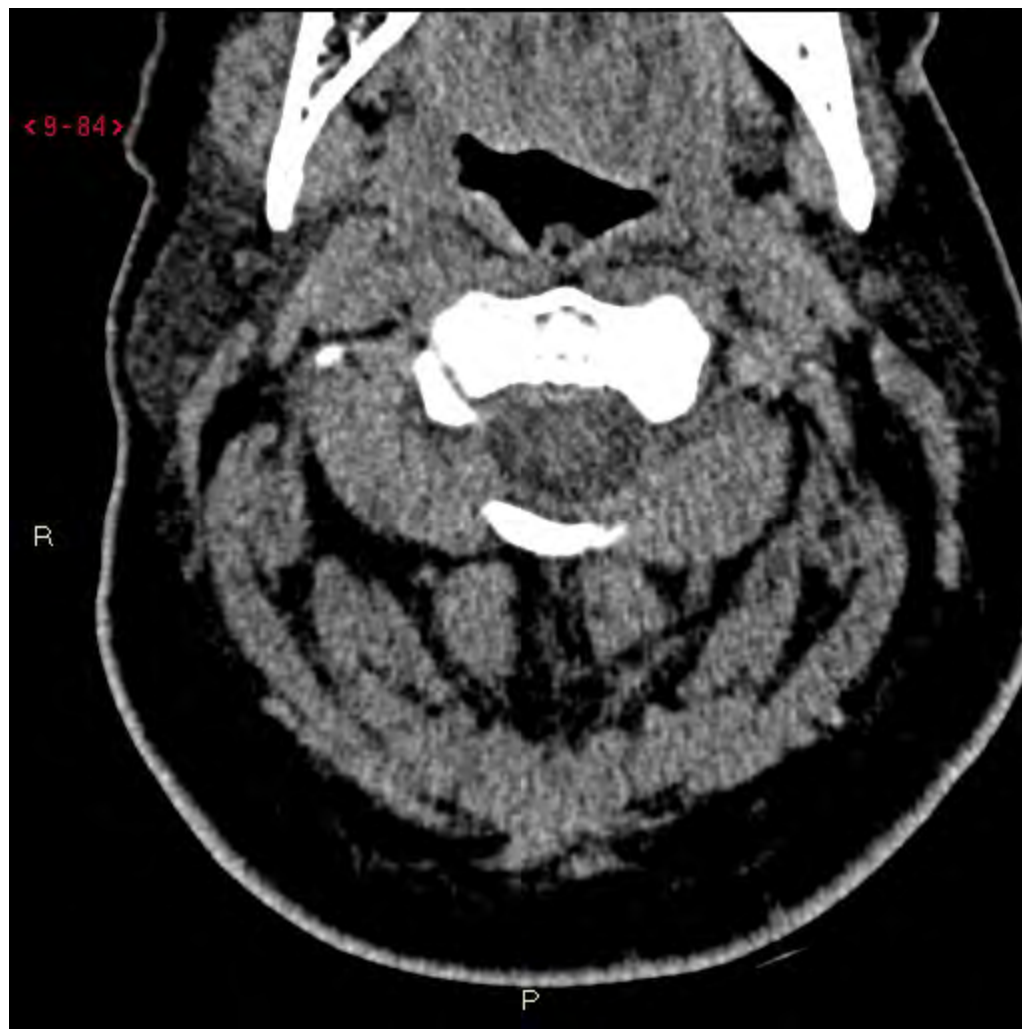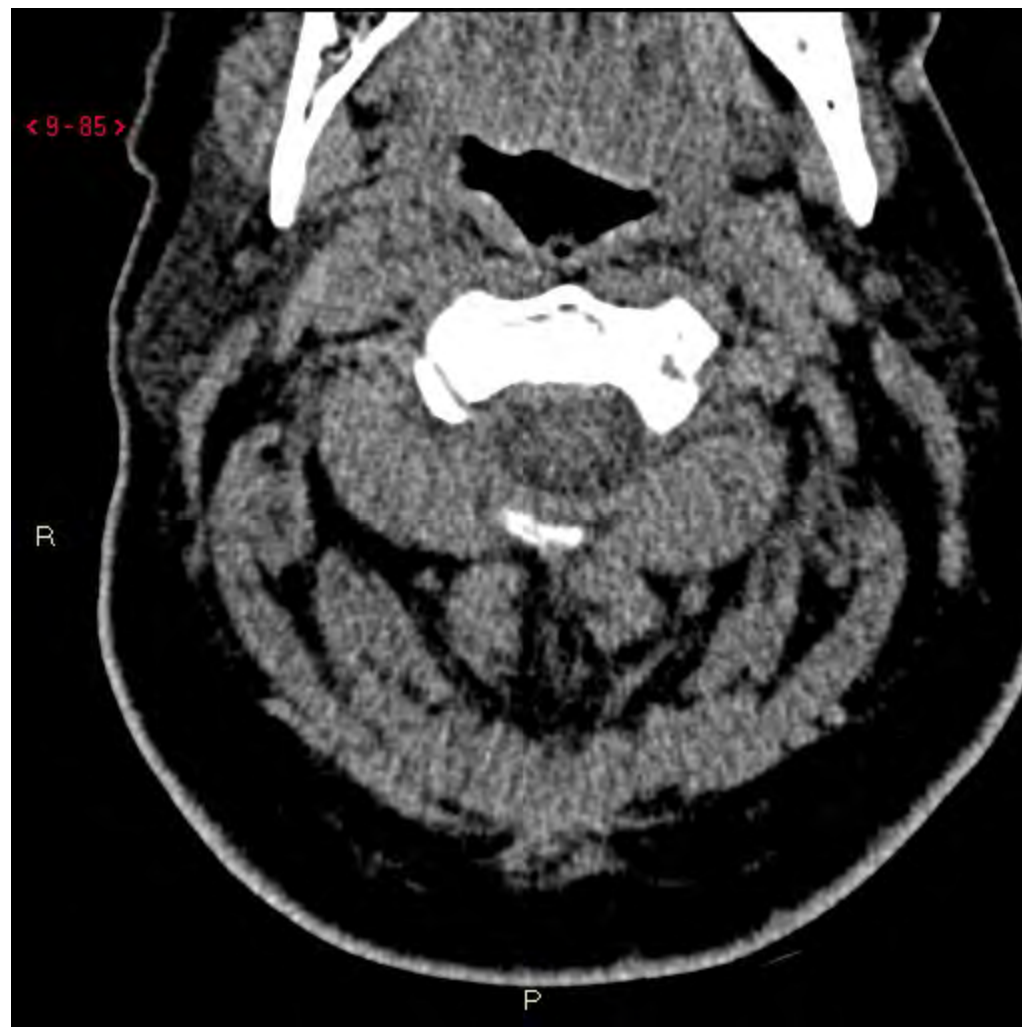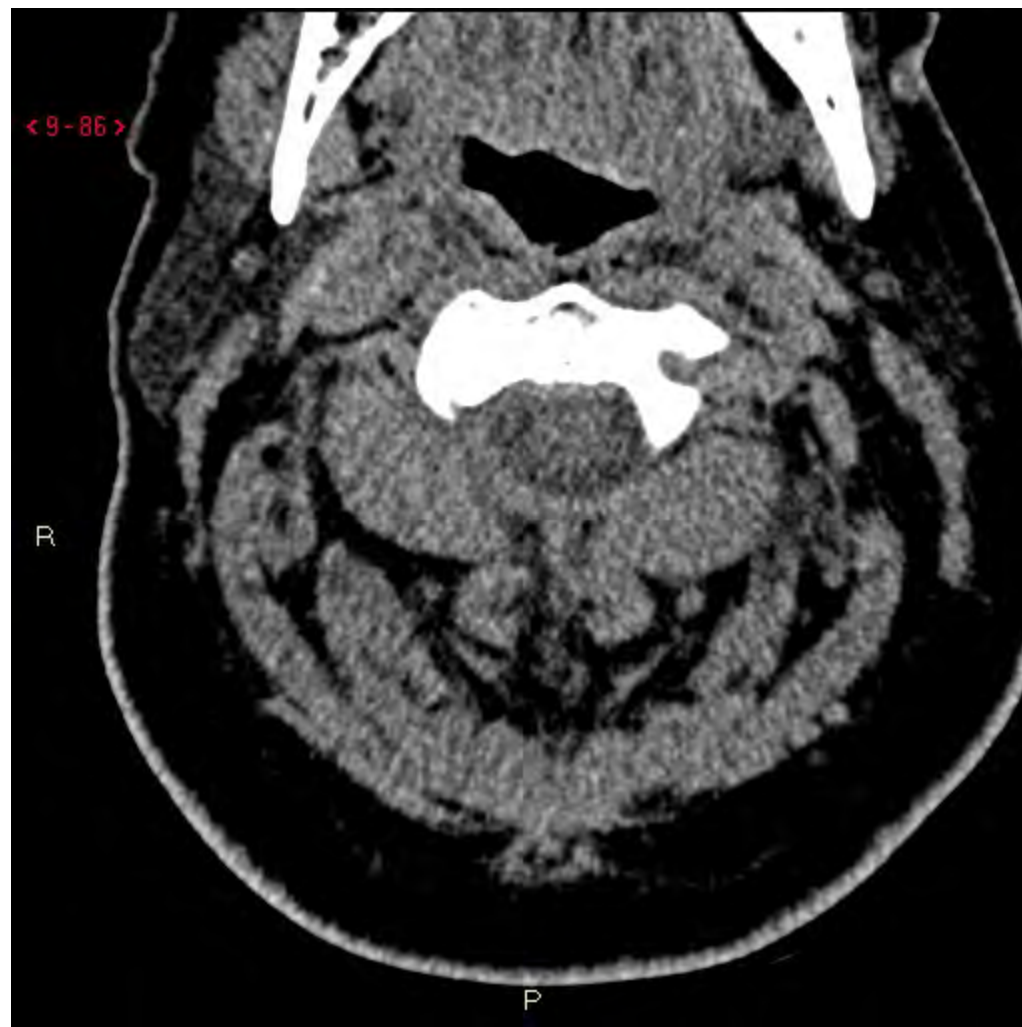








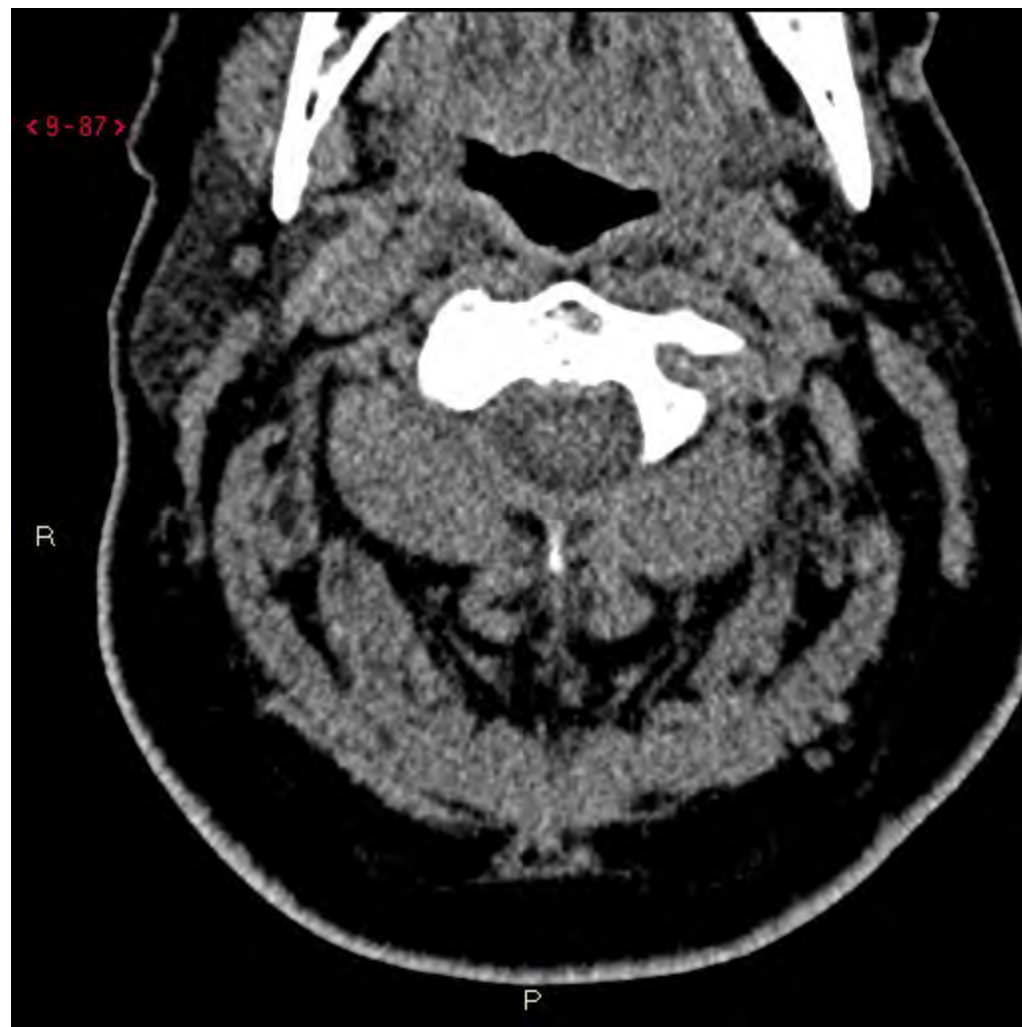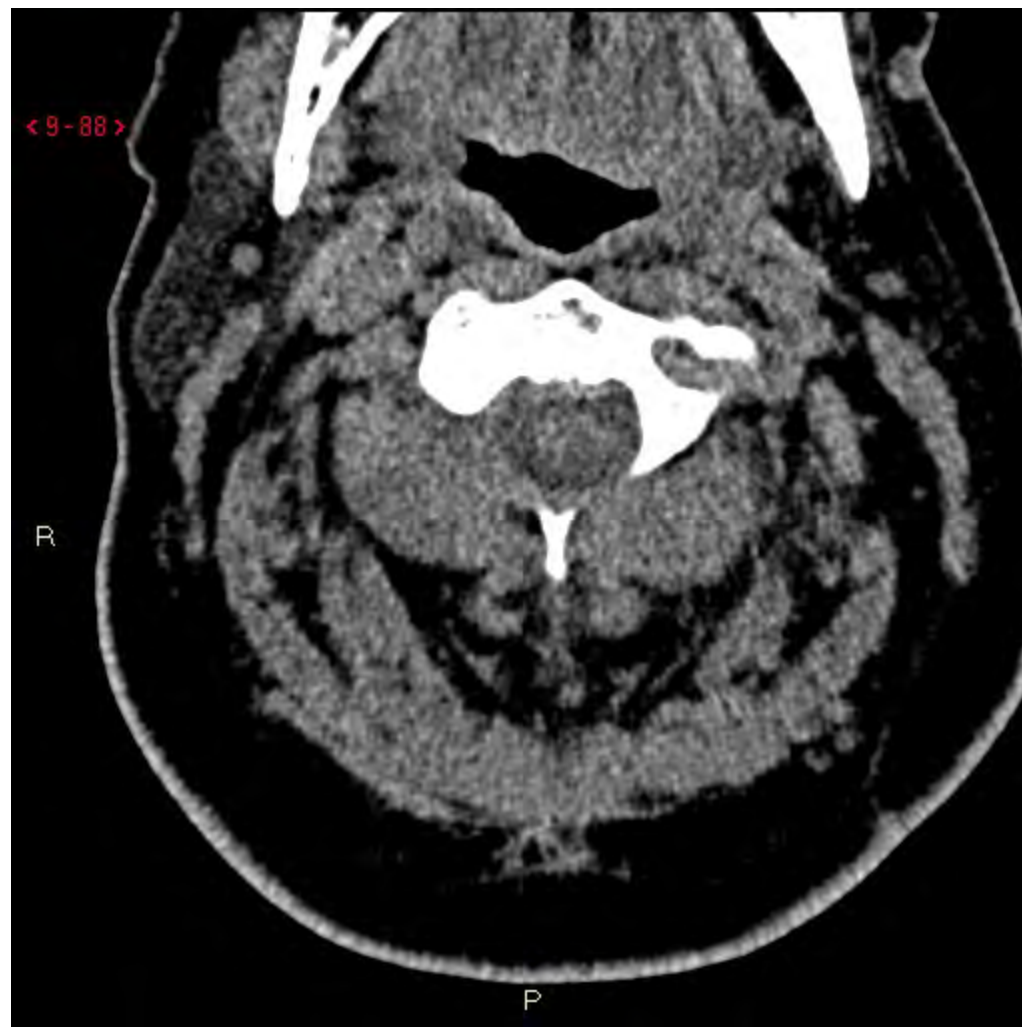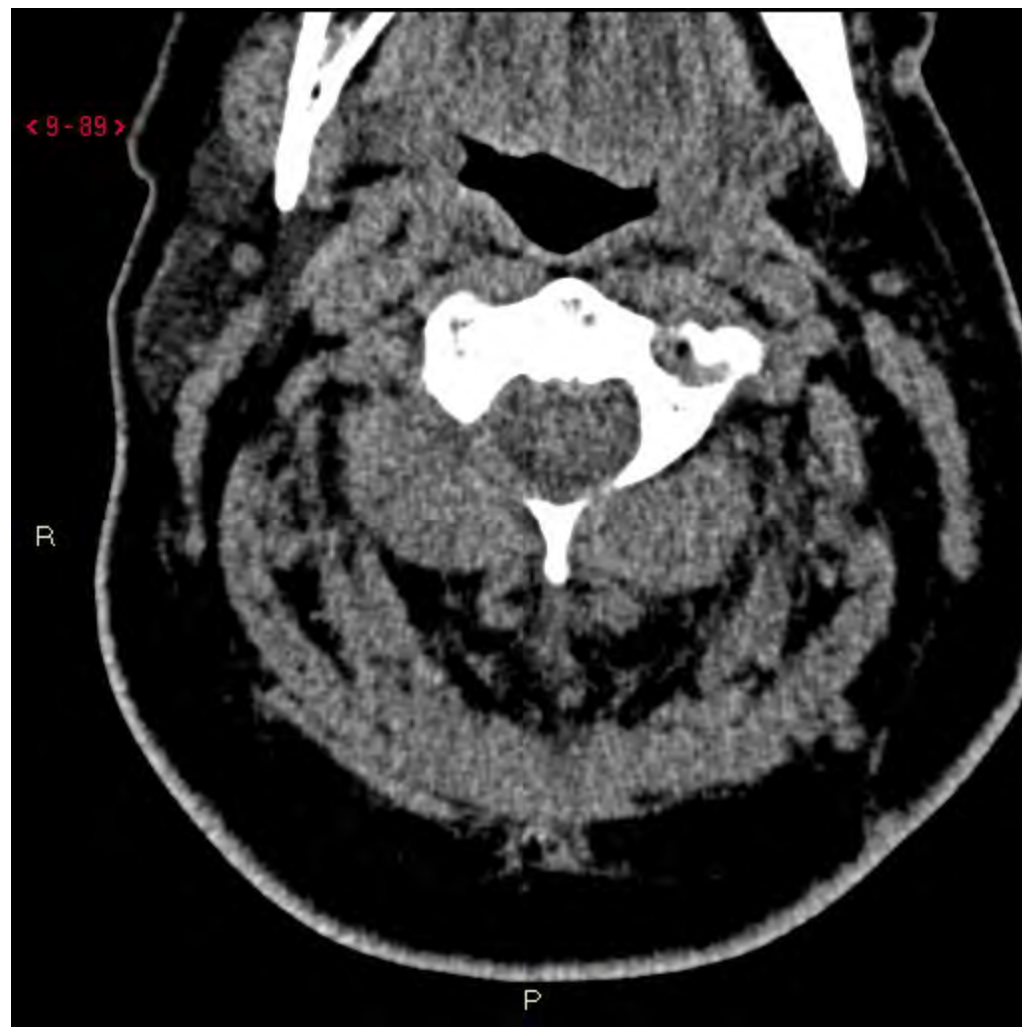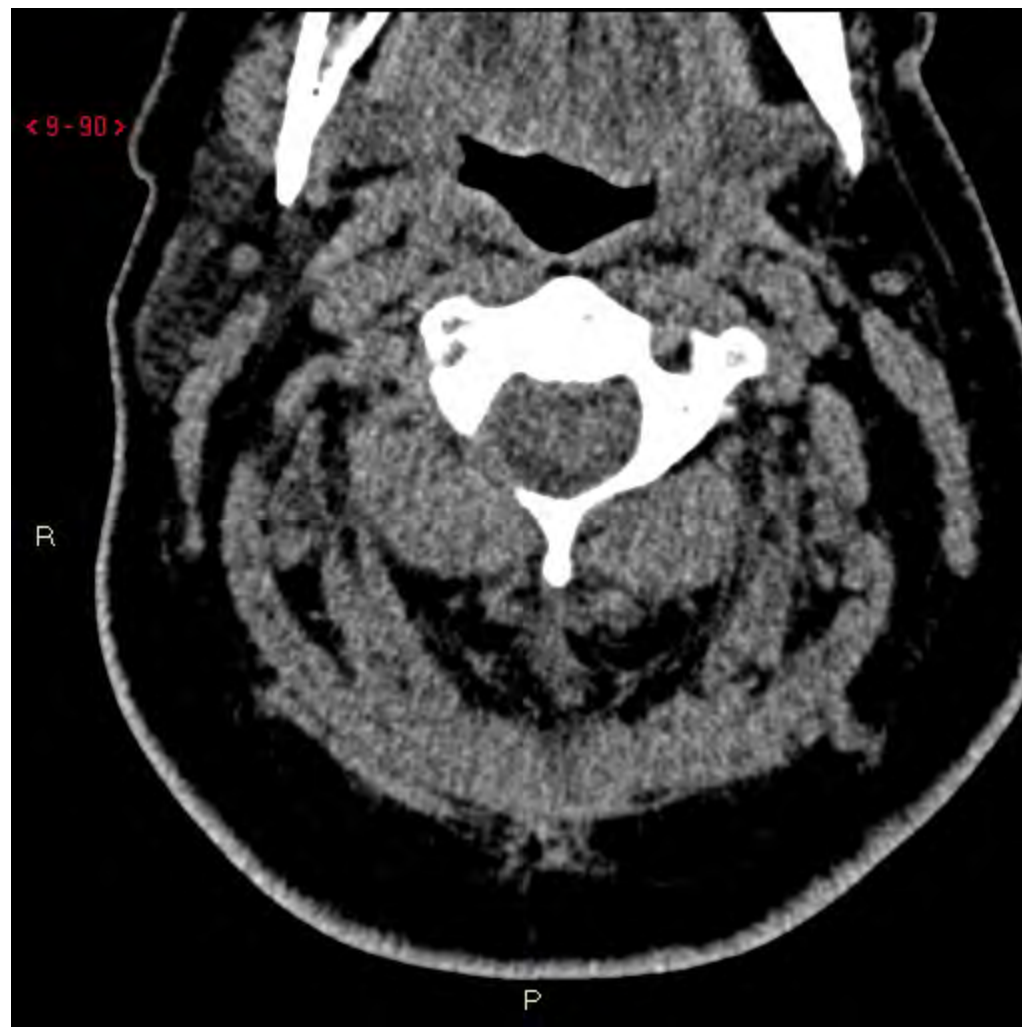


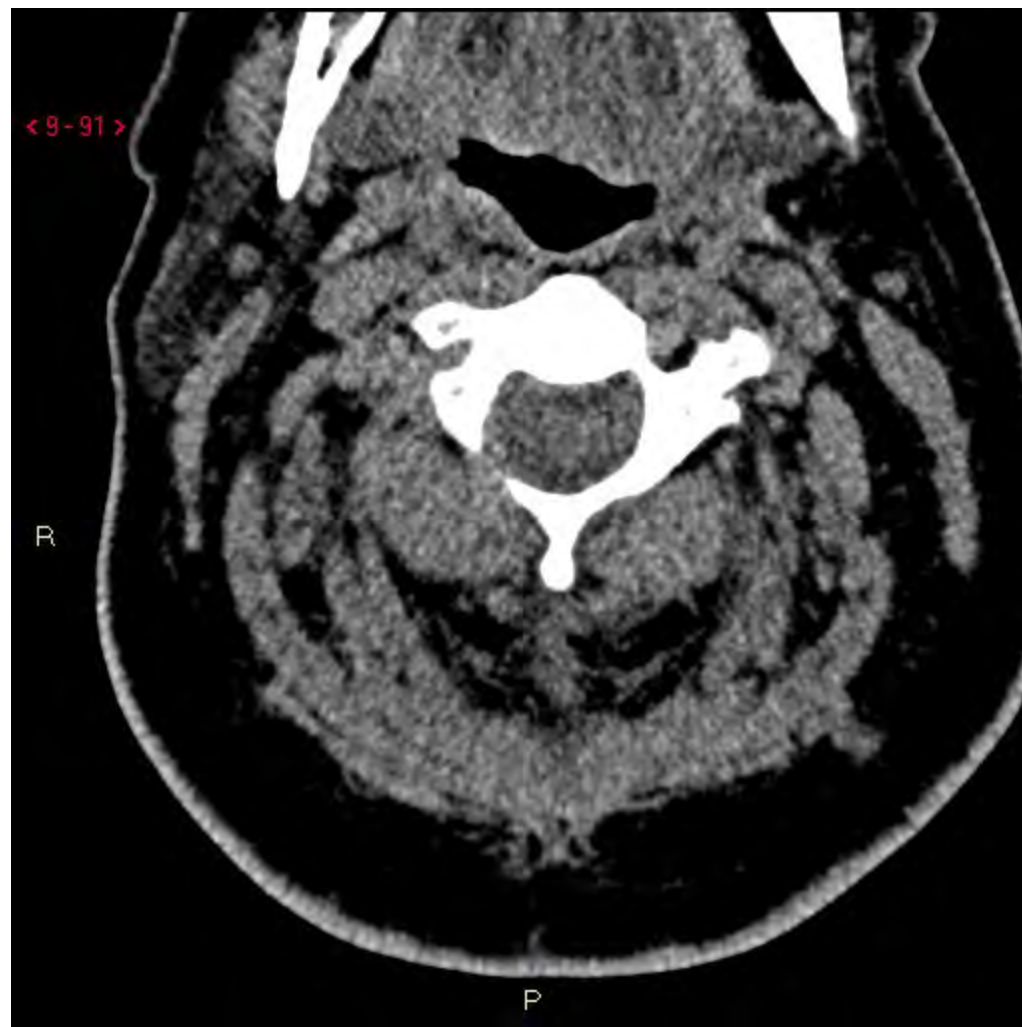












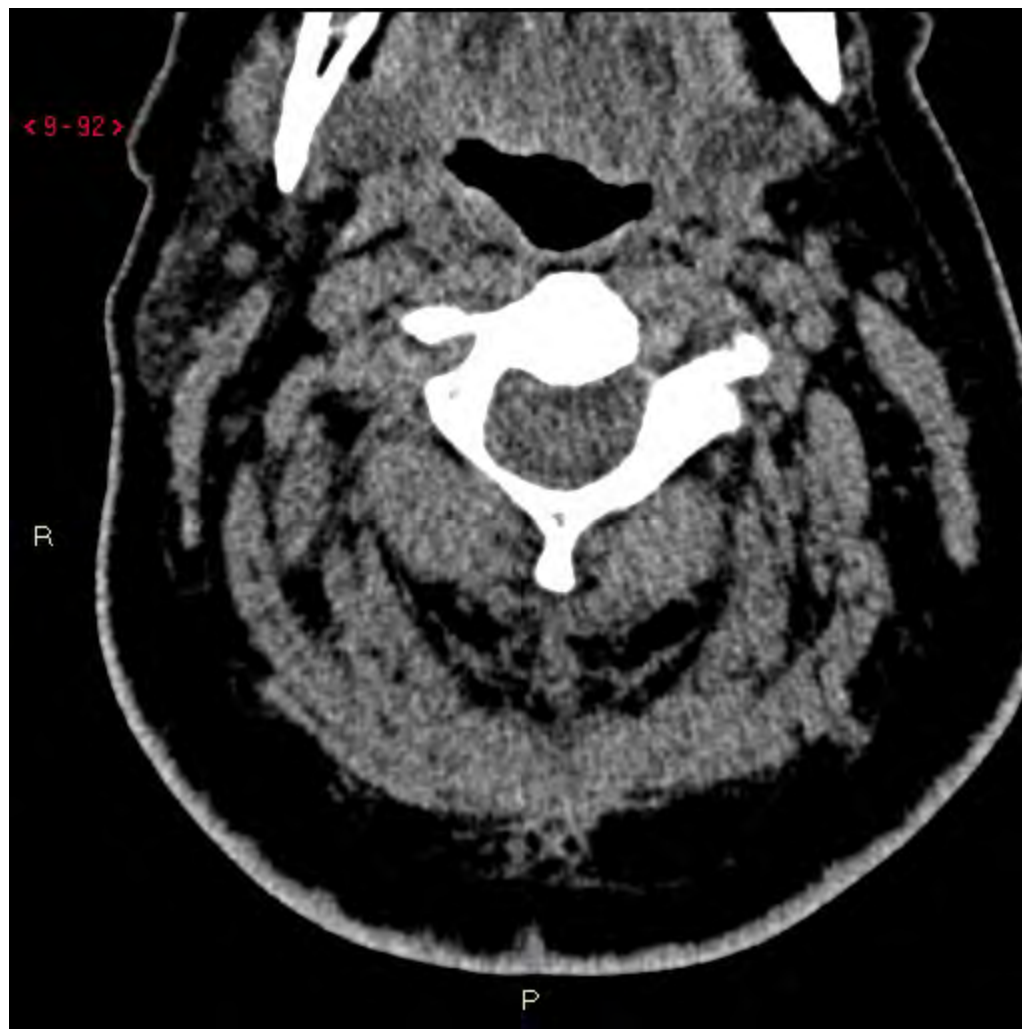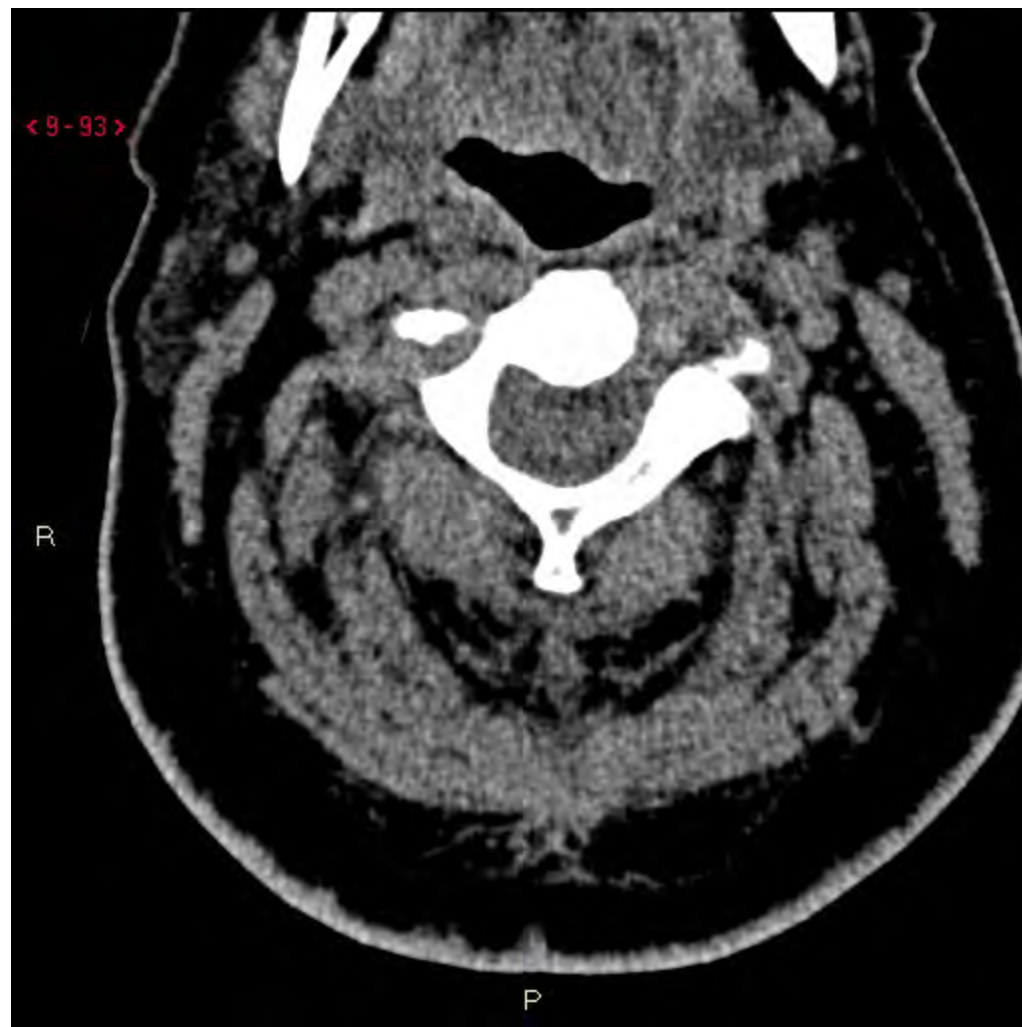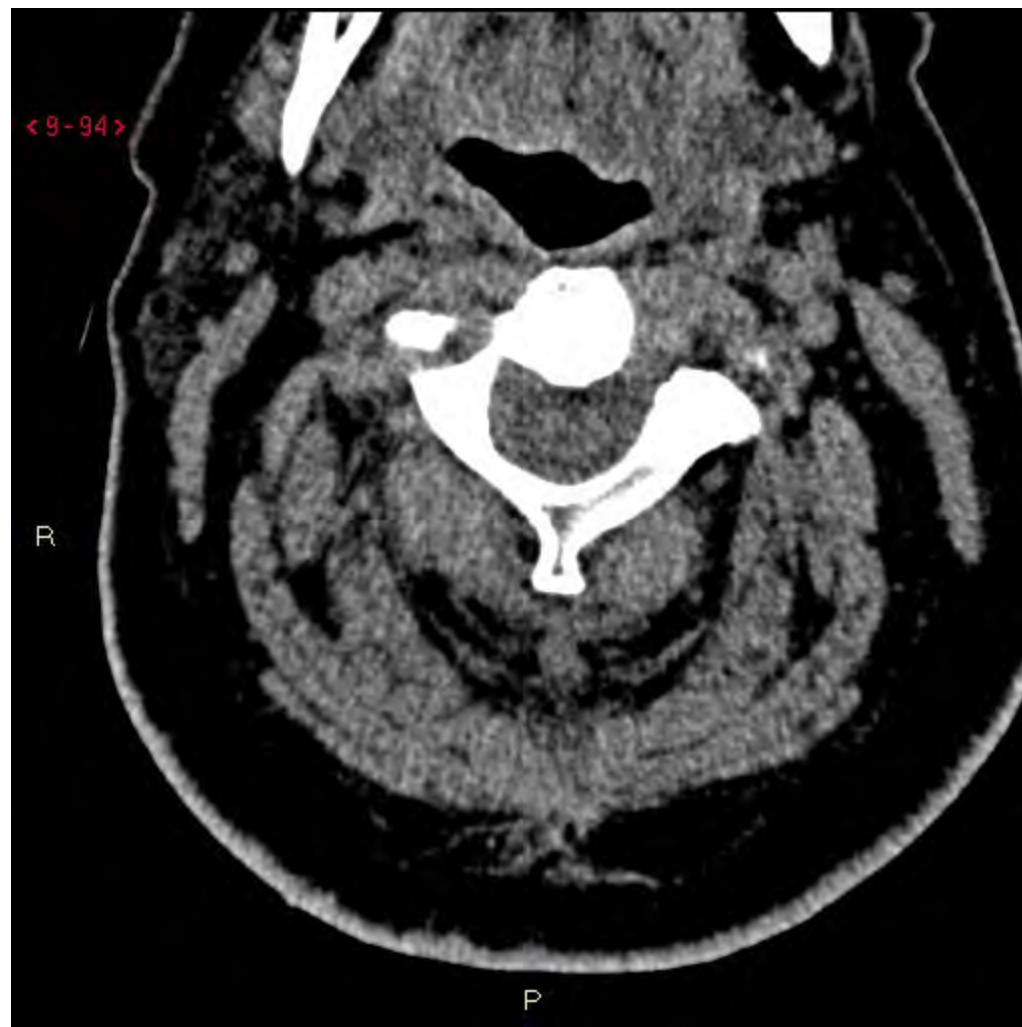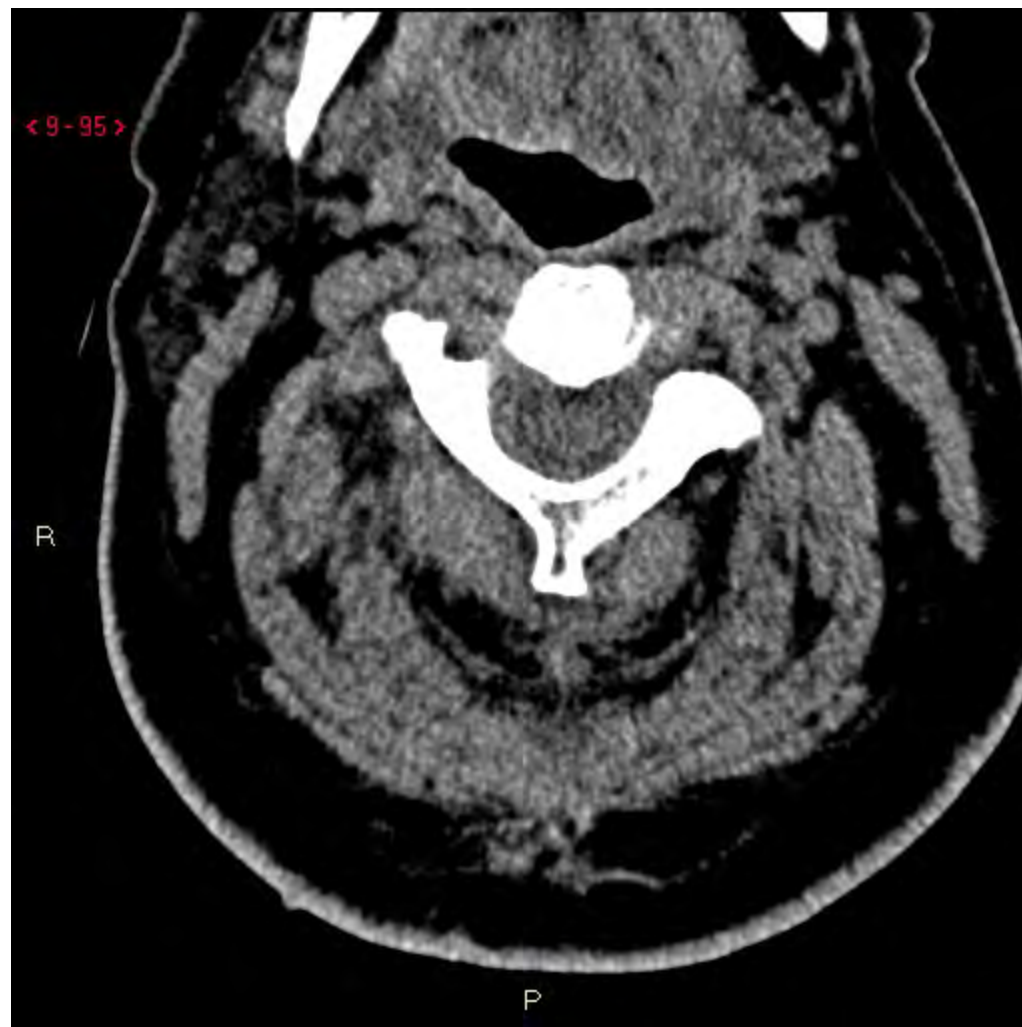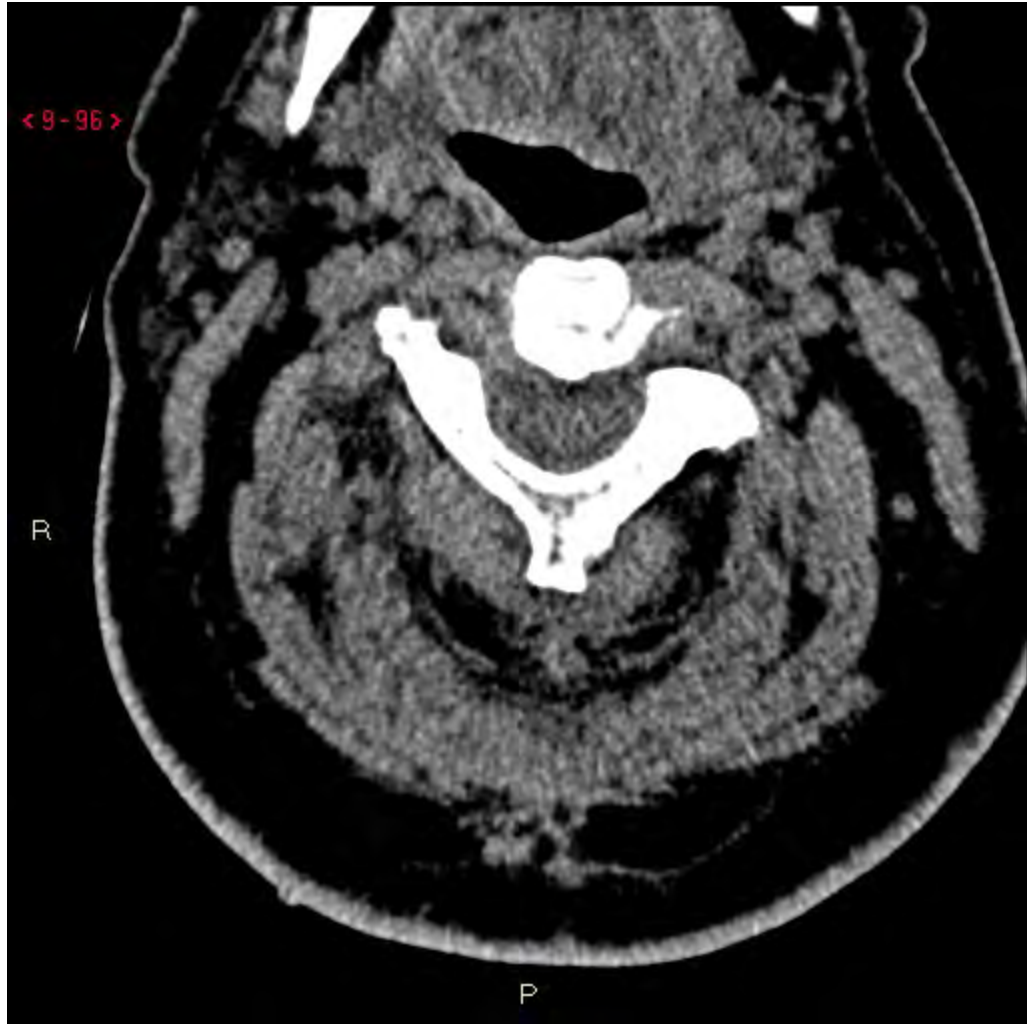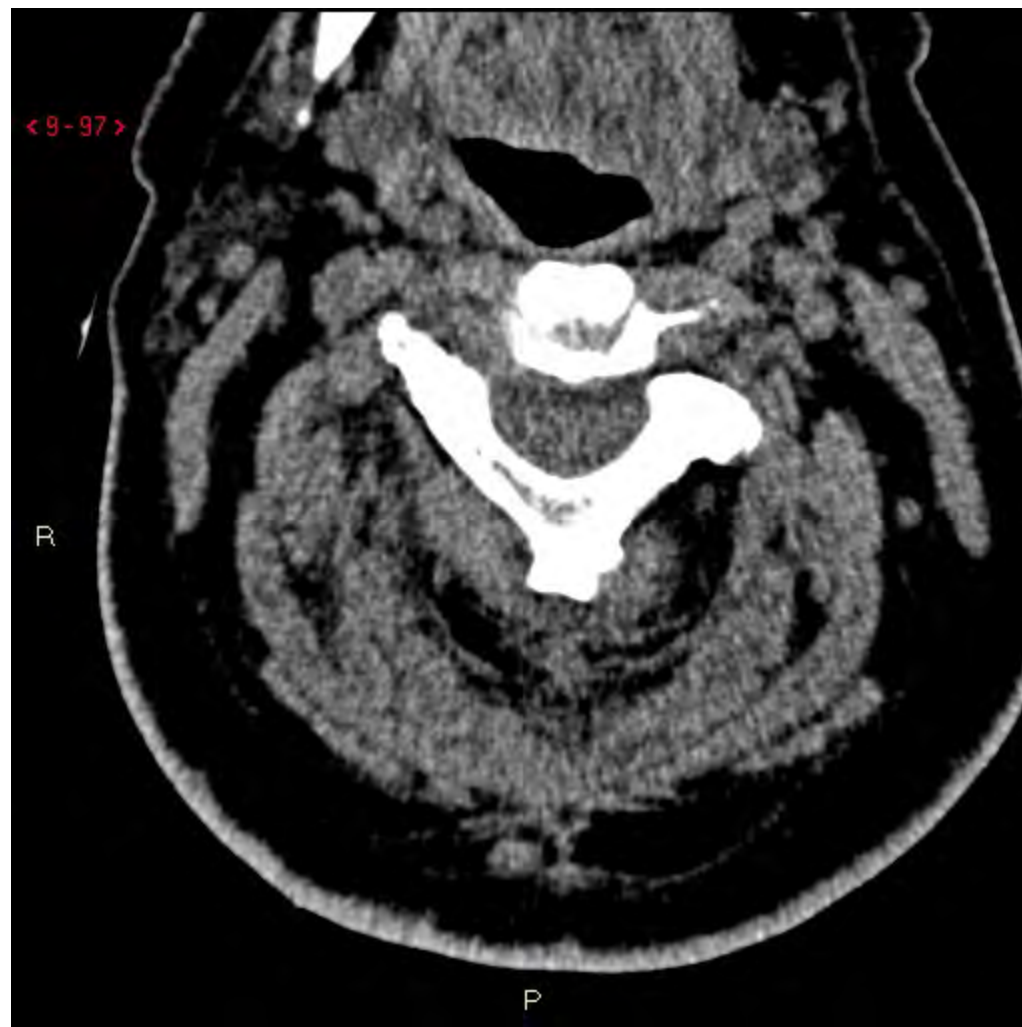








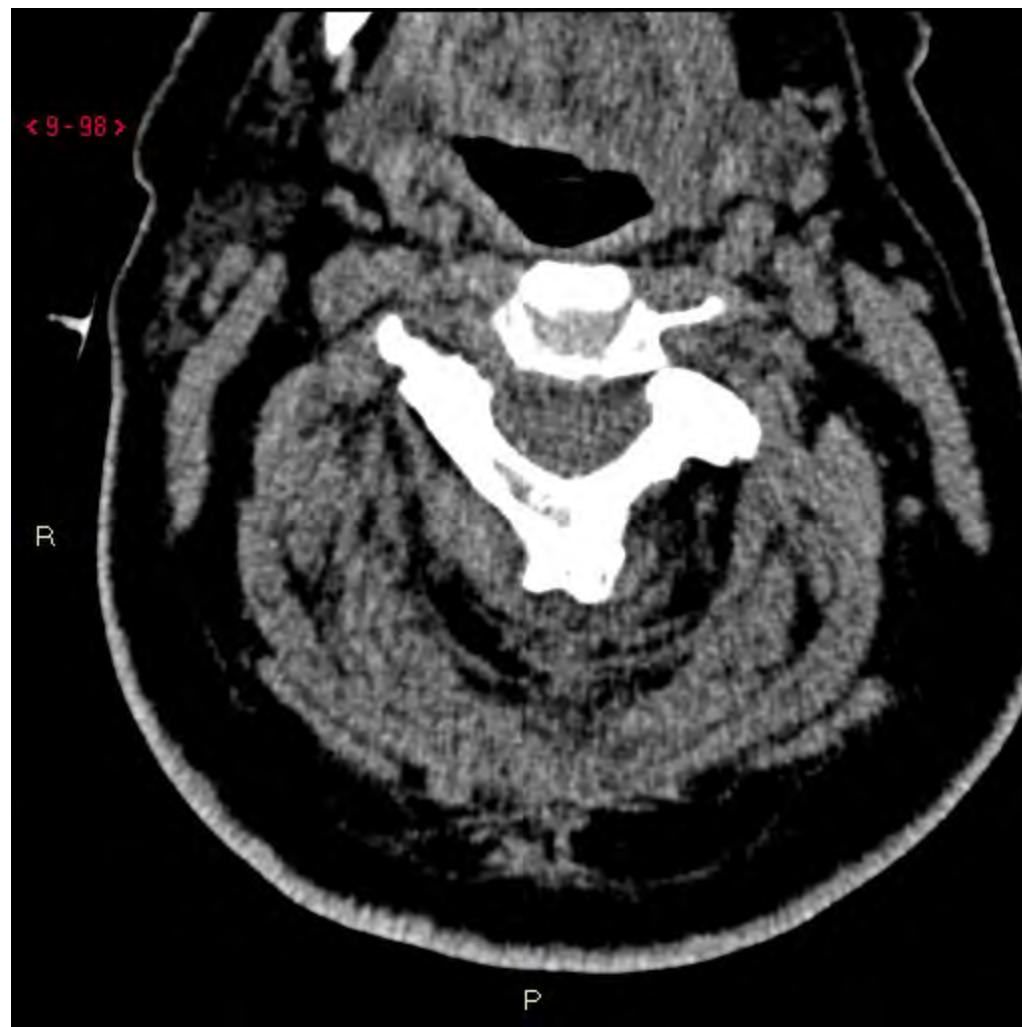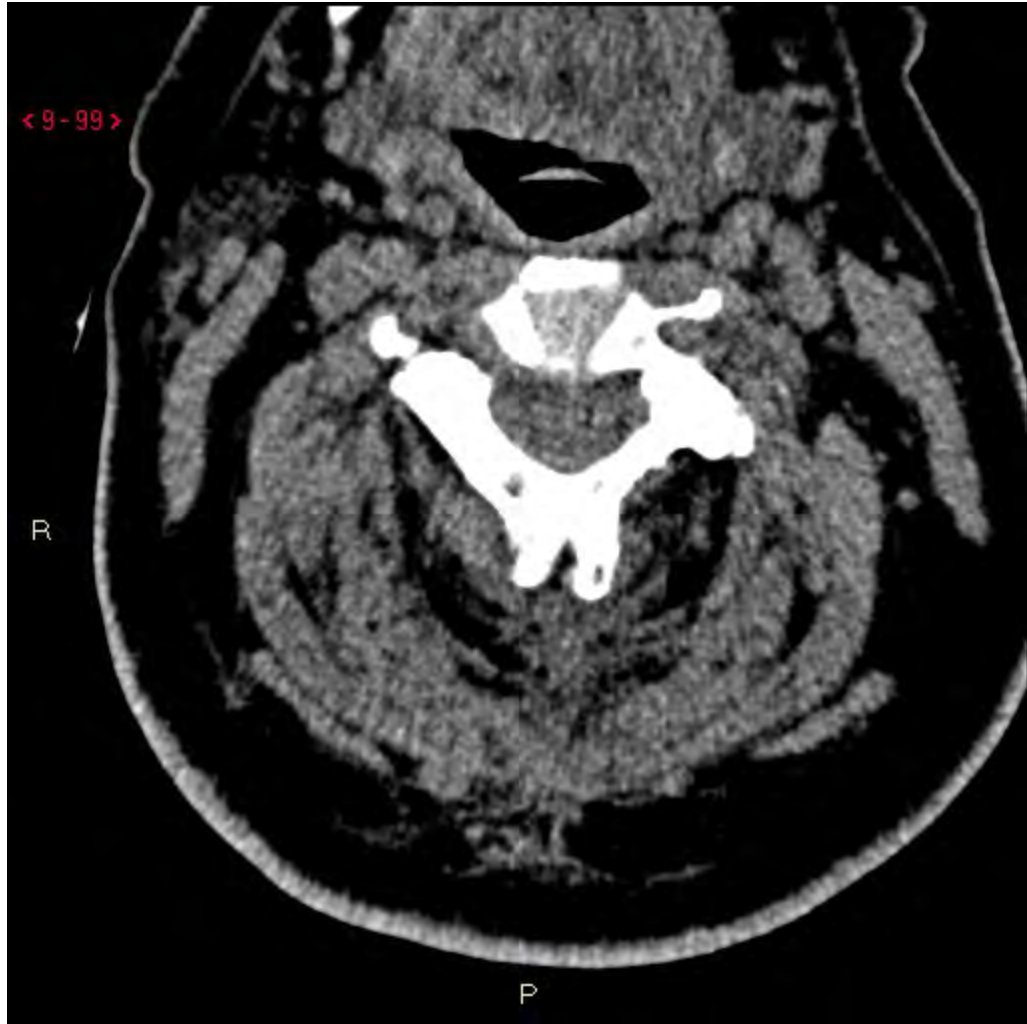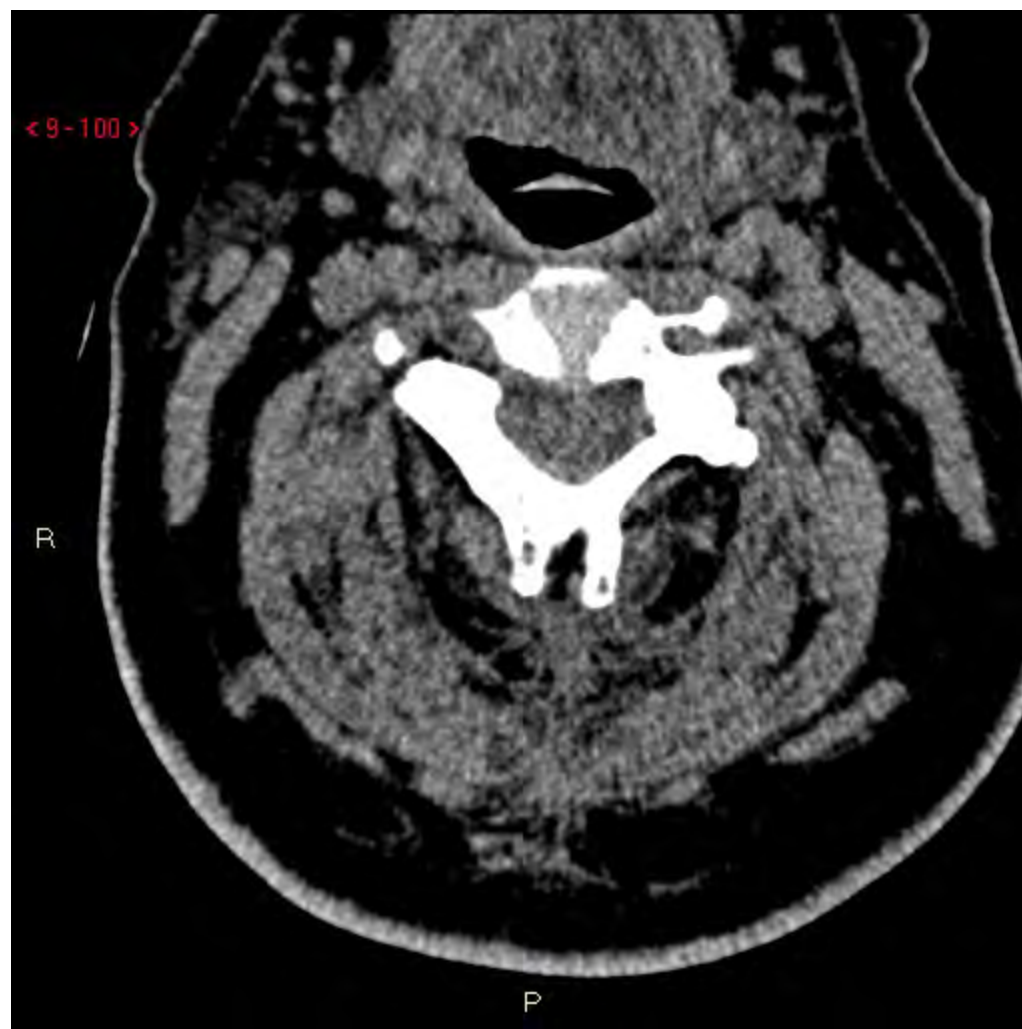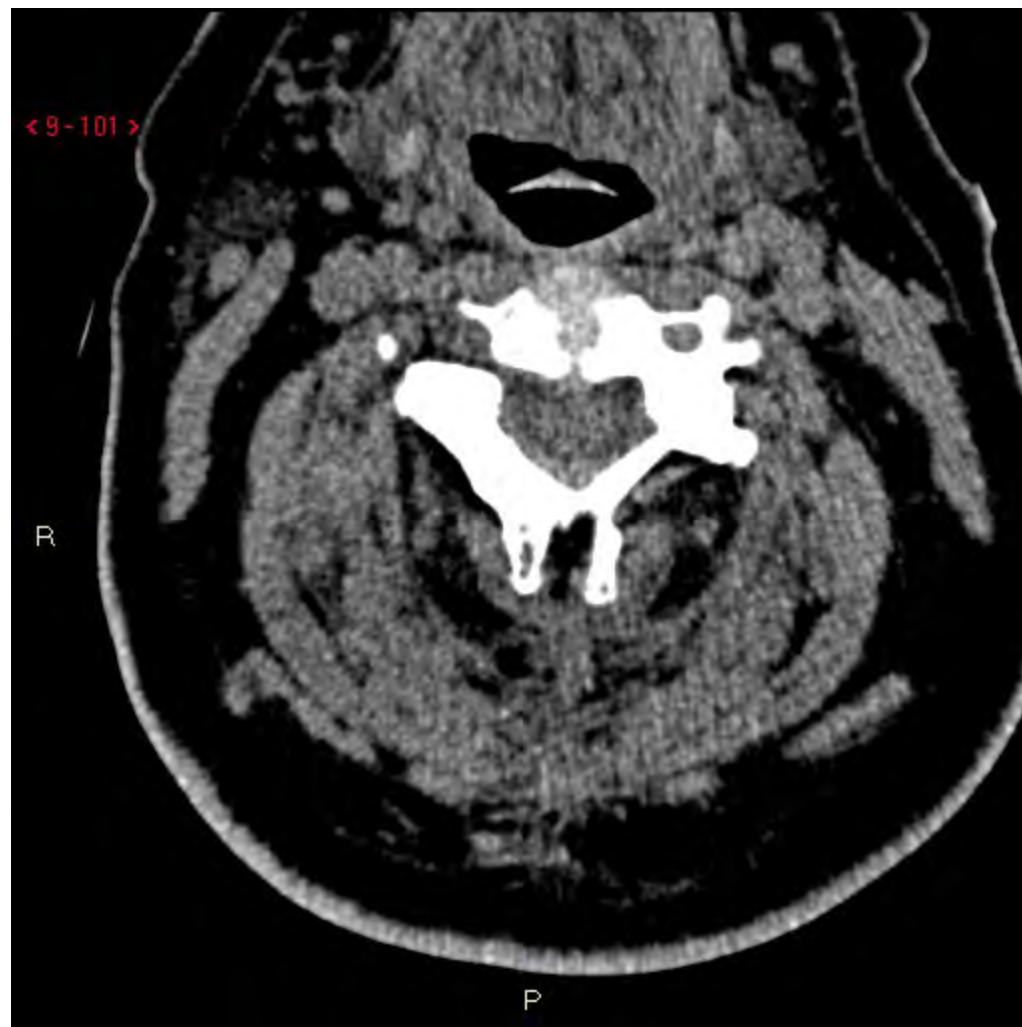








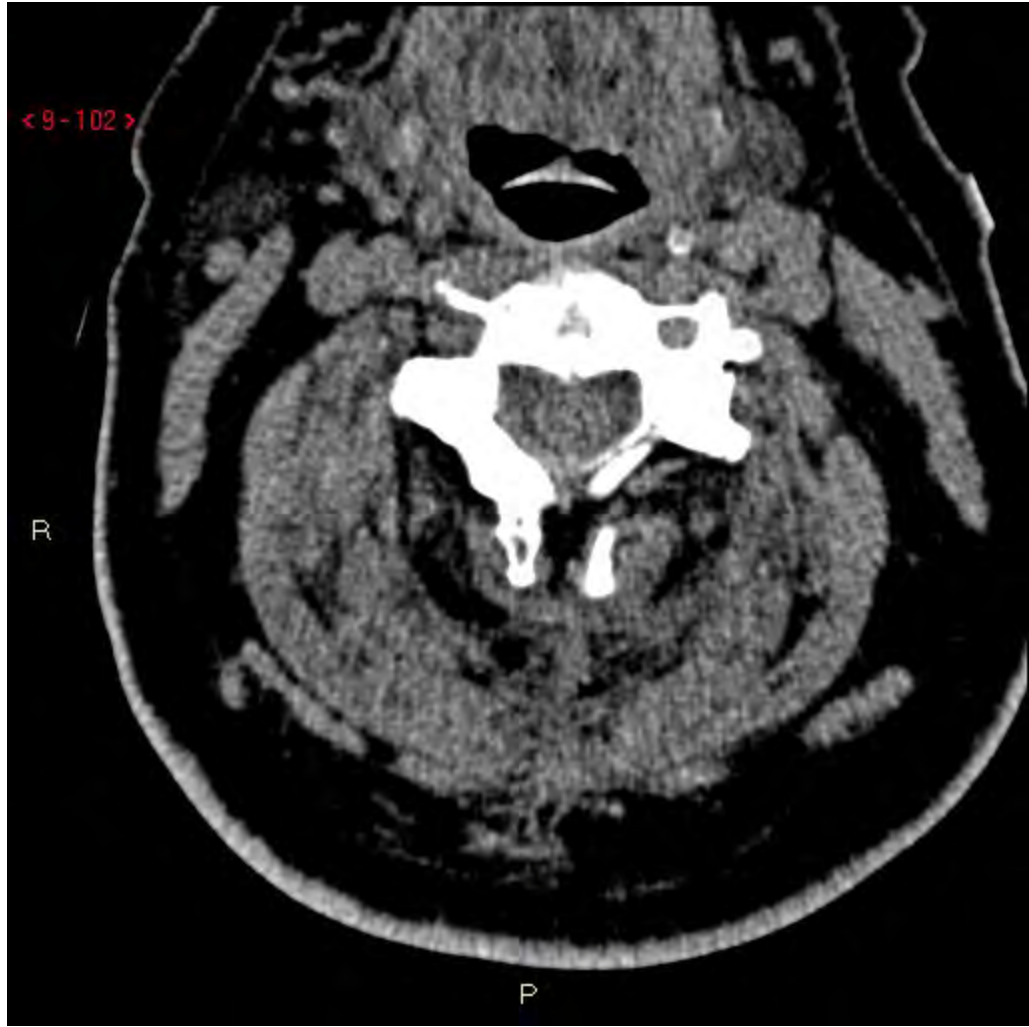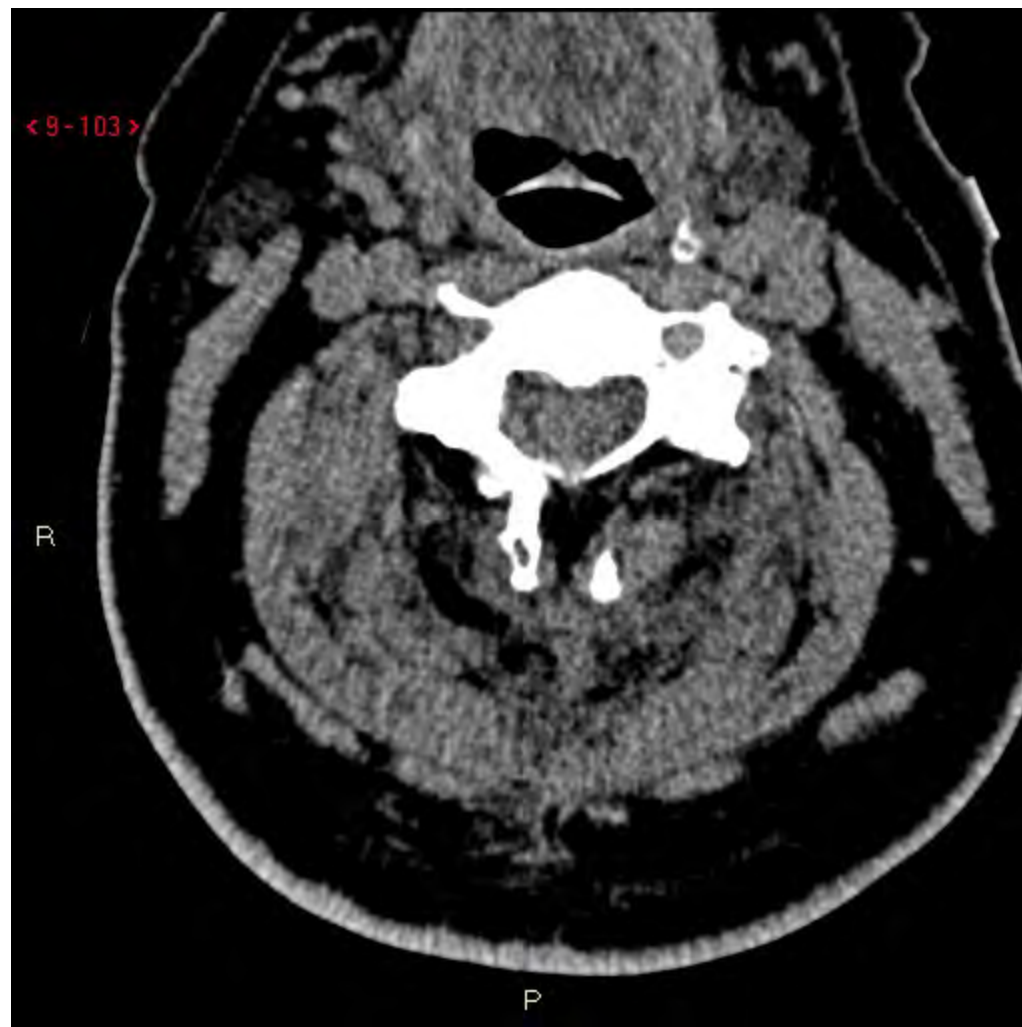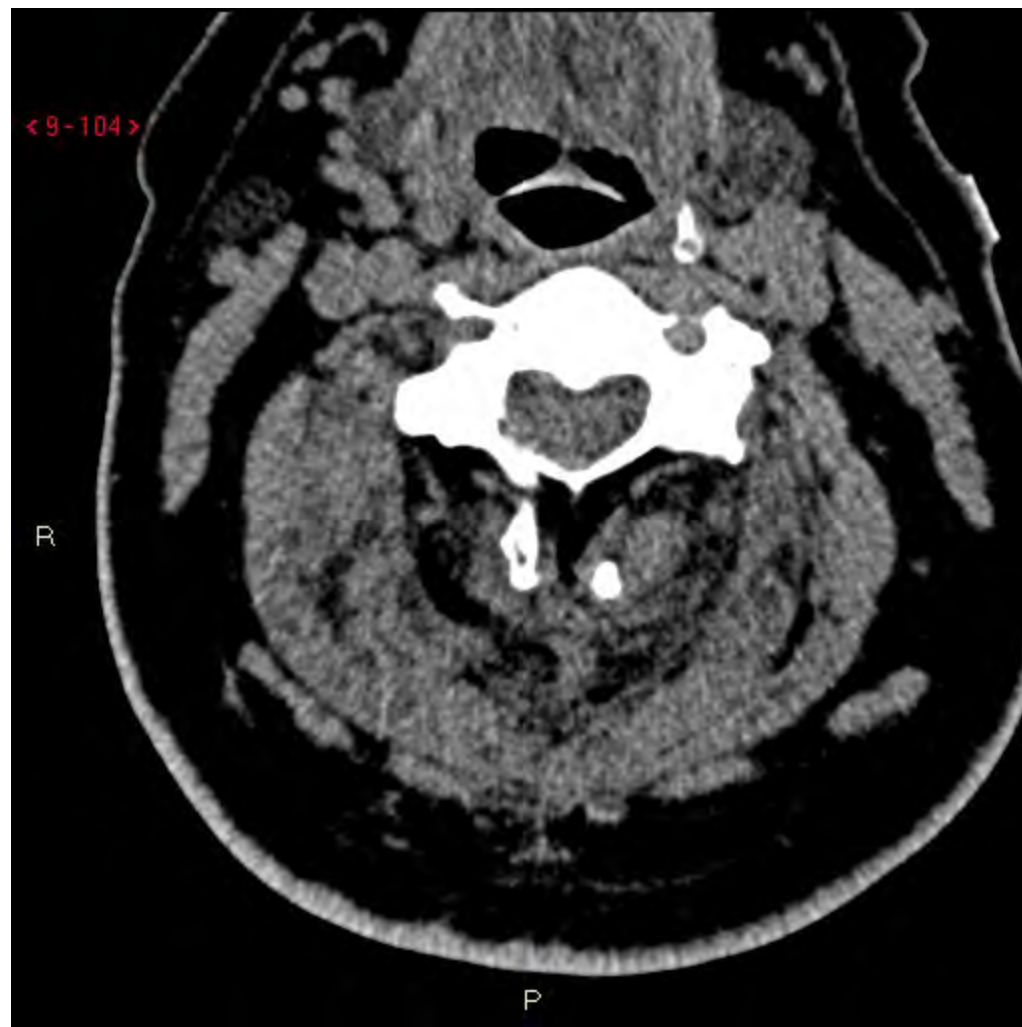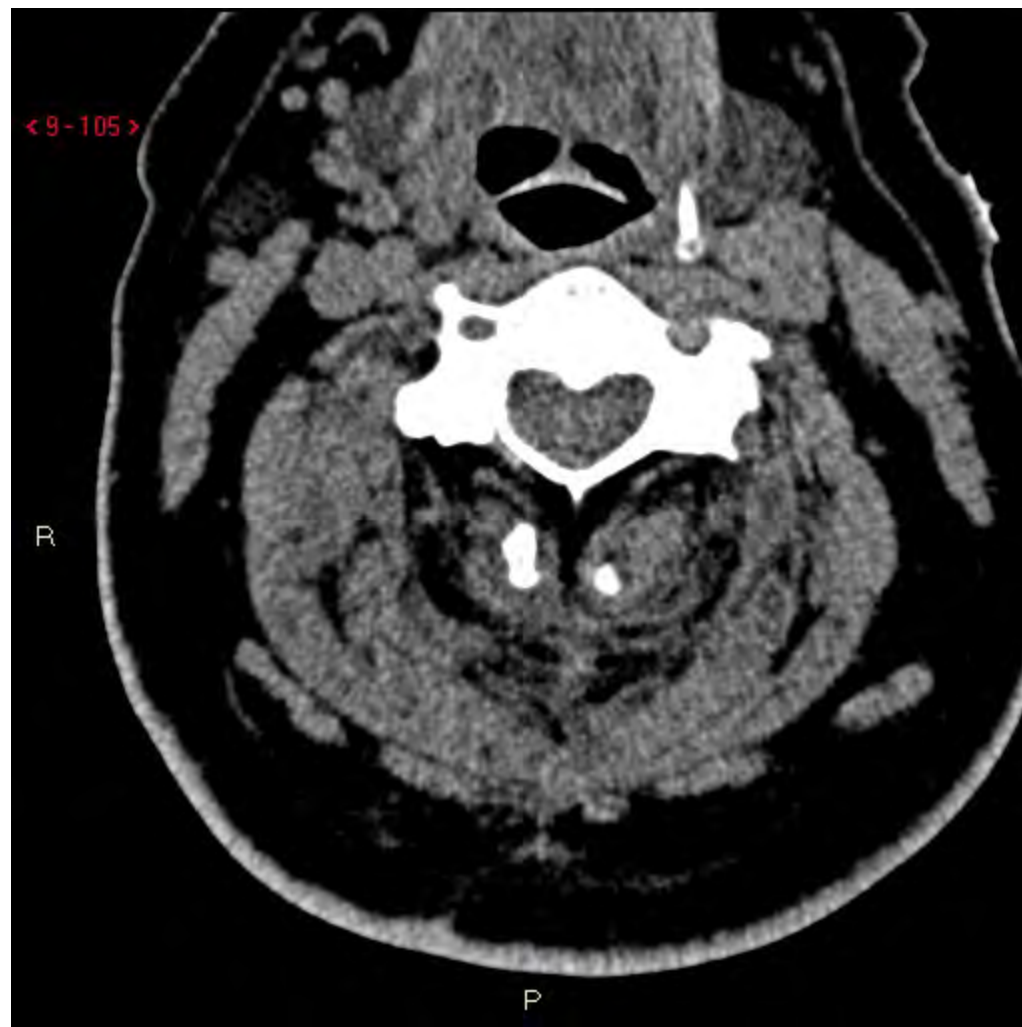


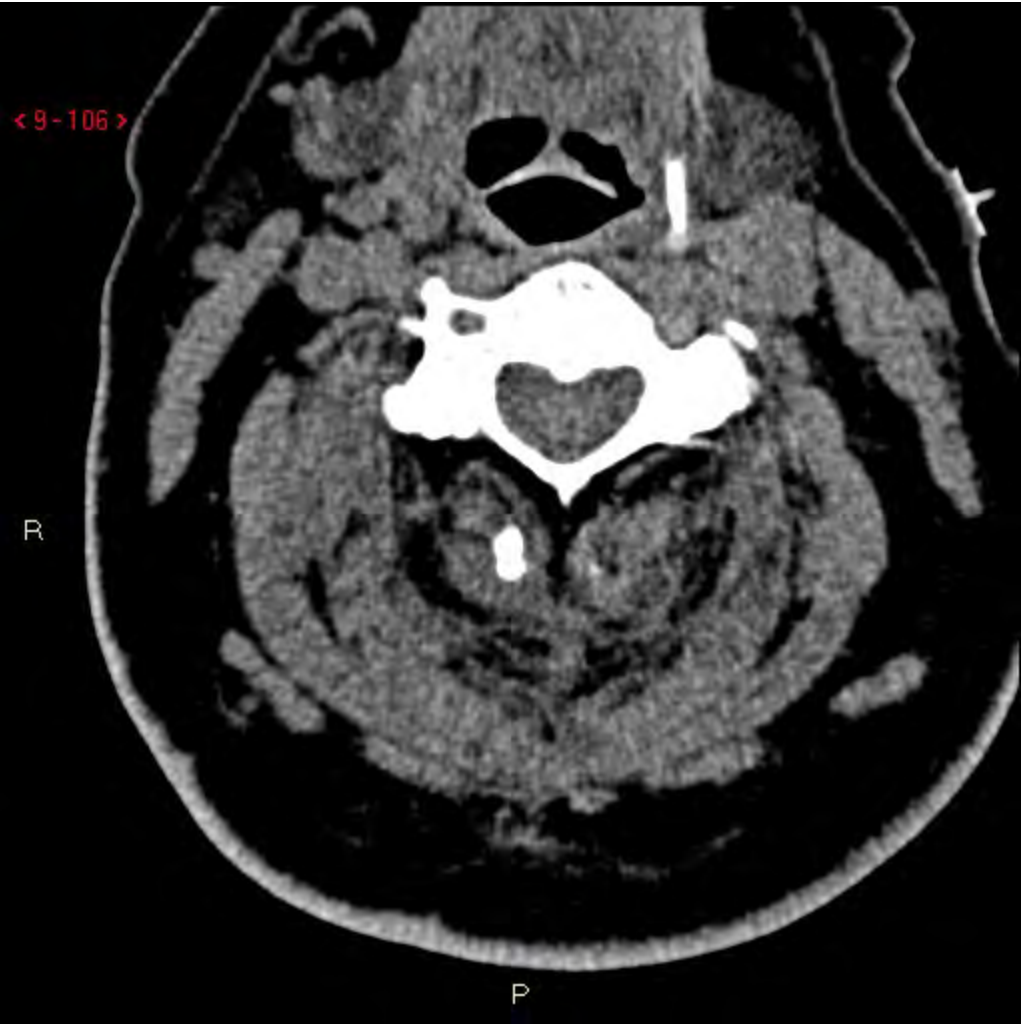




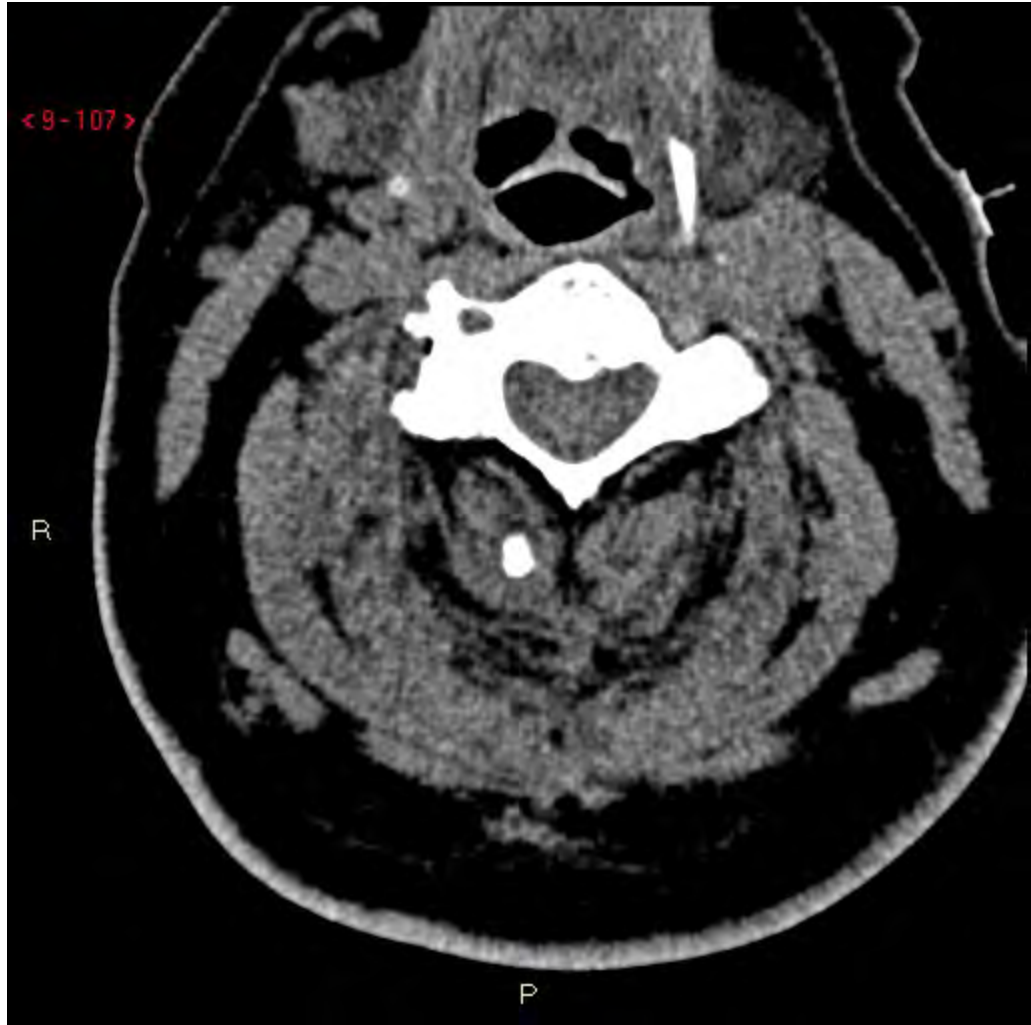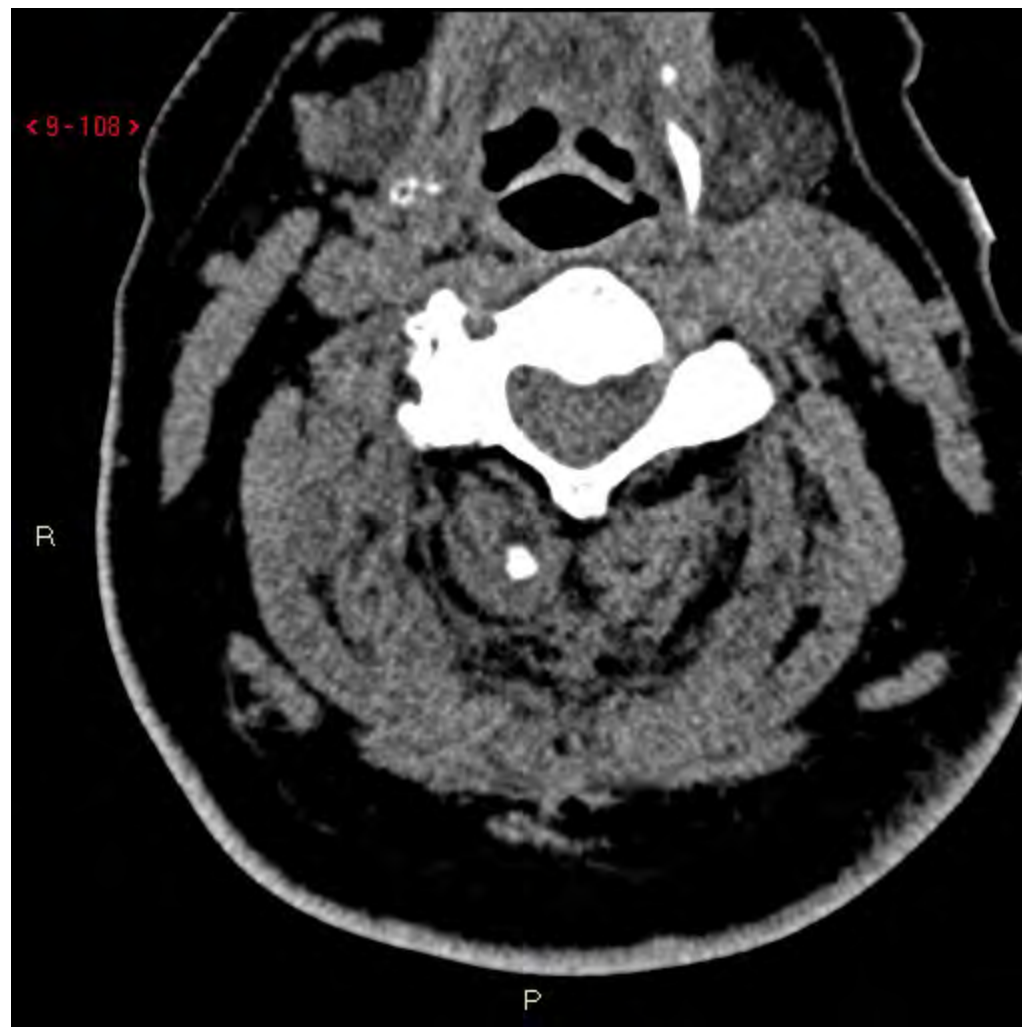




















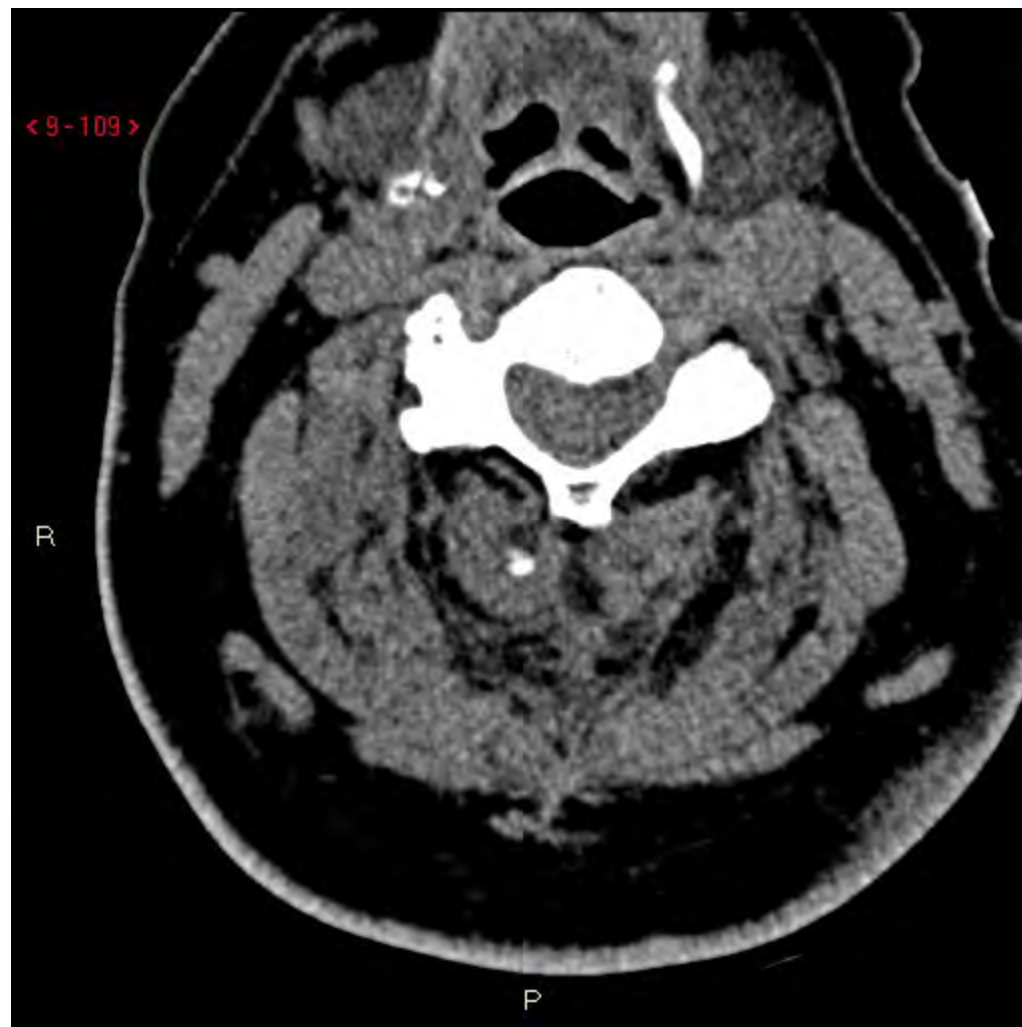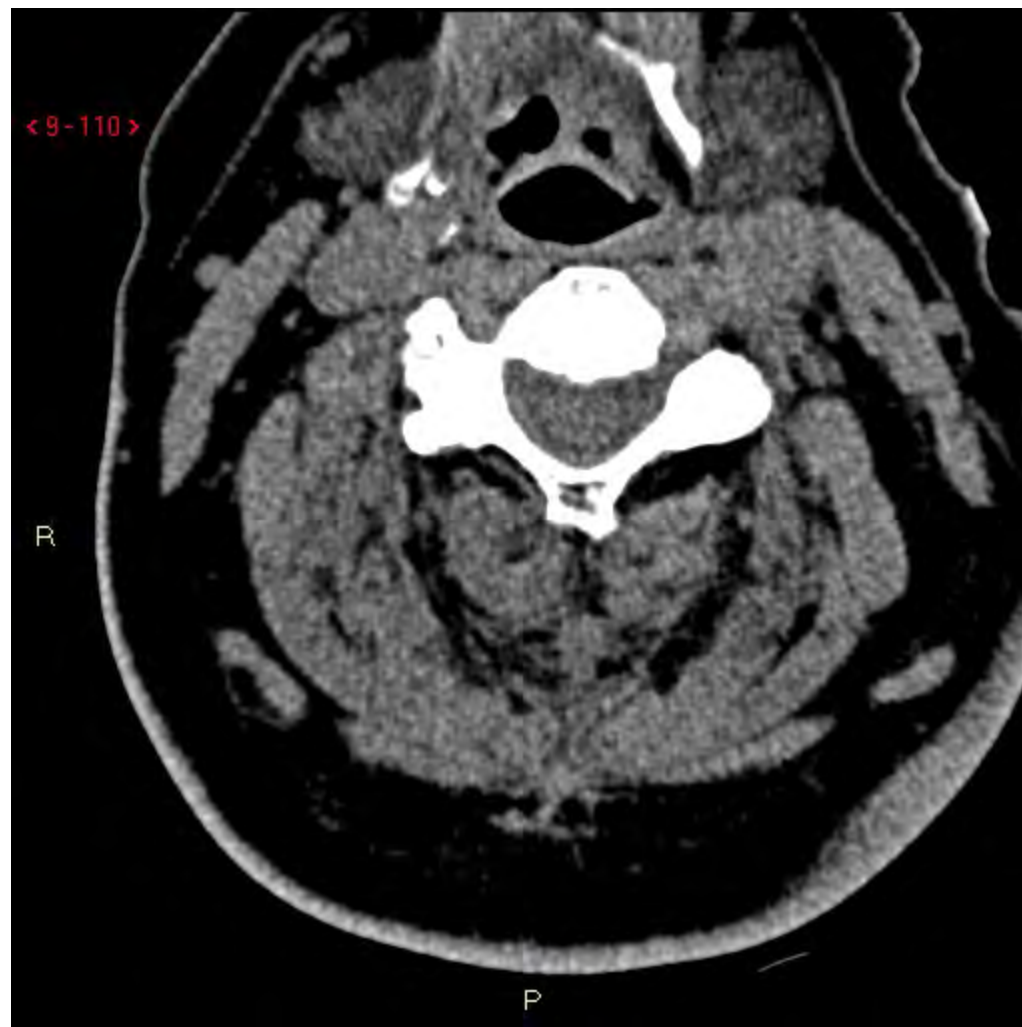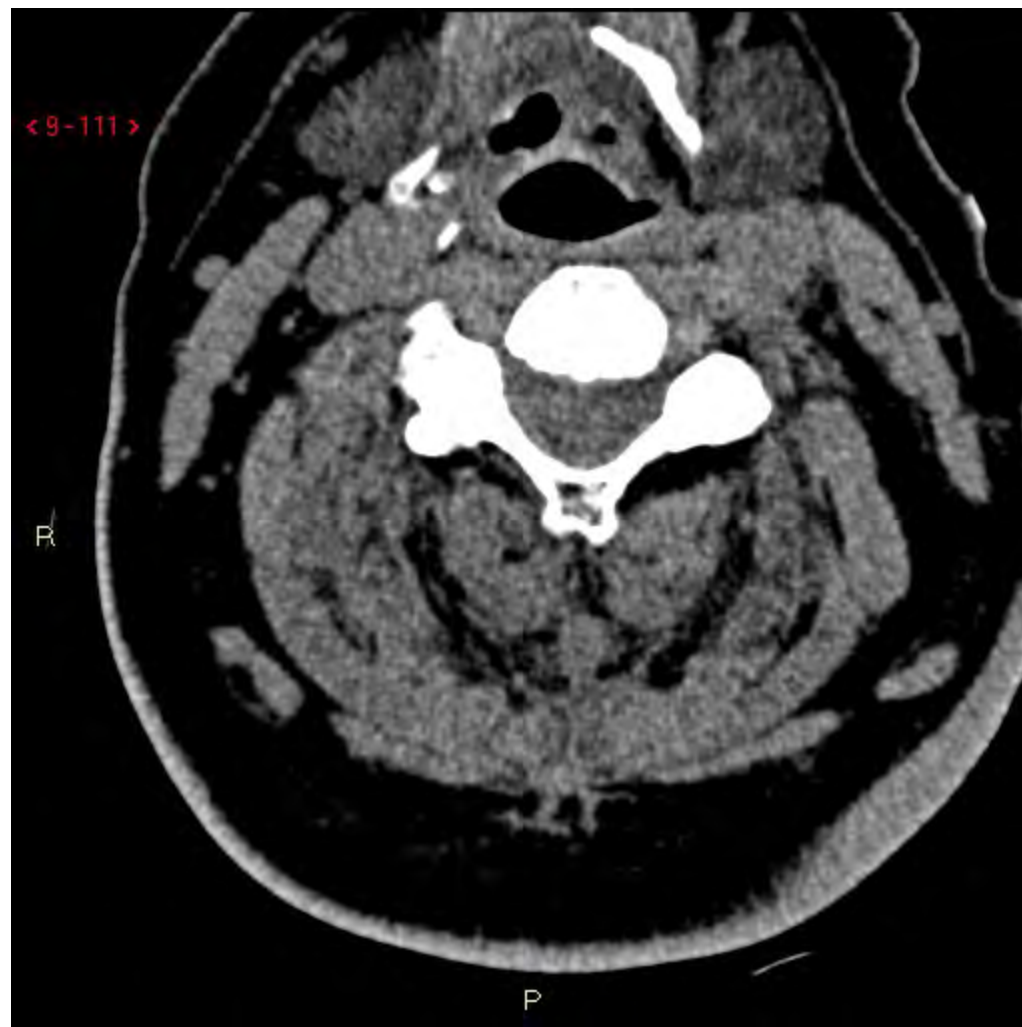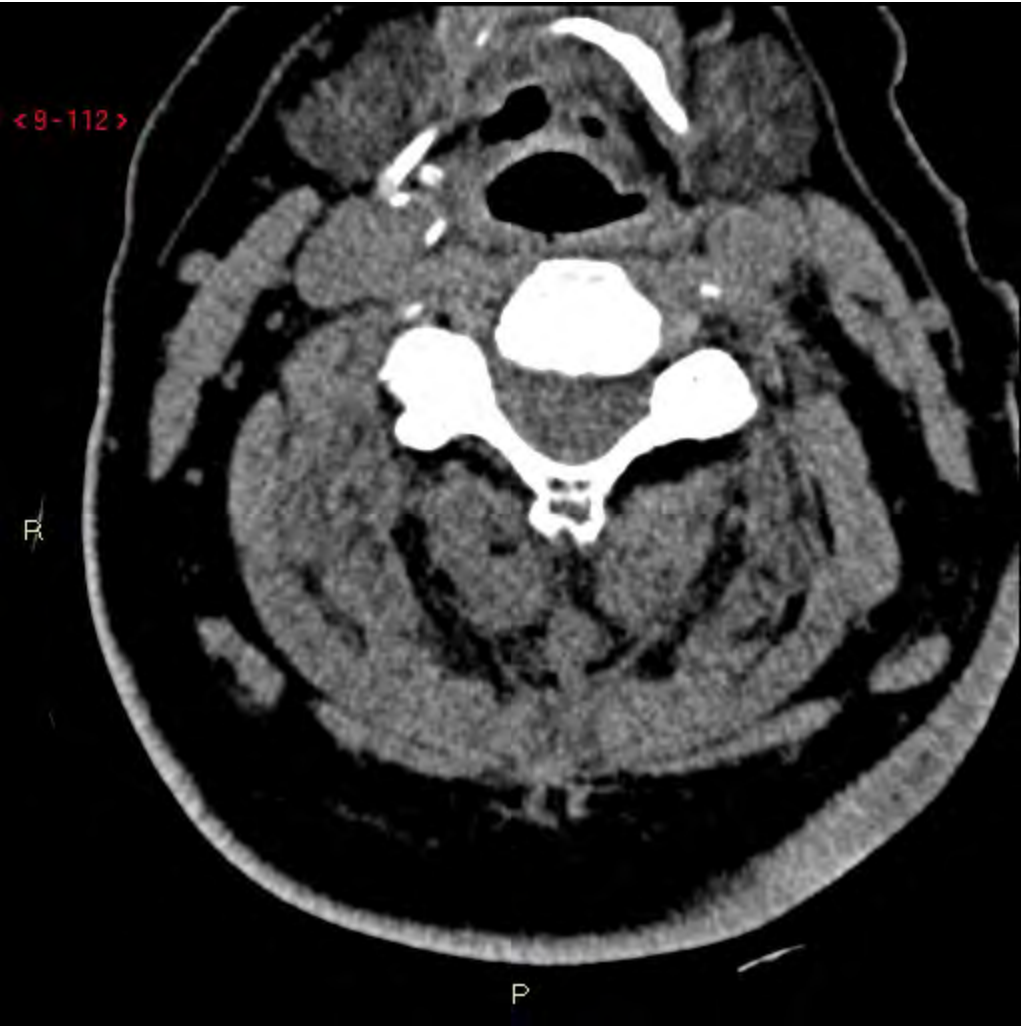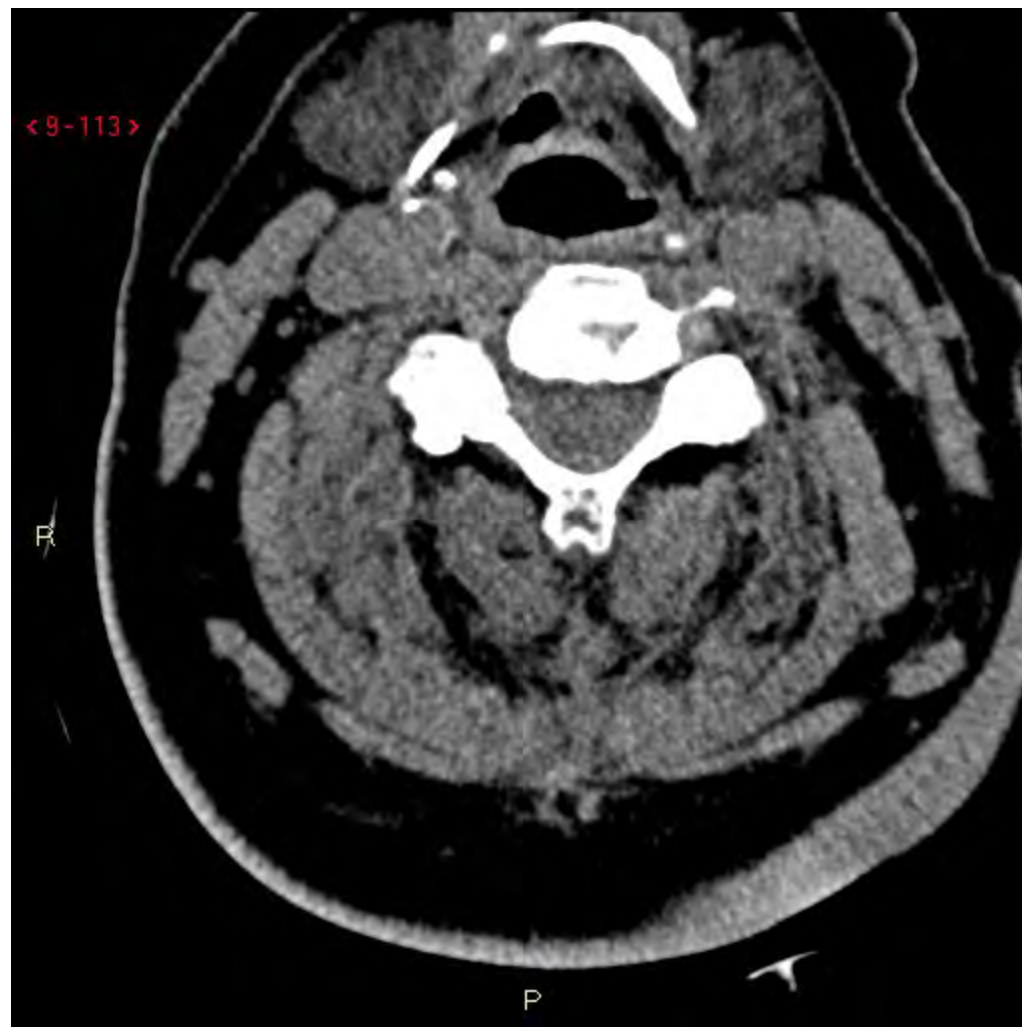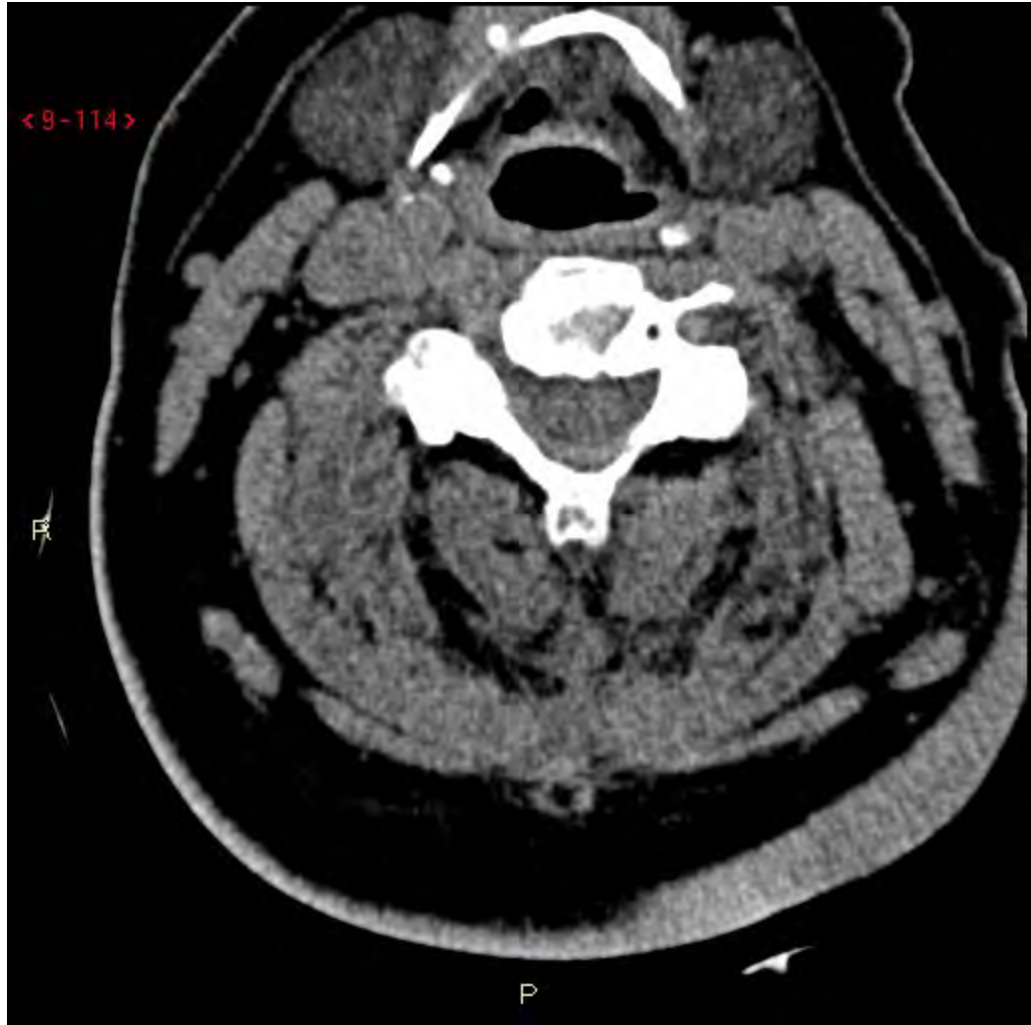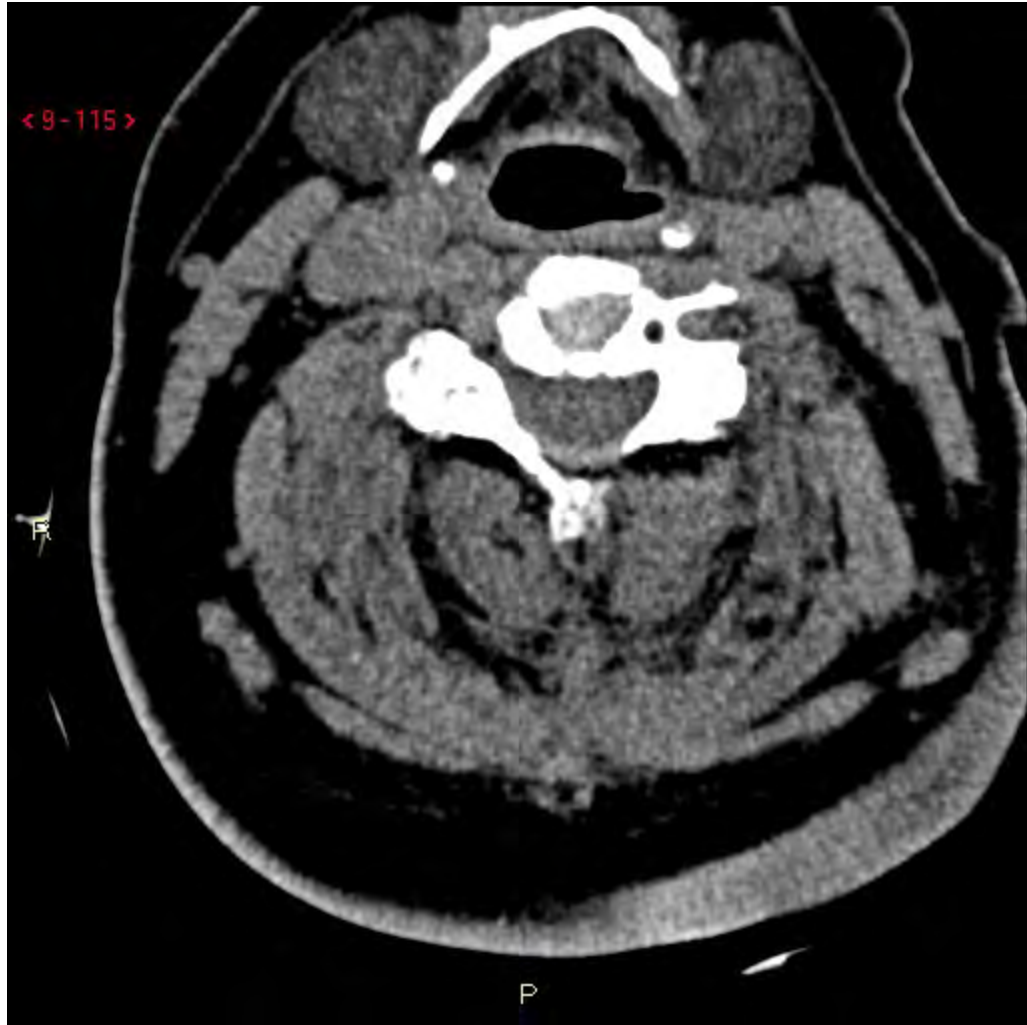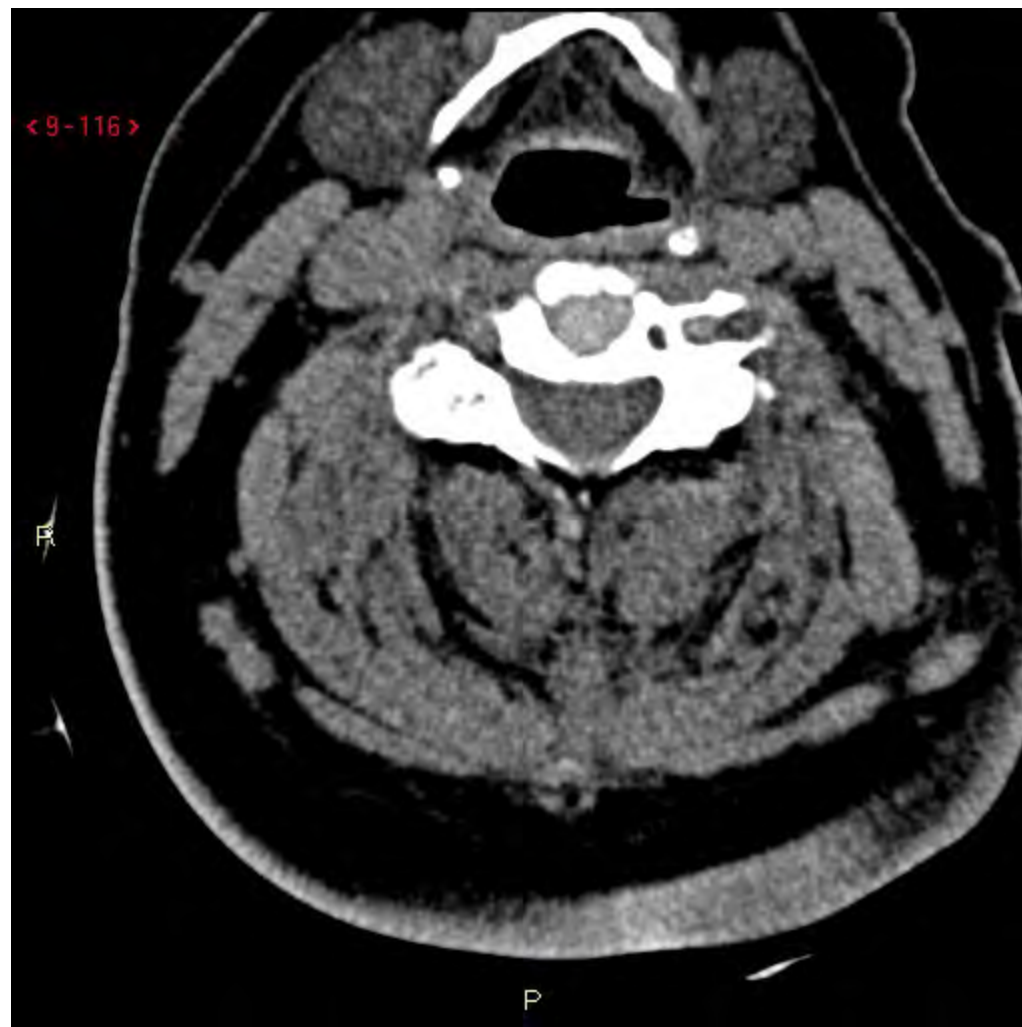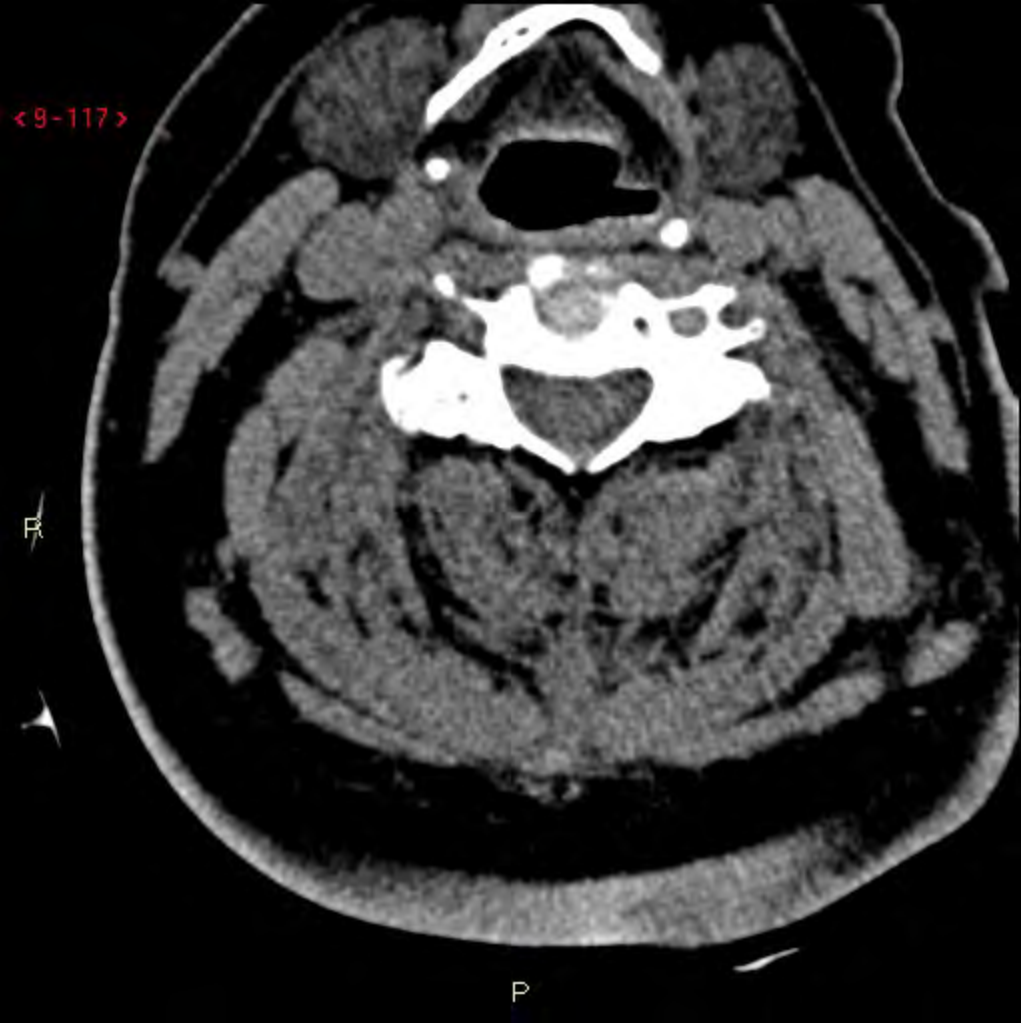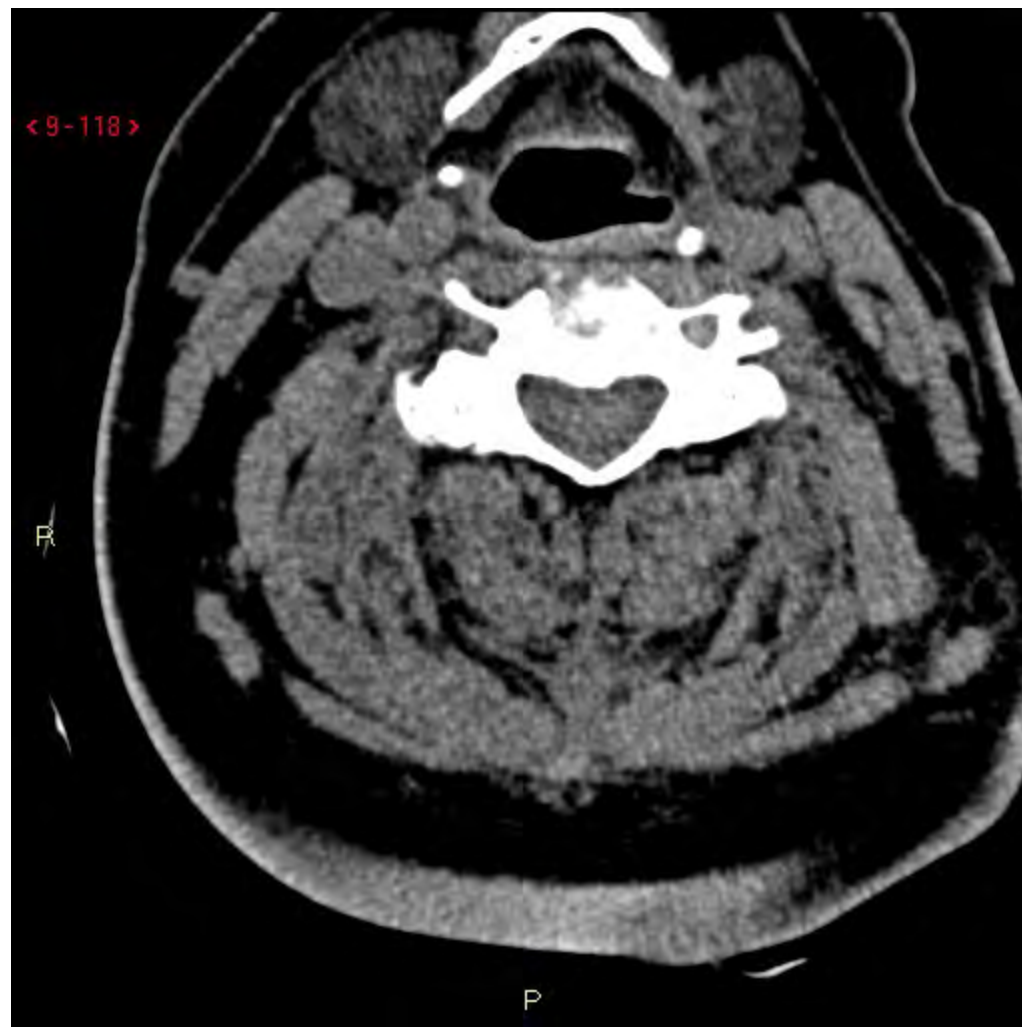










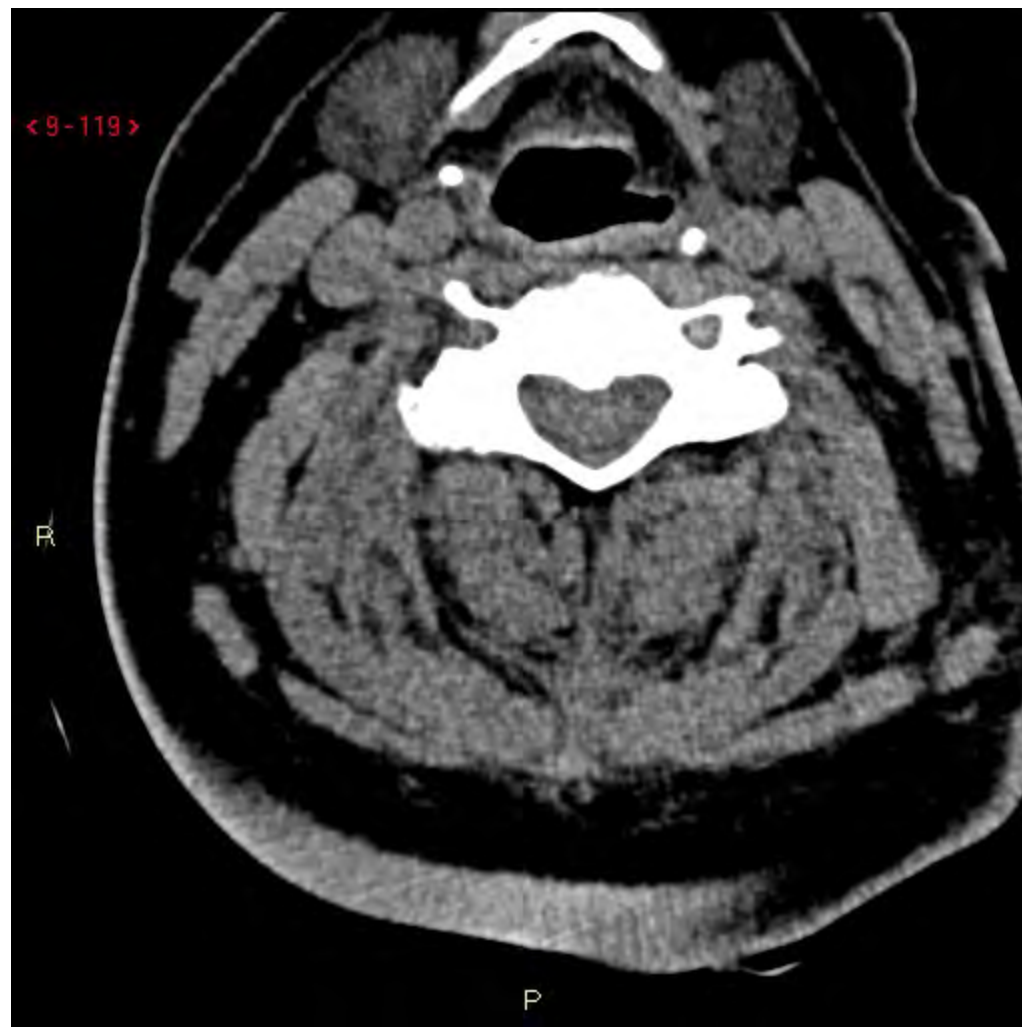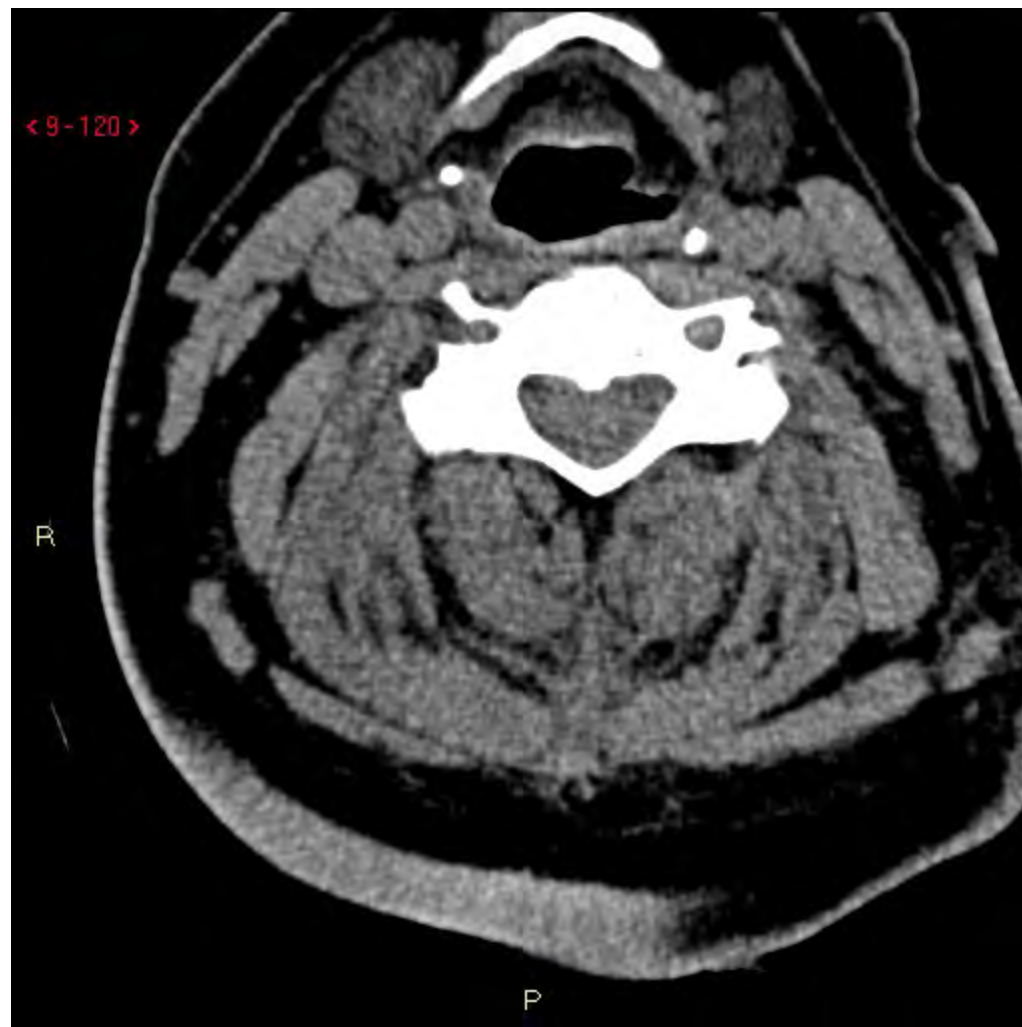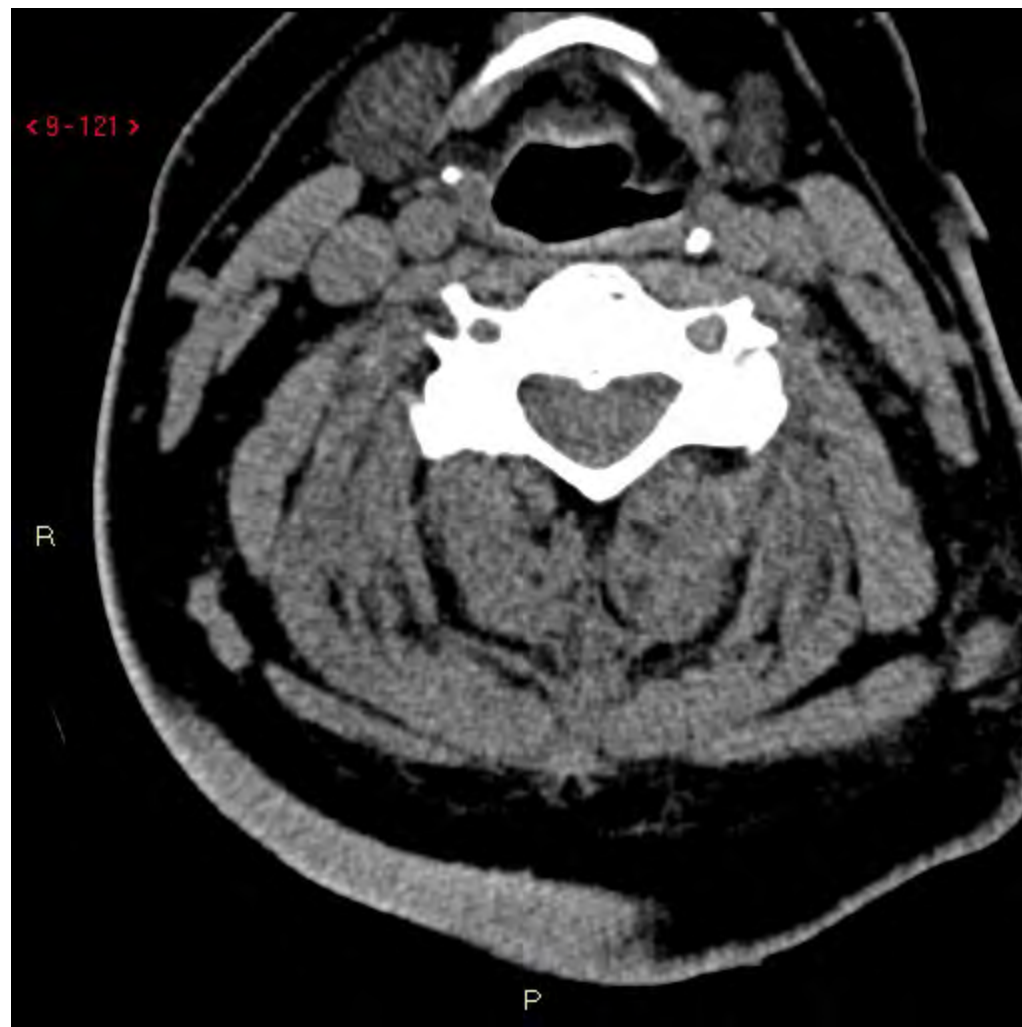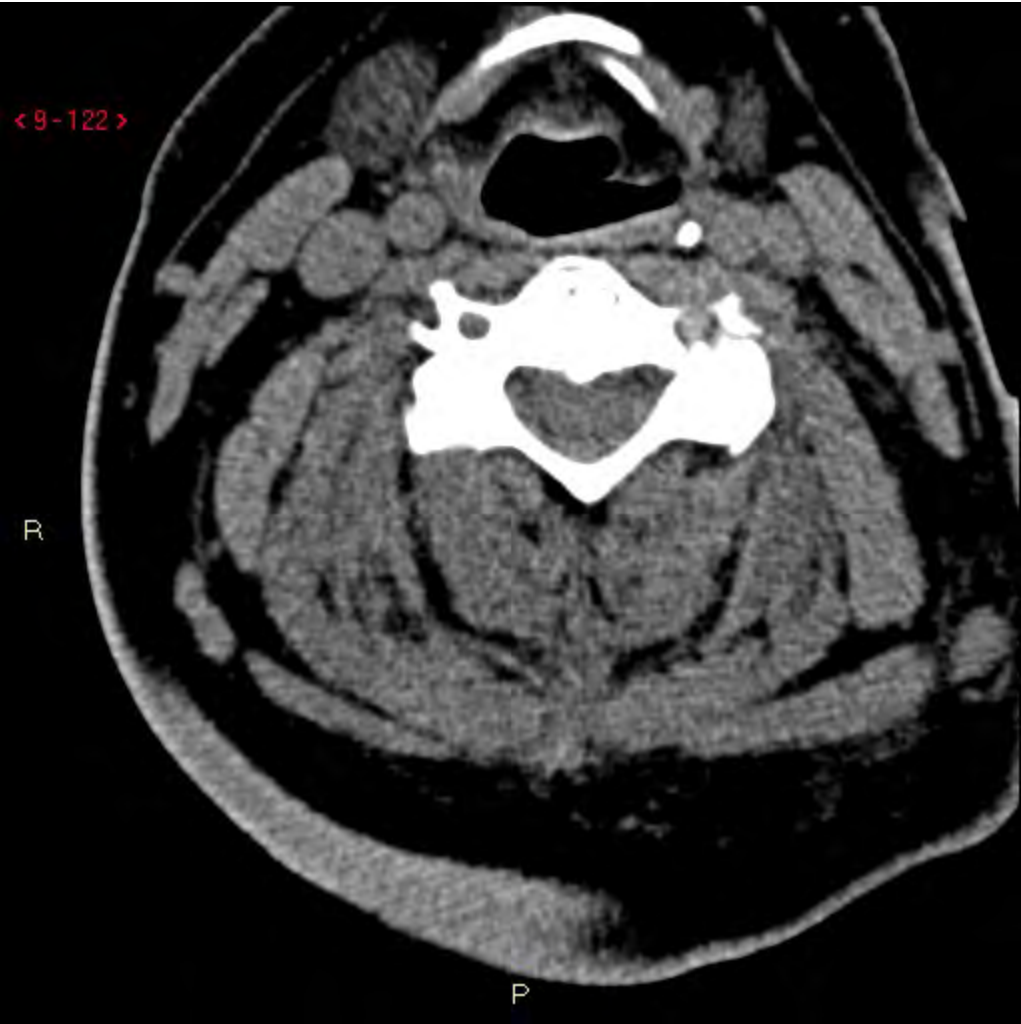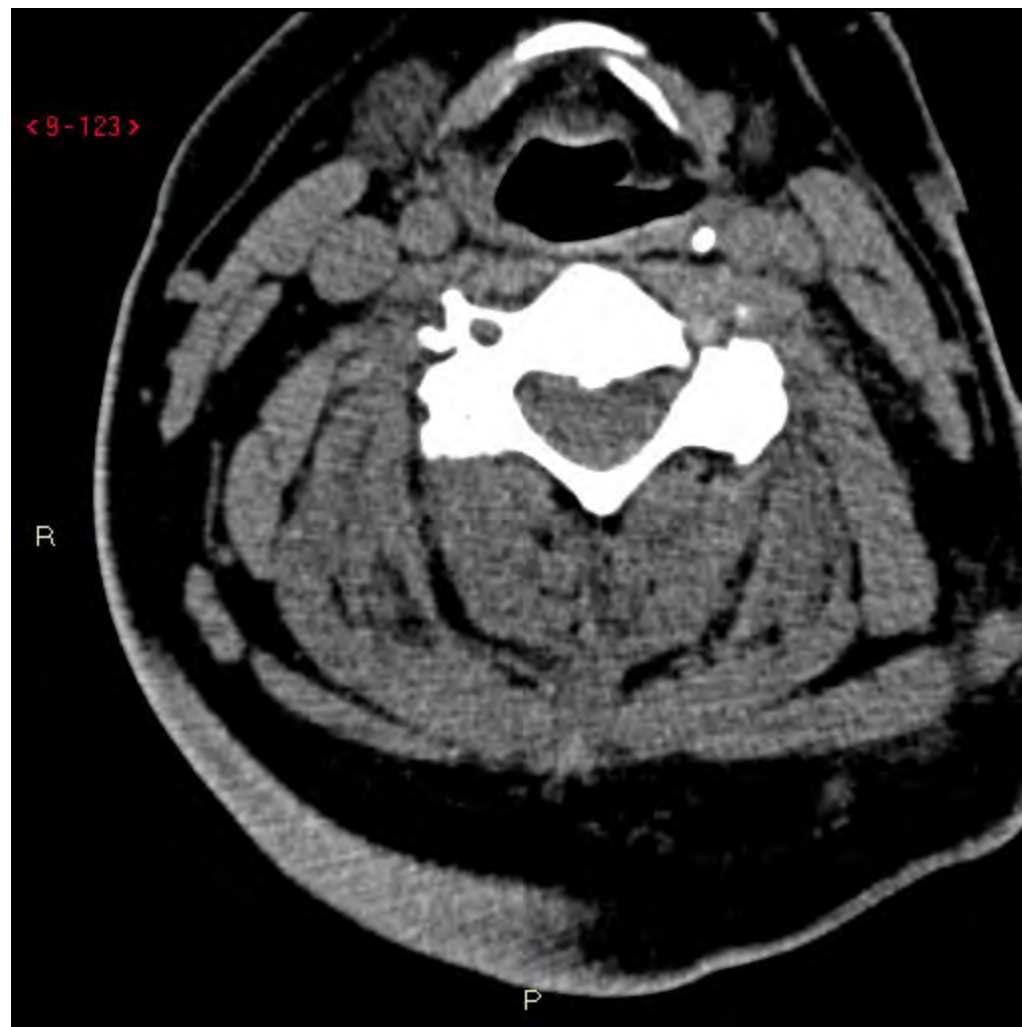



















































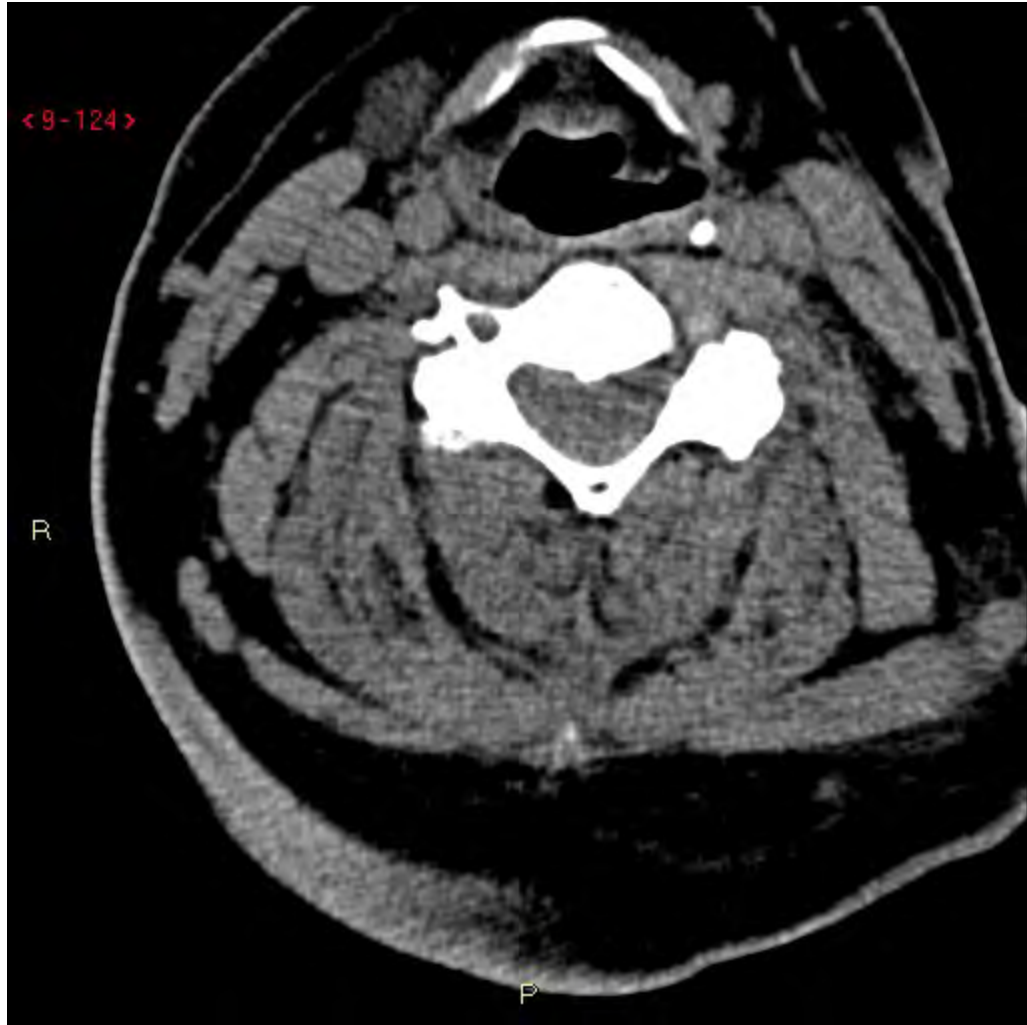


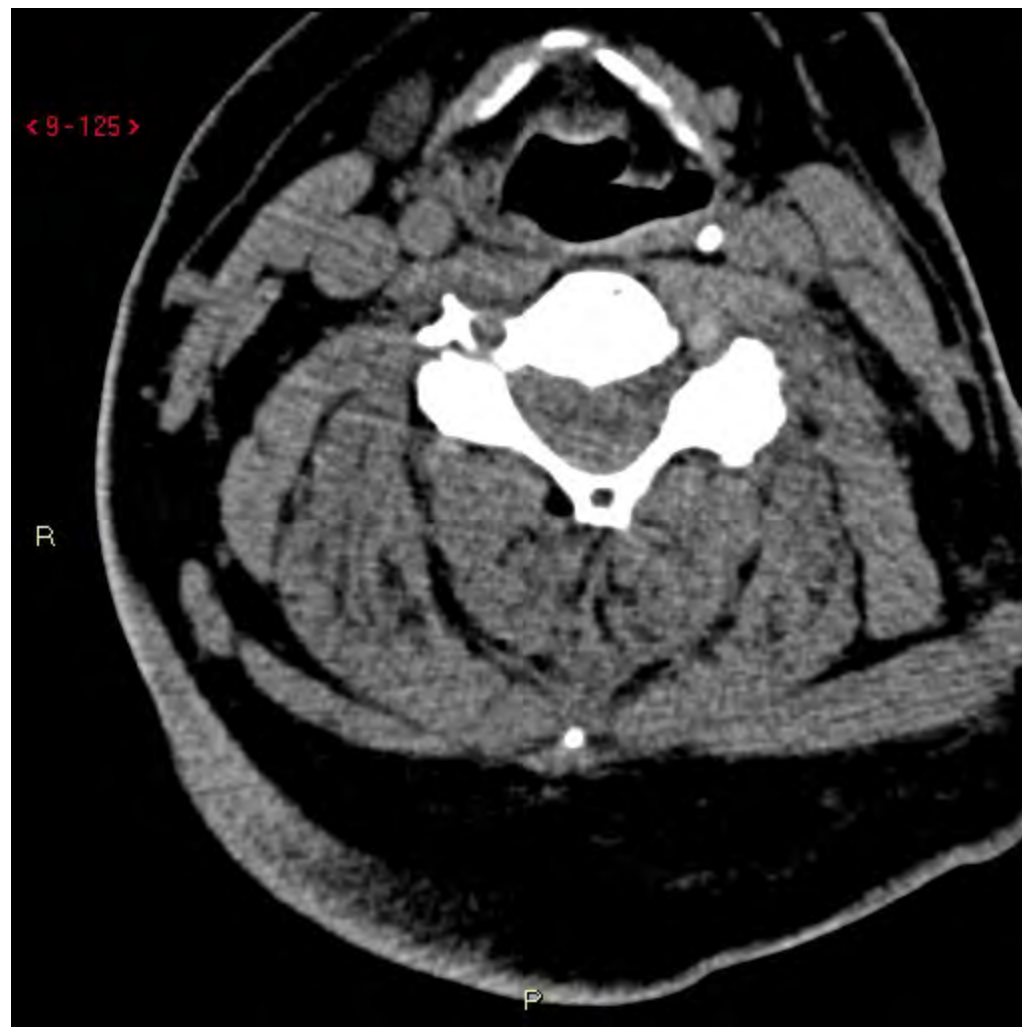


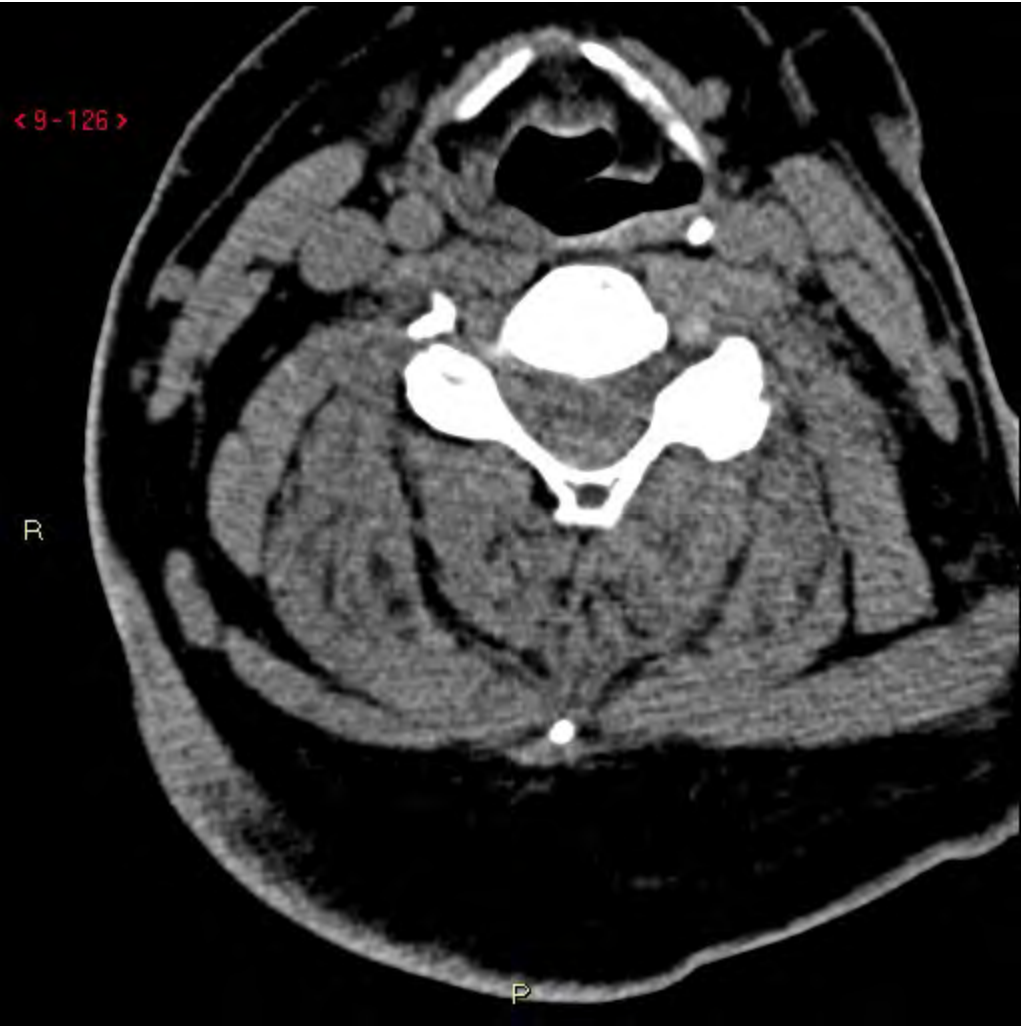


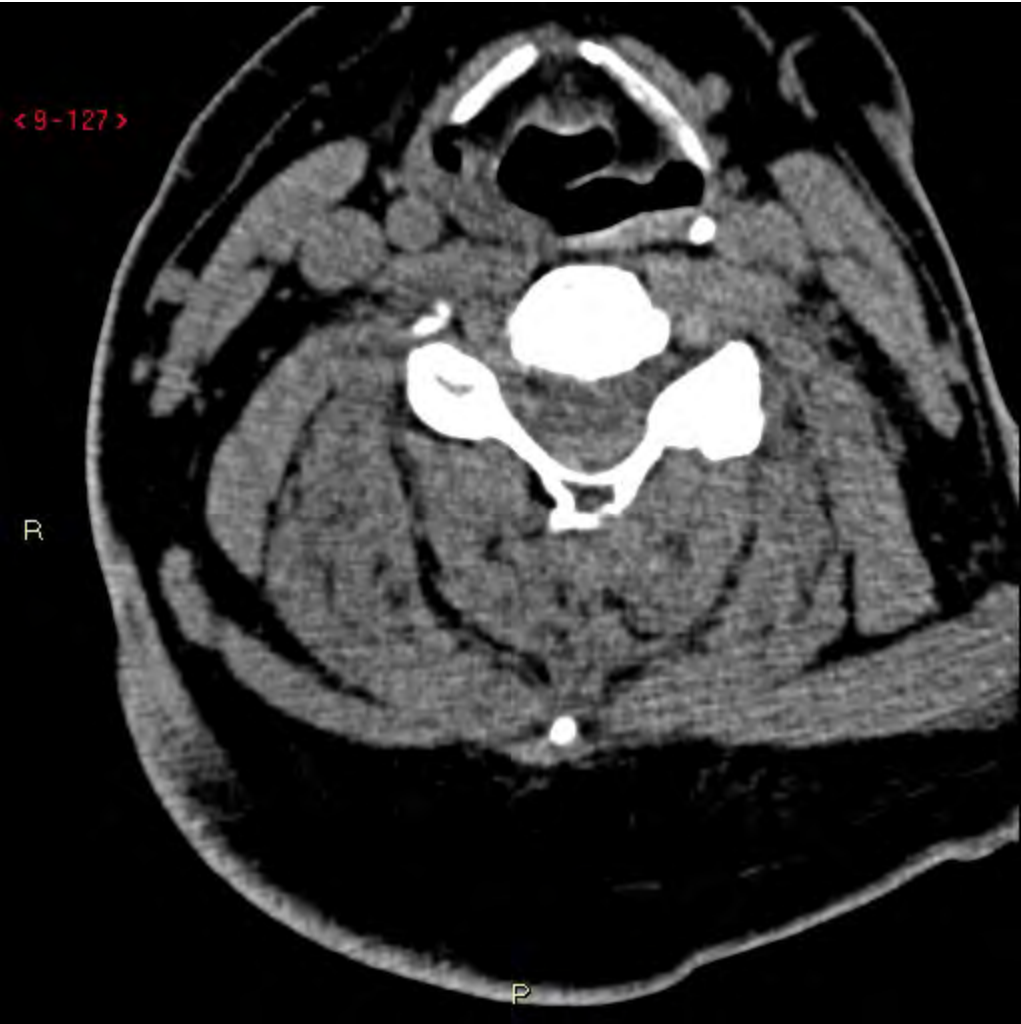


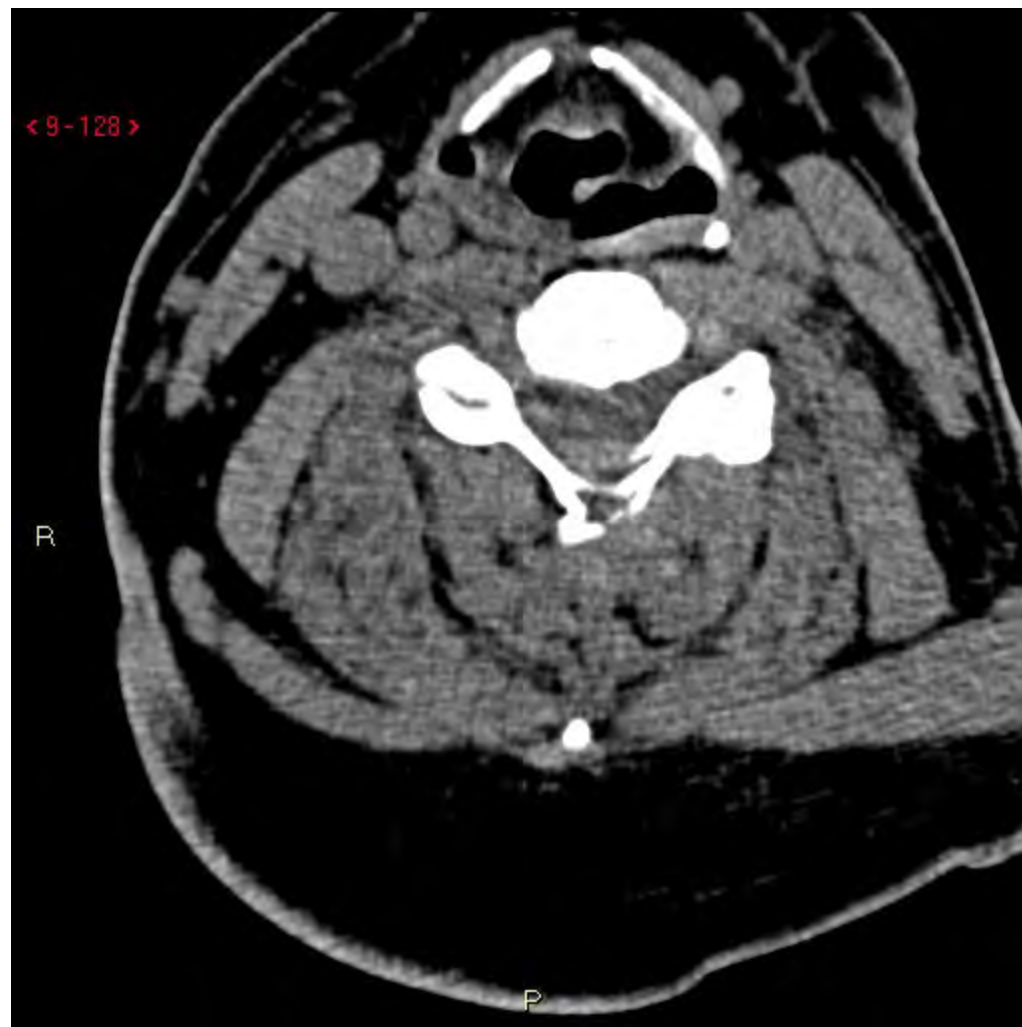


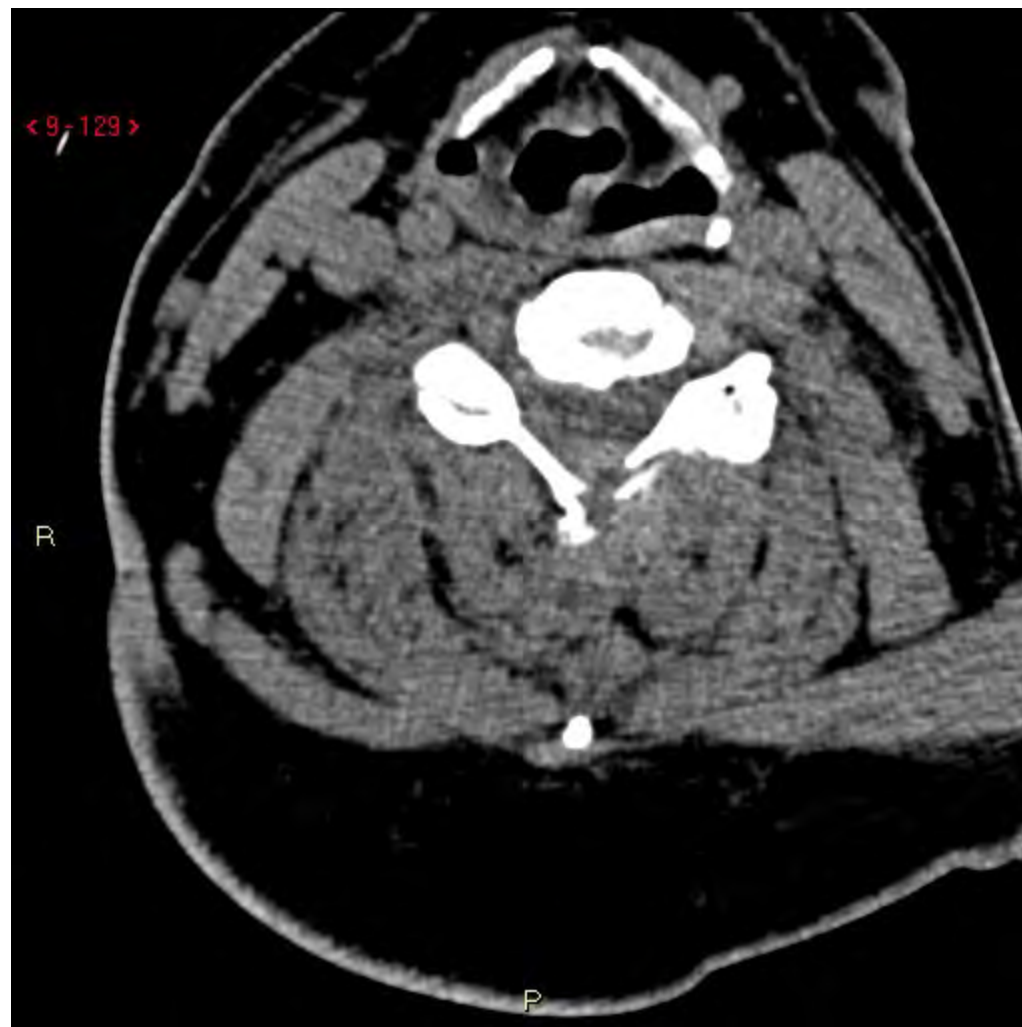


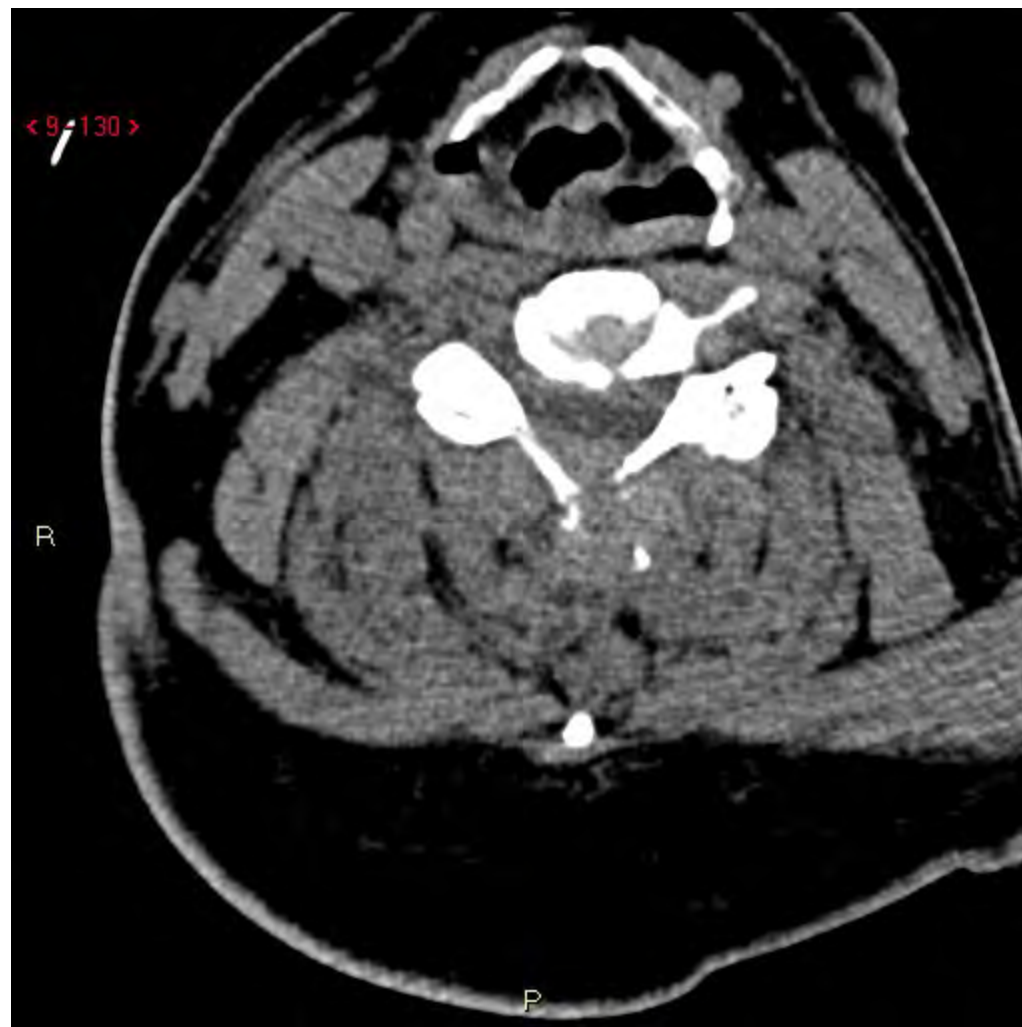


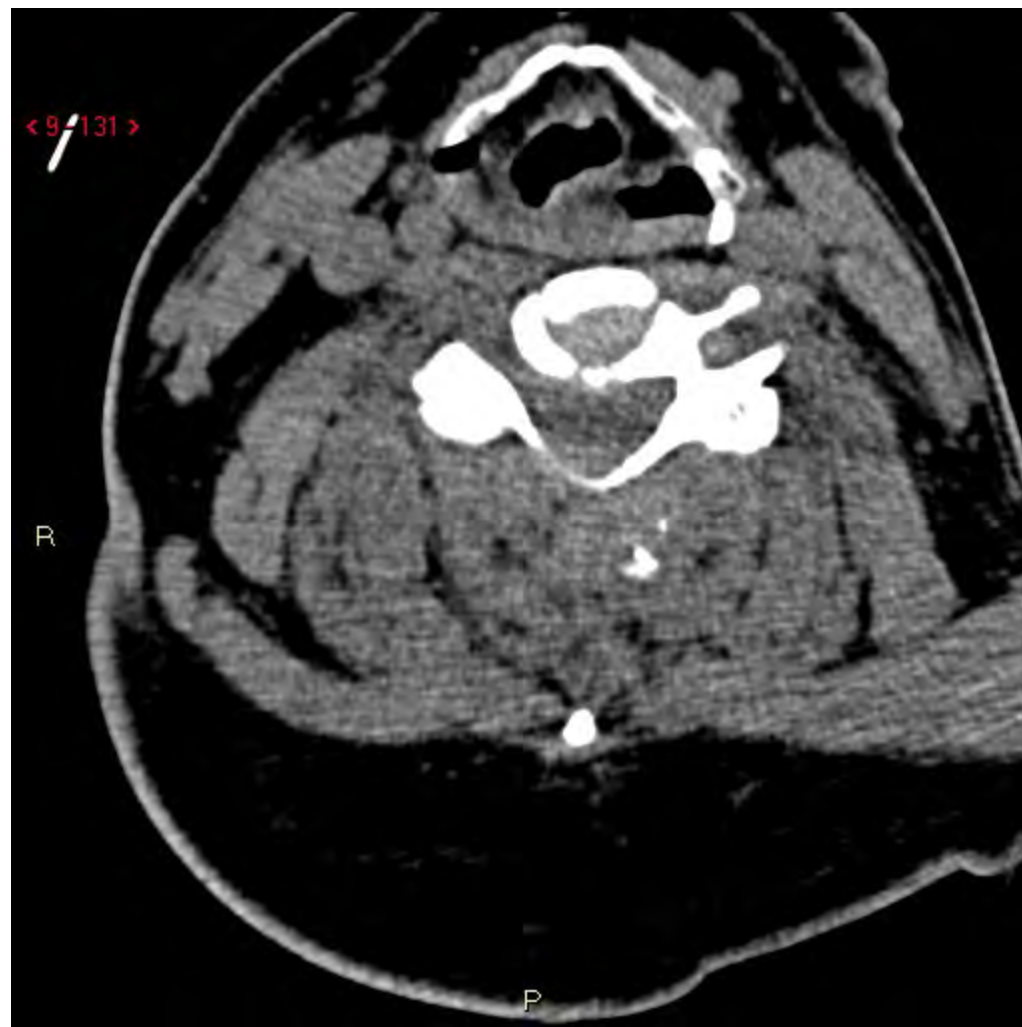


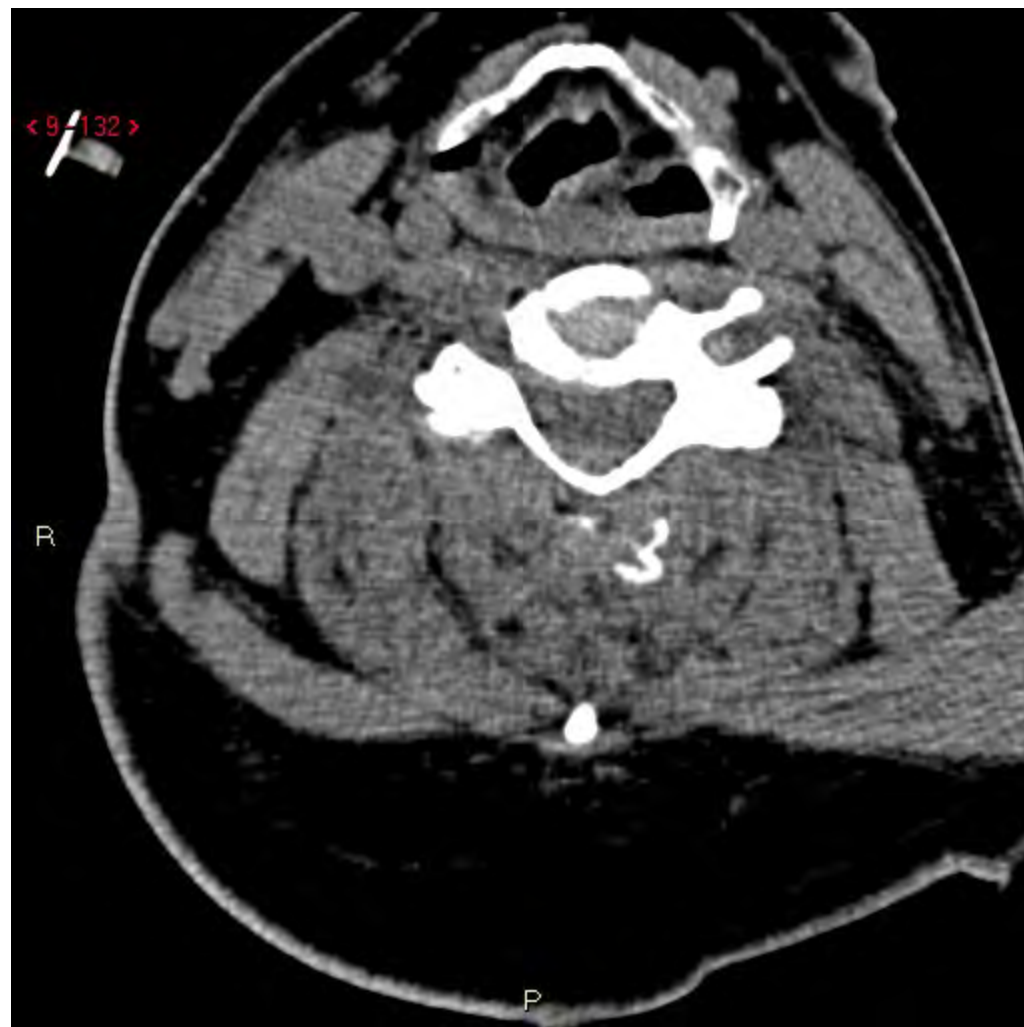
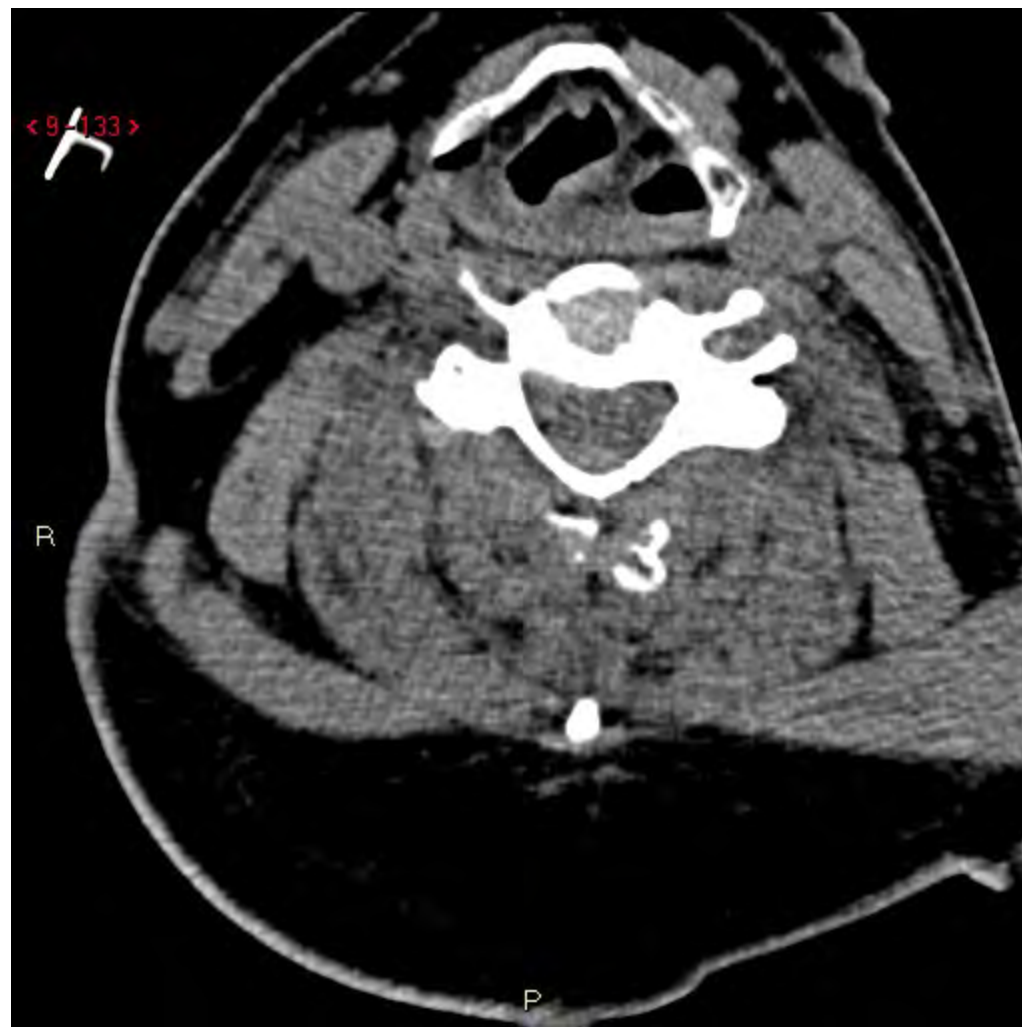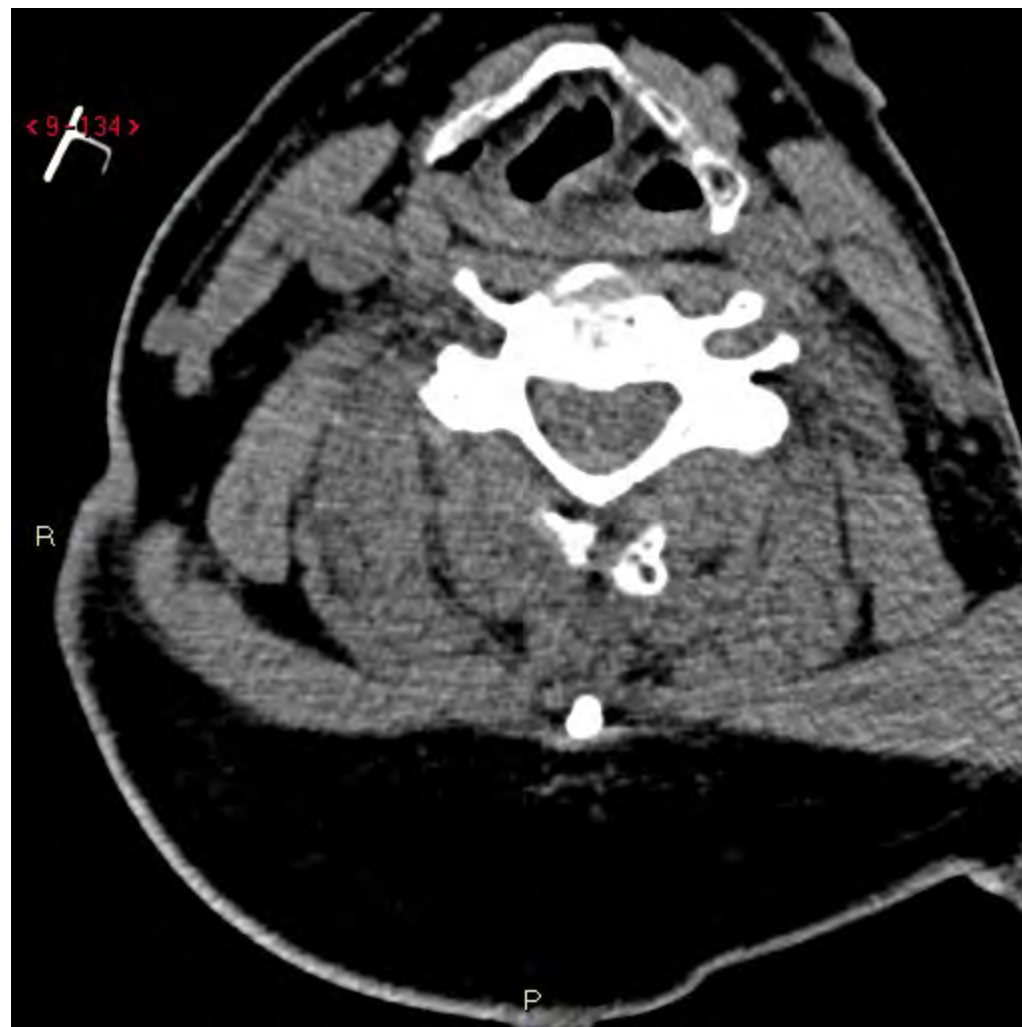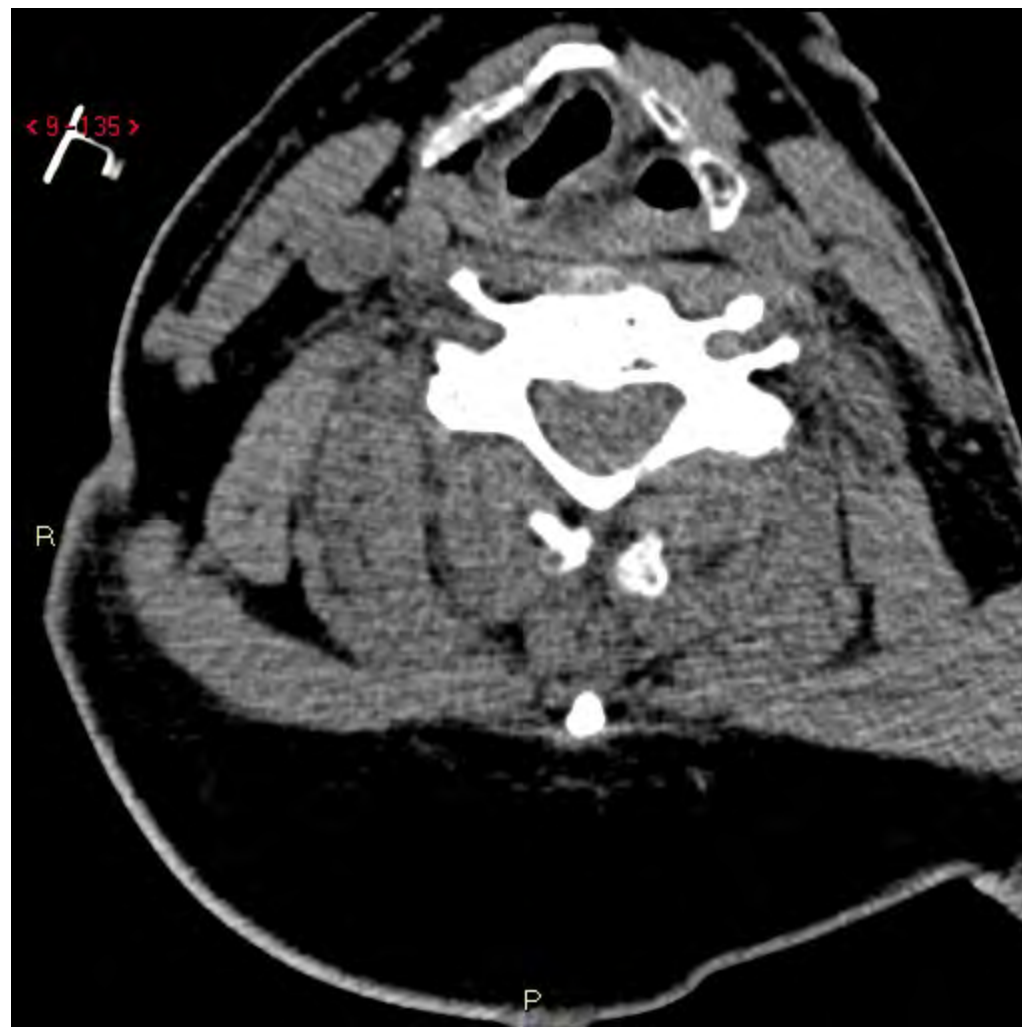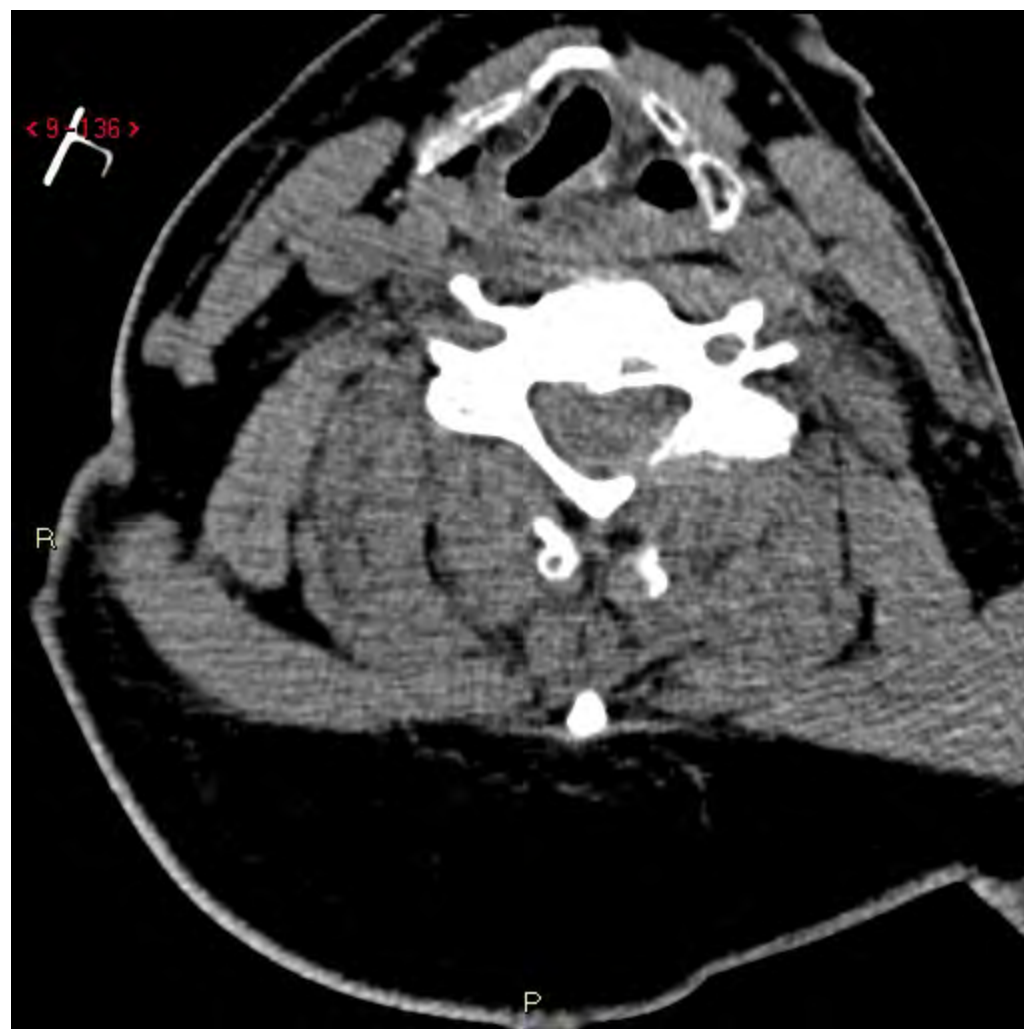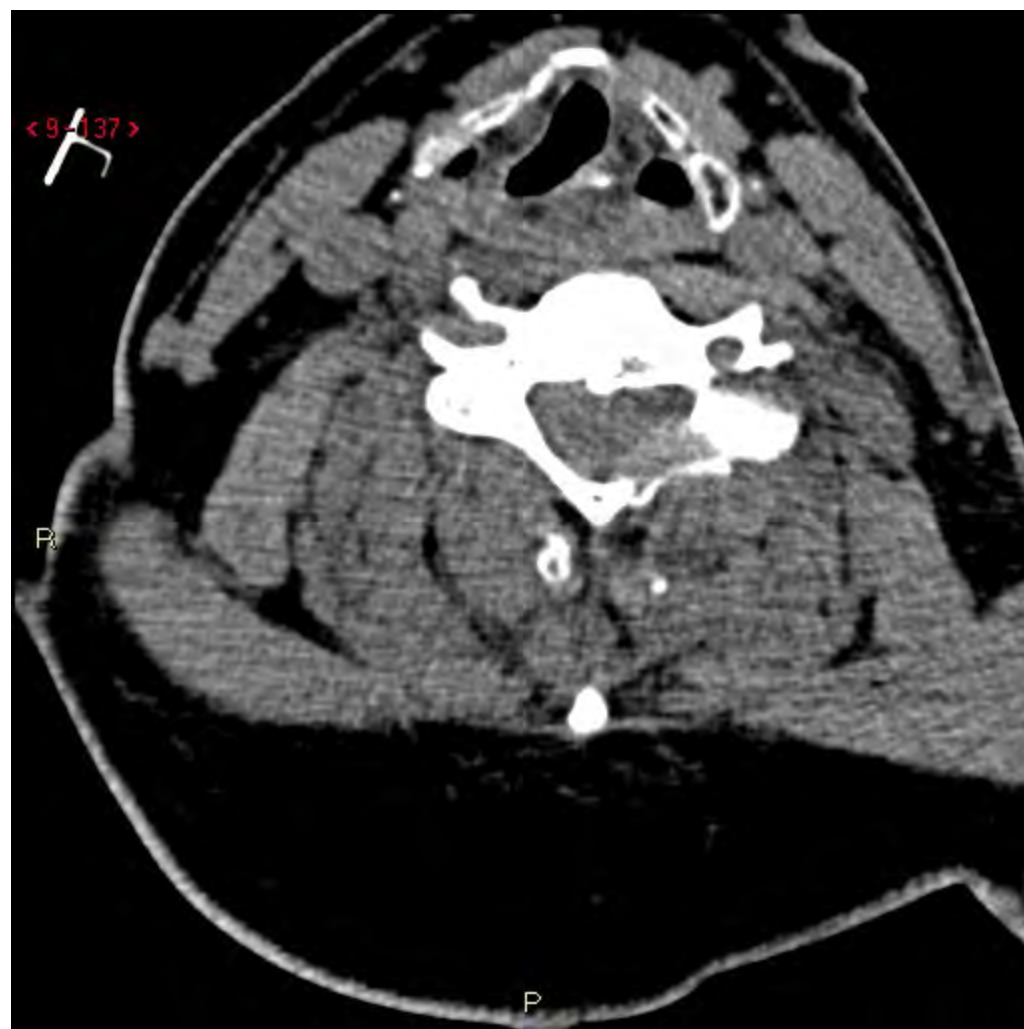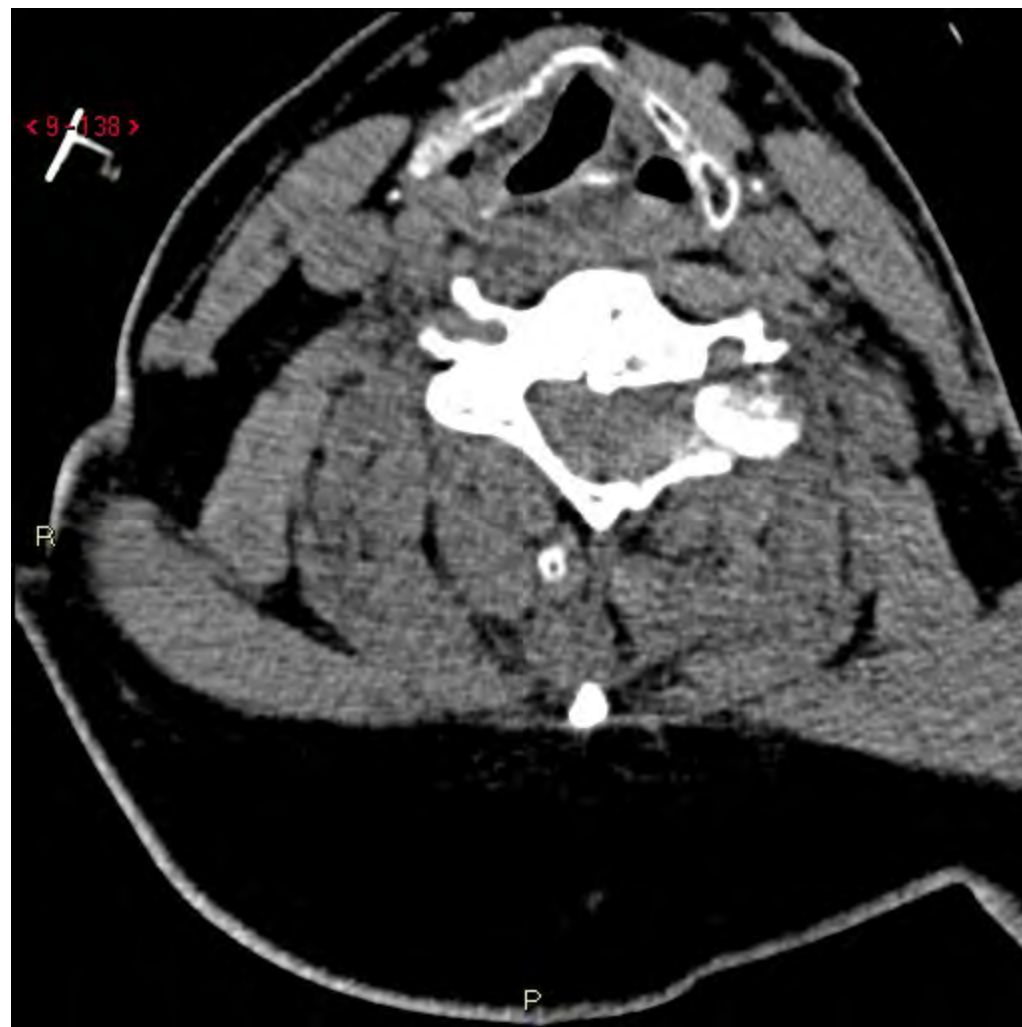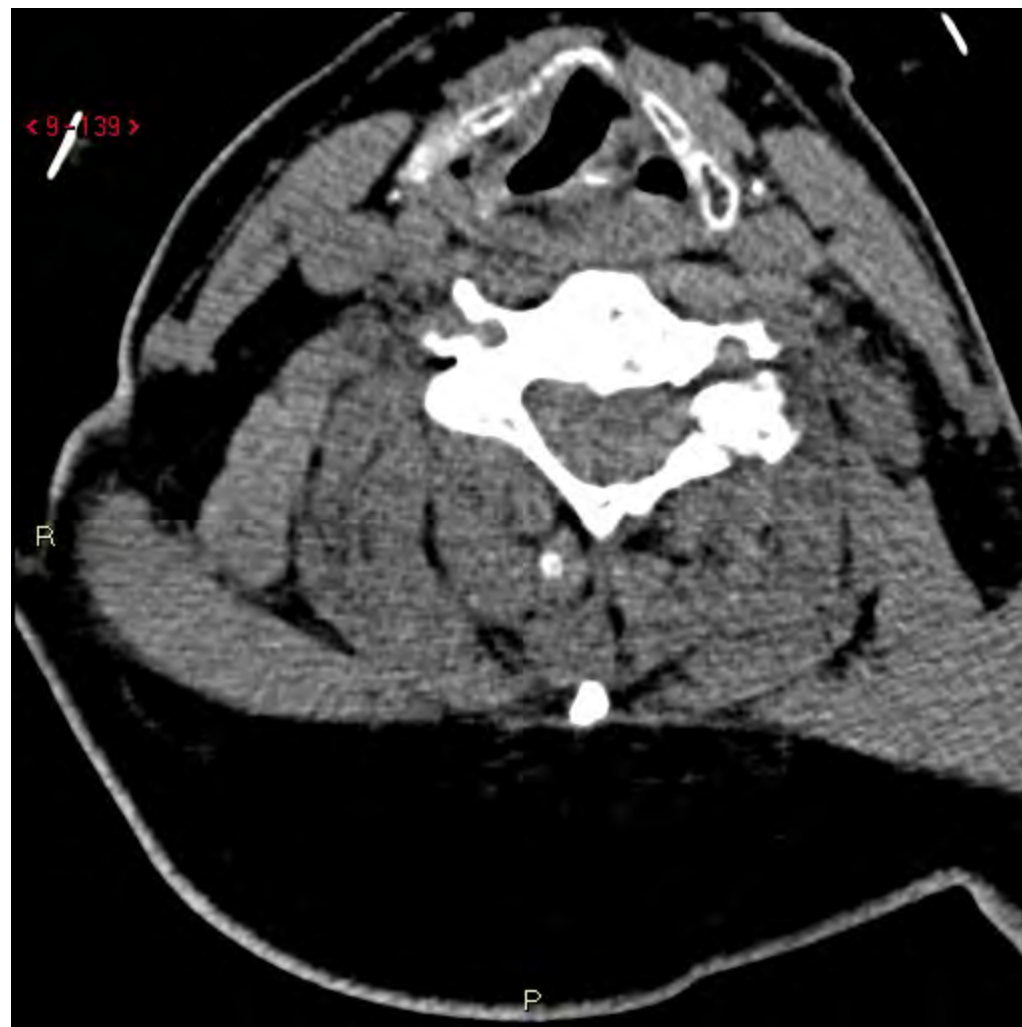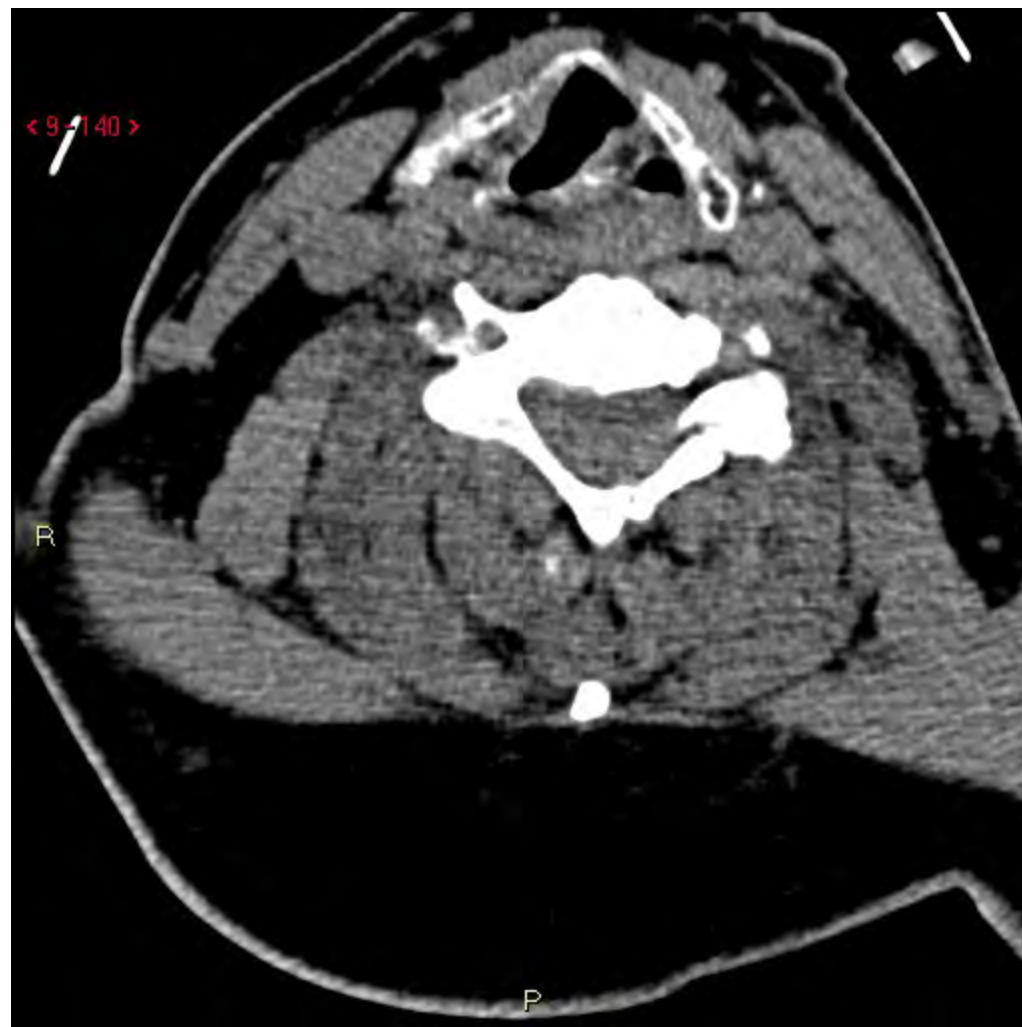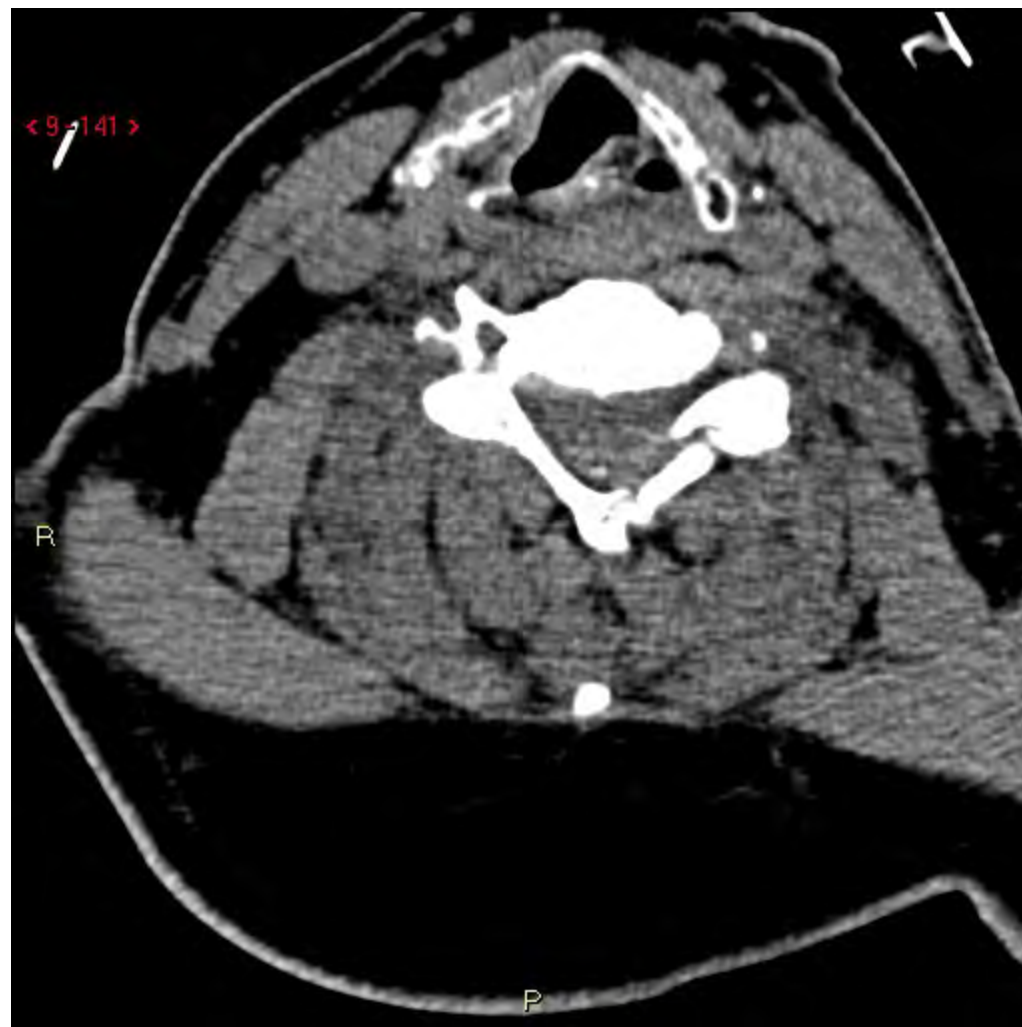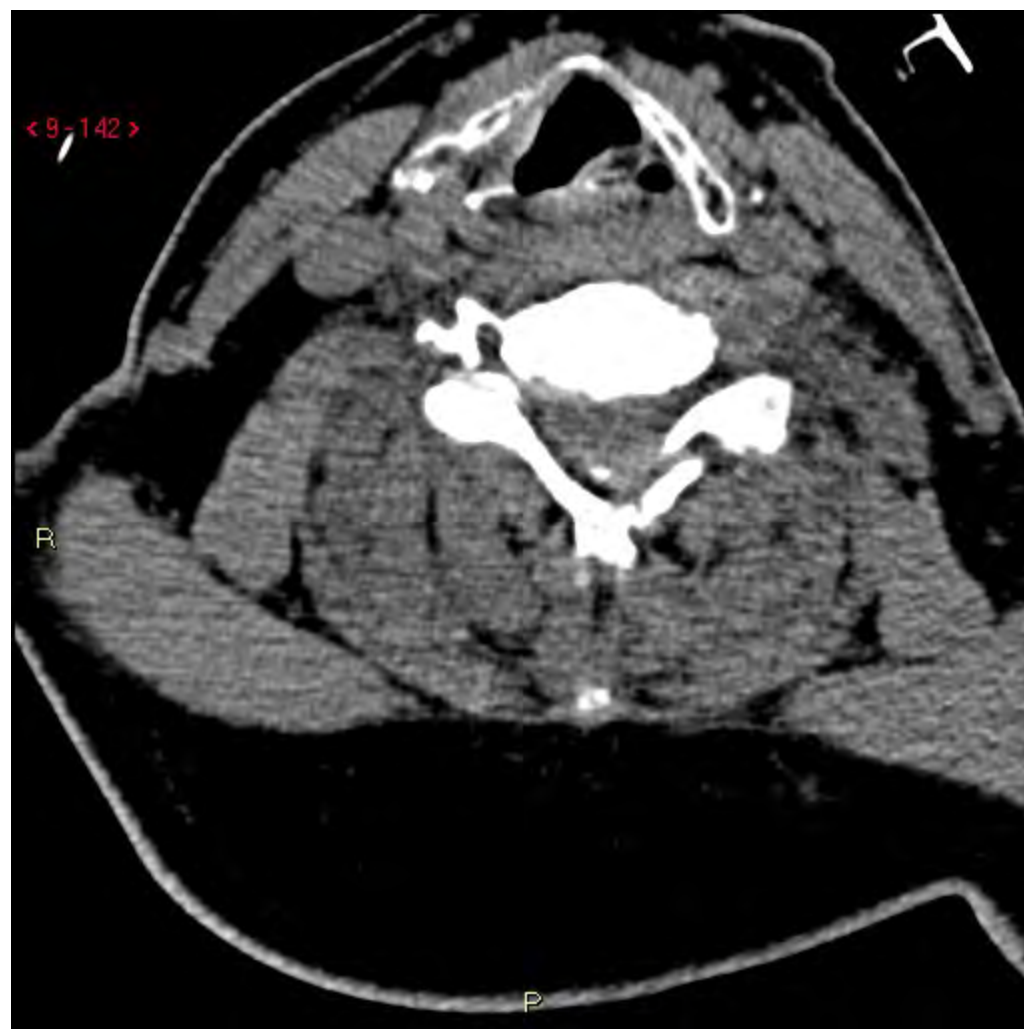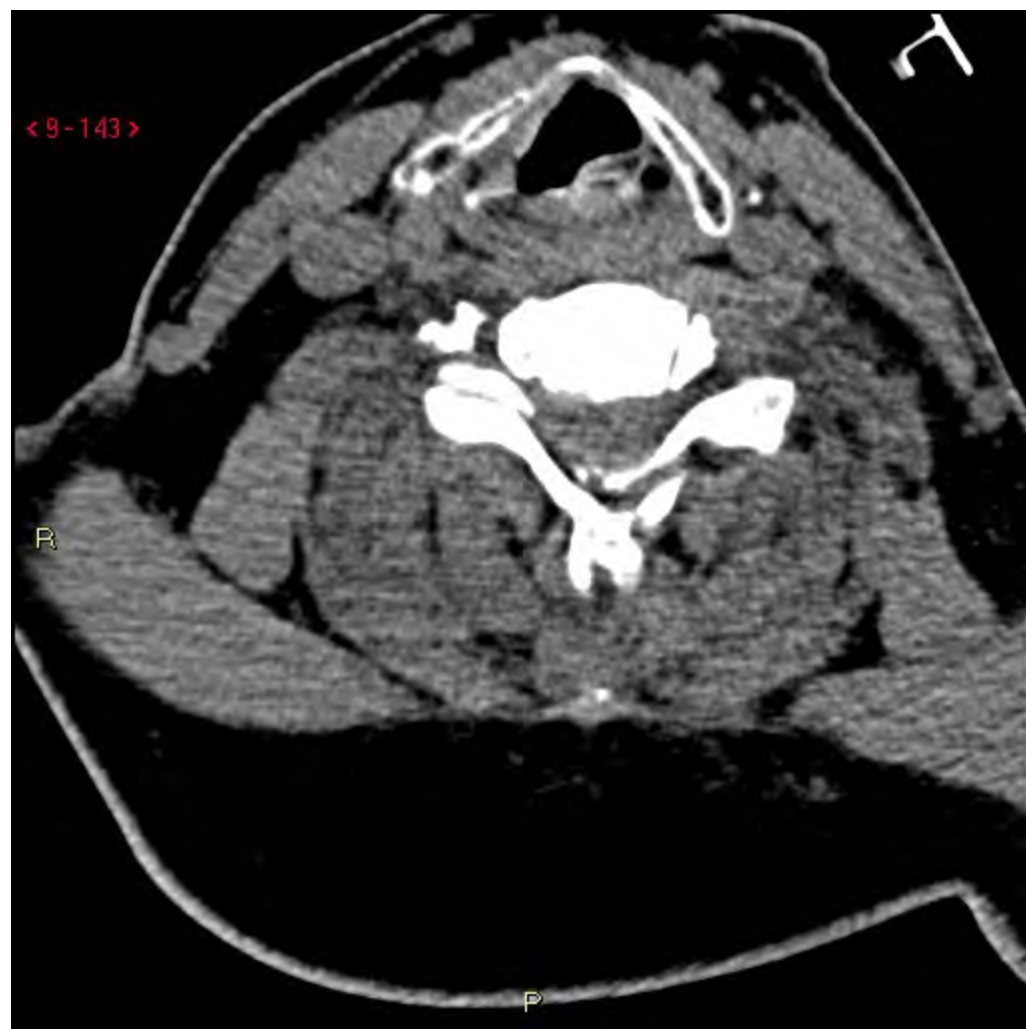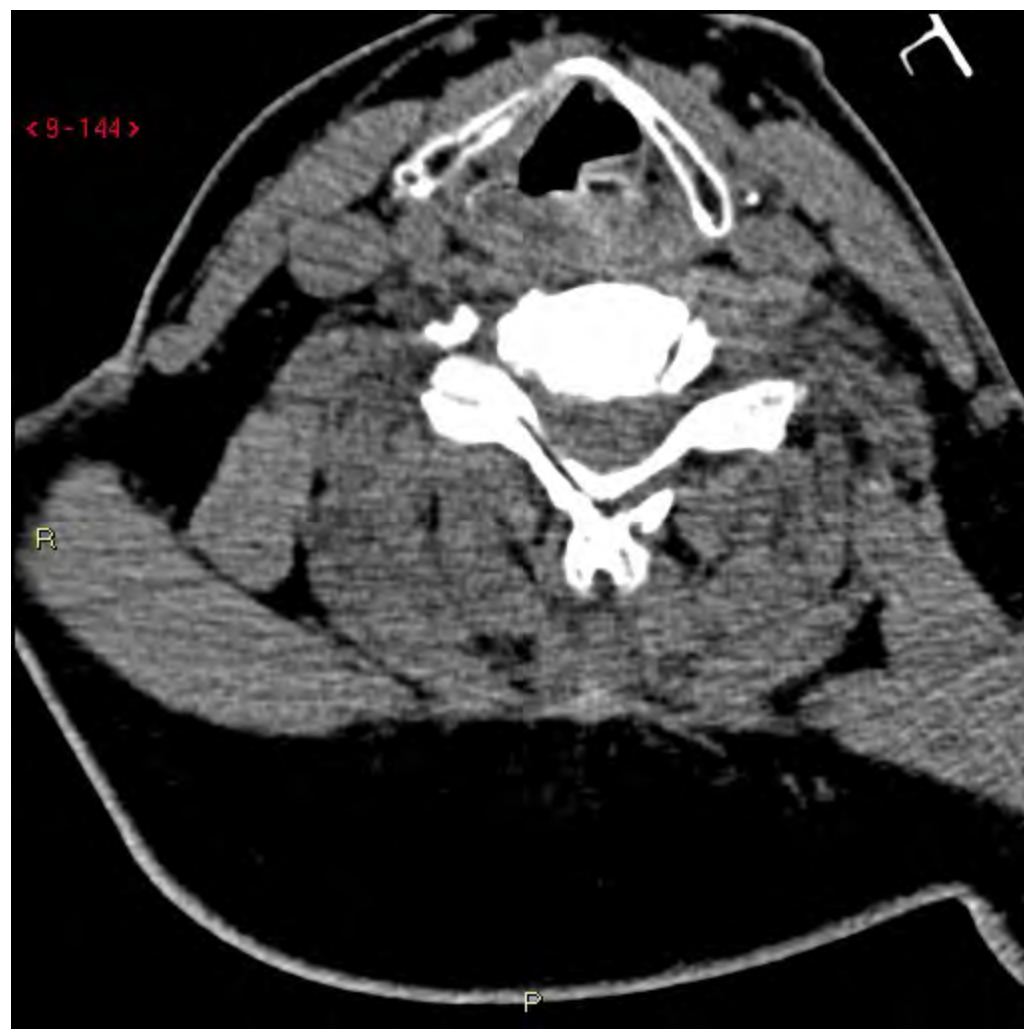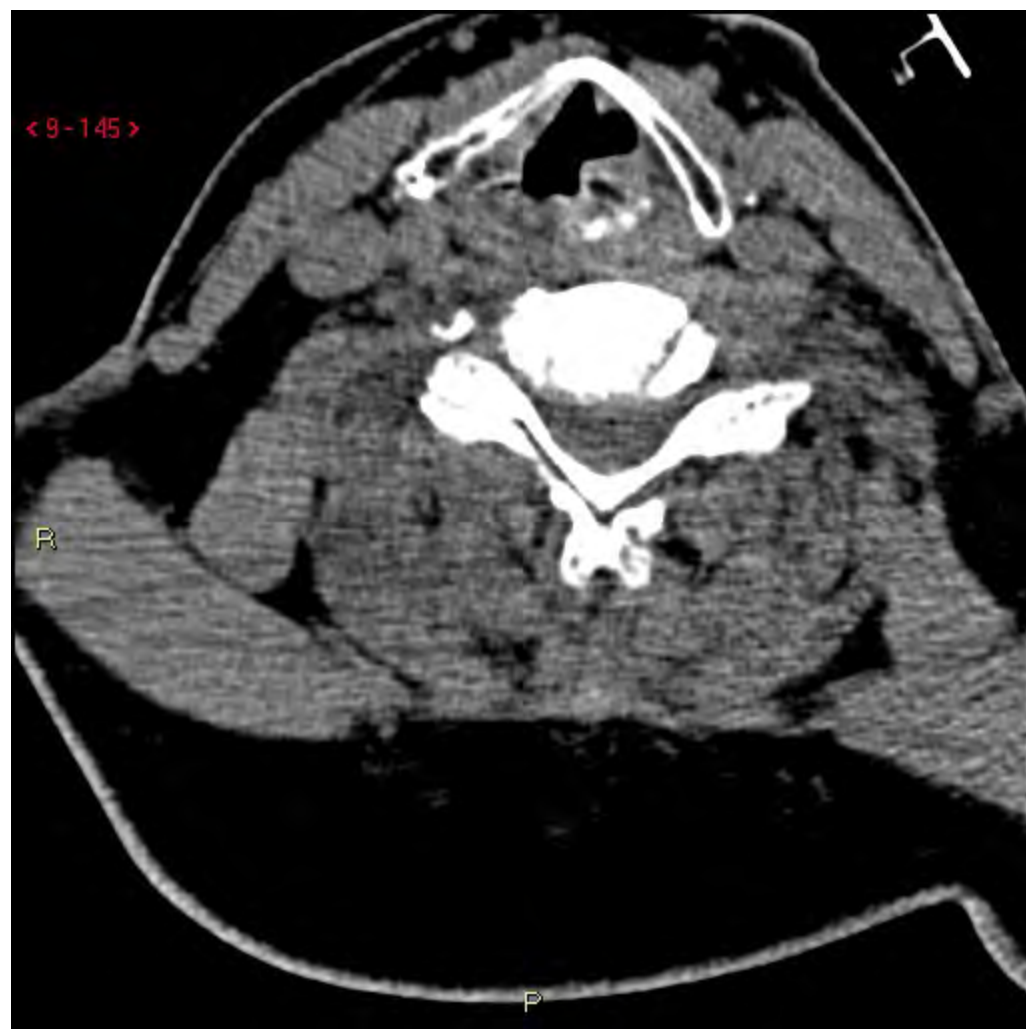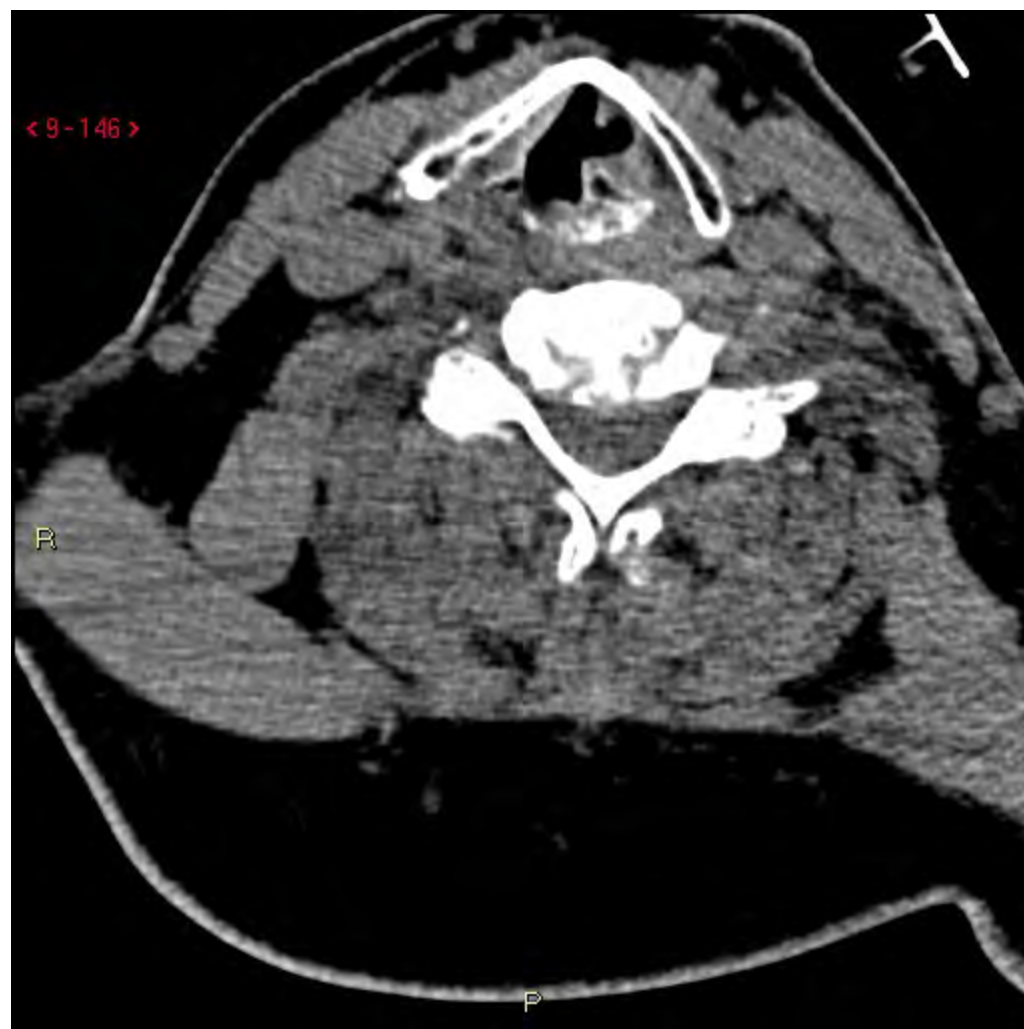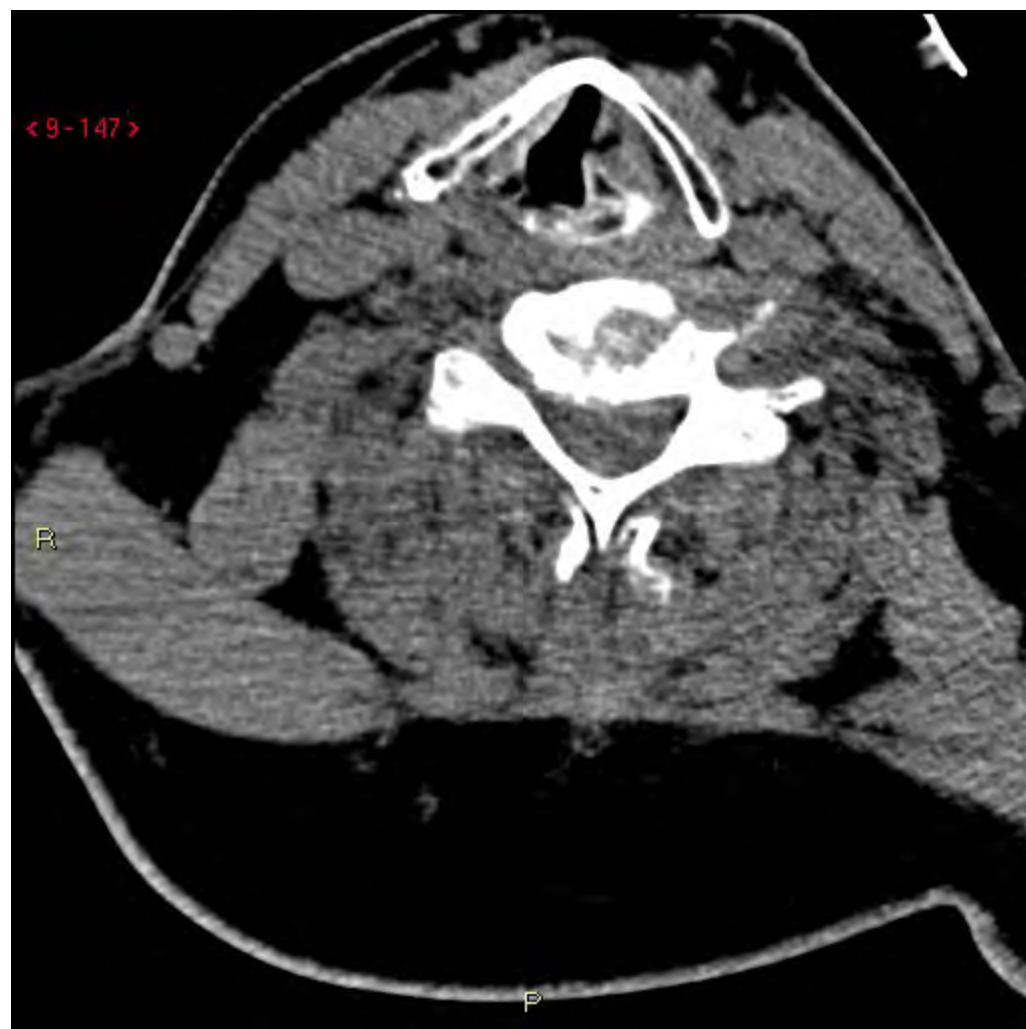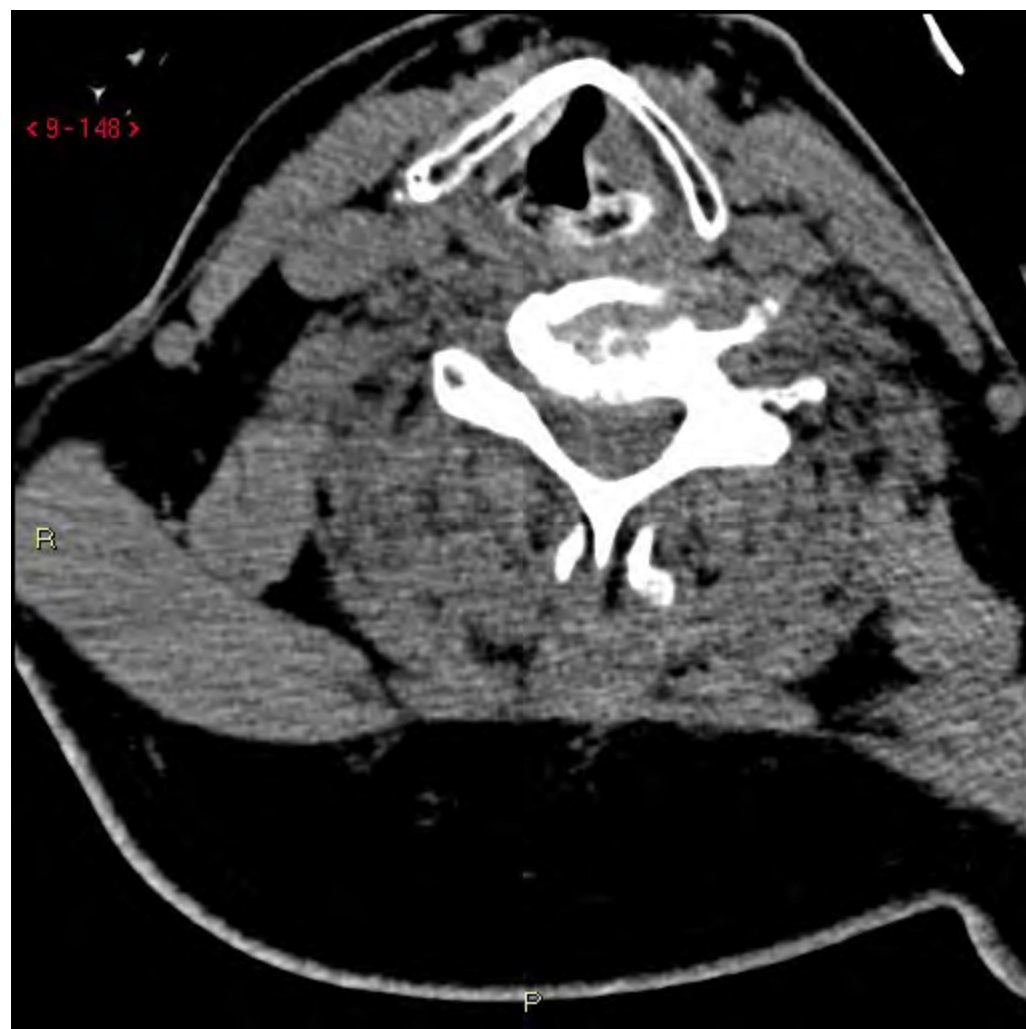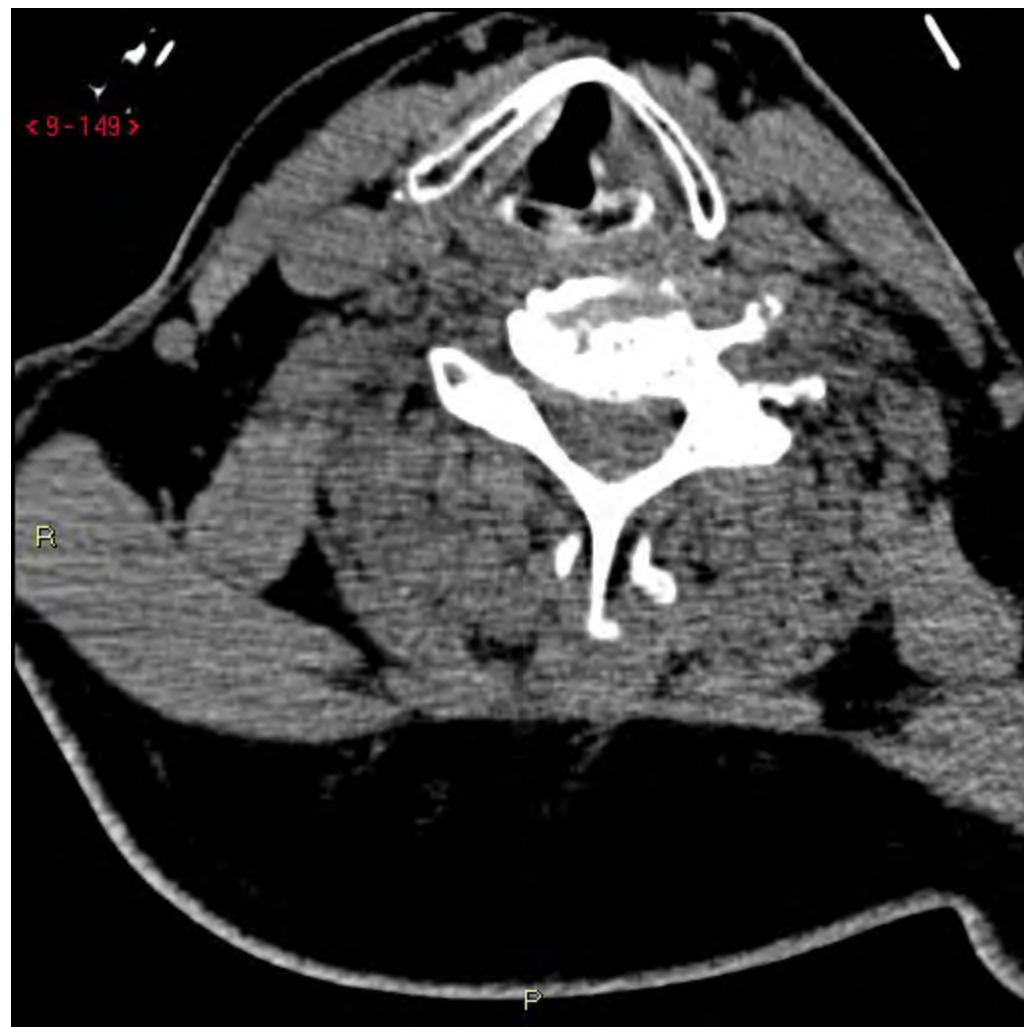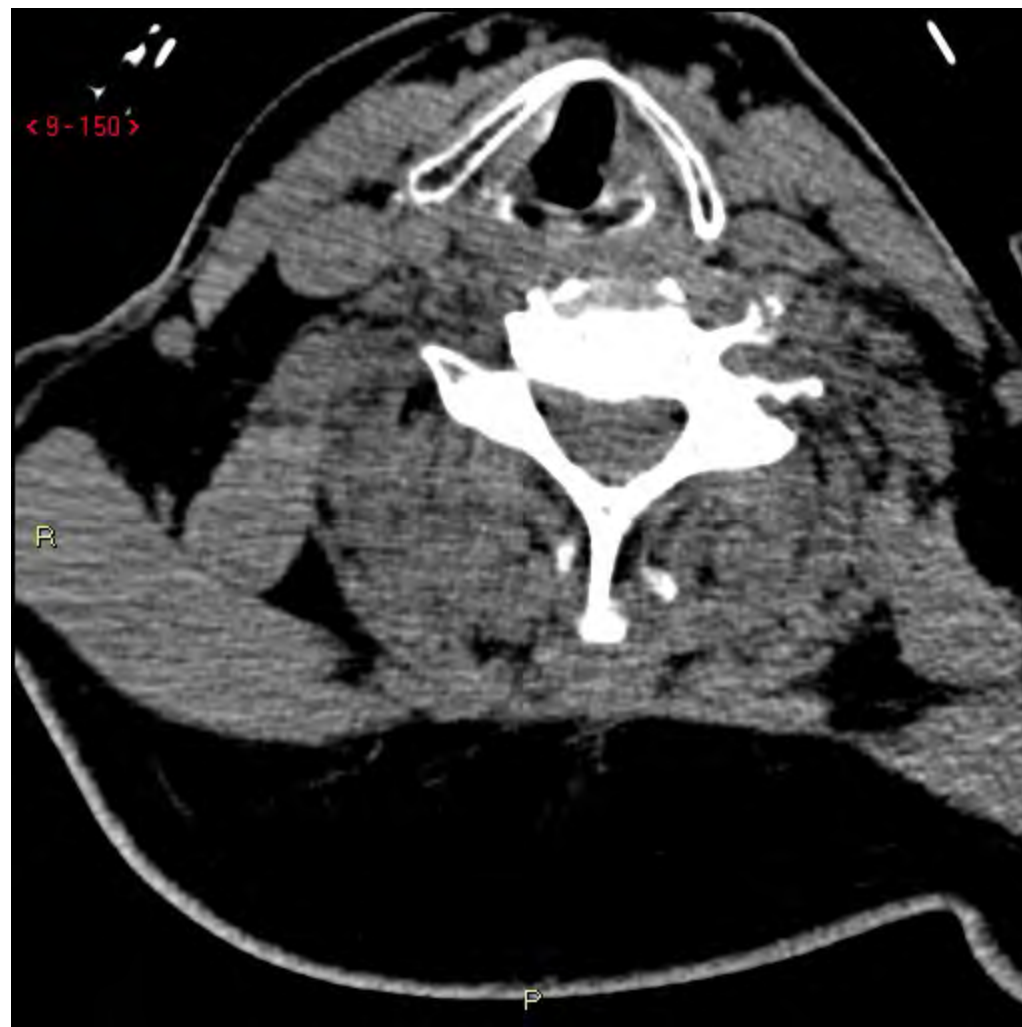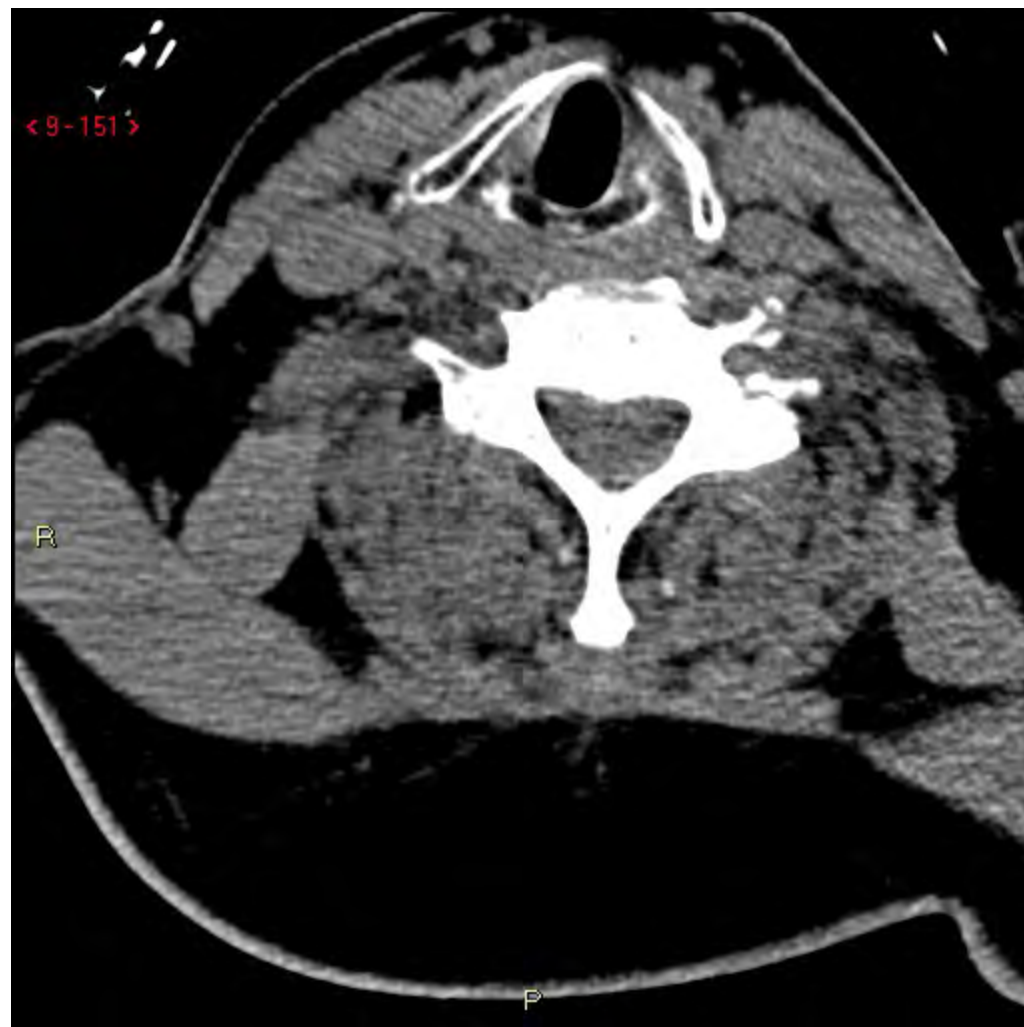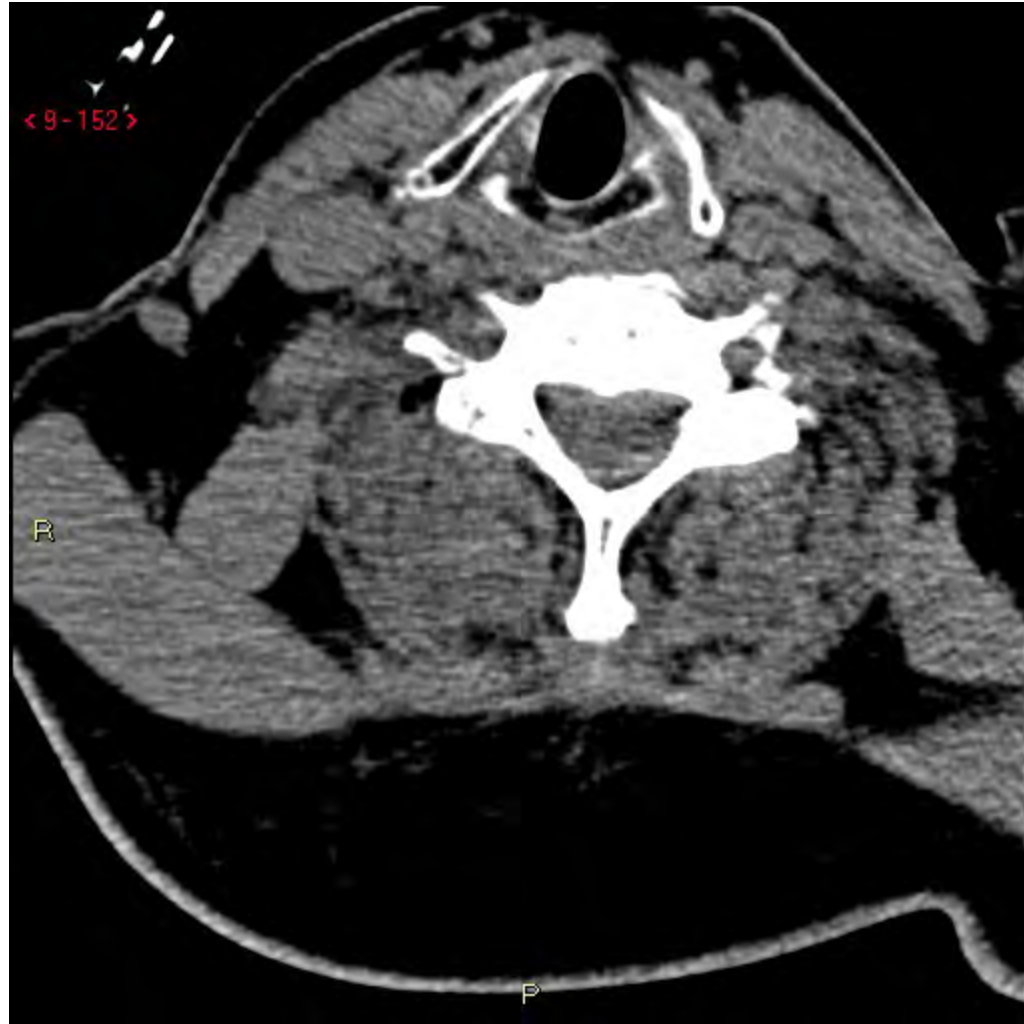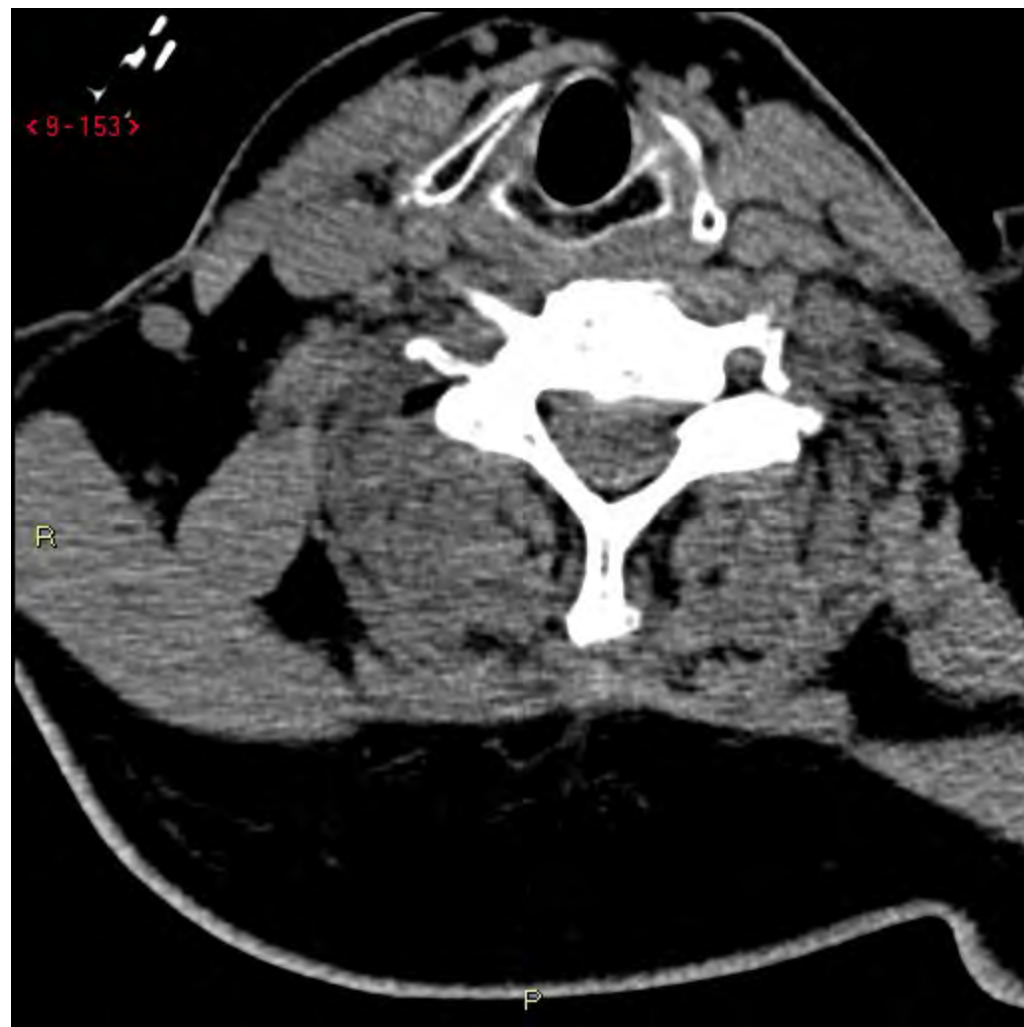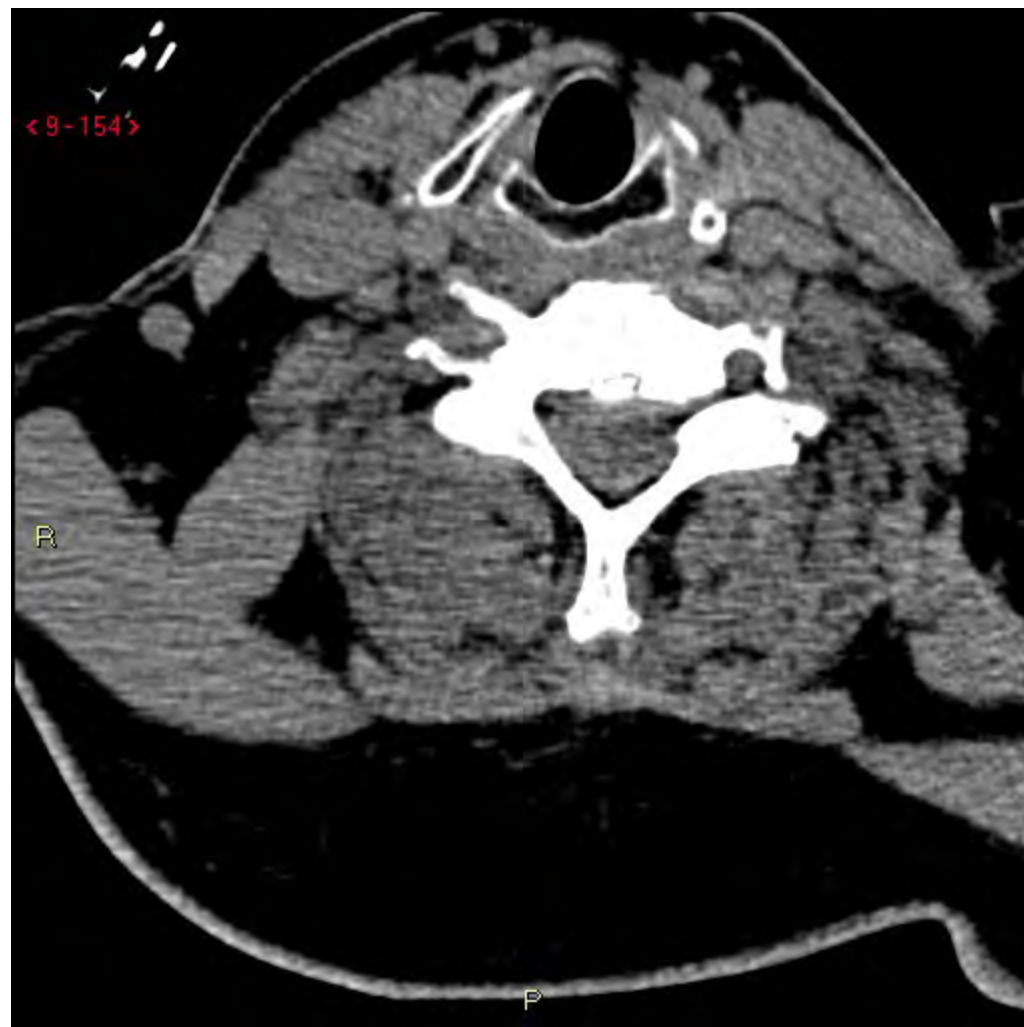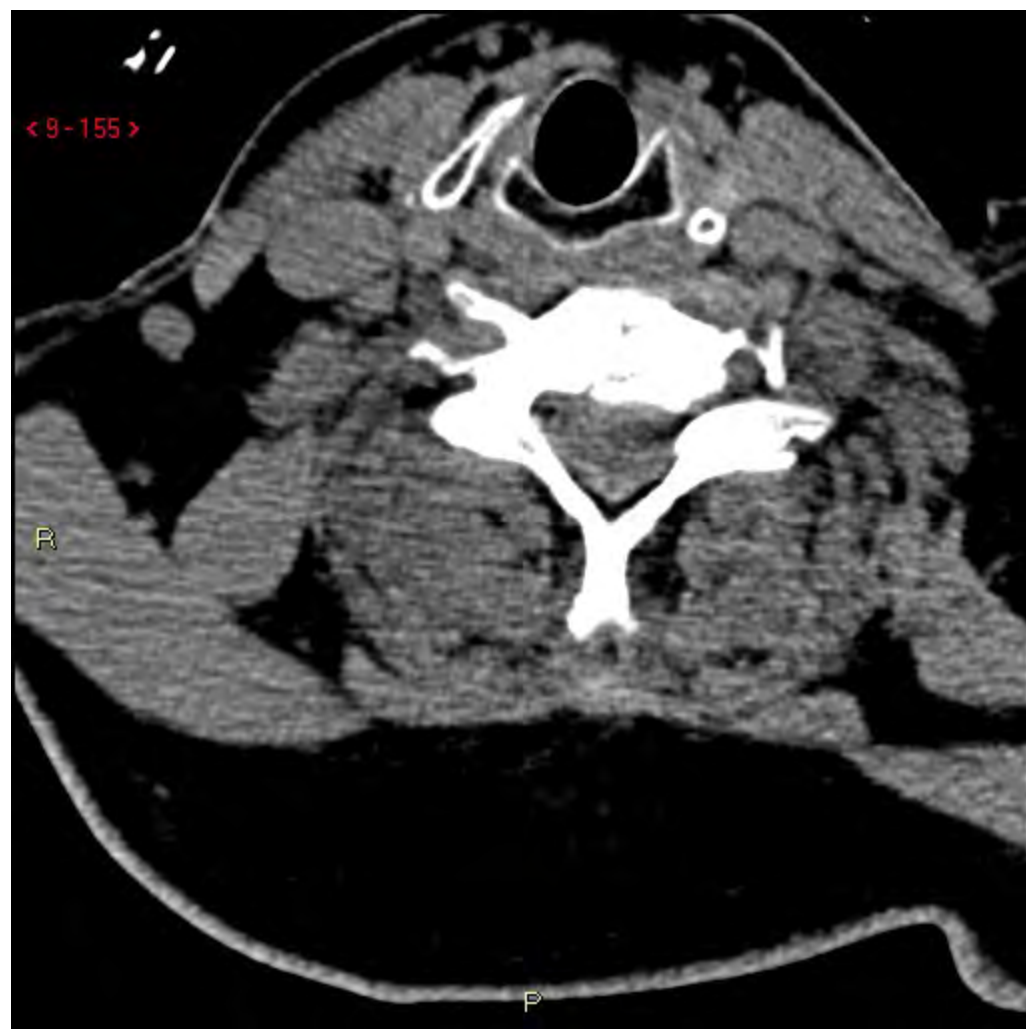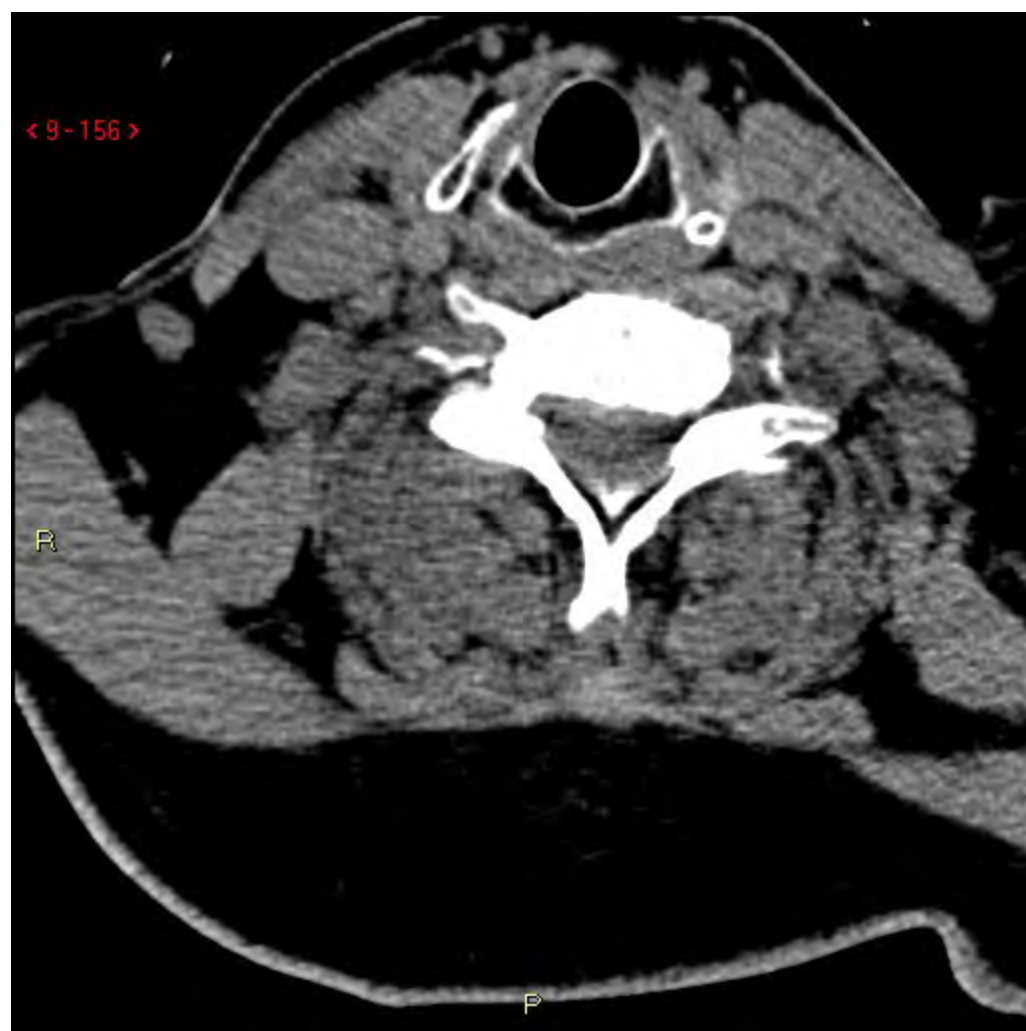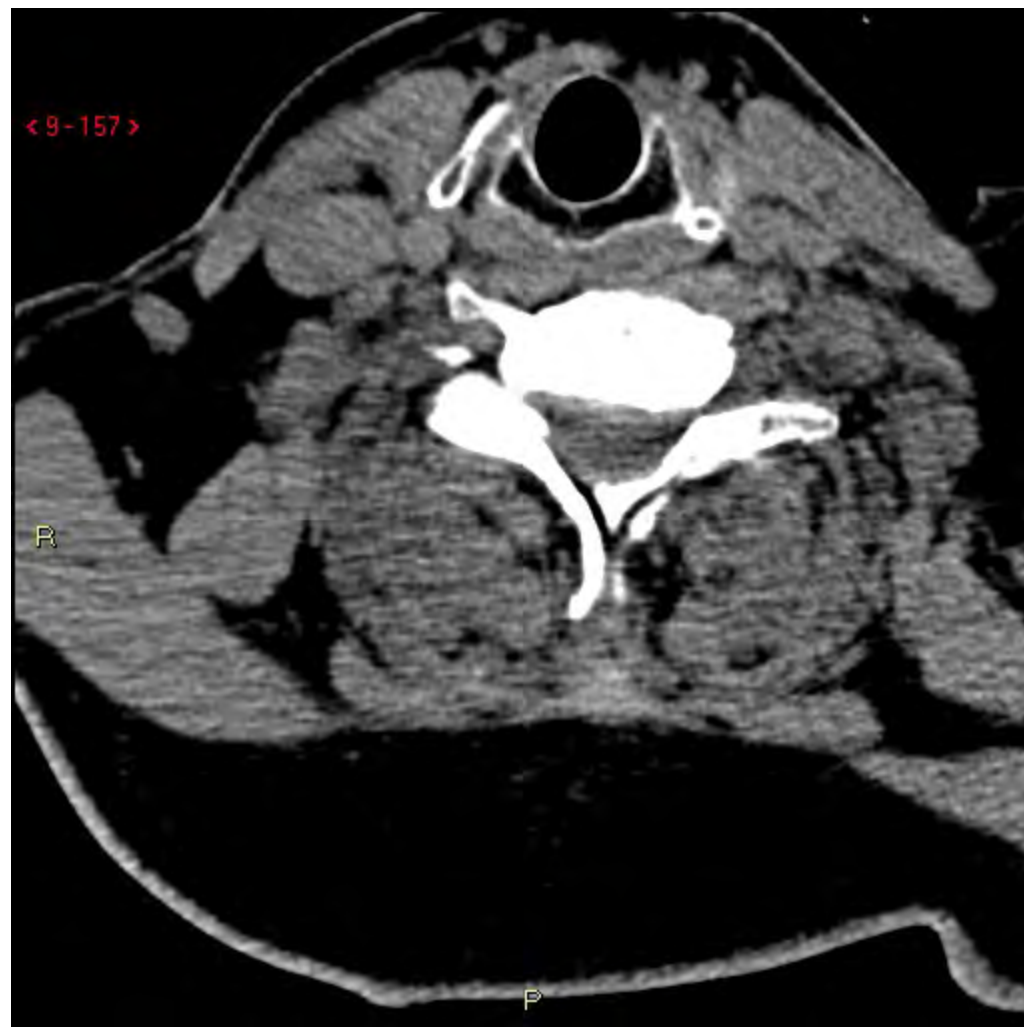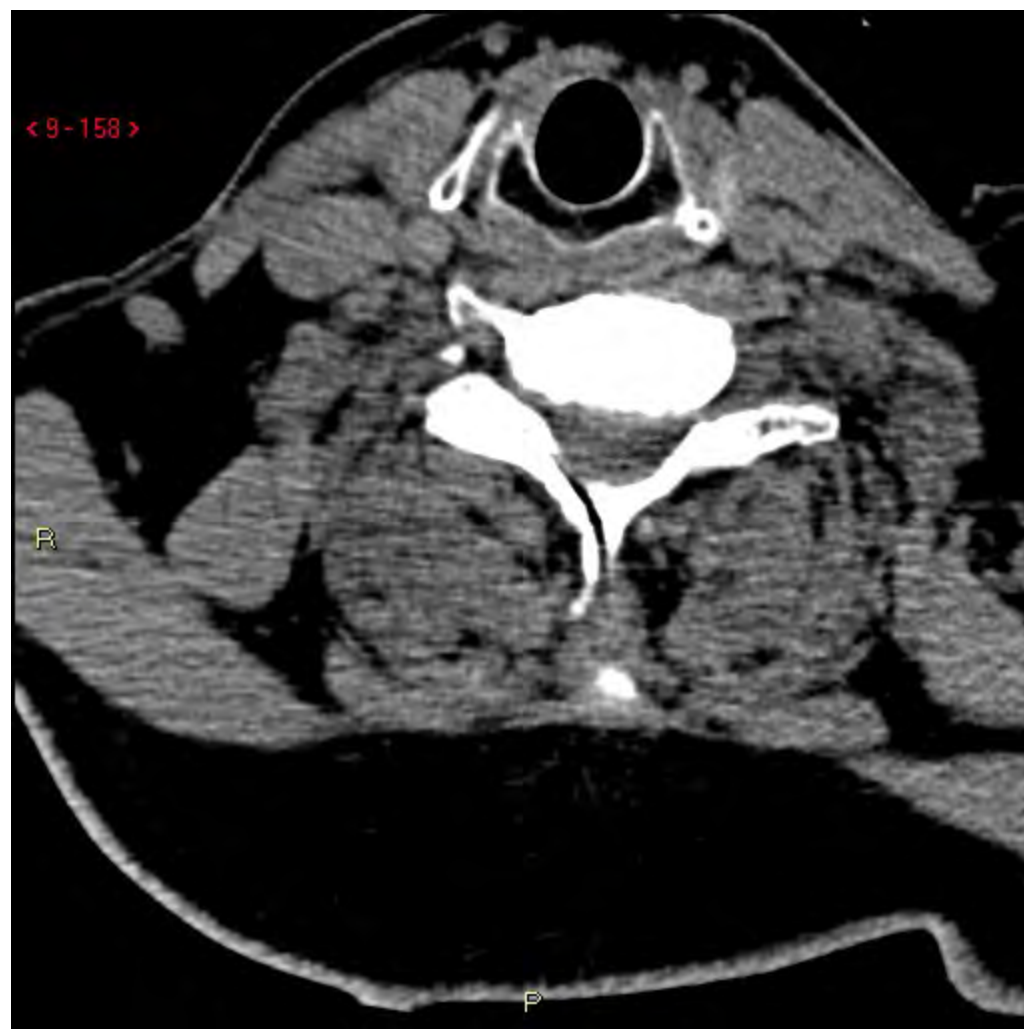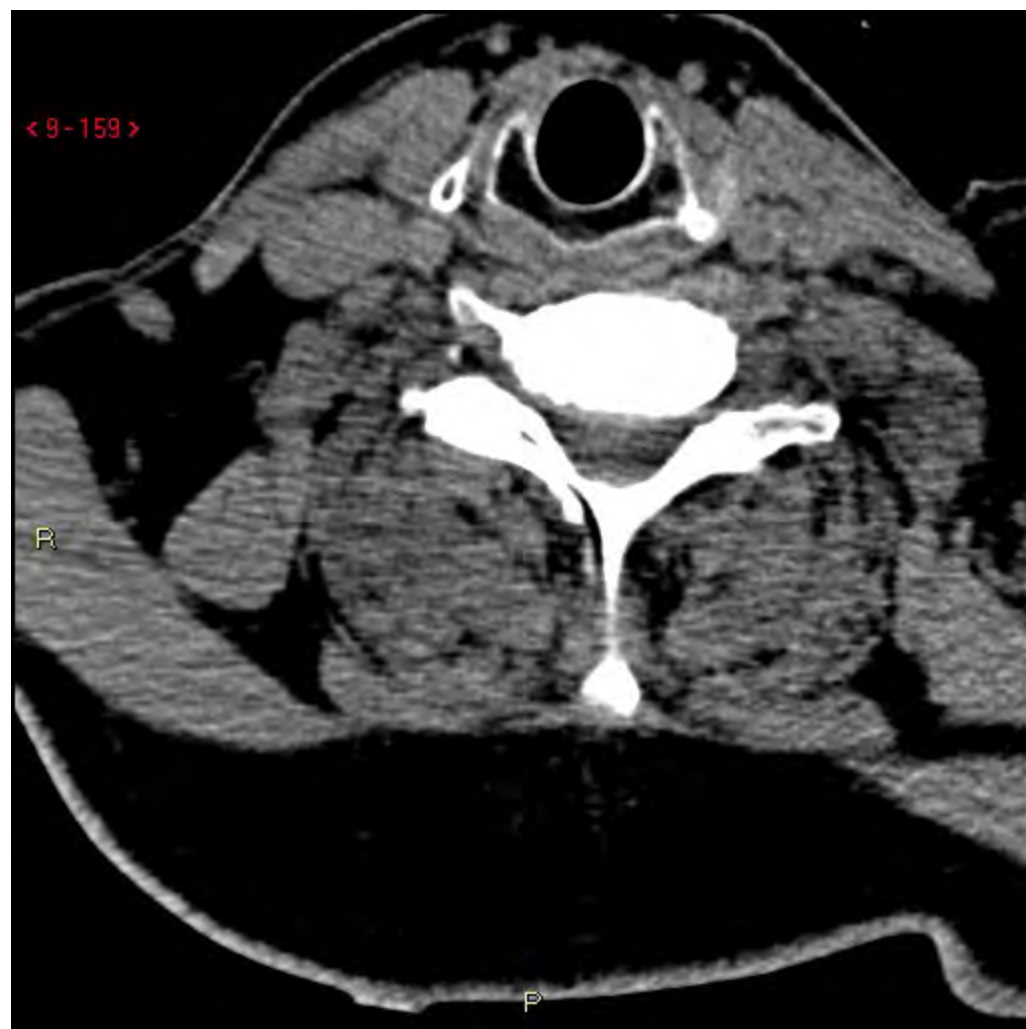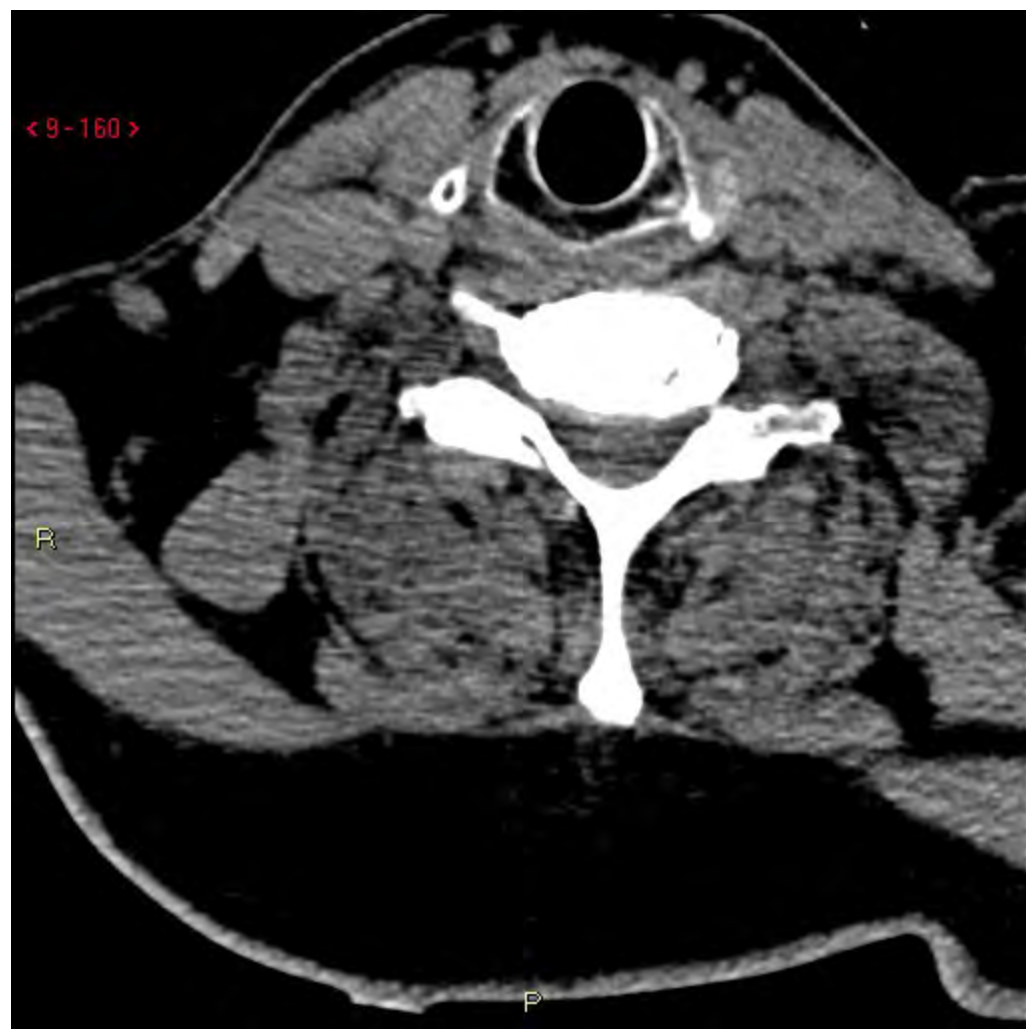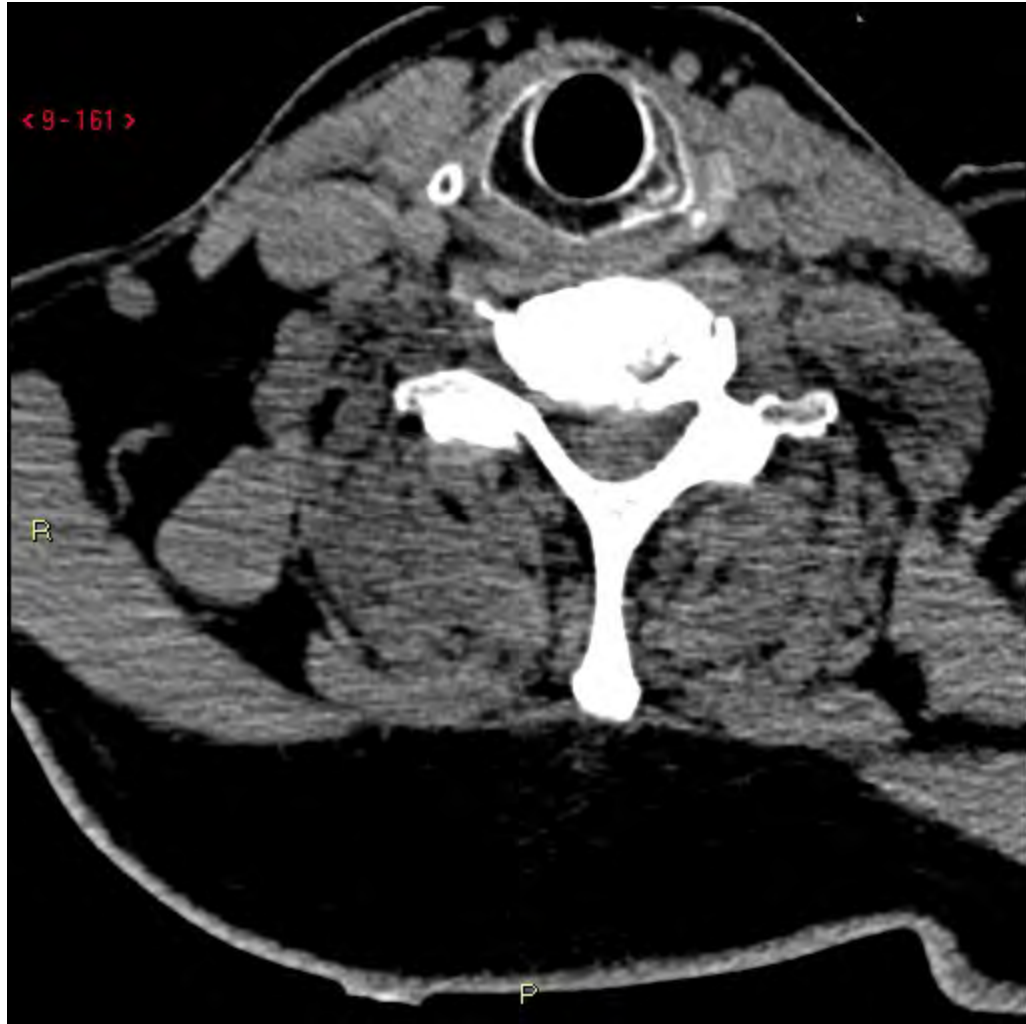










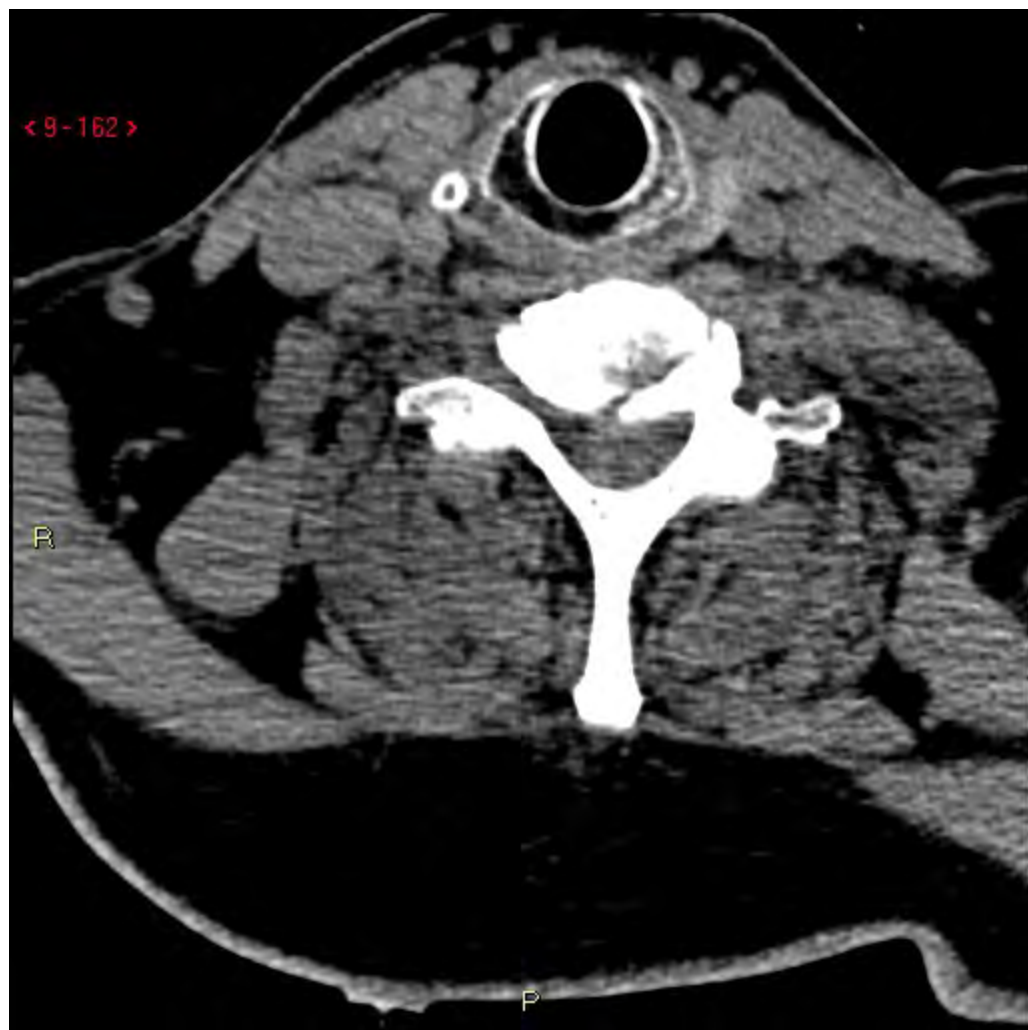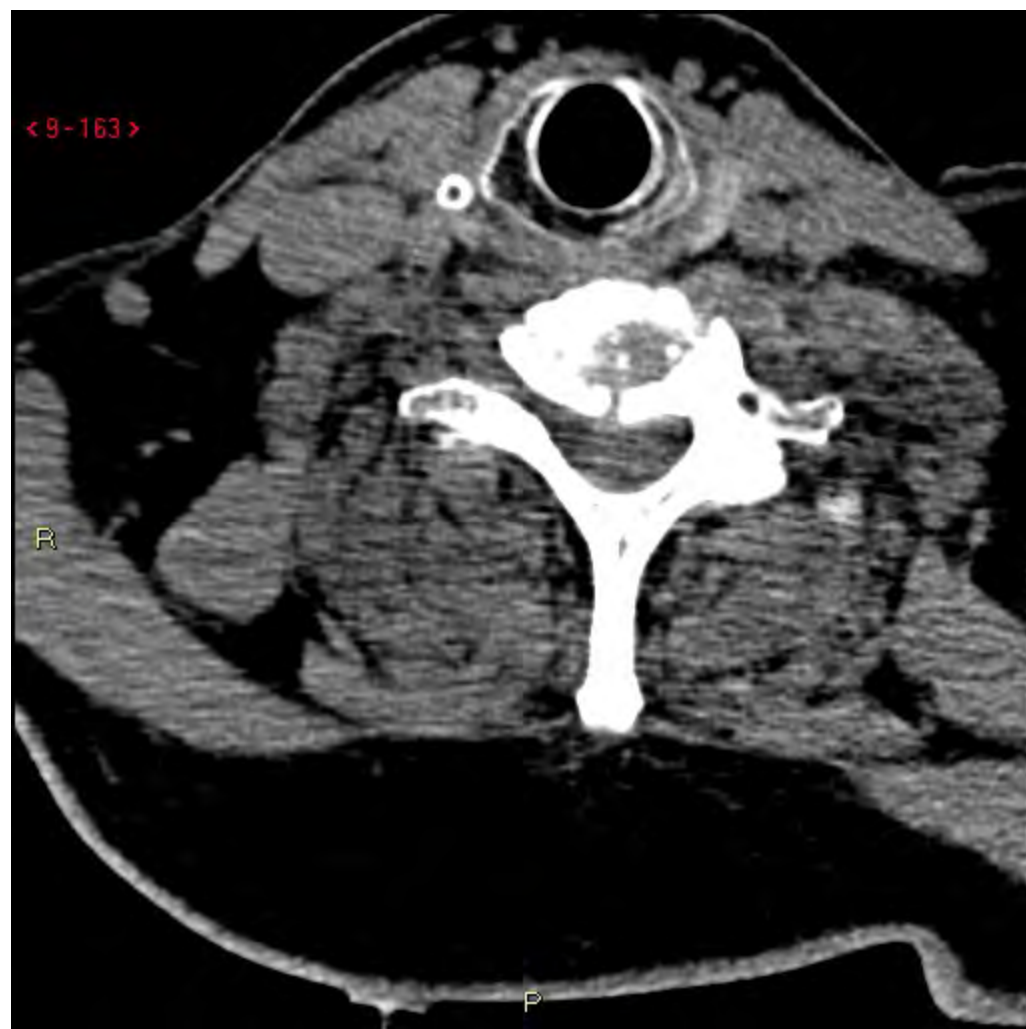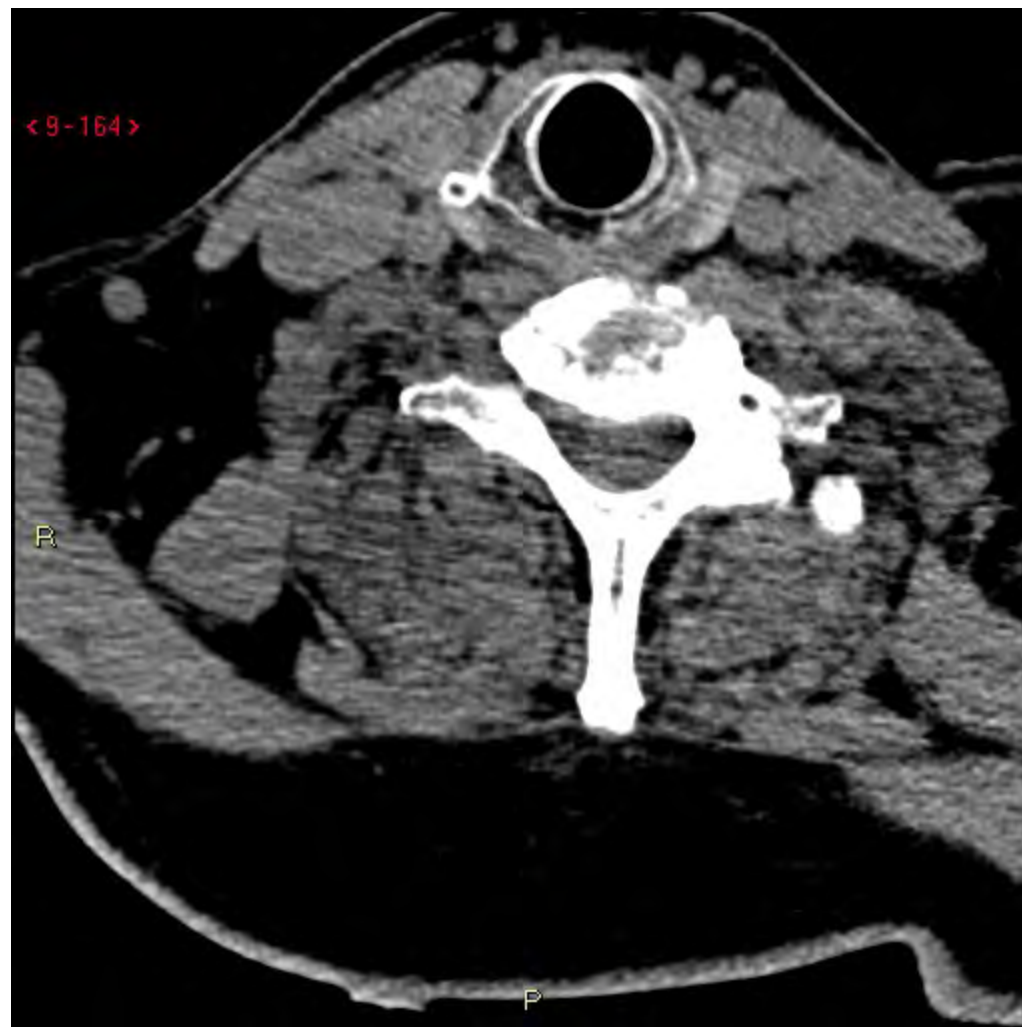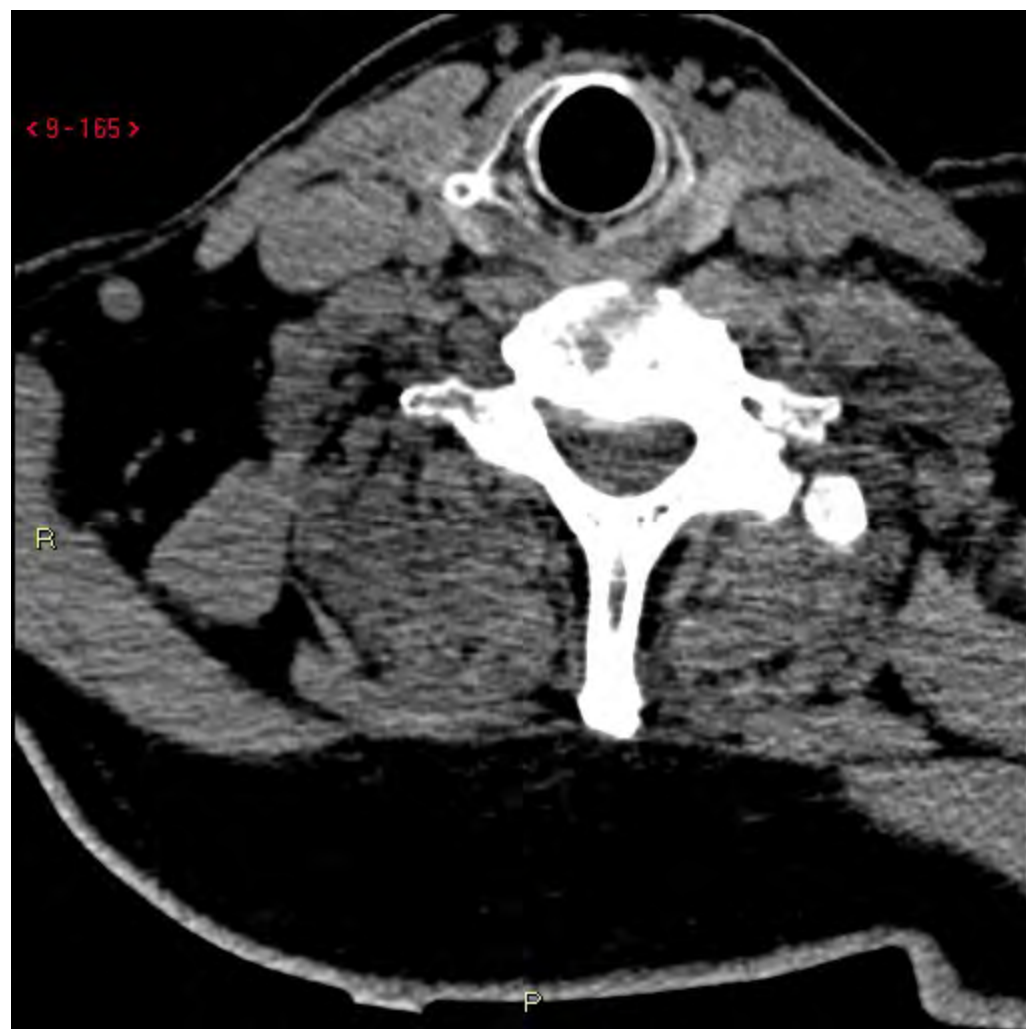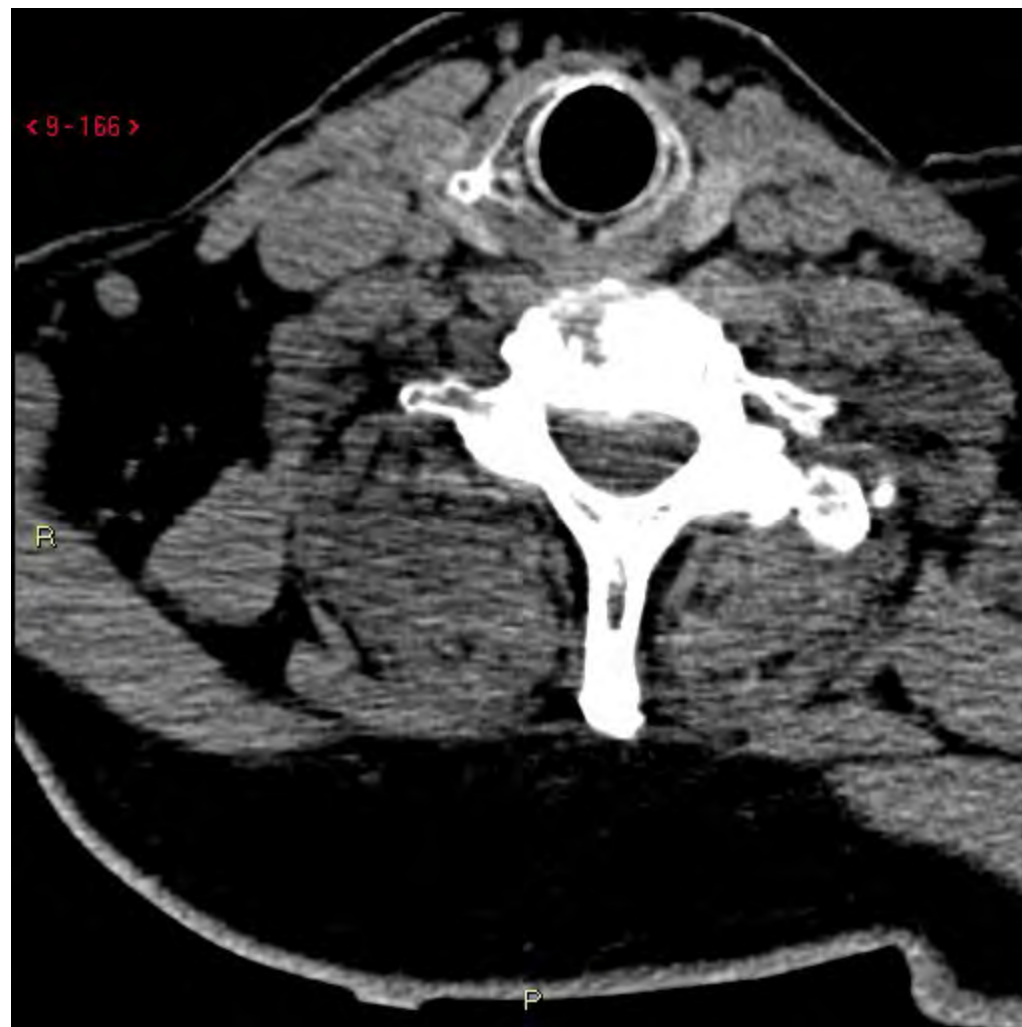












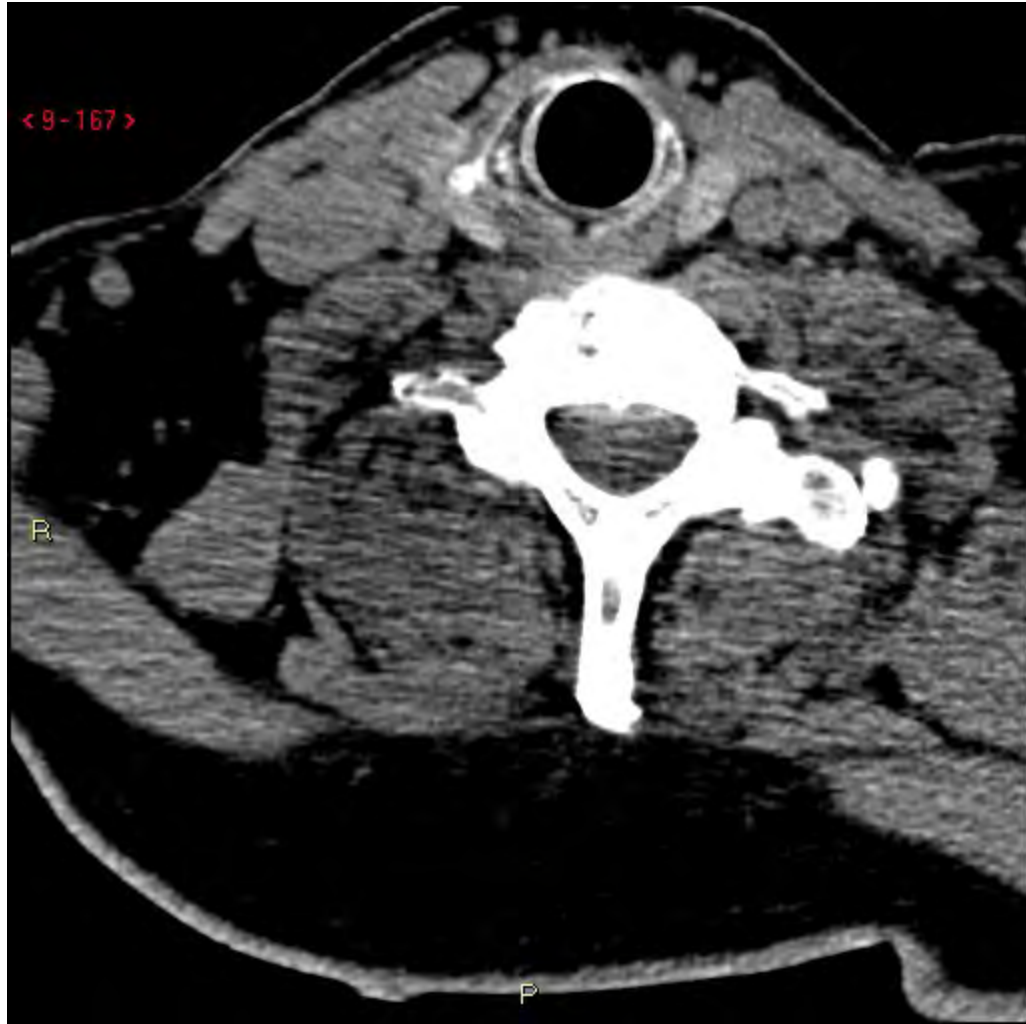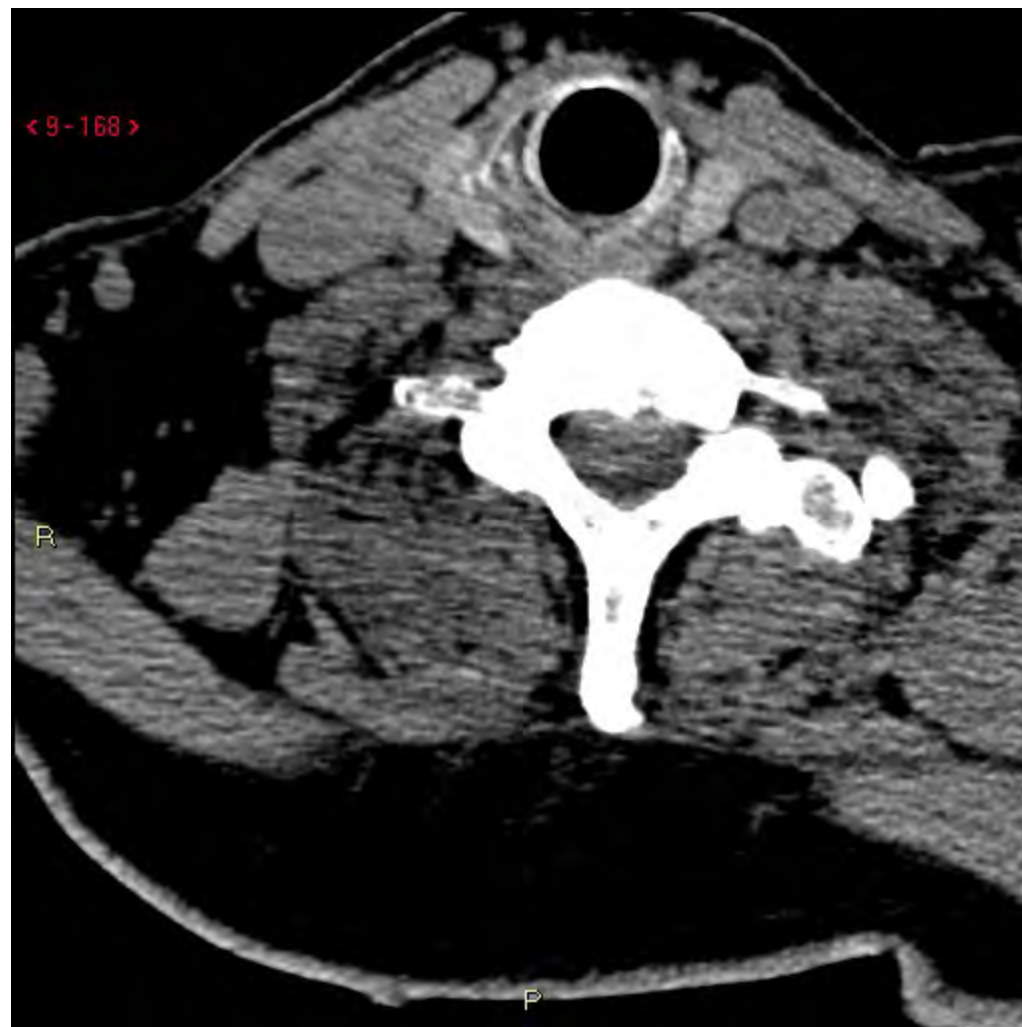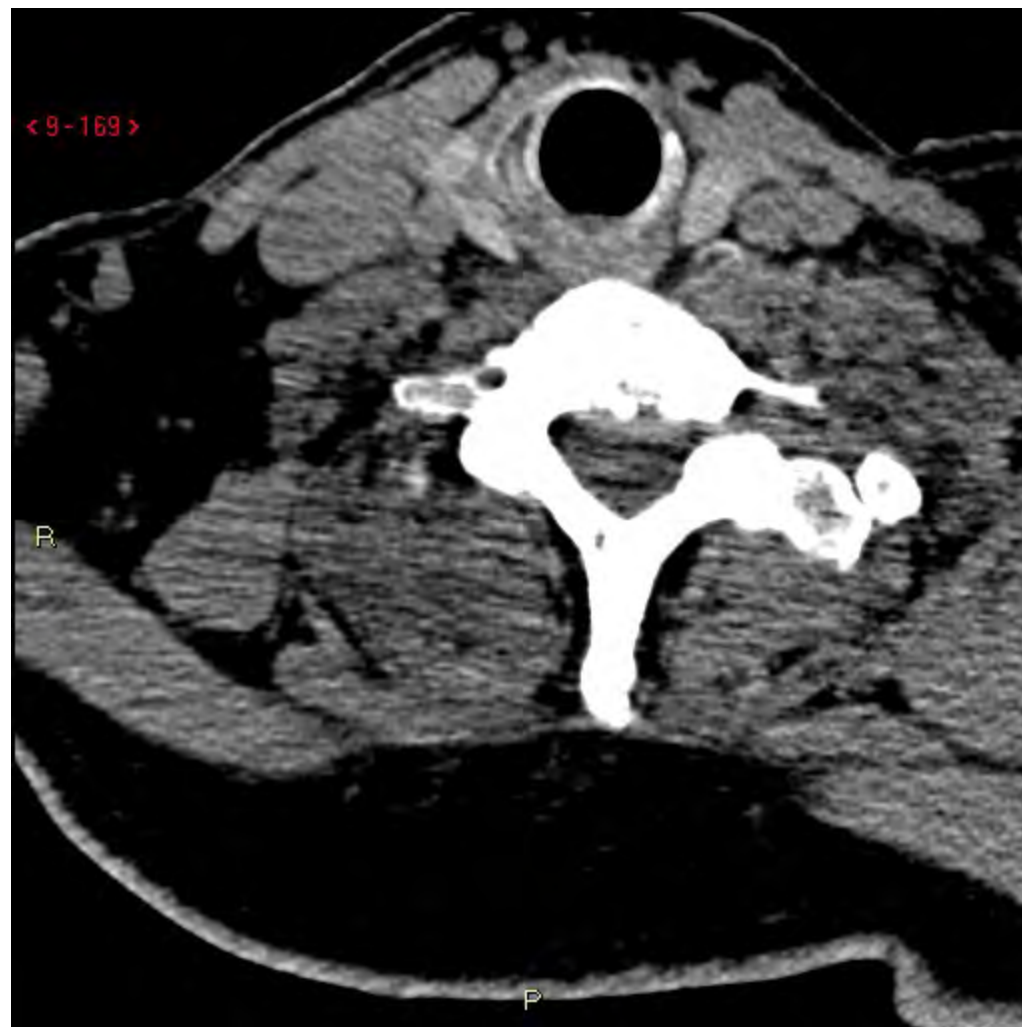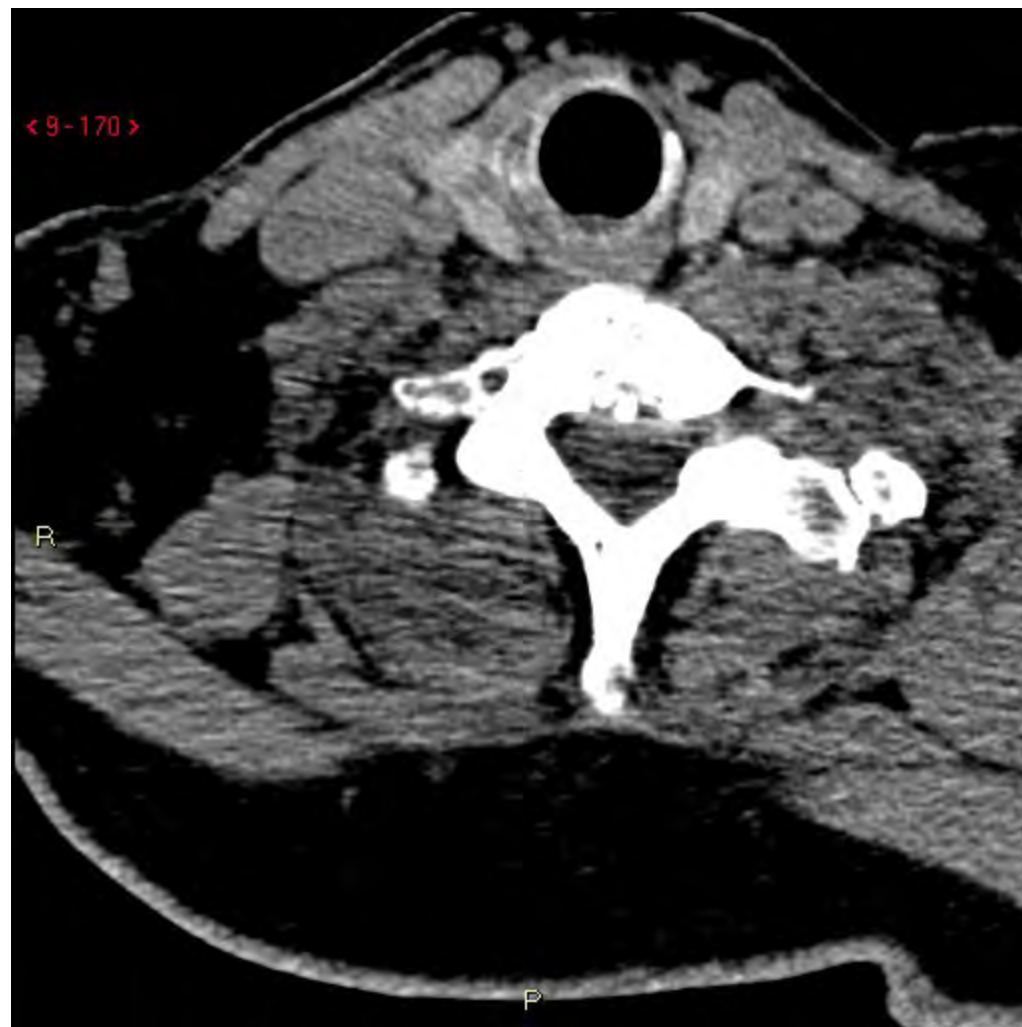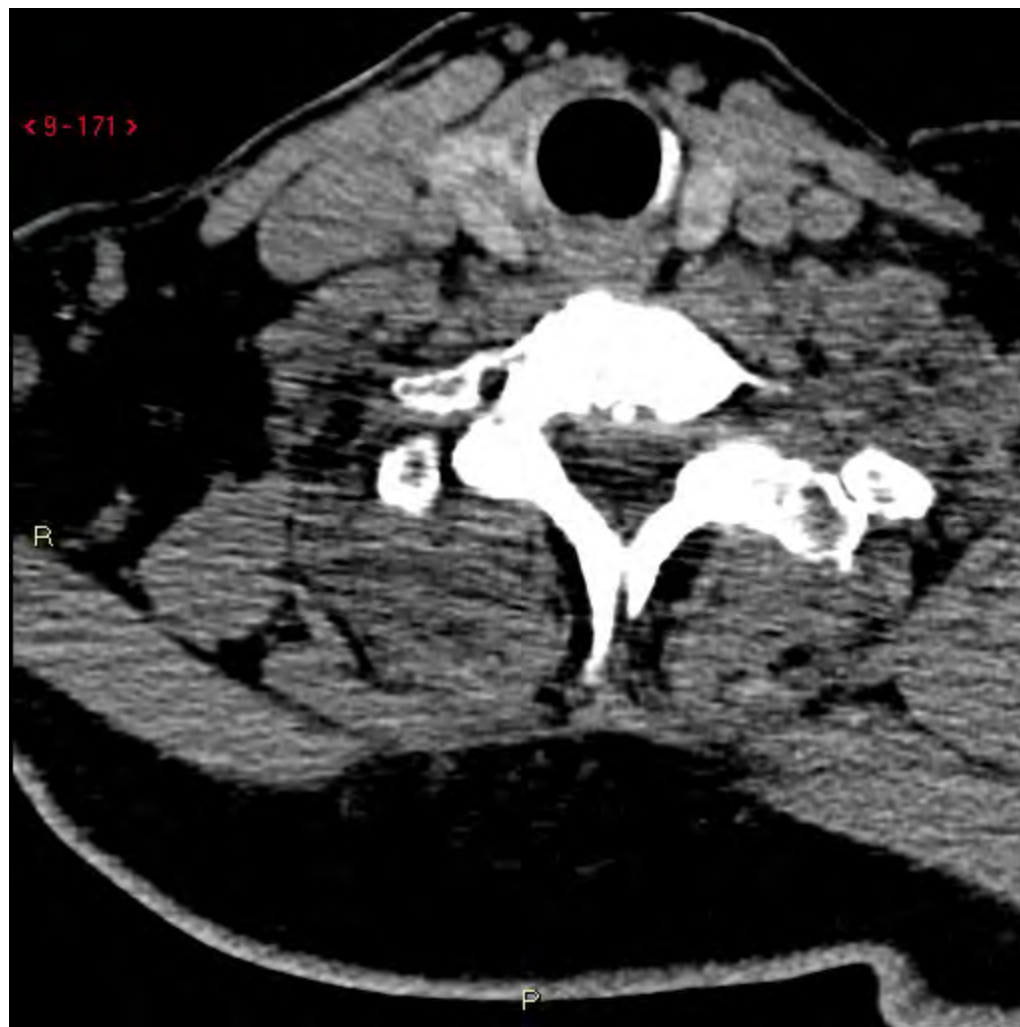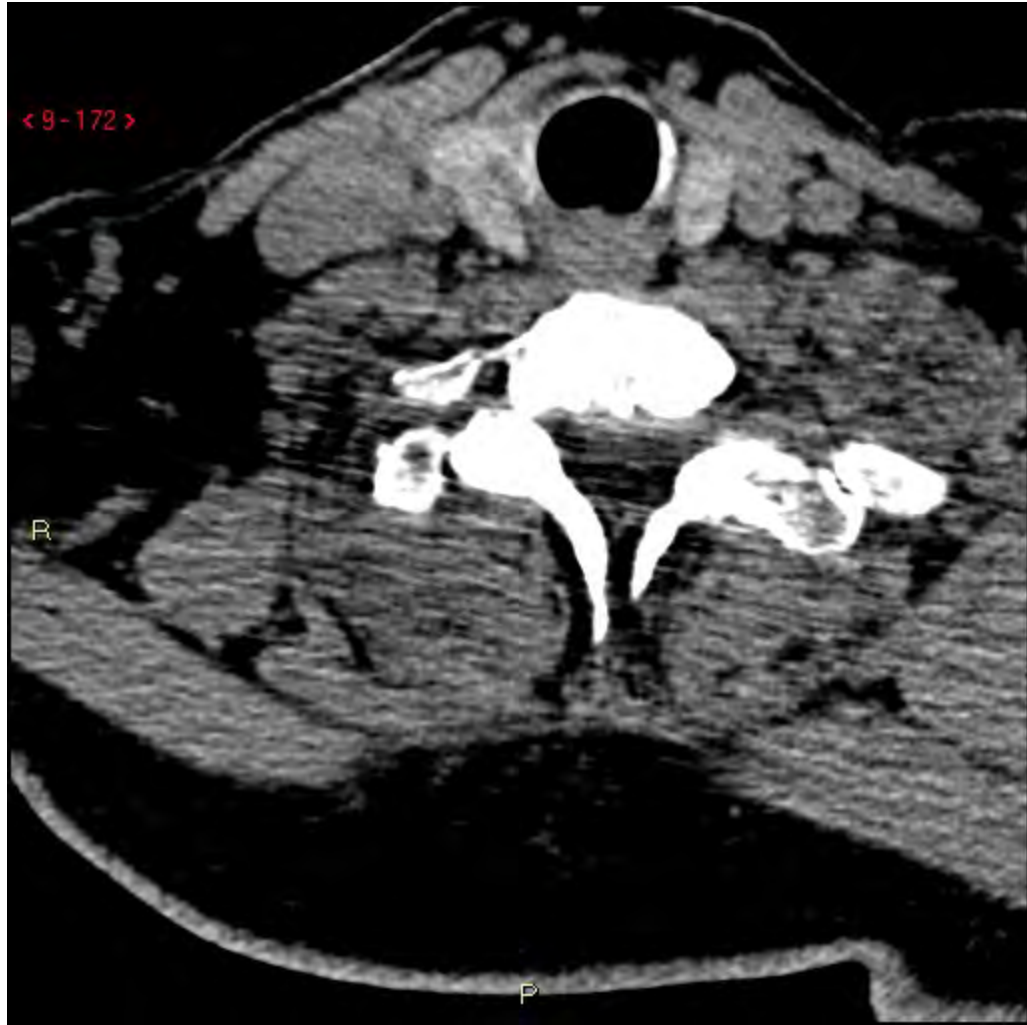


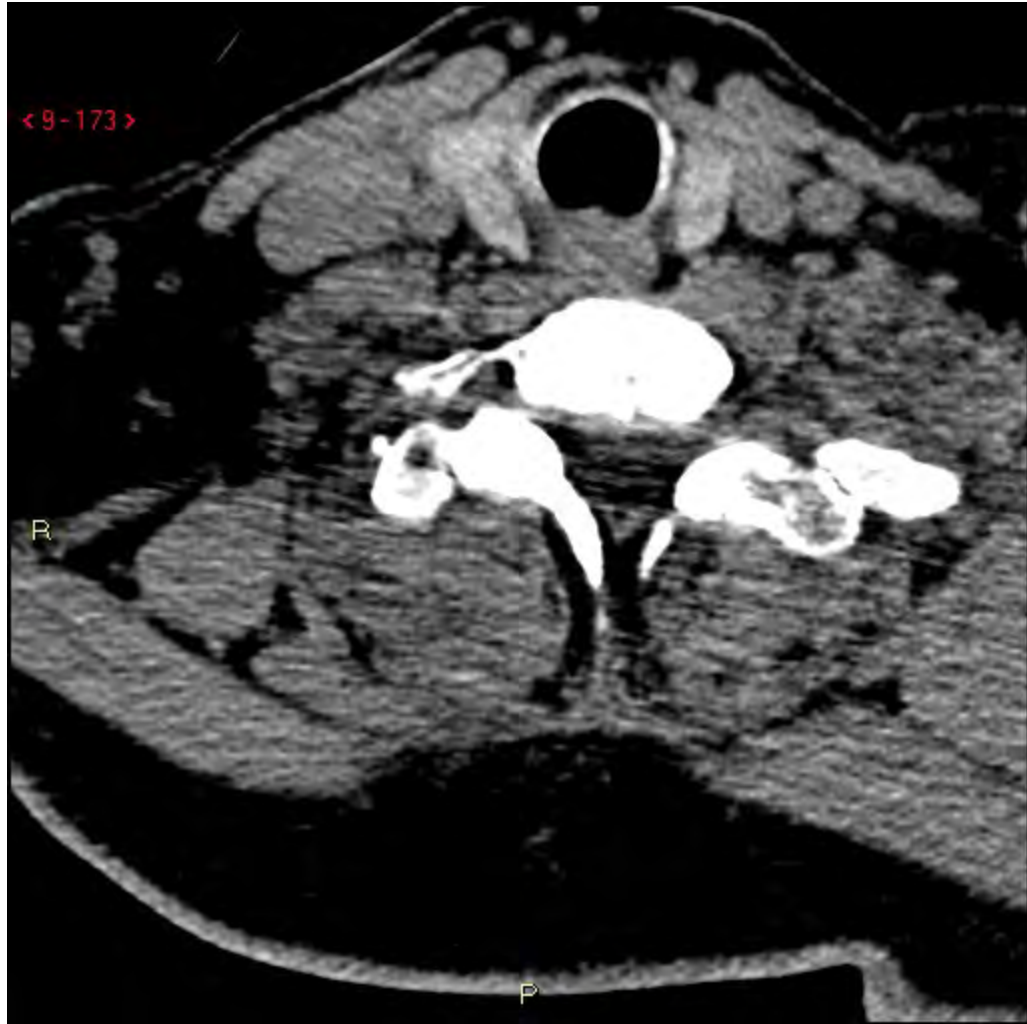


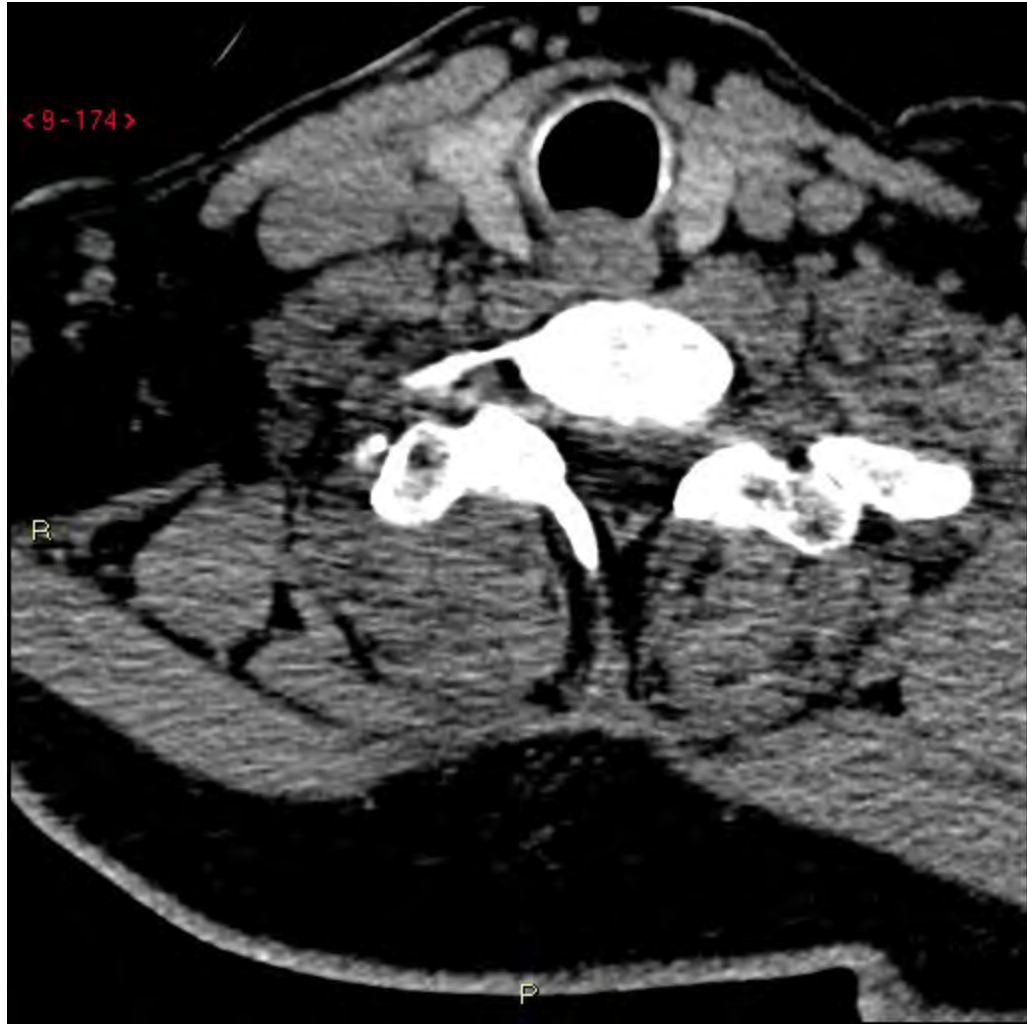










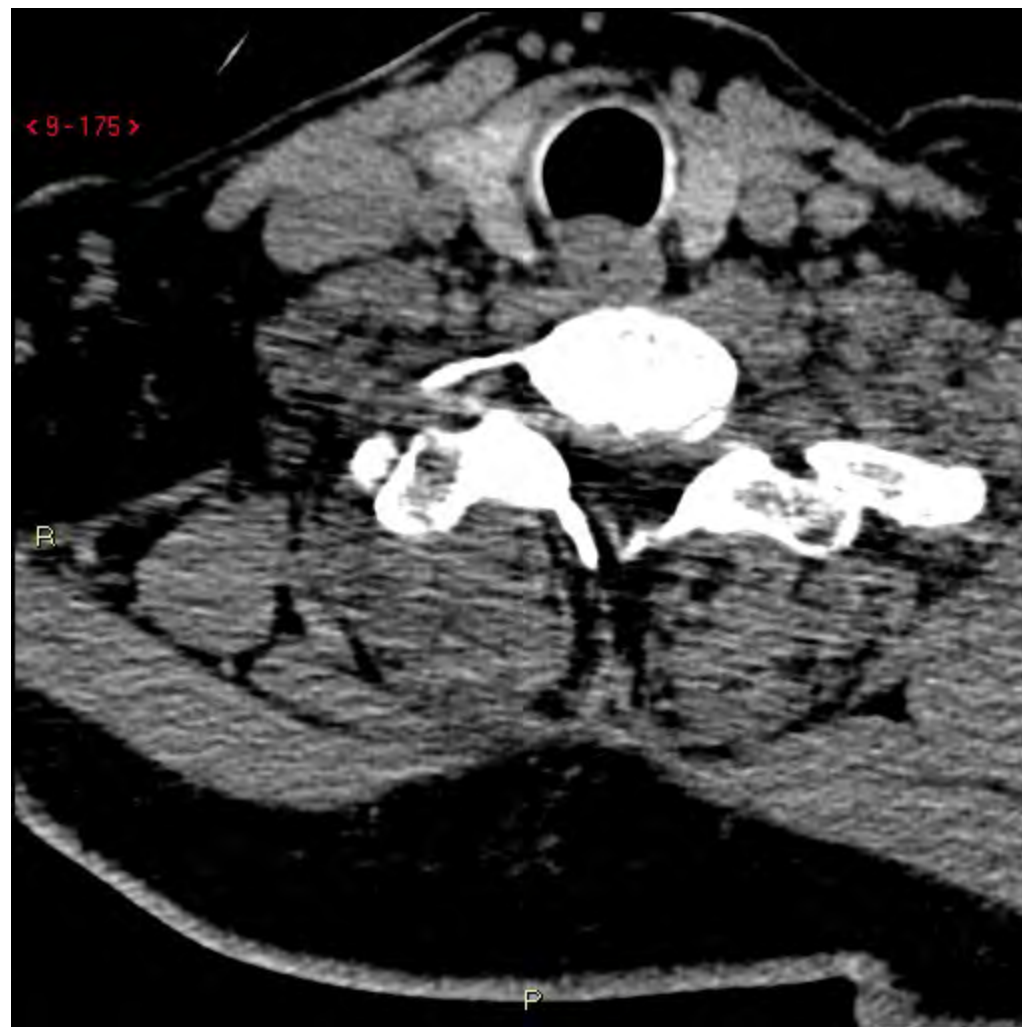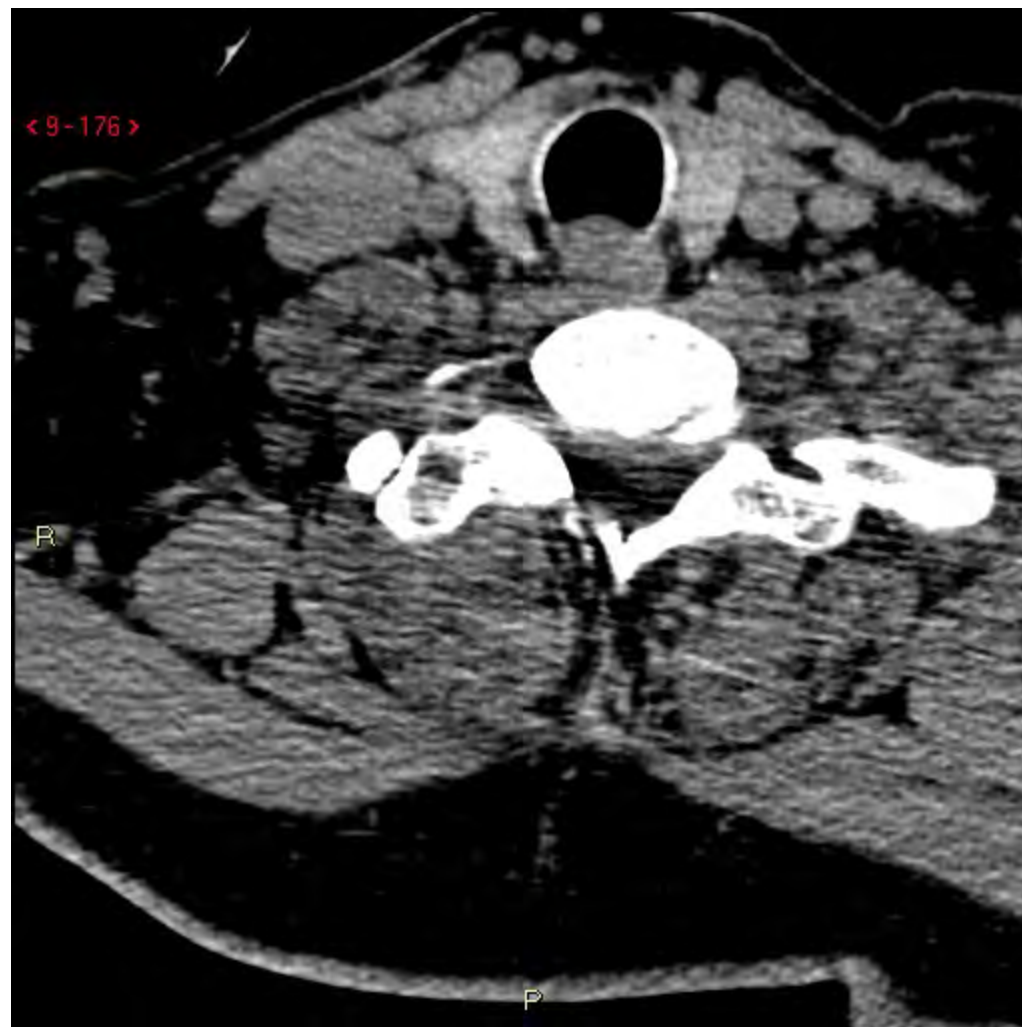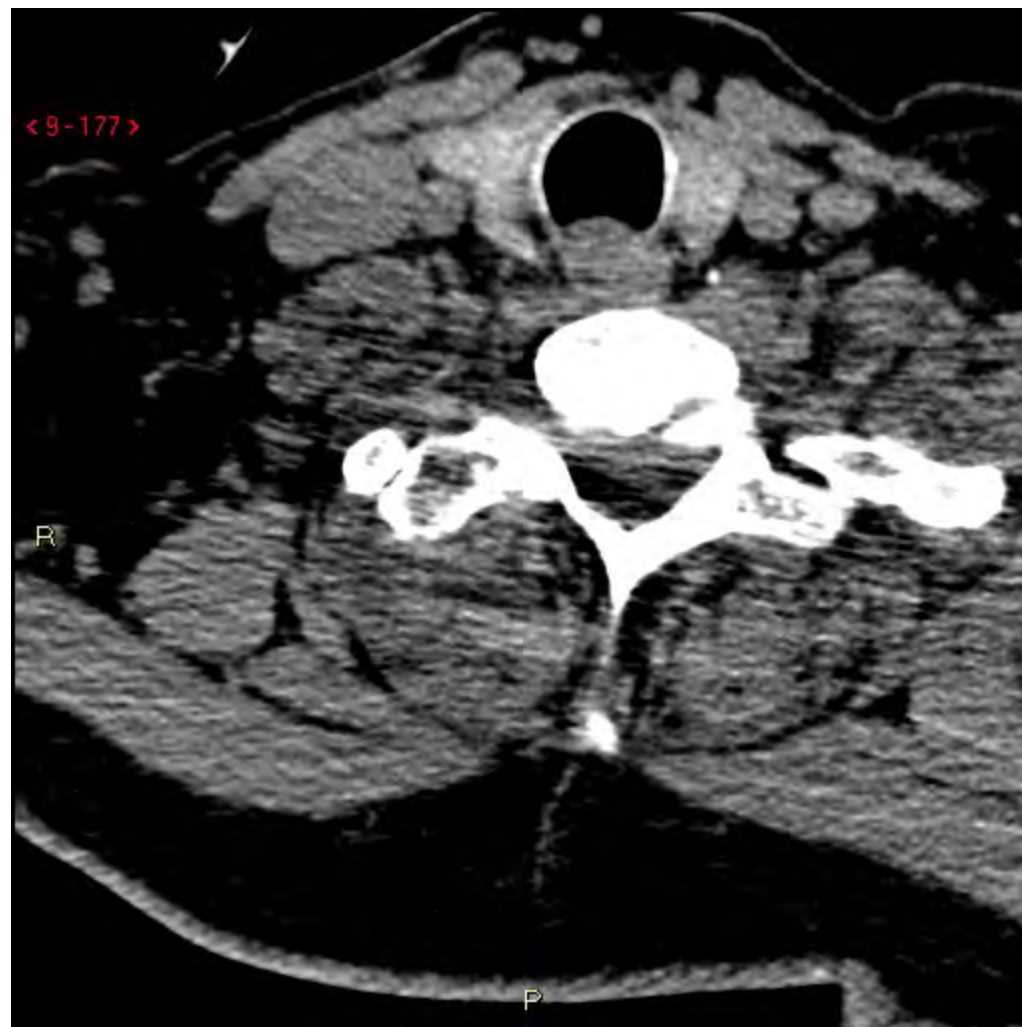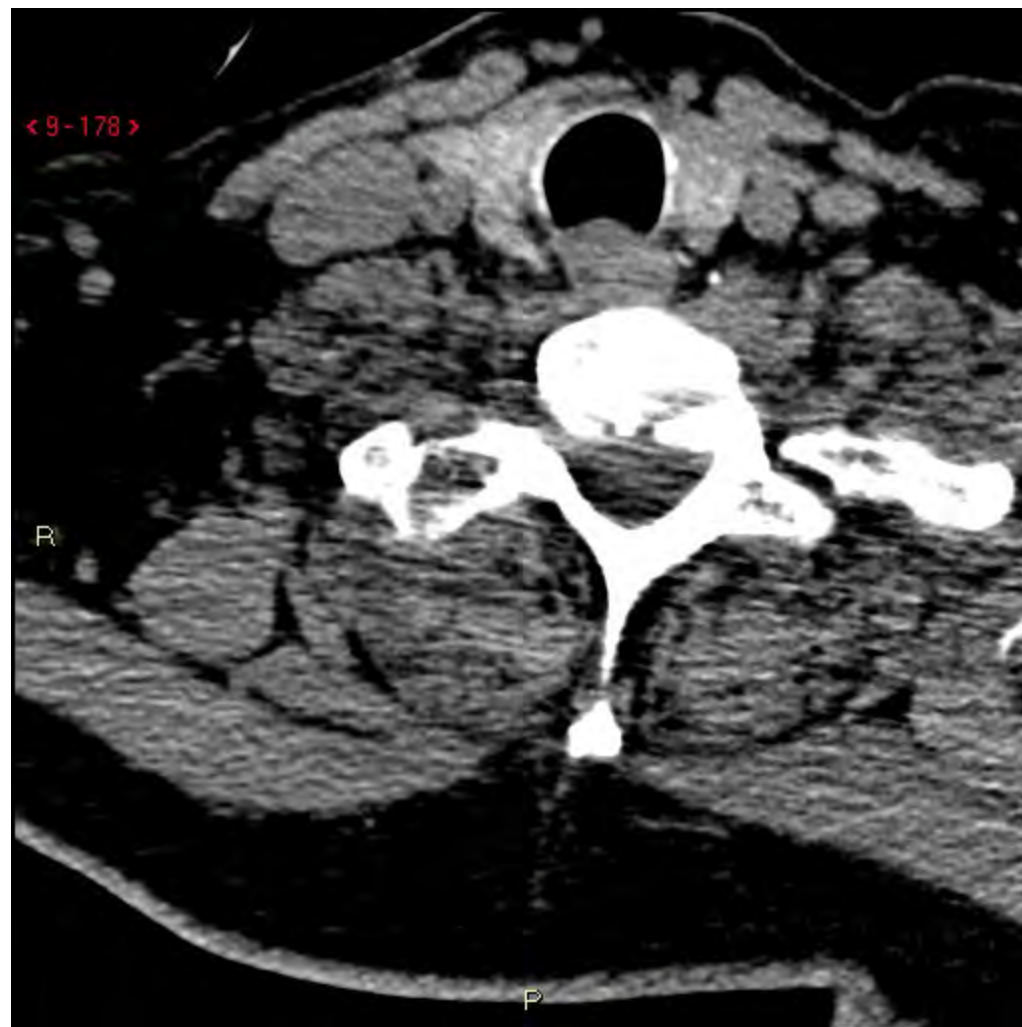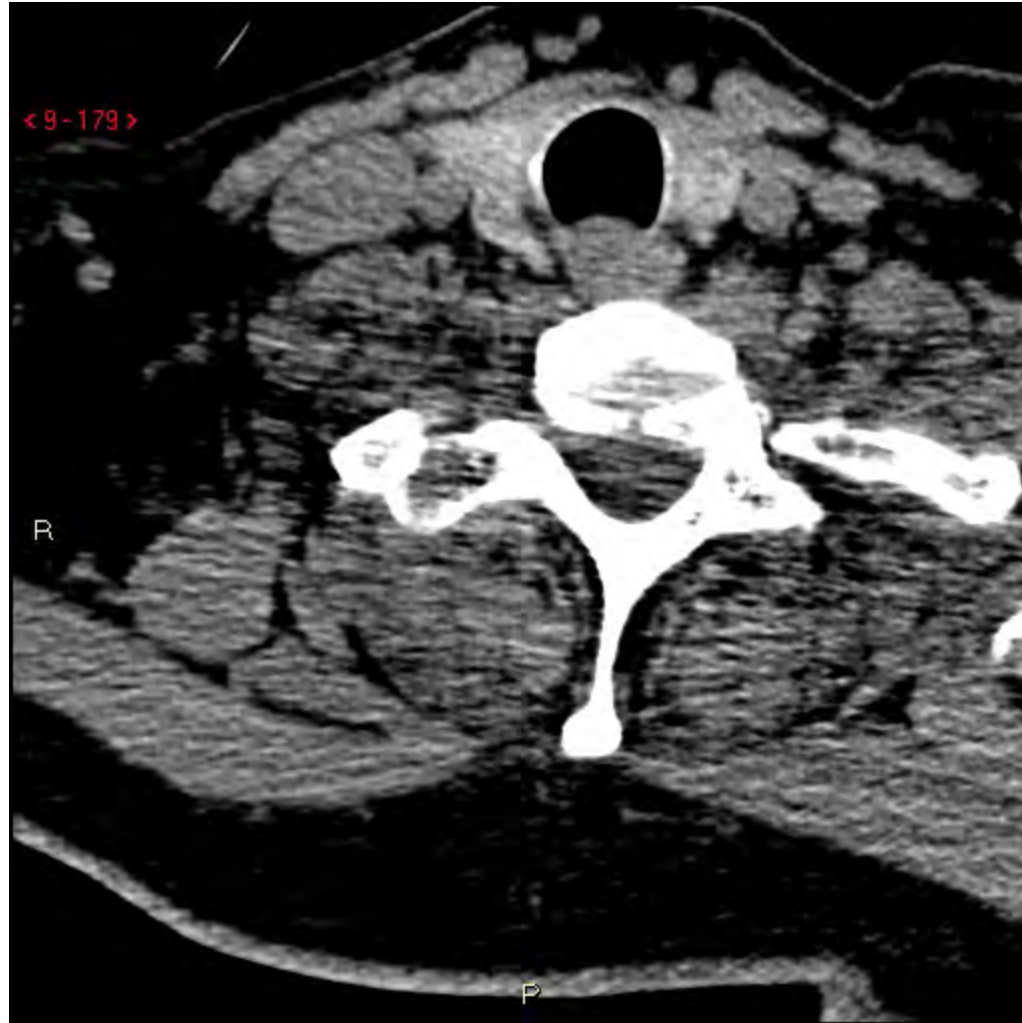




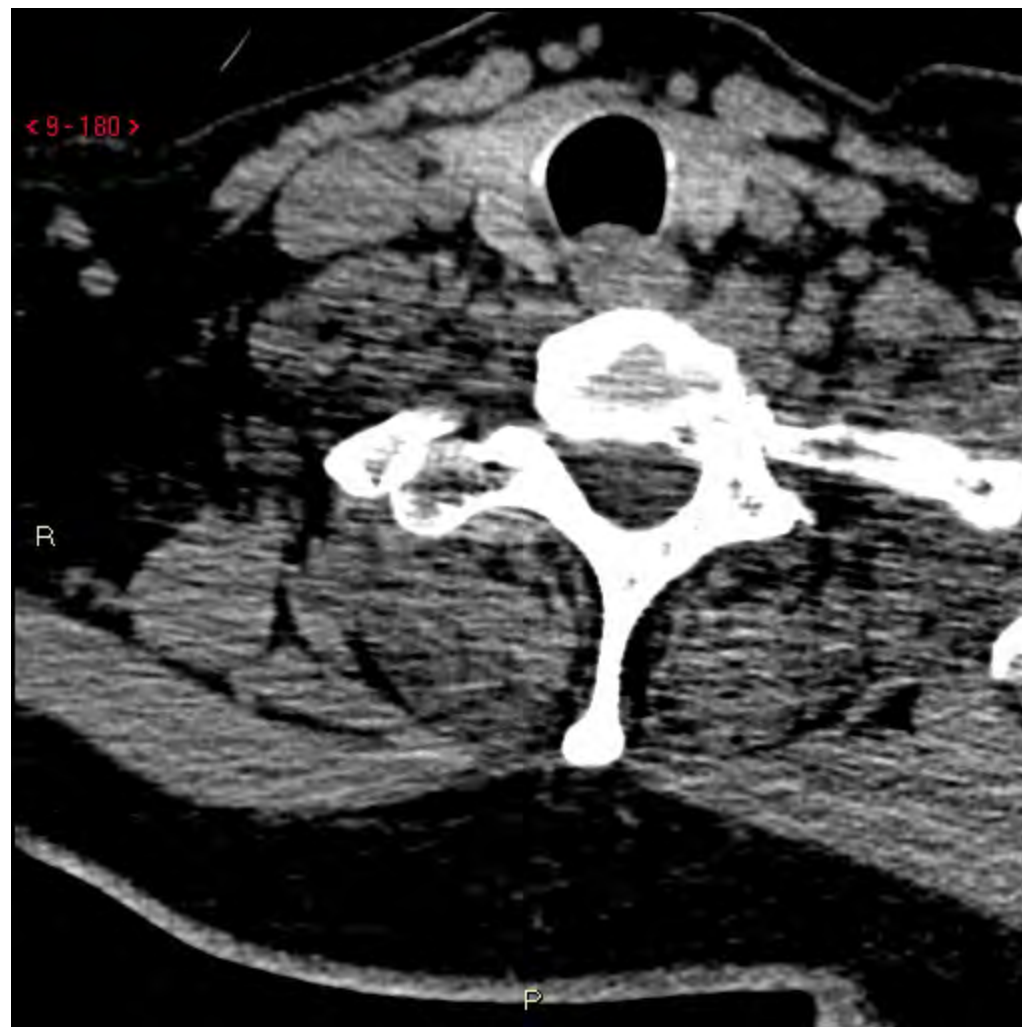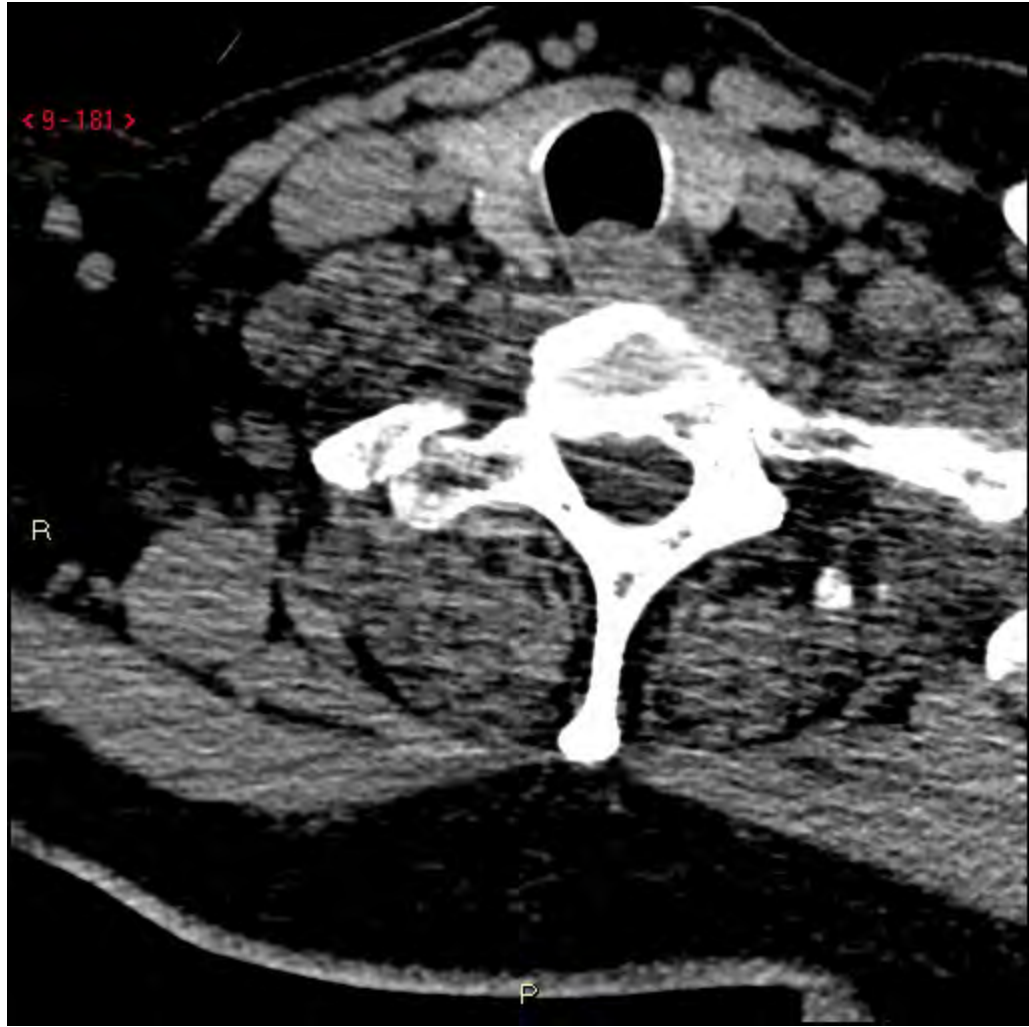
























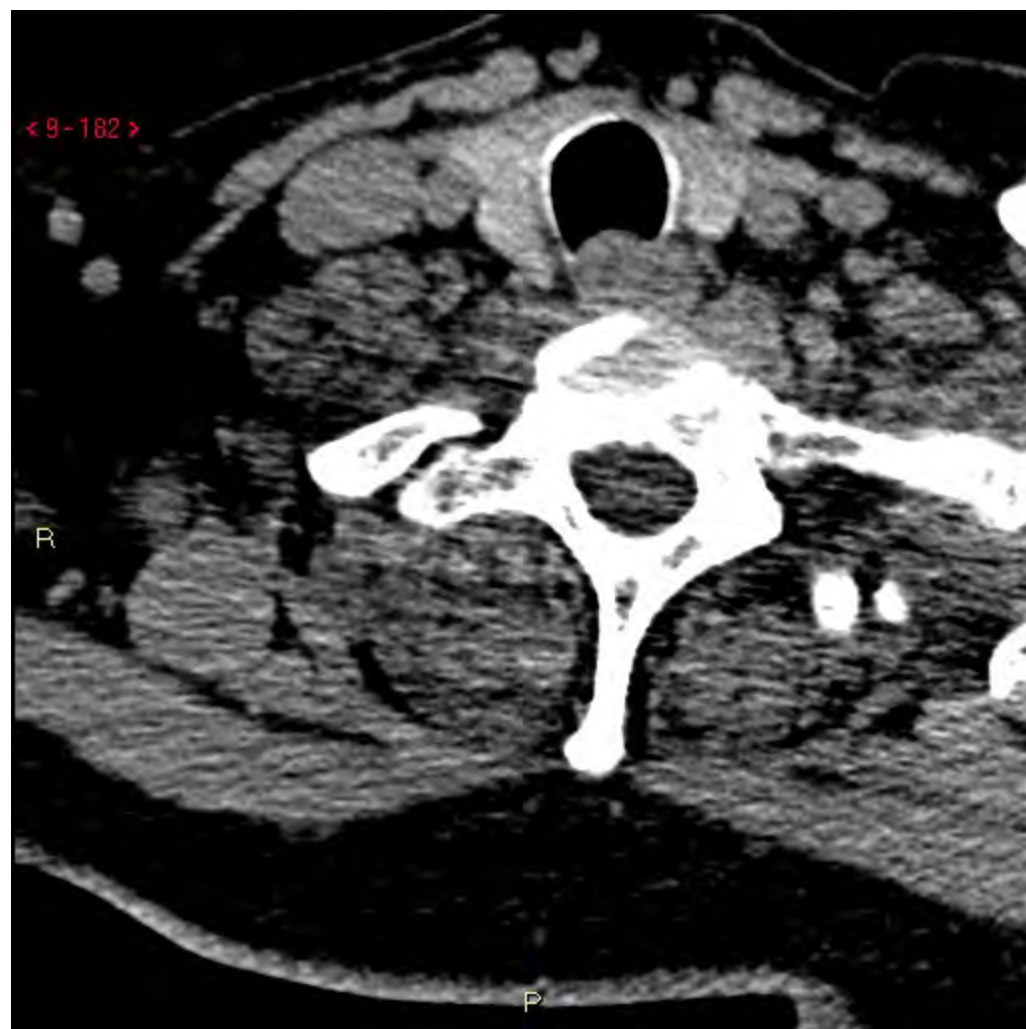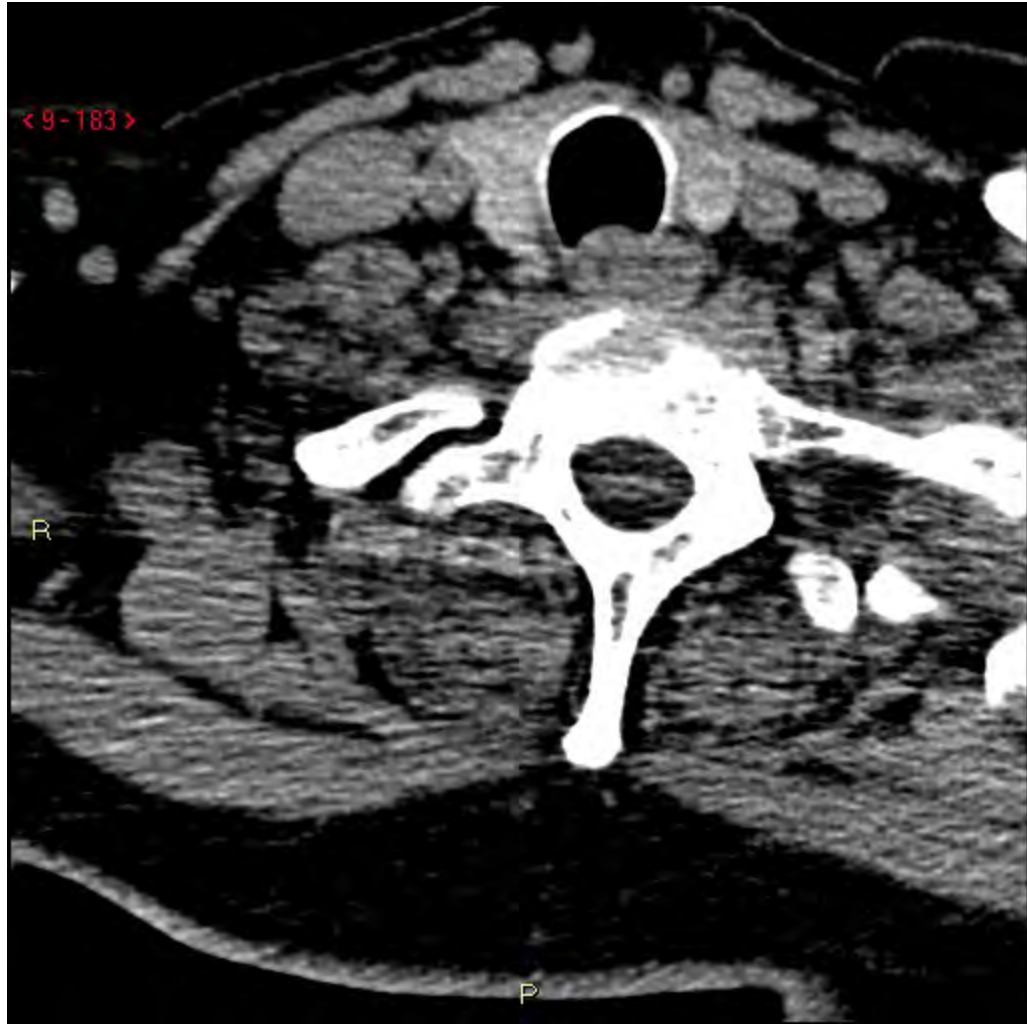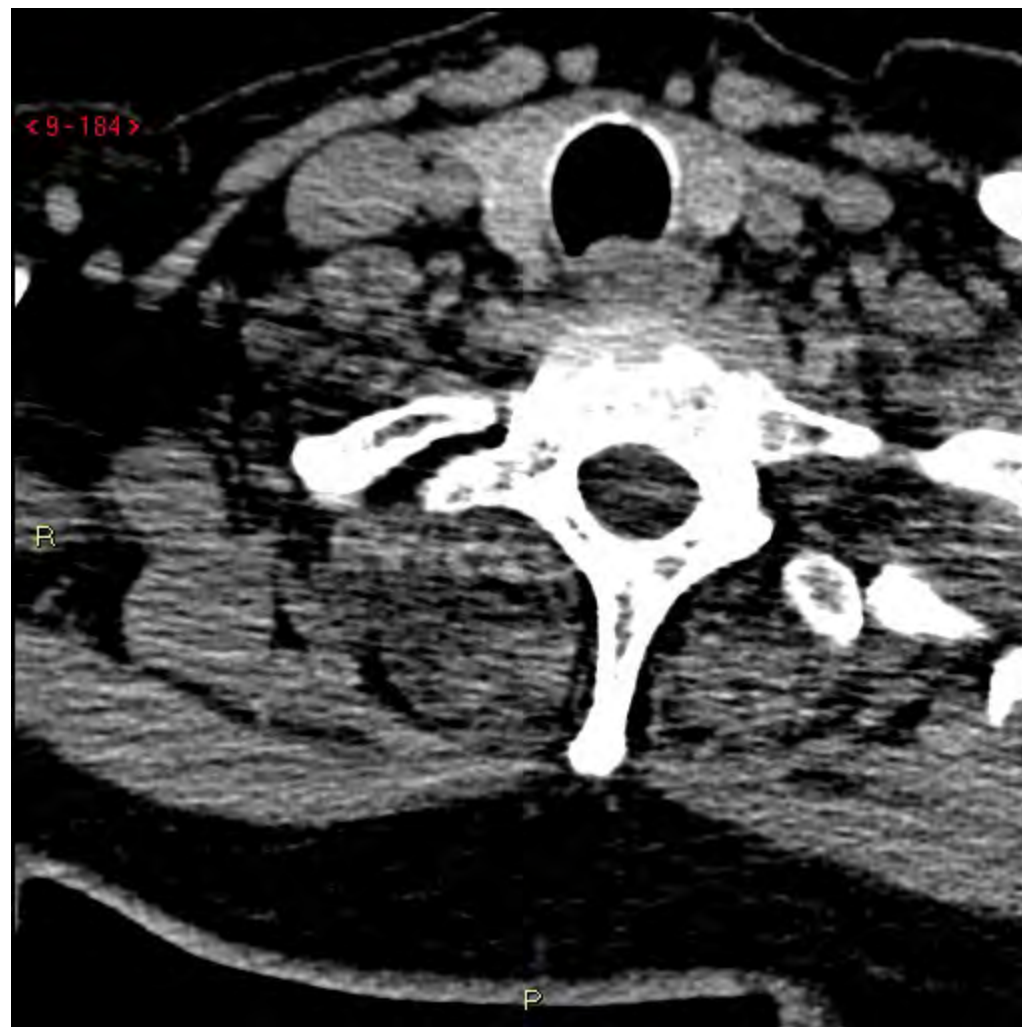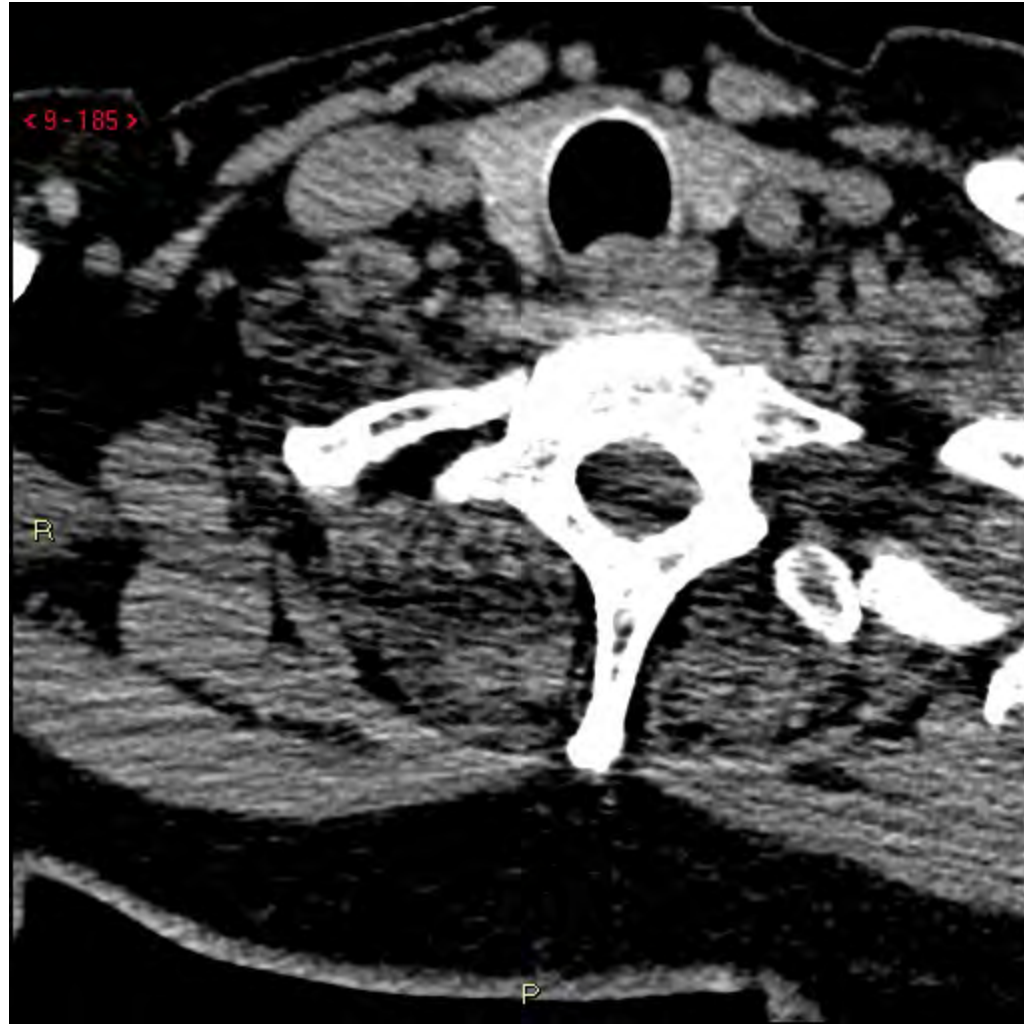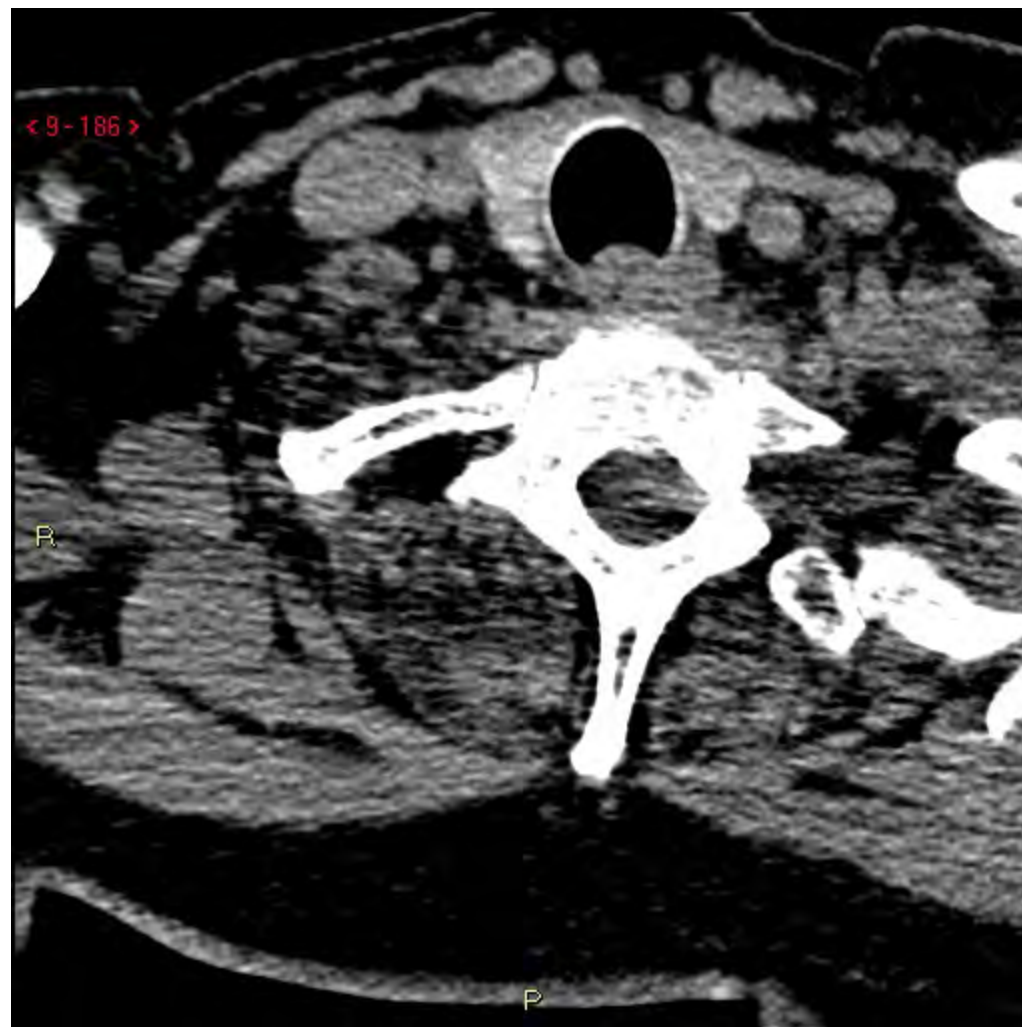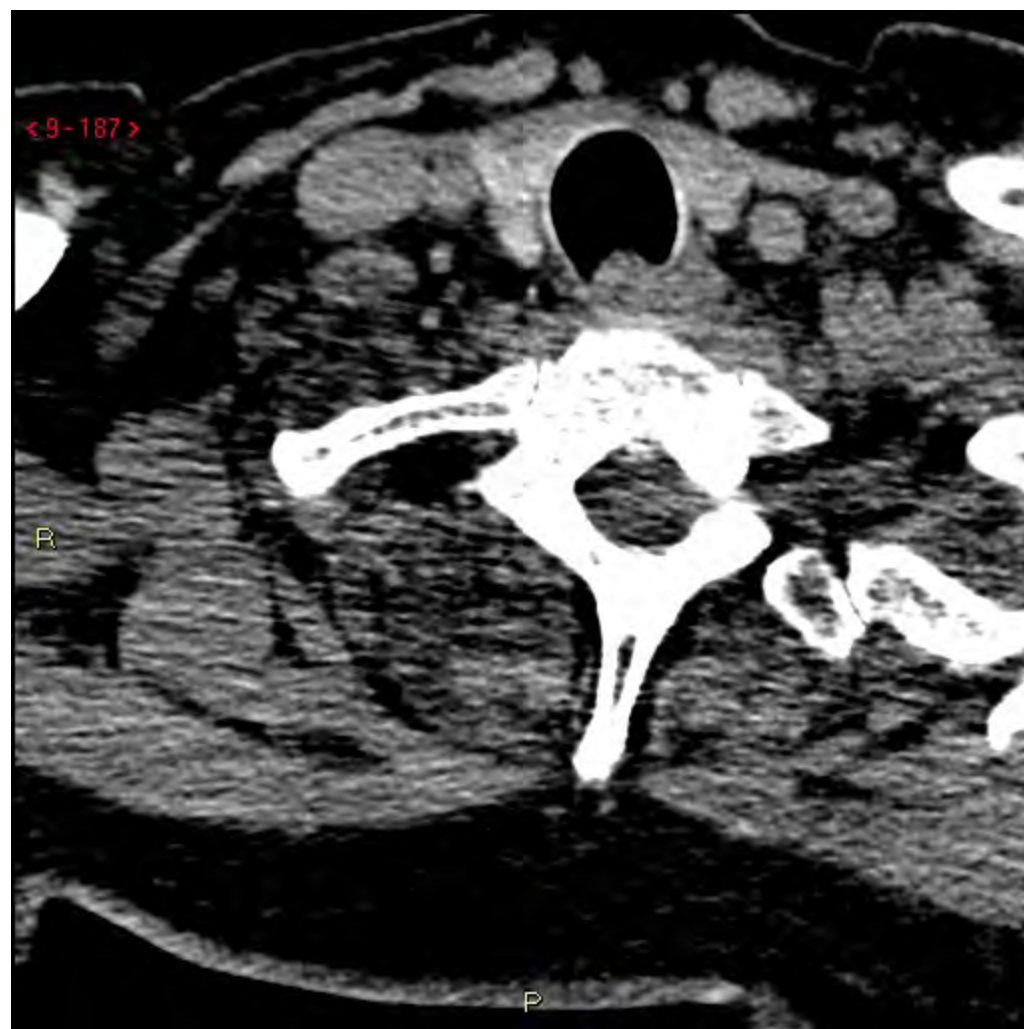Fall 3

Fynd:

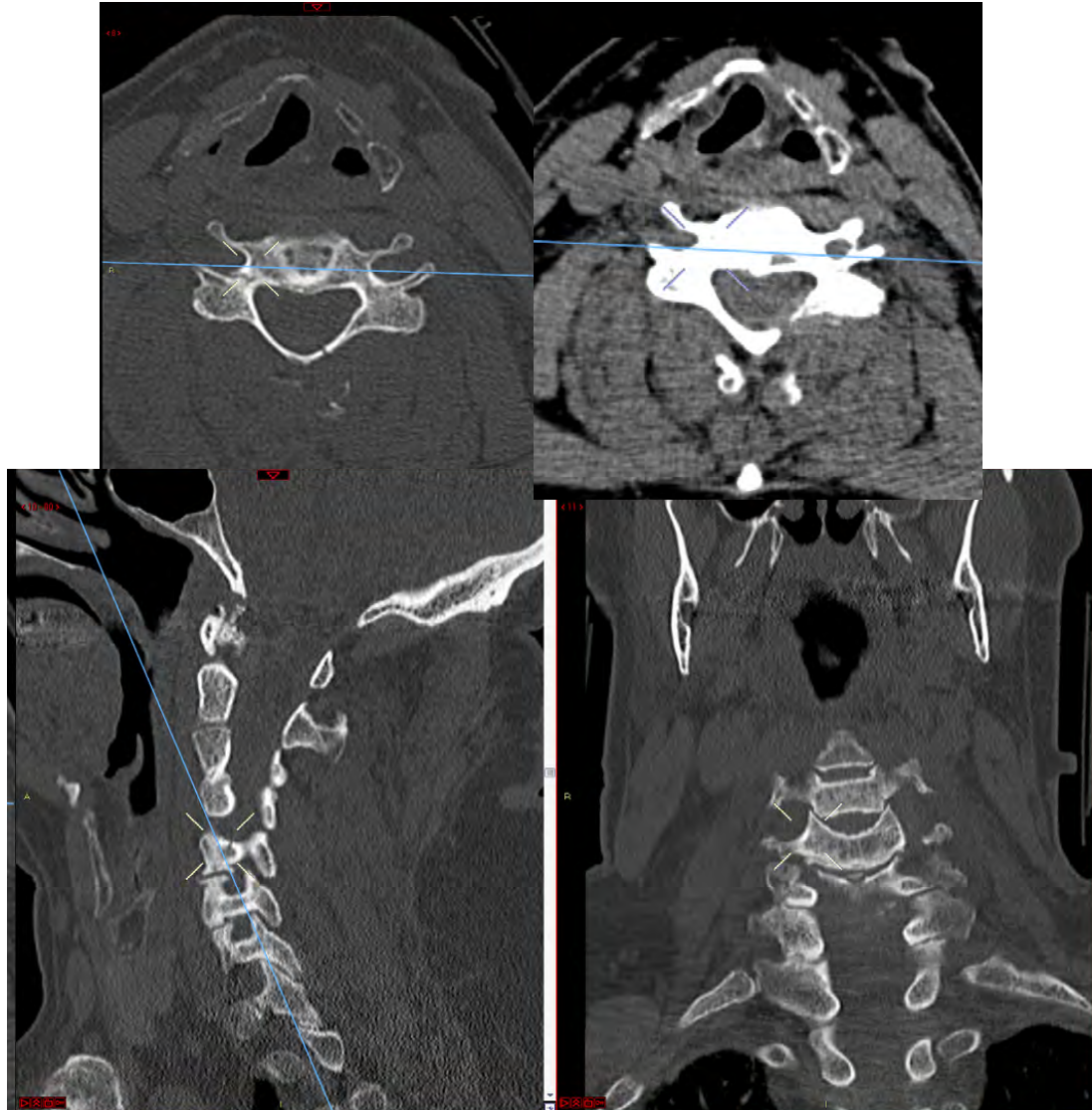
Svar 1:

Halsrygg: Komminut fraktur dorsalt genom lamina C5 sin och anteriort C5 dx, nära transversalutskottet; ringa frakturdiastaser. Antytt vidgade facettleder bilat C5-C6. Möjligen lätt rotationsinslag. Blockkota C3-C4. Även frakturer i spinalutskotten C4-C5, och avlöst fragment från sup-ant delen a spinalutskottet C6, vid canalis vertebralis. Dors-sup i corpus C6 finns ojämnheter där fraktur ej kan uteslutas. Svårbedömt pga utbredda degenerativa förändringar. Förekomst av diskbråck svårbedömt pga dålig bildkvalitet.

Håller du med?

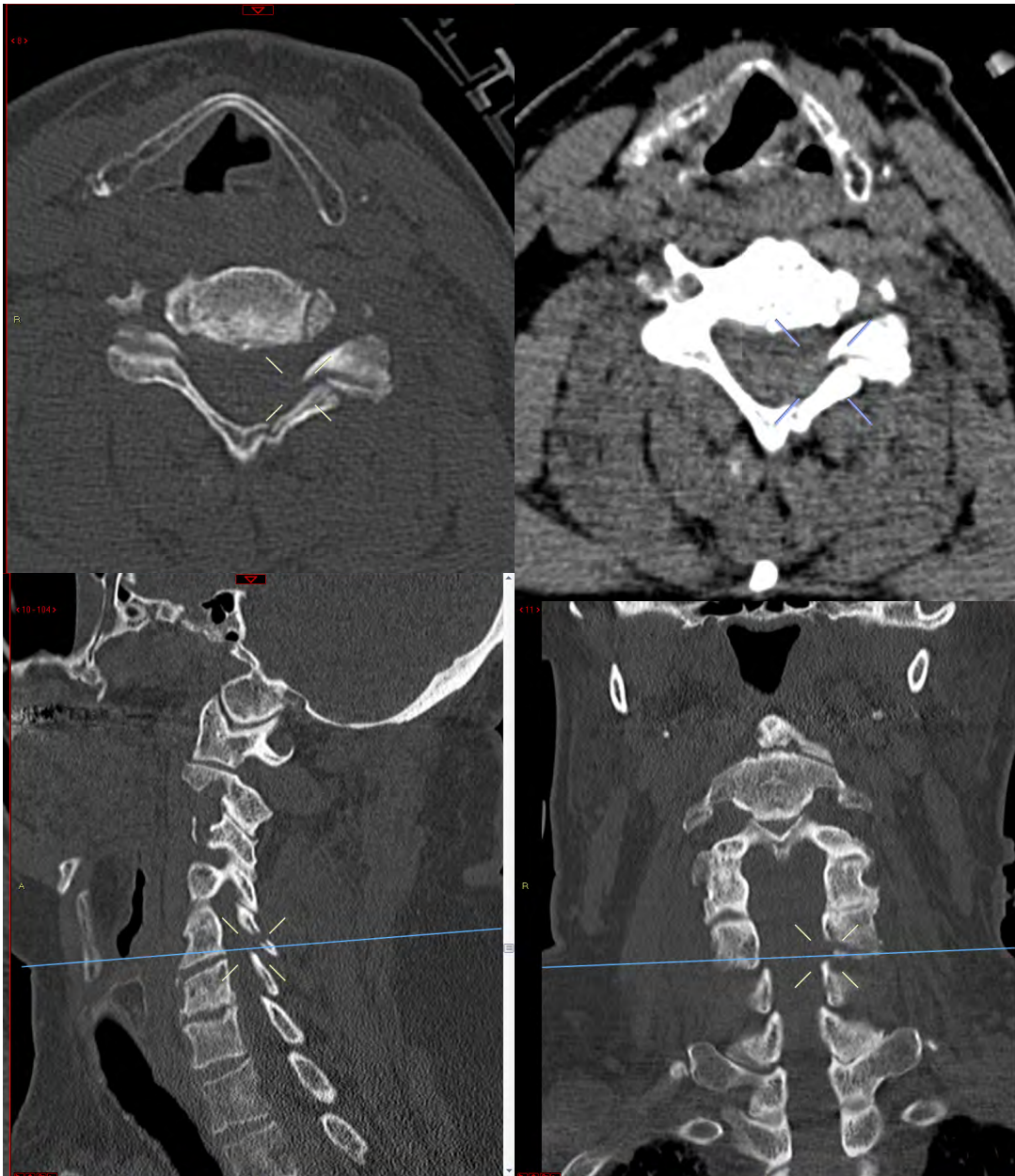
Fall 3

Höger



Fall 3

Vänster sida



Fall 3

Svar 1:

Halsrygg: Komminut fraktur dorsalt genom lamina C5 sin och anteriort C5 dx, nära transversalutskottet; ringa frakfurdiastaser. Antytt vidgade facettleder bilat C5-C6. Möjligen lätt rotationsinslag. Blockkota C3-C4. Även frakturer i spinalutskotten C4-C5, och avlöst fragment från sup-ant delen a spinalutskottet C6, vid canalis vertebralis. Dors-sup i corpus C6 finns ojämnheter där fraktur ej kan uteslutas. Svårbedömt pga utbredda degenerativa förändringar. Förekomst av diskbräck svårbedömt pga dålig bildkvalitet.

STABILT?

Fall 3

Nytt svar efter granskning:

Svar 2:

Avlösning av processus spinosus C4. Comminut fraktur i lamina C5 på vänster sida med engagemang av nedre leddutskott, och odislocerad fraktur i bågbasen och tvärutskott C5 på höger sida. Misstänkt skalformad avlösning från övre främre kanten C6 vä sida och odislocerad fraktur i vä tvärrutskott C6. Något ökade ledspalter i facettleder C5-C6. 2 mm dorsal dislokation av lamina C5 i förhållande till lamina C6 med minimal avlösning i övre kanten av den sistnämnda.

STABILT?

Fall 3

SLIC= Subaxial cervical Spine Injury Classification system.

Poängsystem, Morfologi, Diskoligamentärt komplex och Neurologi.

Rotpåverkan, =1p
Komplett medulla, =2p
Inkomplett medulla=3p
Medullakompression+
nervpåverkan=+1p

DL-komplex
Sannolikt= 1p,
Skadad= 2p

Kompression, =1p
Kompression+Burst, =2p
Distraktion,
(facettledssublux, hyperextension)=3p
Translation/**rotation**, (facettledslux,
teardrop, flexion-
kompressionsskada)=4p

Fall 3

A - Compression injuries (30%)

I - Anterior vertebral body compression (wedge fractures)

II - Comminuted fractures (7%)

III - Teardrop fractures (23%)

B - Flexion-extension-distraction injuries (28%)

I - Moderate sprain, or whiplash injury

II - Severe sprains (14% of cases)

III - Bilateral fracture-dislocations (9%)

C - Rotation injuries (39%)

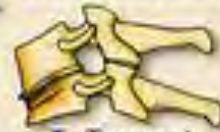I - **Unifacet fractures** (20% of injuries)

II - Fracture separation of the articular pillar (10%)

III - Unilateral dislocation (9% of lesions)

CLASSIFICATION OF LOWER CERVICAL SPINE INJURIES

A COMPRESSION INJURIES



I. Tassement antérieur

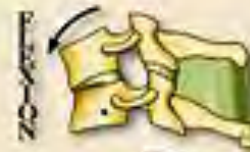

II. Comminutive fracture



III. "Tear drop" fracture

B FLEXION-EXTENSION-DISTRACTION INJURIES



I. Entorse "moyenne"



II. Entorse grave



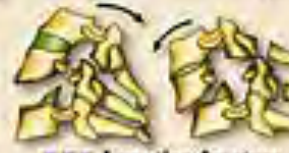III. Luxation fracture biarticulaire



I. Entorse "moyenne"



II. Entorse grave



III. Luxation fracture biarticulaire

C ROTATION INJURIES



I. Fracture unilatérale (E.U.A.)



II. Fracture-séparation du massif artulaire (F.S.M.A.)



III. Luxation unilatérale (L.U.A.)

Fall 3

Förslag: Misstänkt genomgående fraktursystem C4-6, som omfattar spinalutskotten C4 och 5, laminae ...ledutskott och ventrala kraniella hörnet på corpus C6. Ingen luxation. Ingen säker patologisk rotation.

INSTABILT!?