

Fall 3B

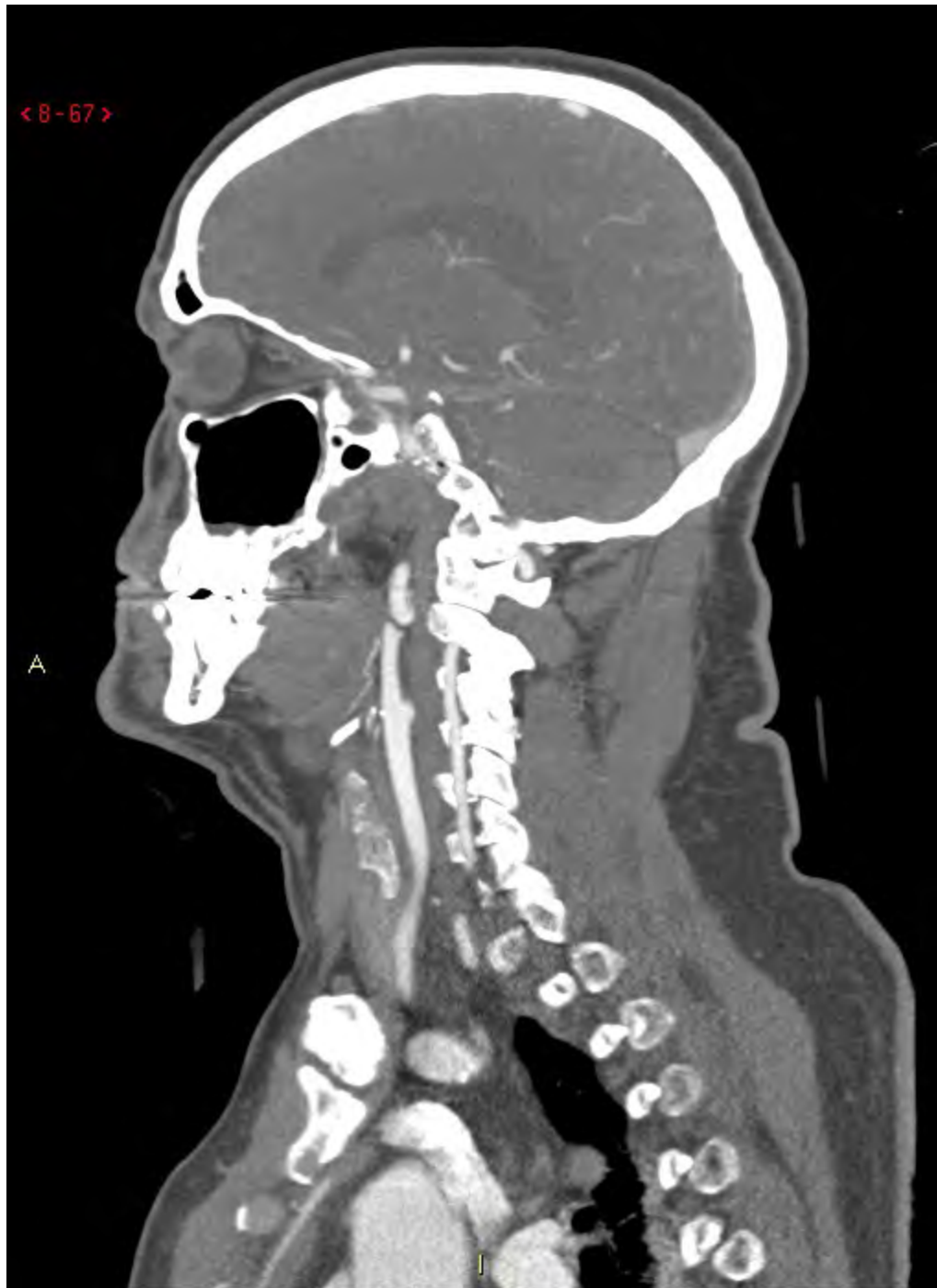# Fall 3B

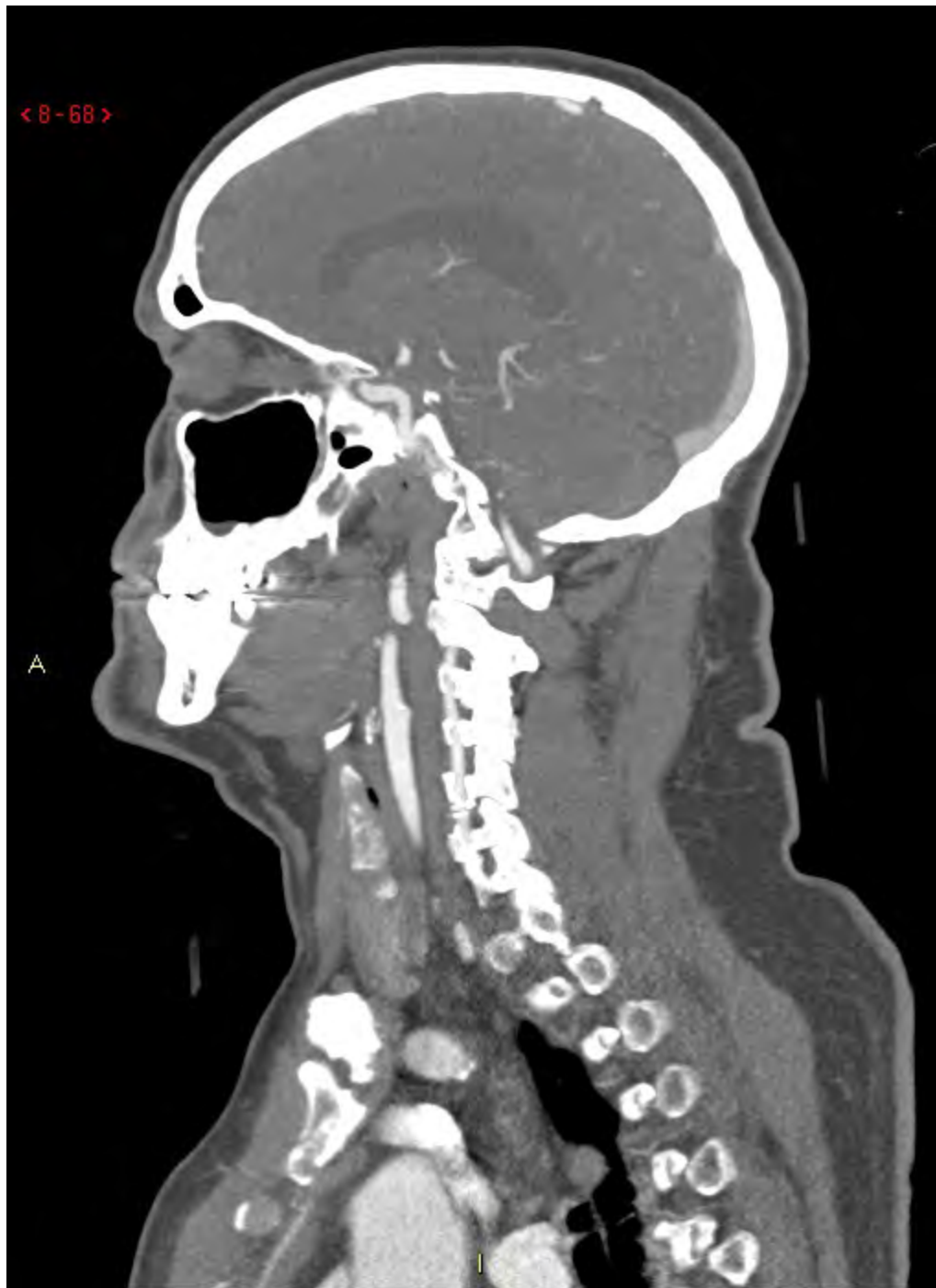Efter RTG-besked, bestämmer kliniker och patient att patienten ska få halskrage och gå hem. Han mår ganska bra. Ända tills han sätter sig upp på britskanten. Detta utlöser en kraftig rotatorisk yrsel. Klinikern hör av sig och rådgör med RTG-jouren. De kommer överens om att nästa undersöknign ska bli en:

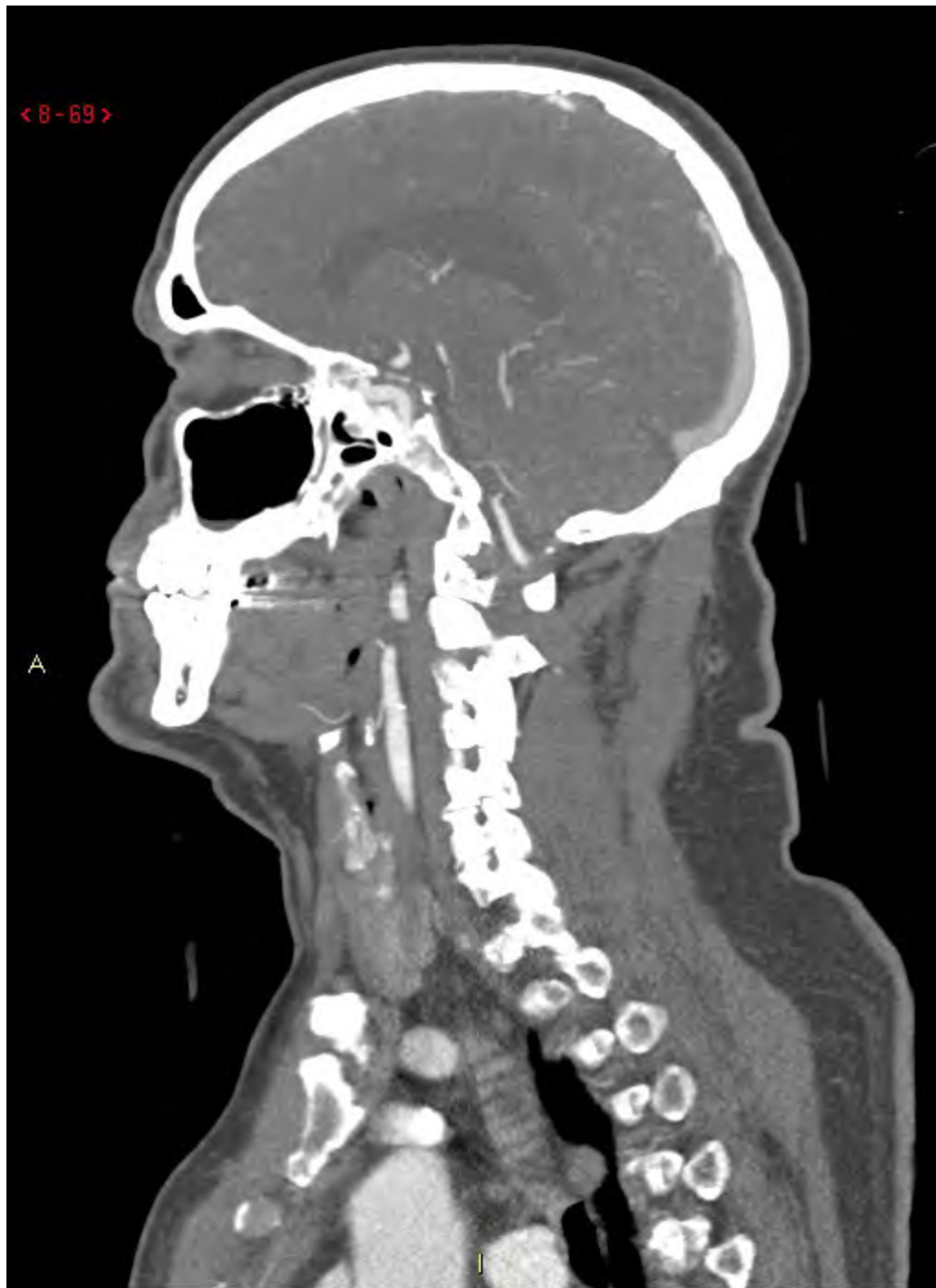Fall 3B

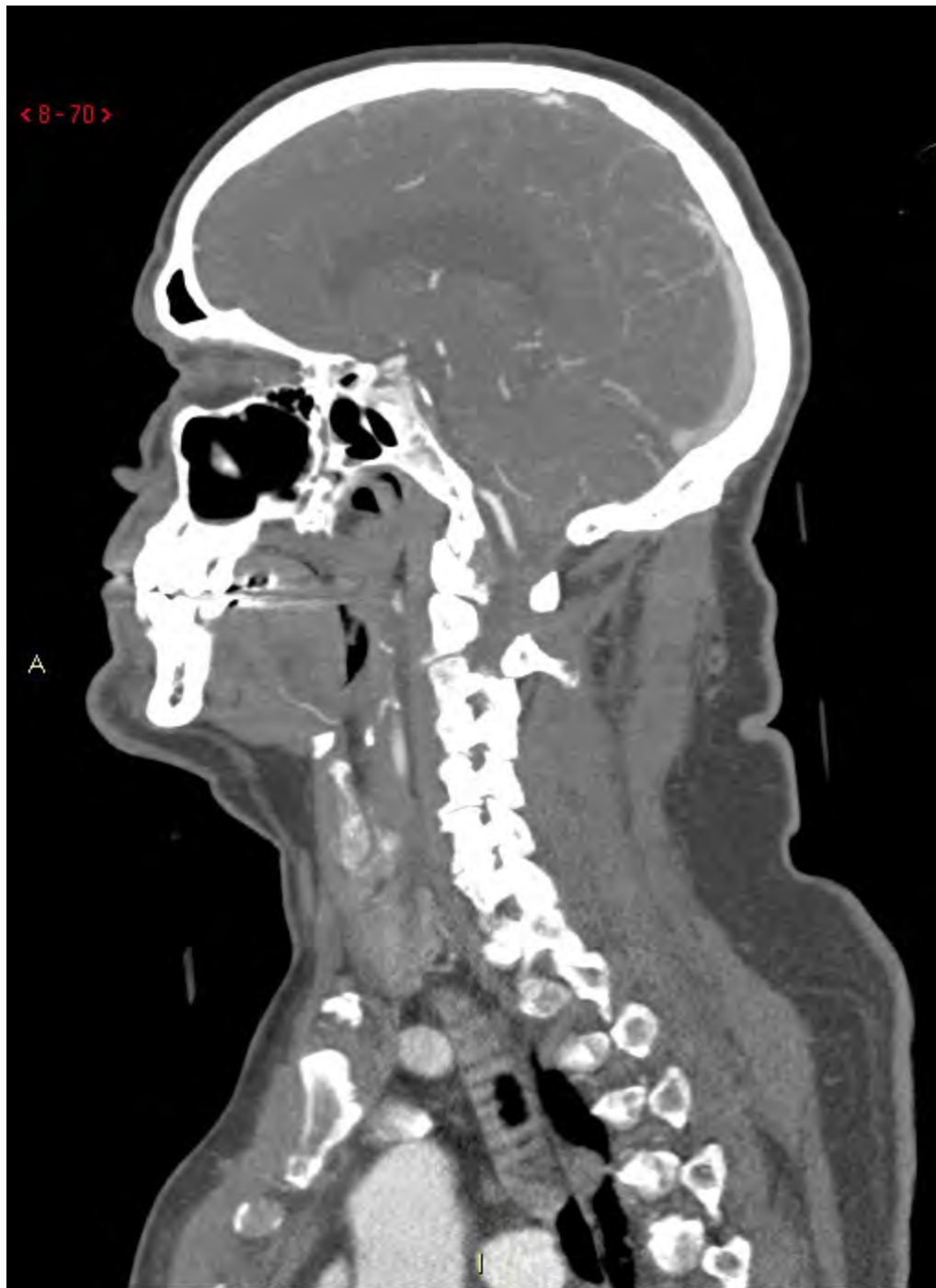DT-Angio

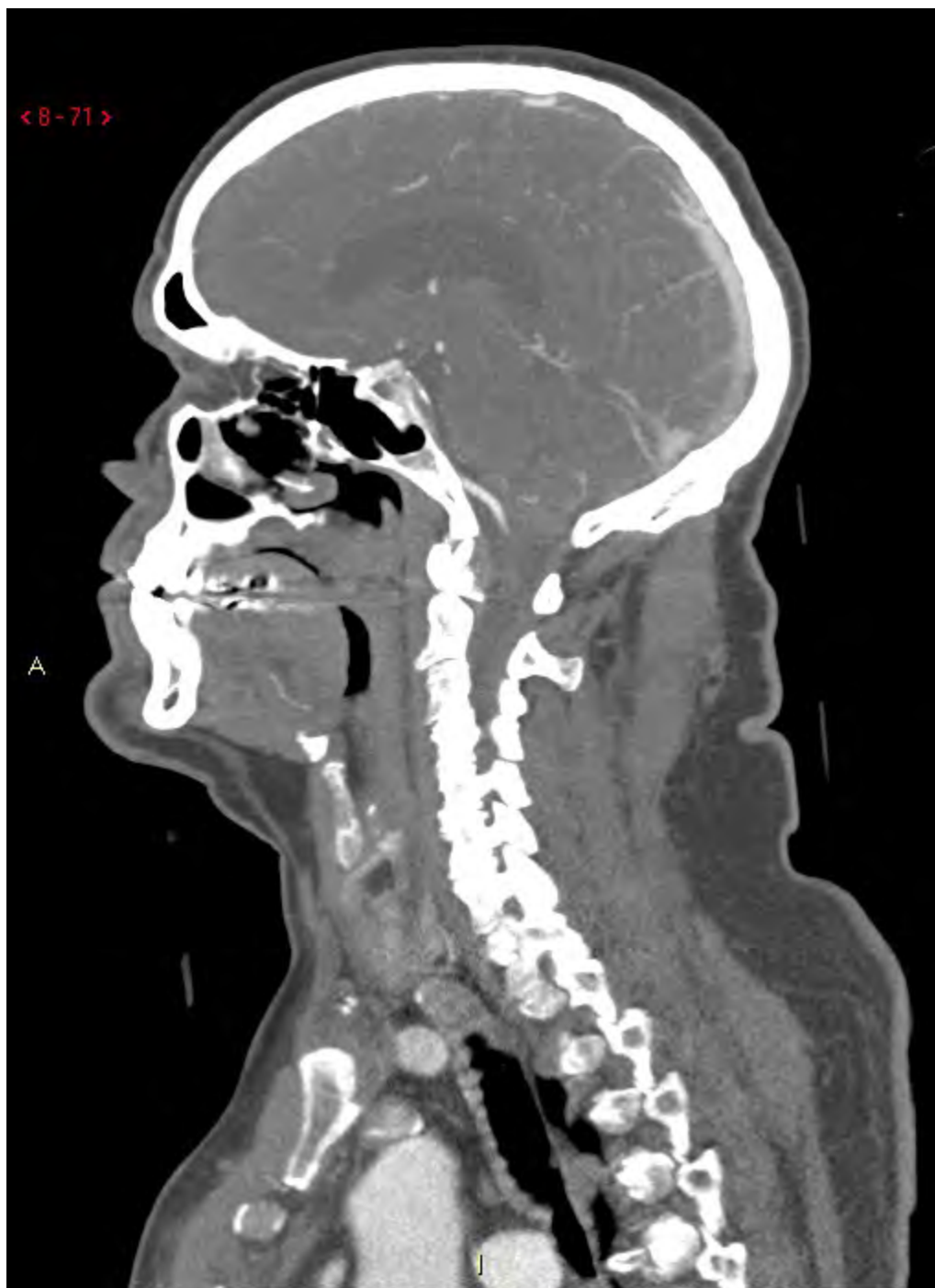< 8-67 >



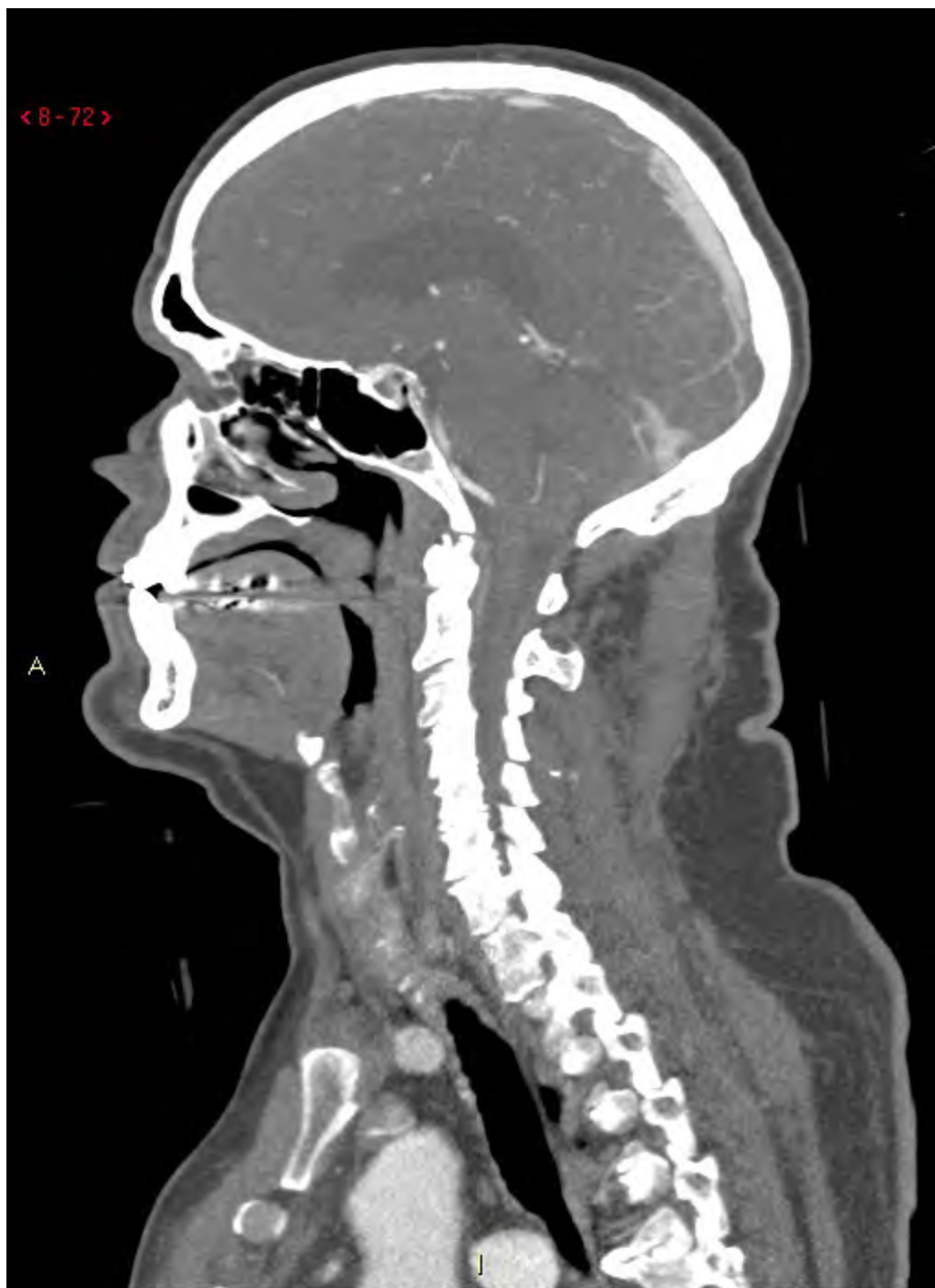


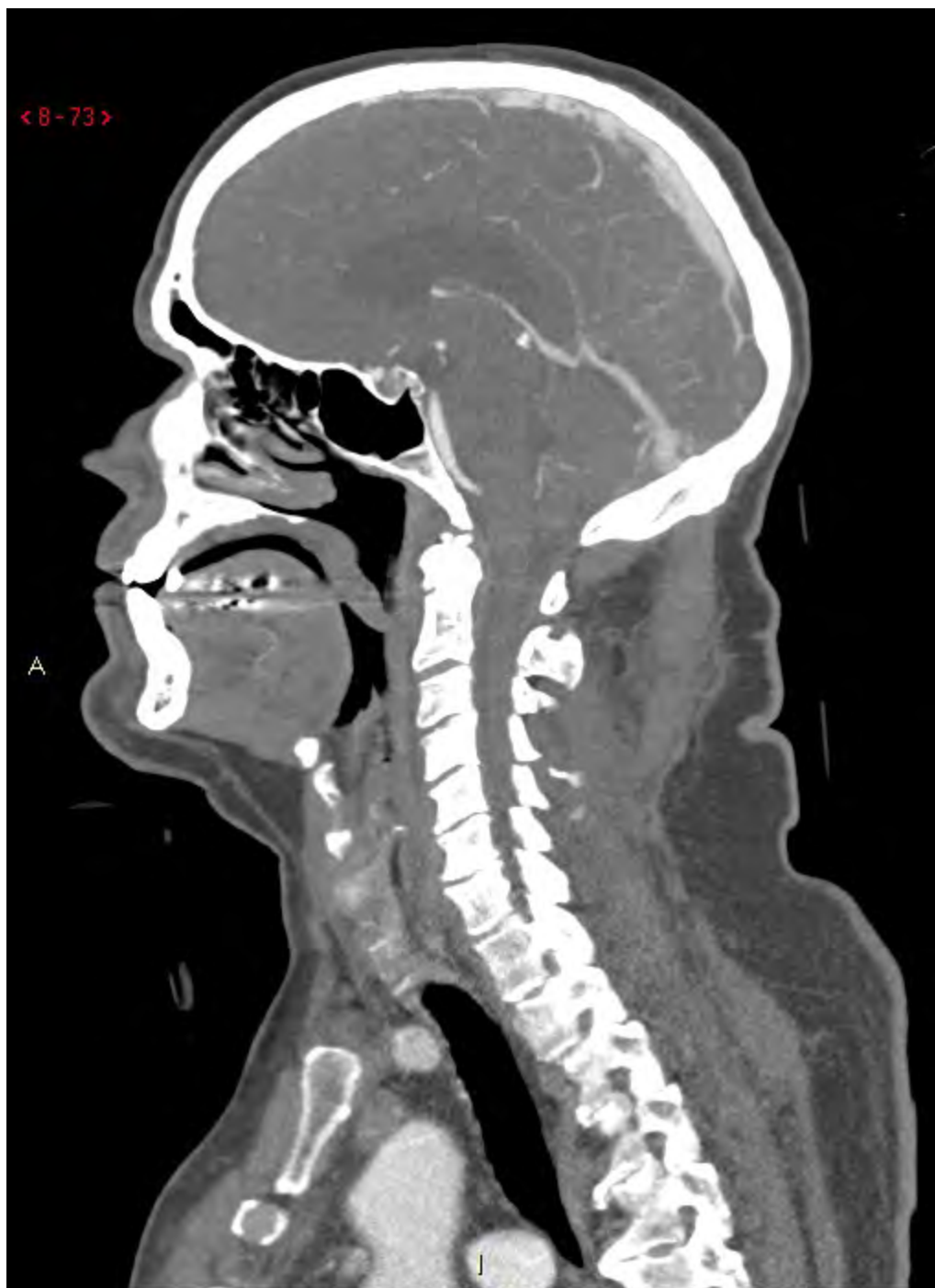


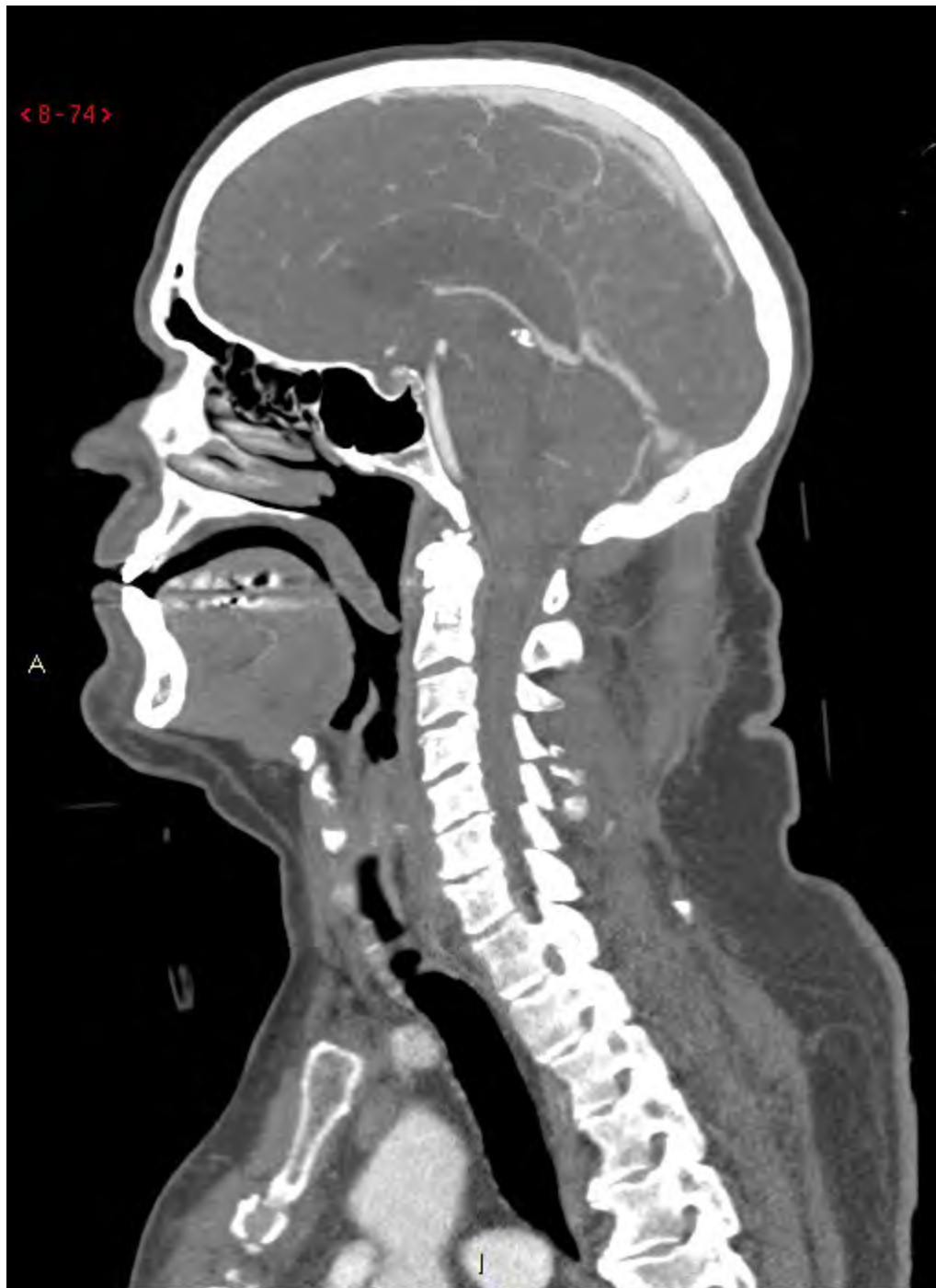


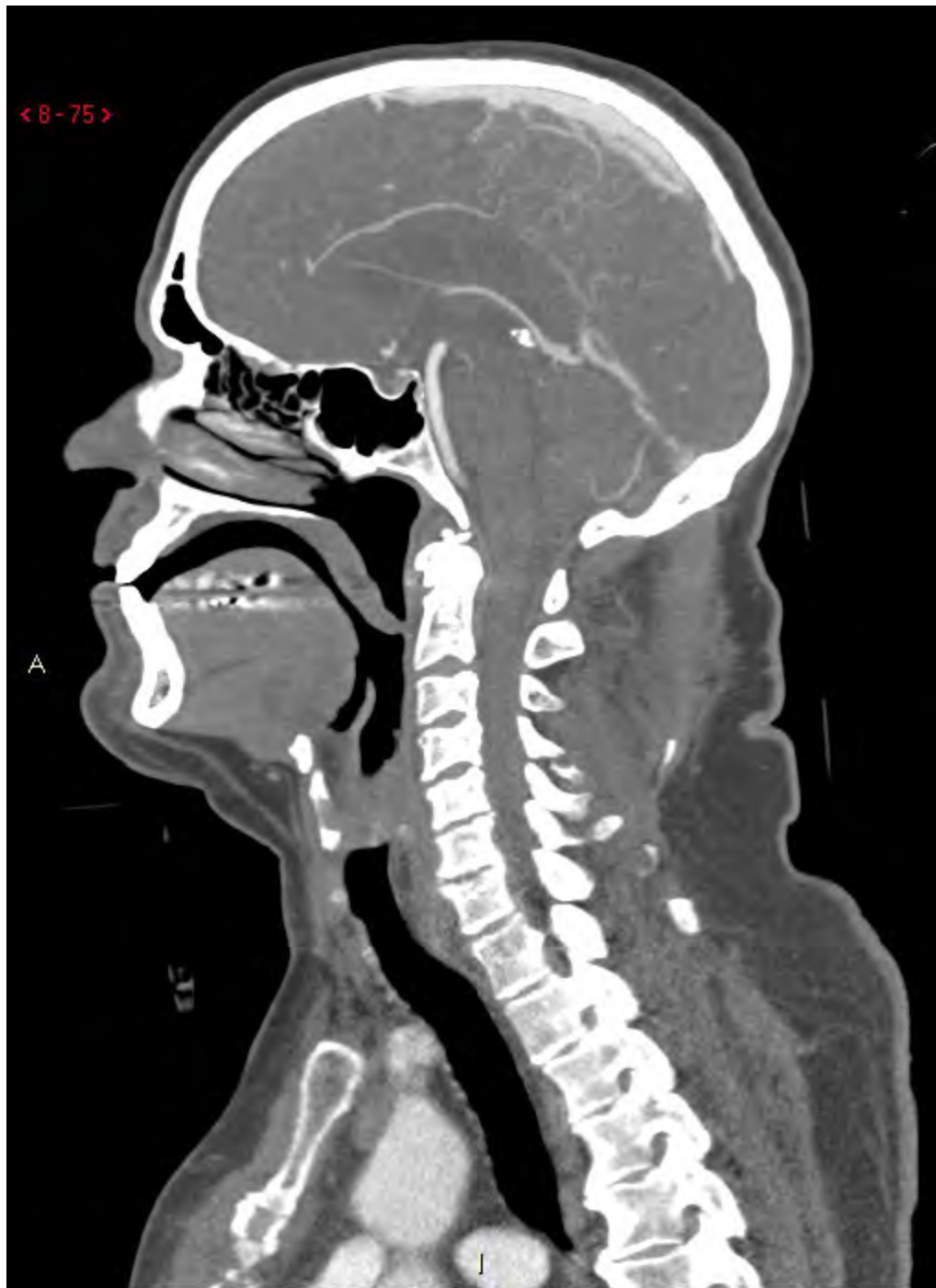


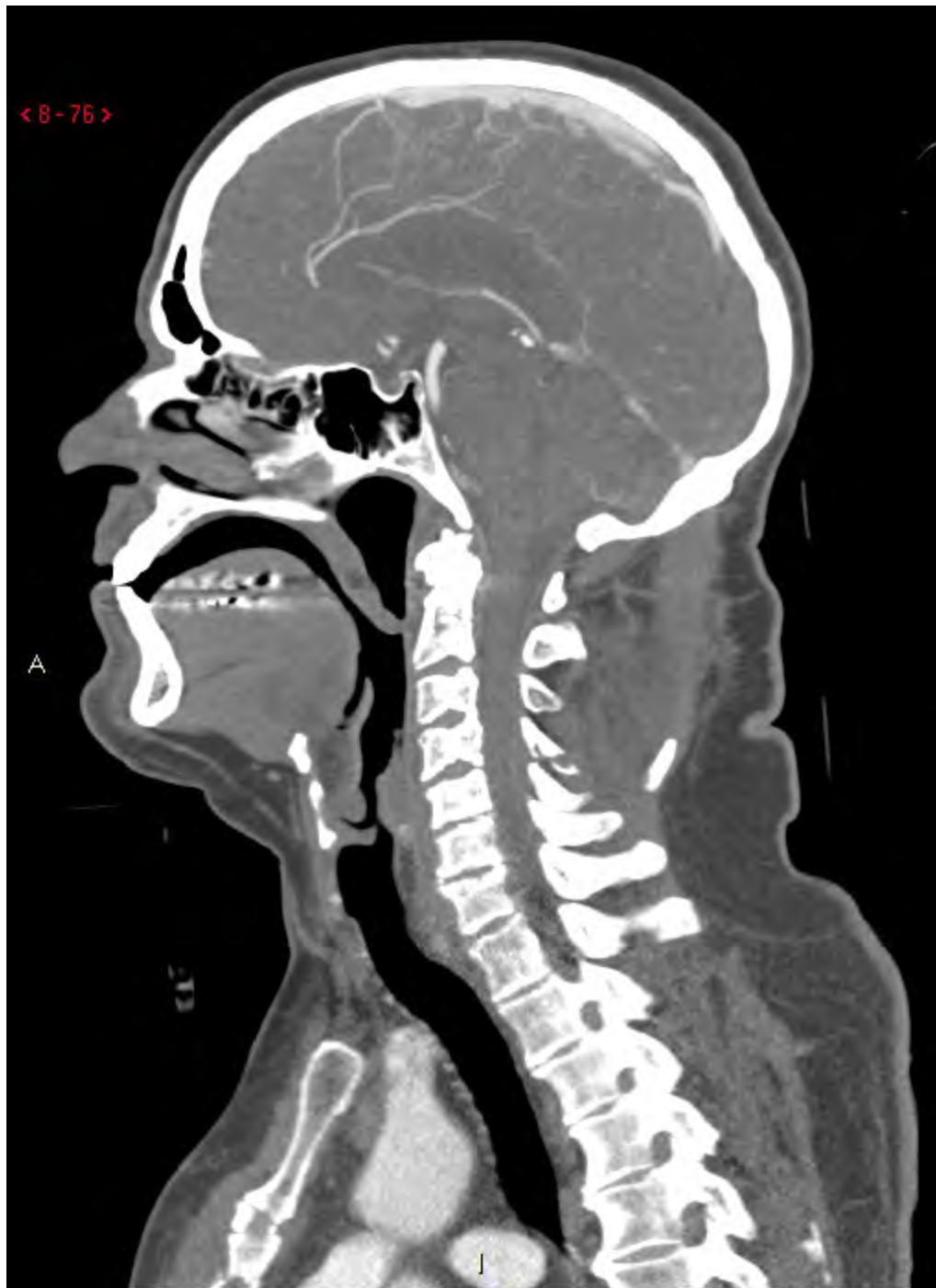


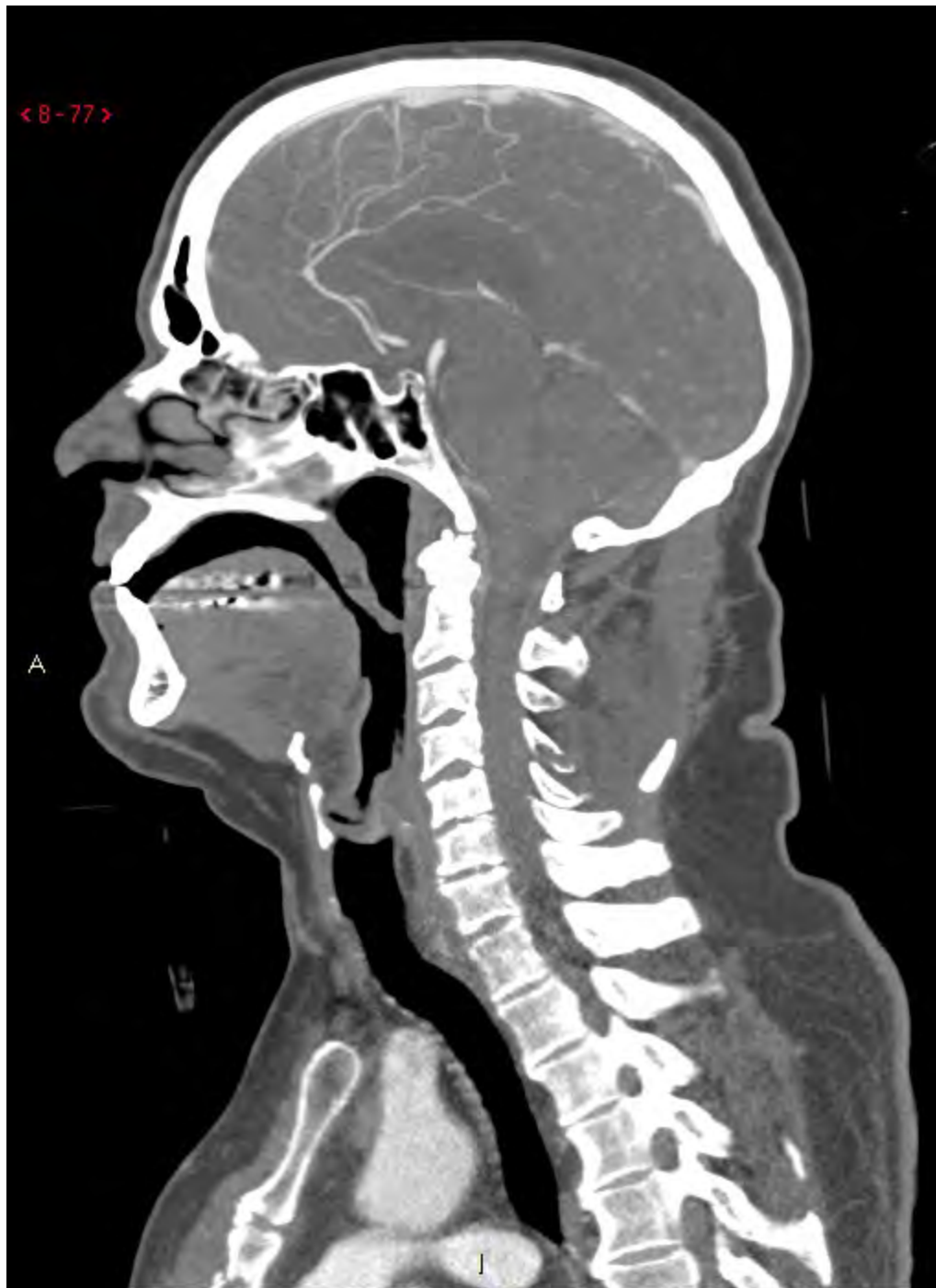




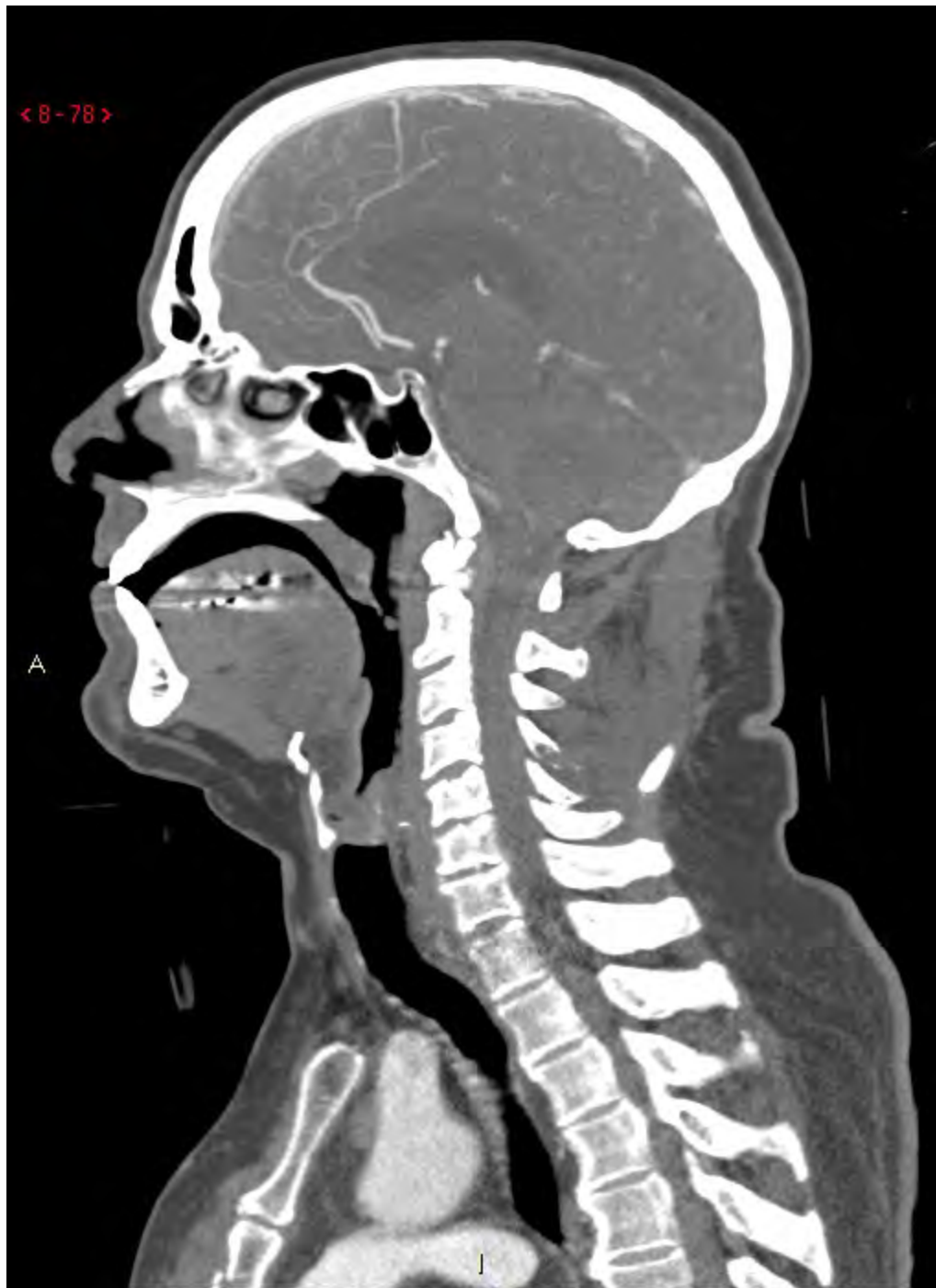


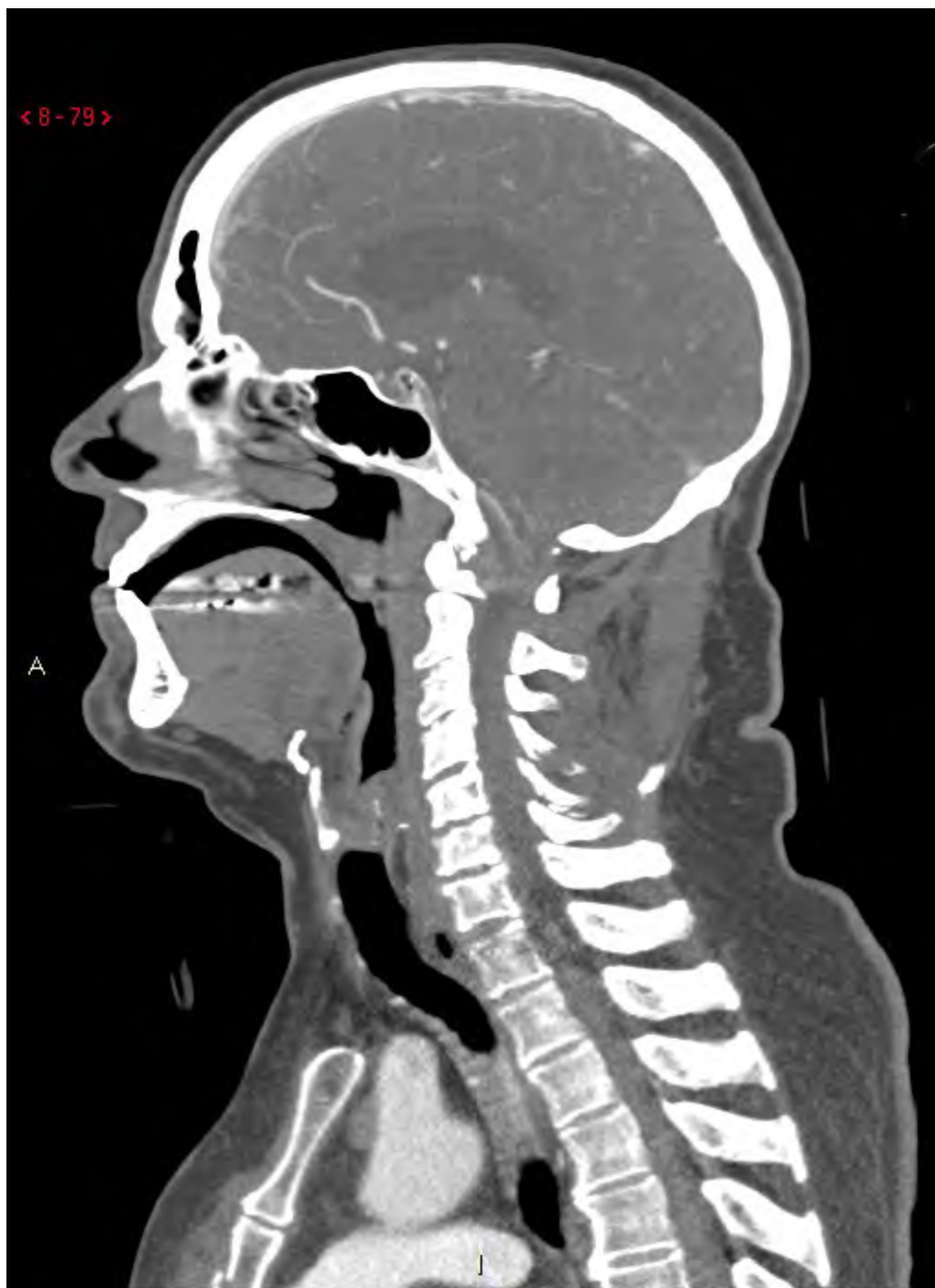




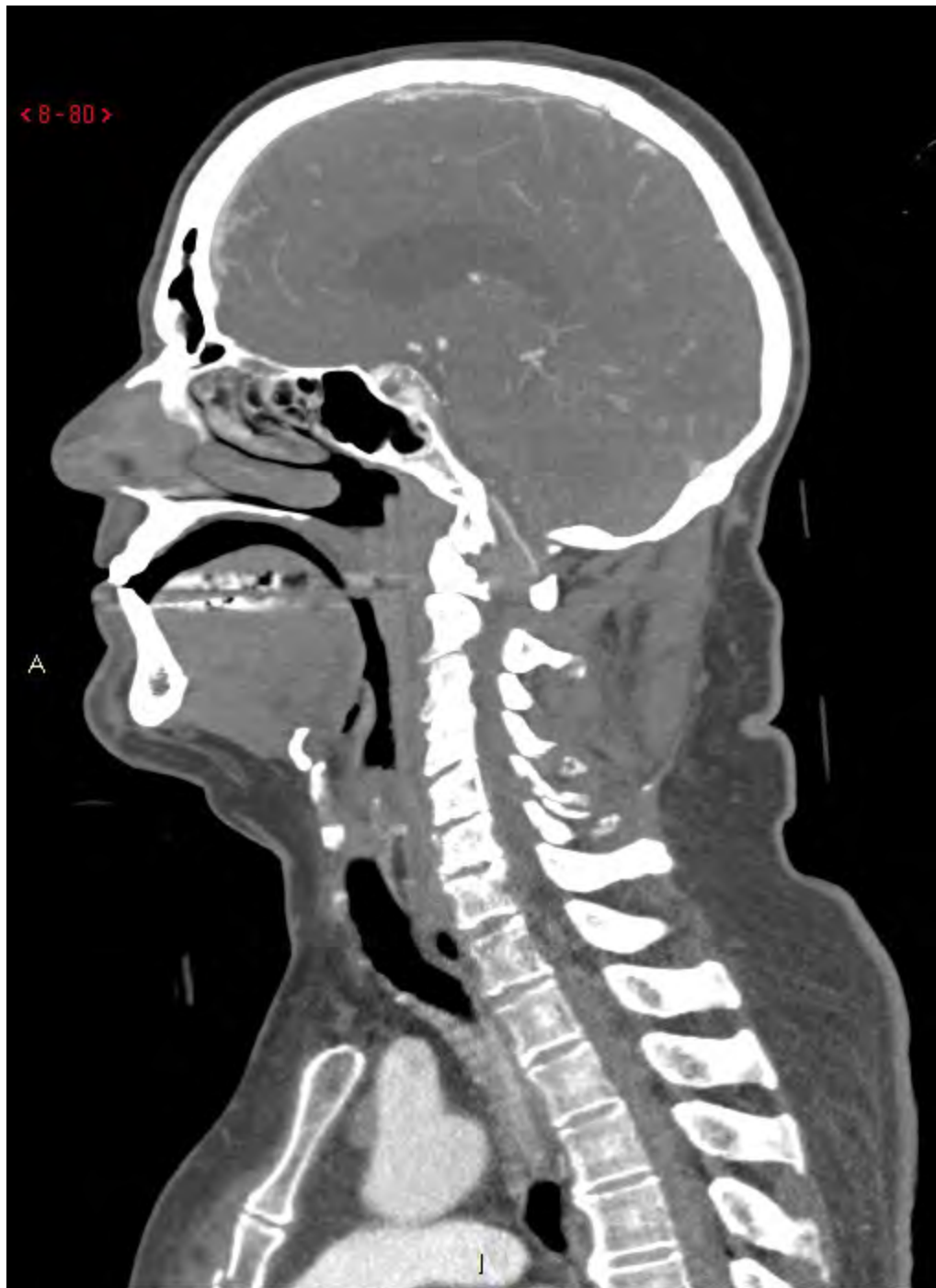


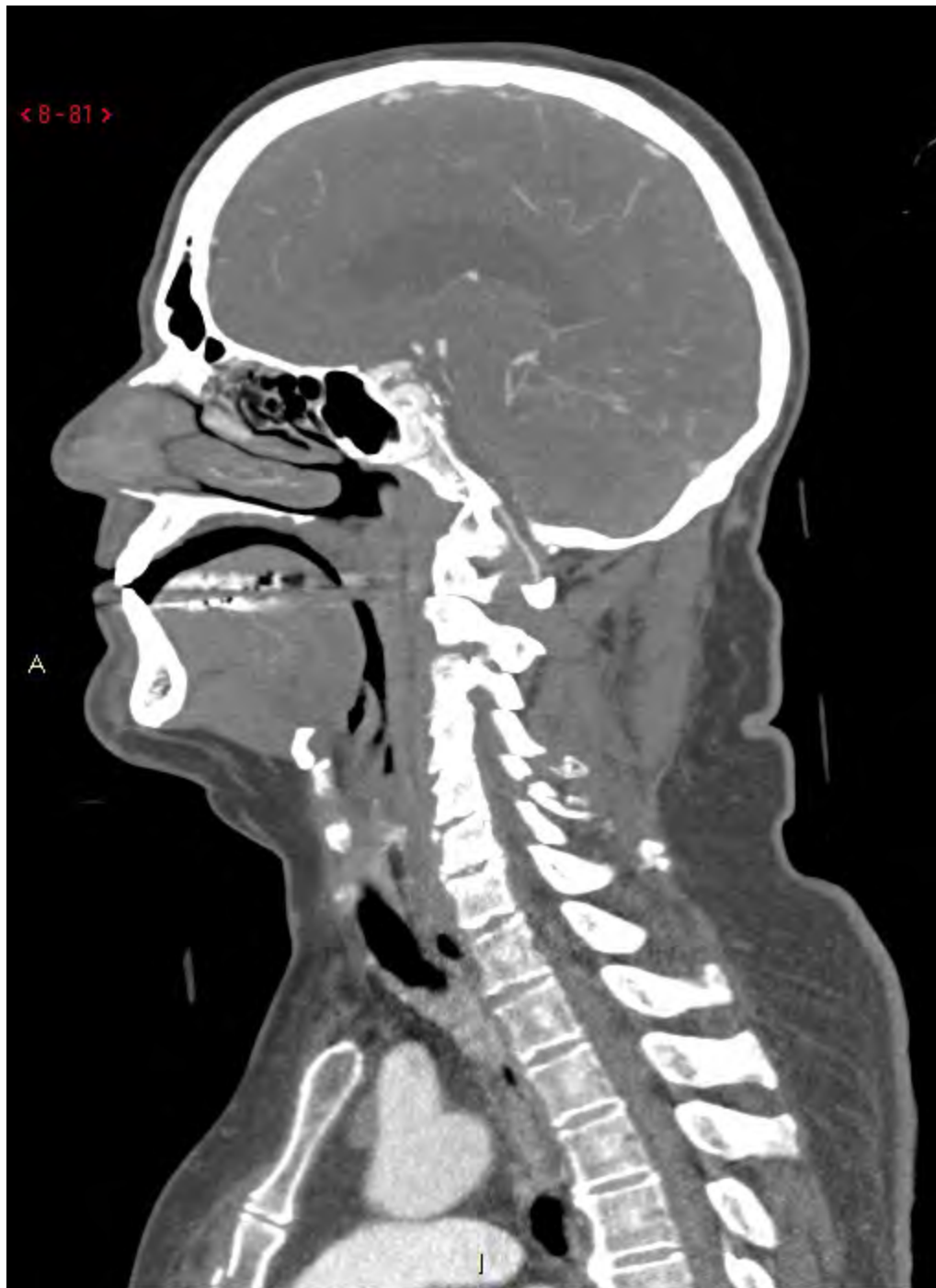


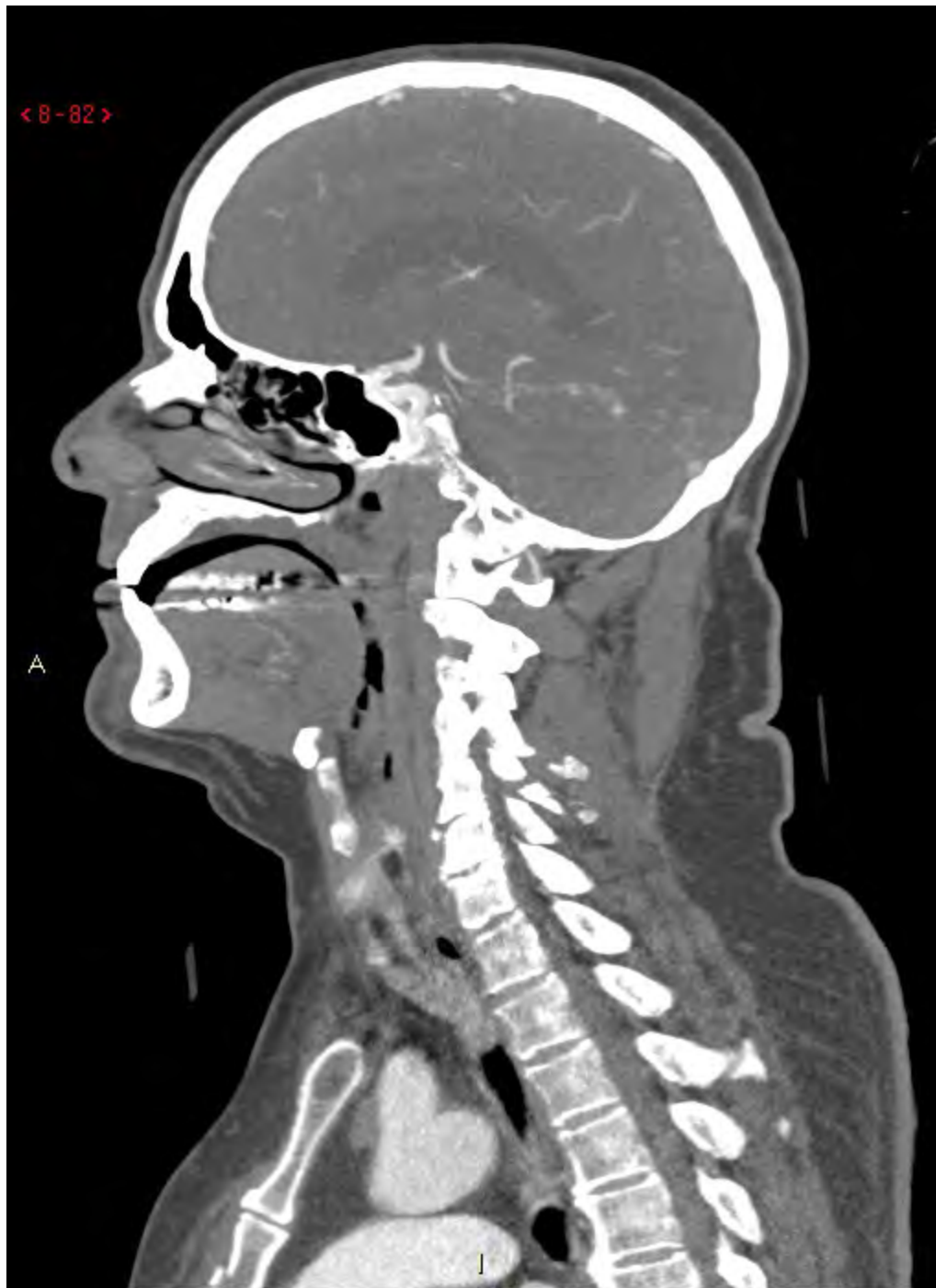

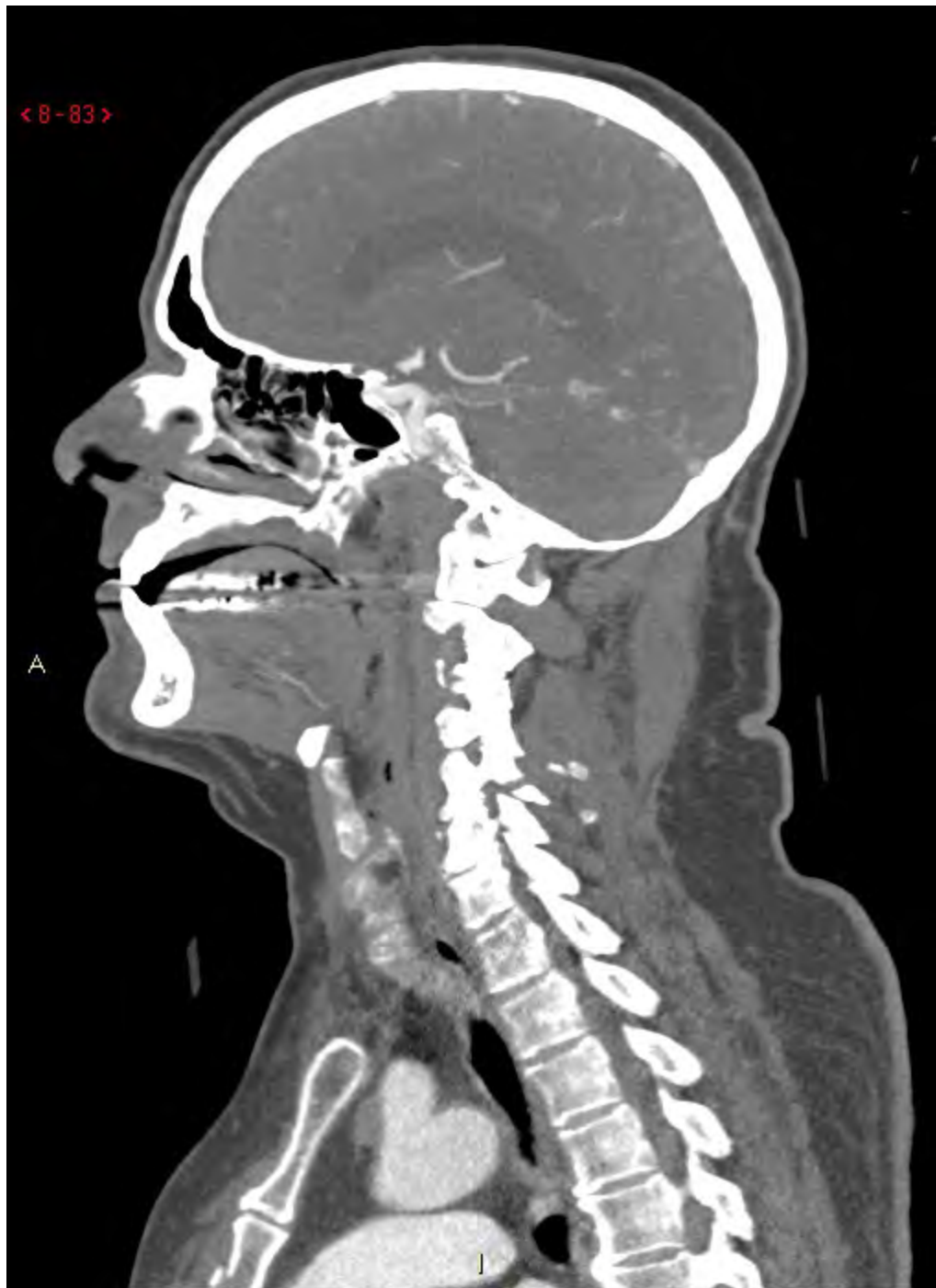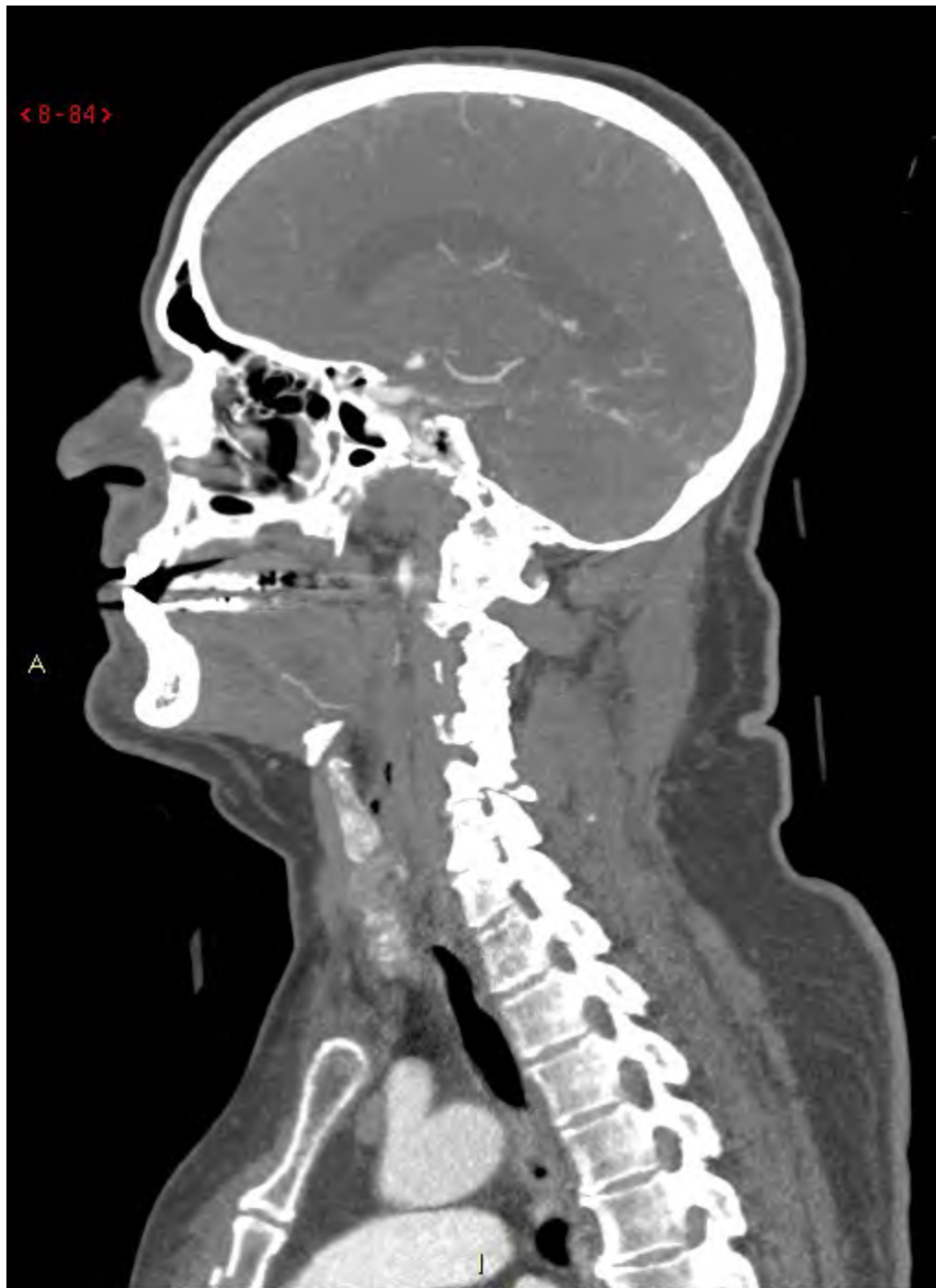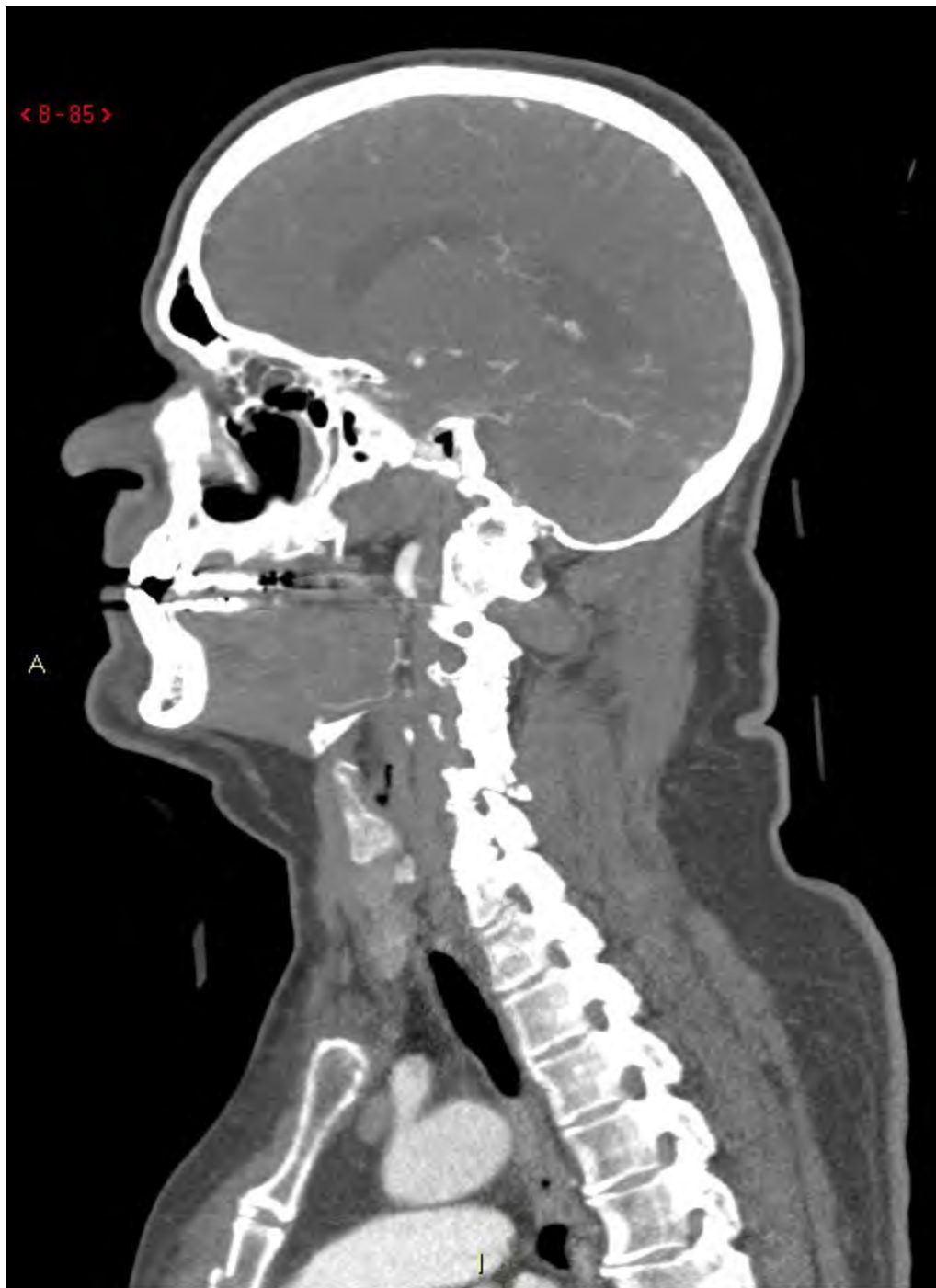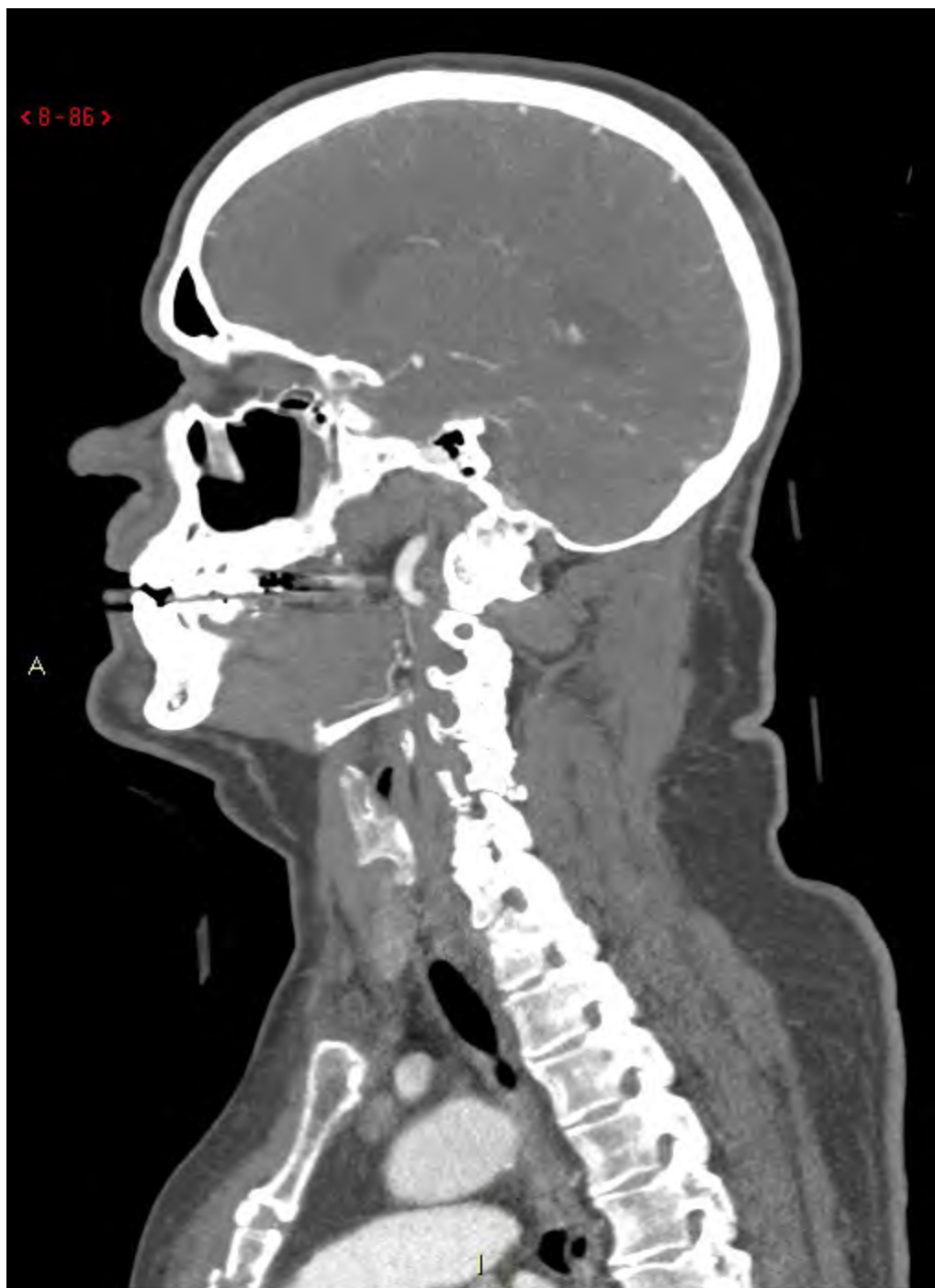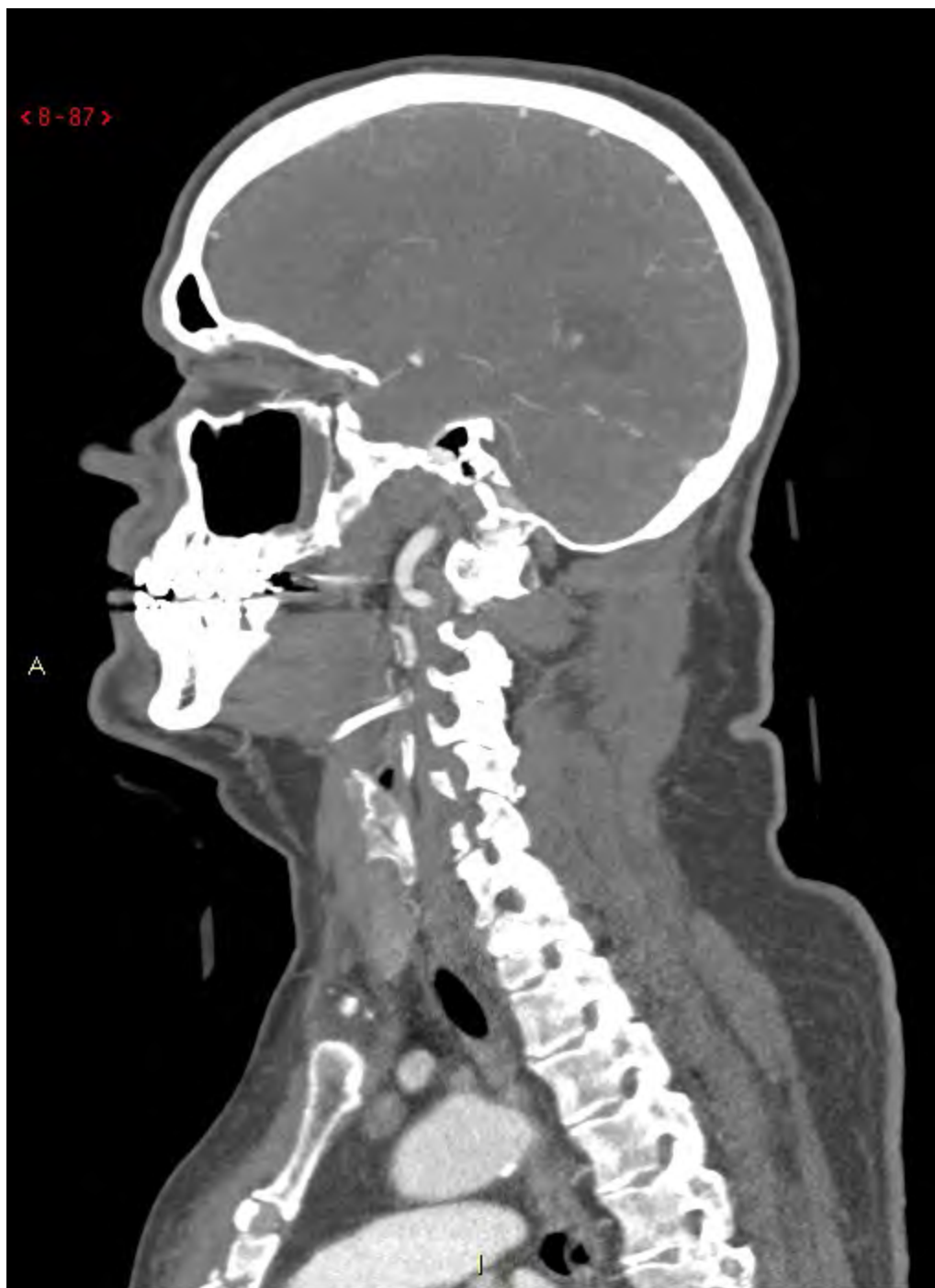




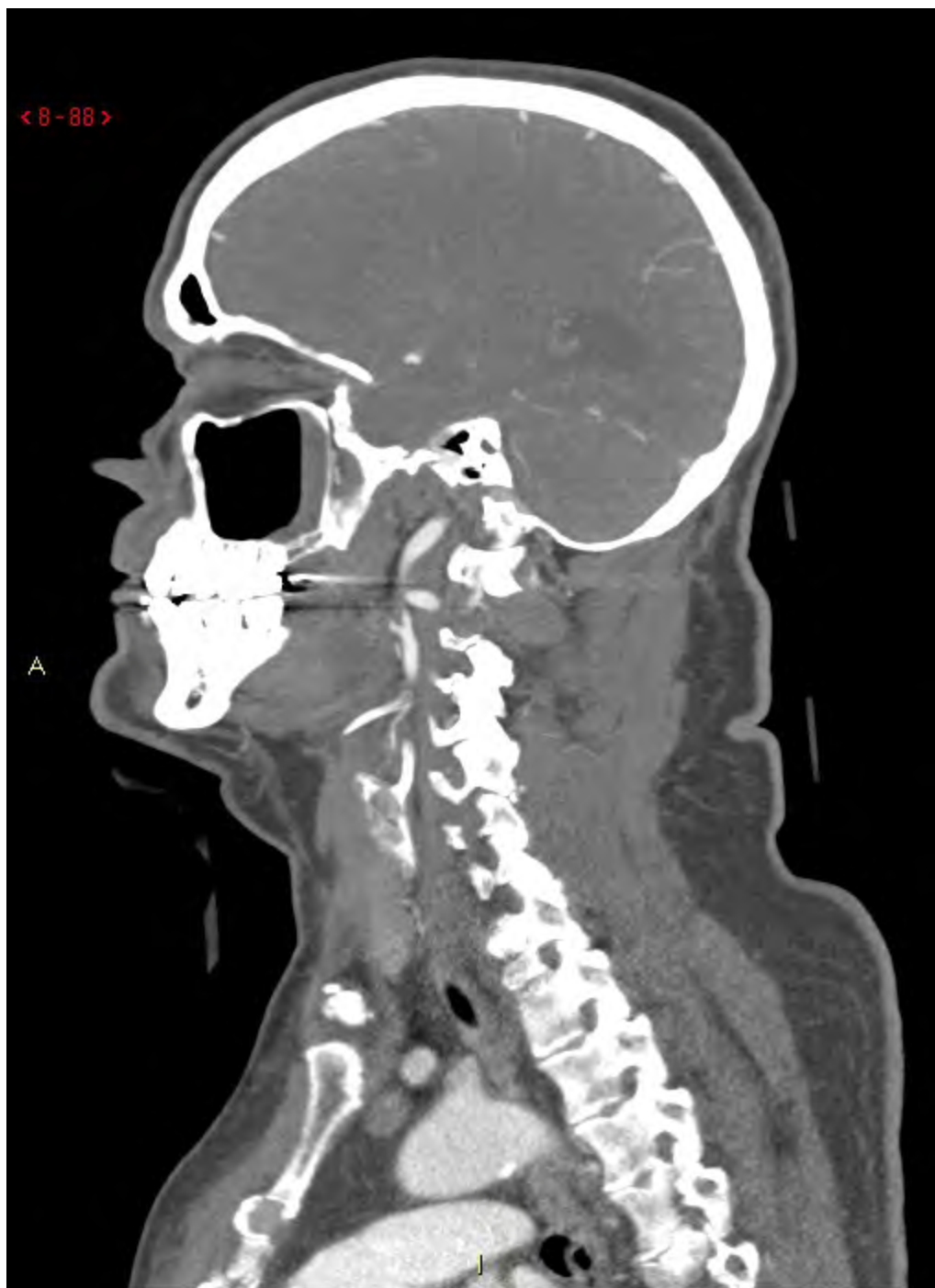




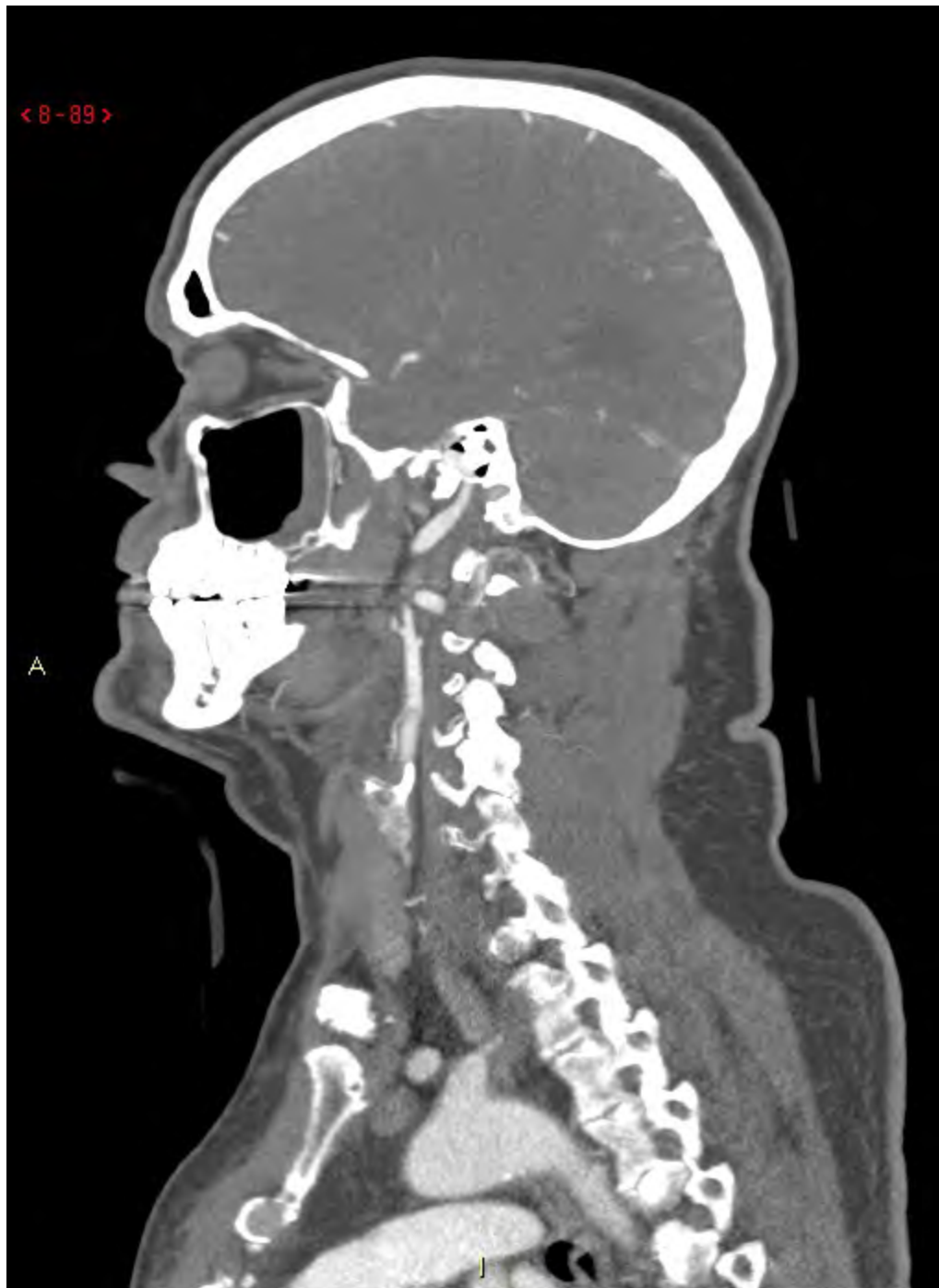








< 8-89 >

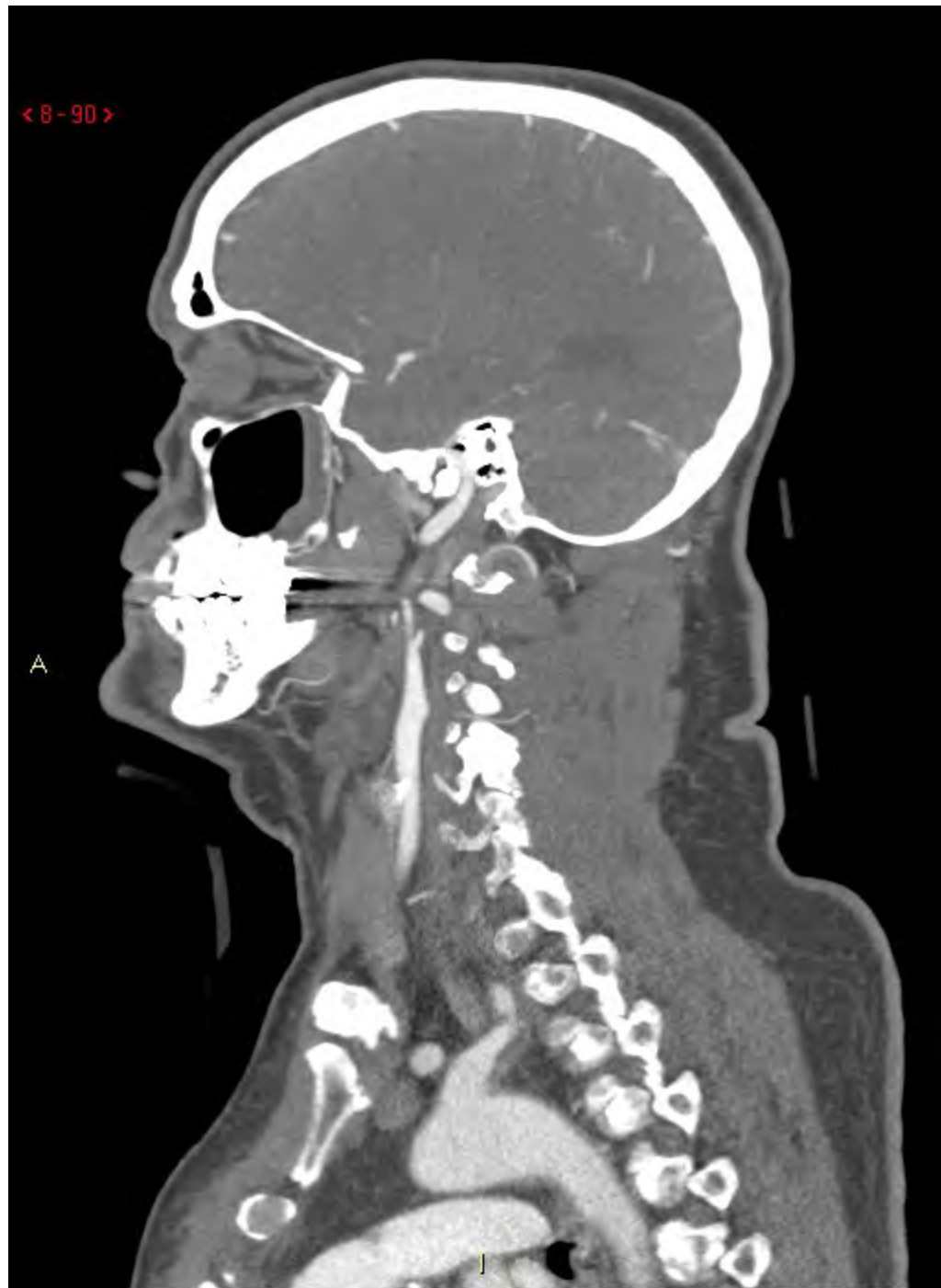


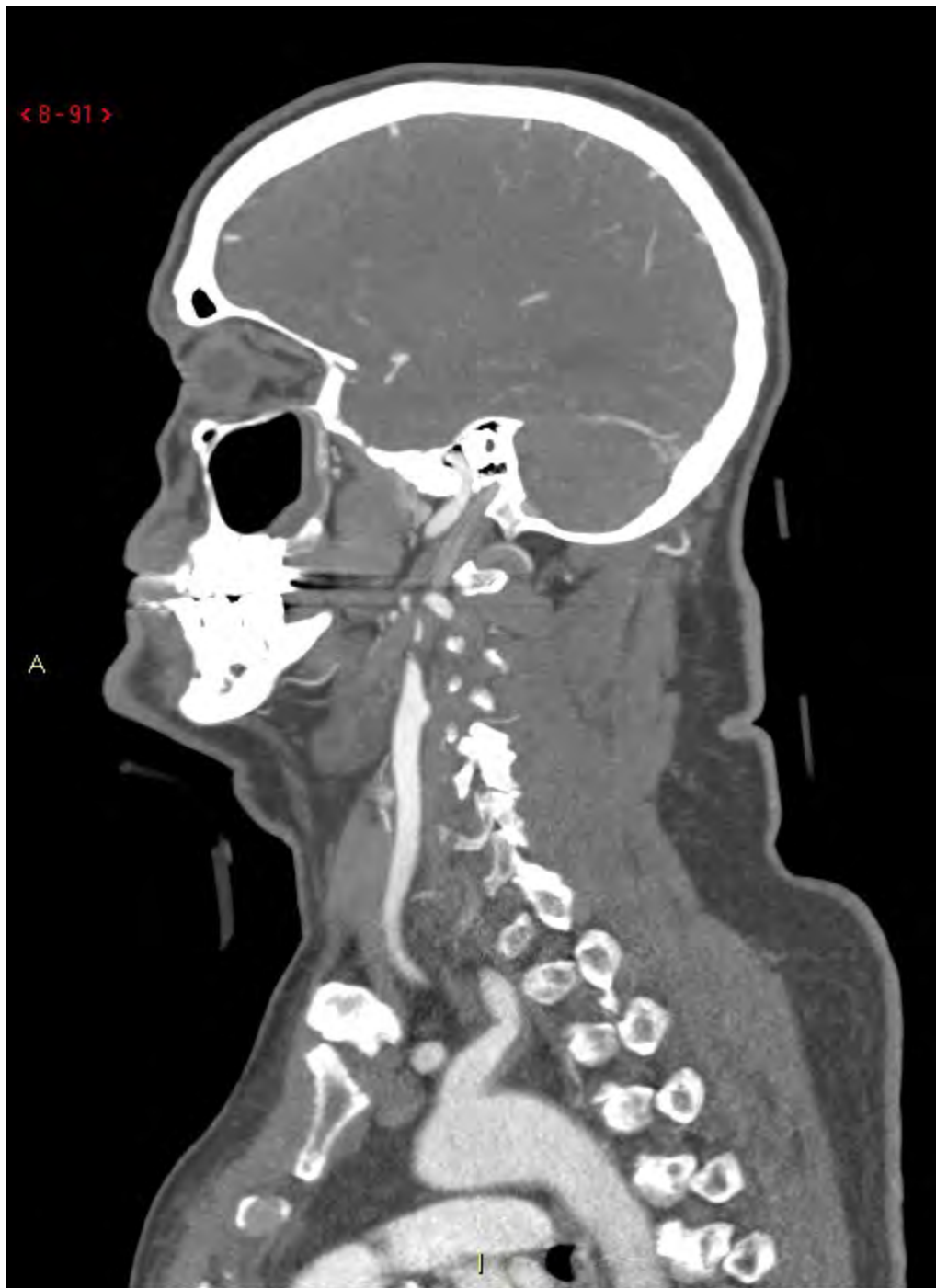
A

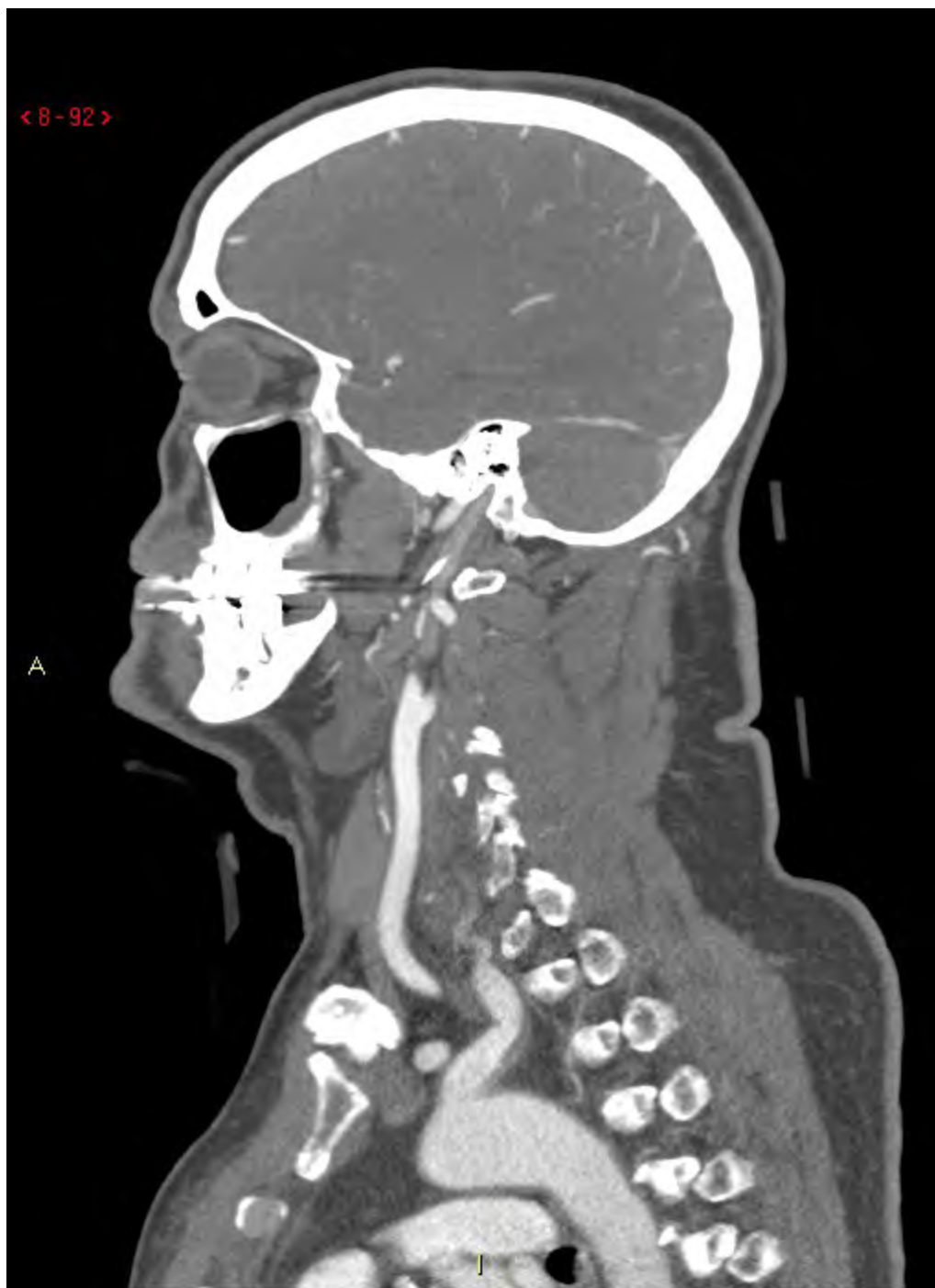
J

< 8 - 90 >

A

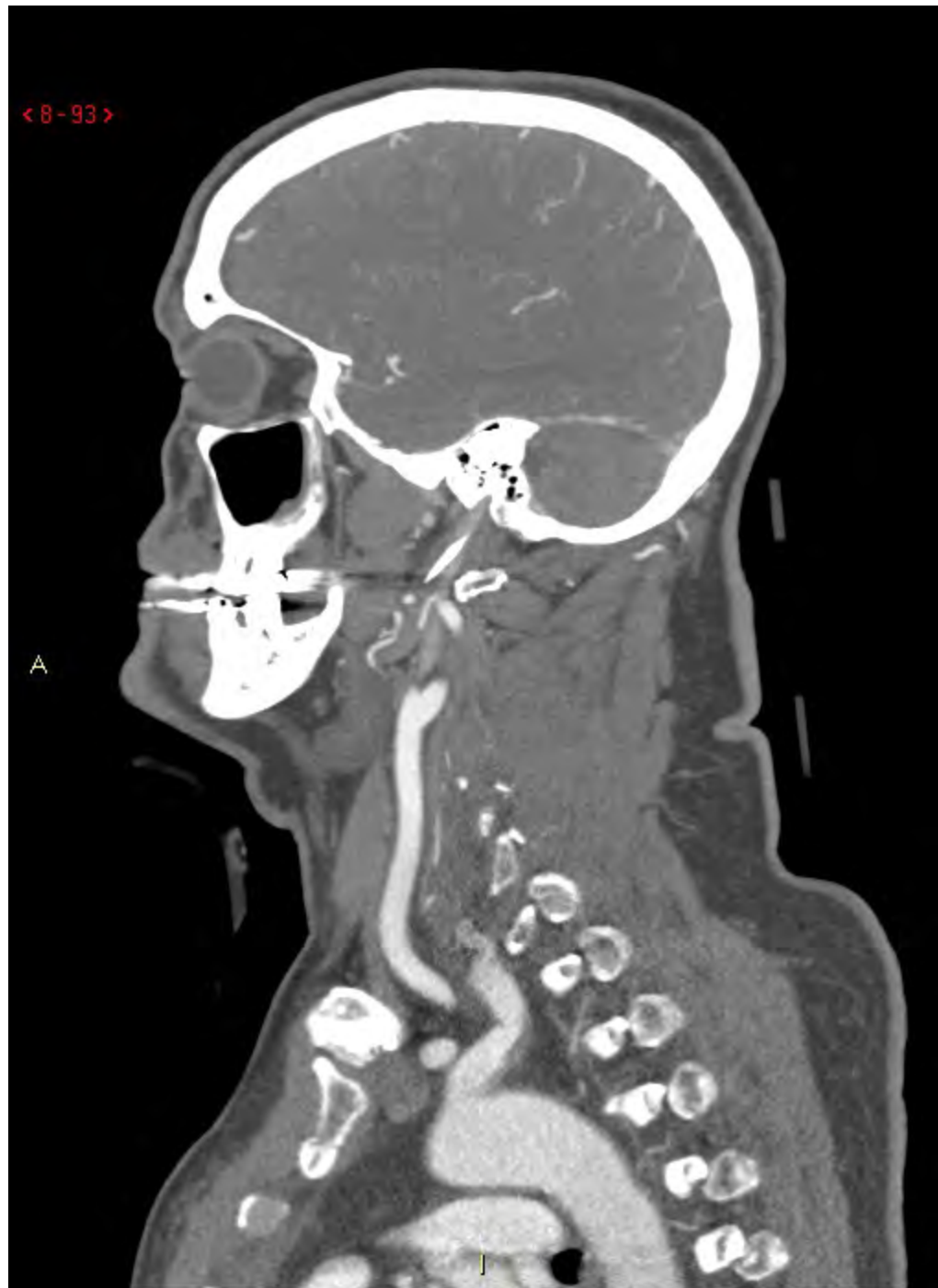






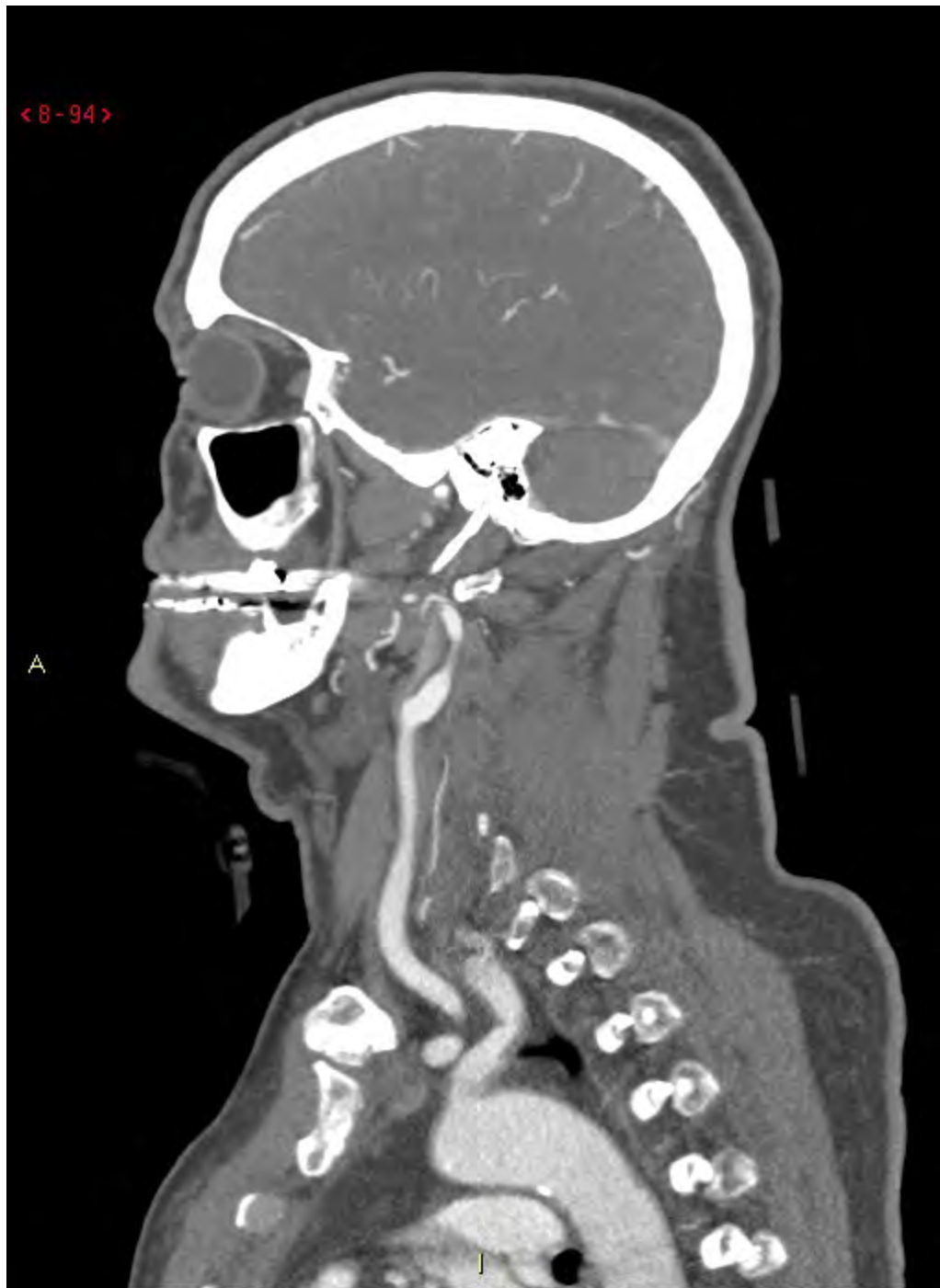
< 8-93 >

A

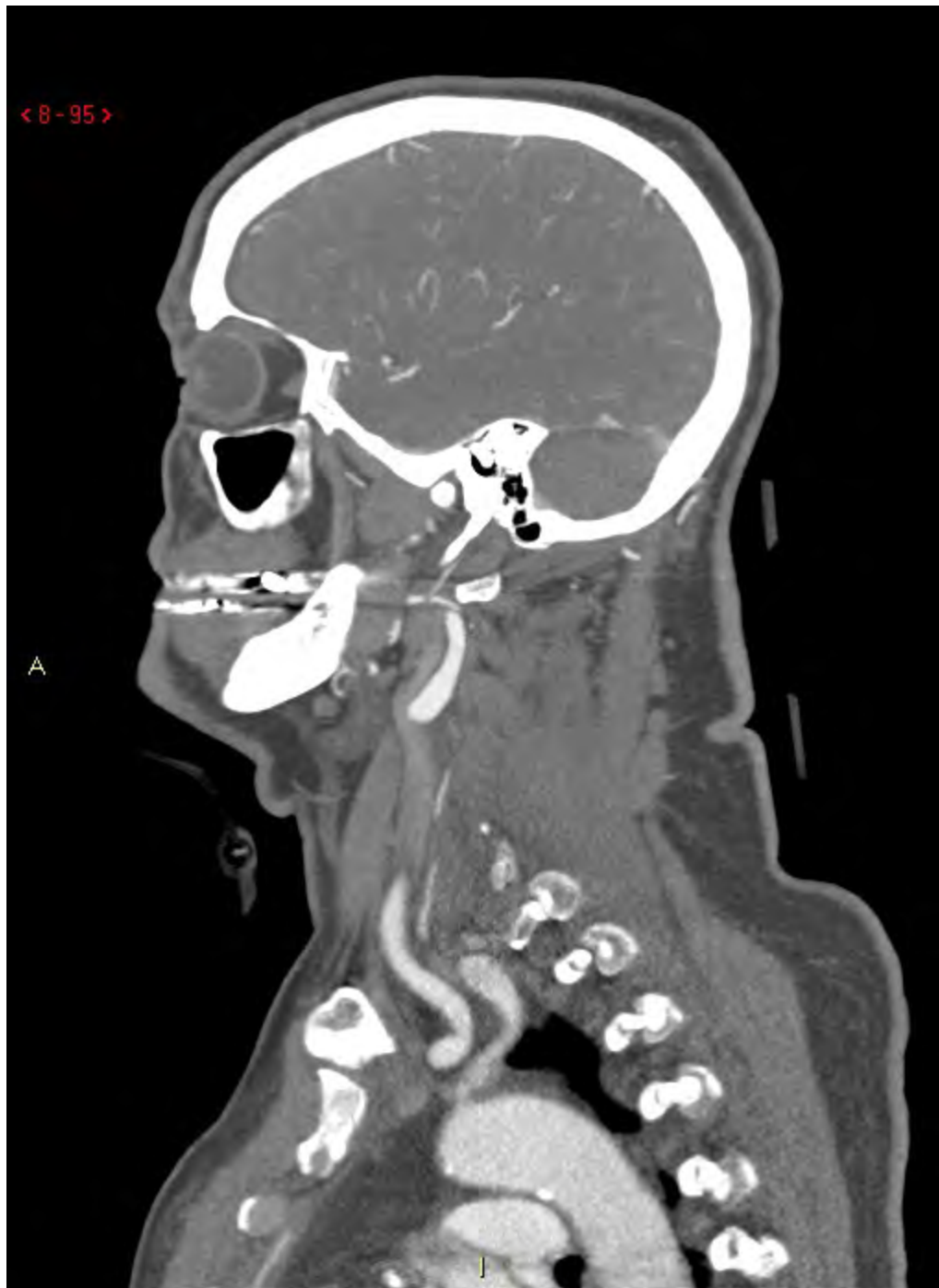


< 8-94 >

A







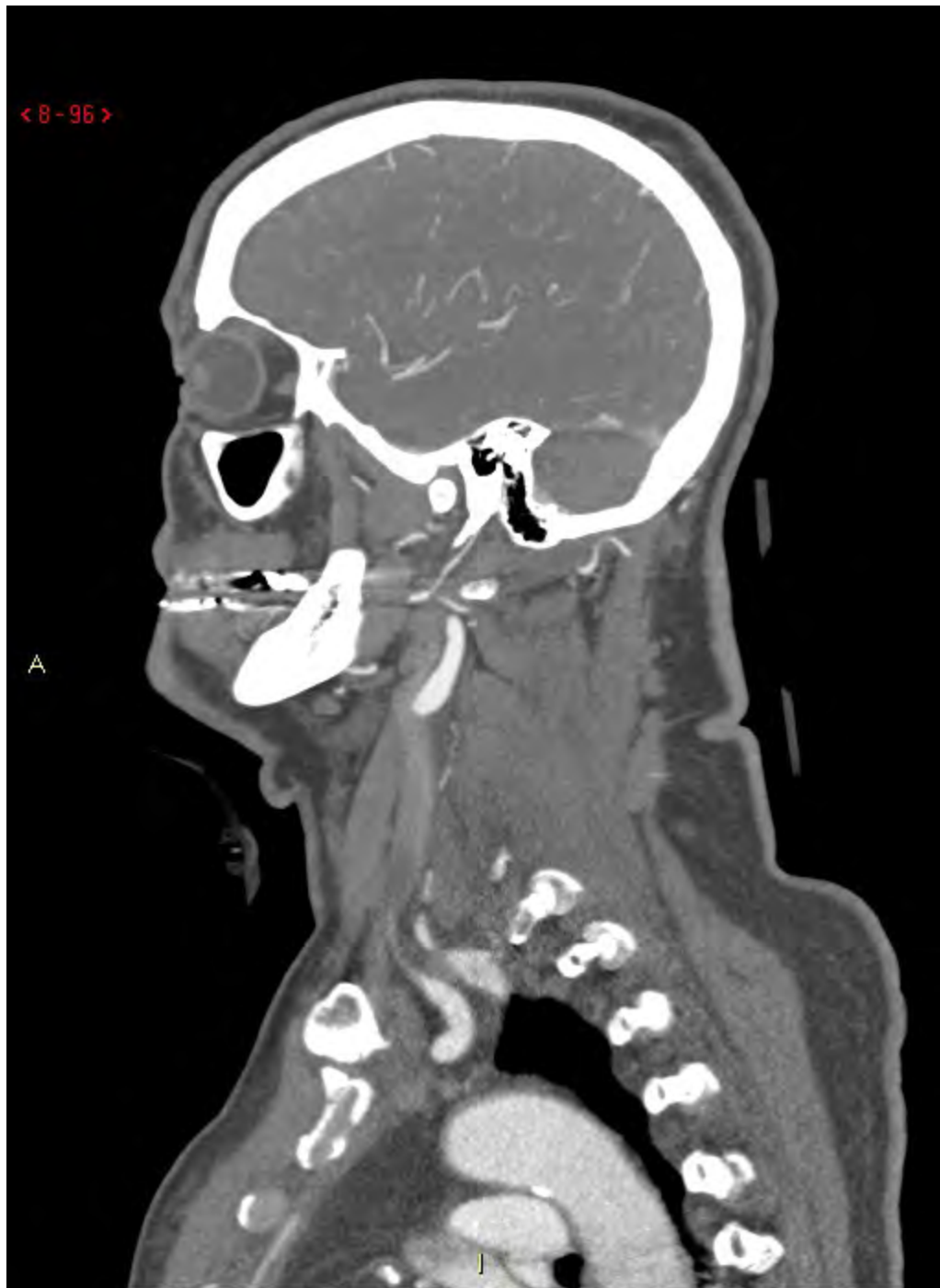< 8 - 95 >

A



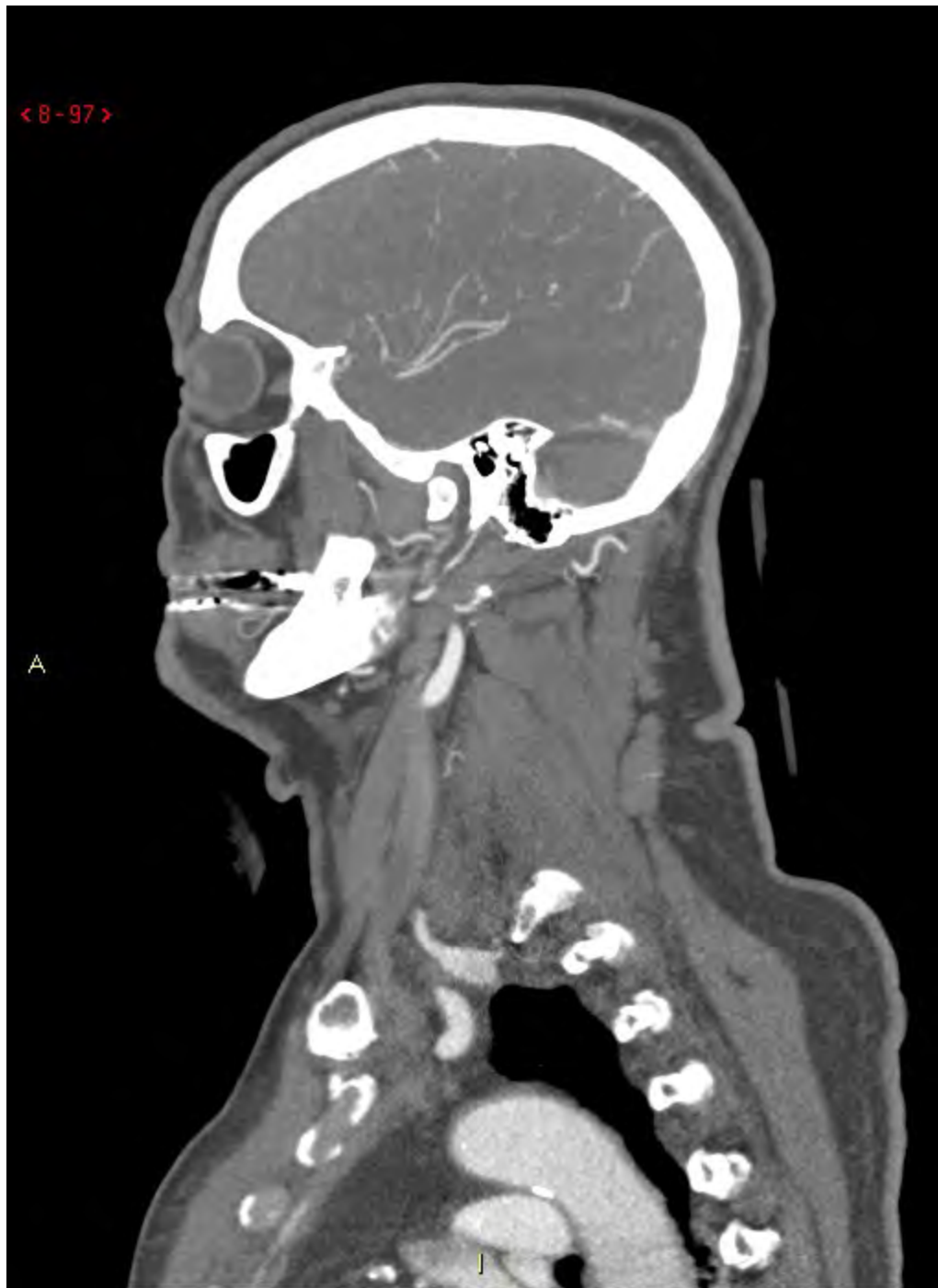
< 8 - 96 >

A



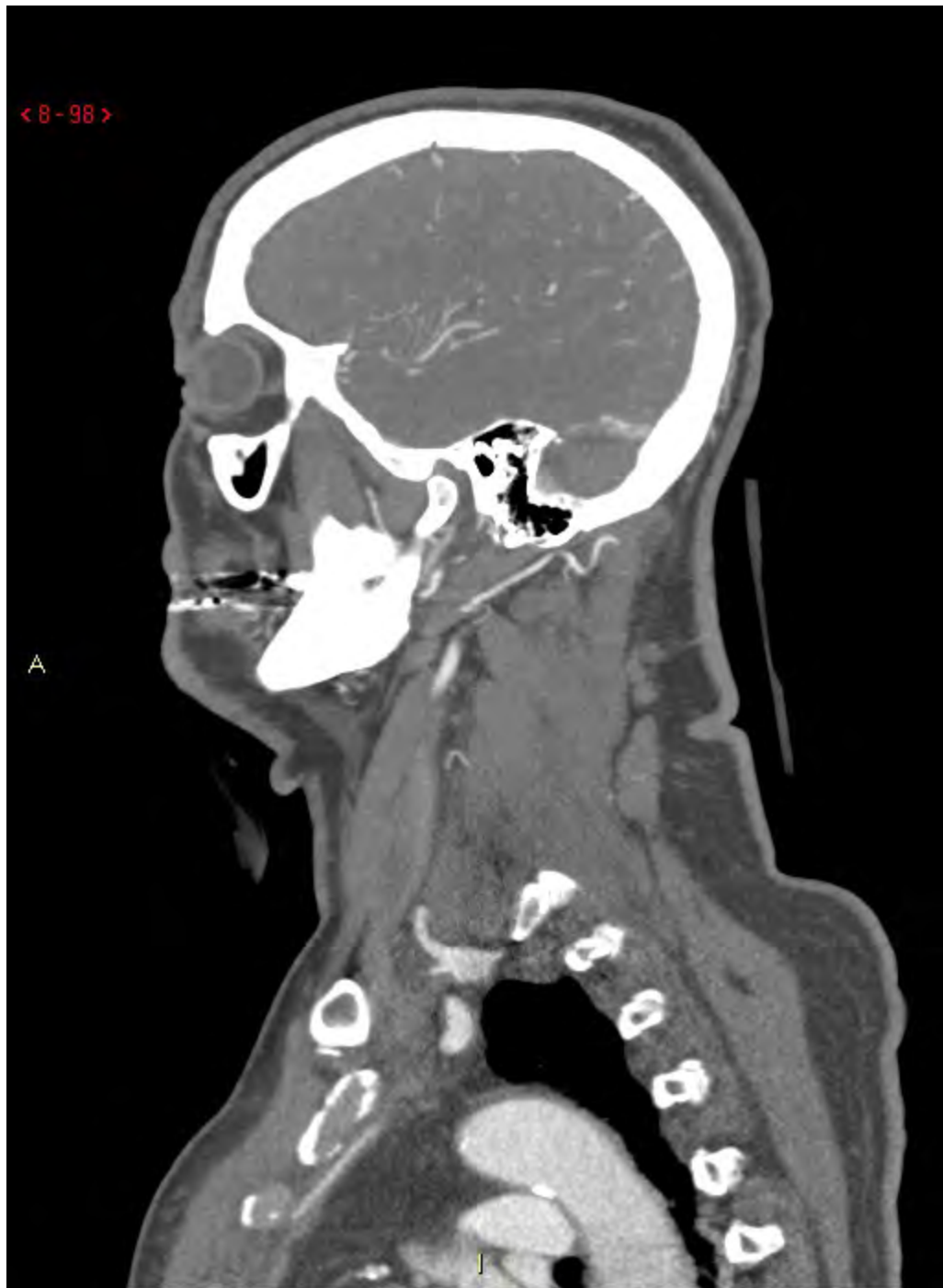< 8 - 97 >

A



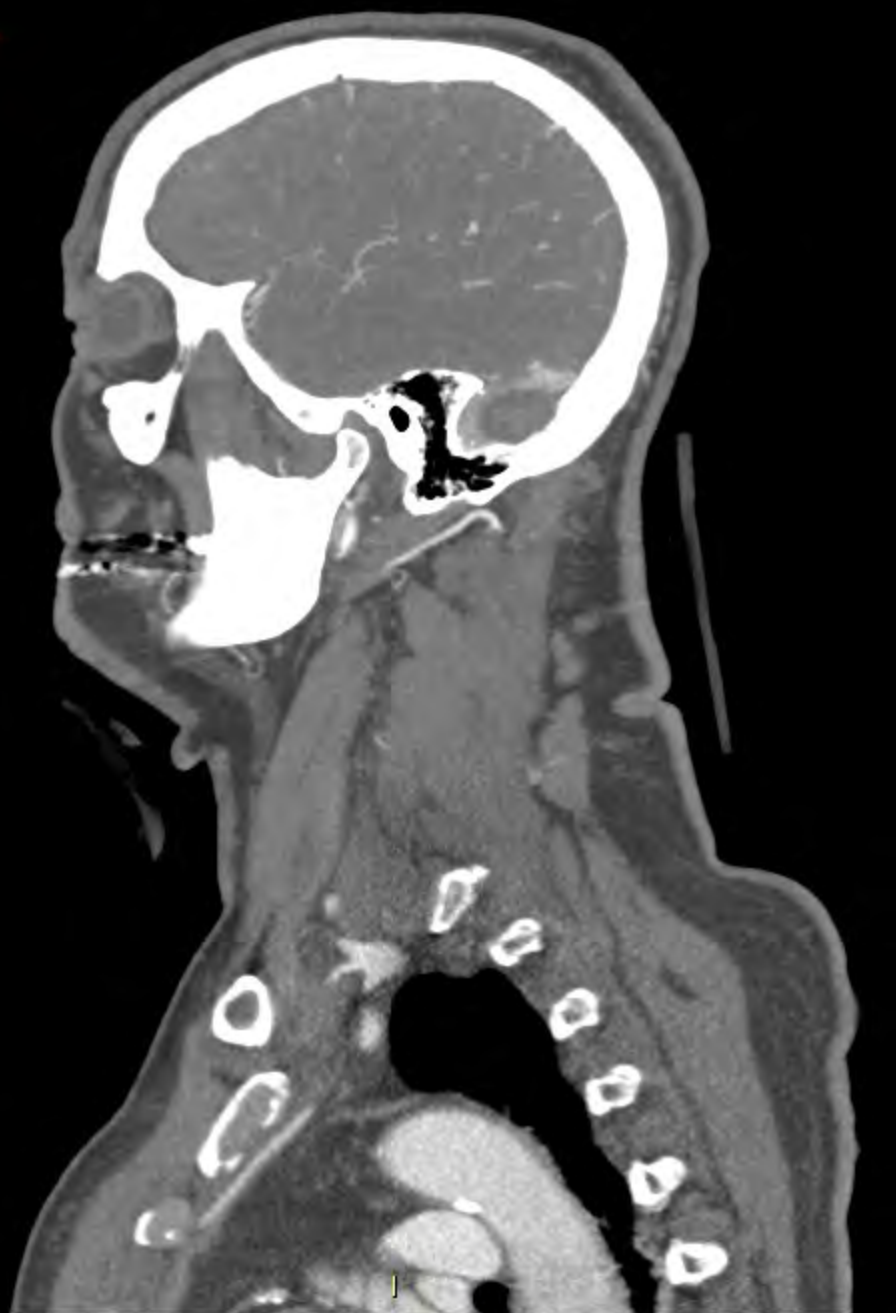< 8 - 98 >

A



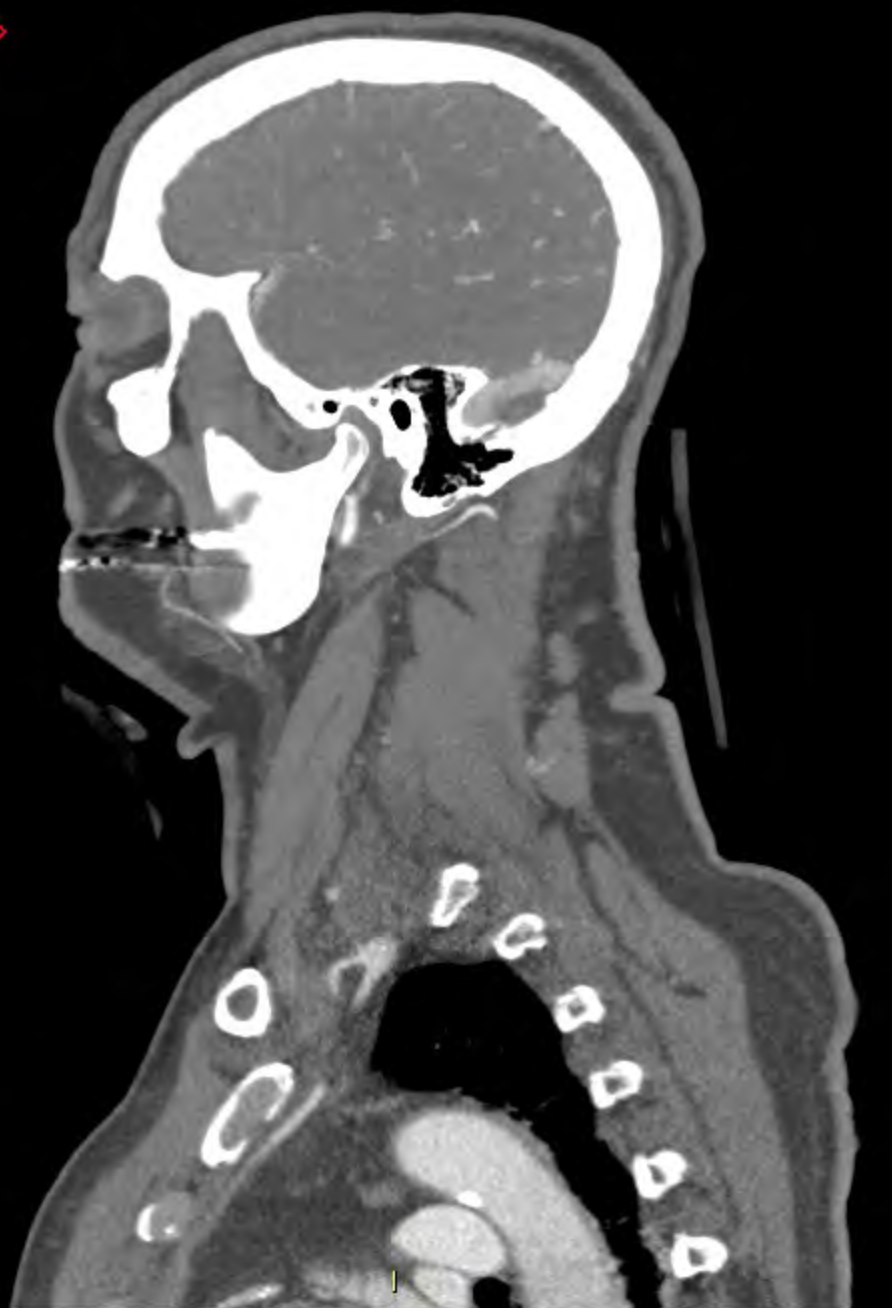< 8 - 99 >

A



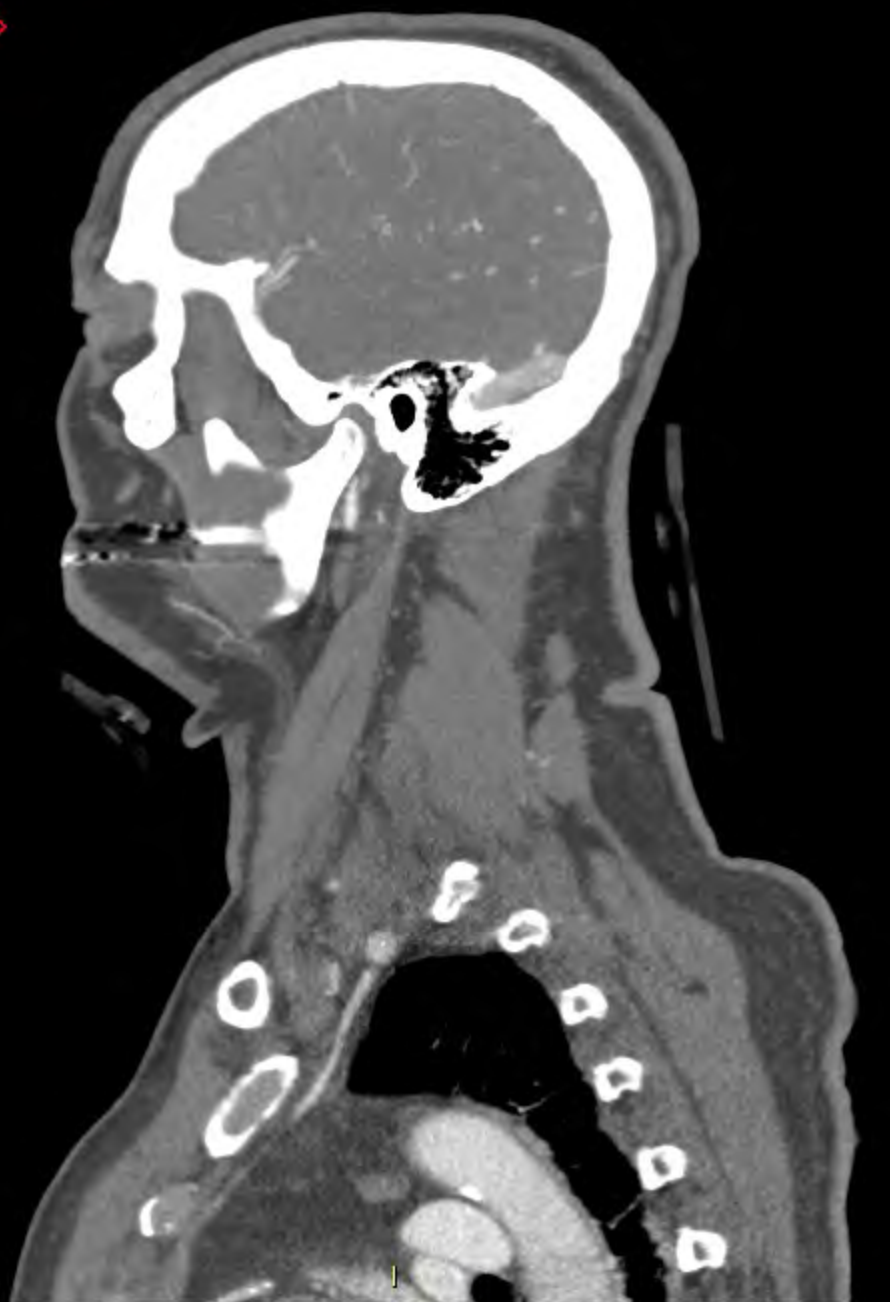< 8-100 >

A



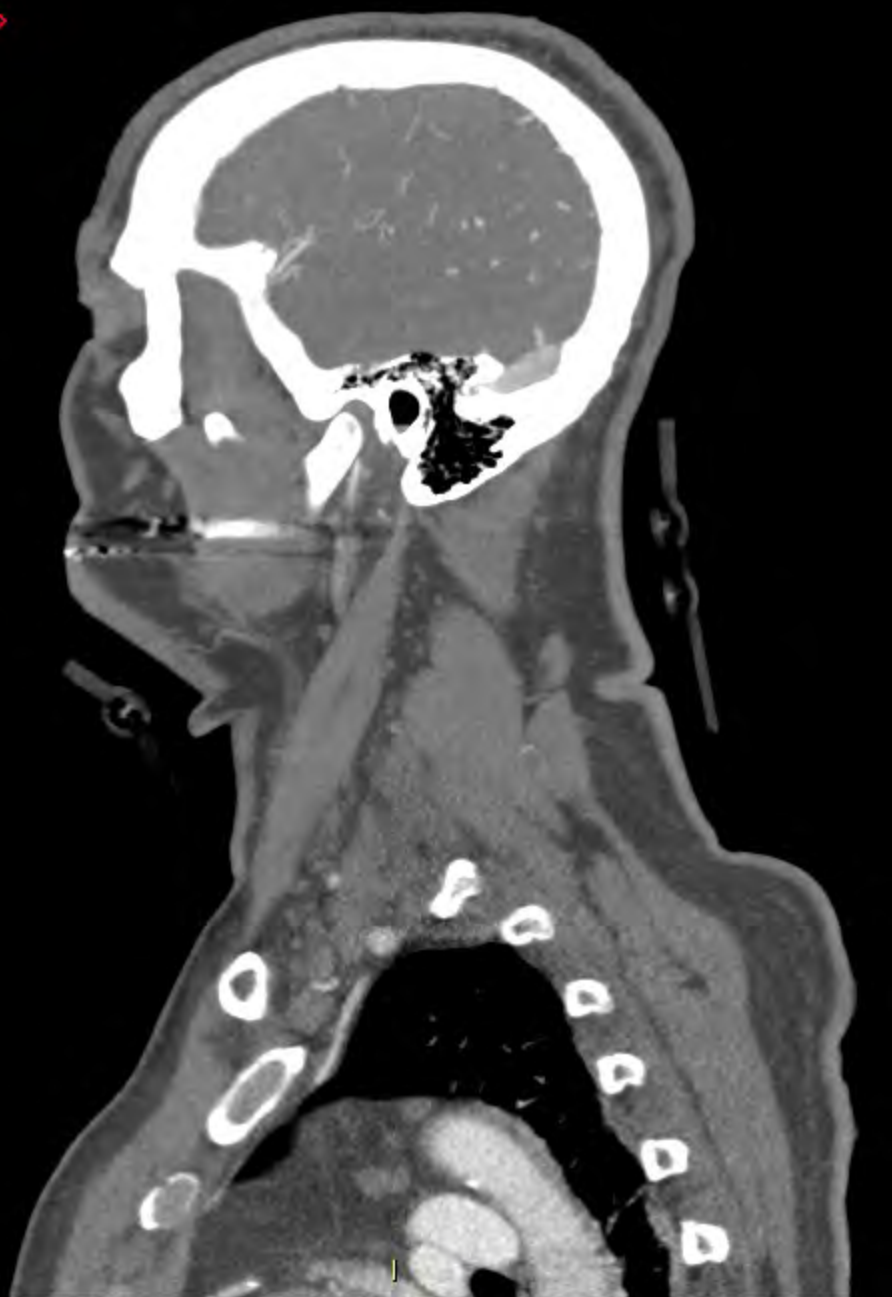
< 8-101 >

A



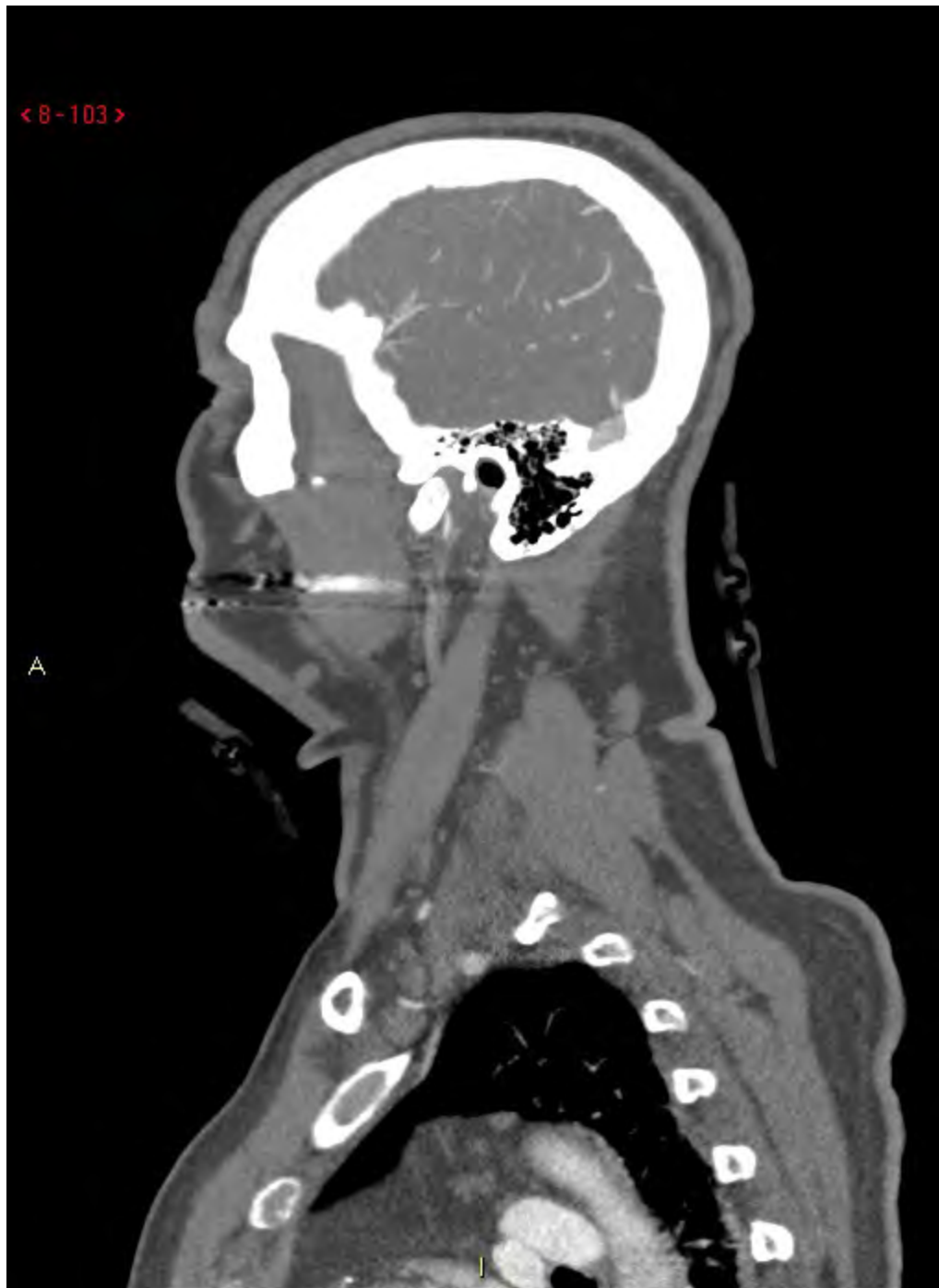< 8-102 >

A





< 8-103 >

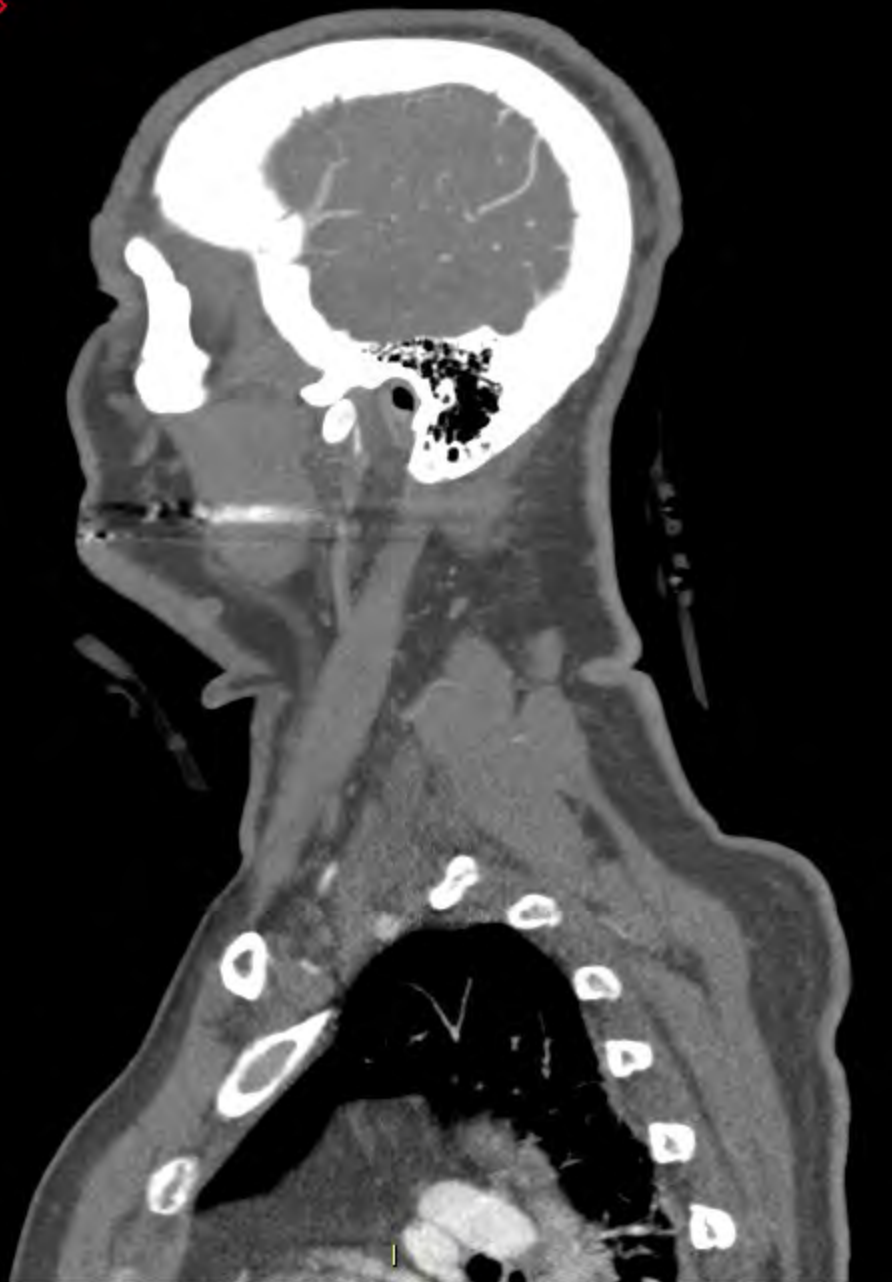

A



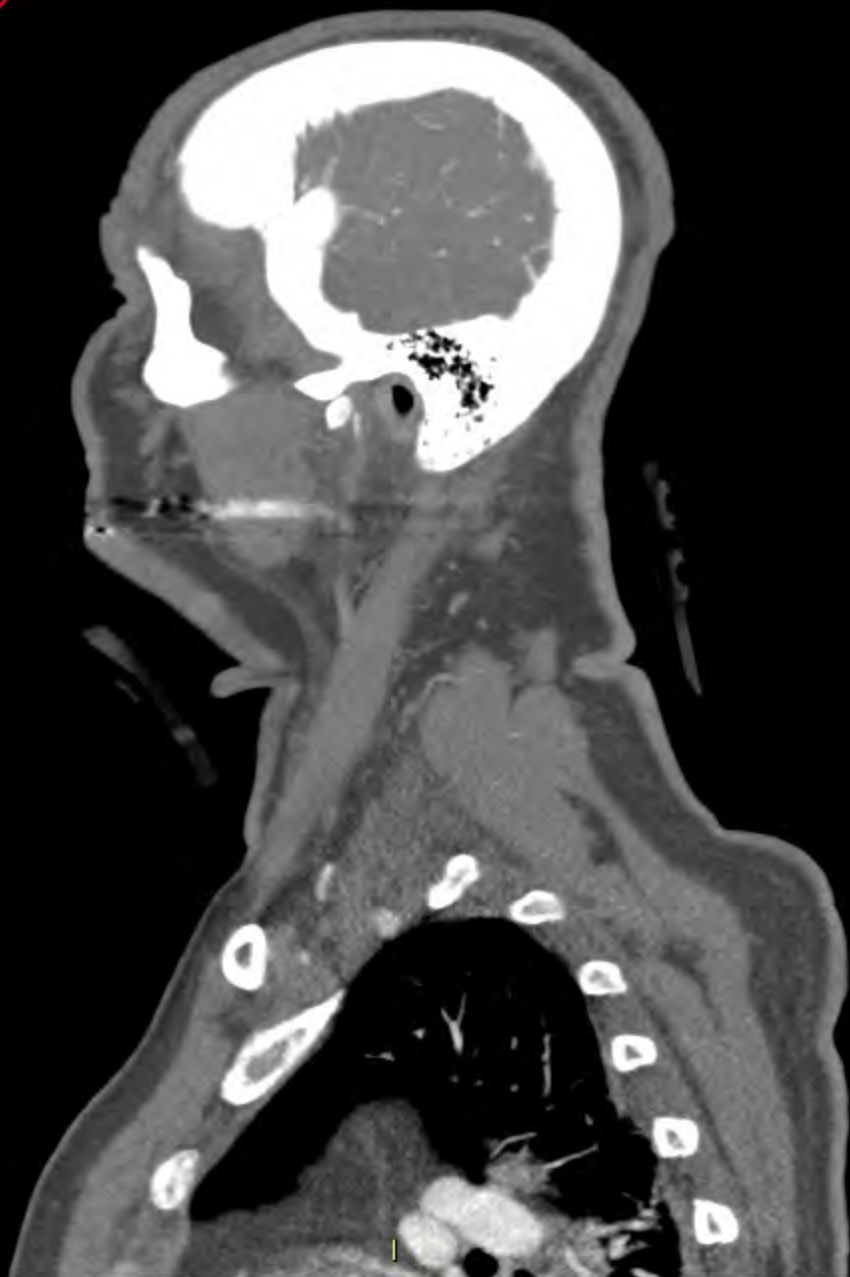< 8-104 >

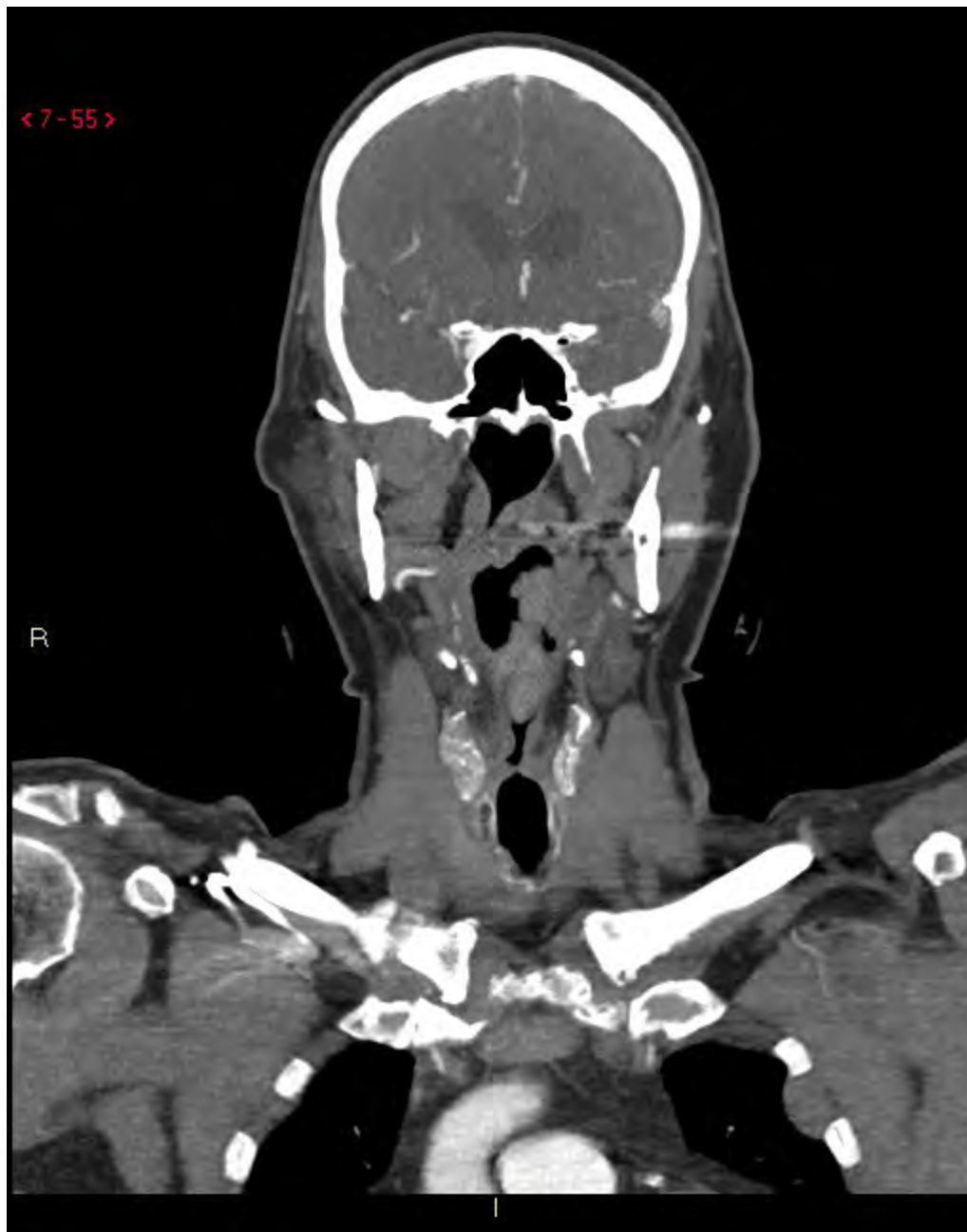A

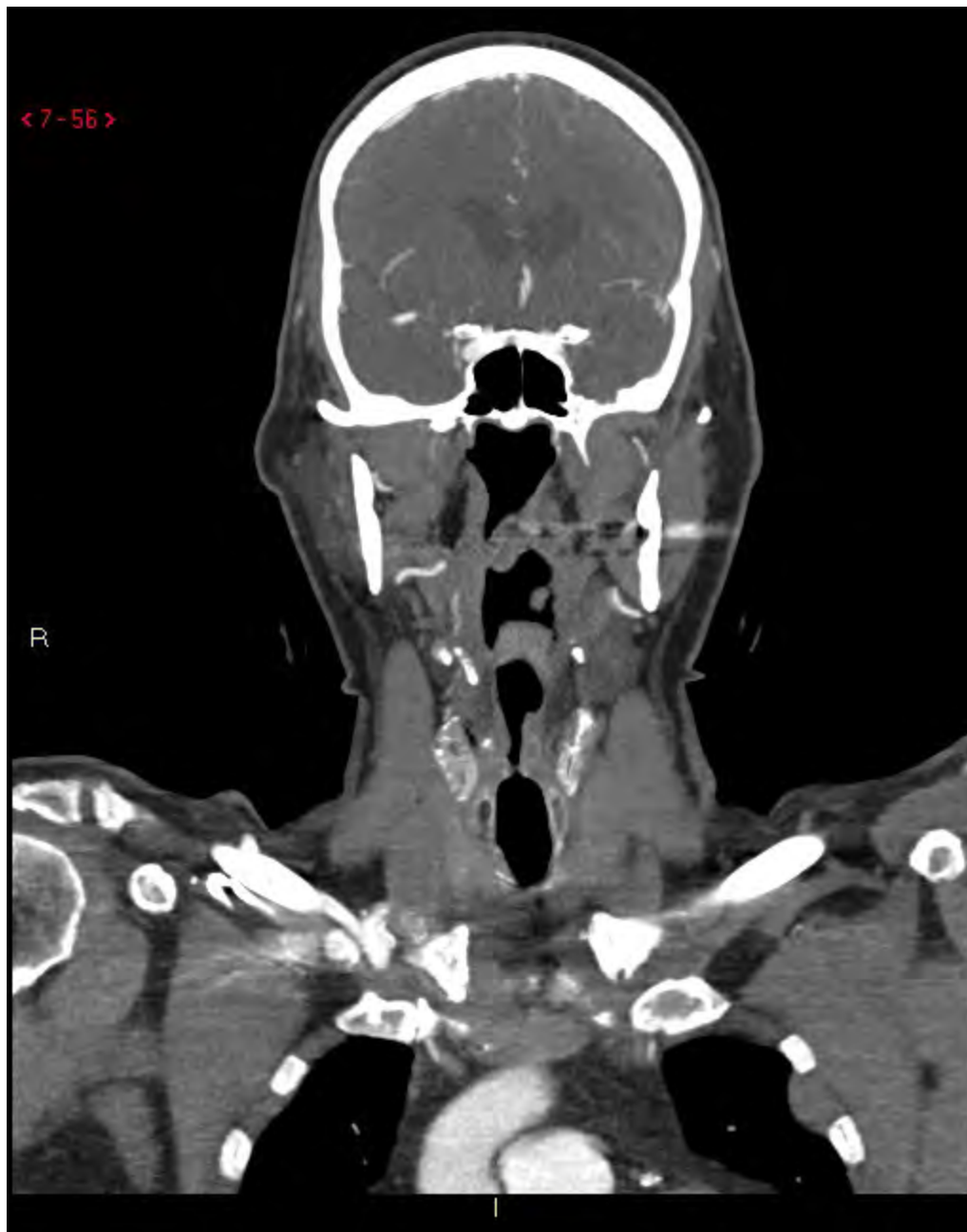

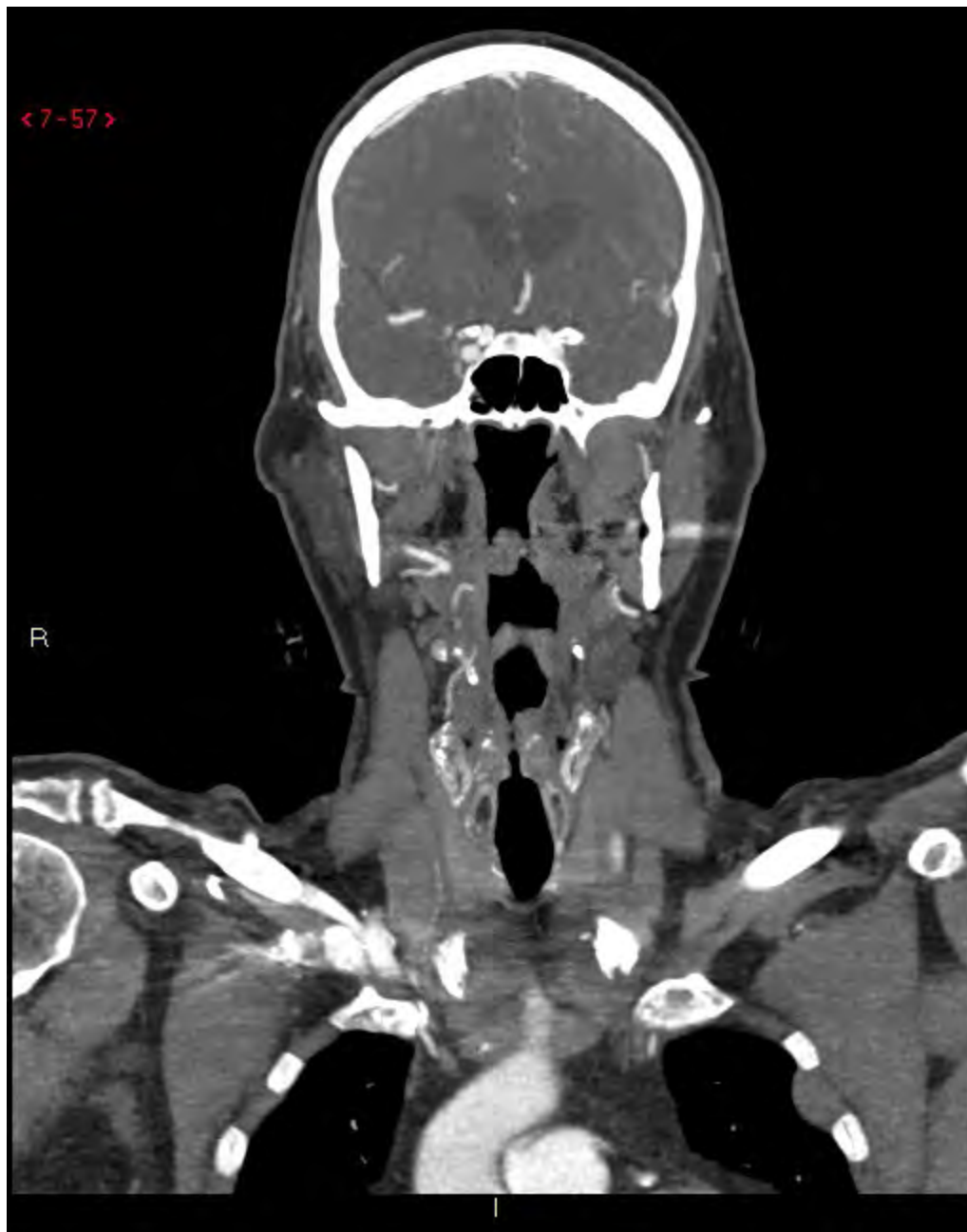< 8-105 >

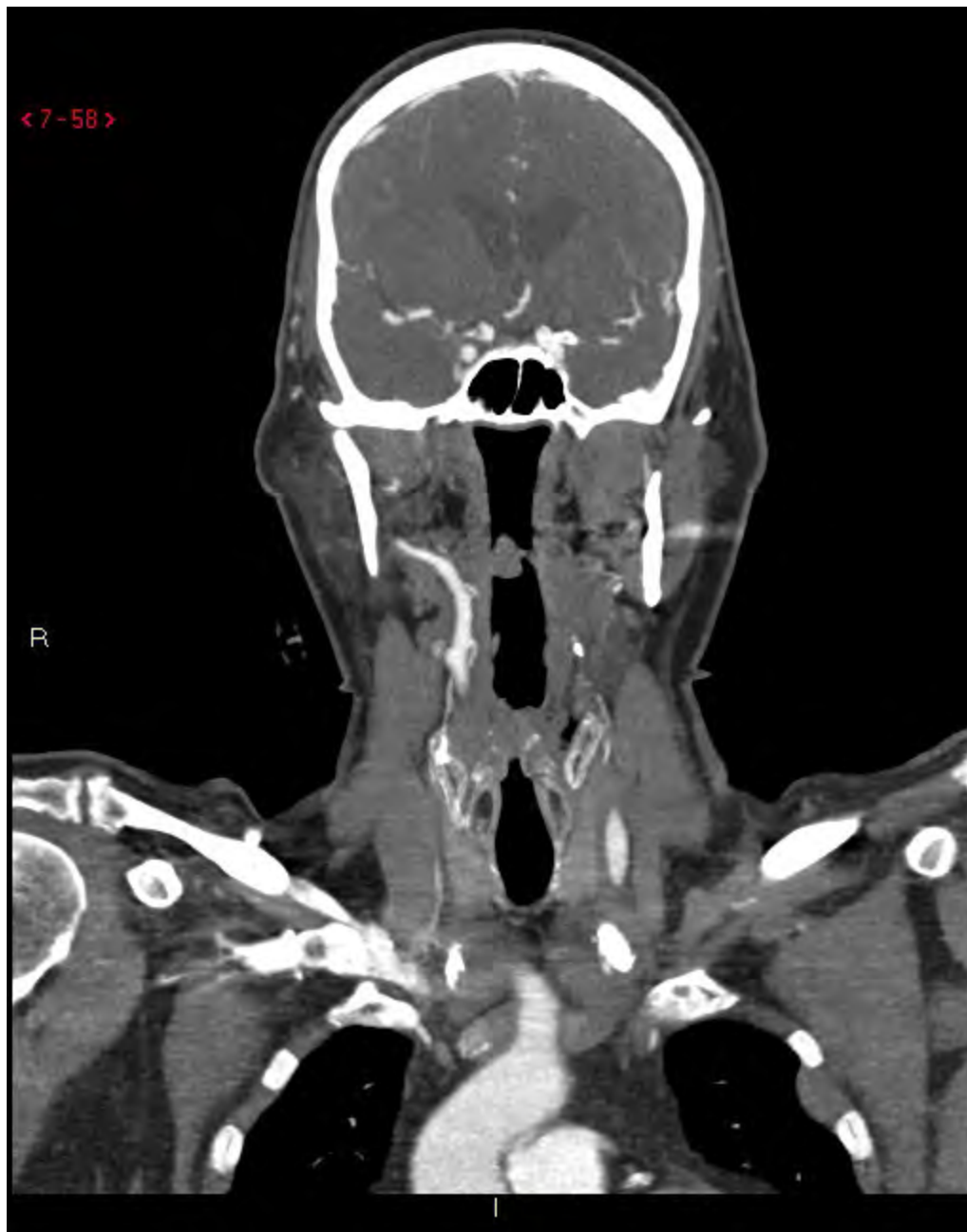A

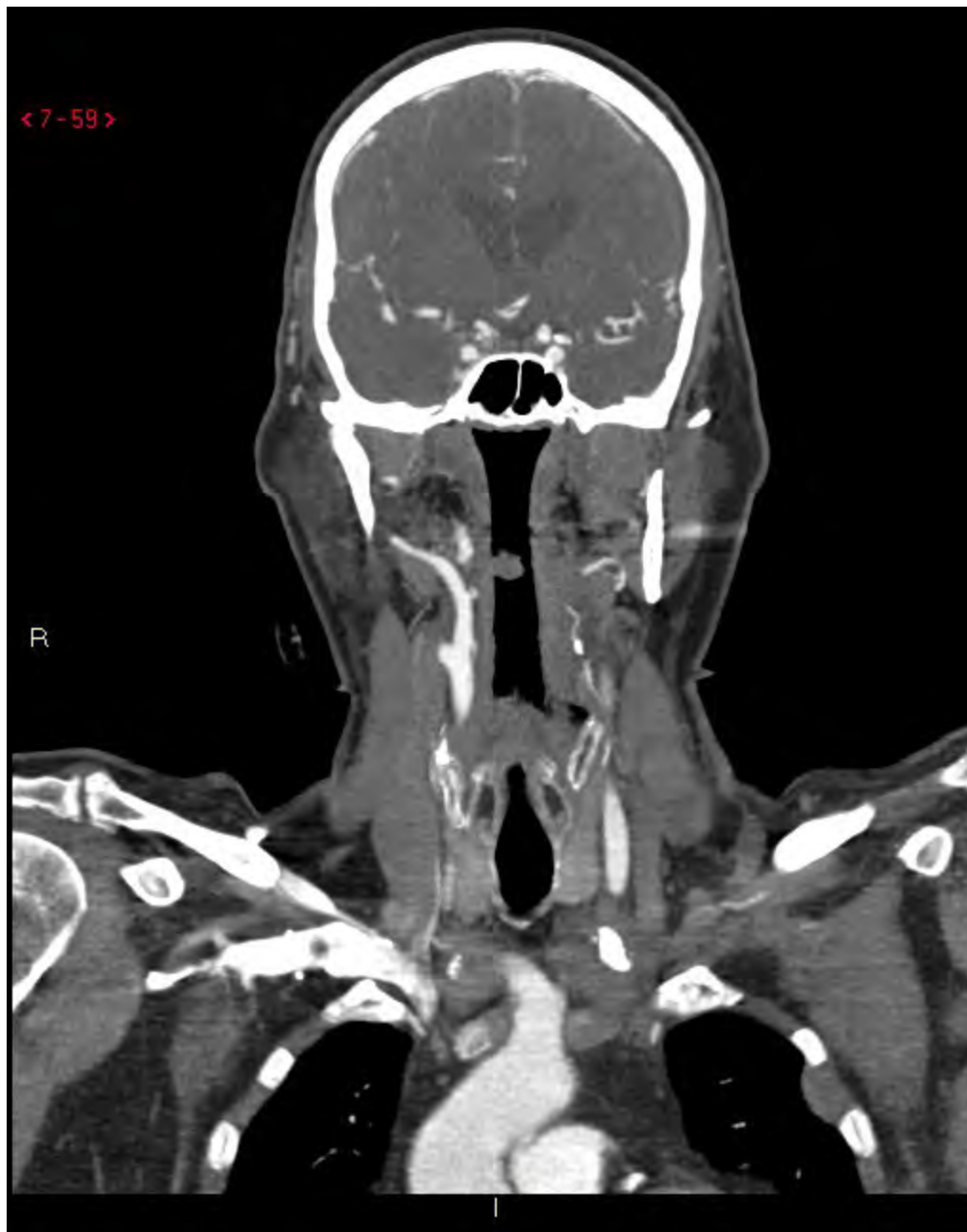




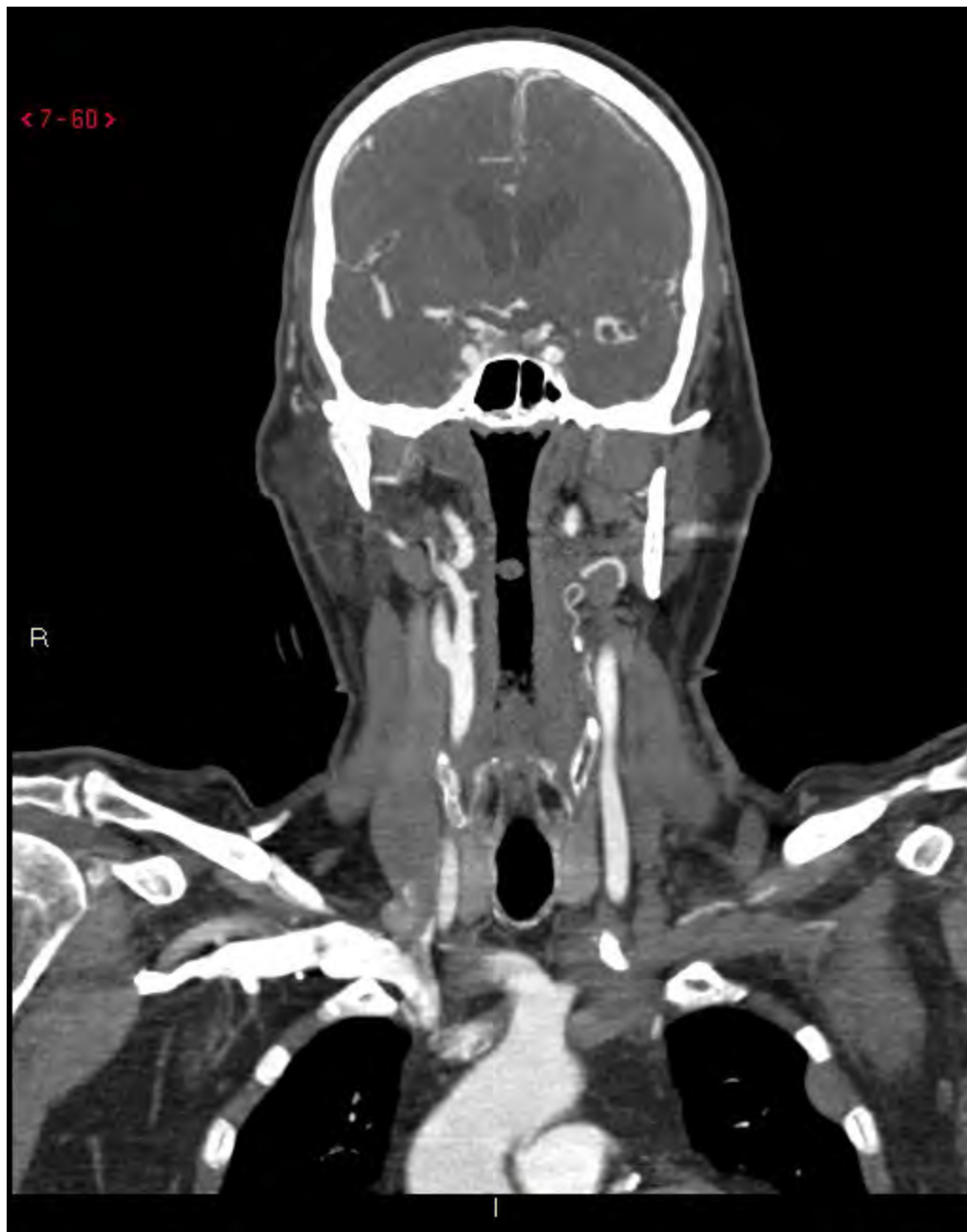


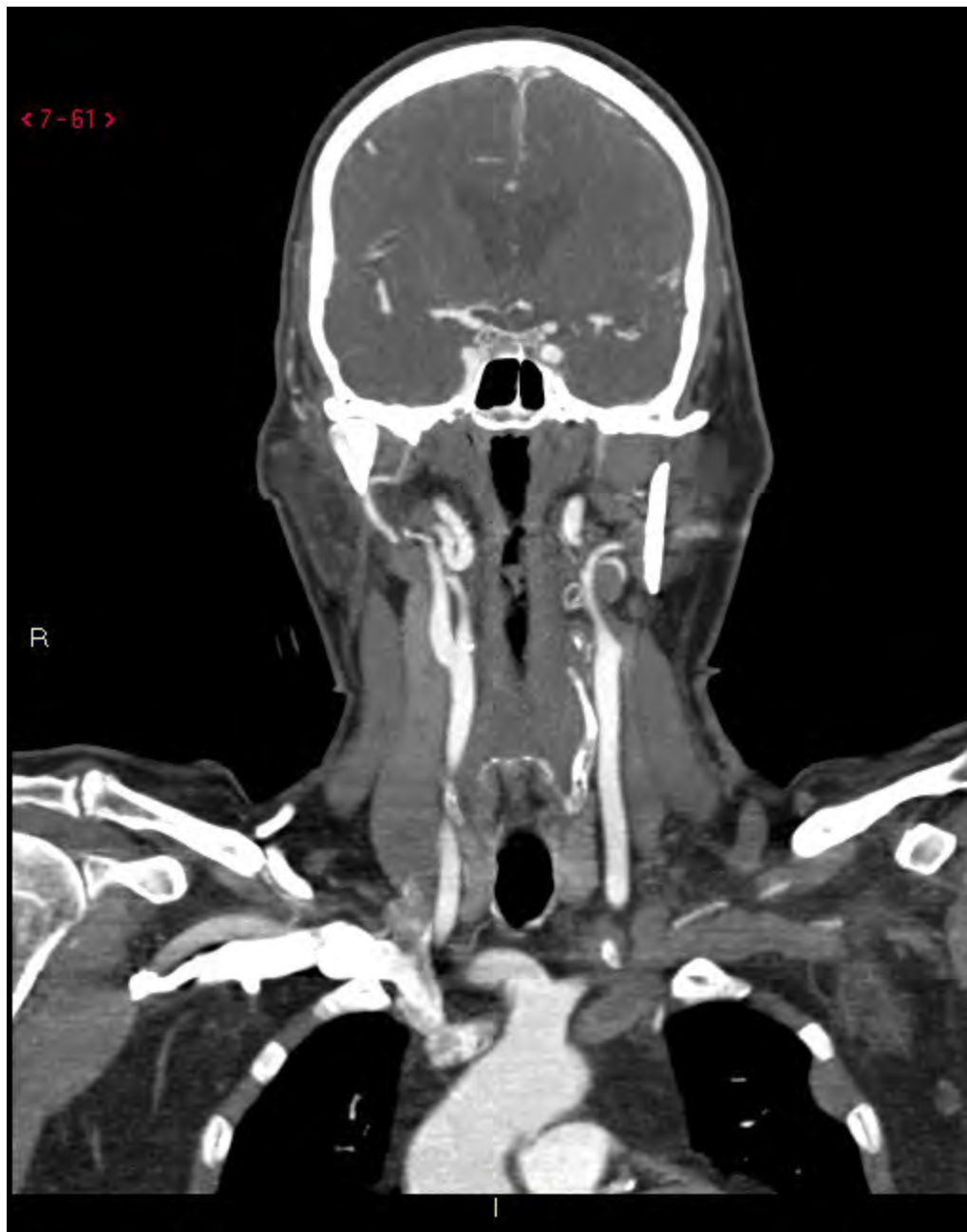


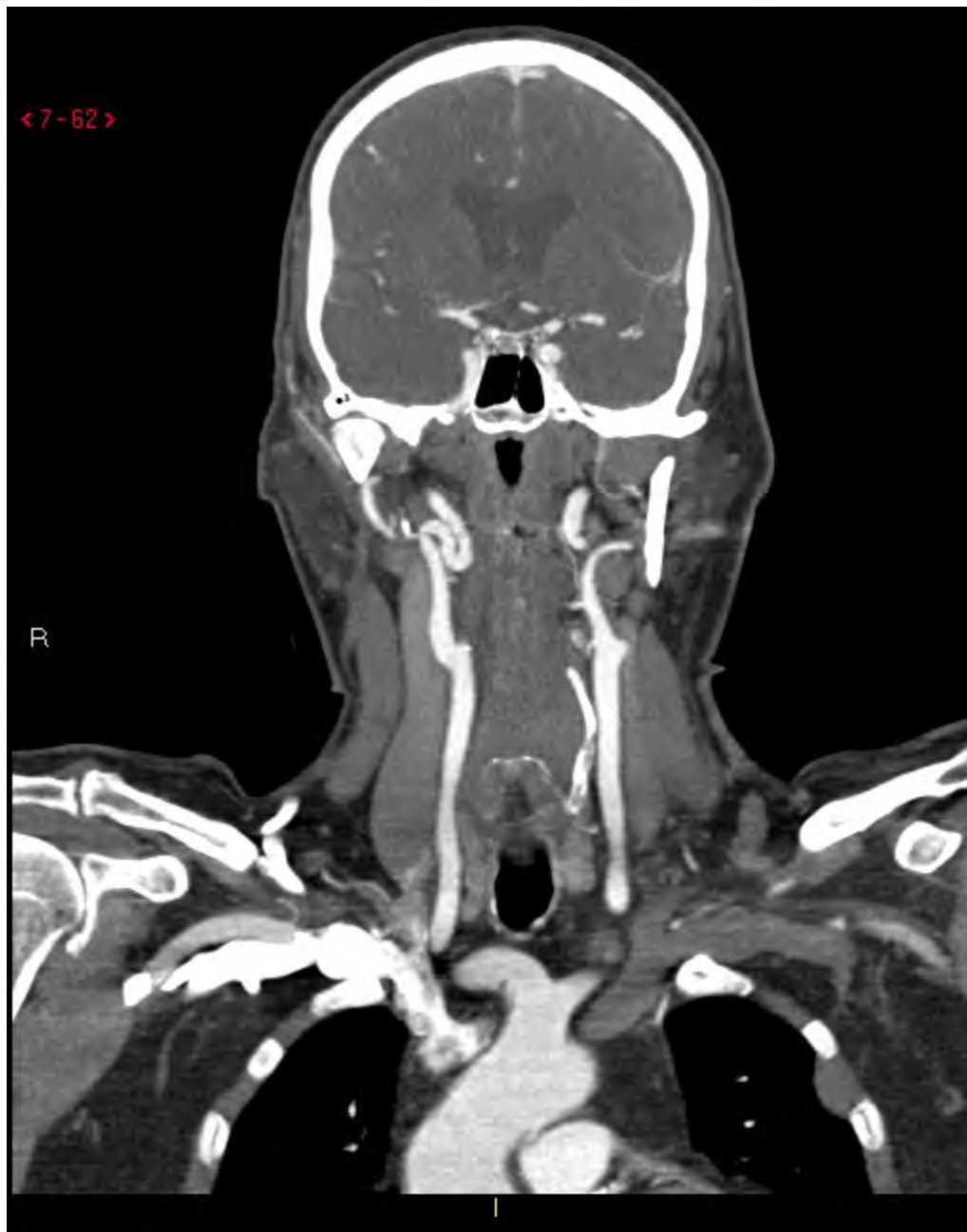


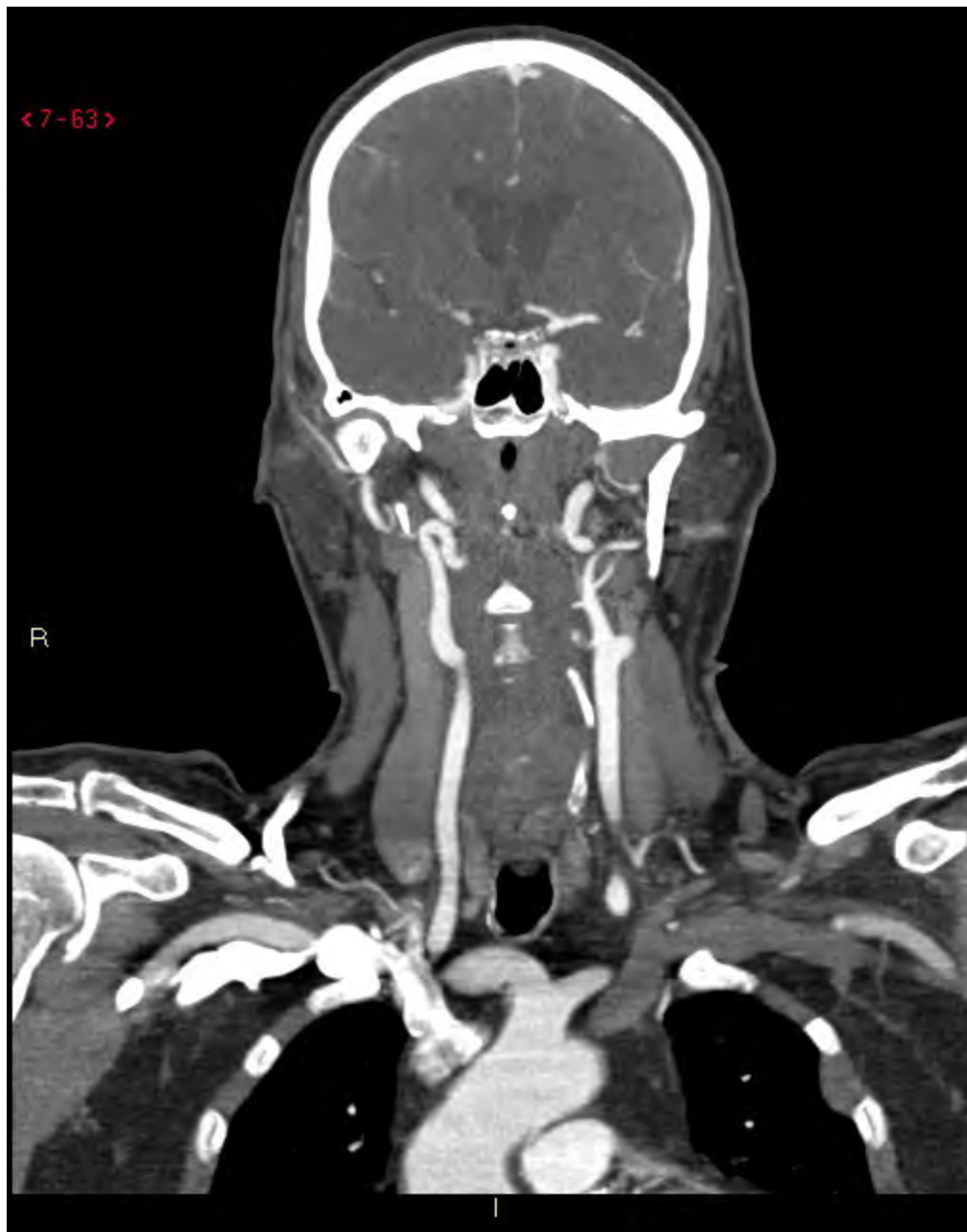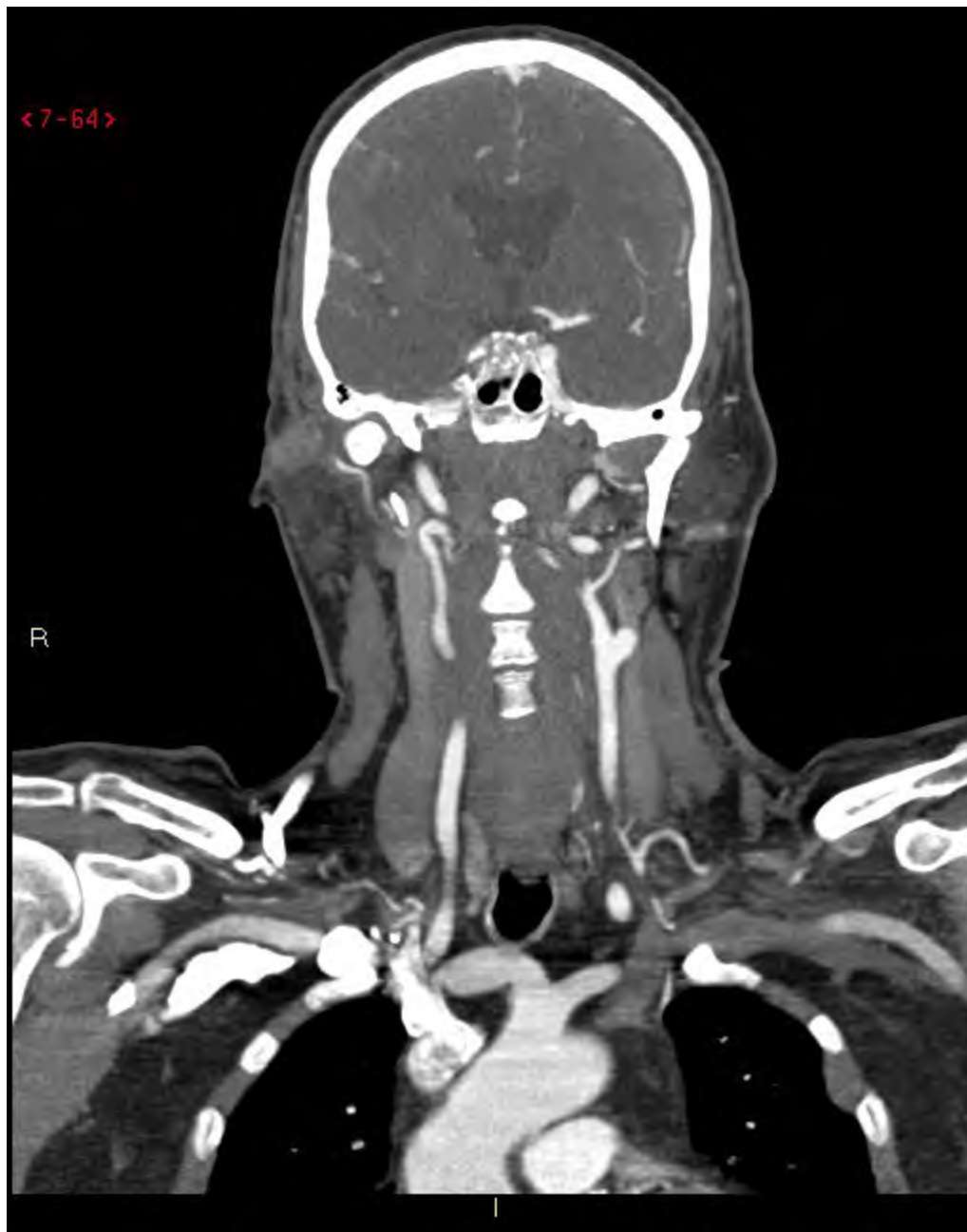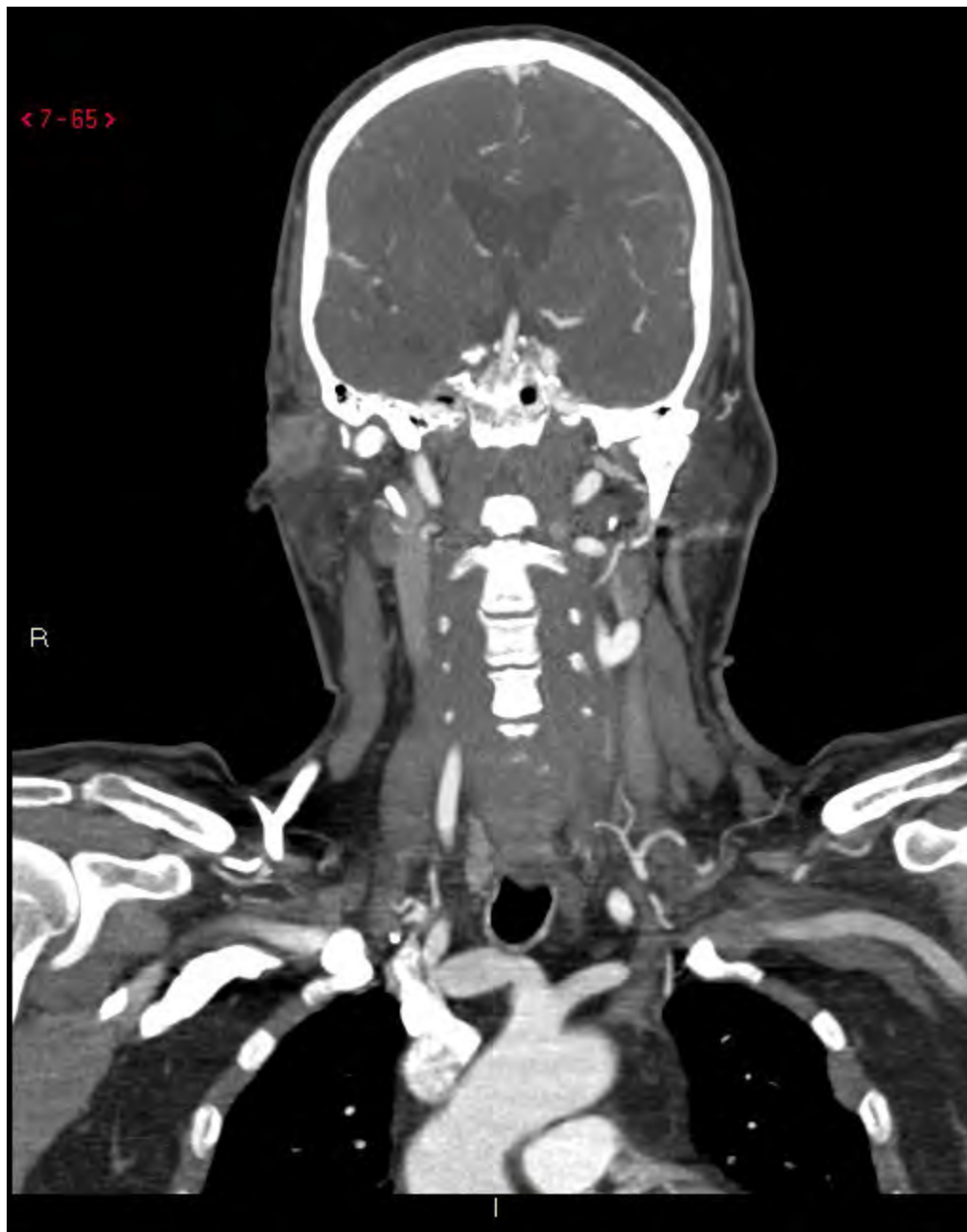








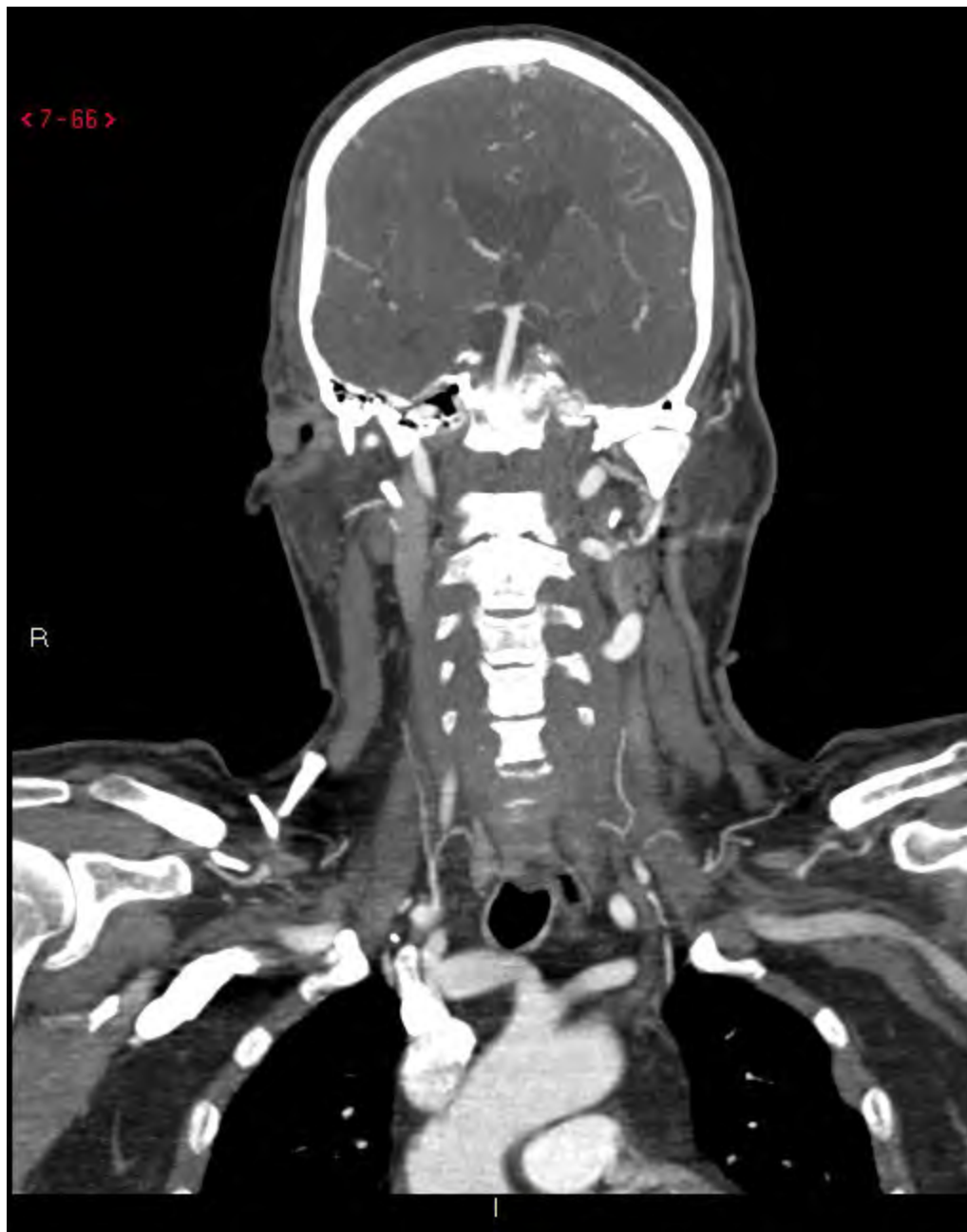



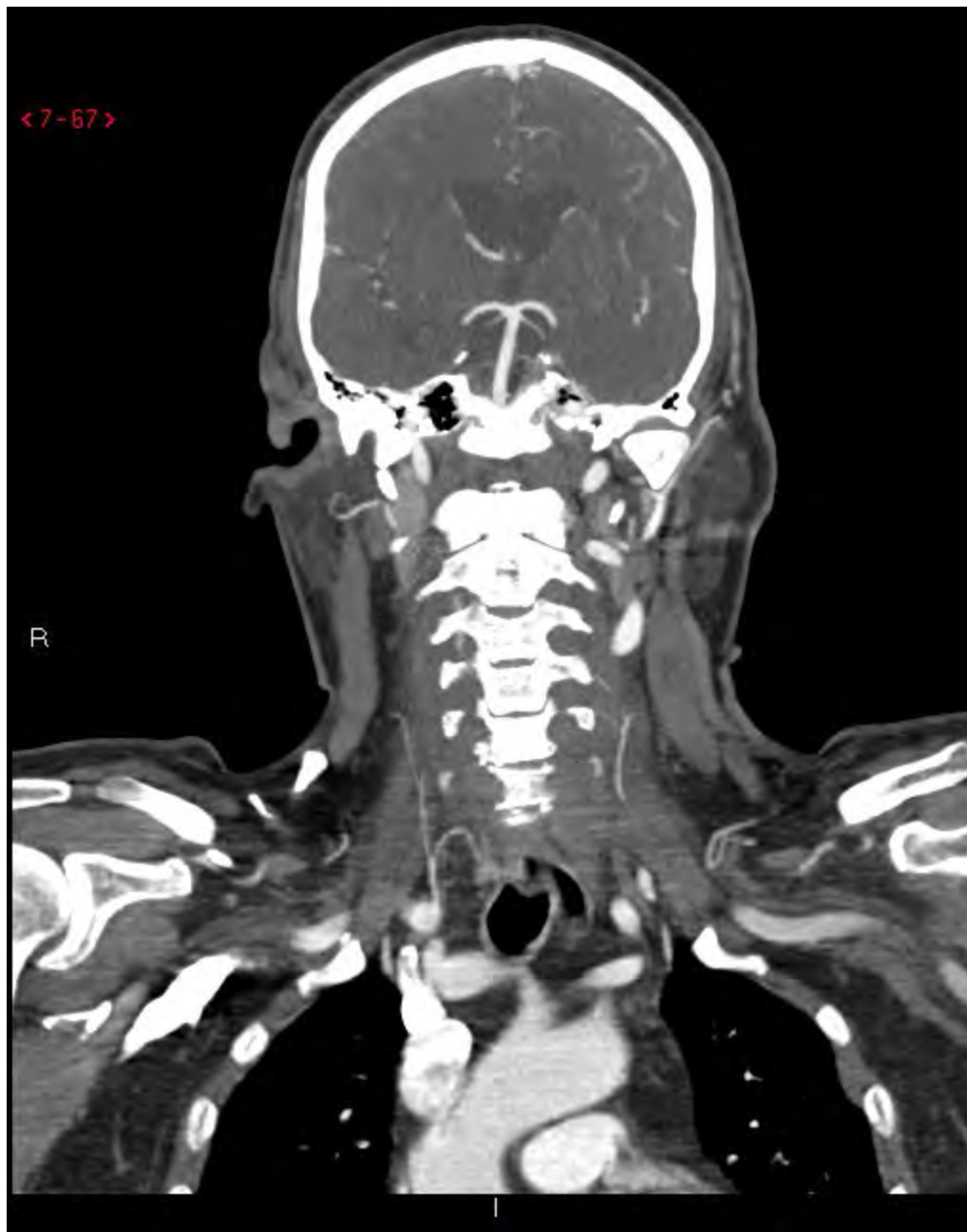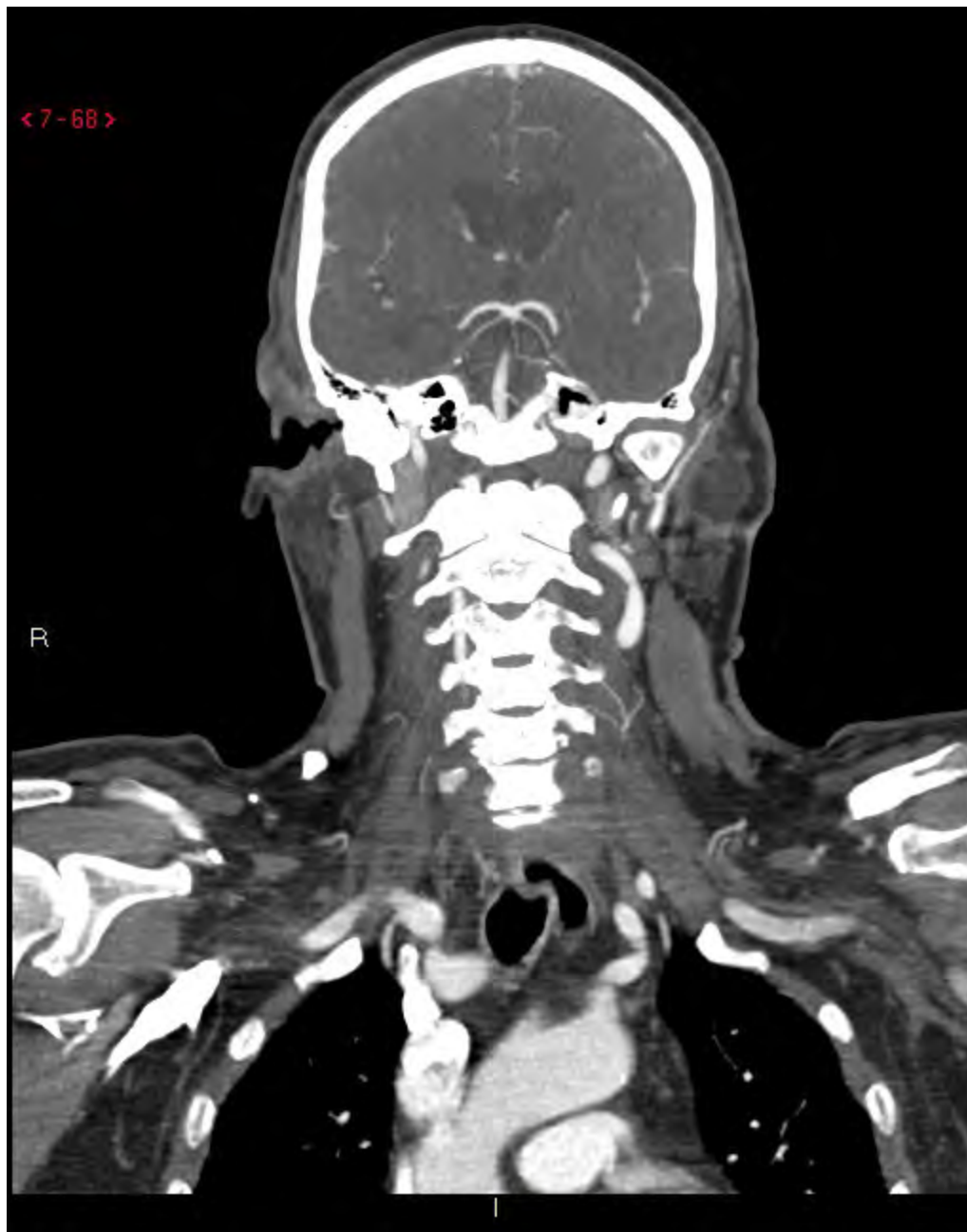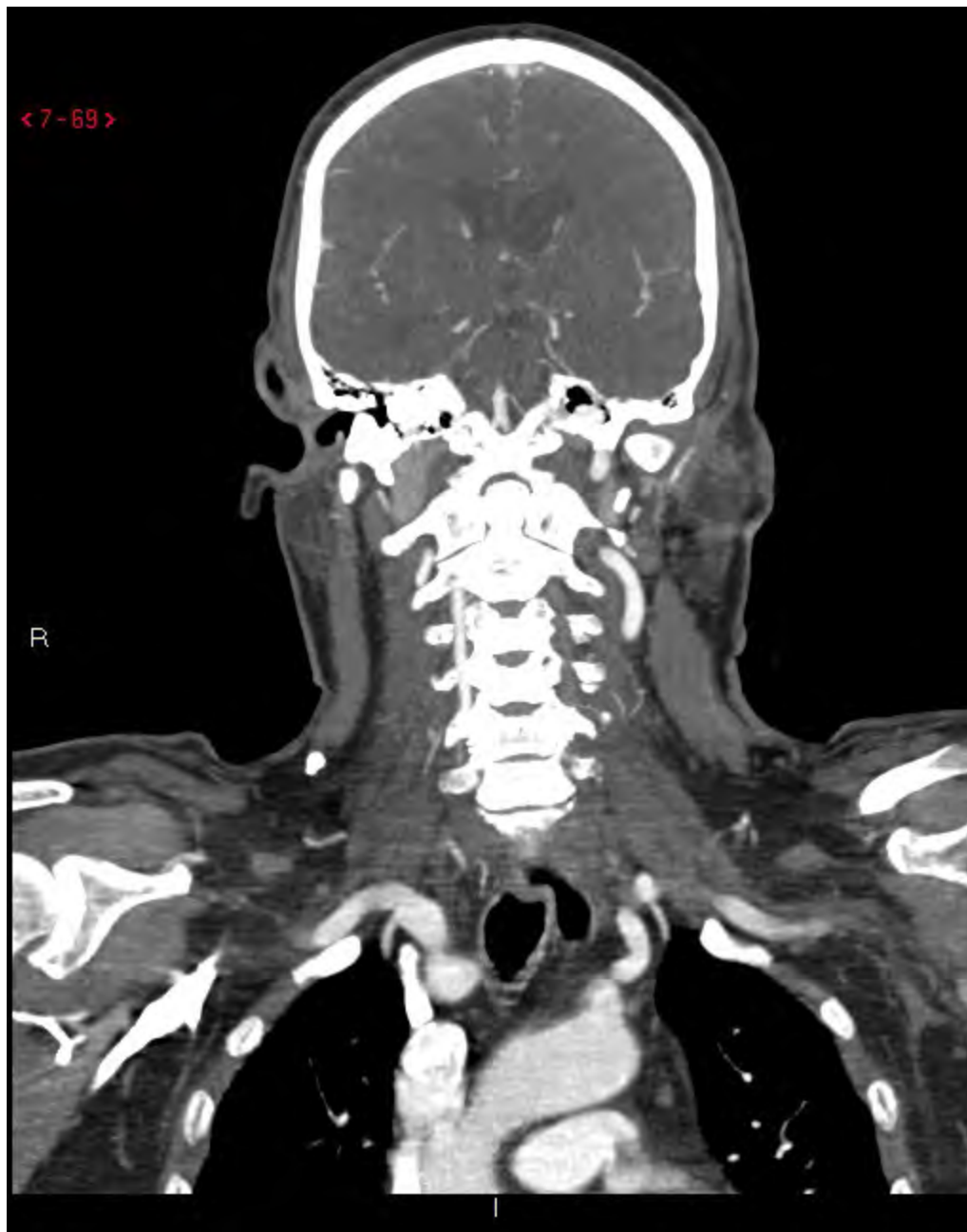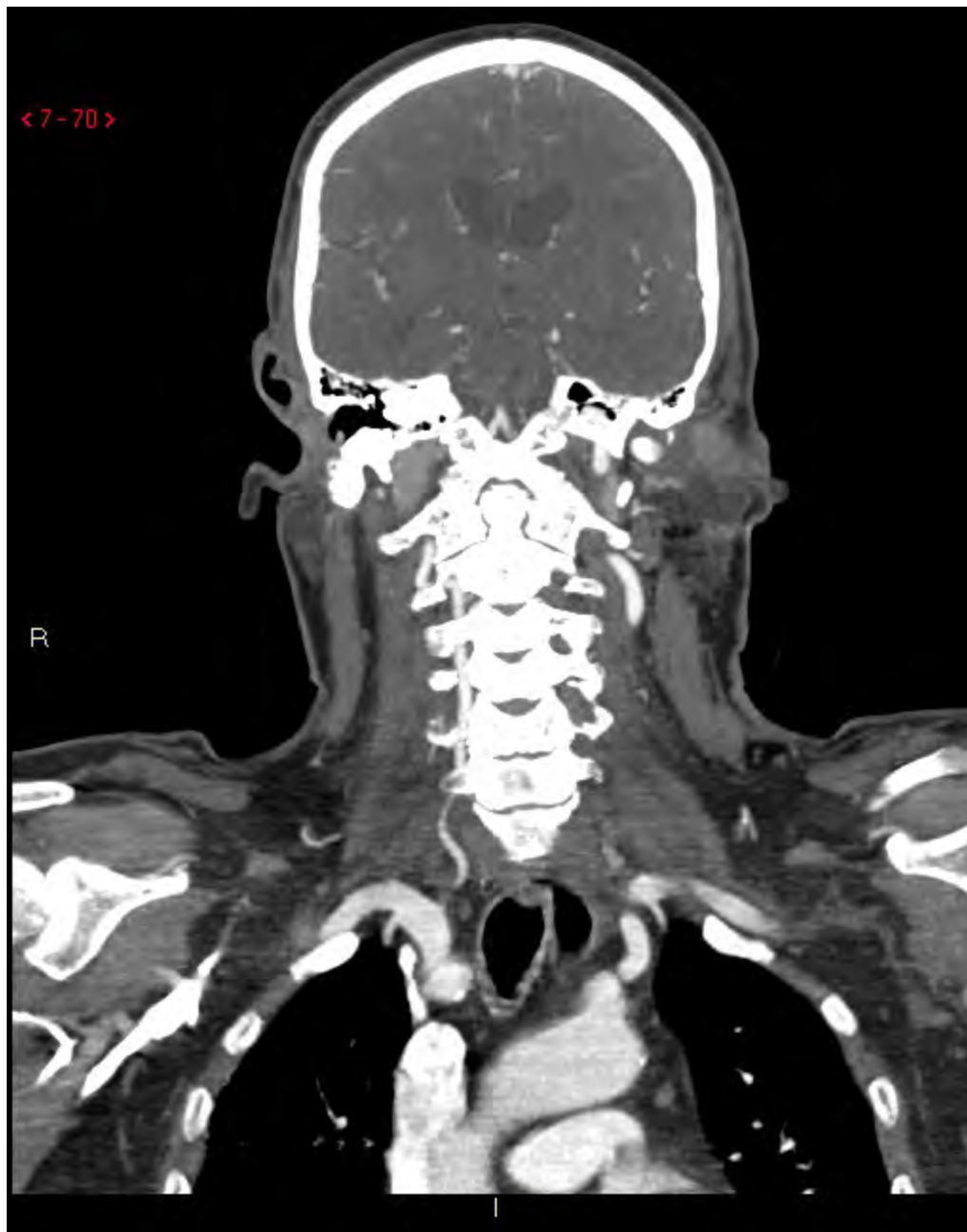




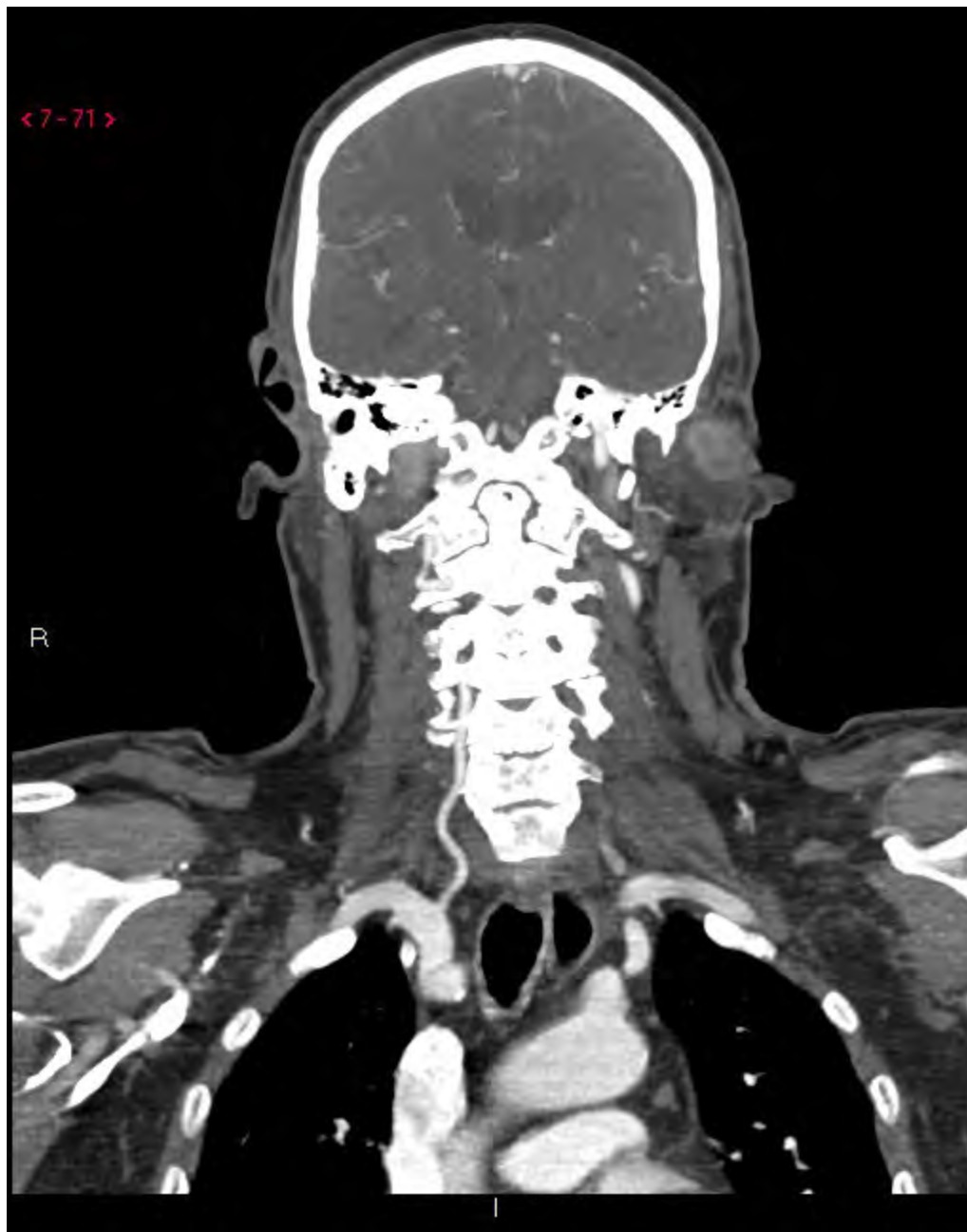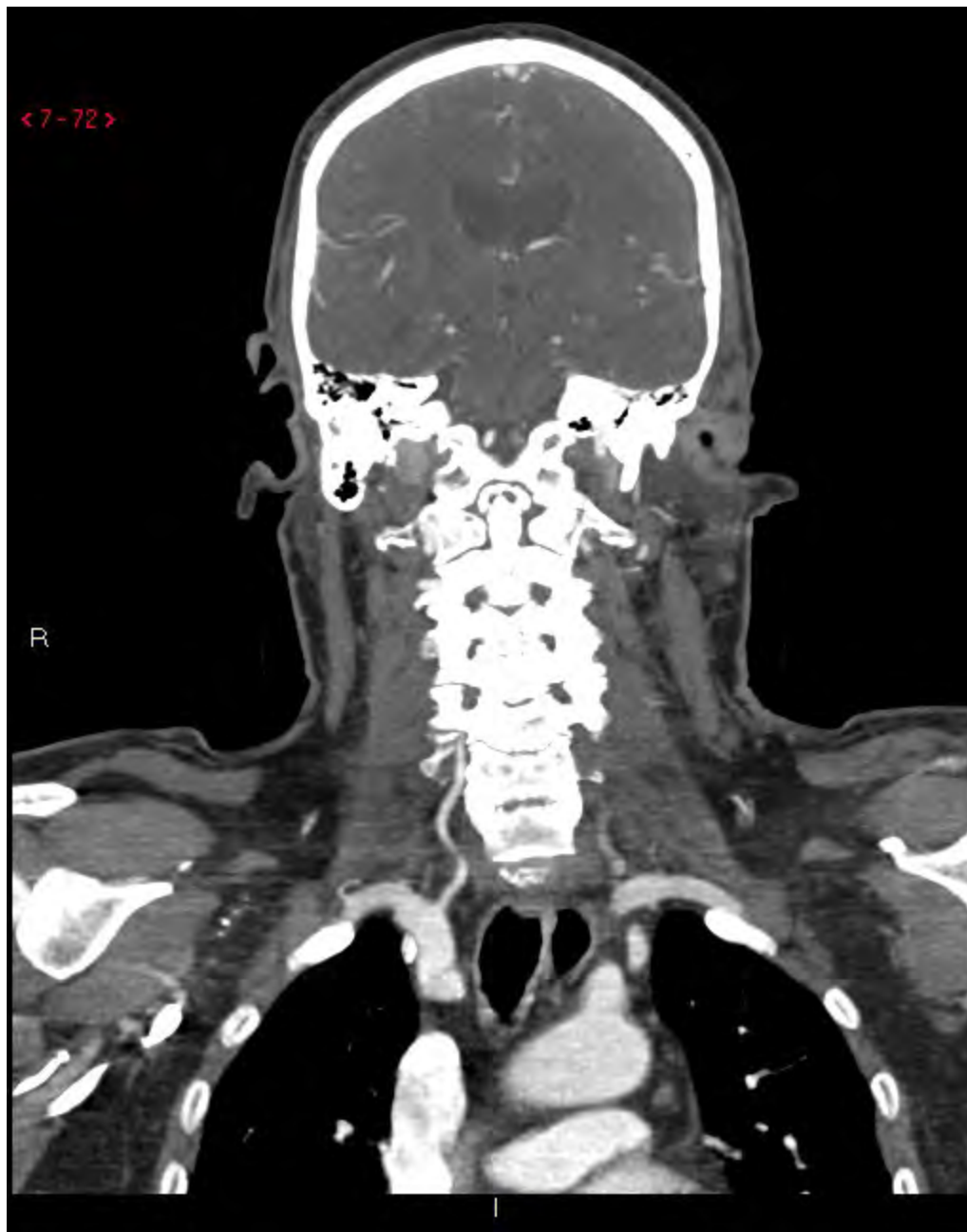


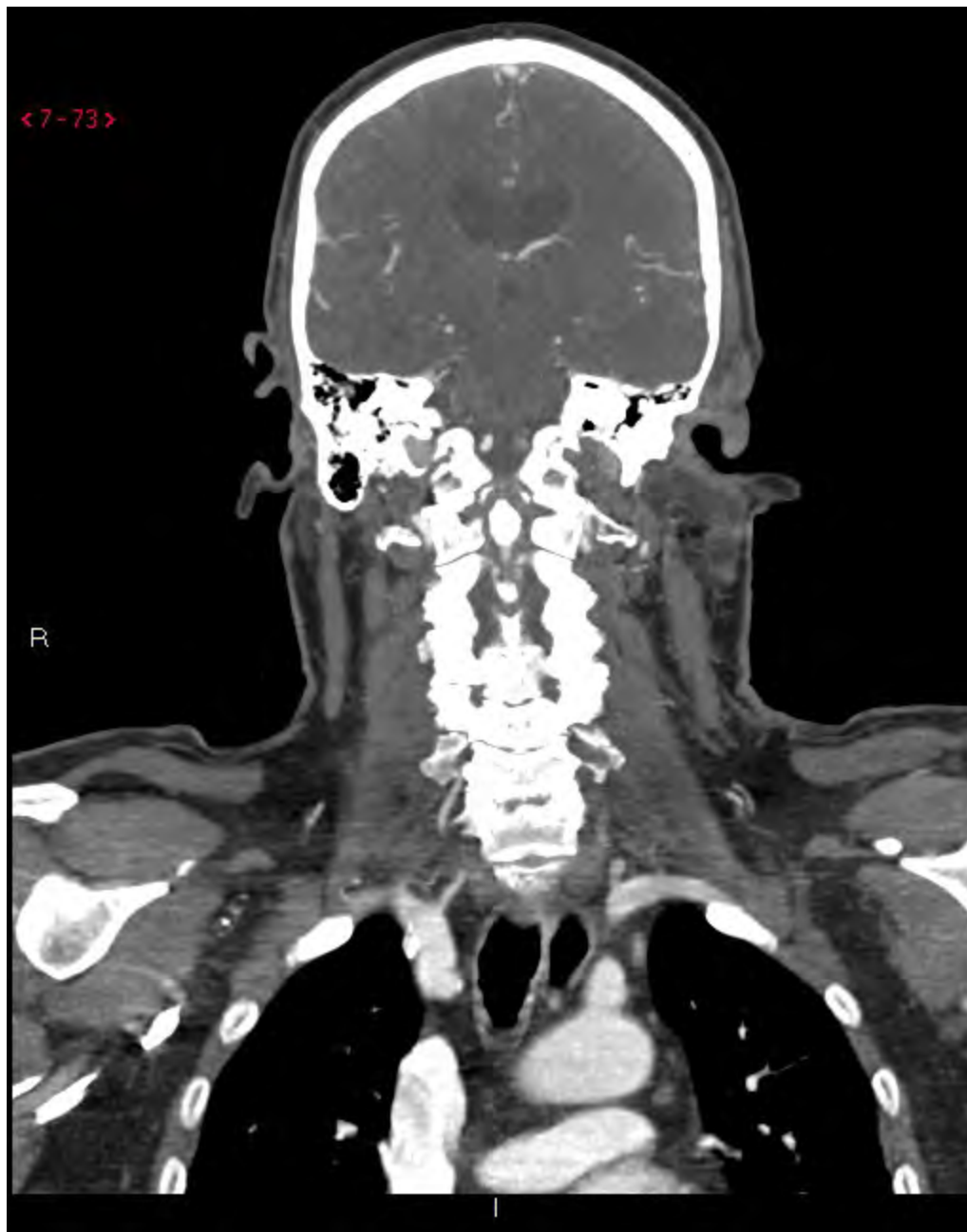






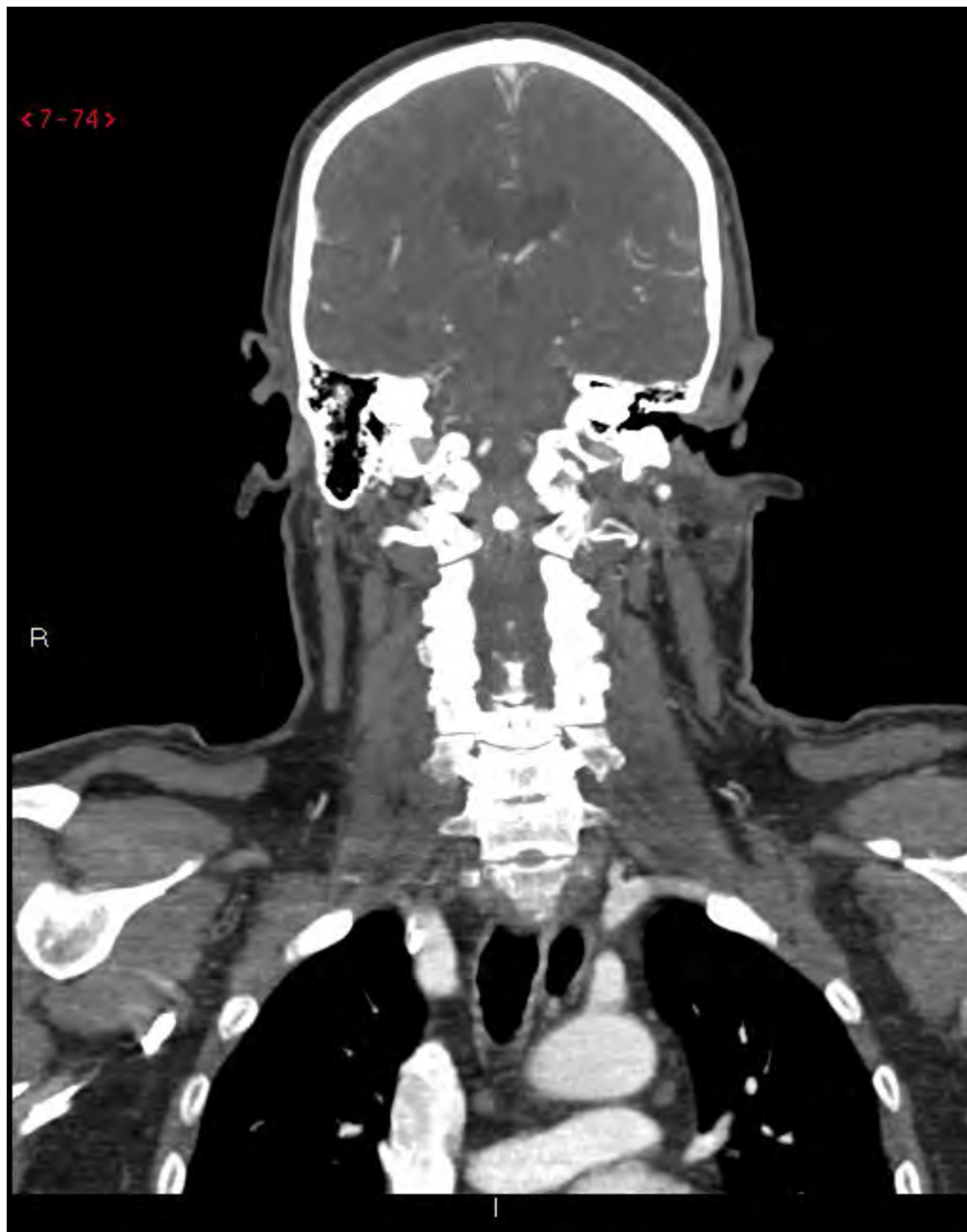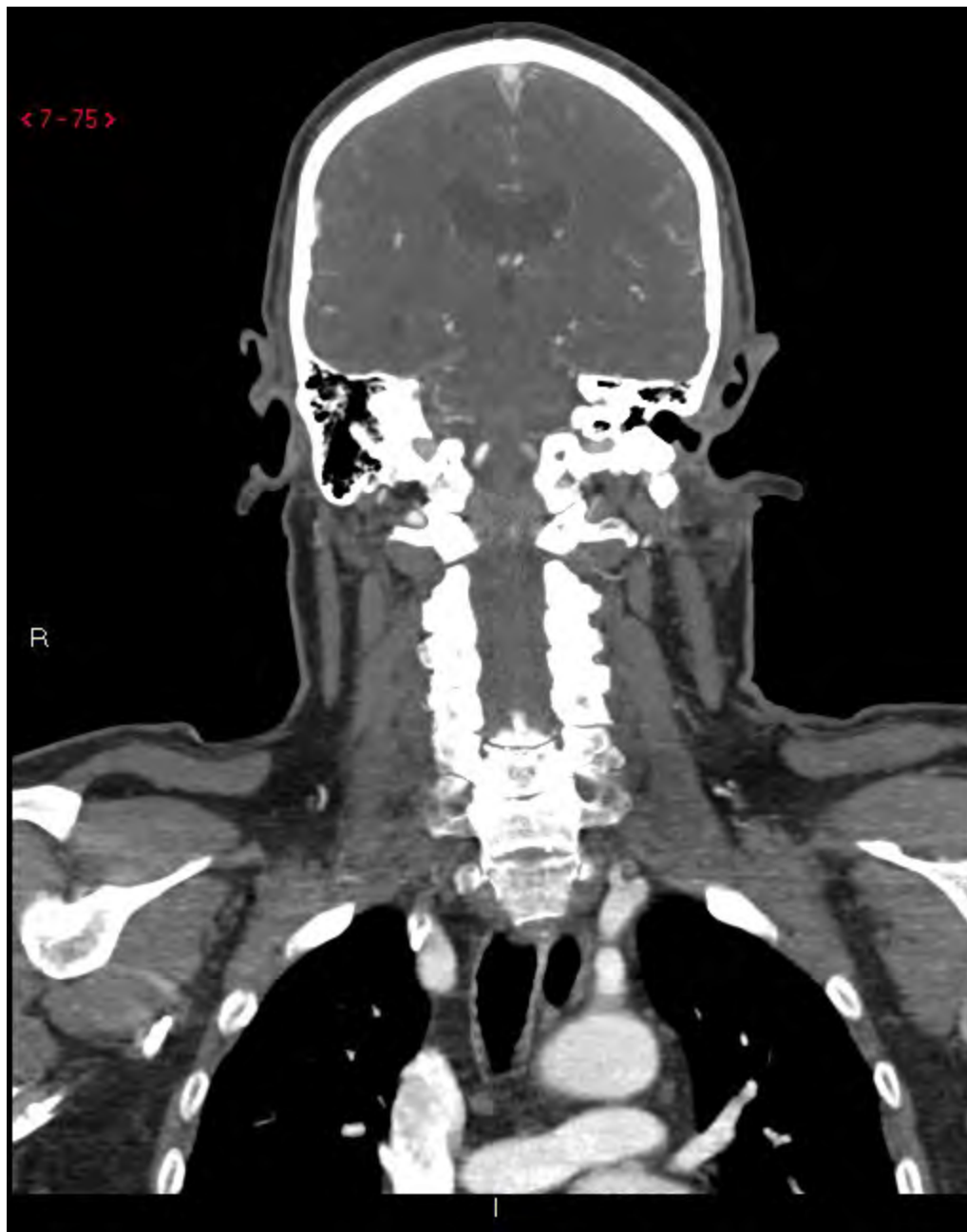


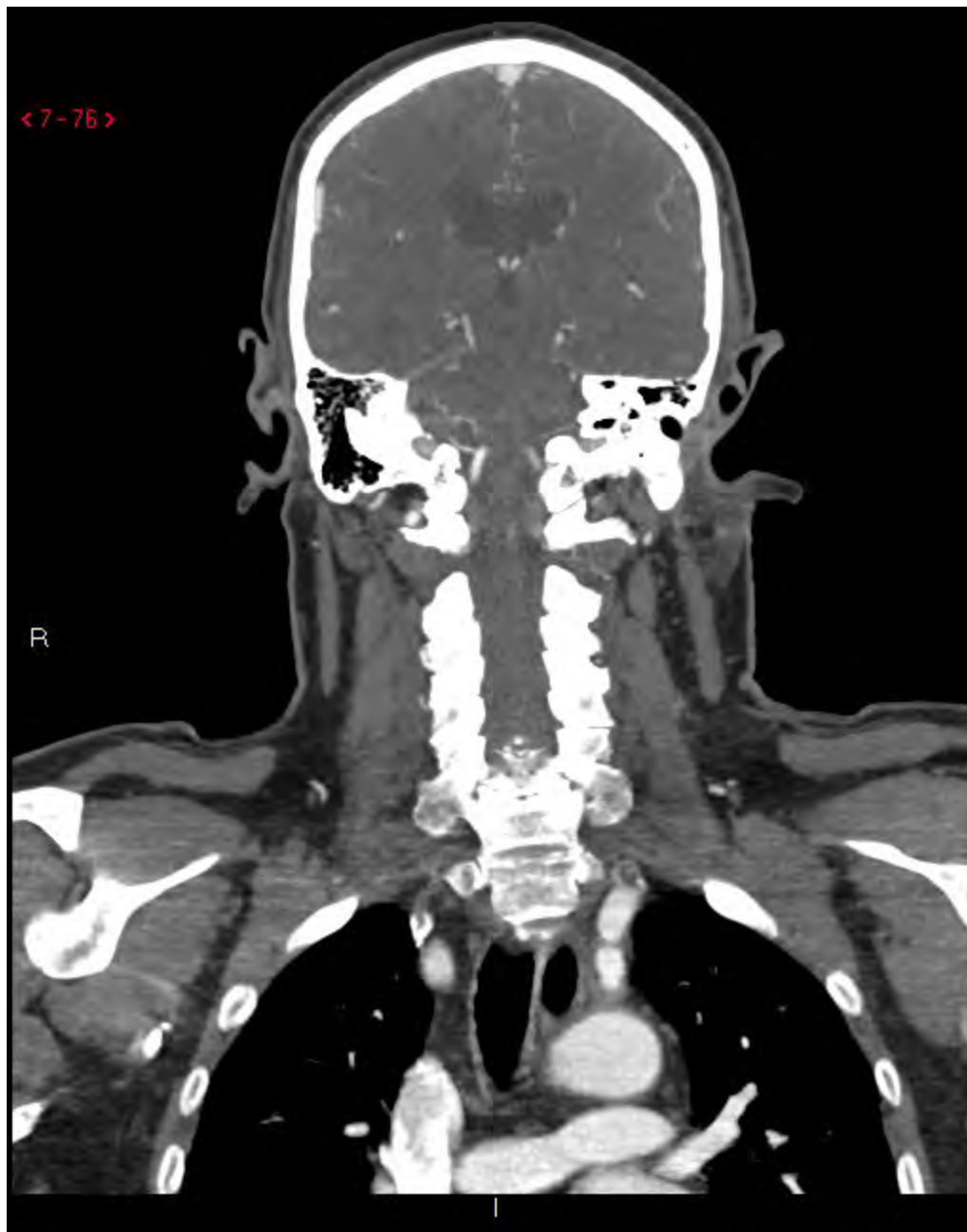


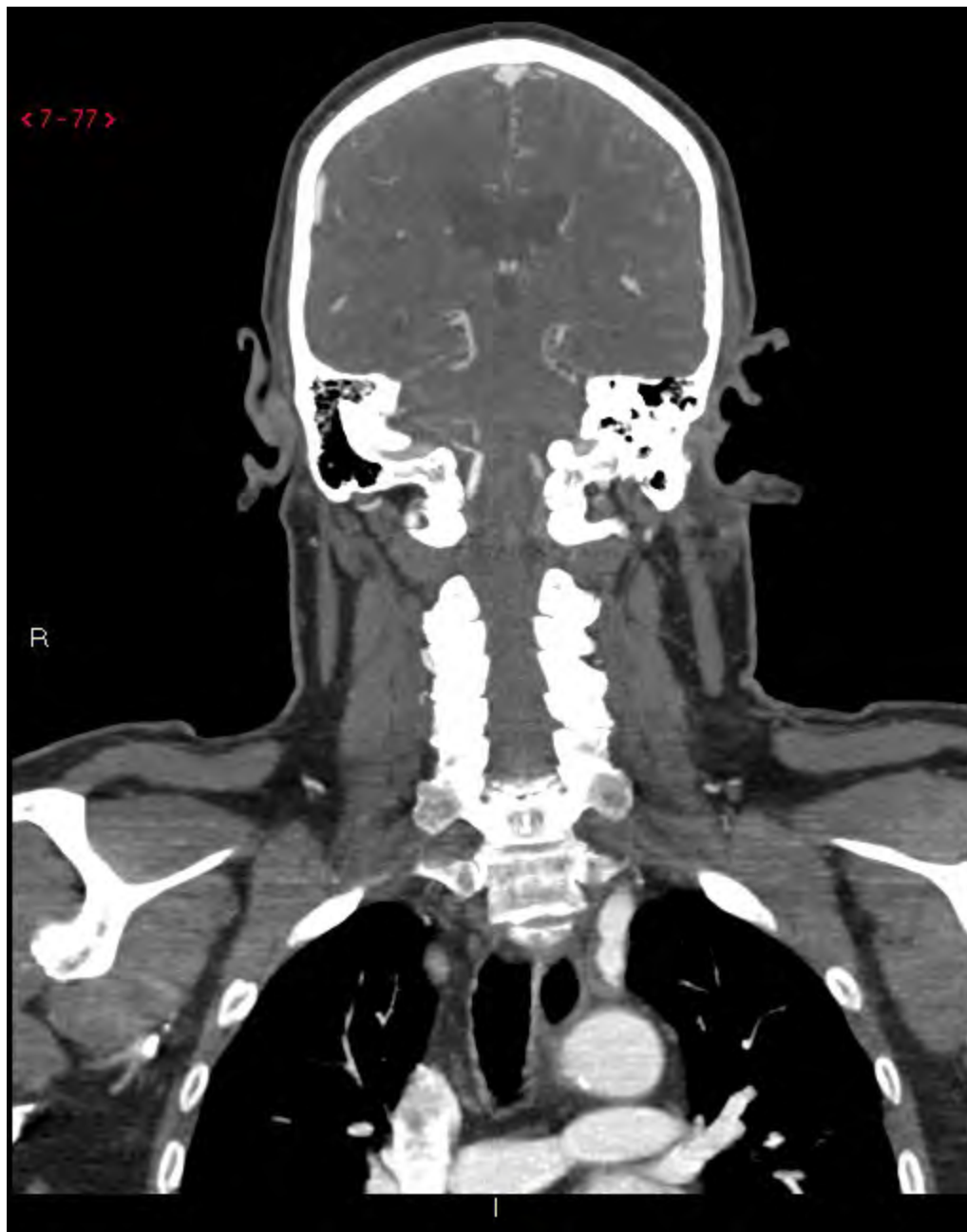


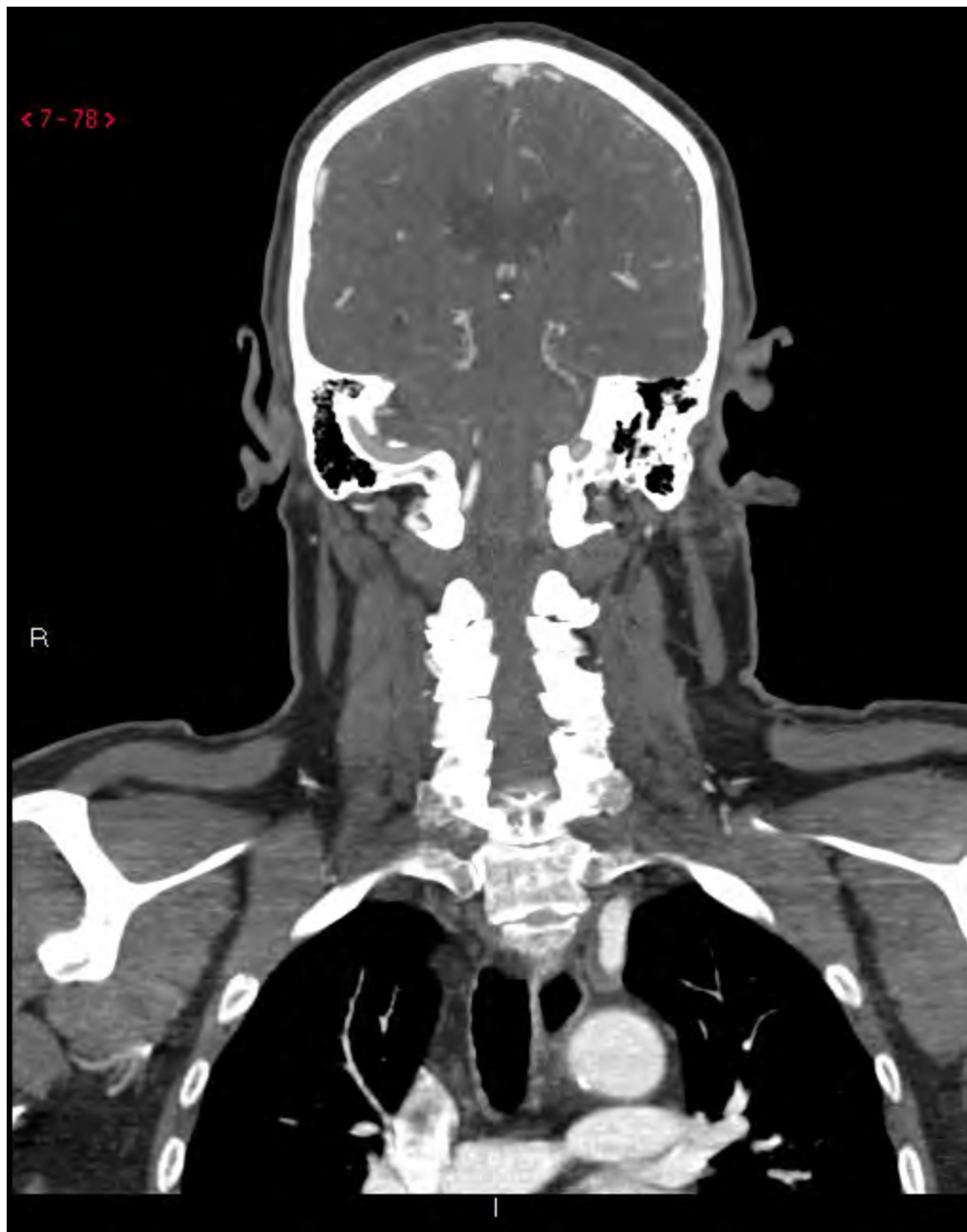














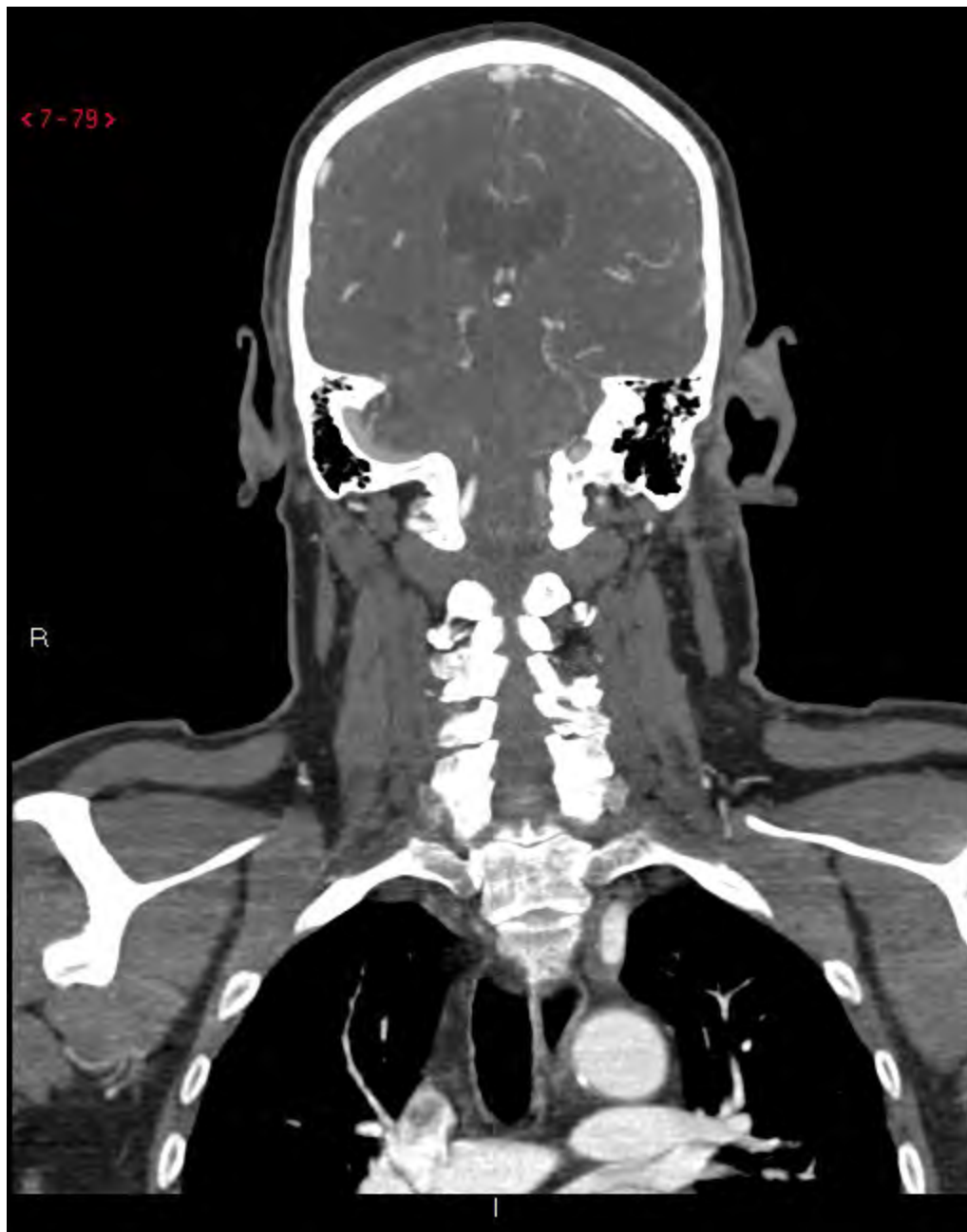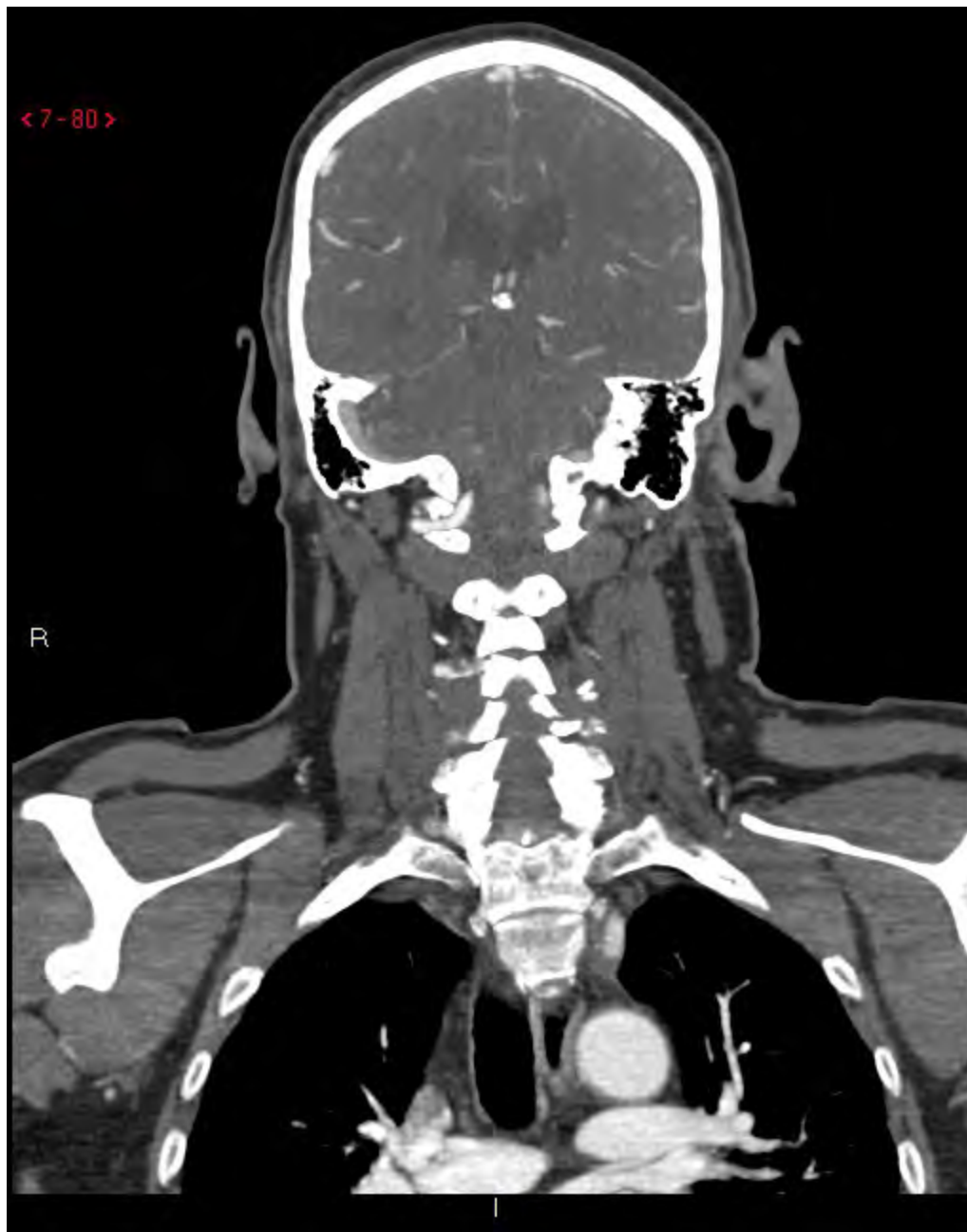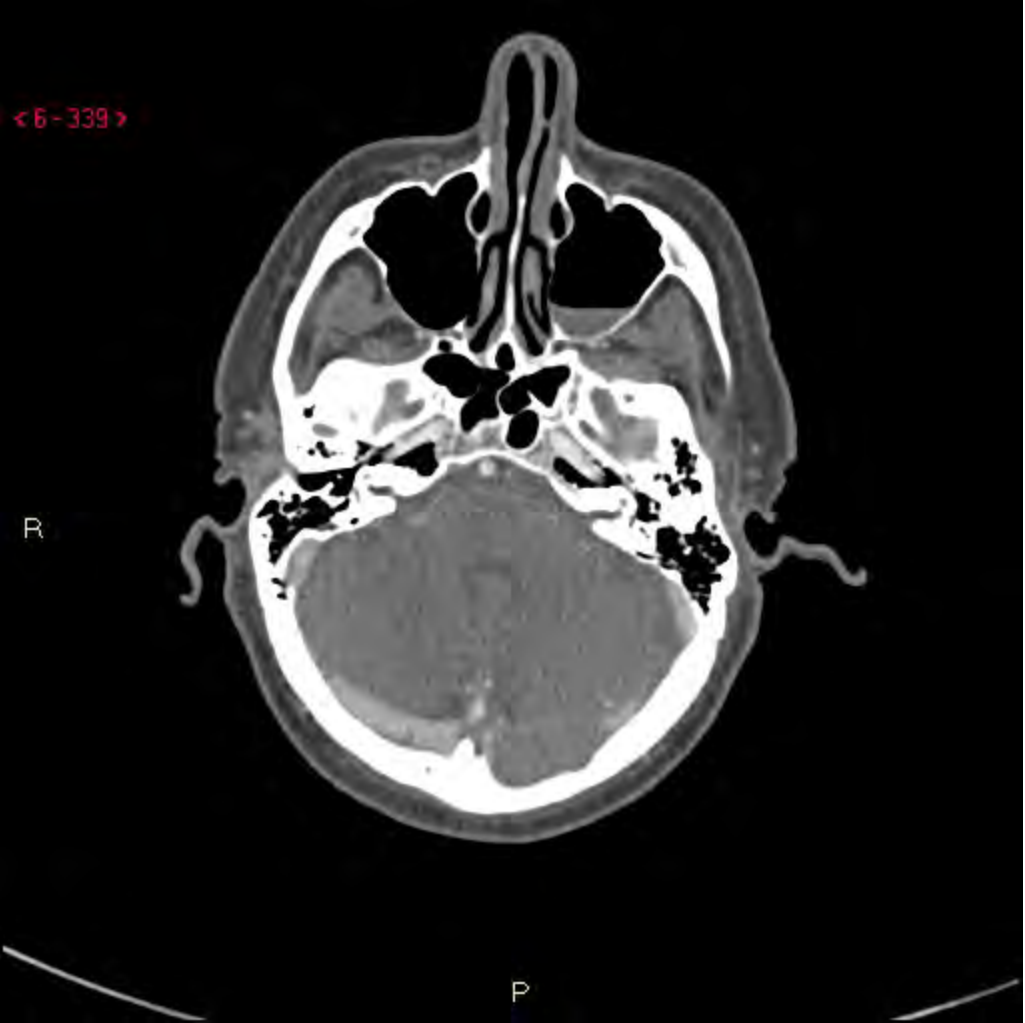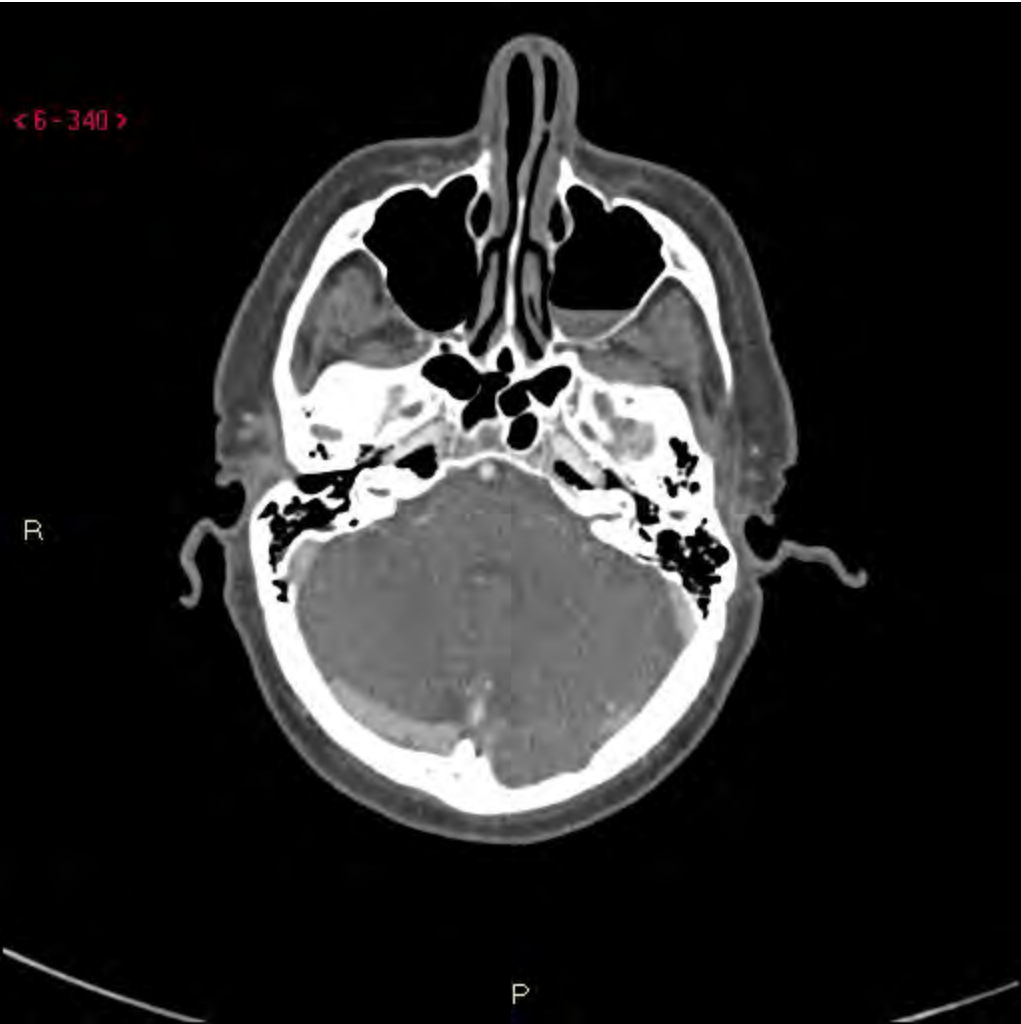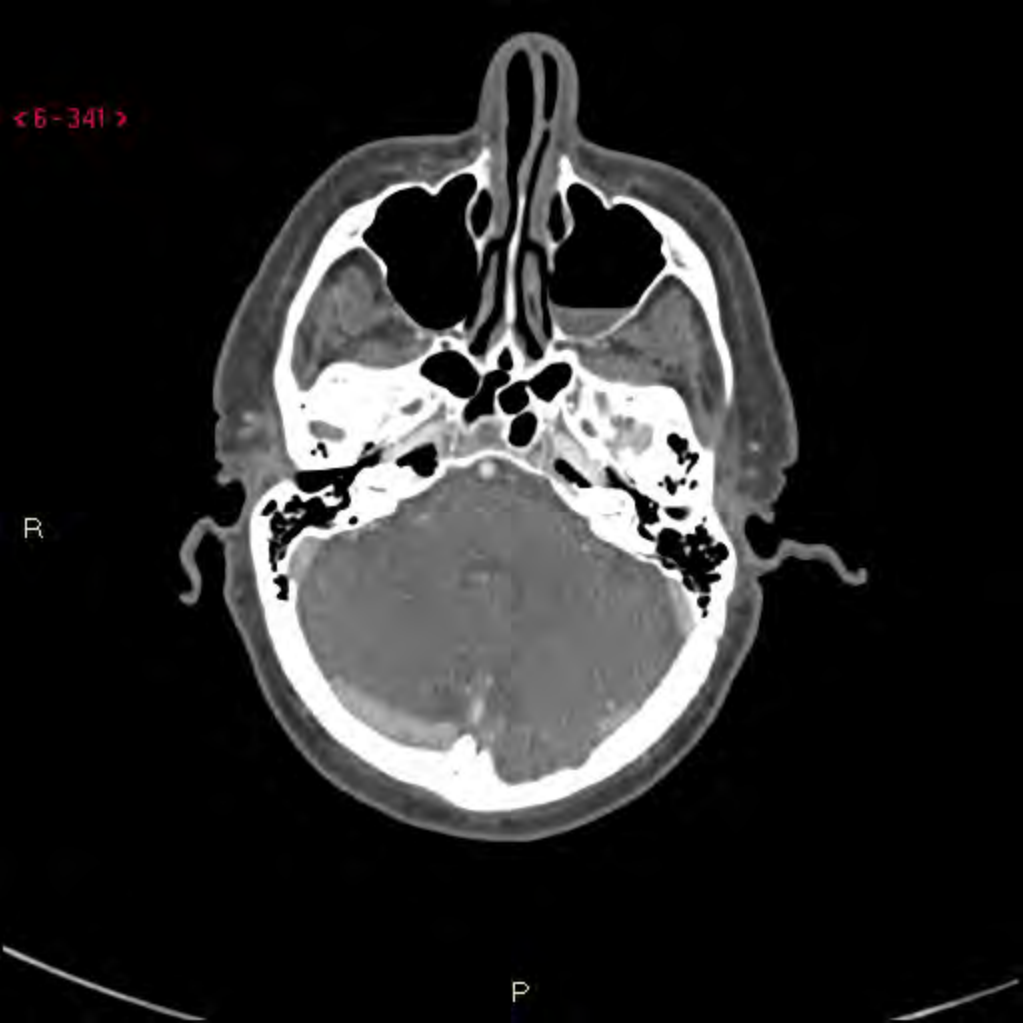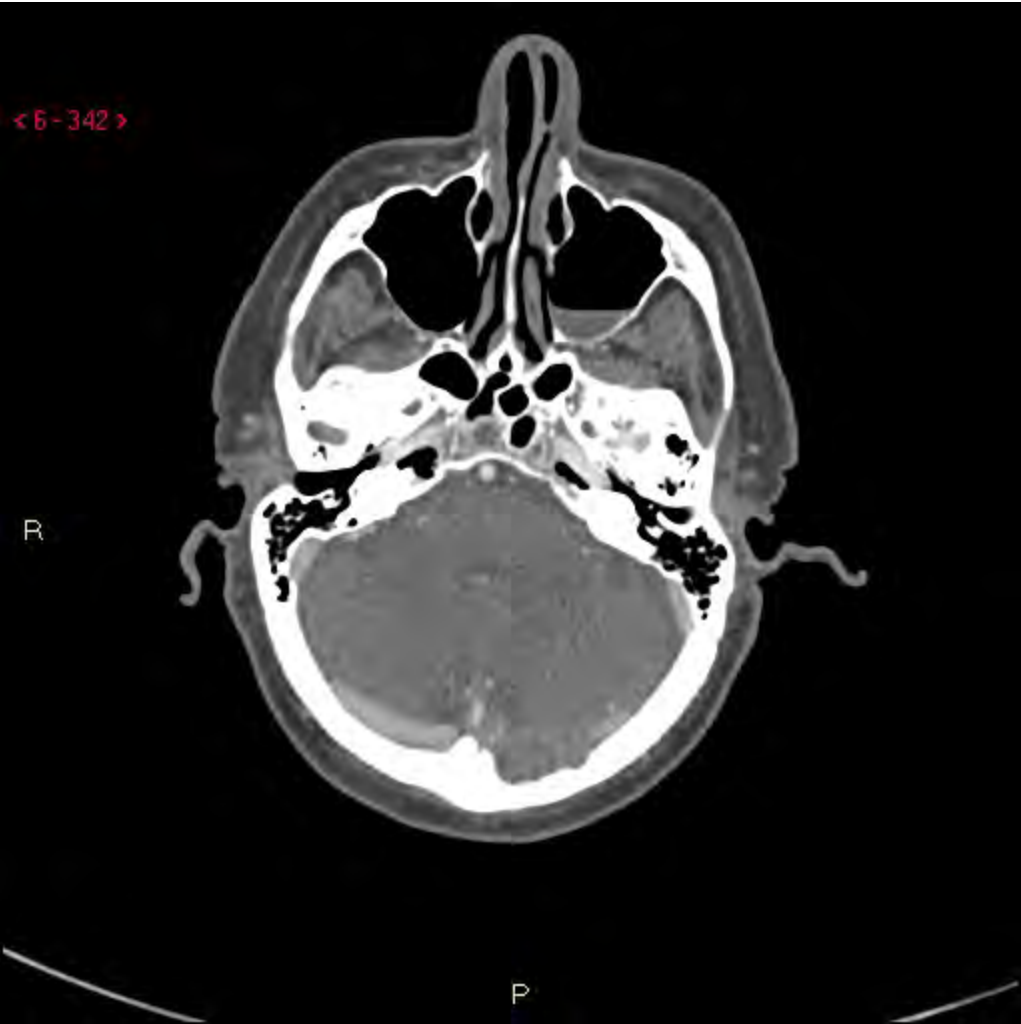






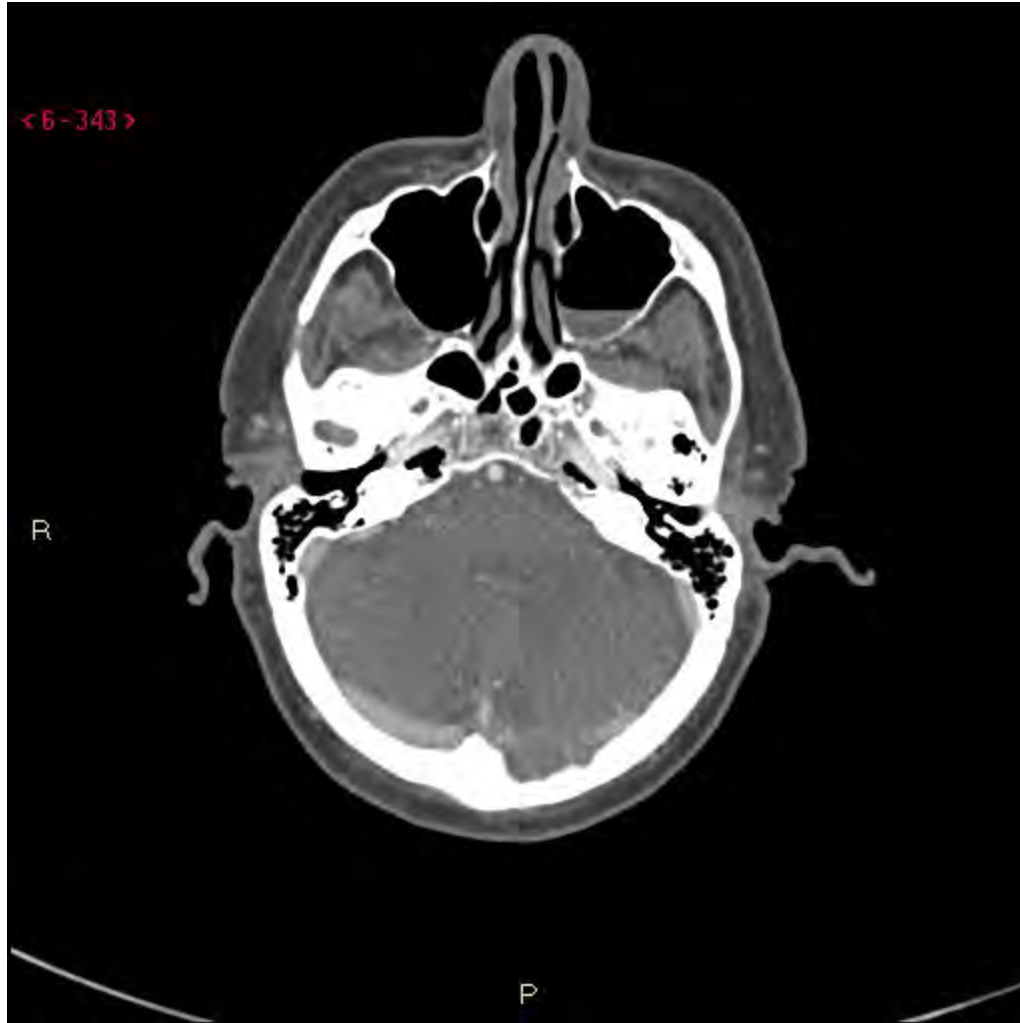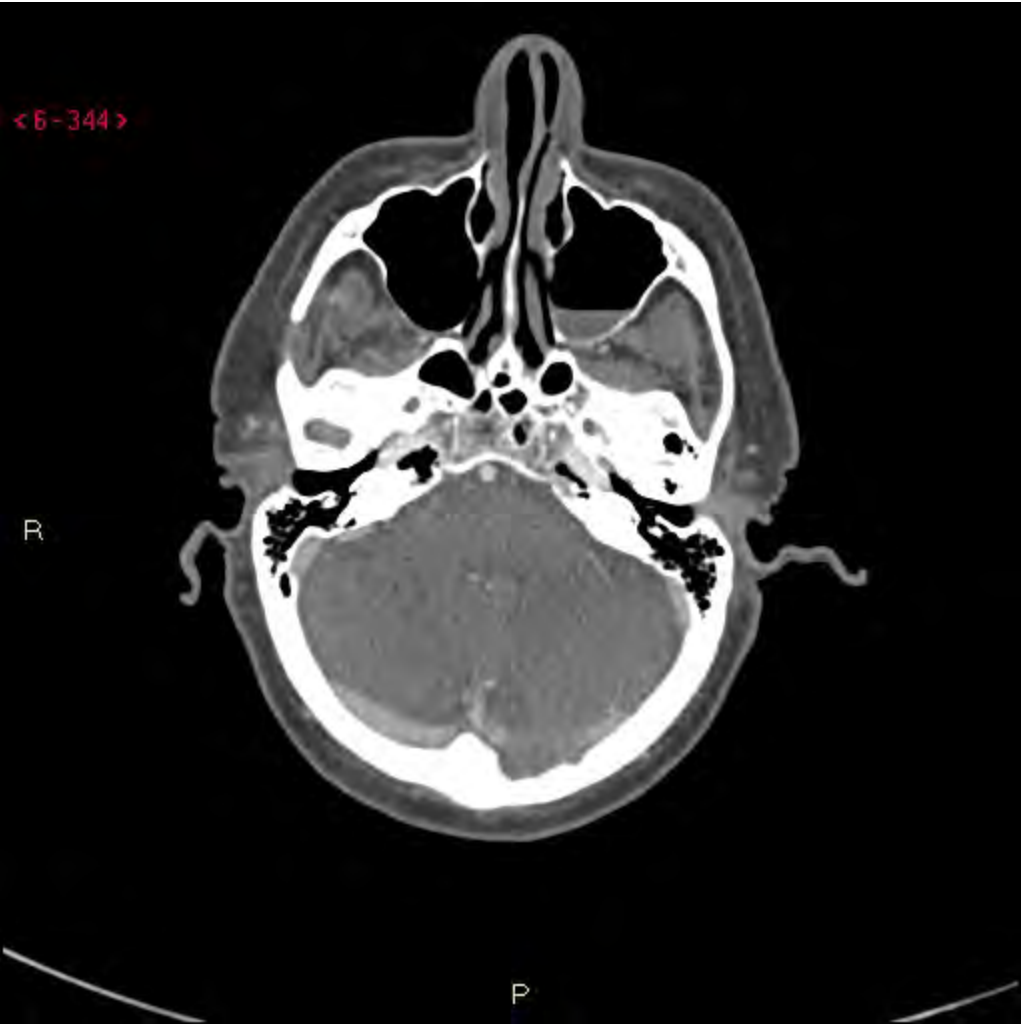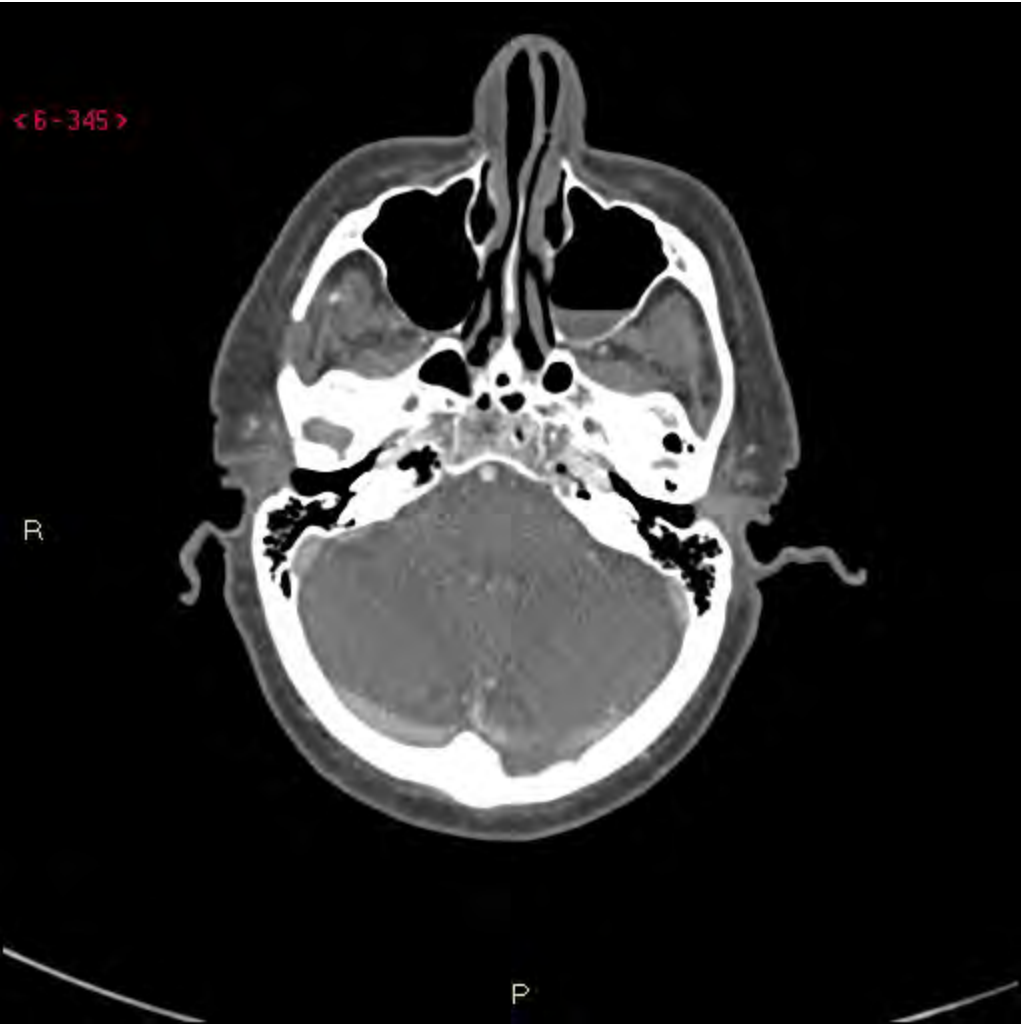








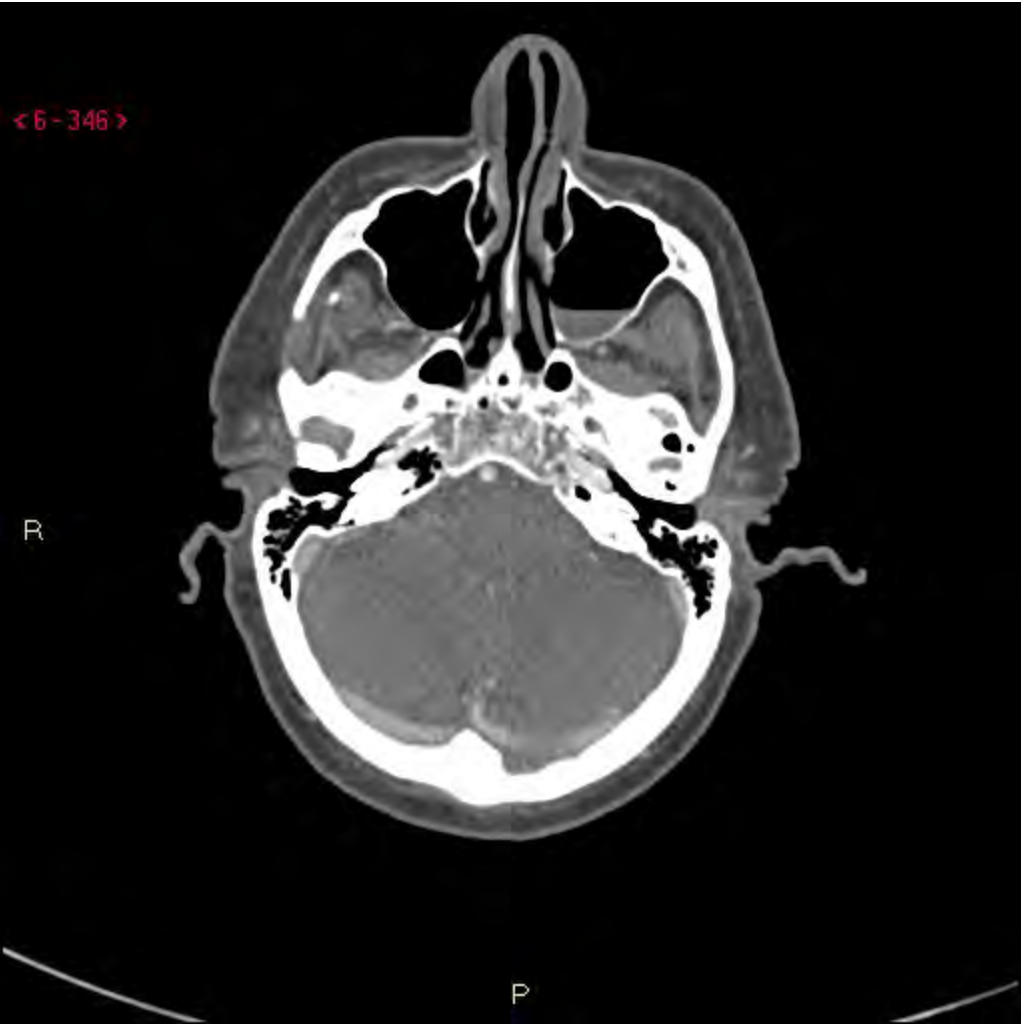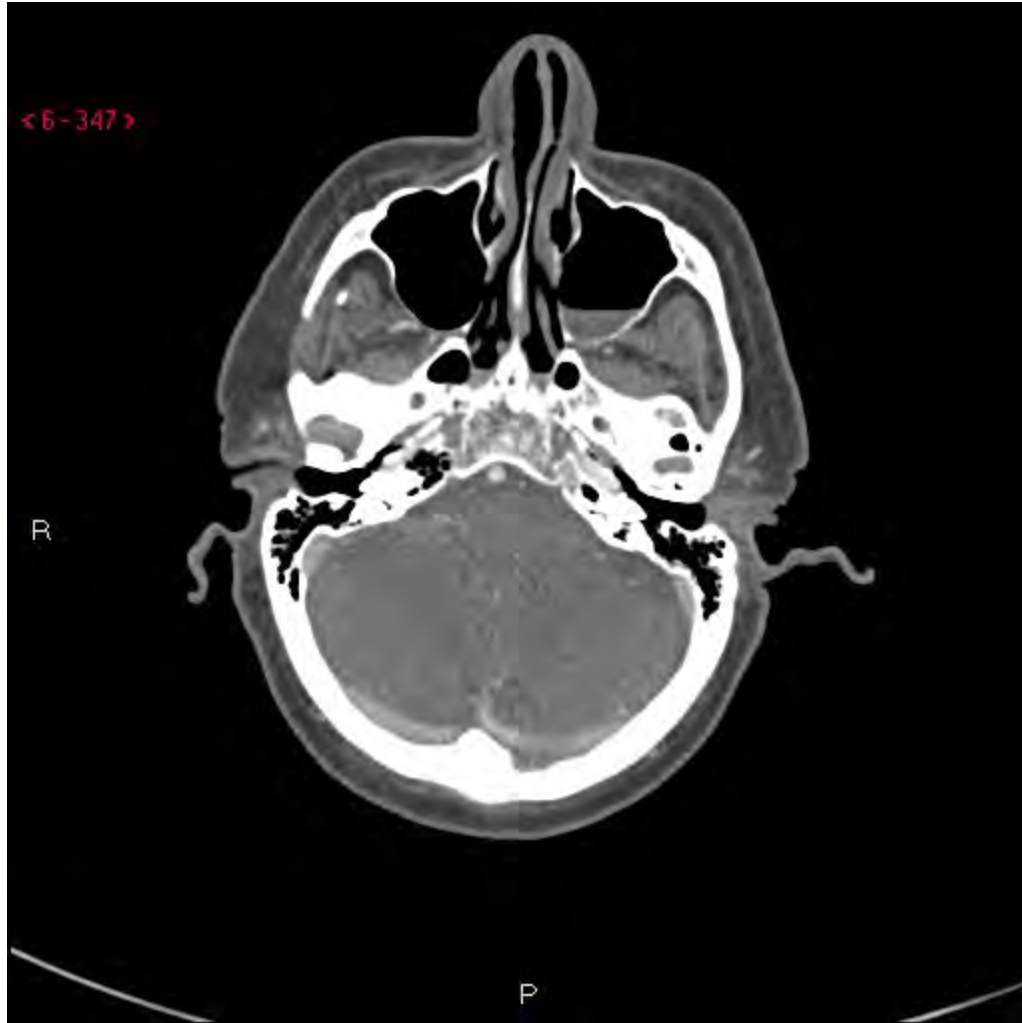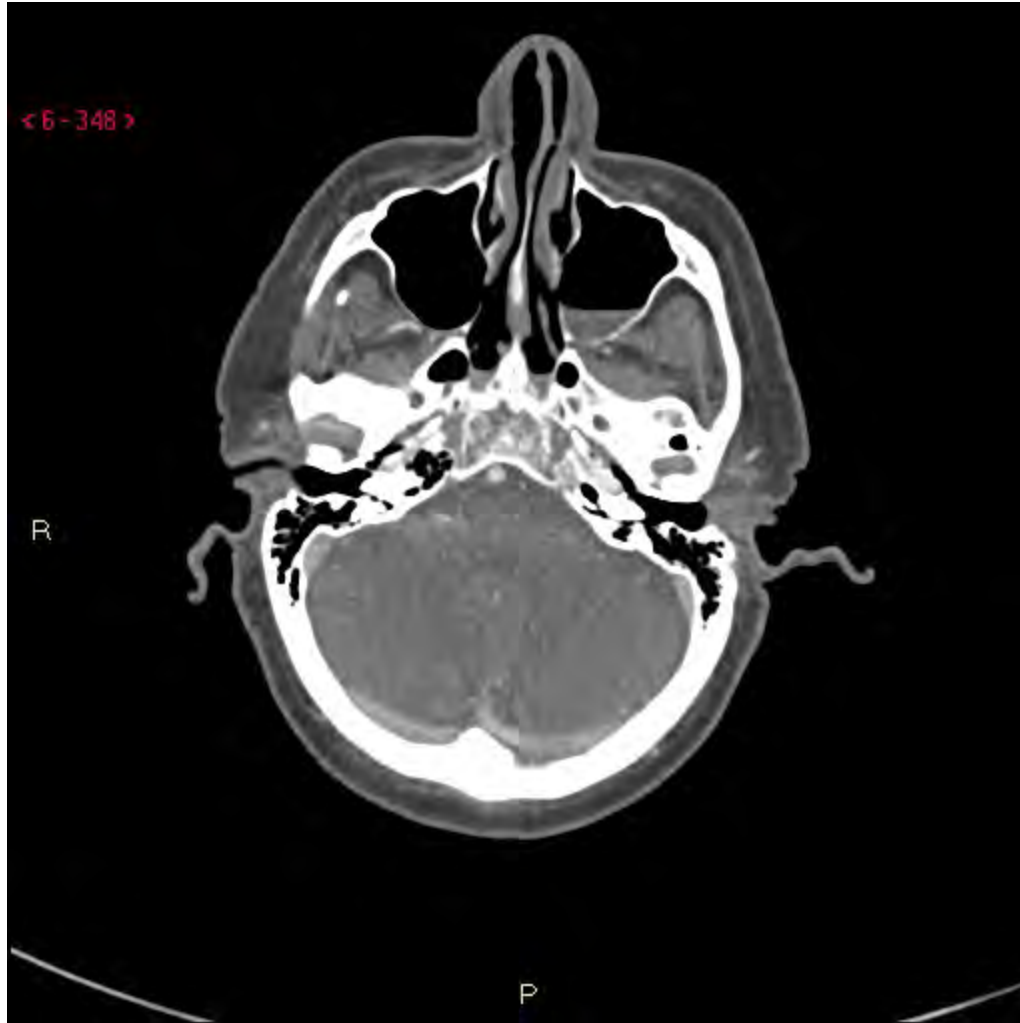






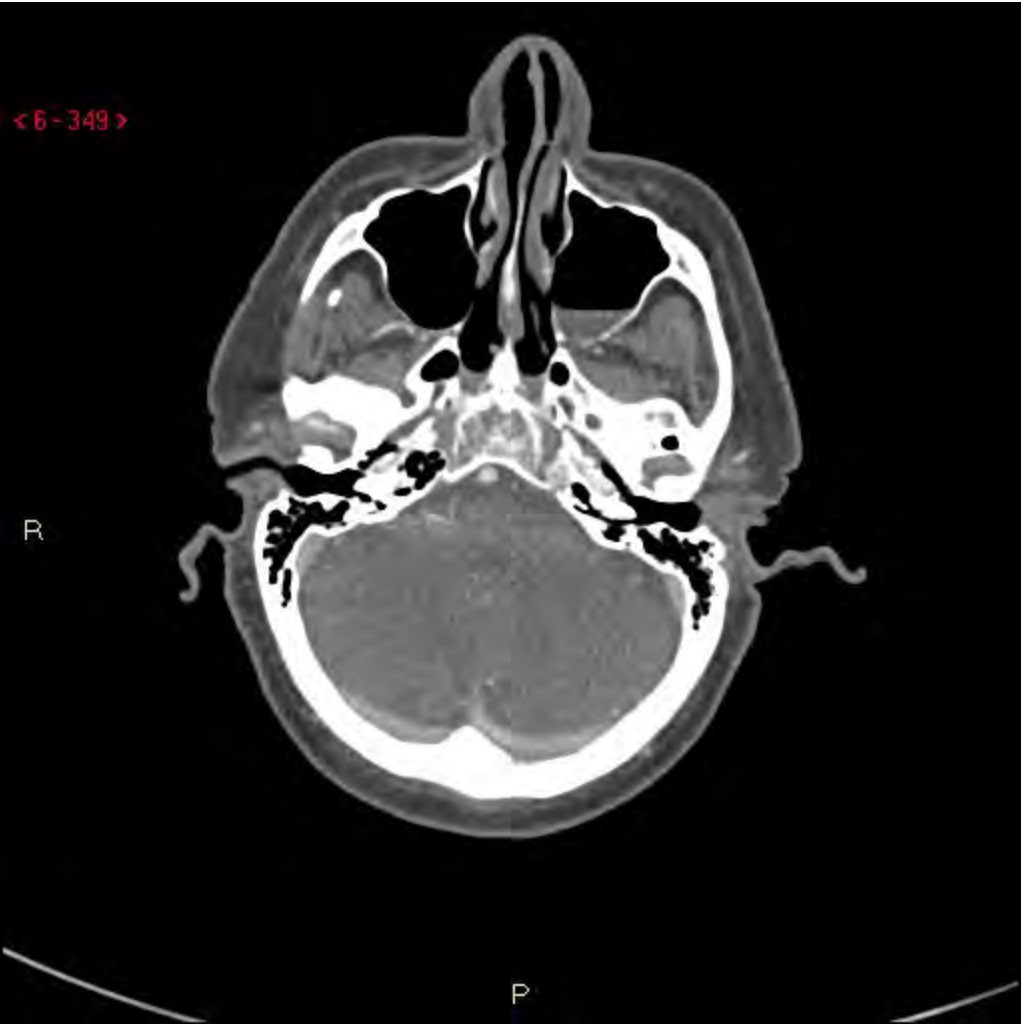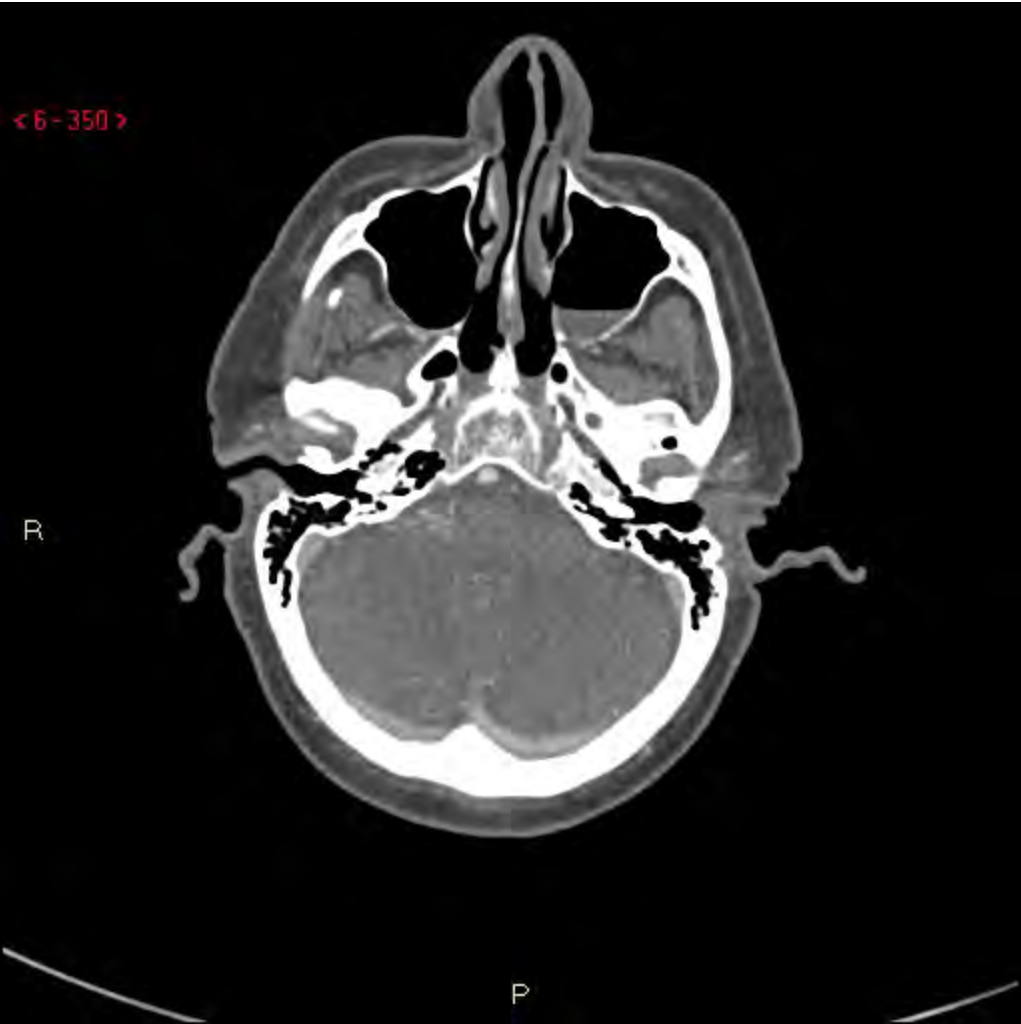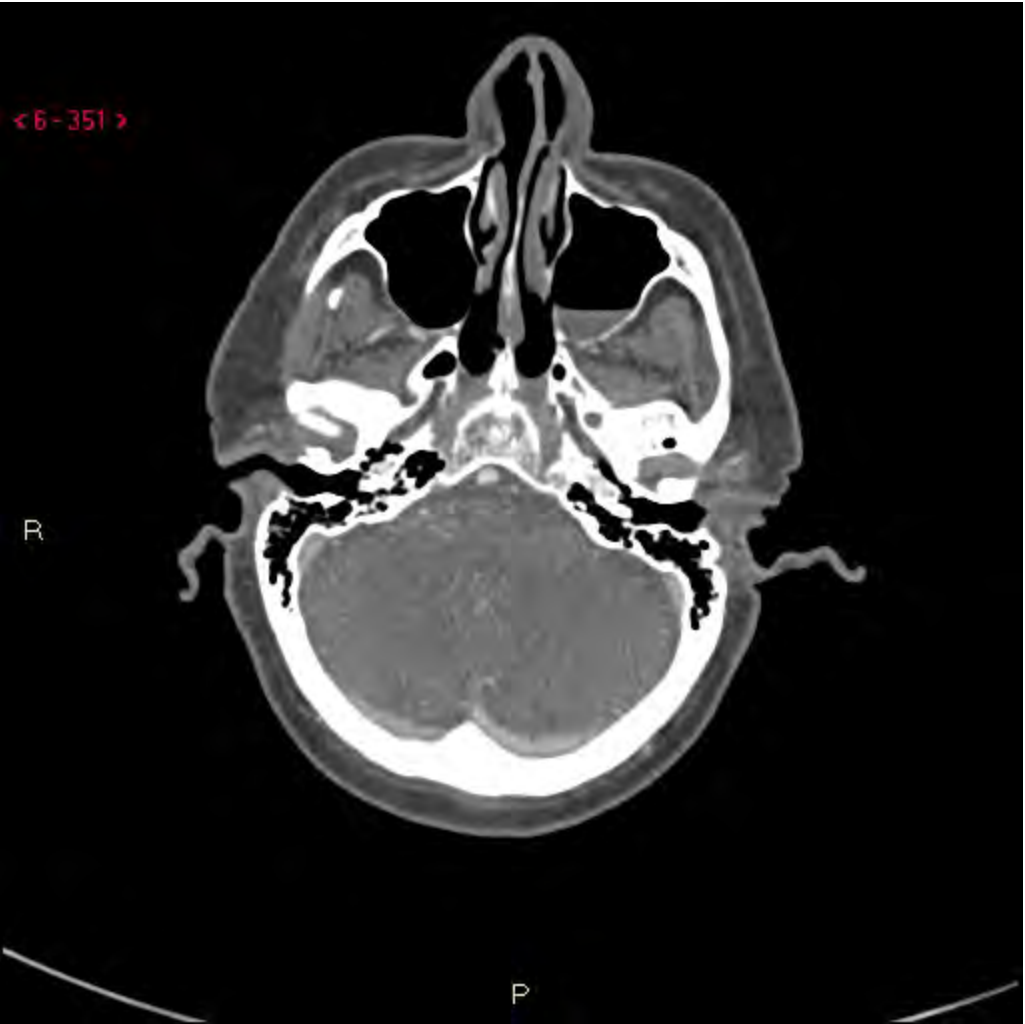


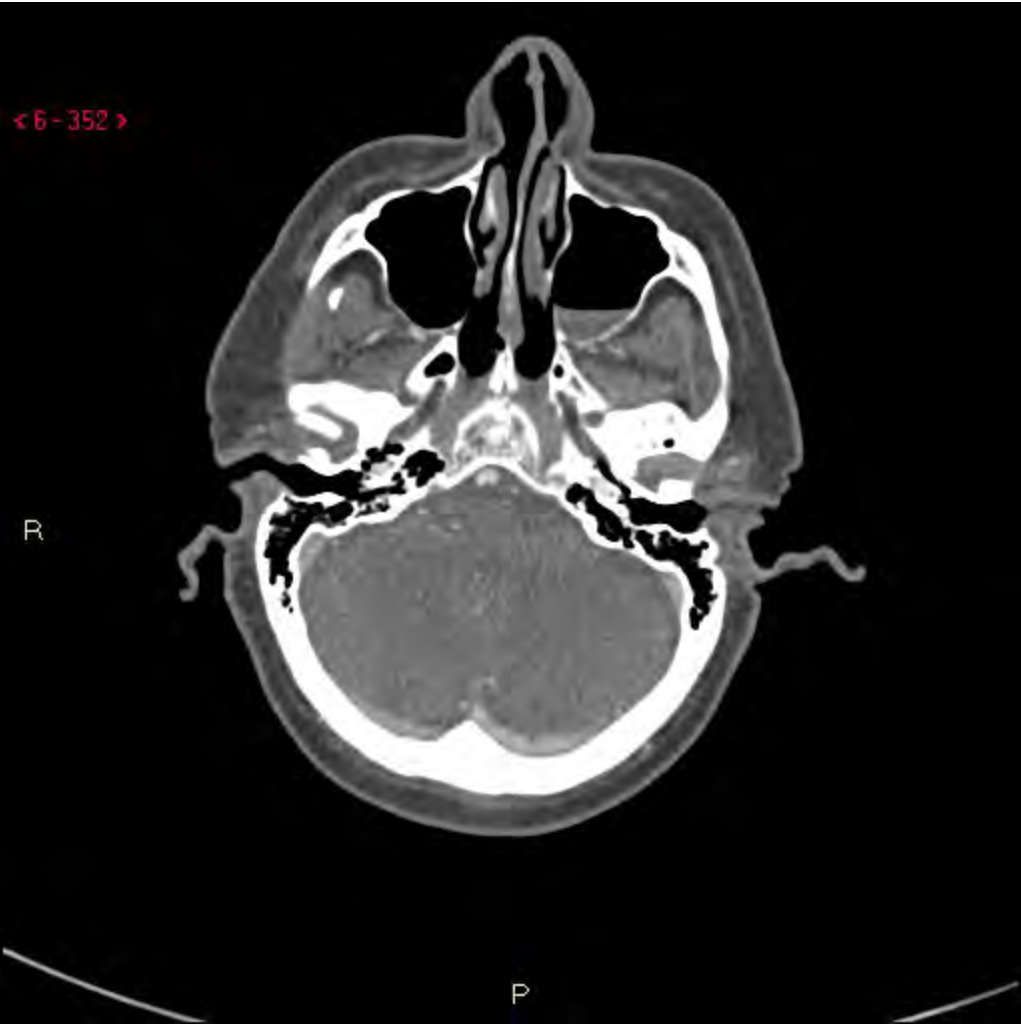






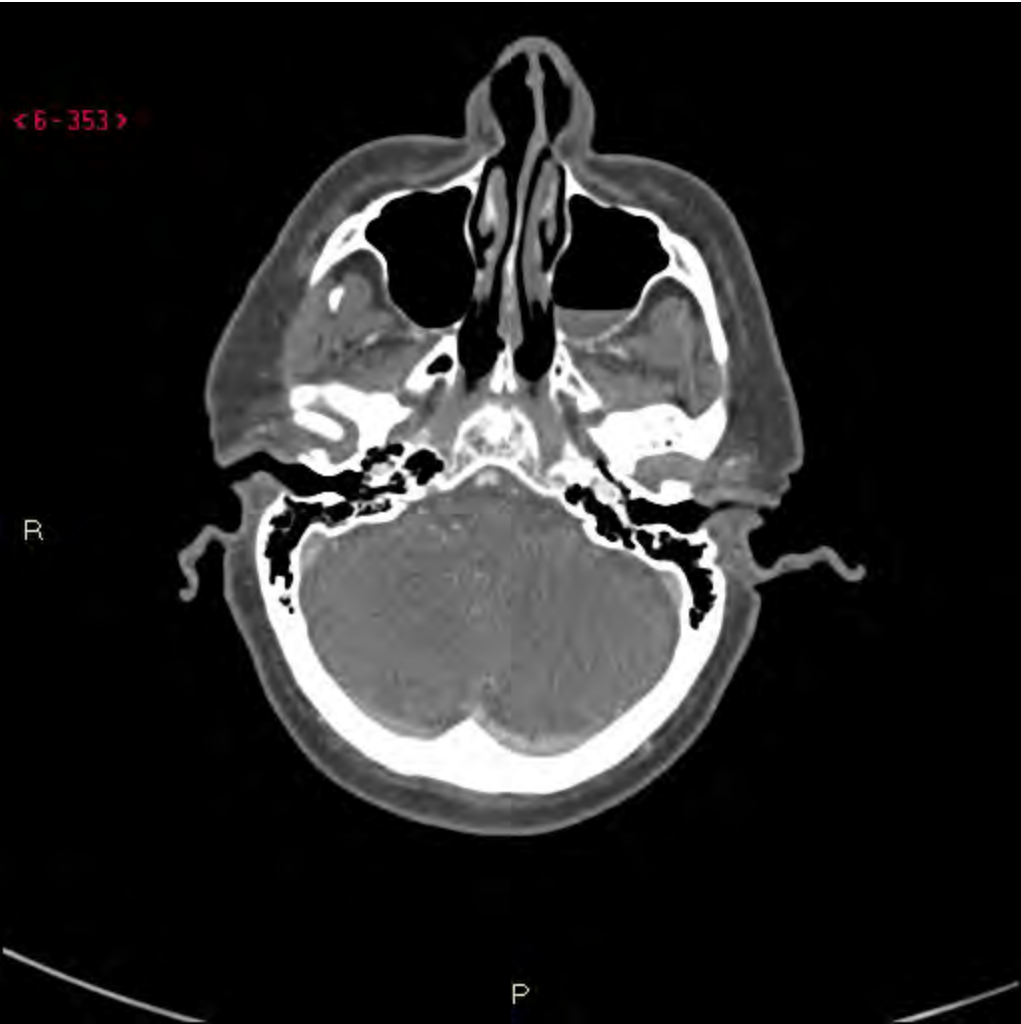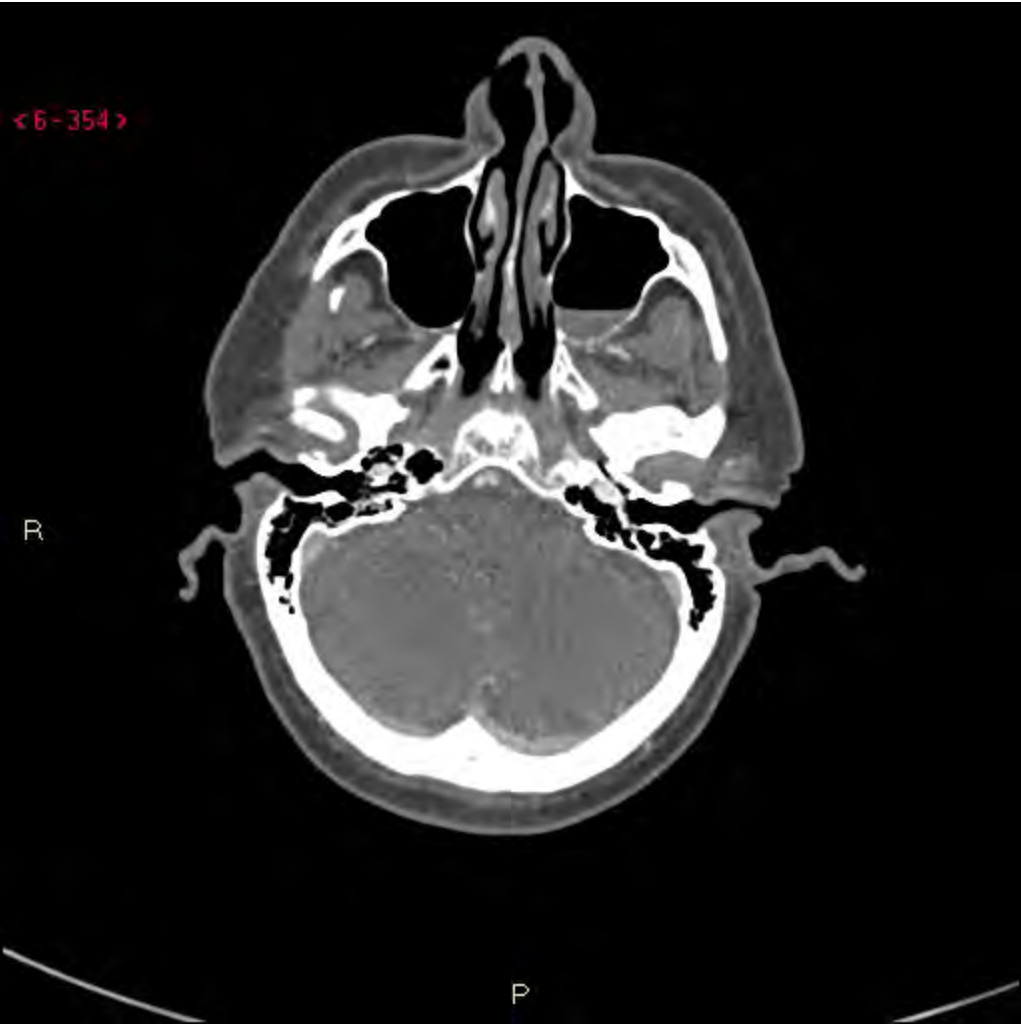


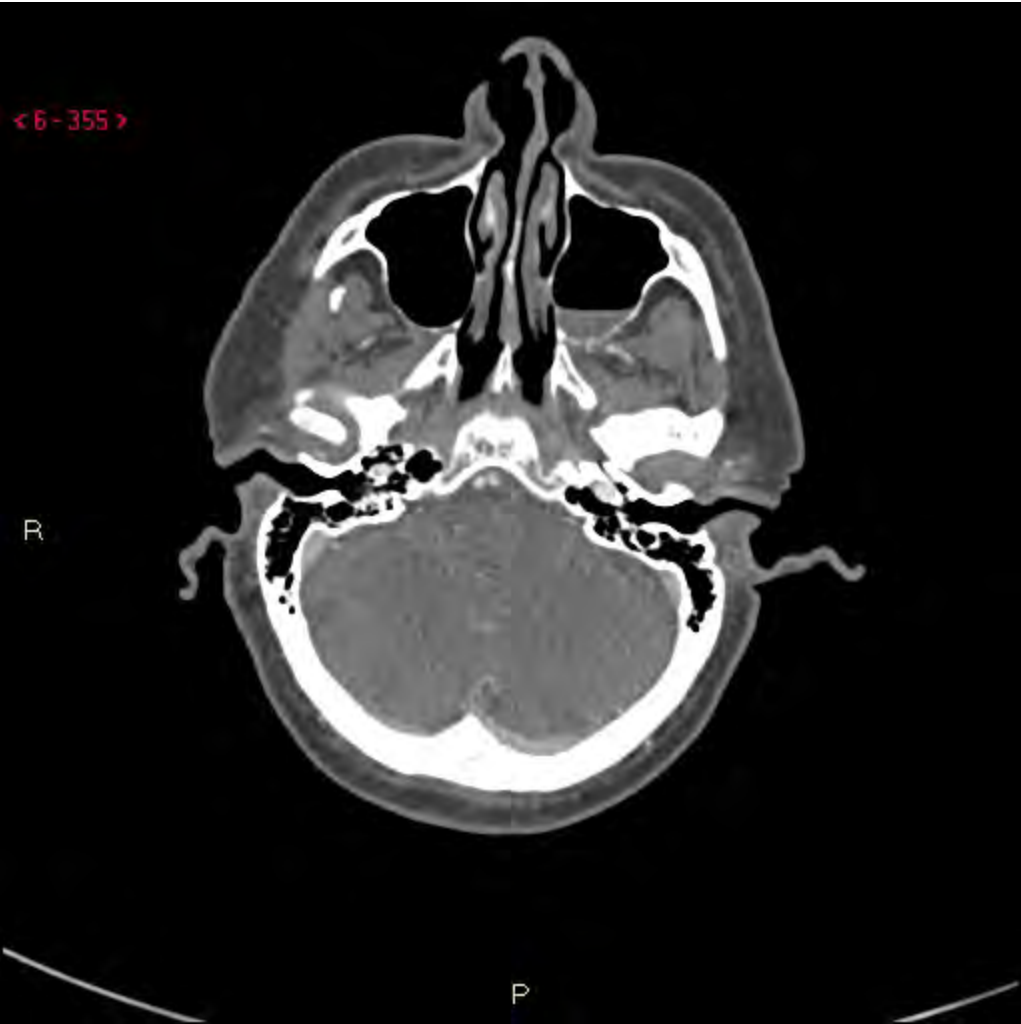


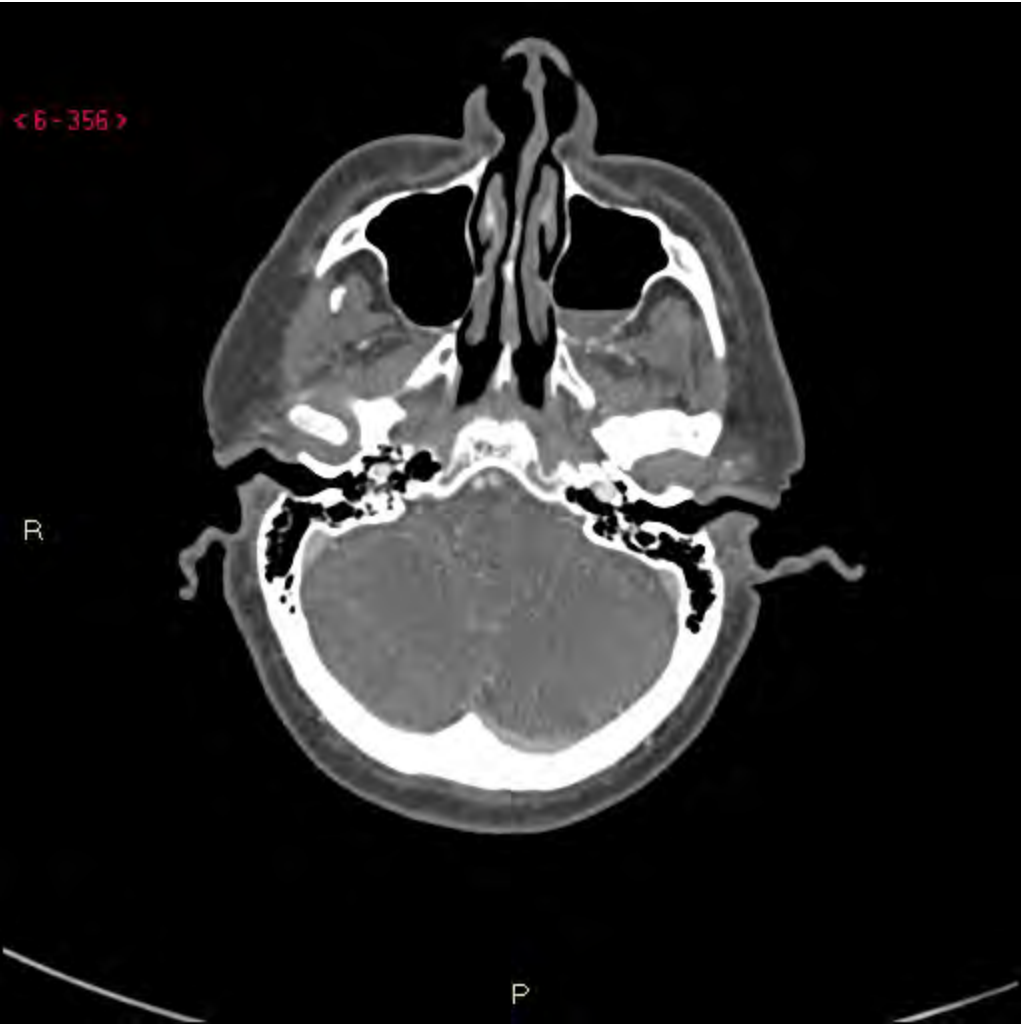


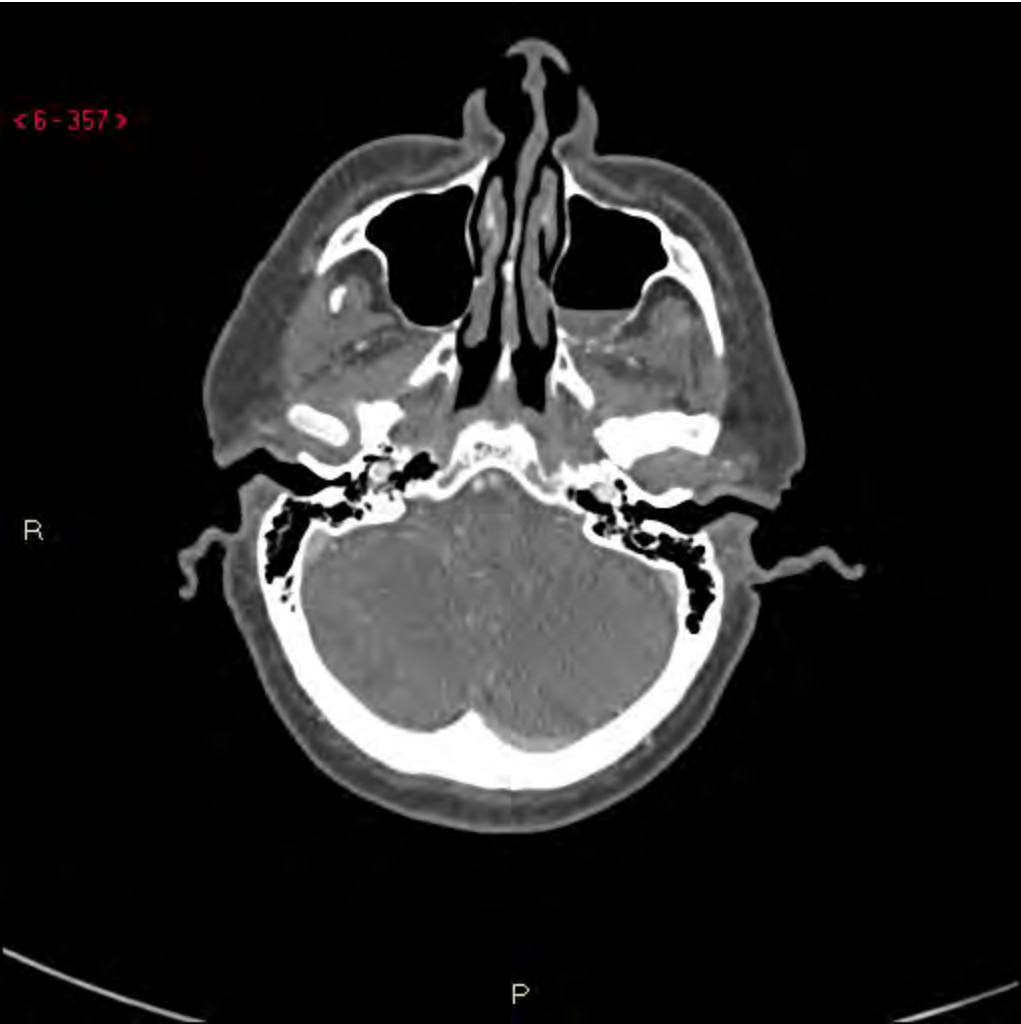




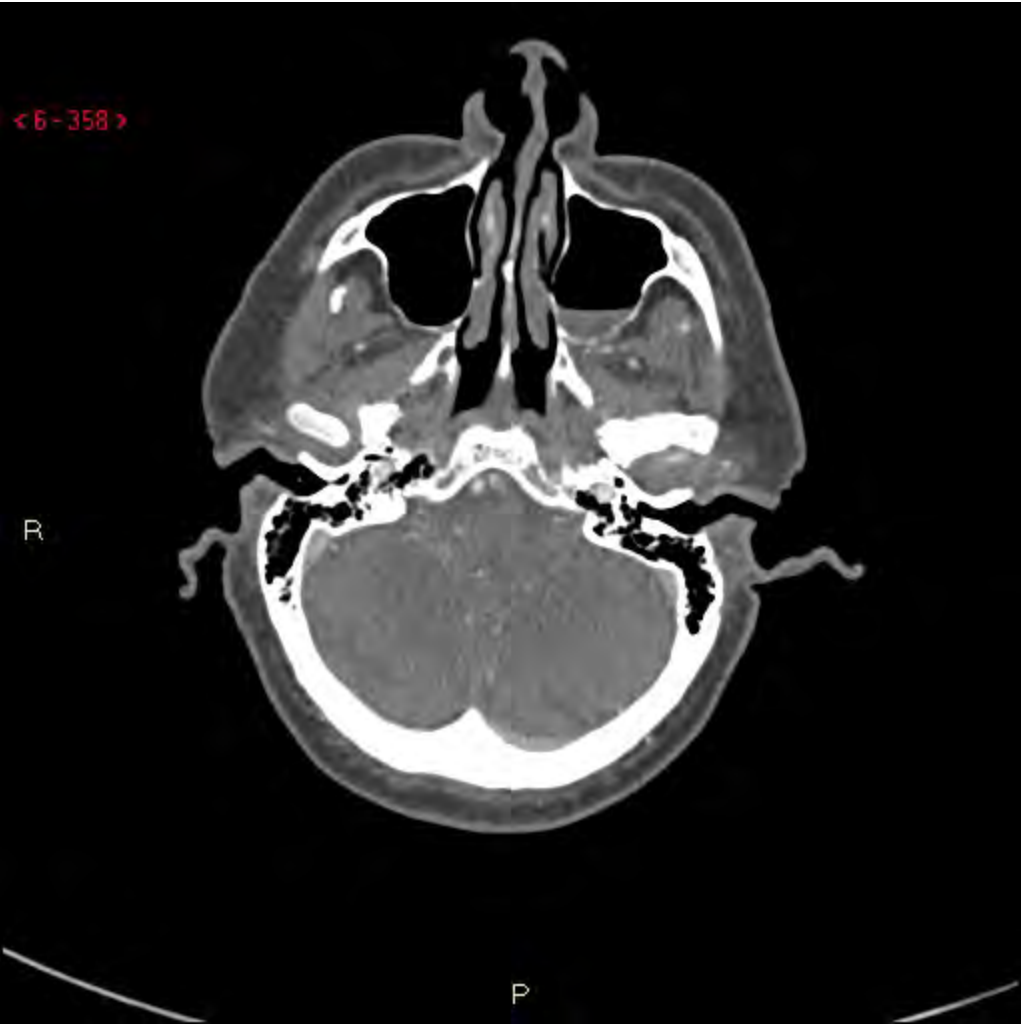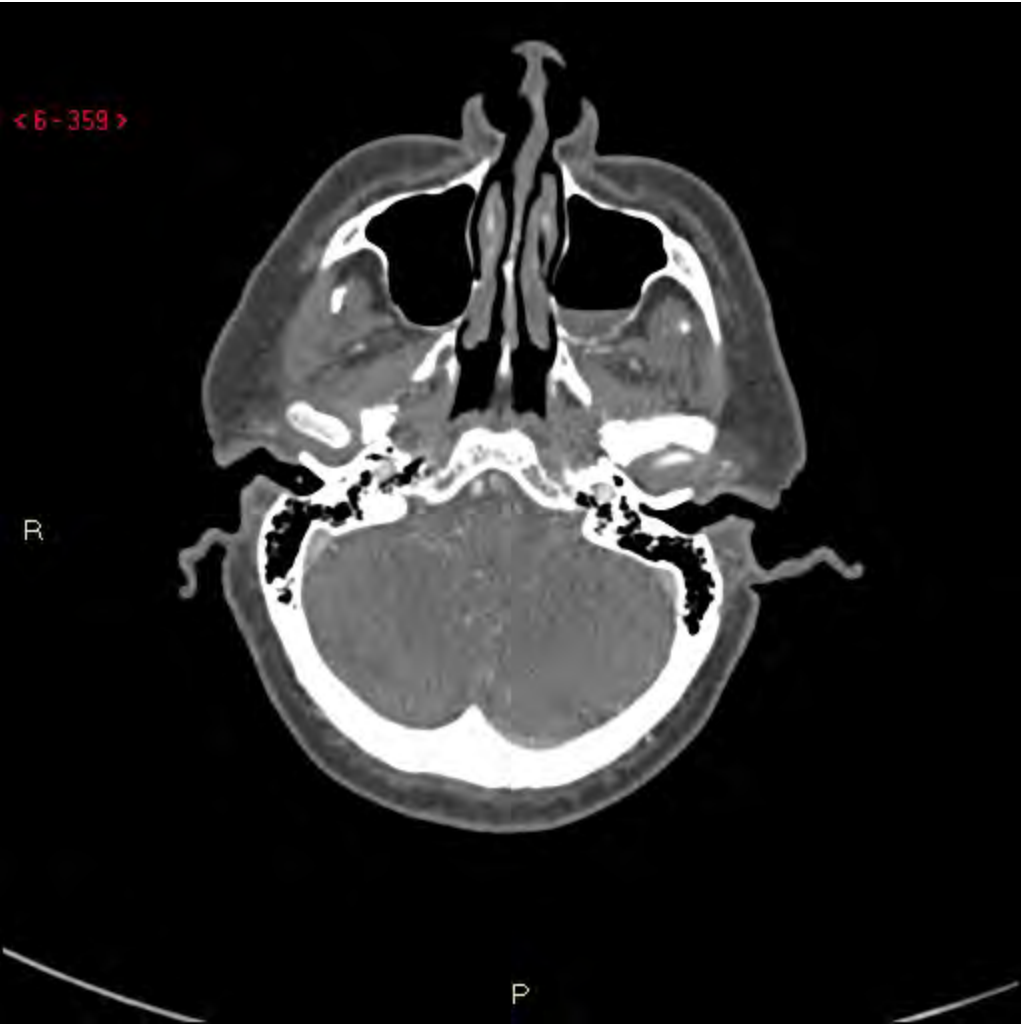






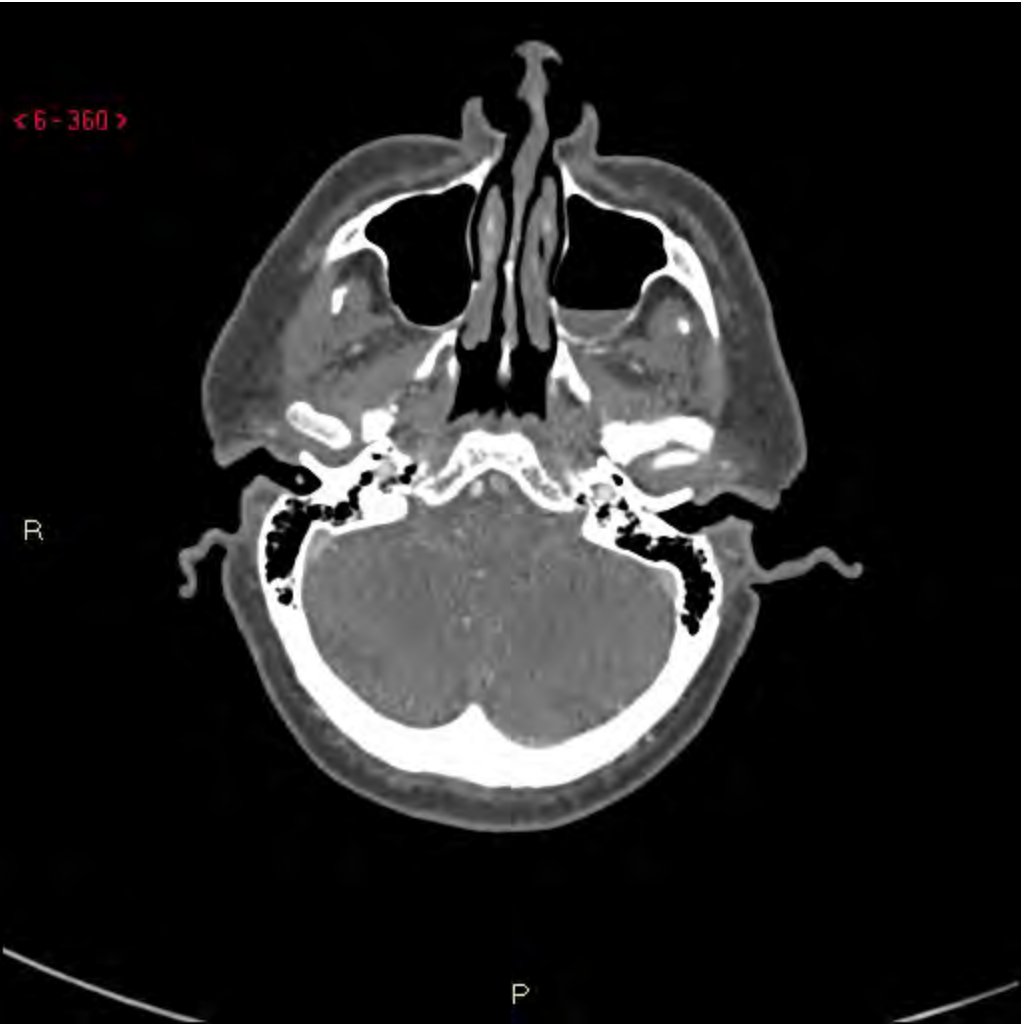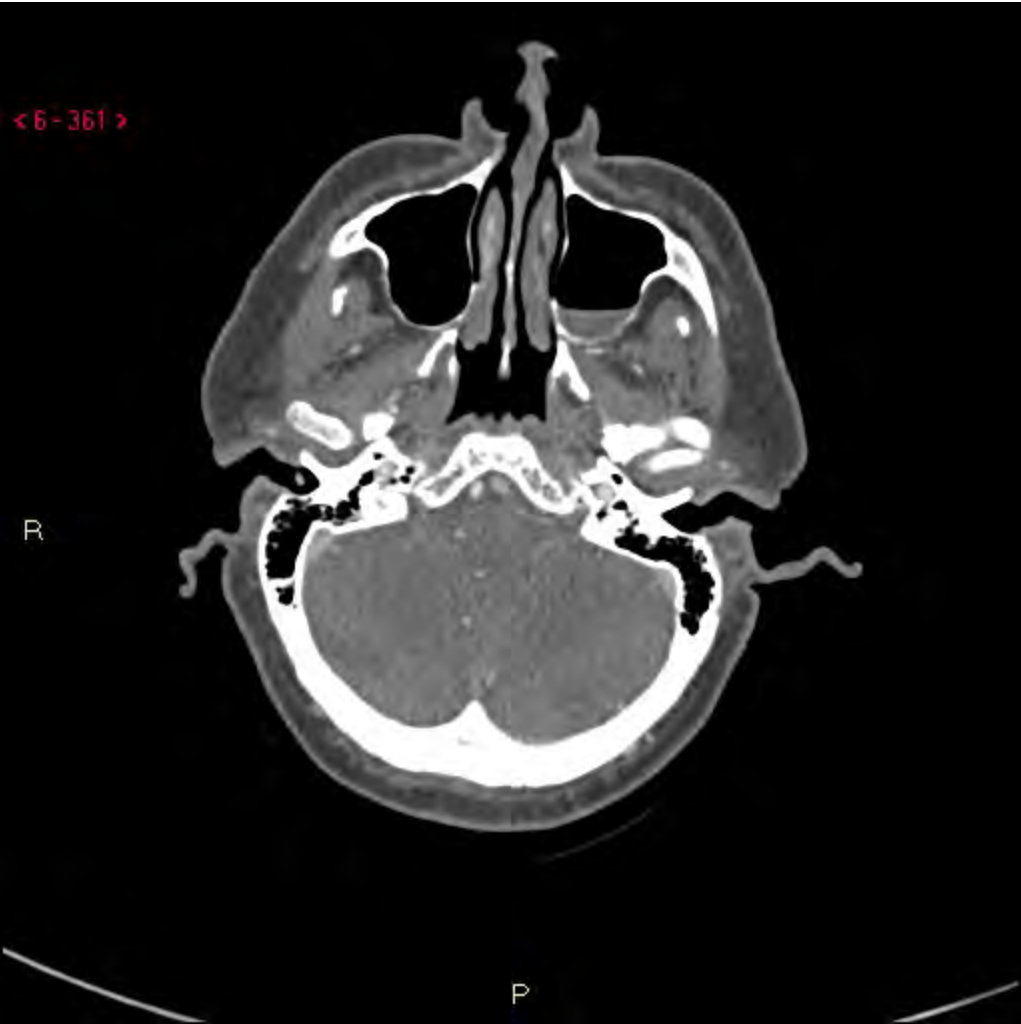


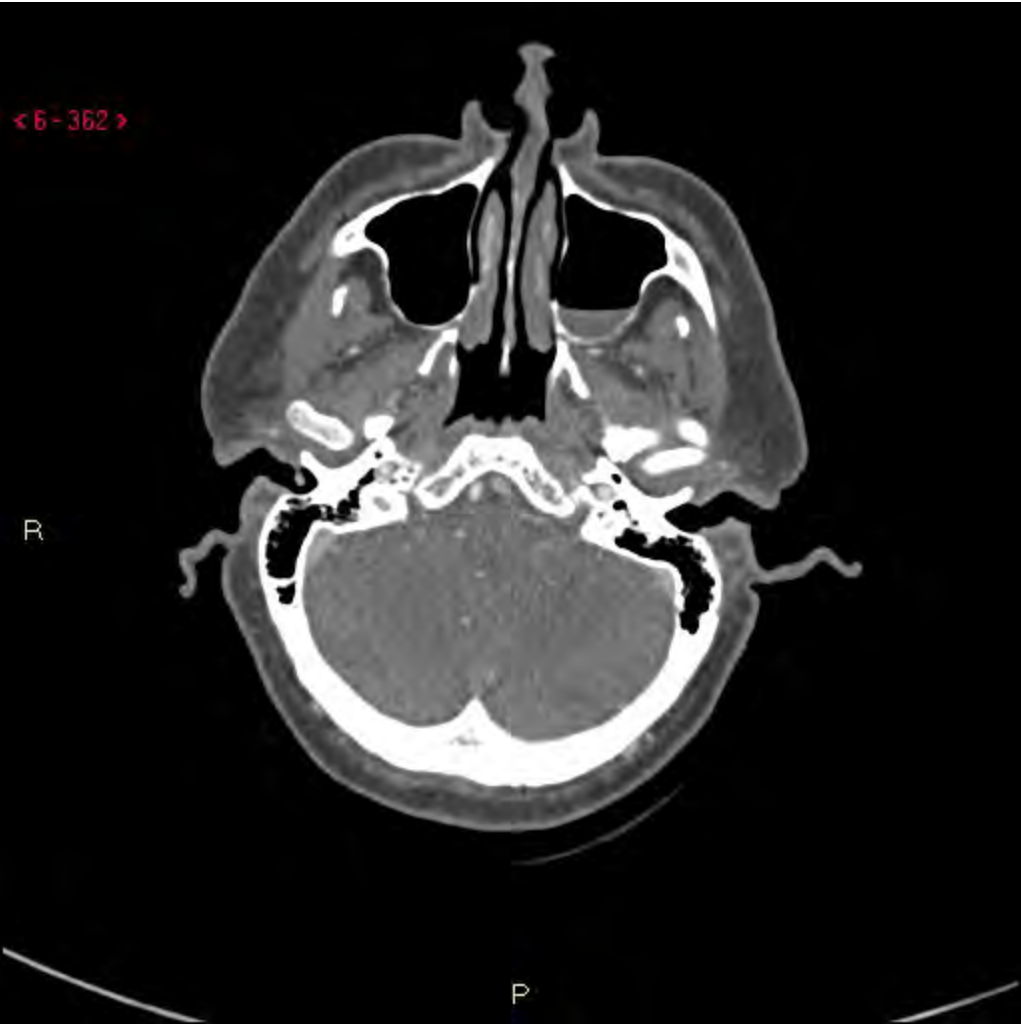


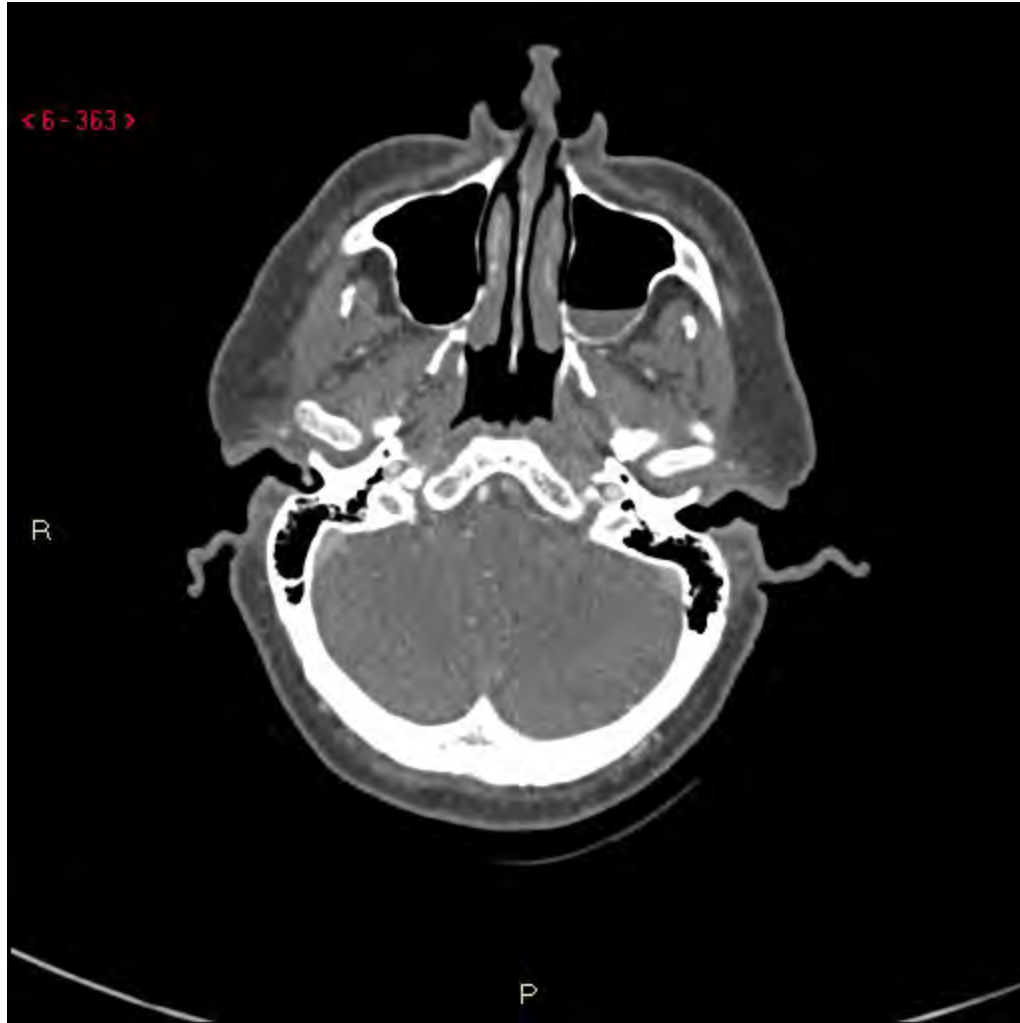


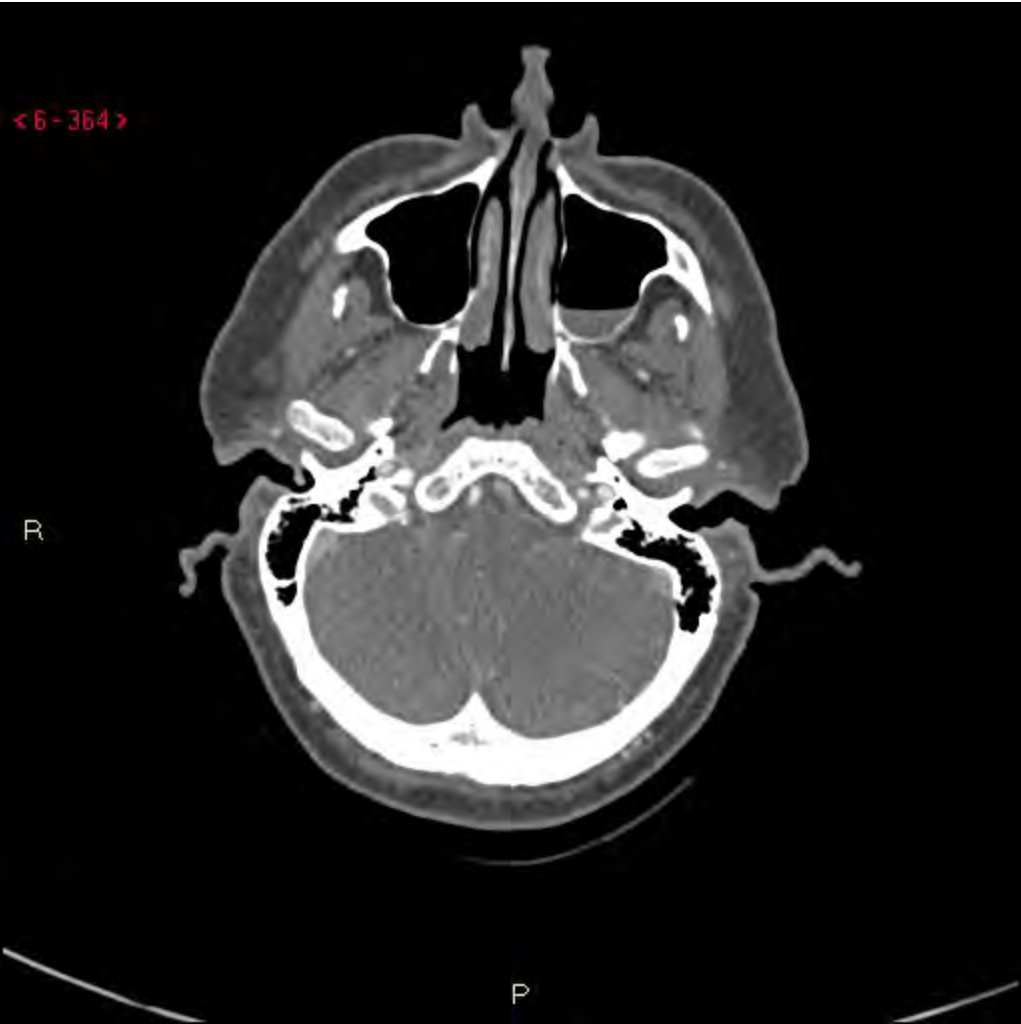


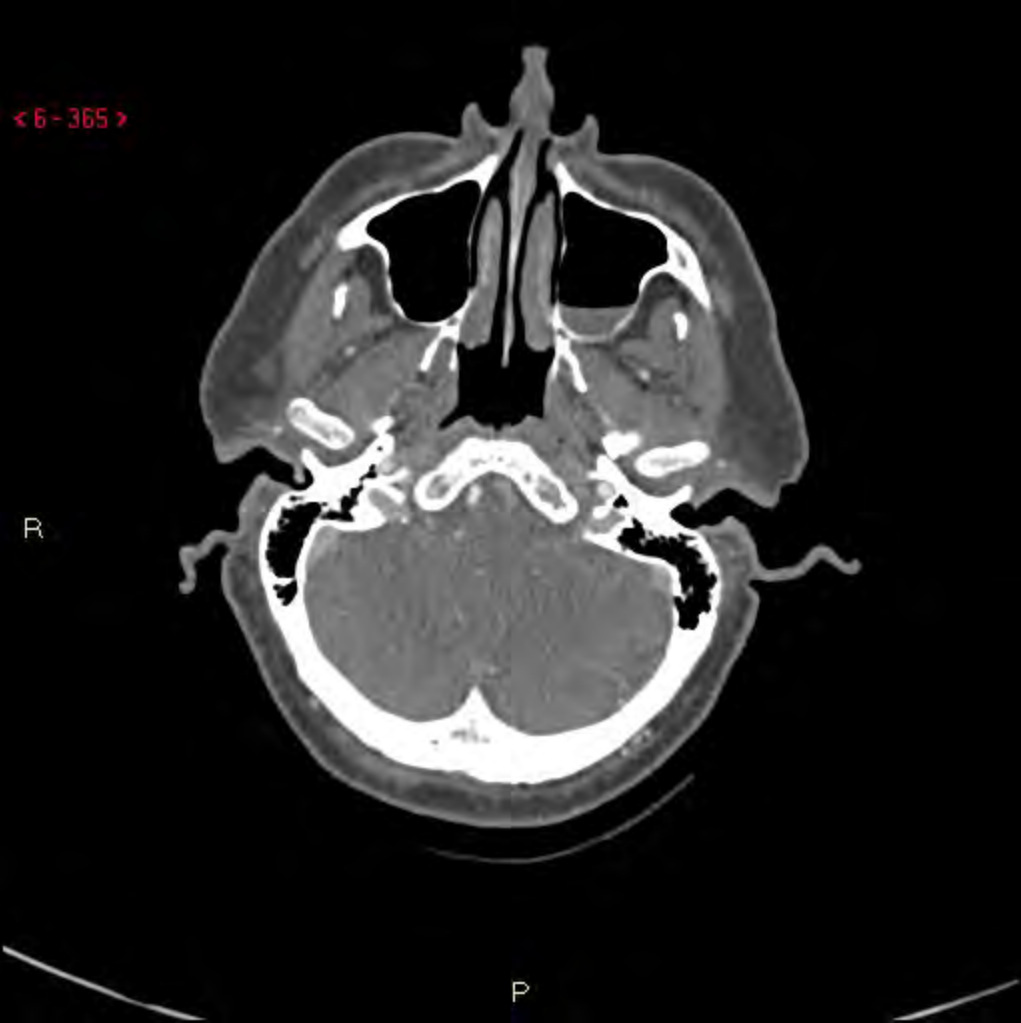


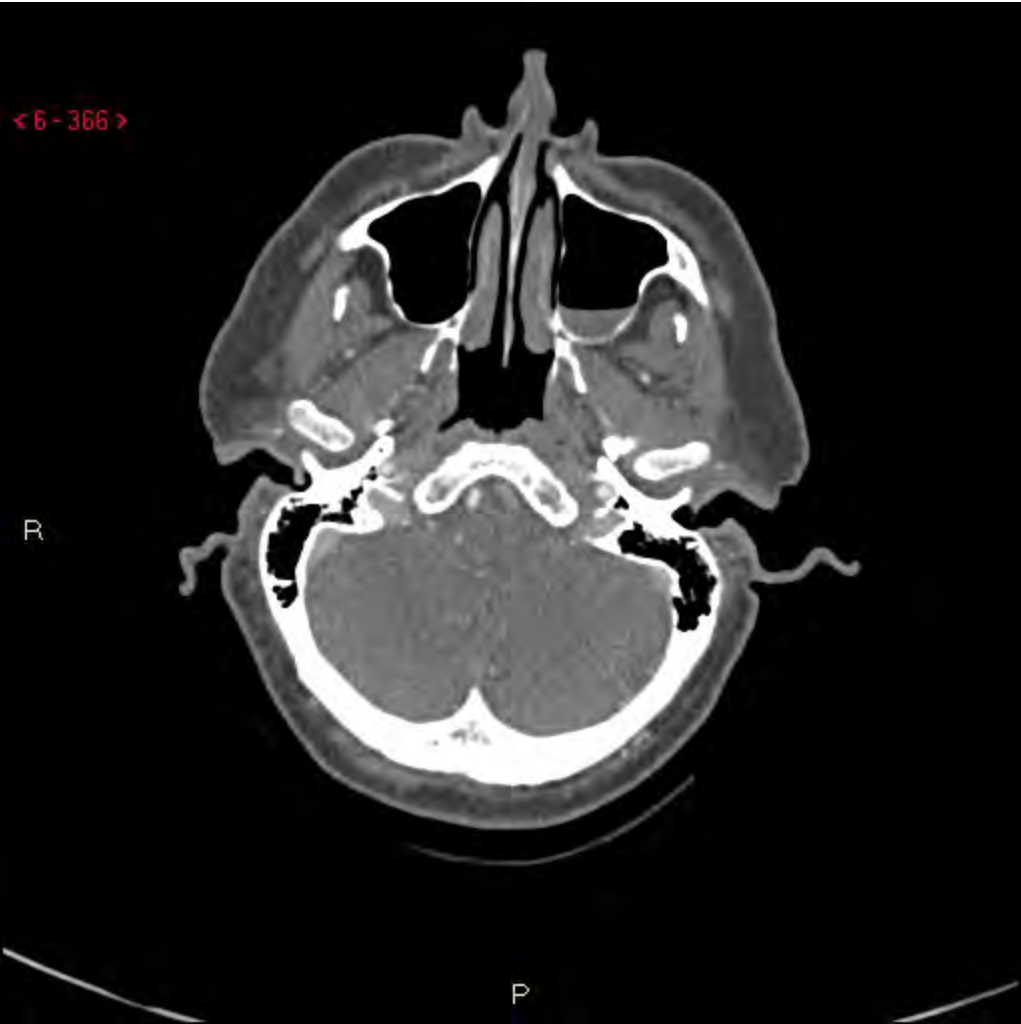




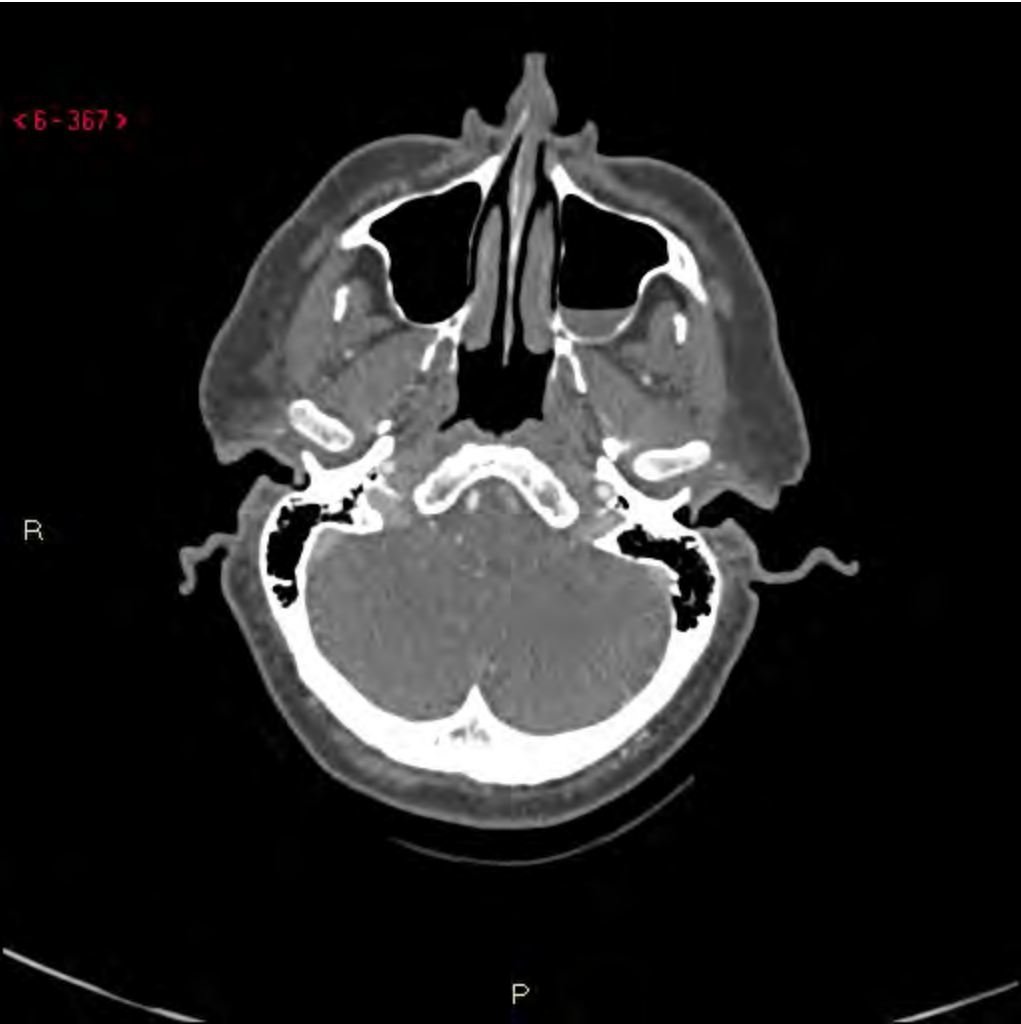


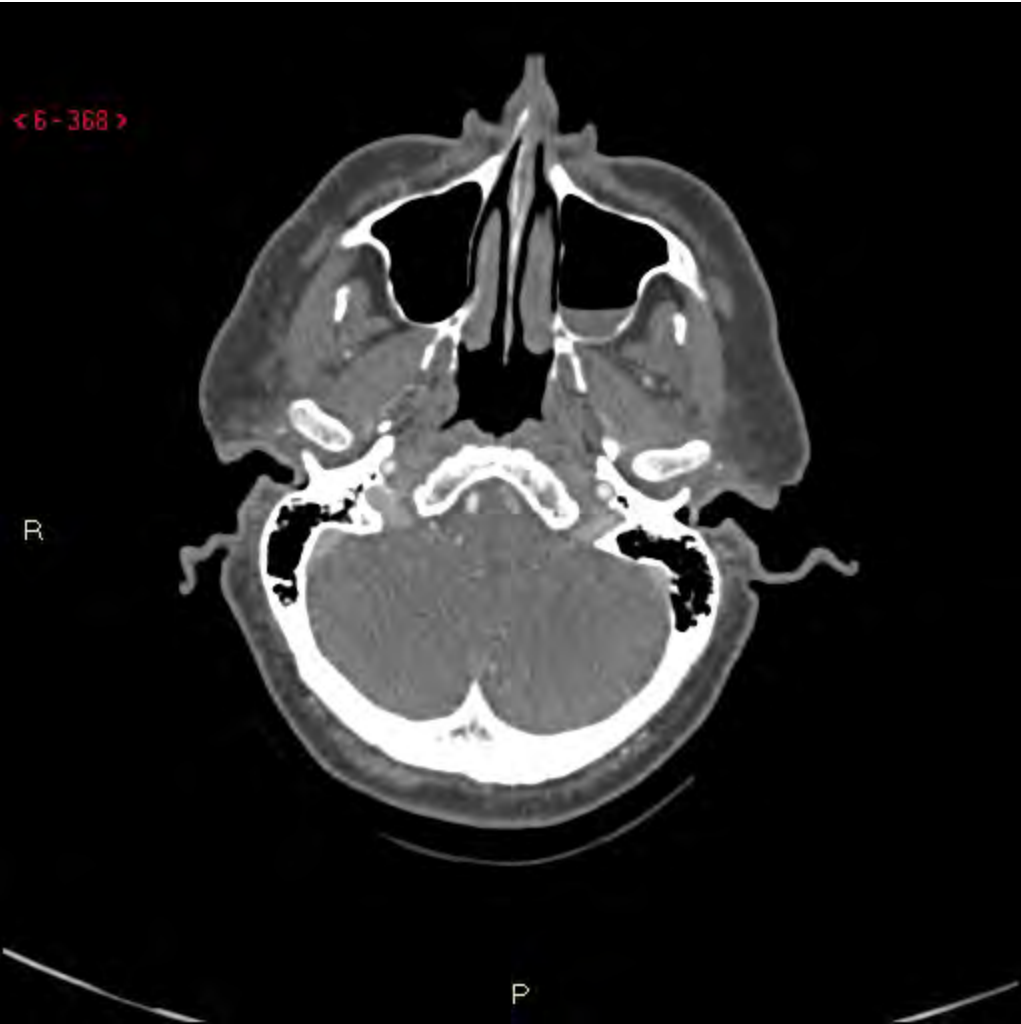








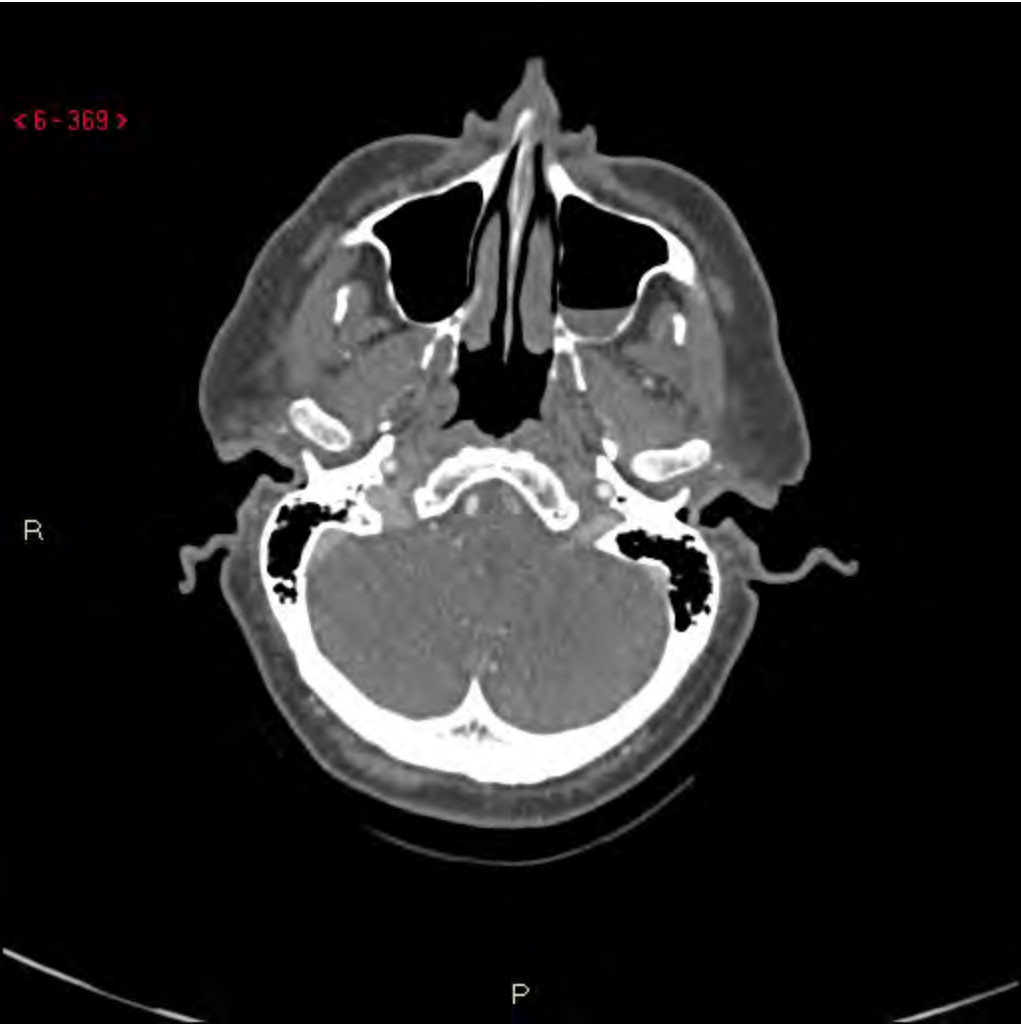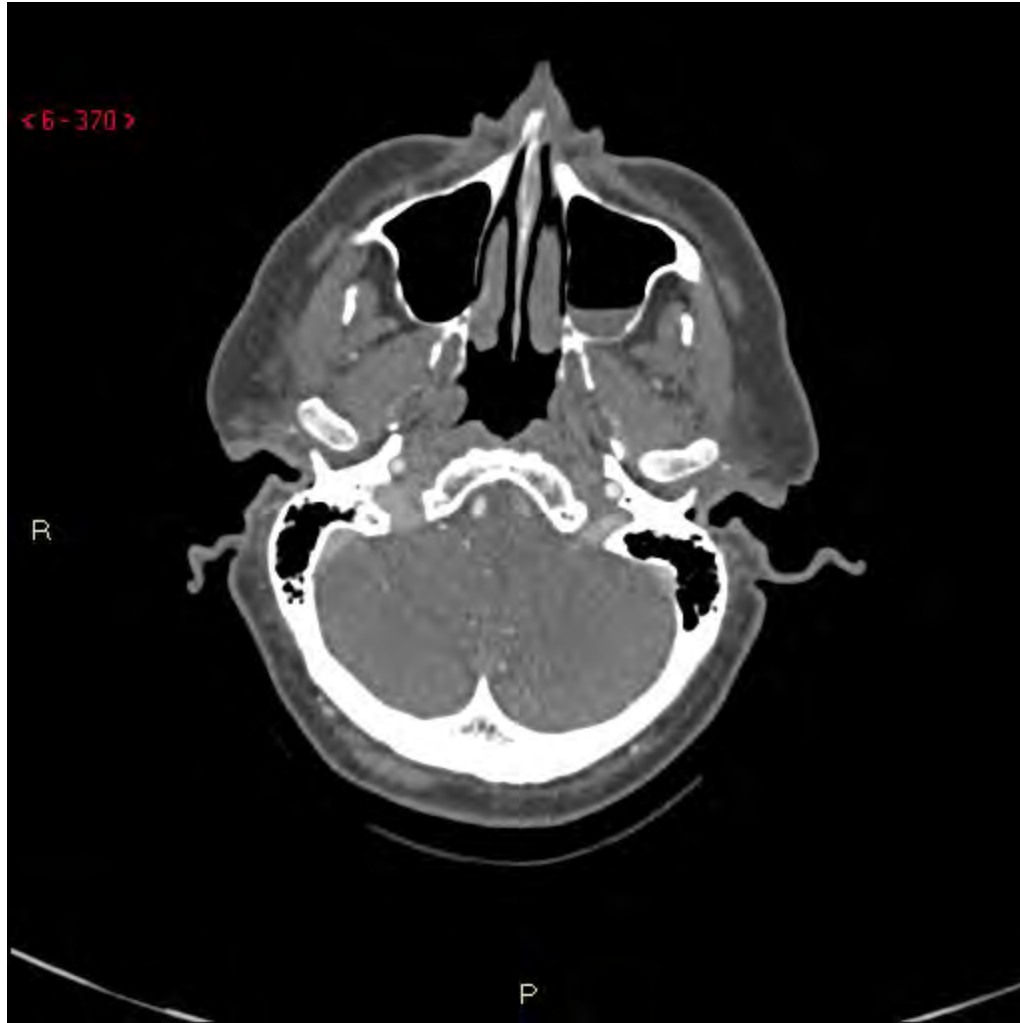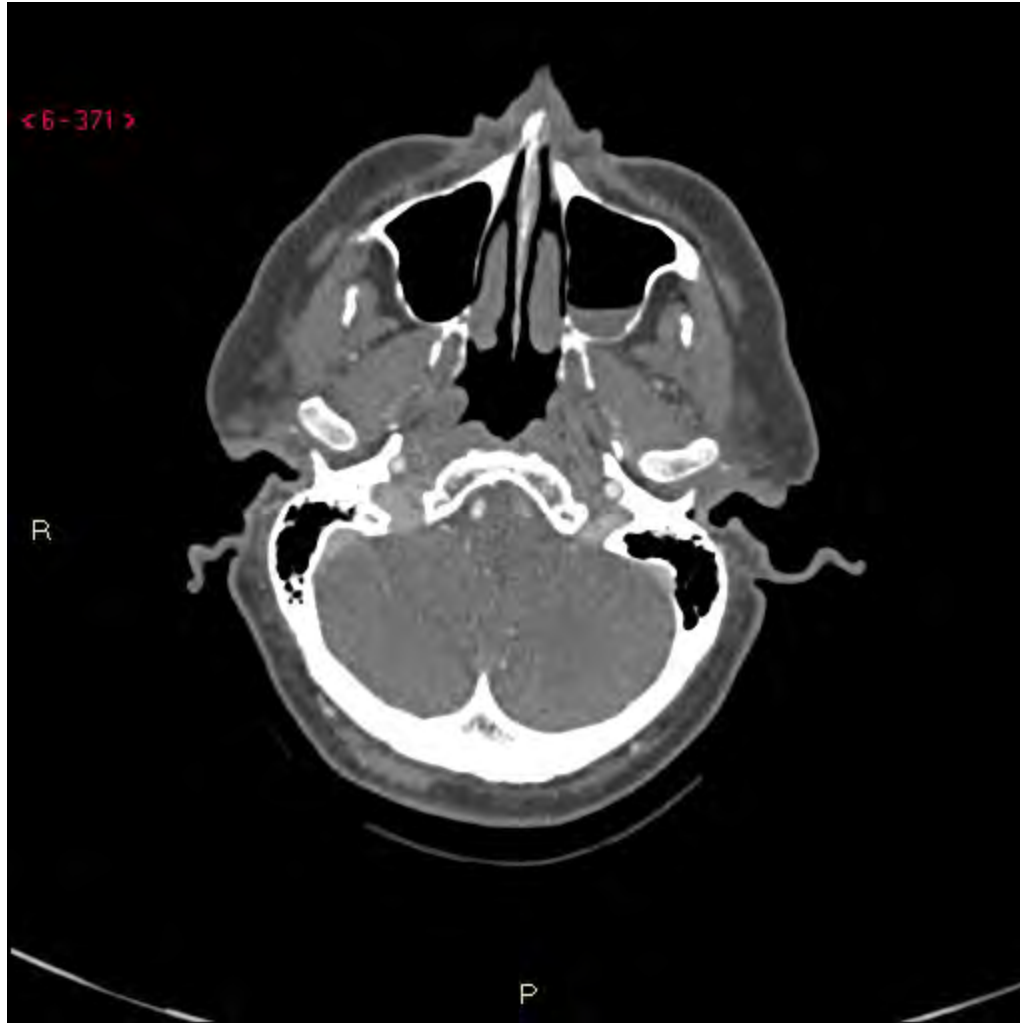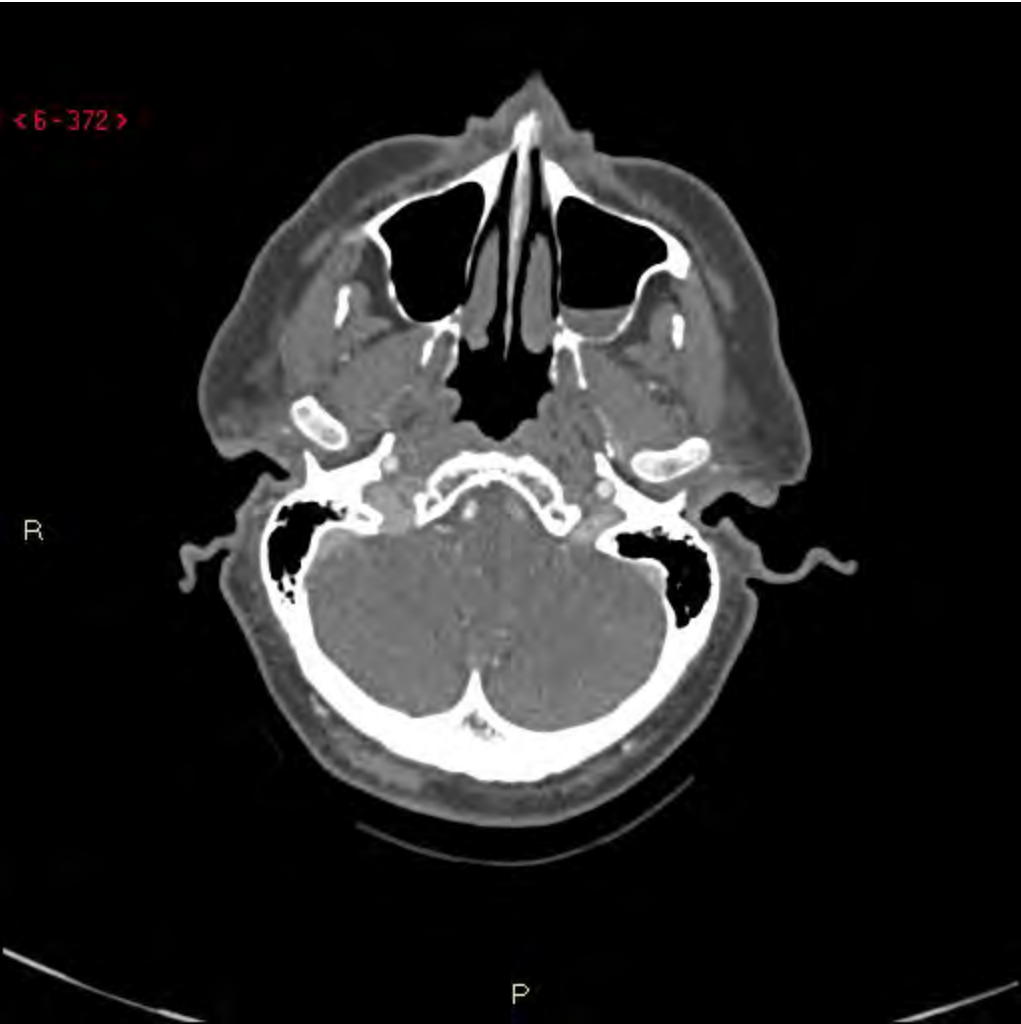














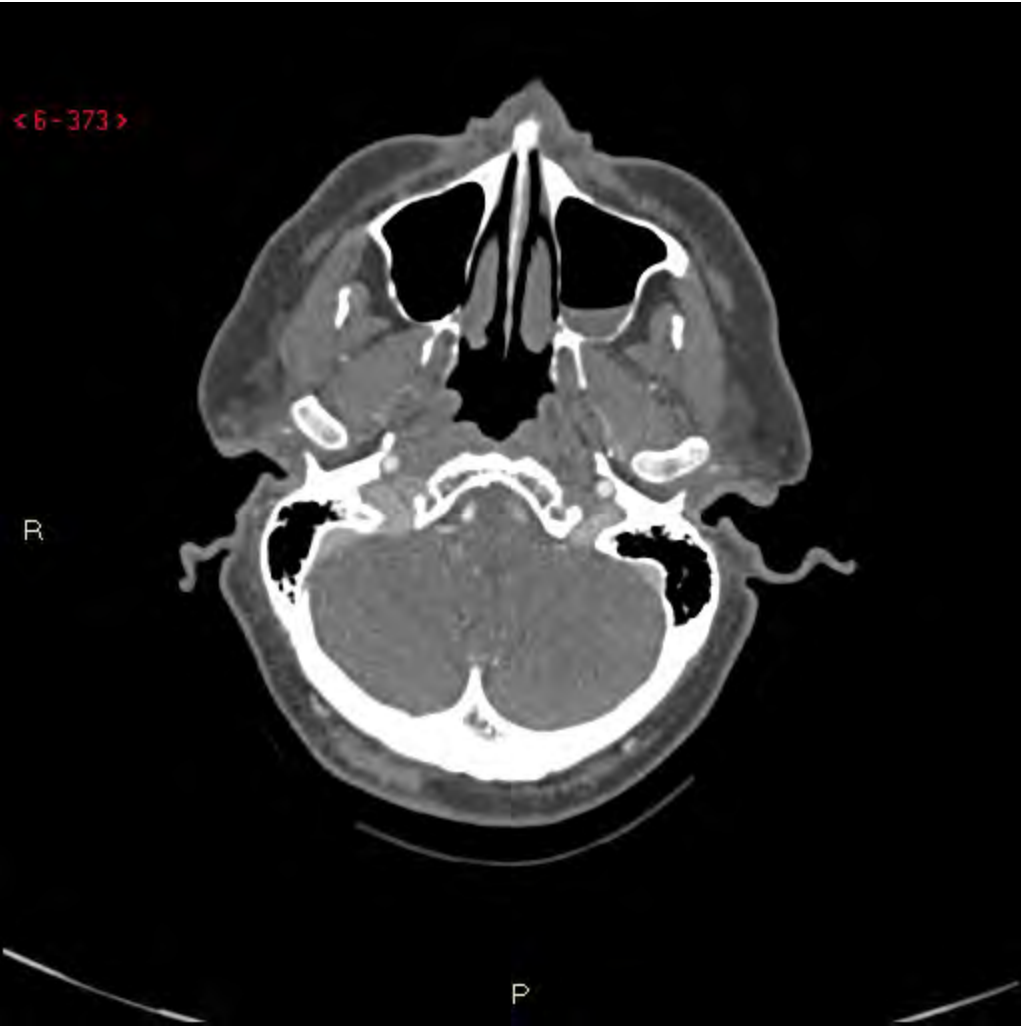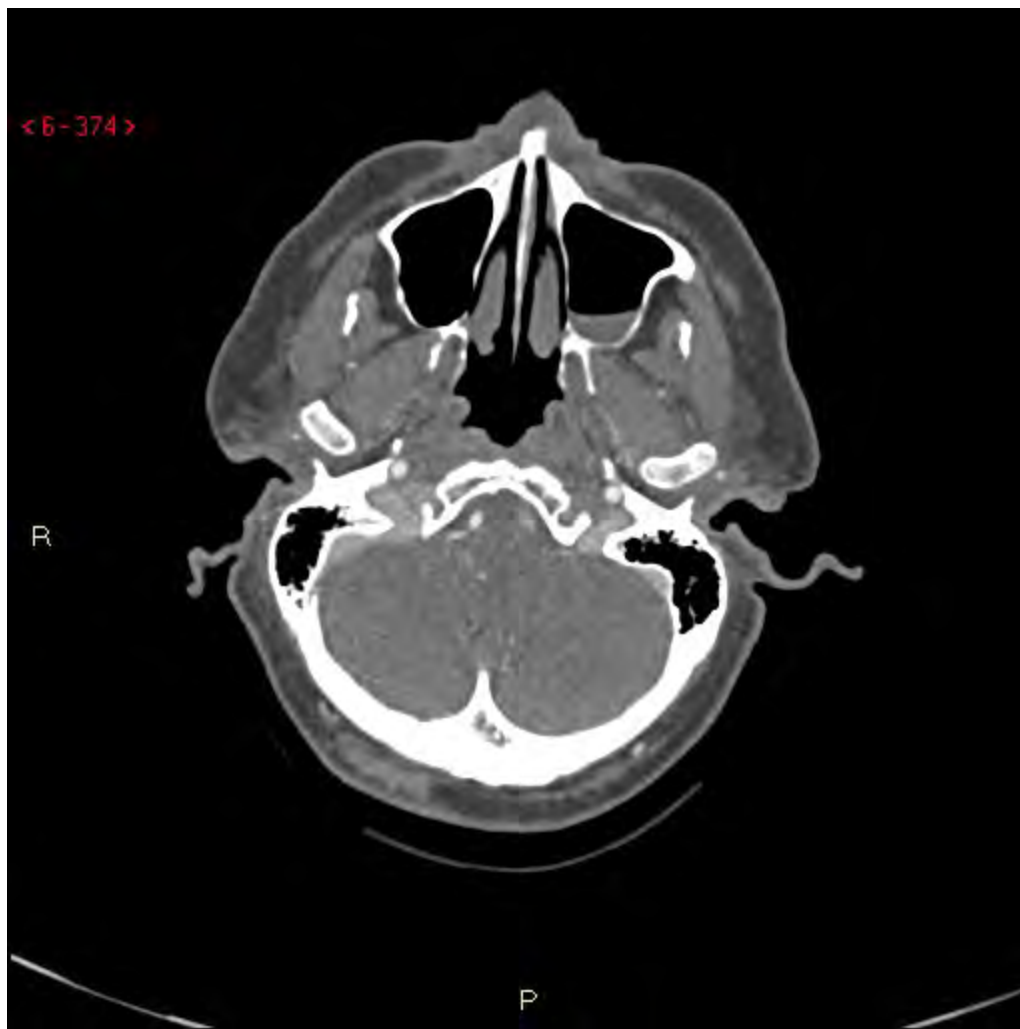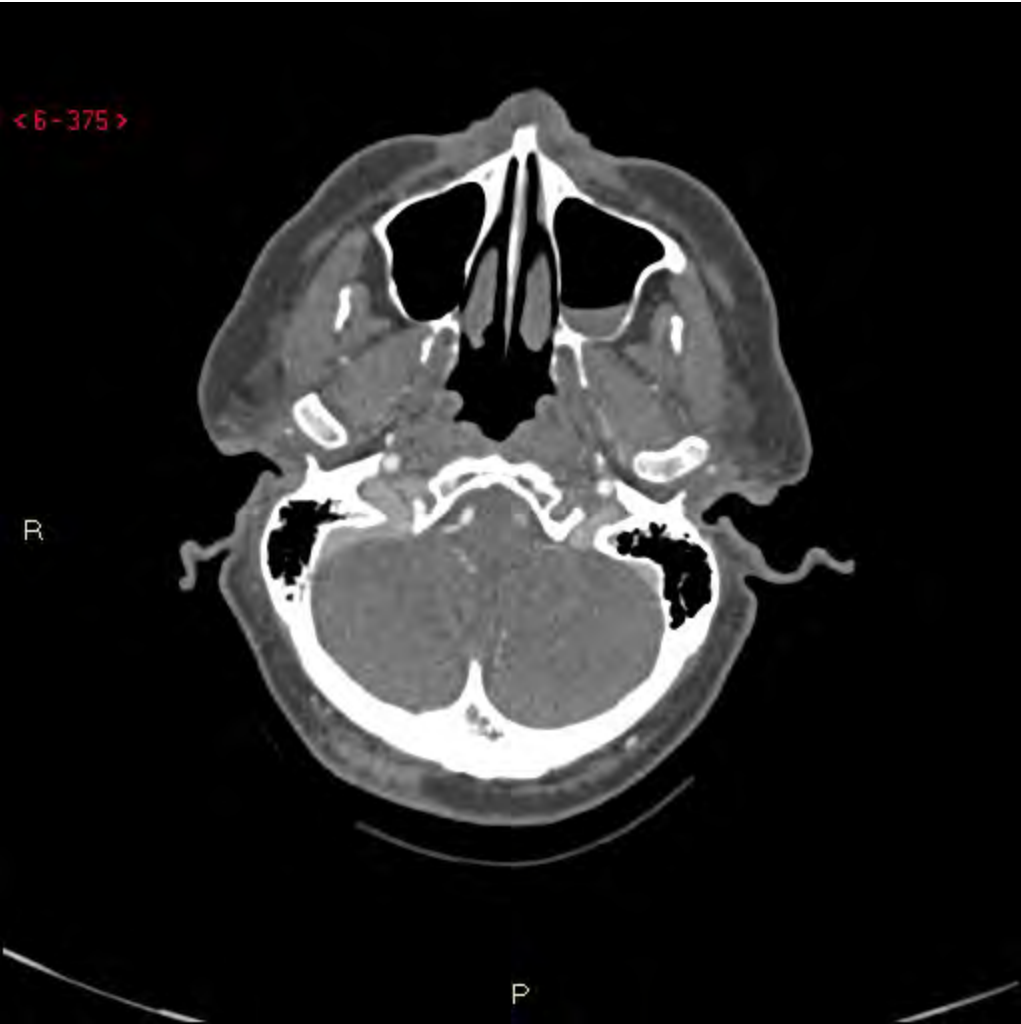
<6-374>

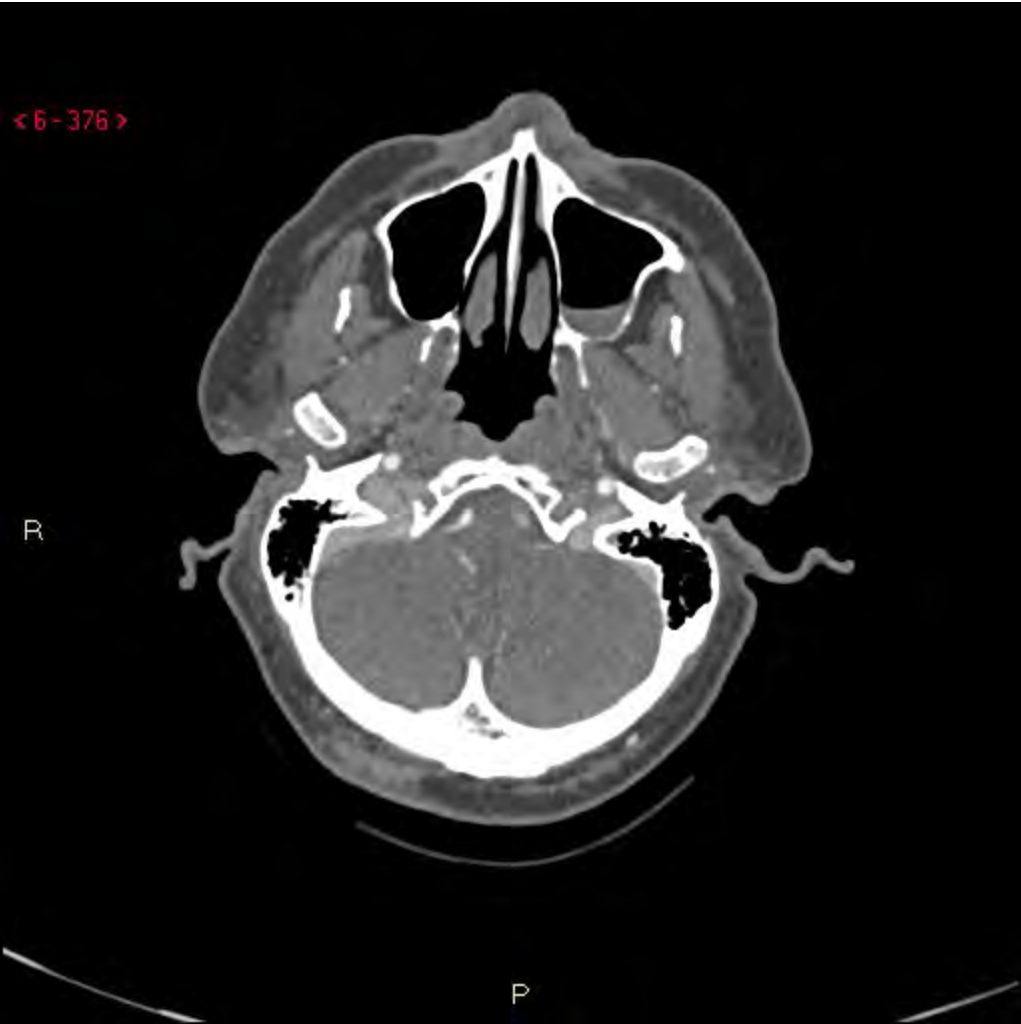R

P





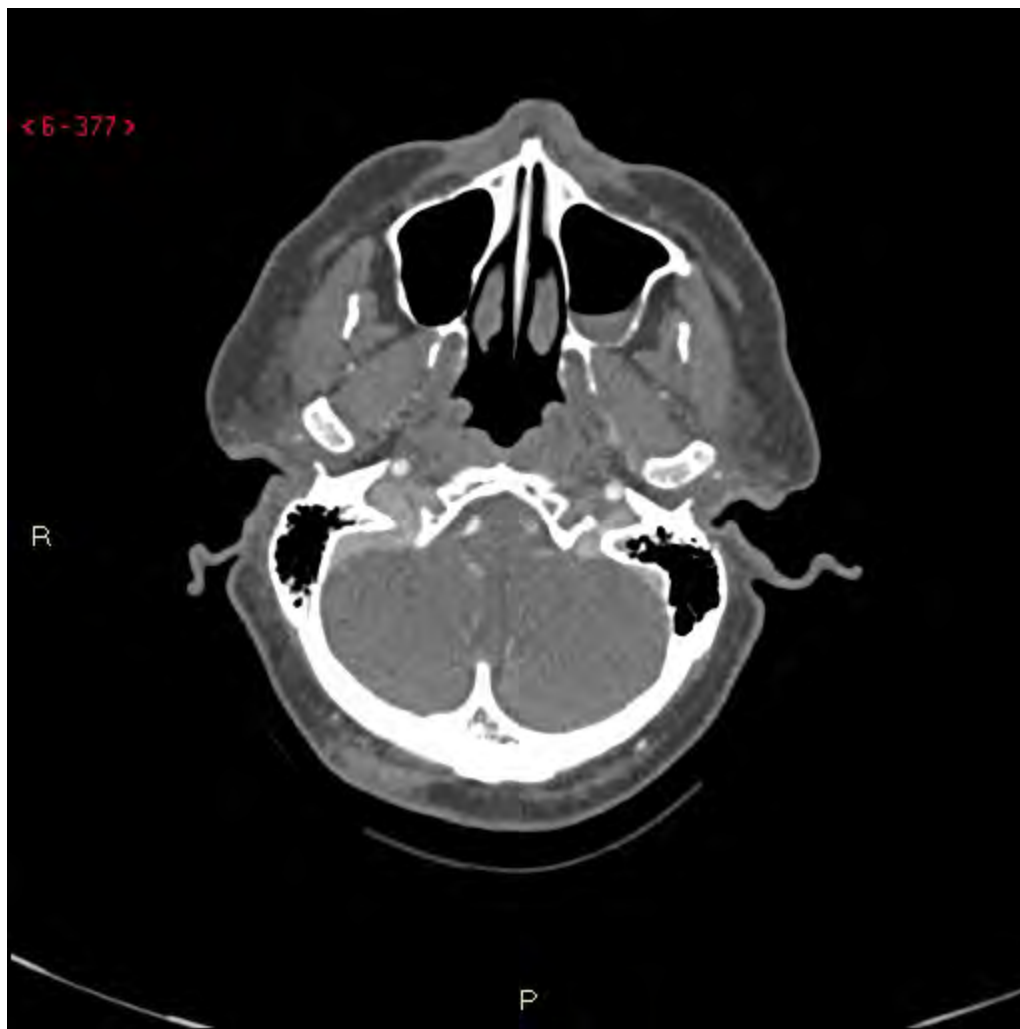



<6-377>

R

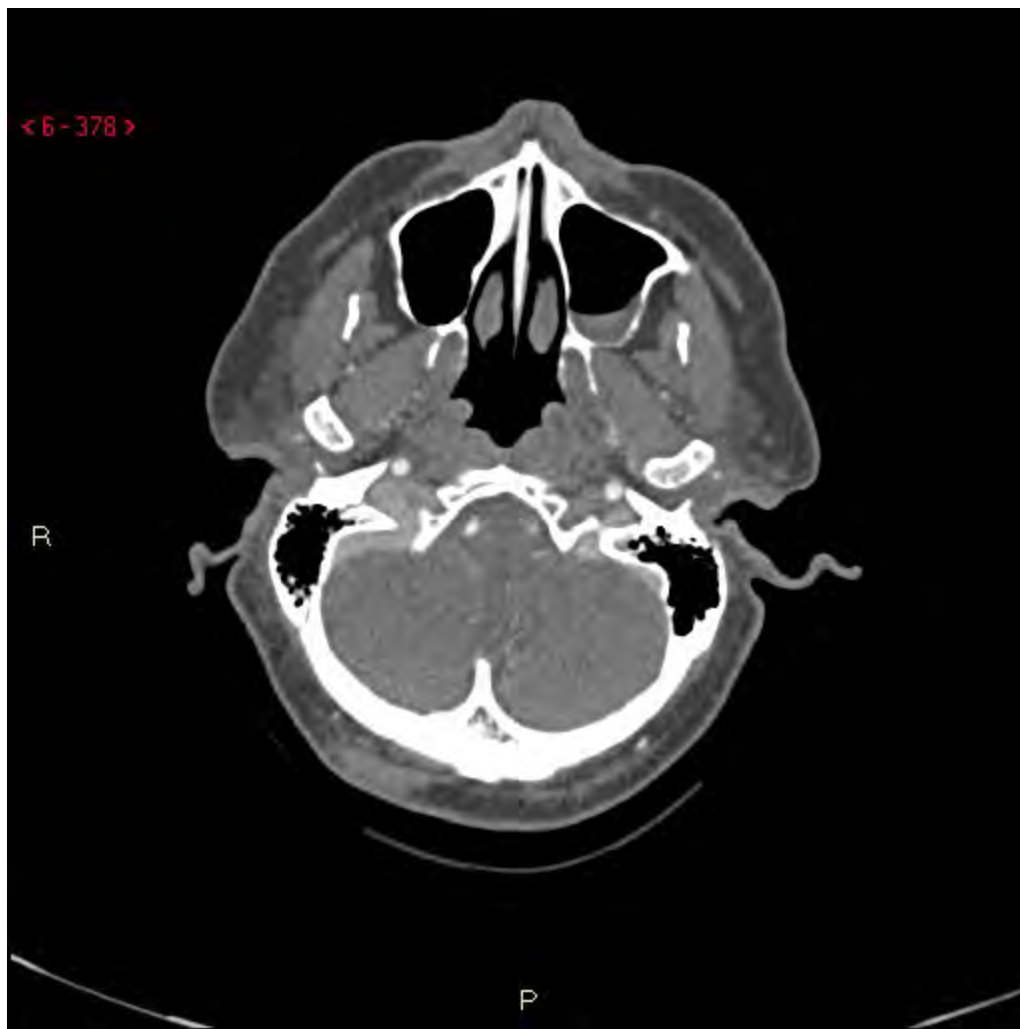P



< 6 - 378 >

R

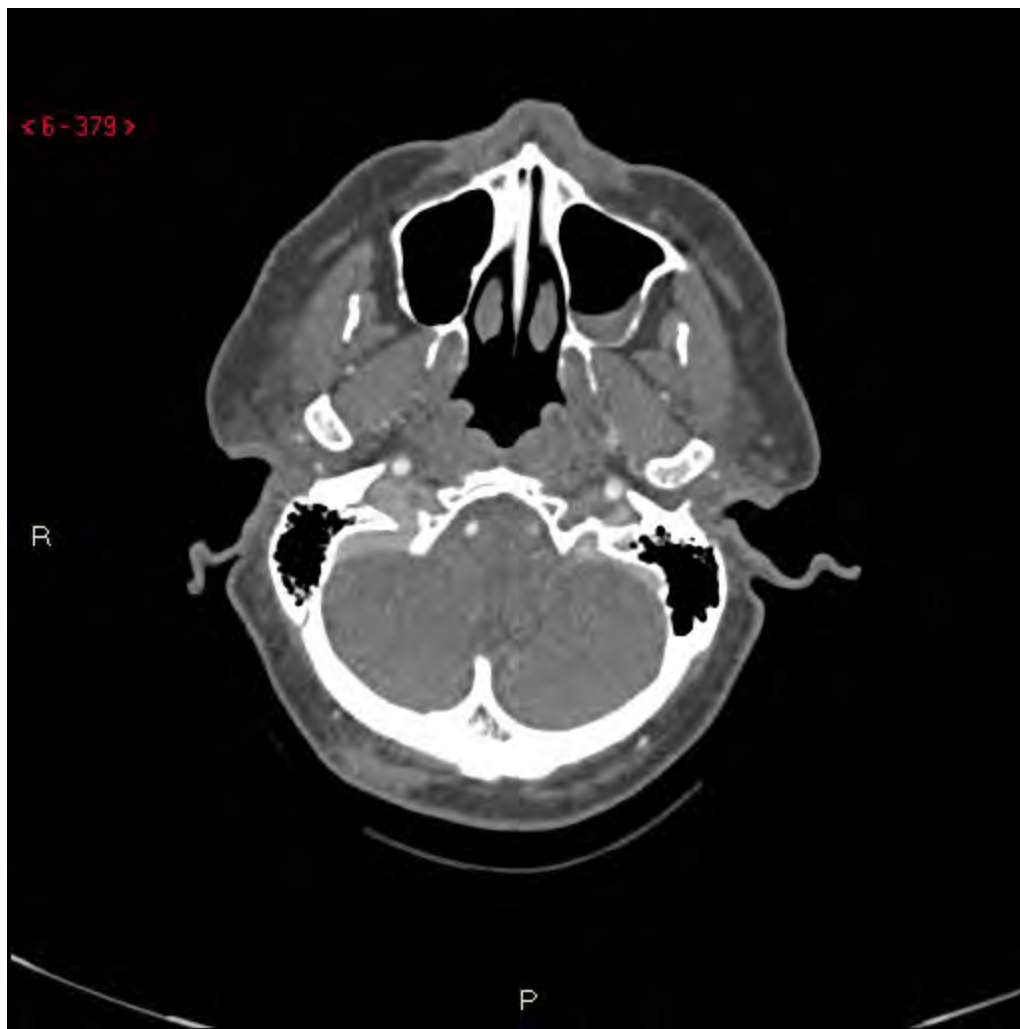P



< 6-379 >

R

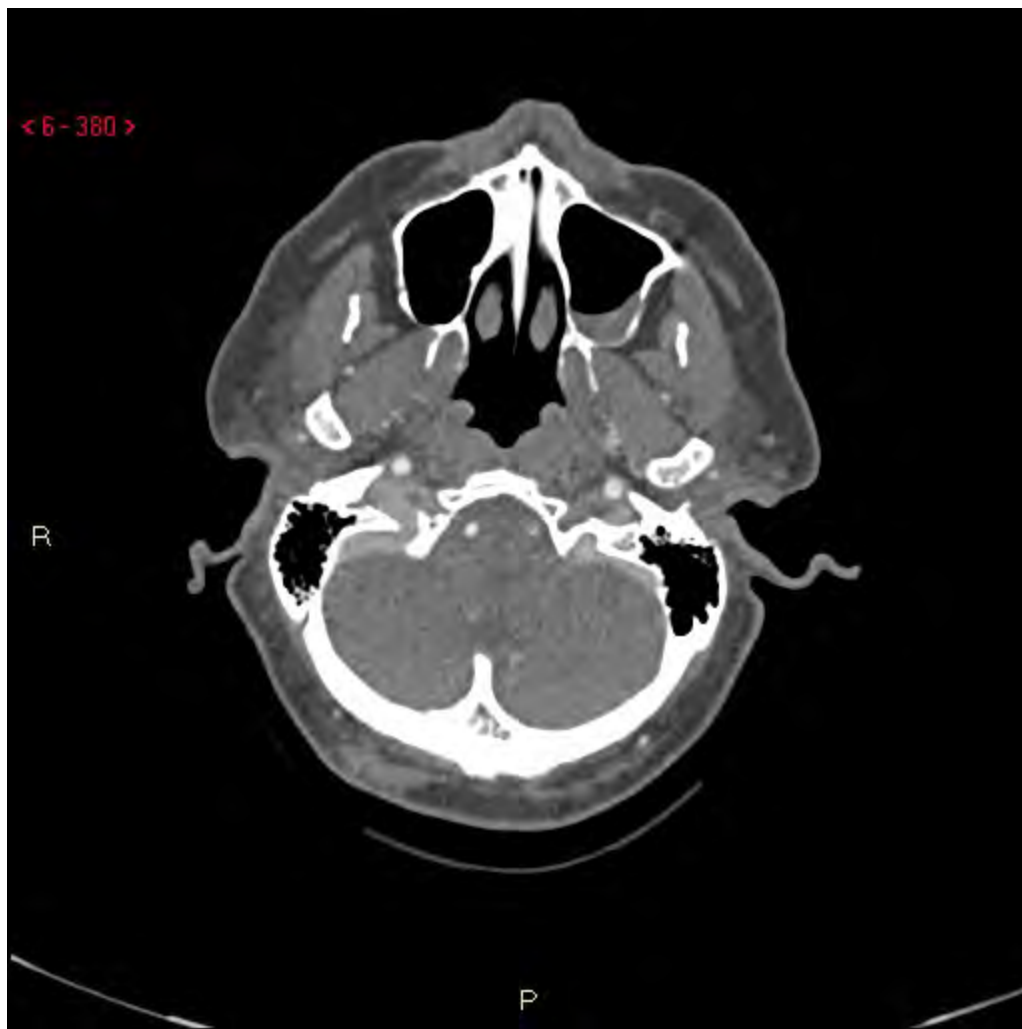P



< 6 - 380 >

R

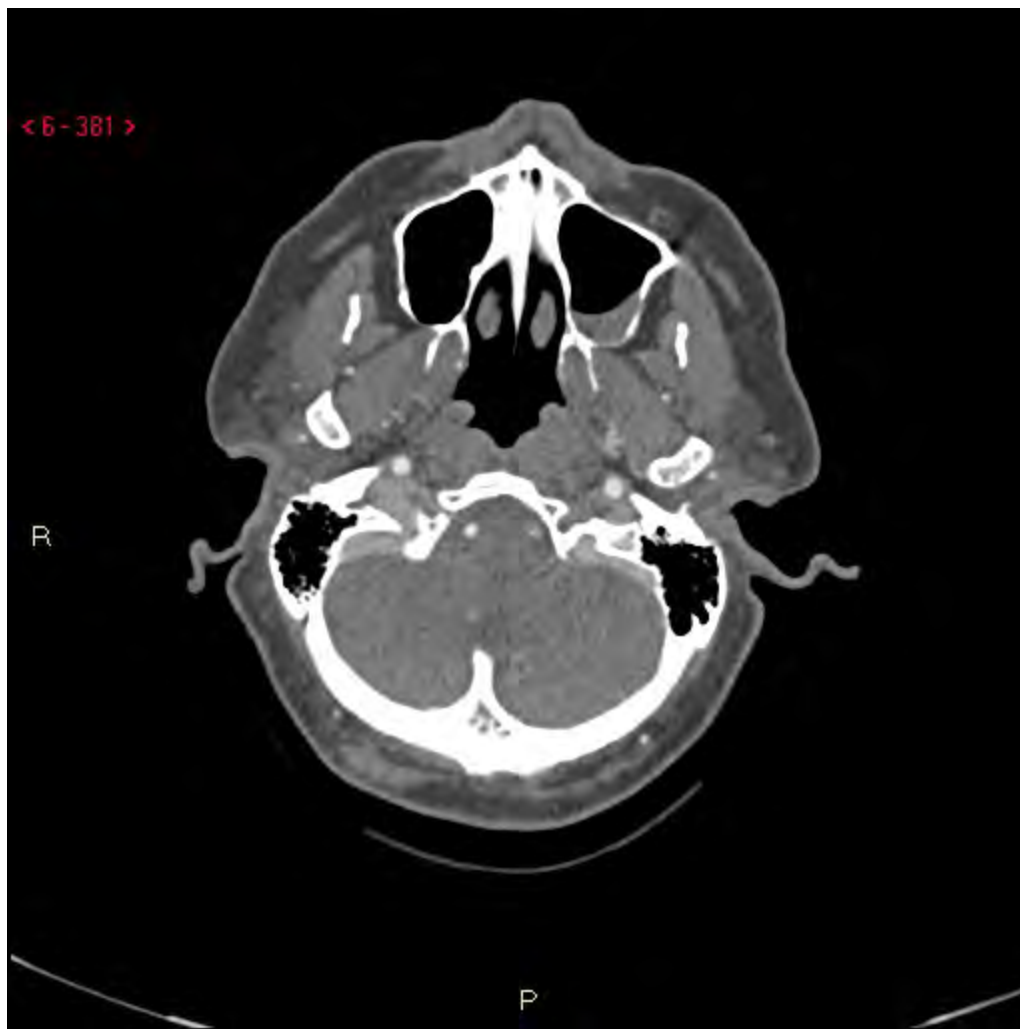P



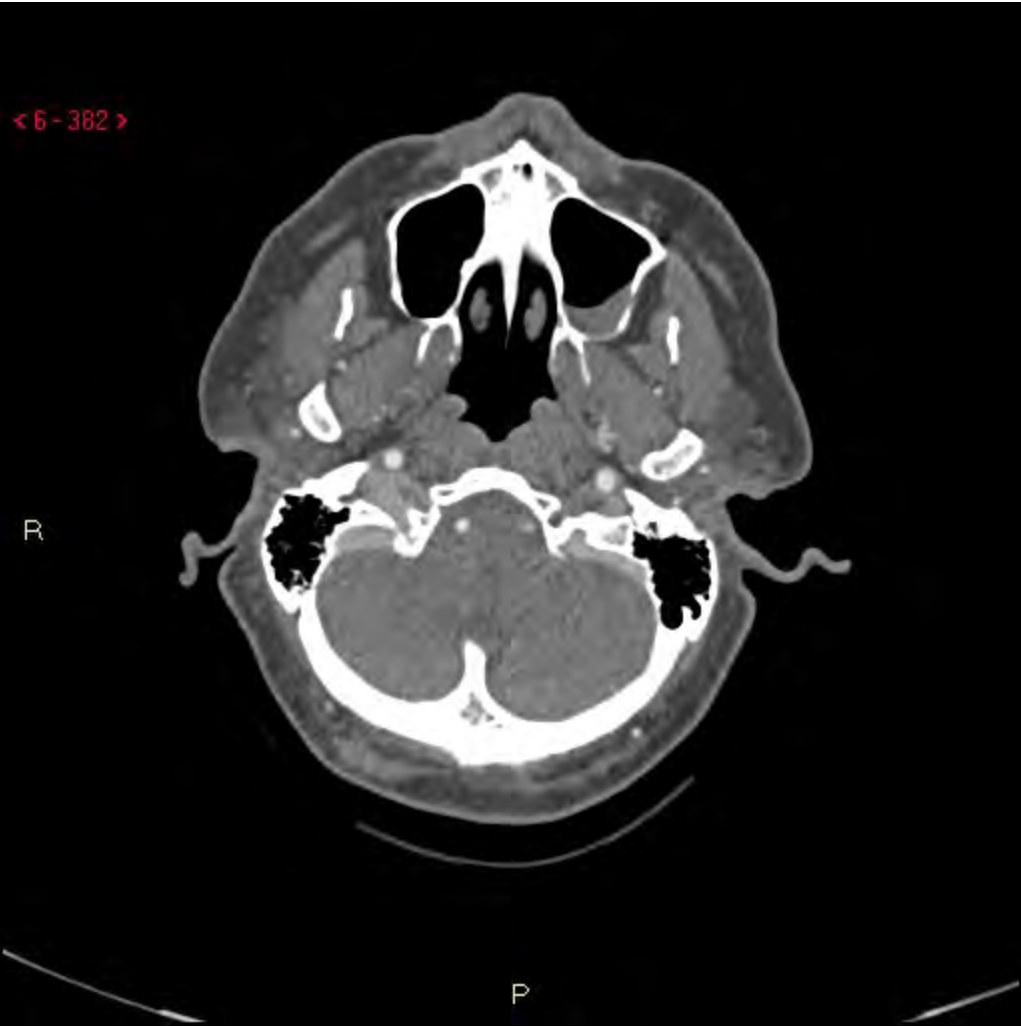< 6 - 381 >

R

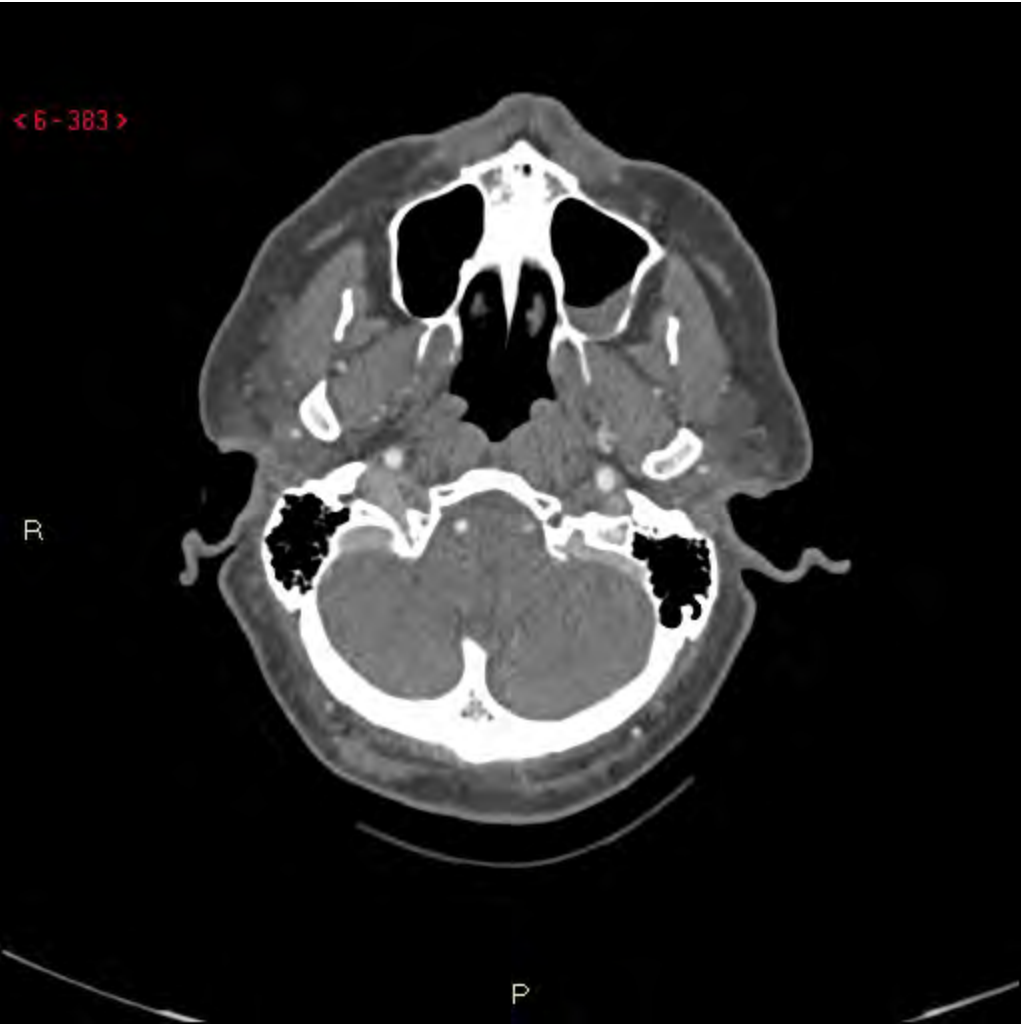P

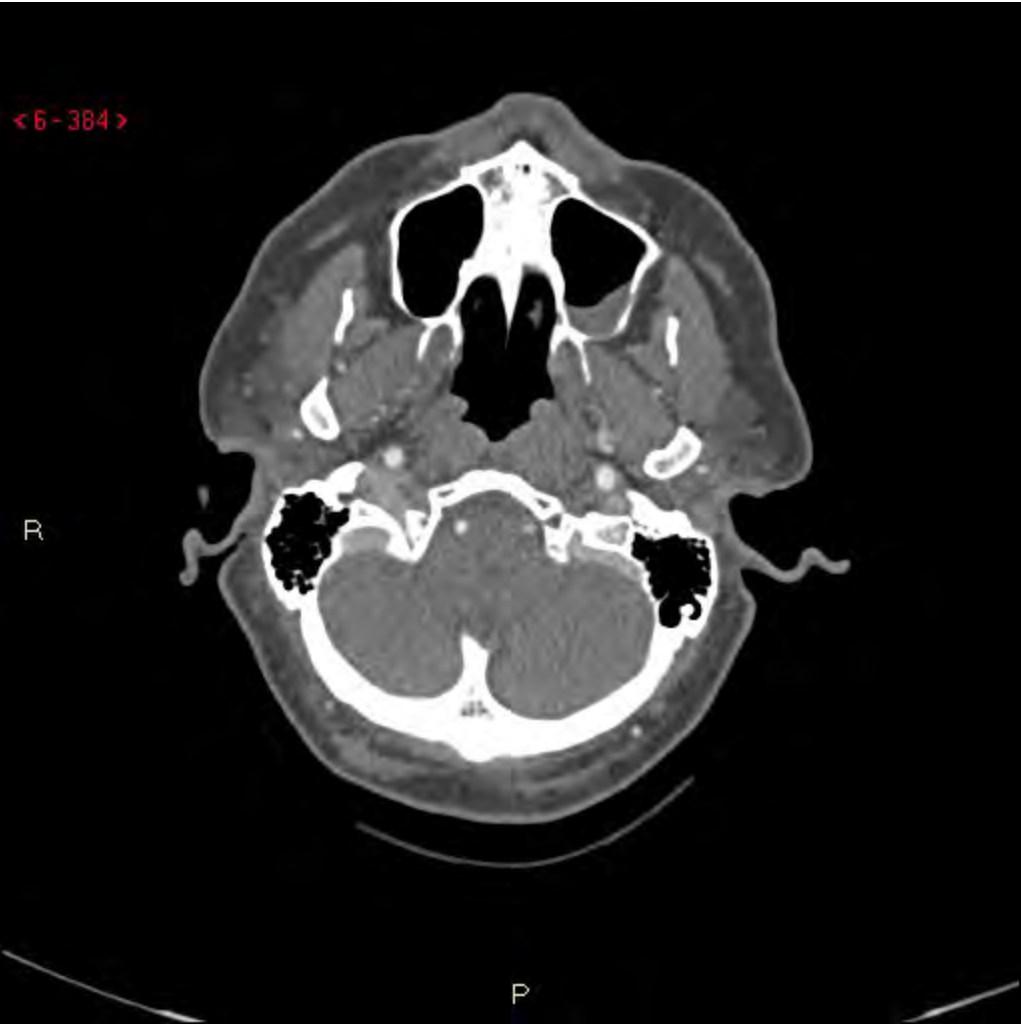

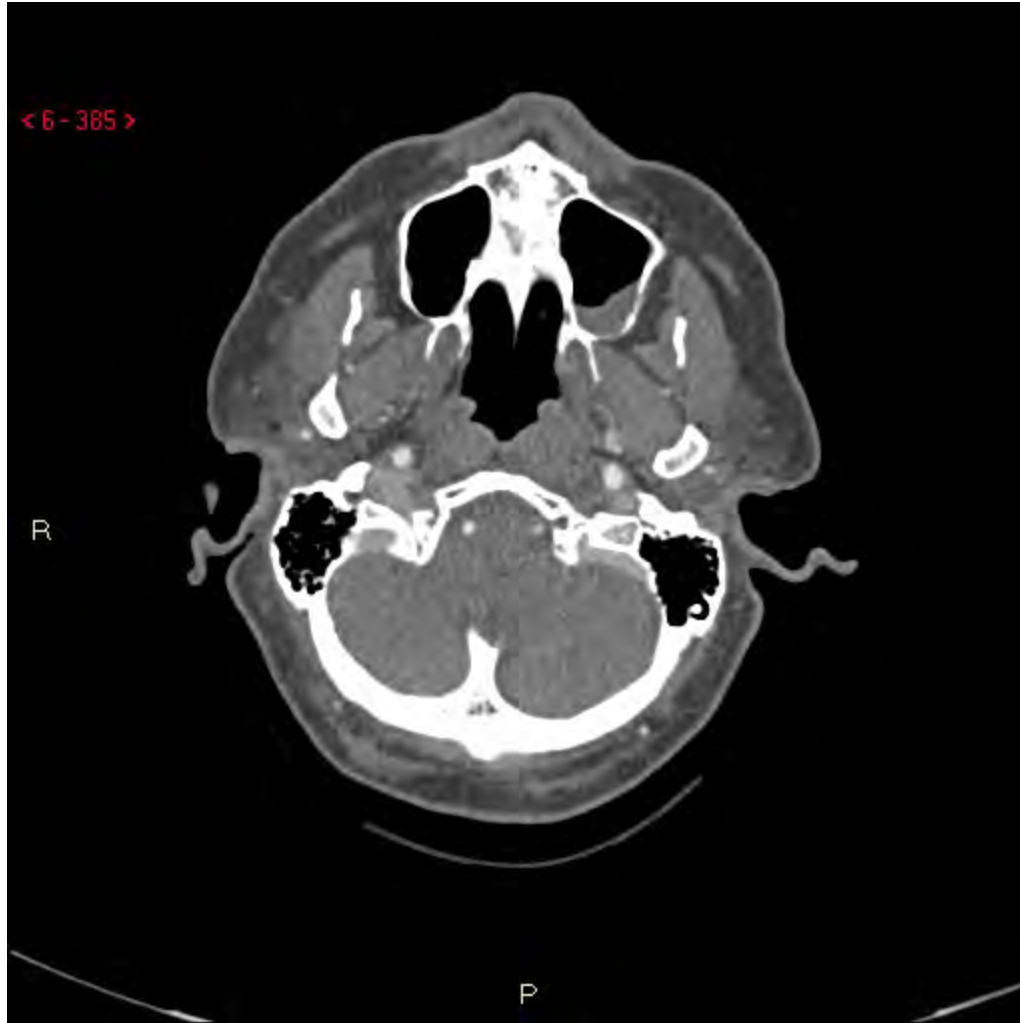< 6 - 382 >

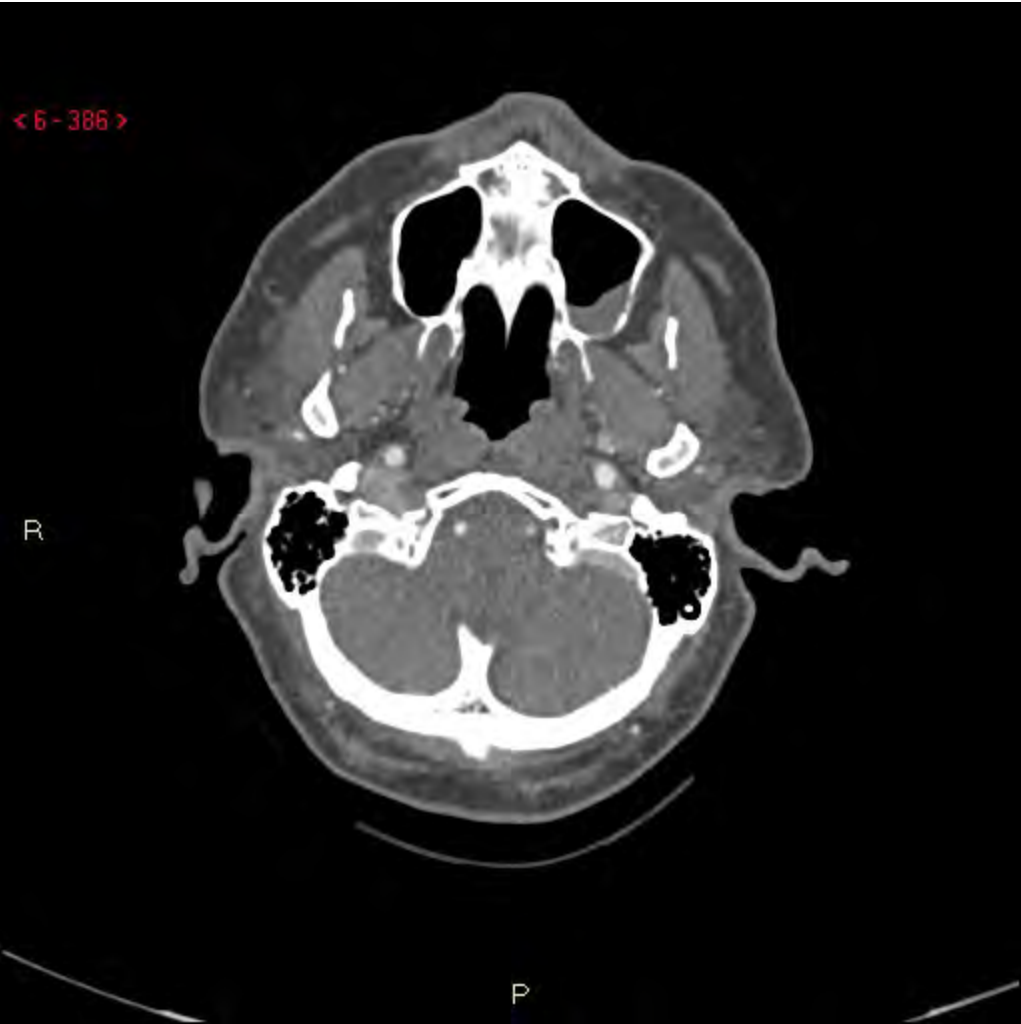




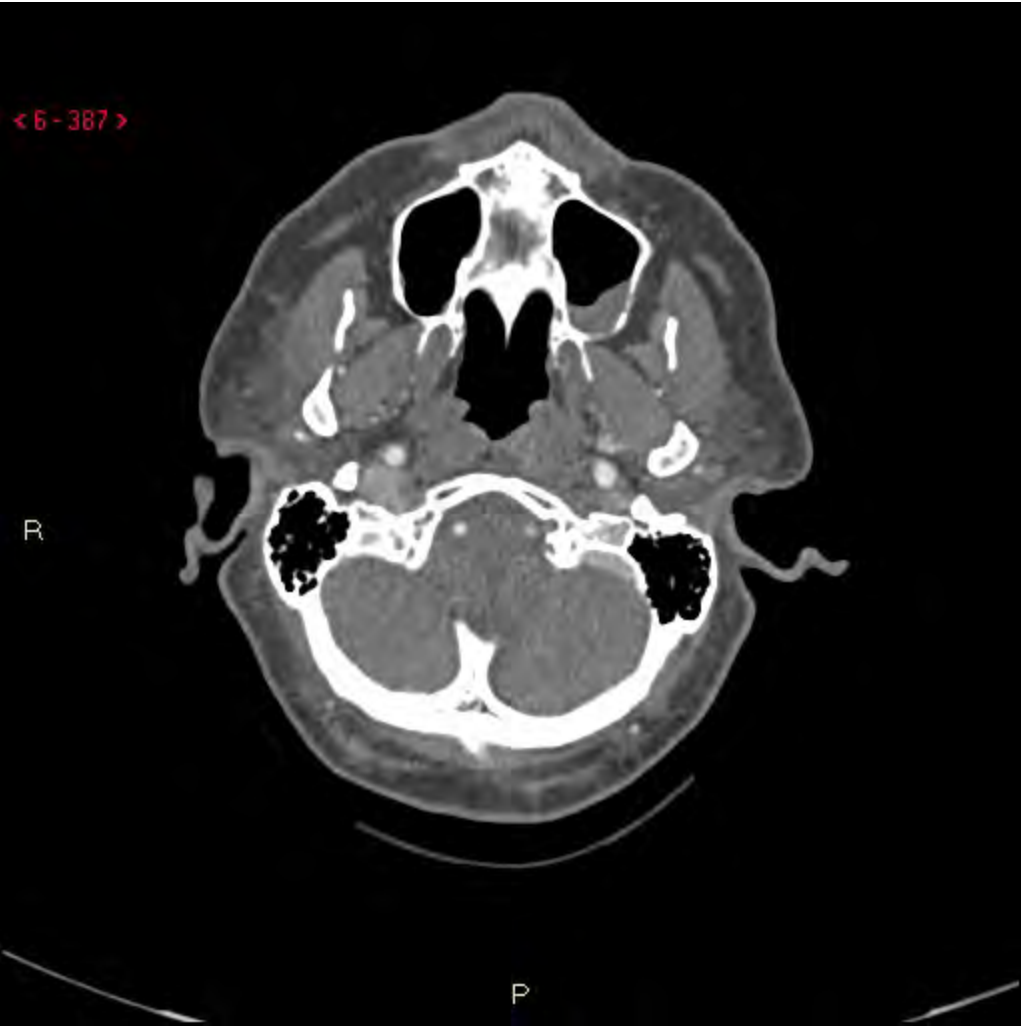




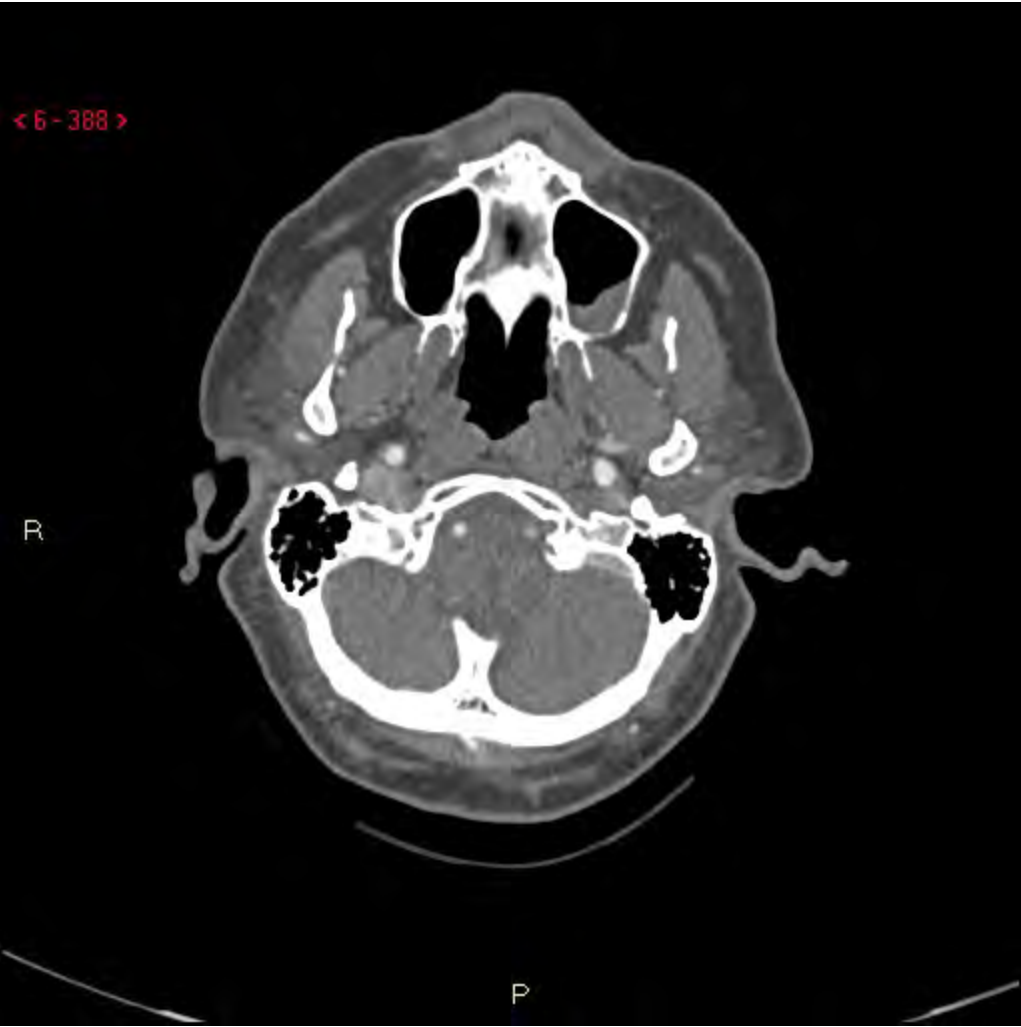

< 6 - 387 >



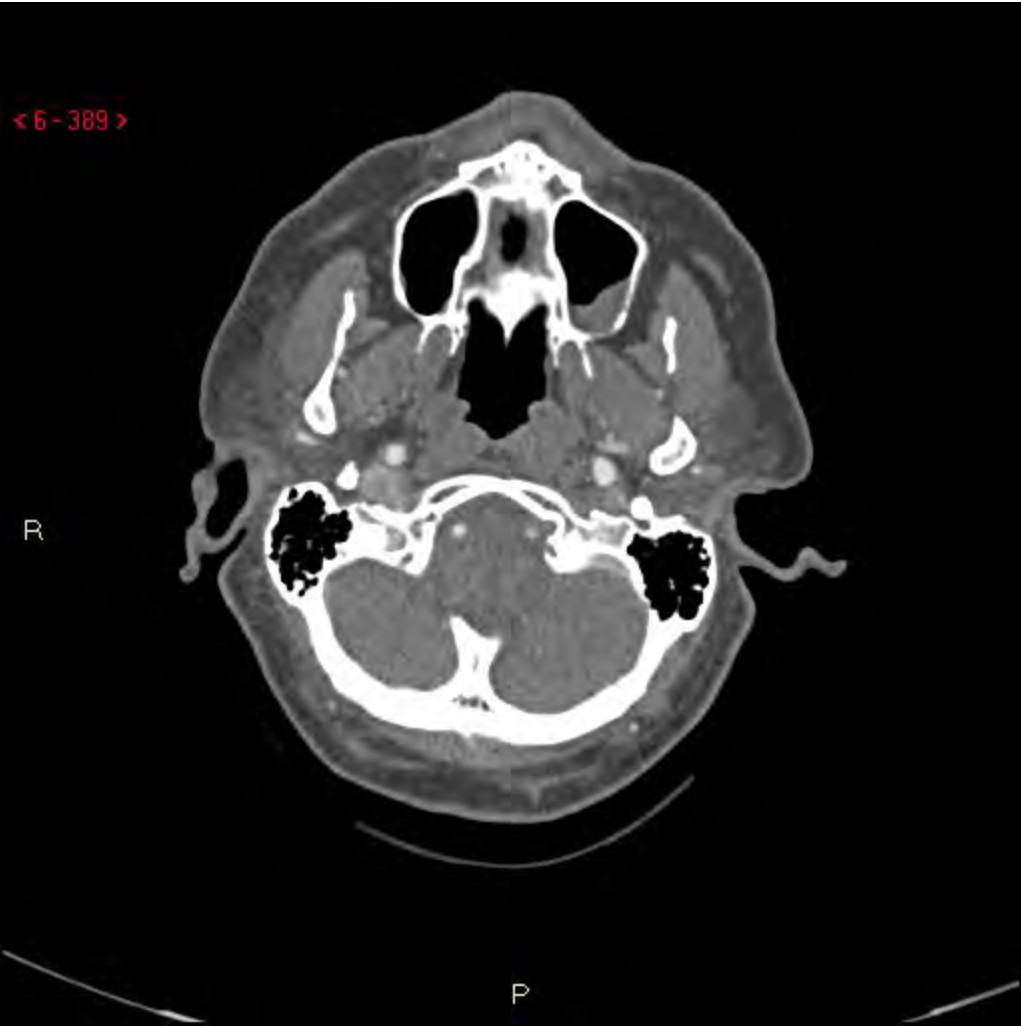< 6 - 388 >

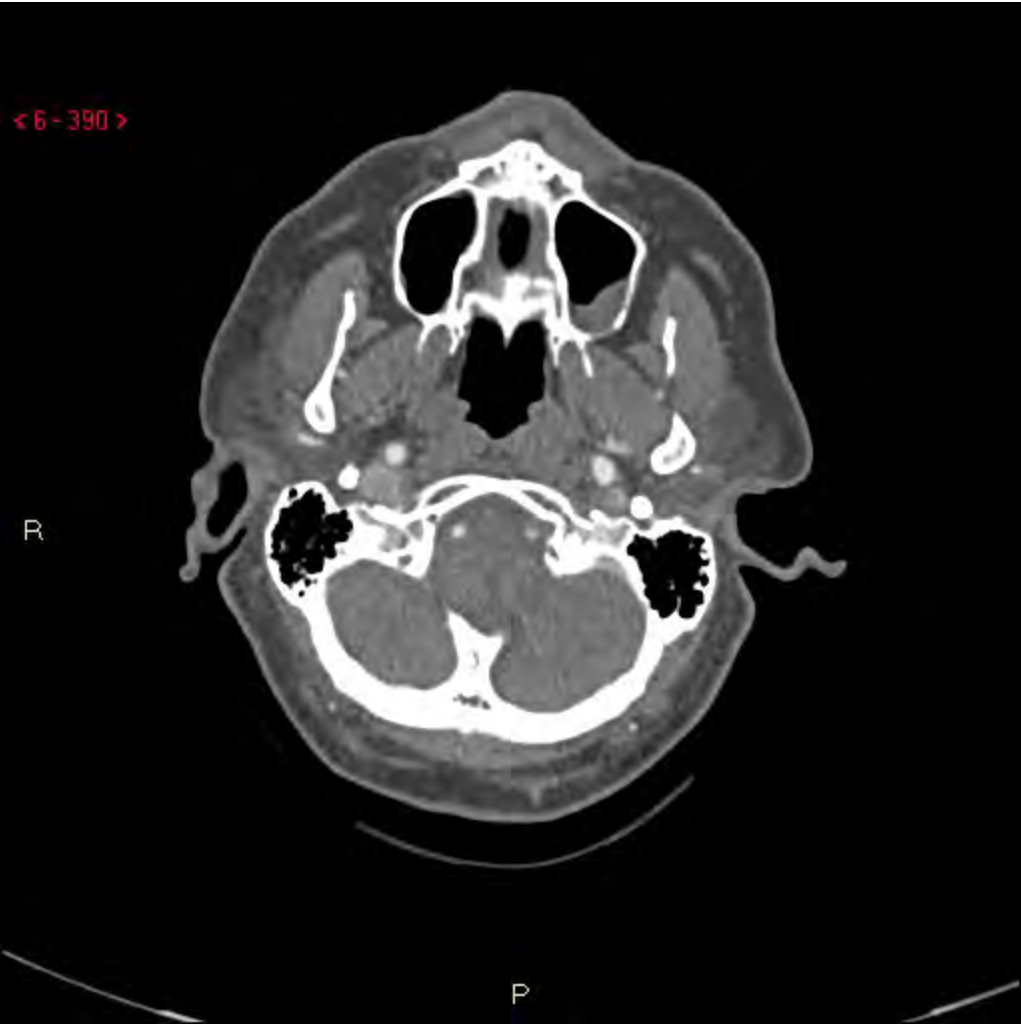

R

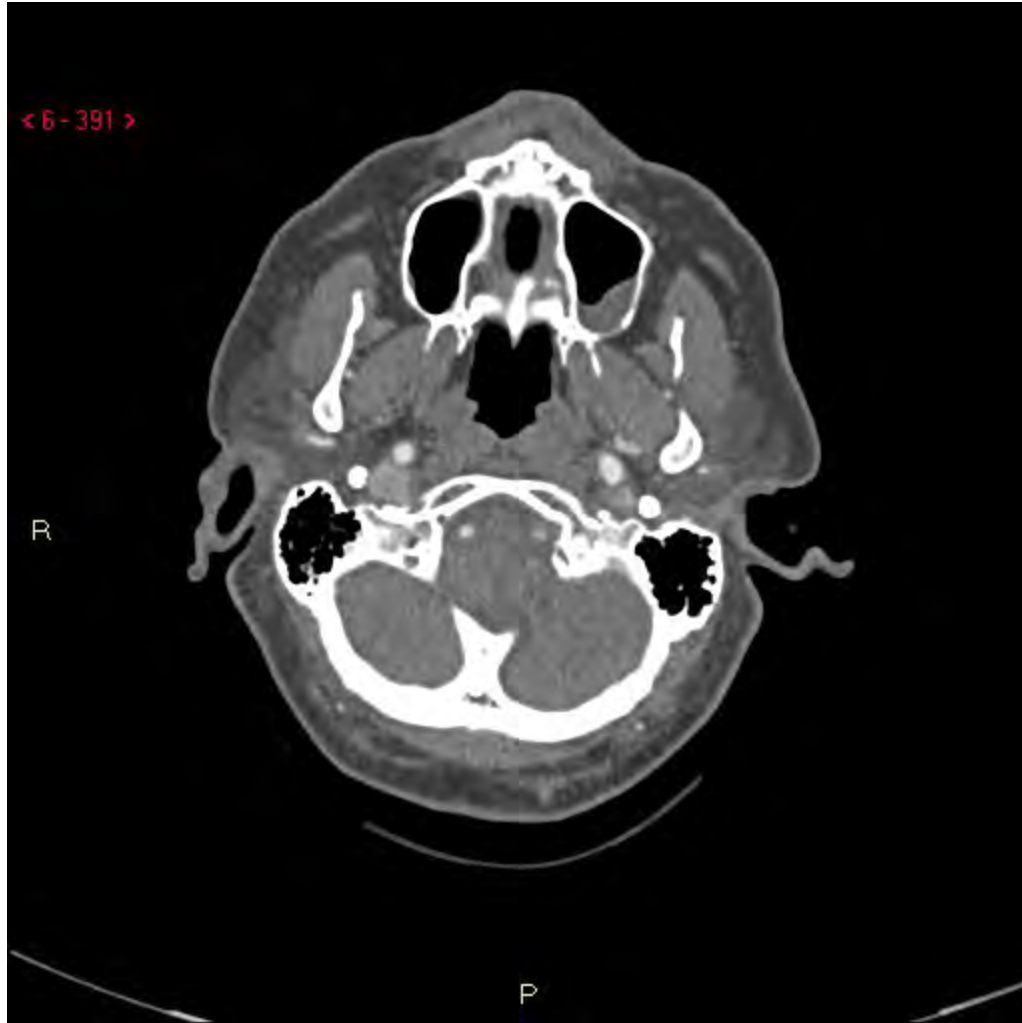P

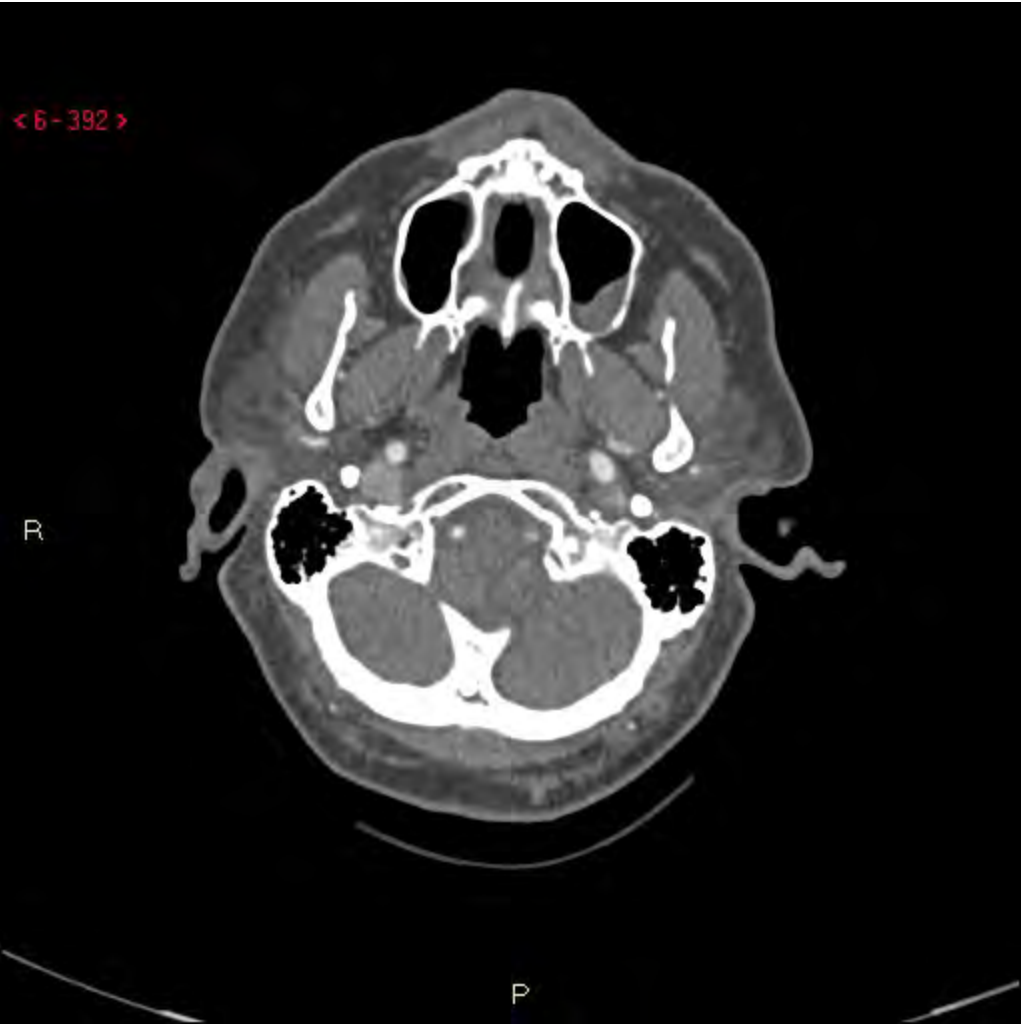< 6 - 389 >







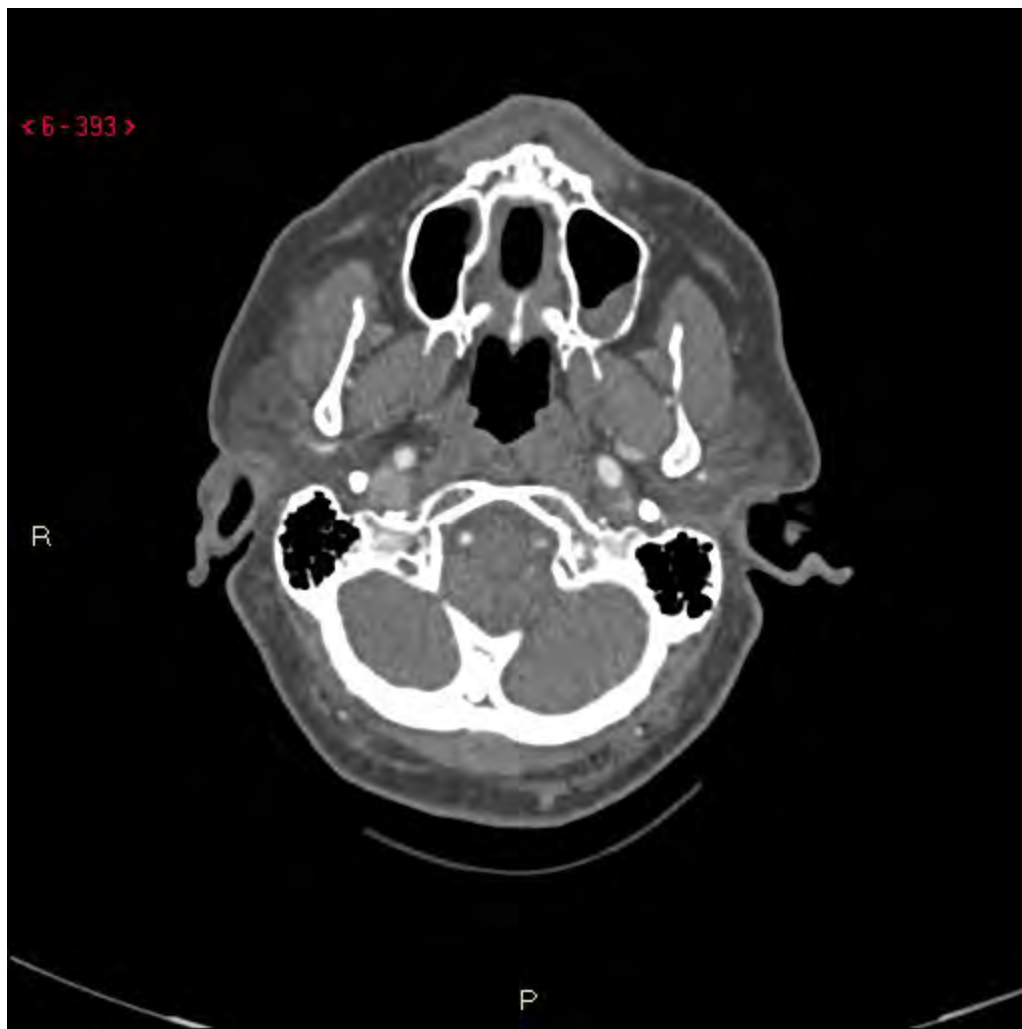



< 6 - 393 >

R

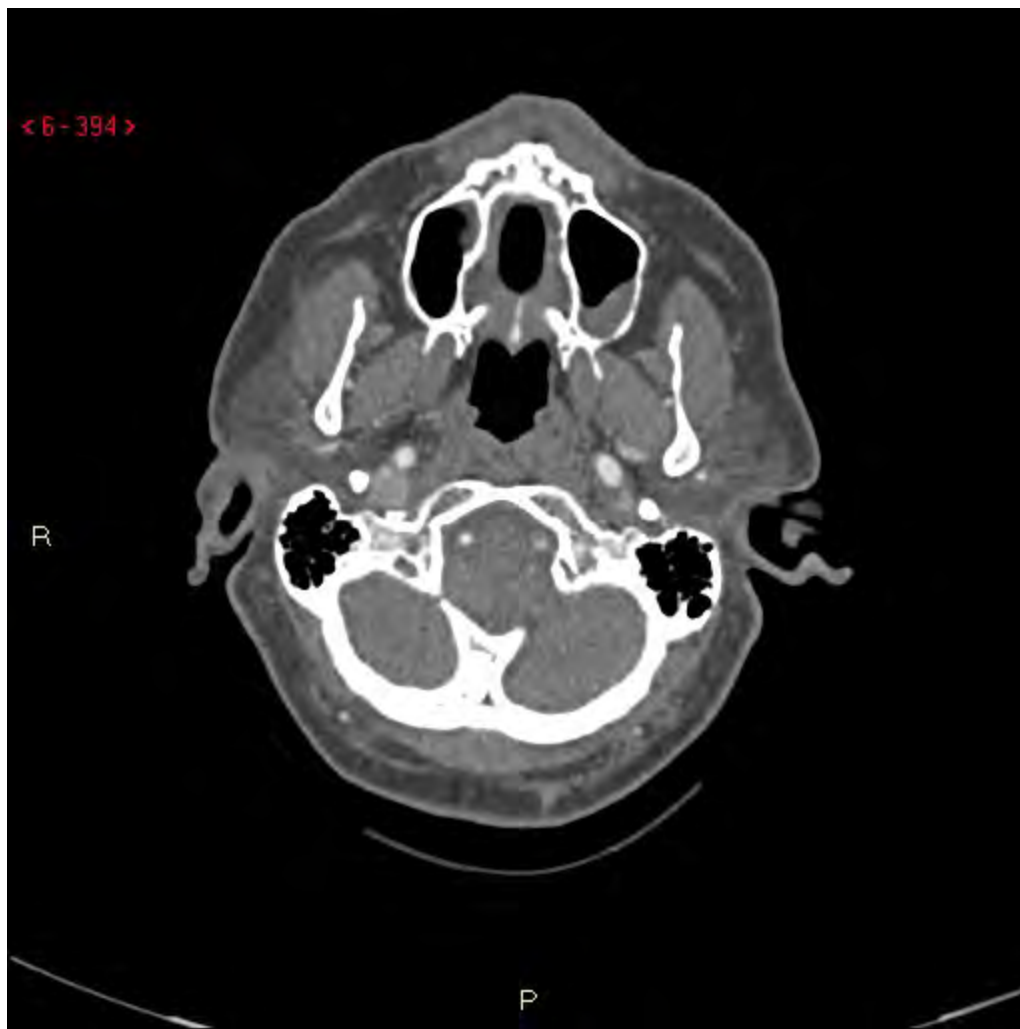P



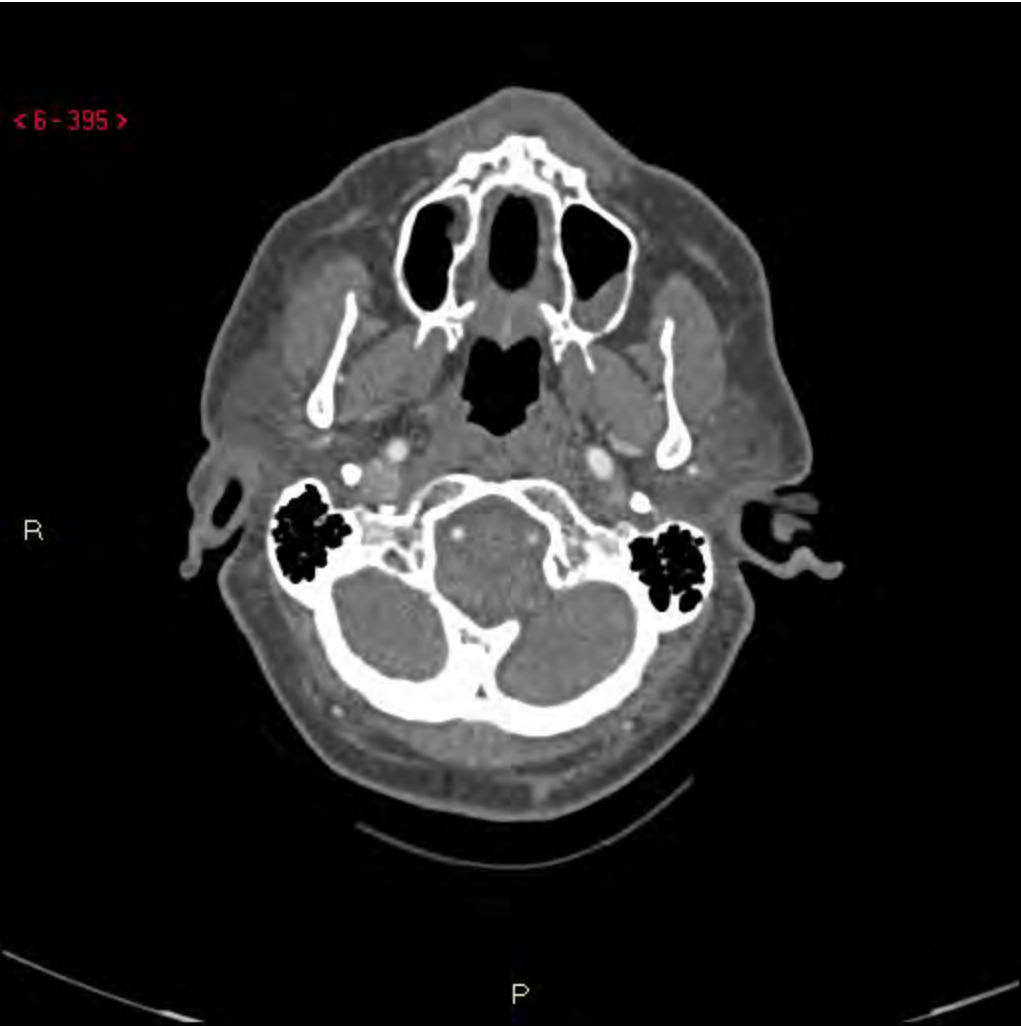< 6 - 394 >

R

P



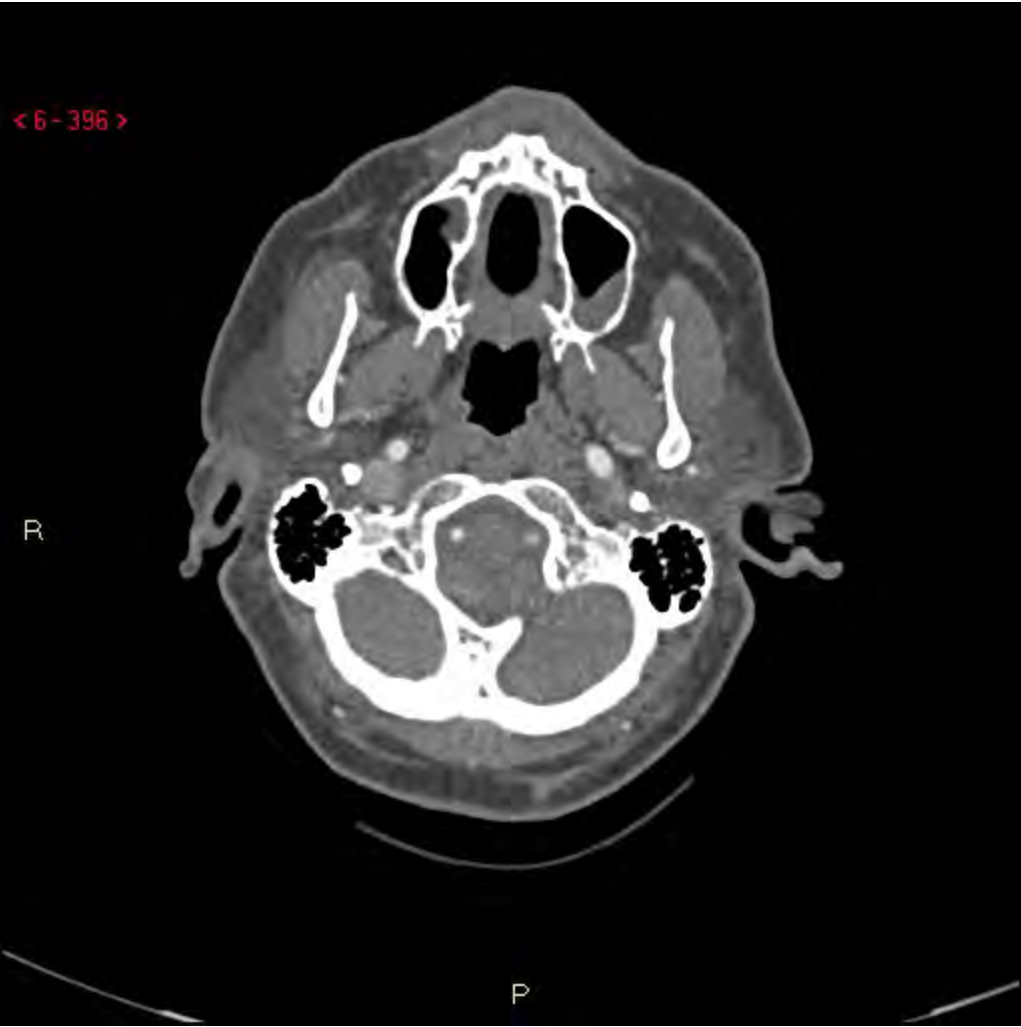< 6 - 395 >



R

P

< 6 - 396 >



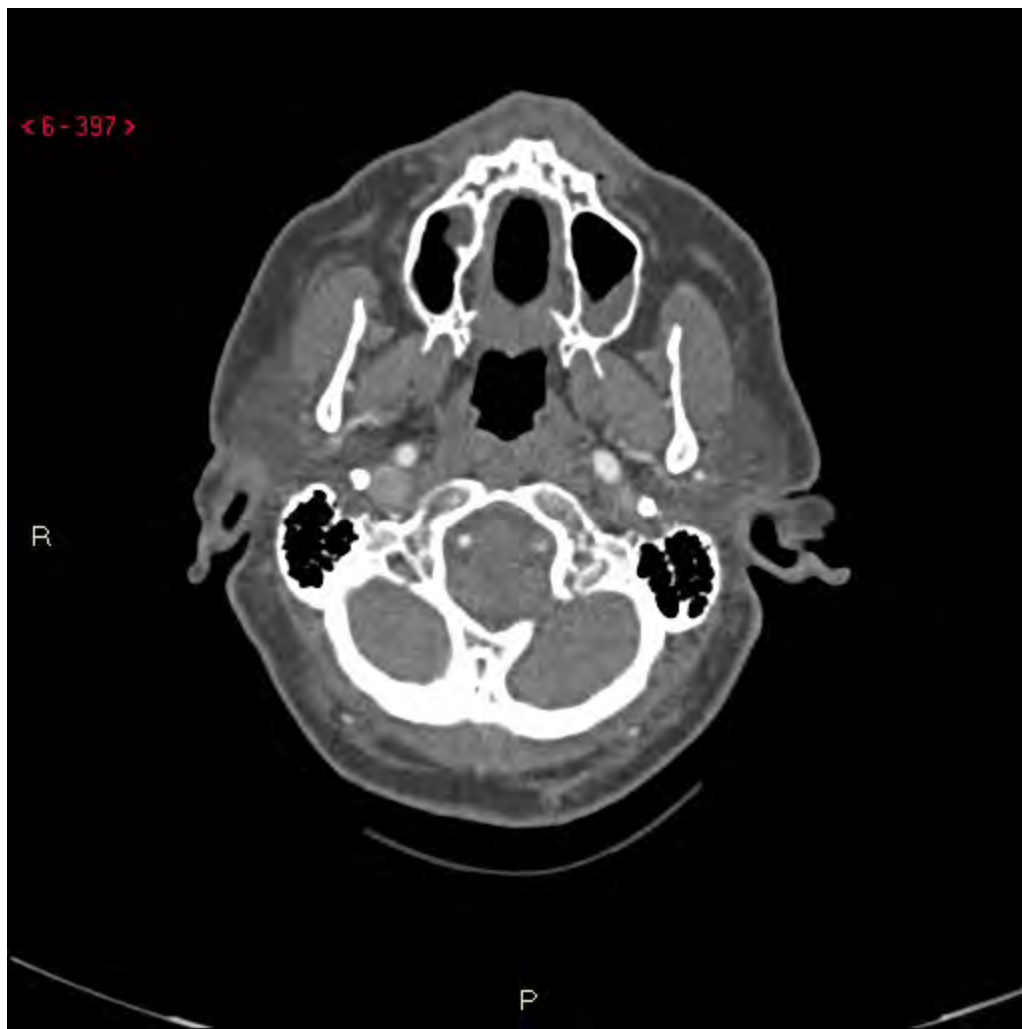R

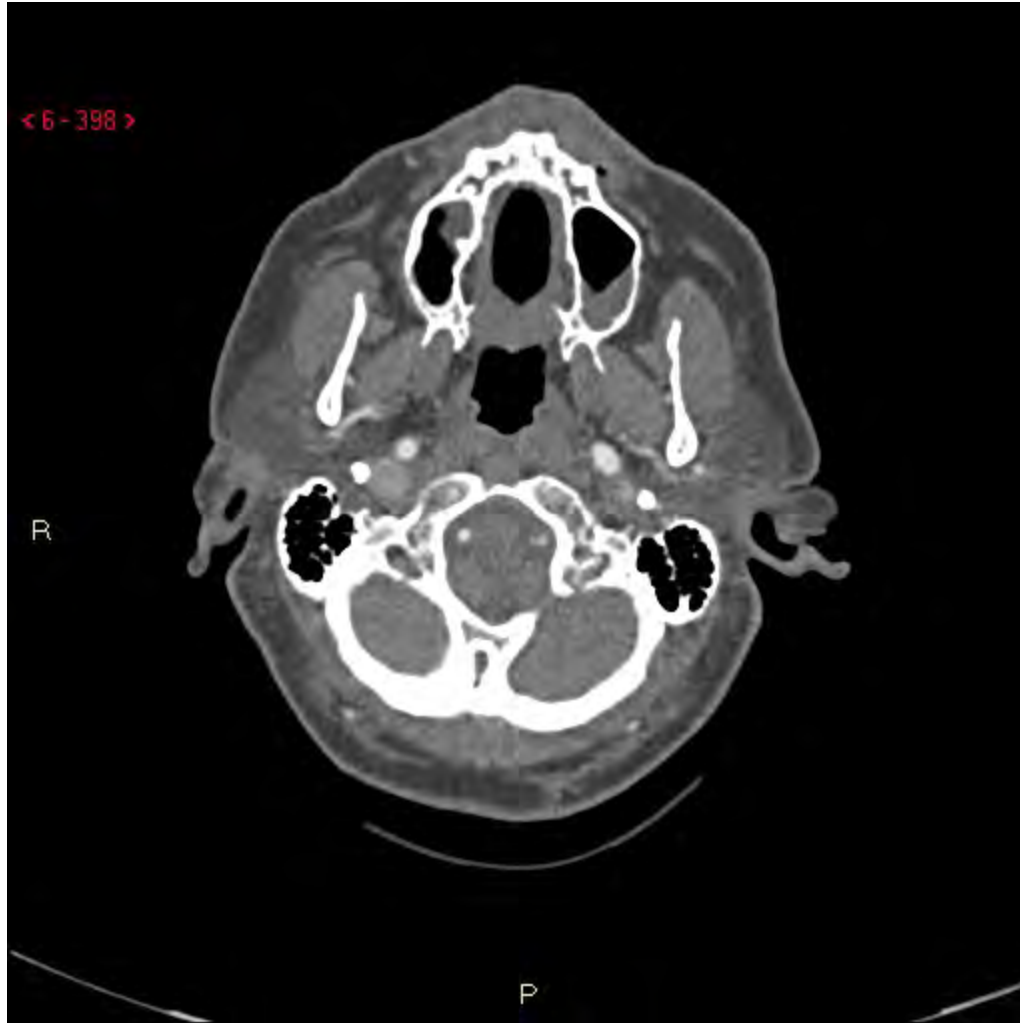P

< 6 - 397 >

R

P



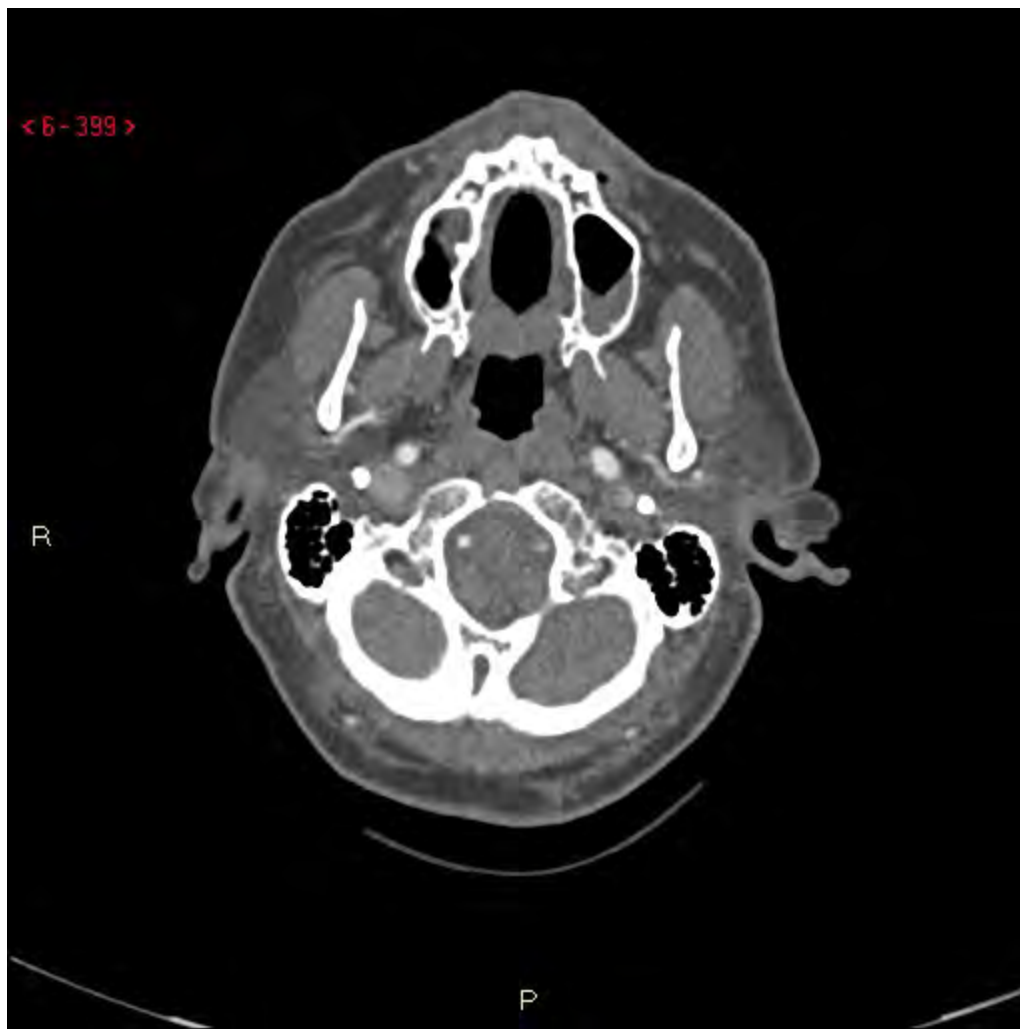


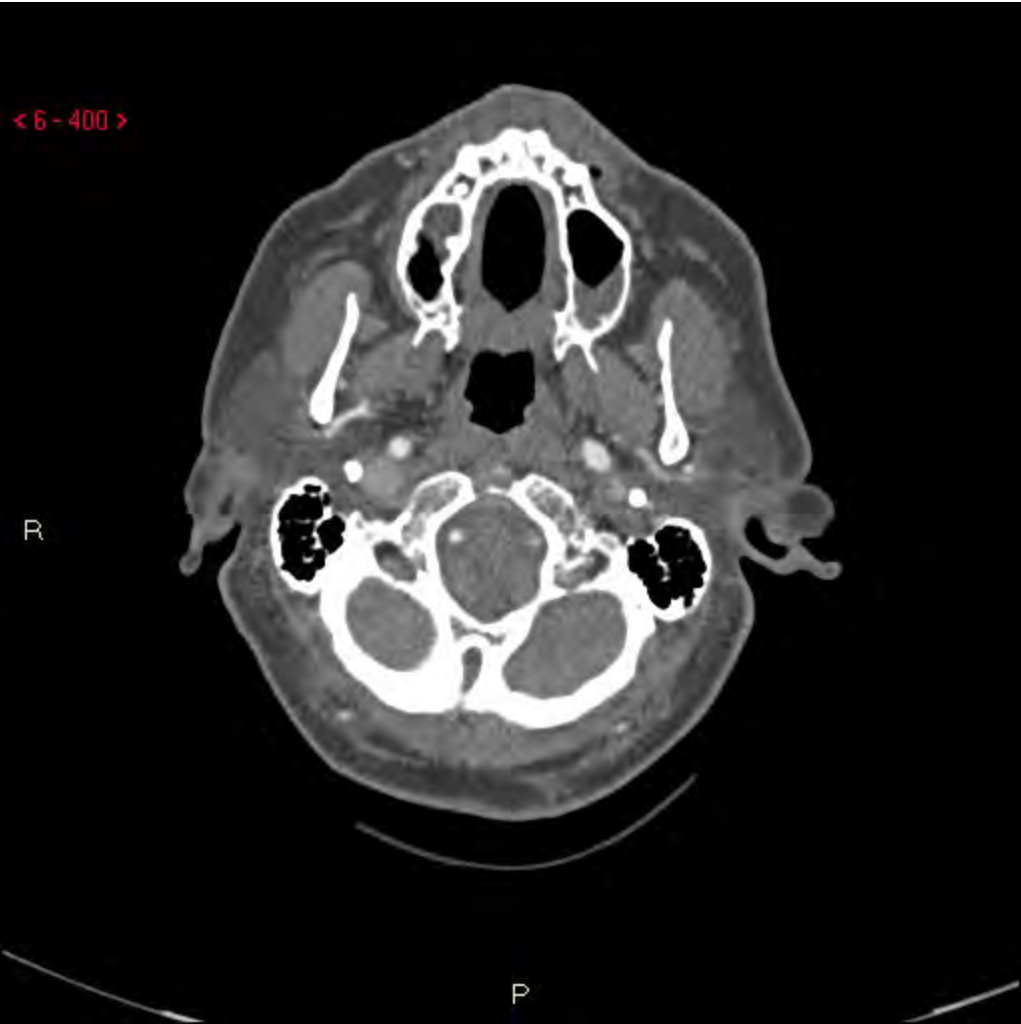
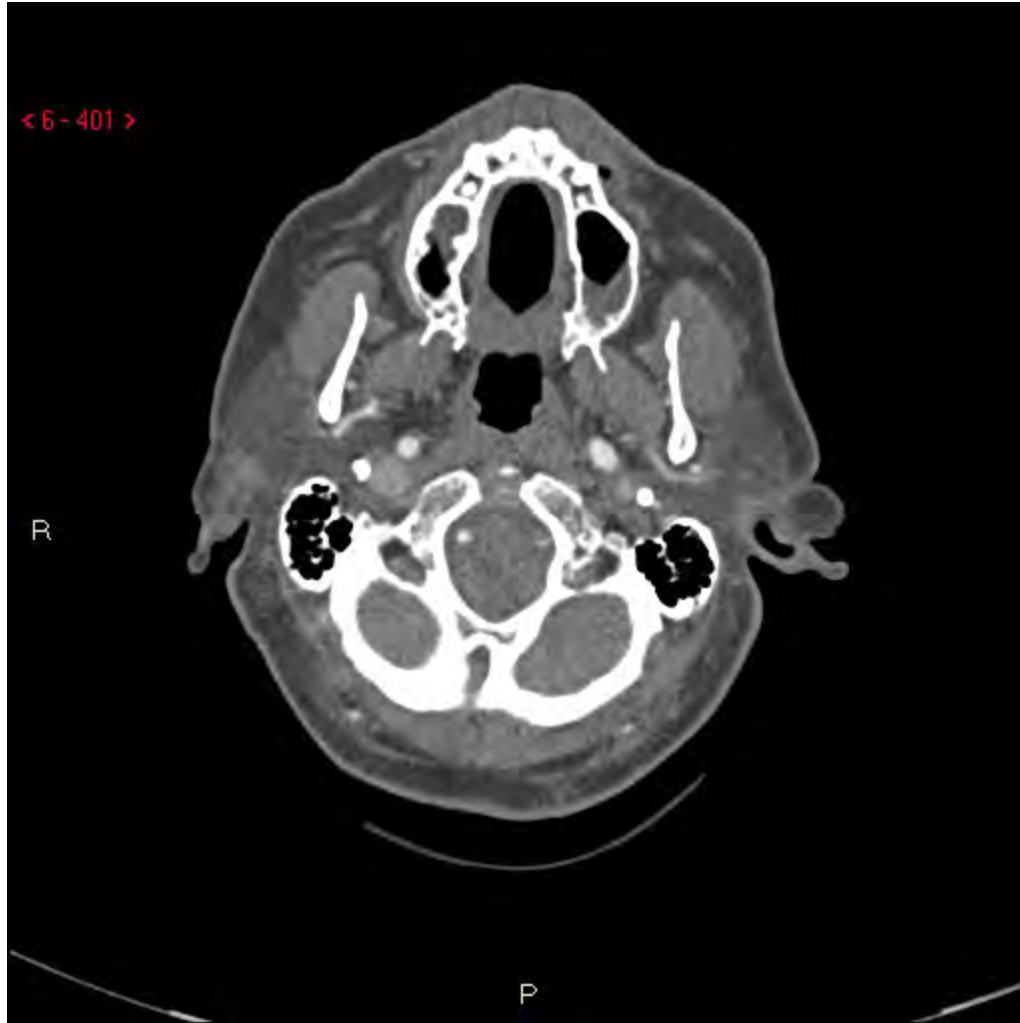< 6 - 399 >

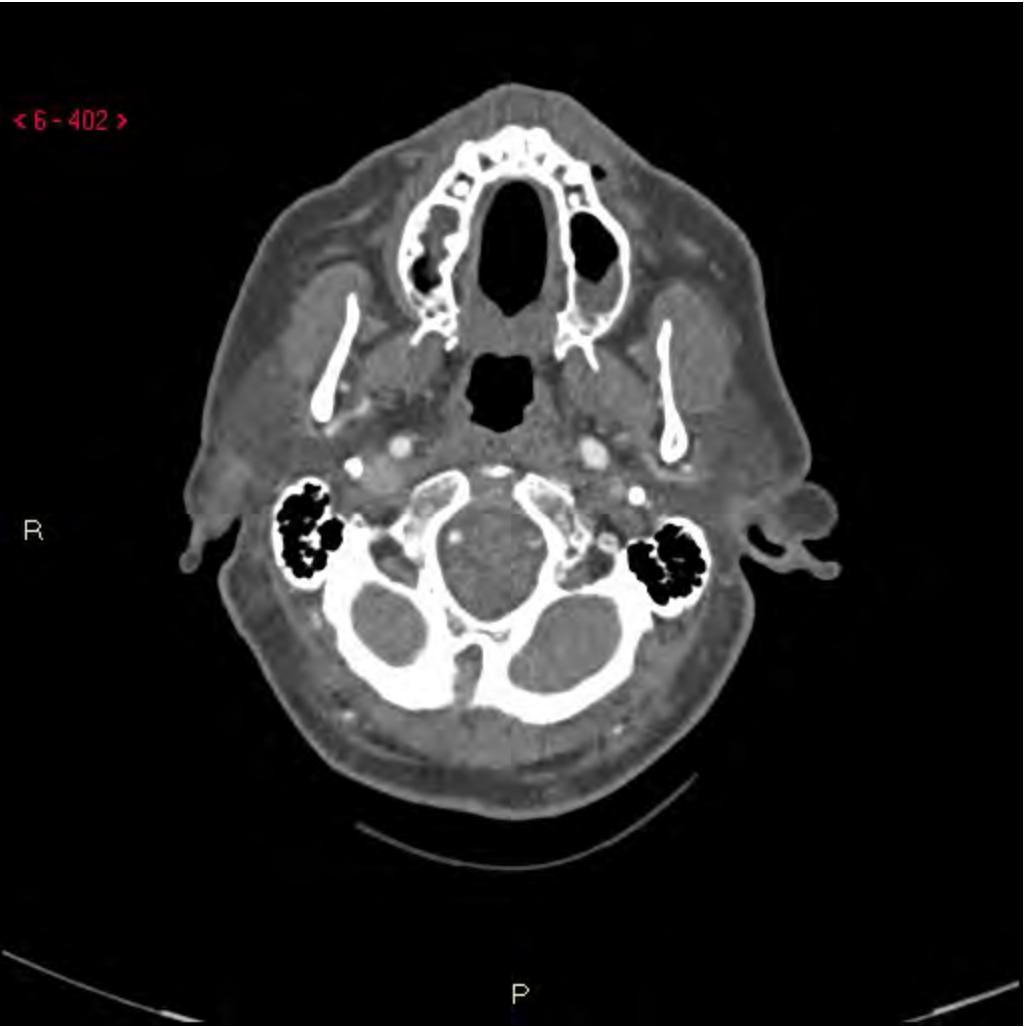R

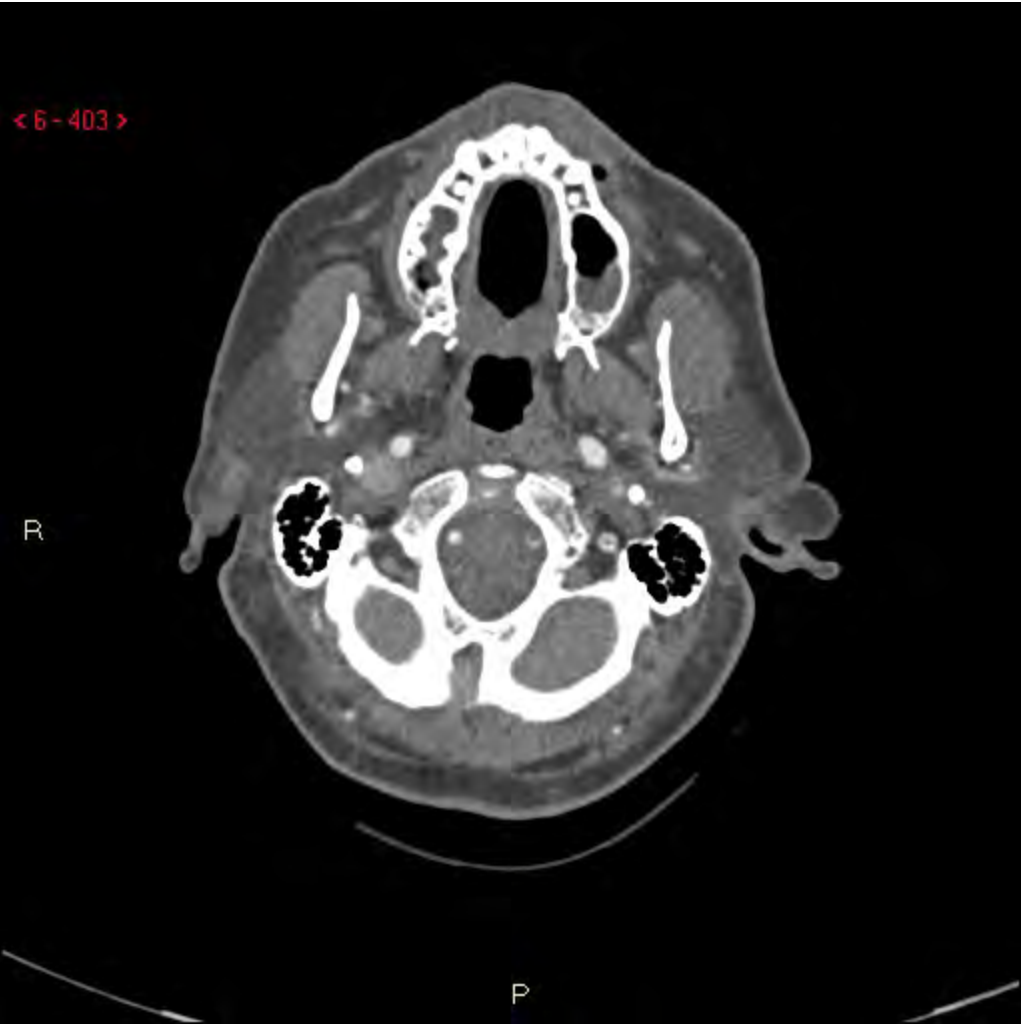P

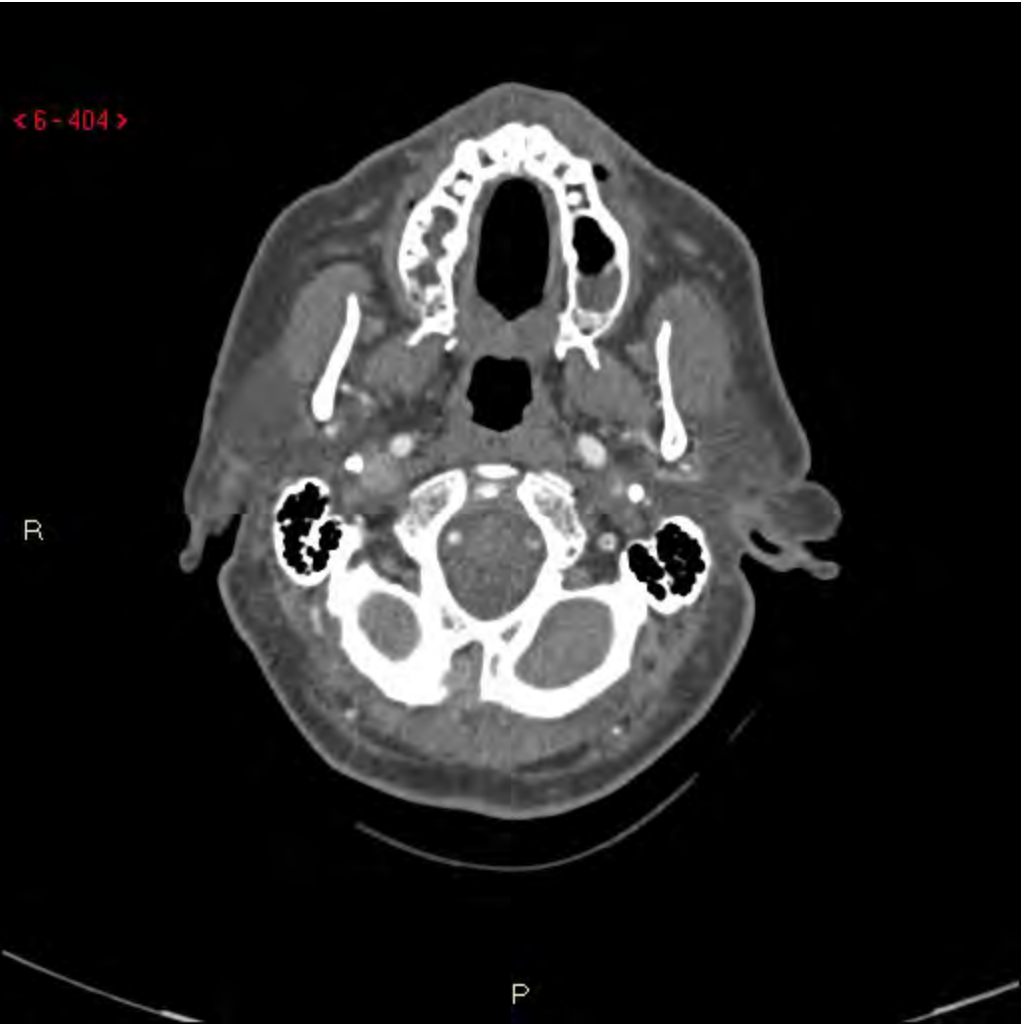


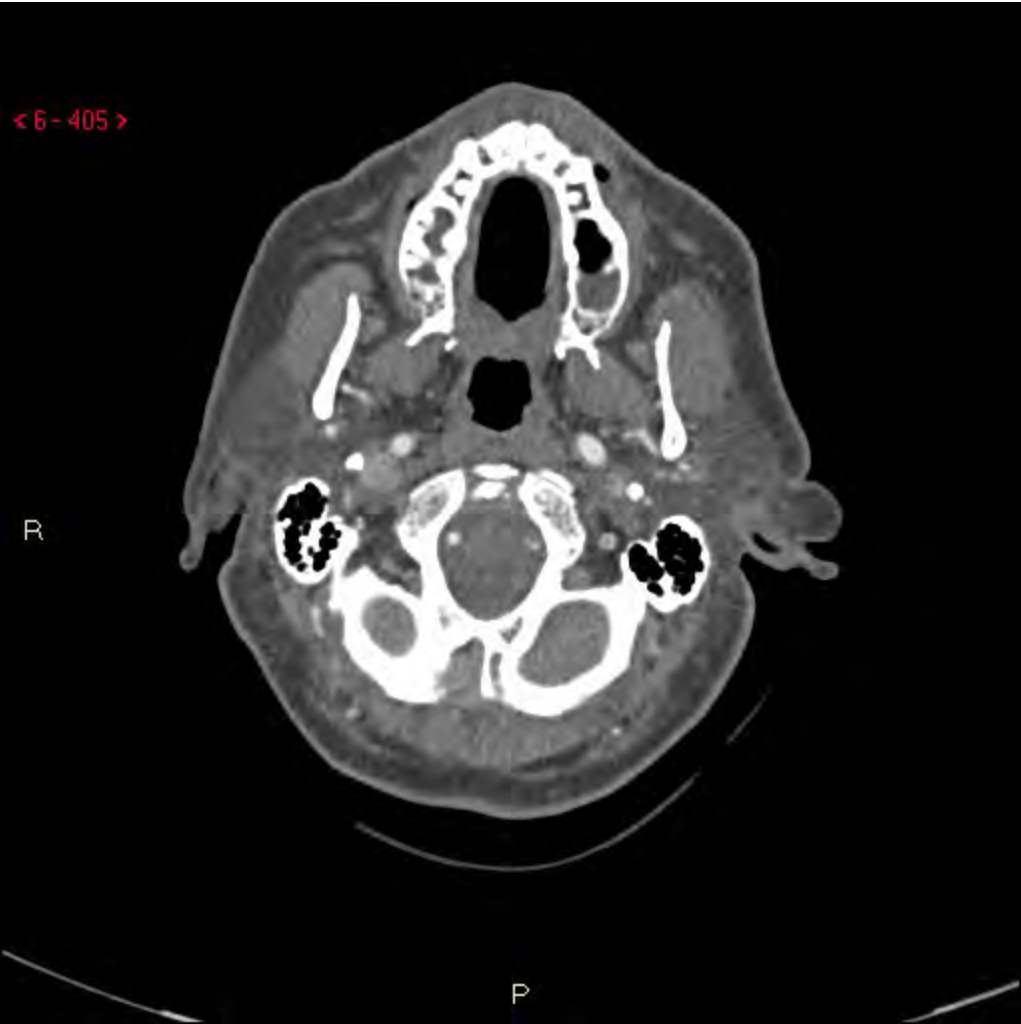


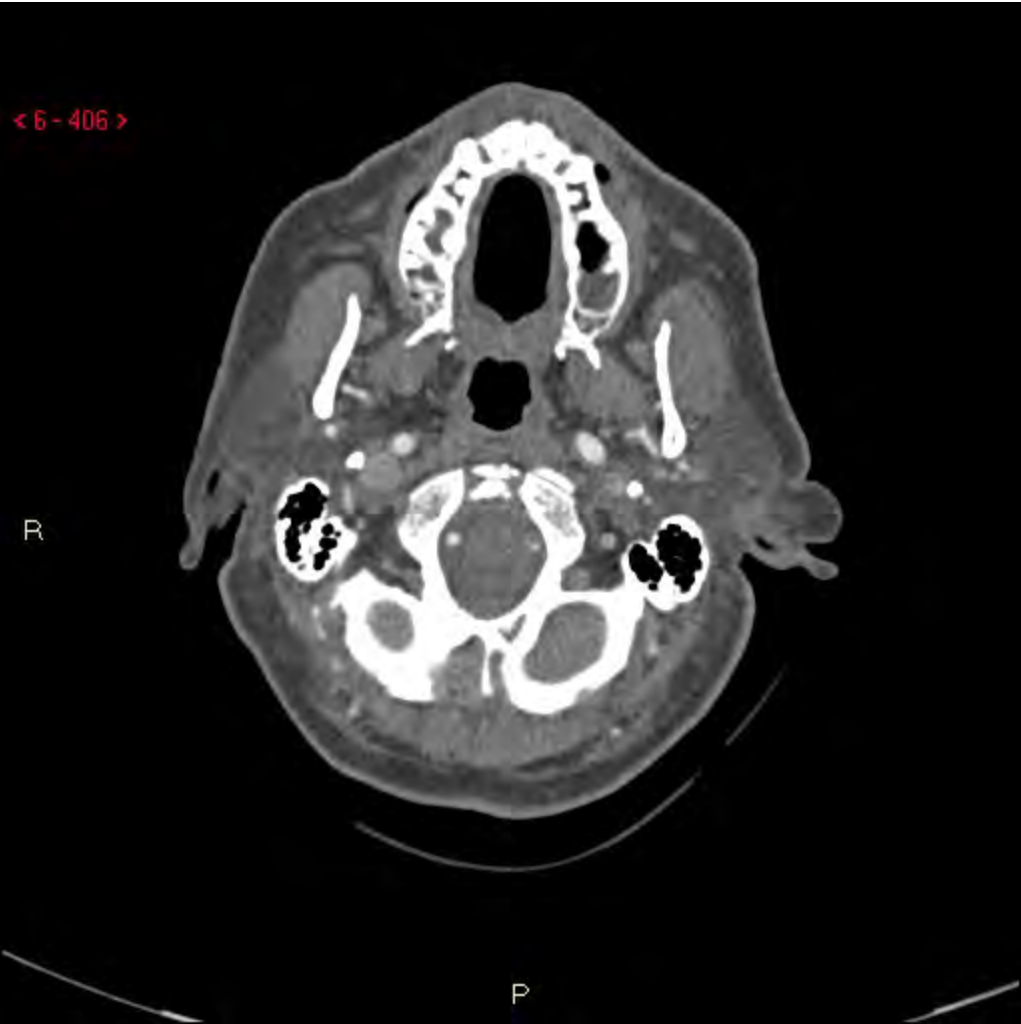




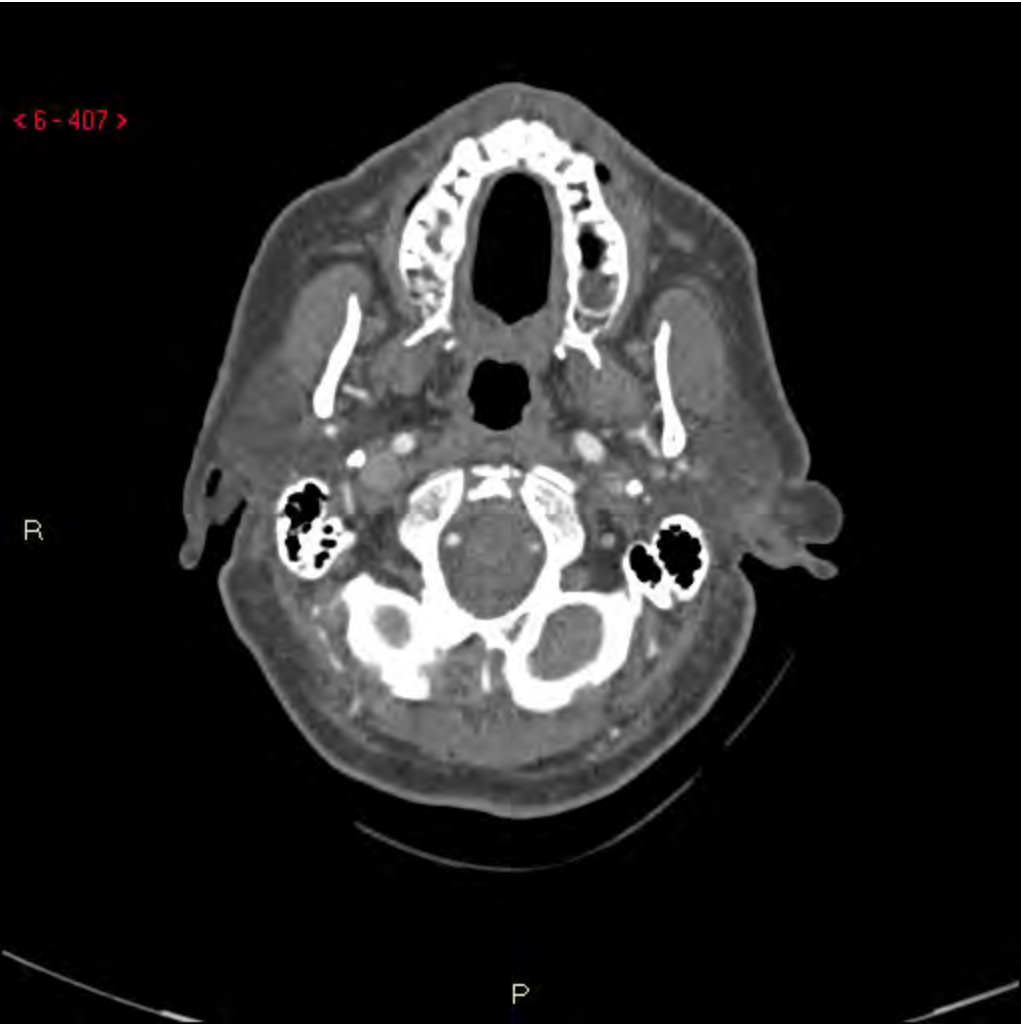


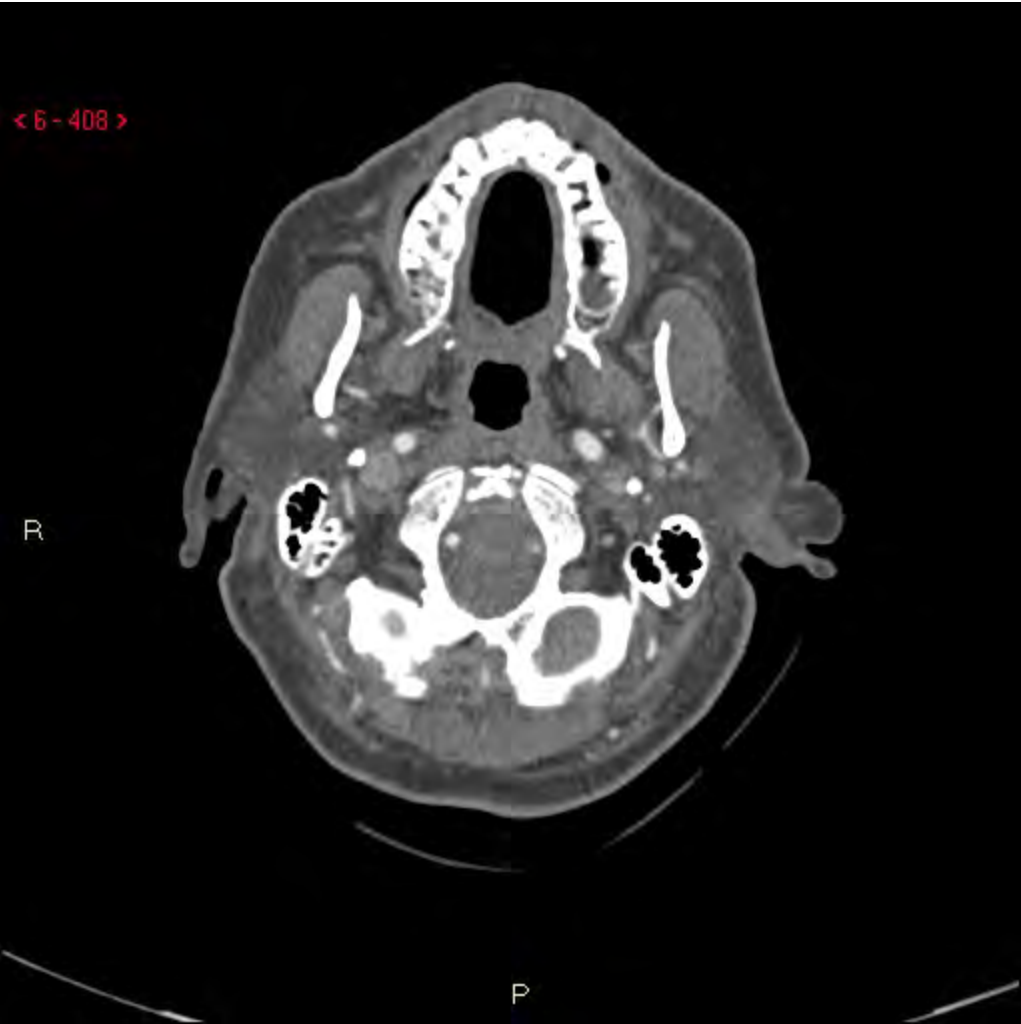


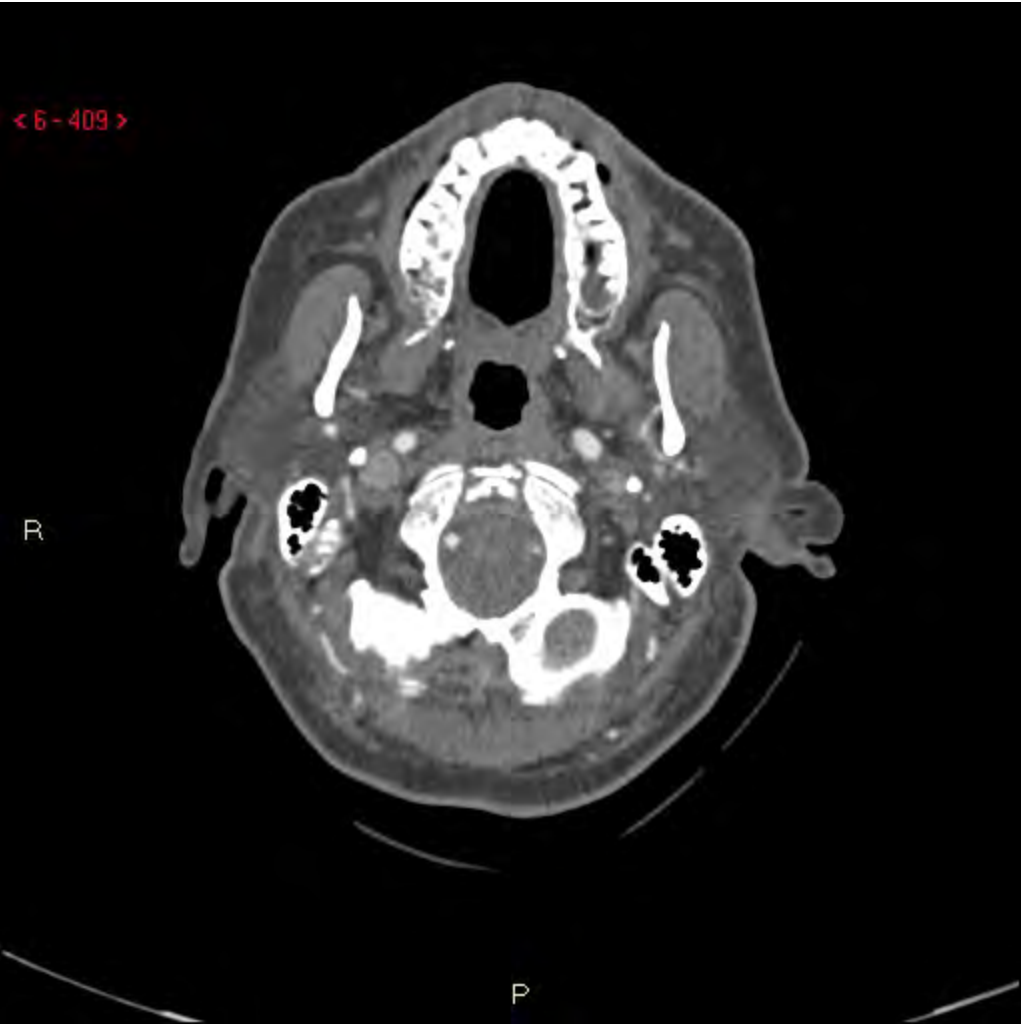
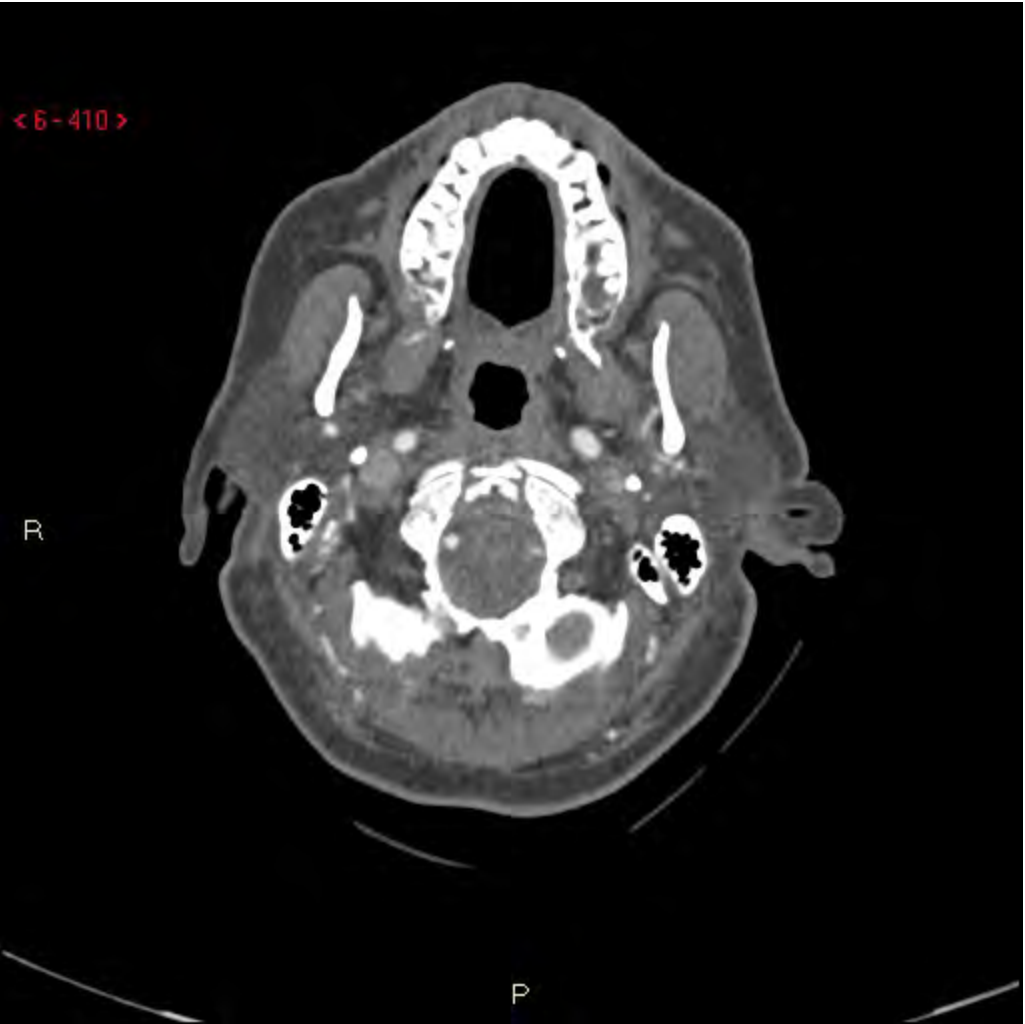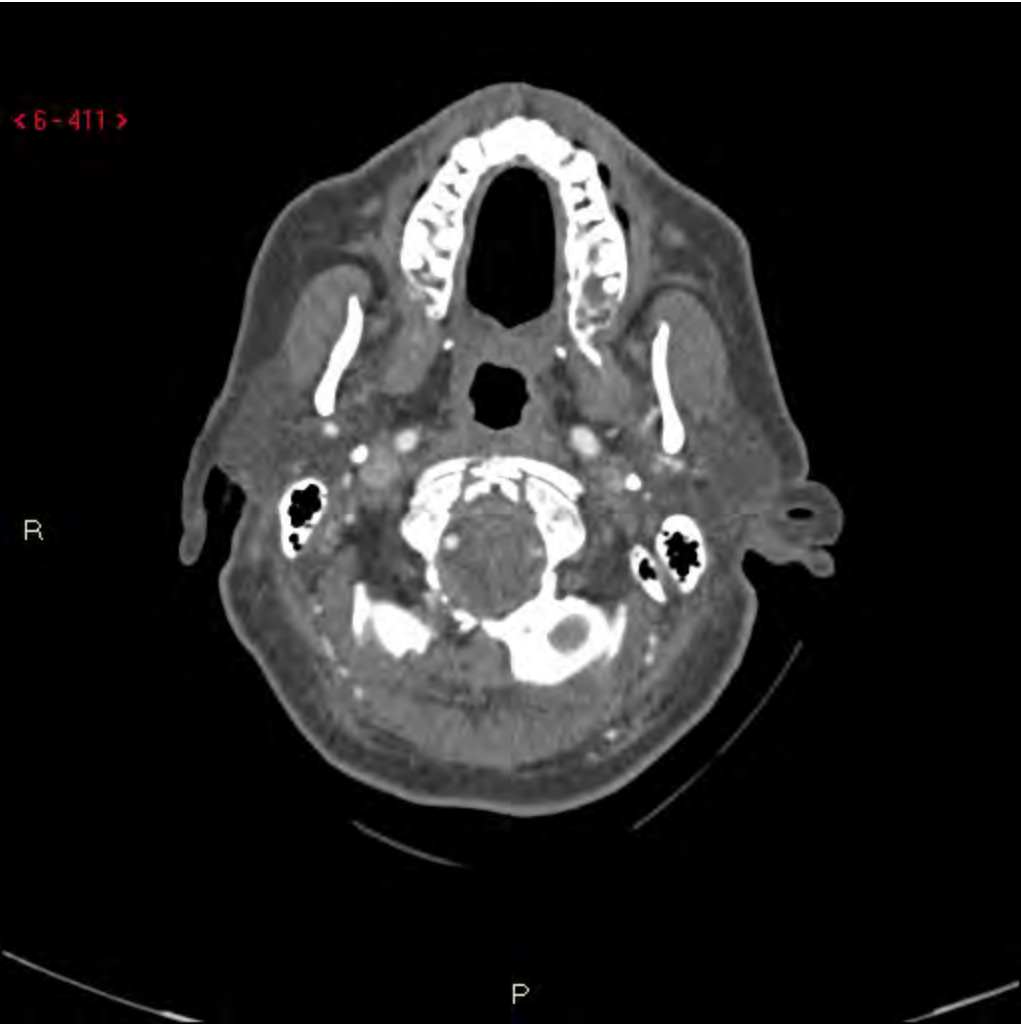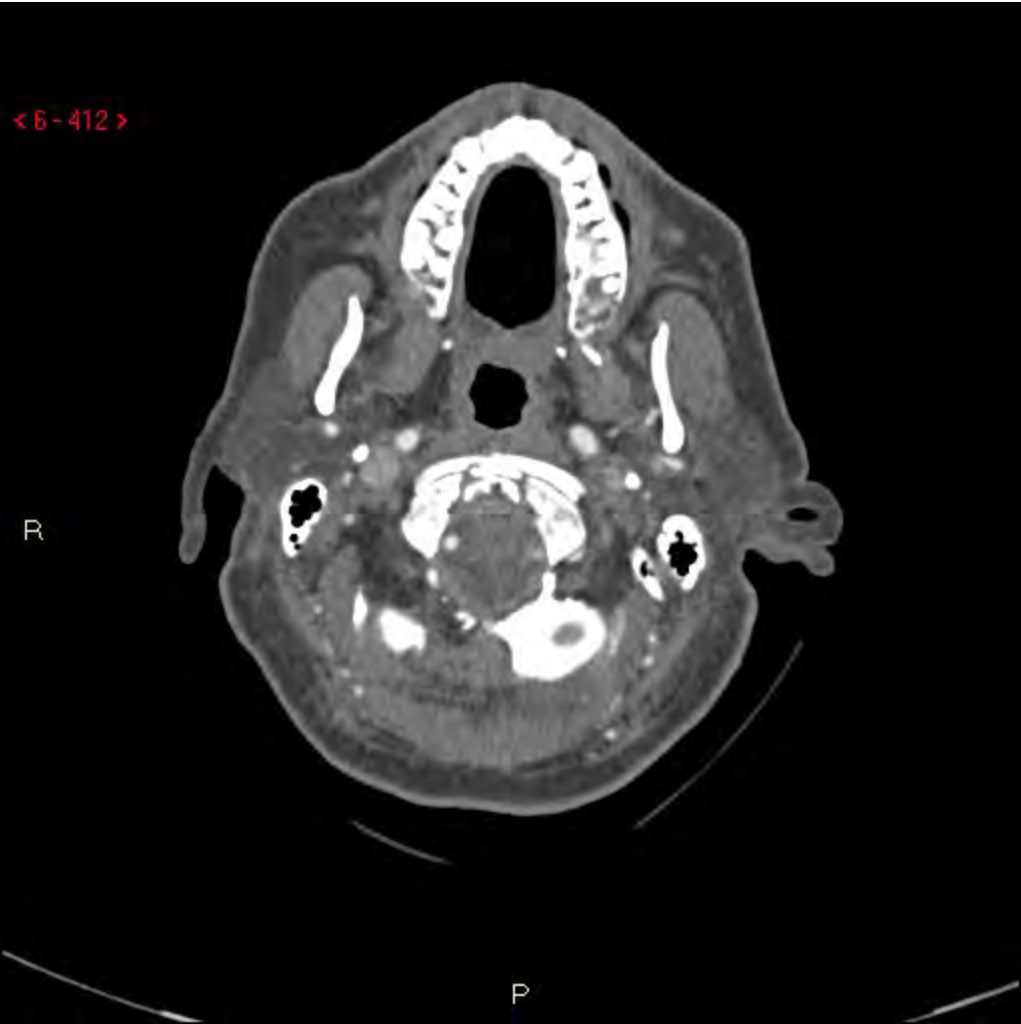


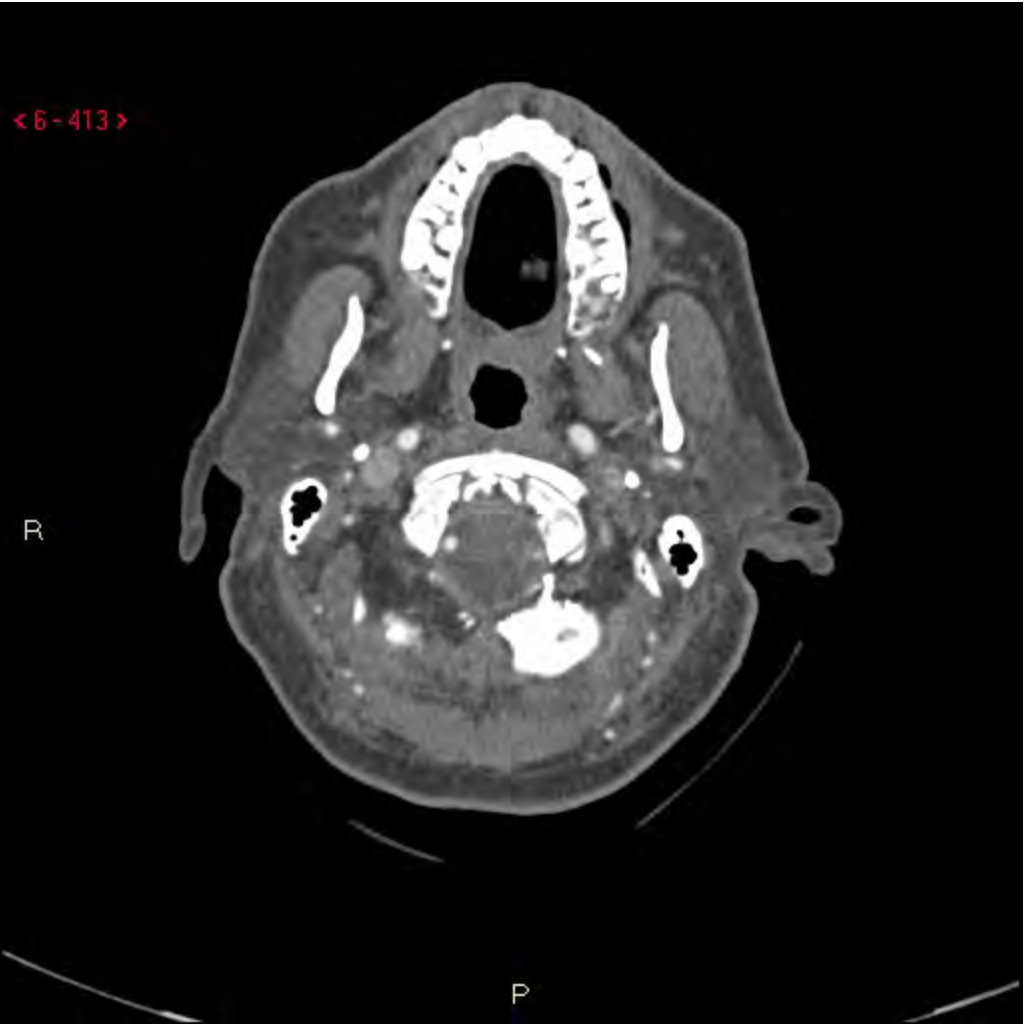


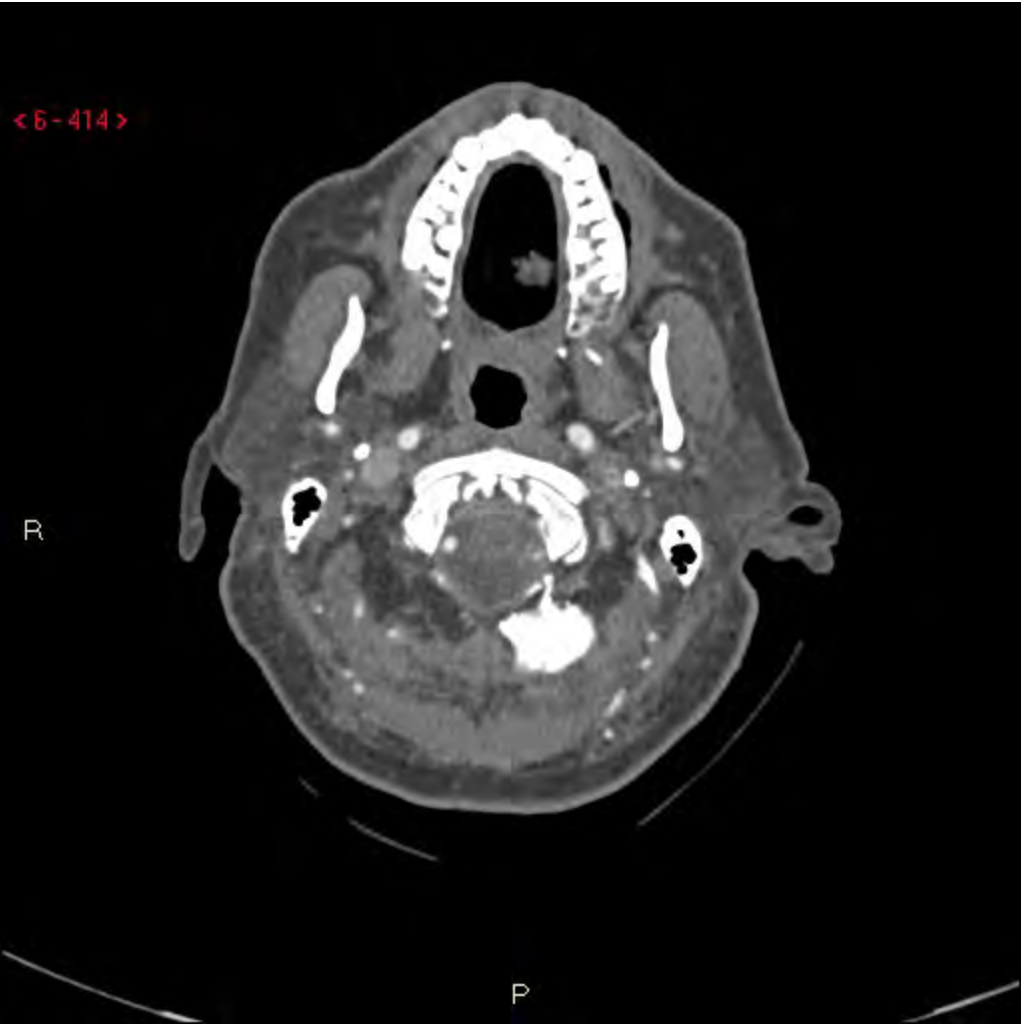




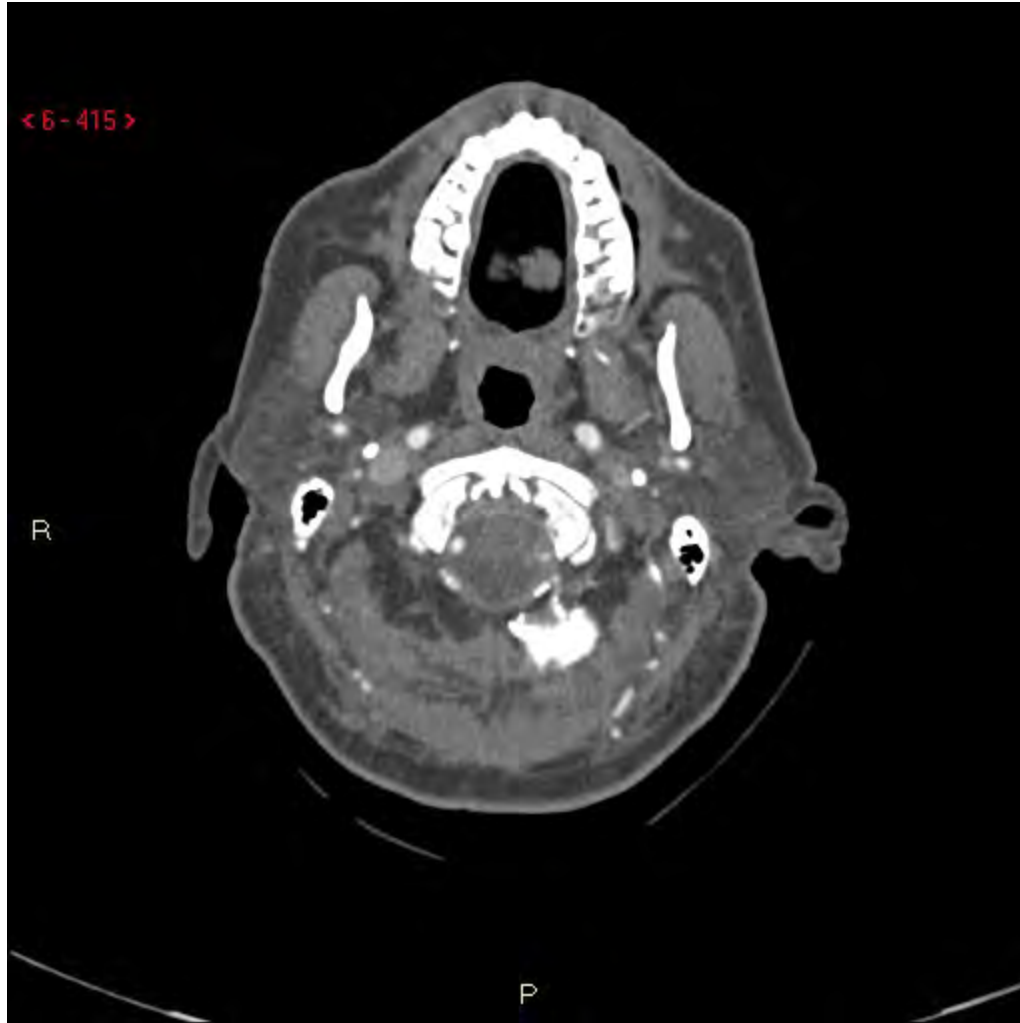


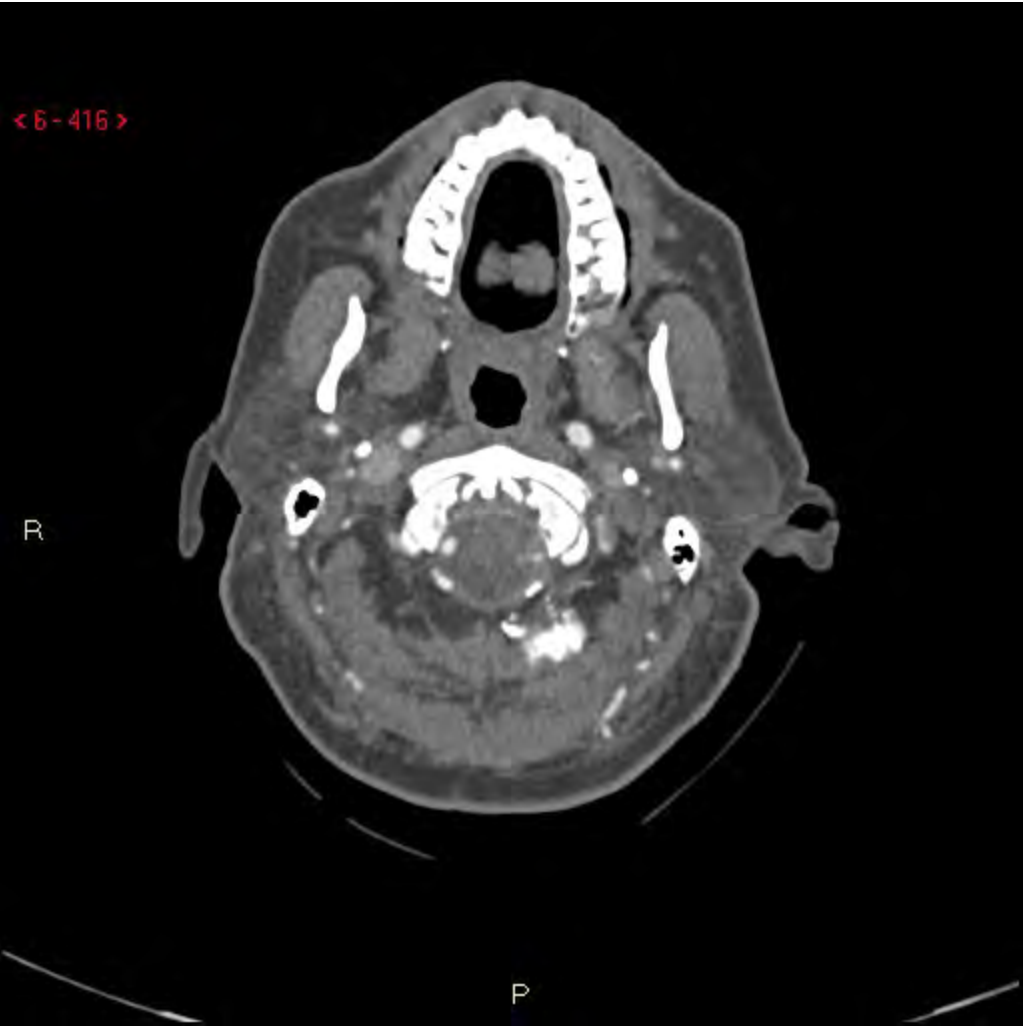


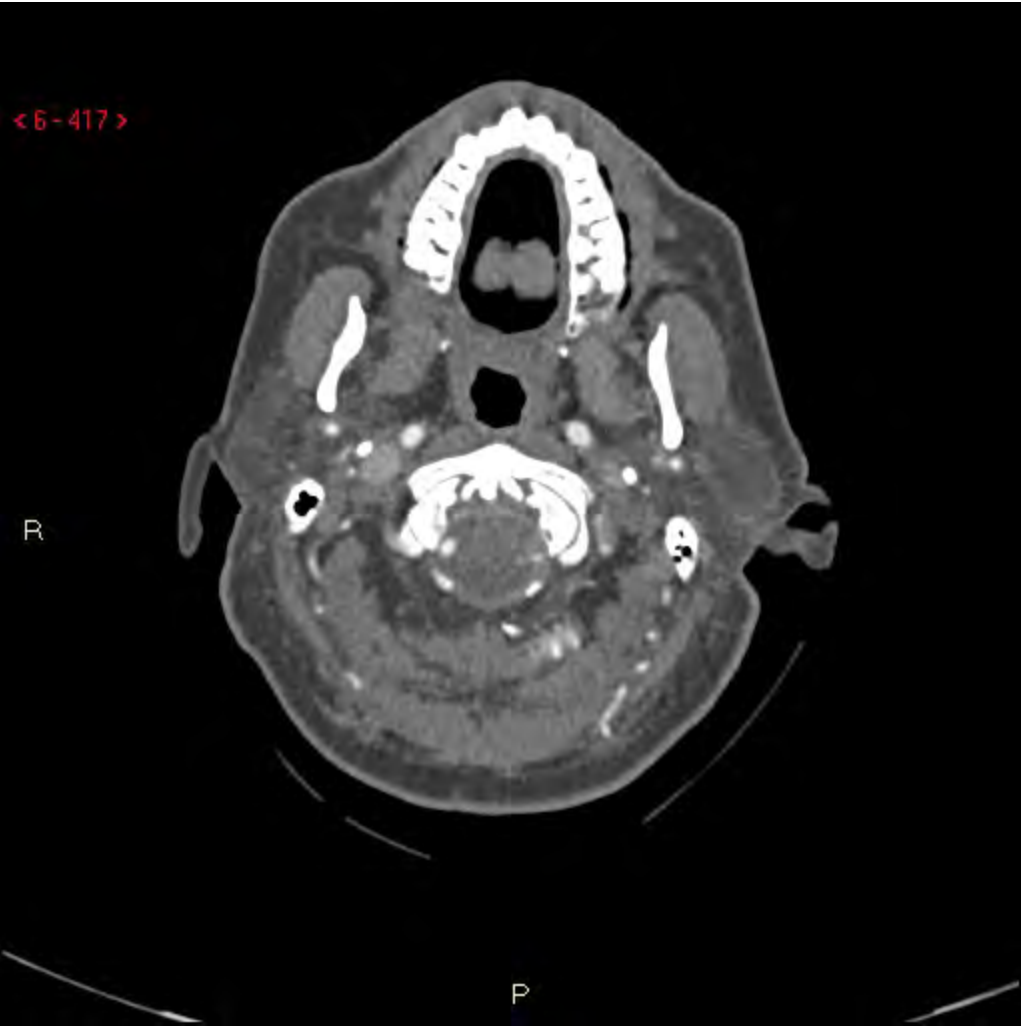










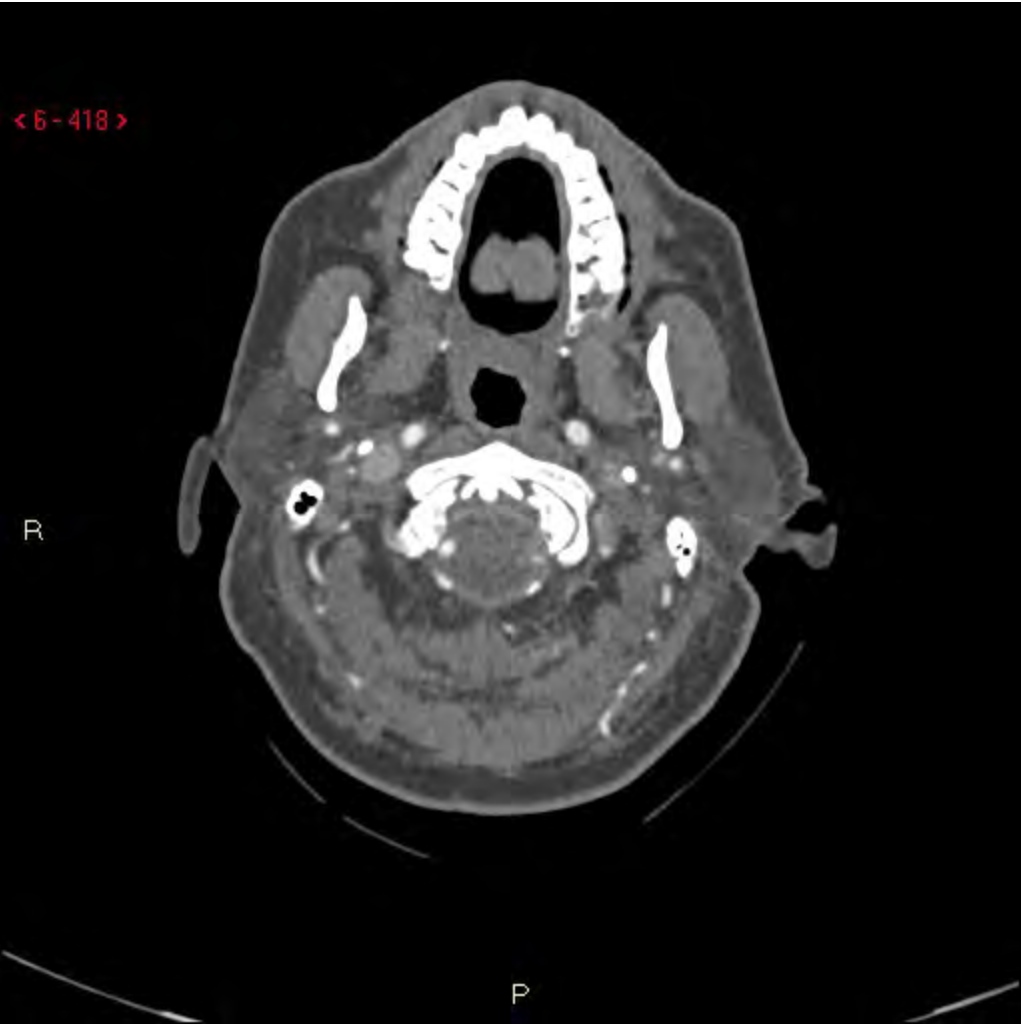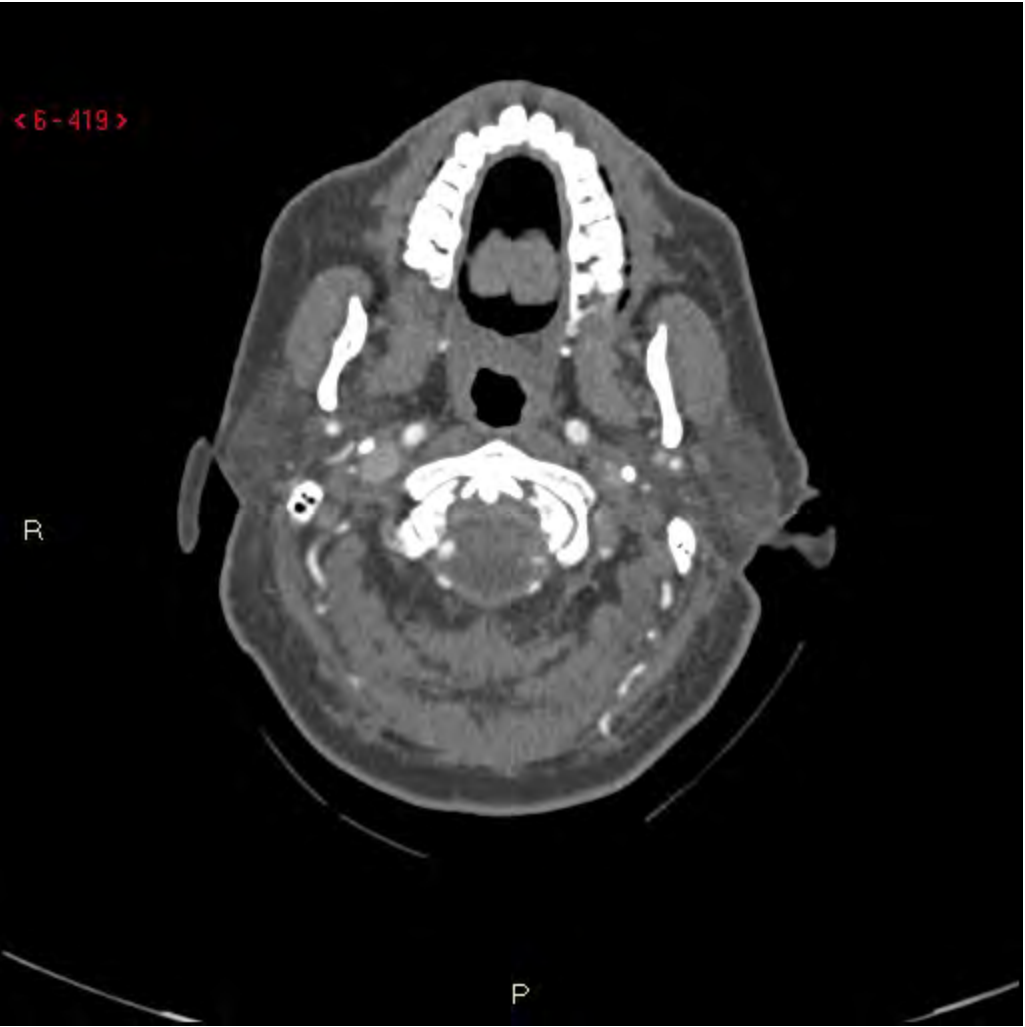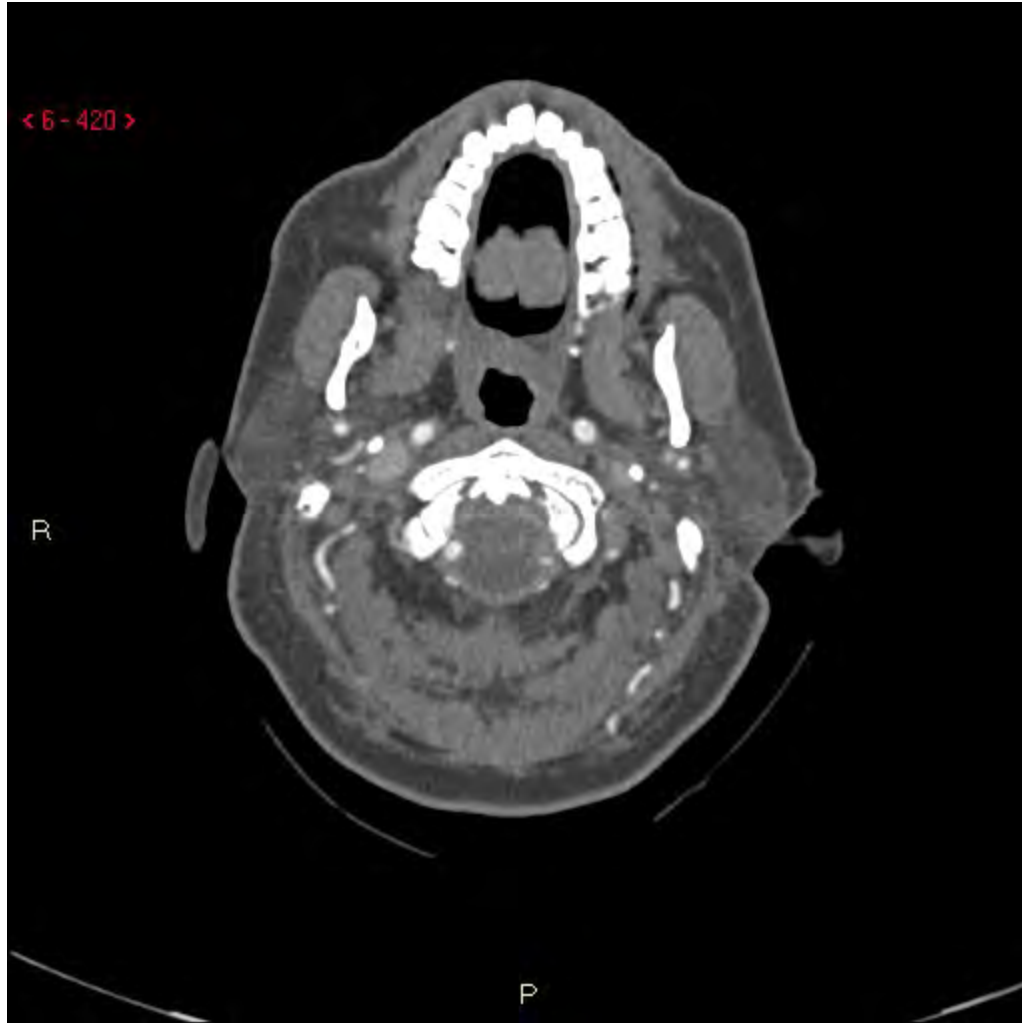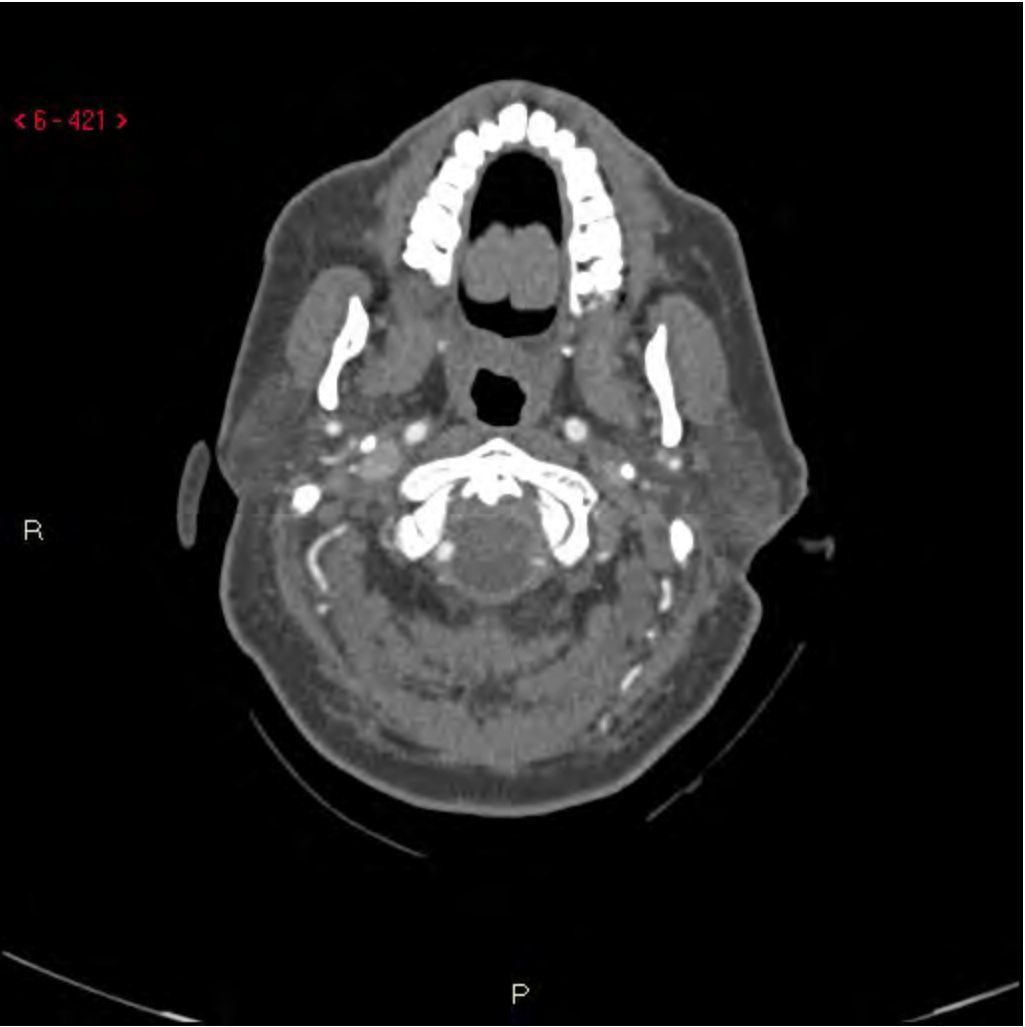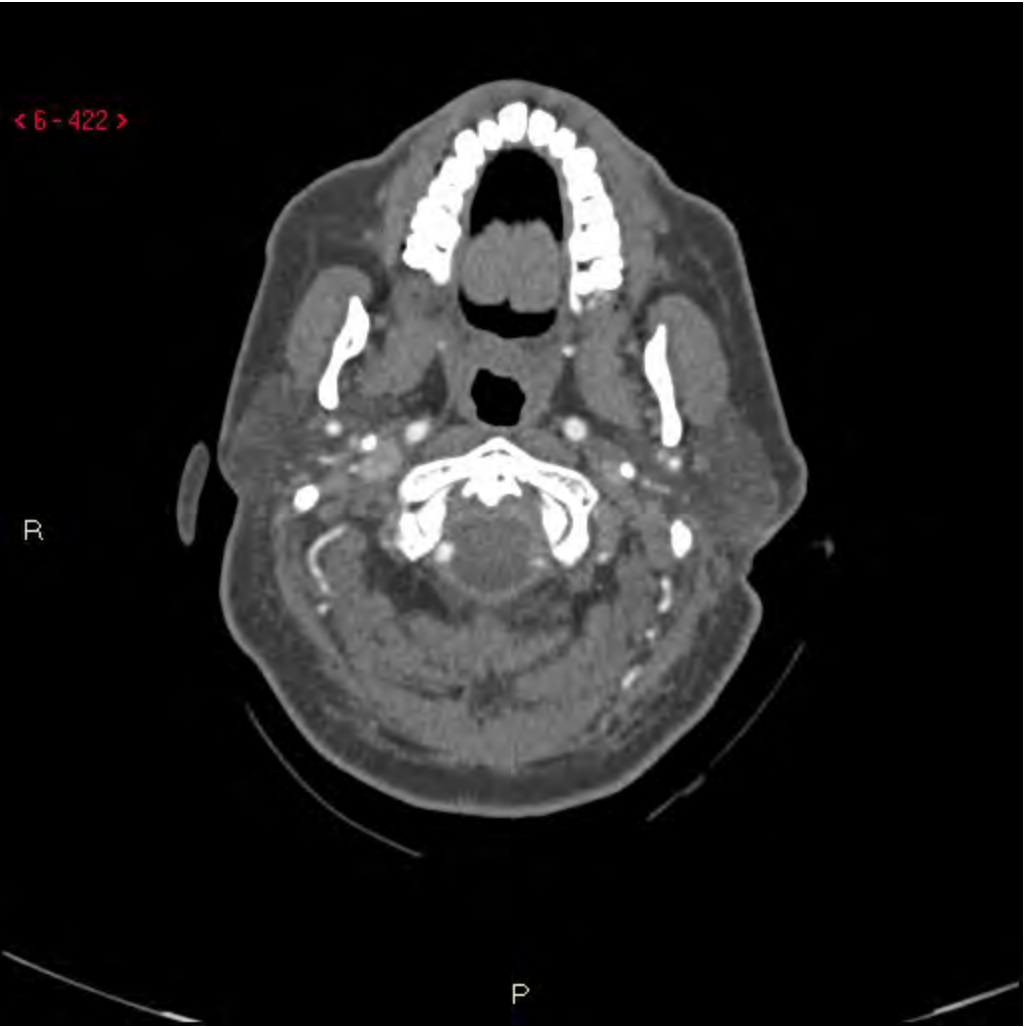




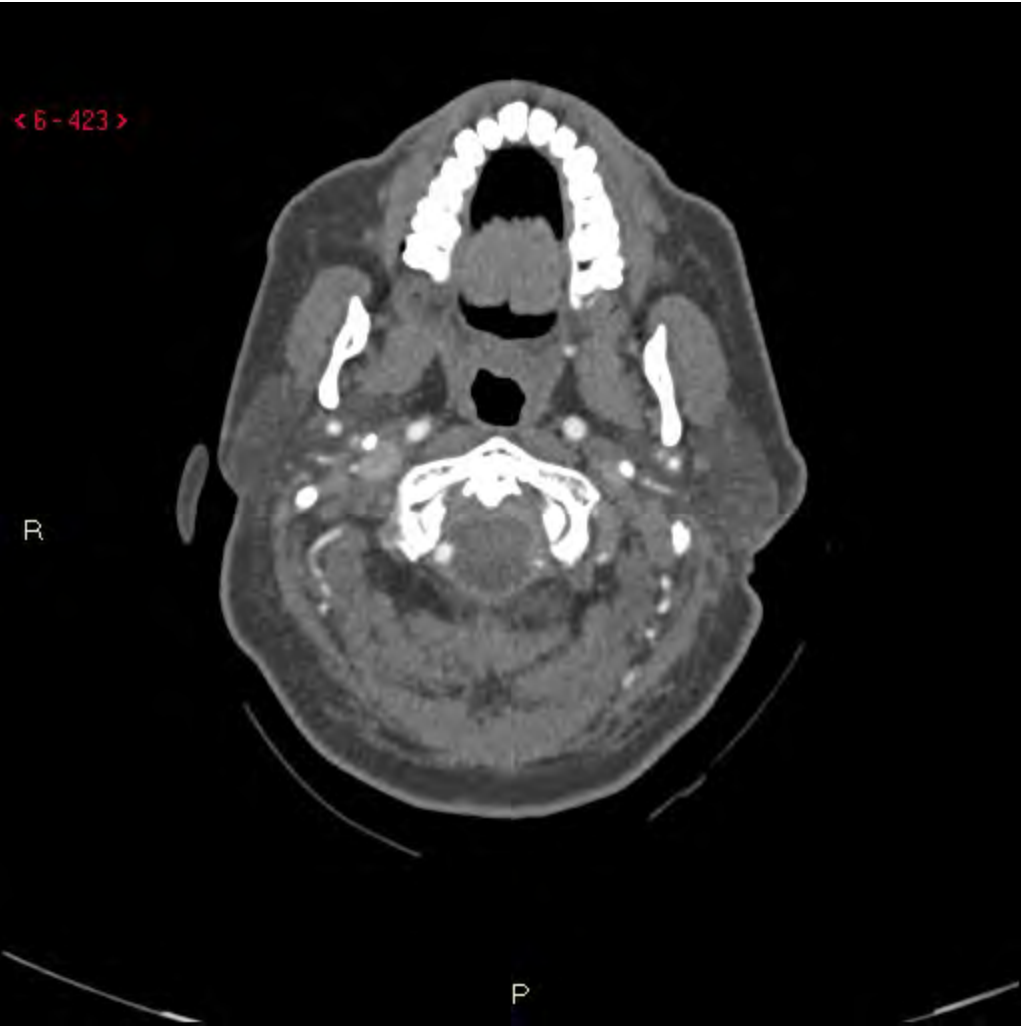






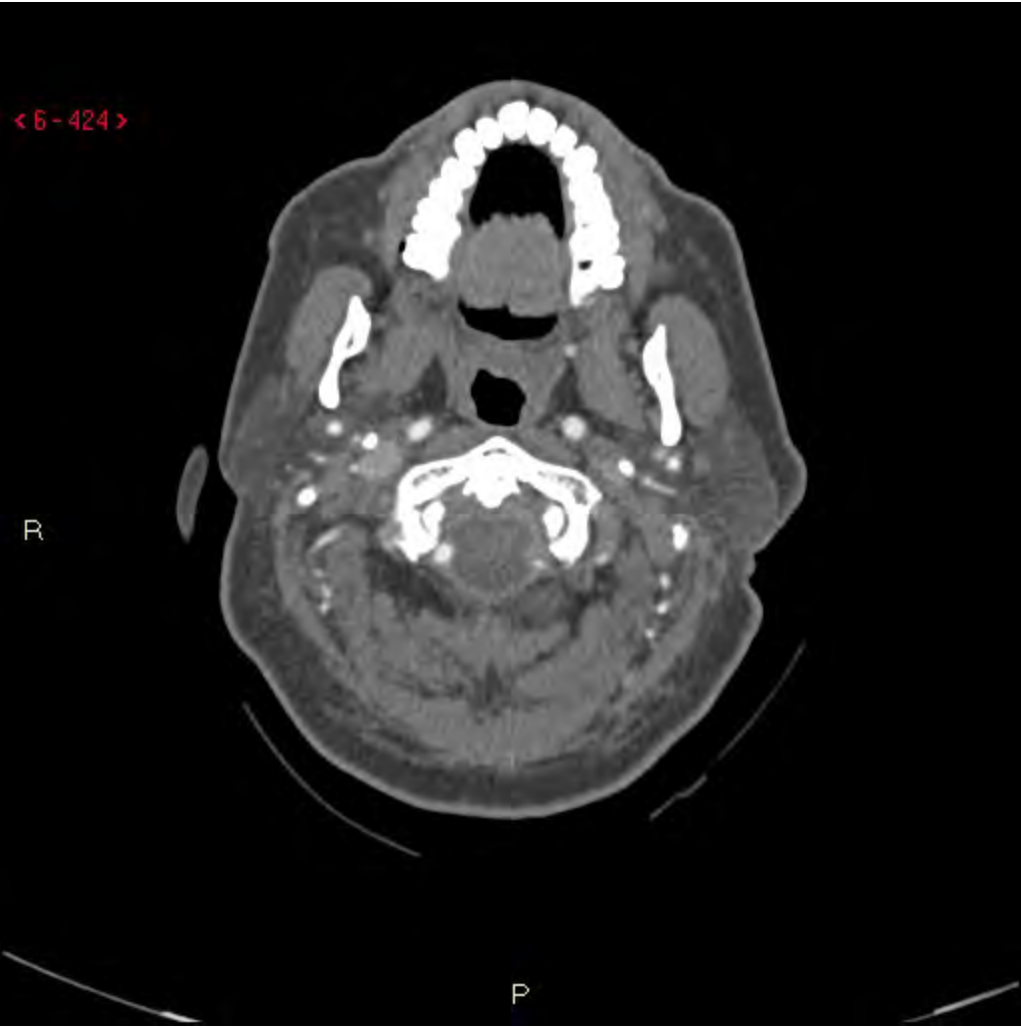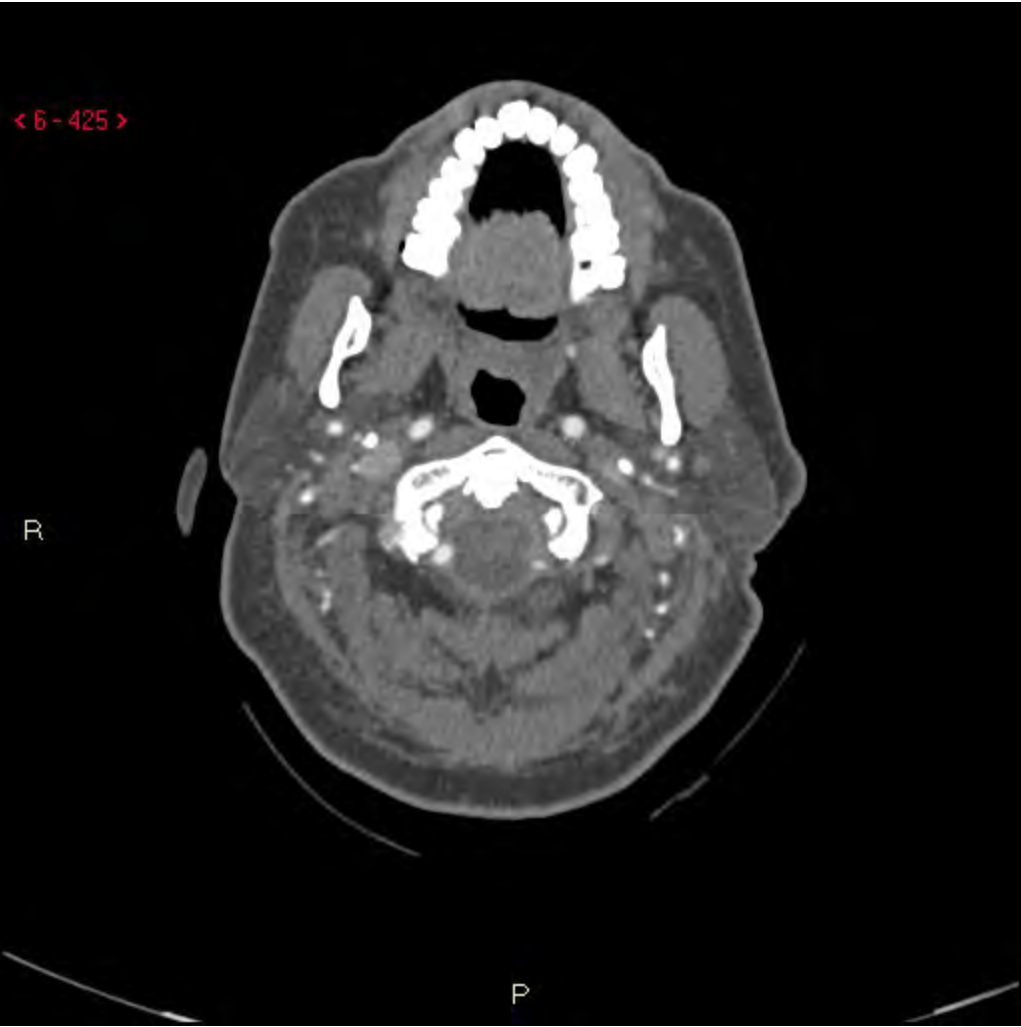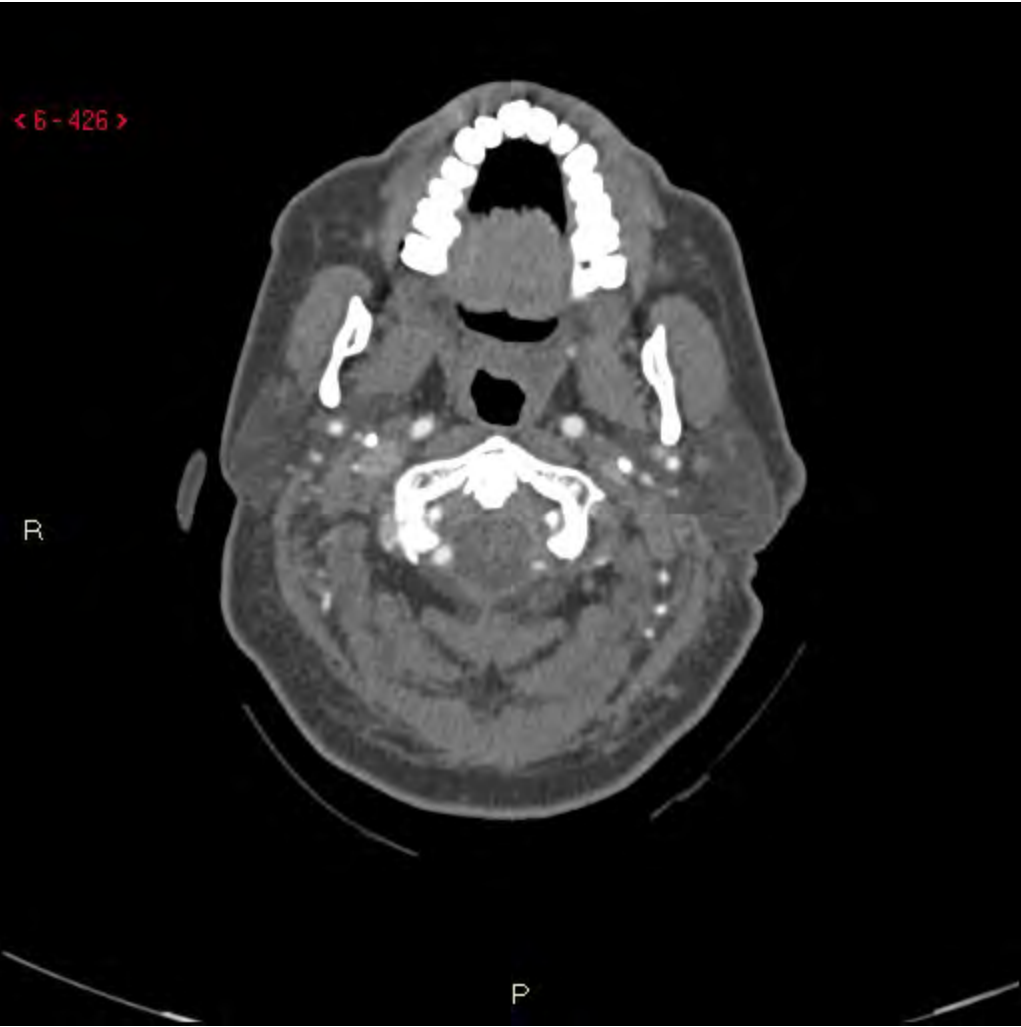


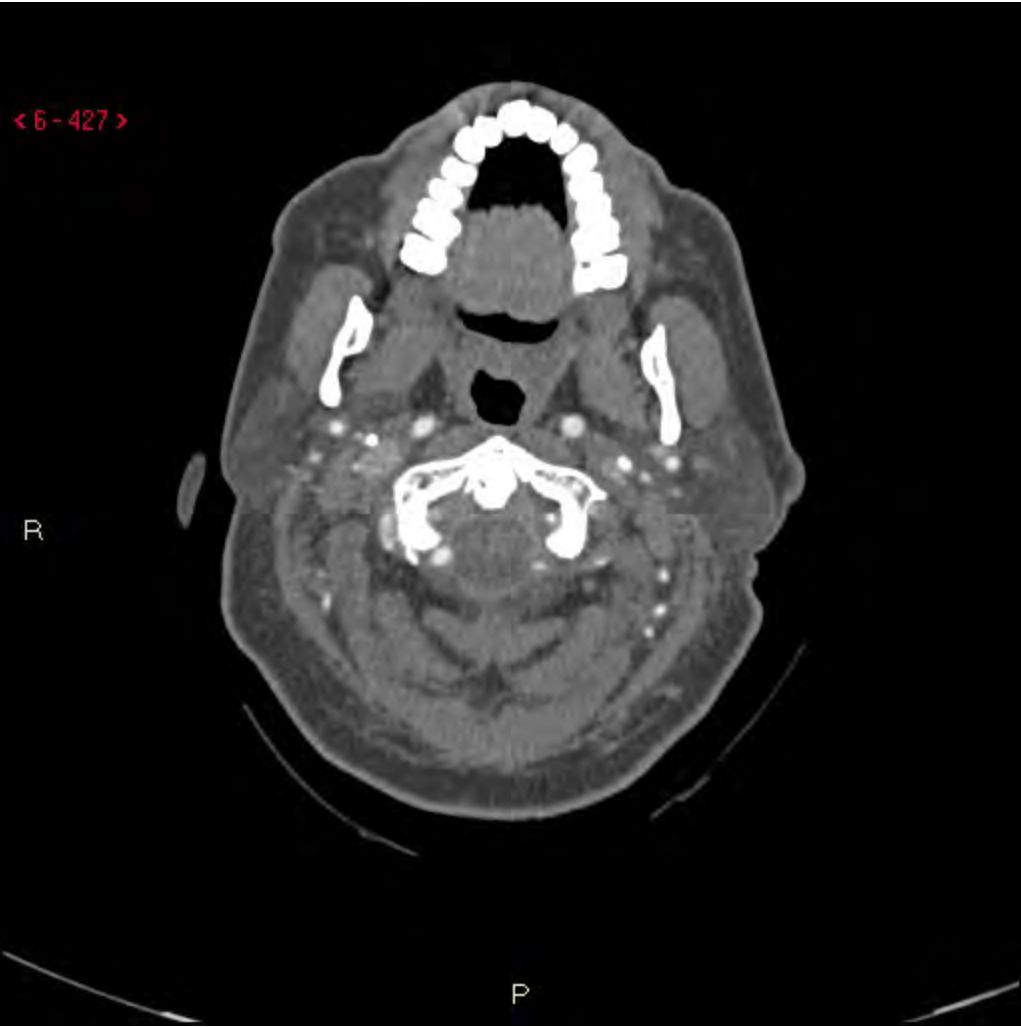




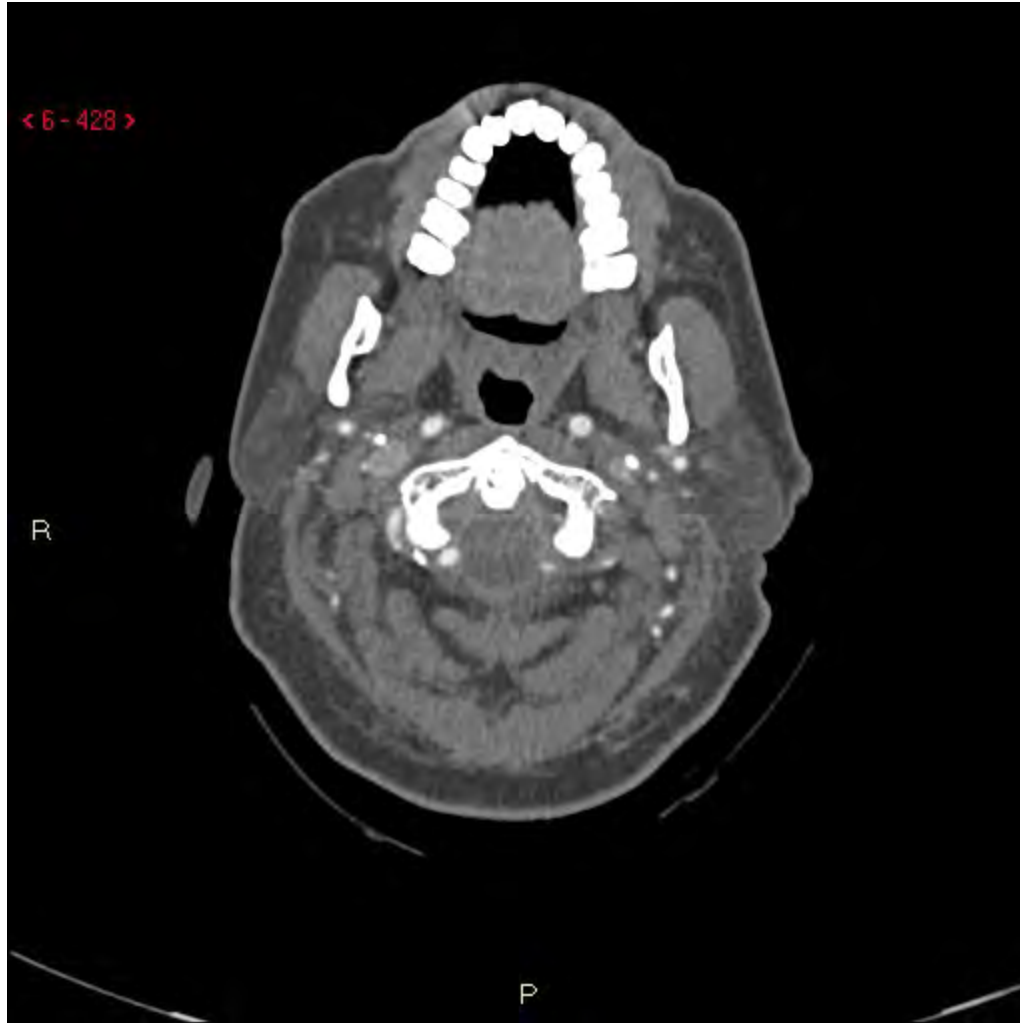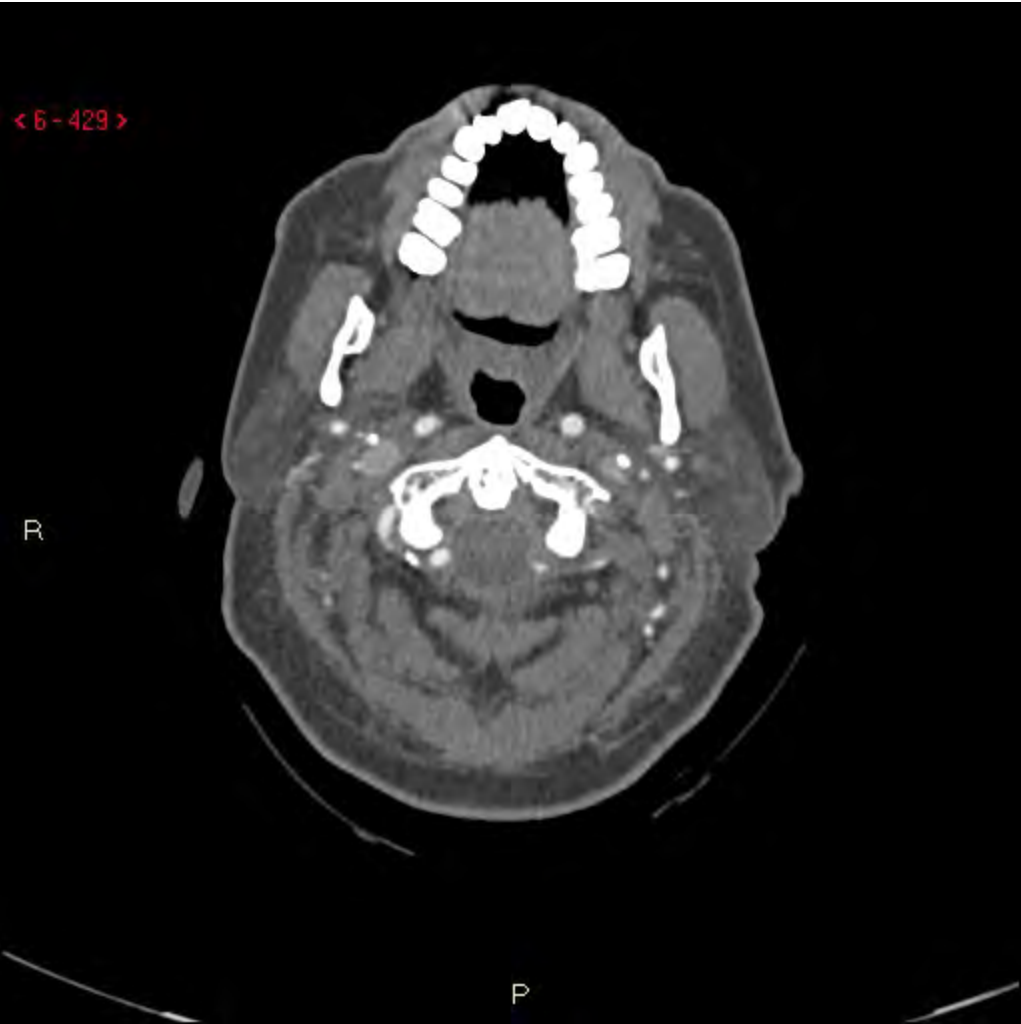

















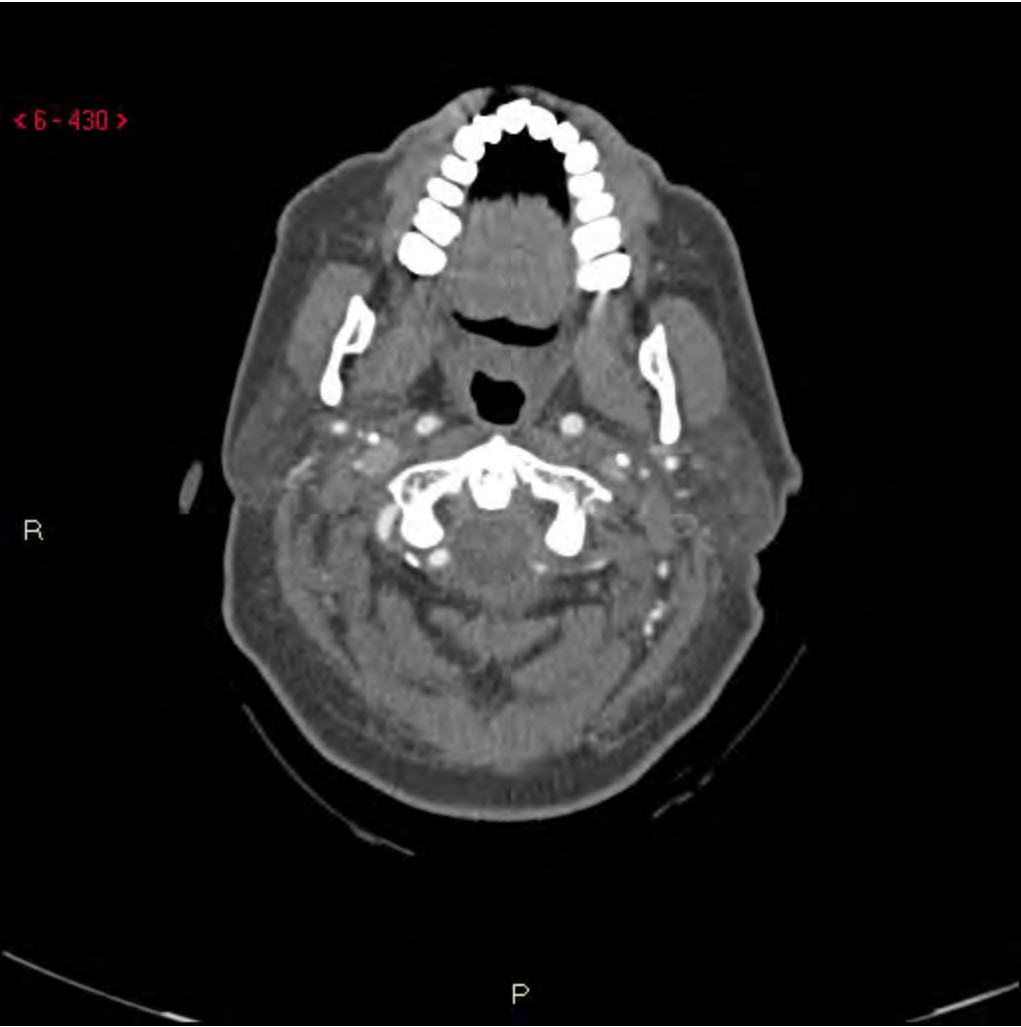




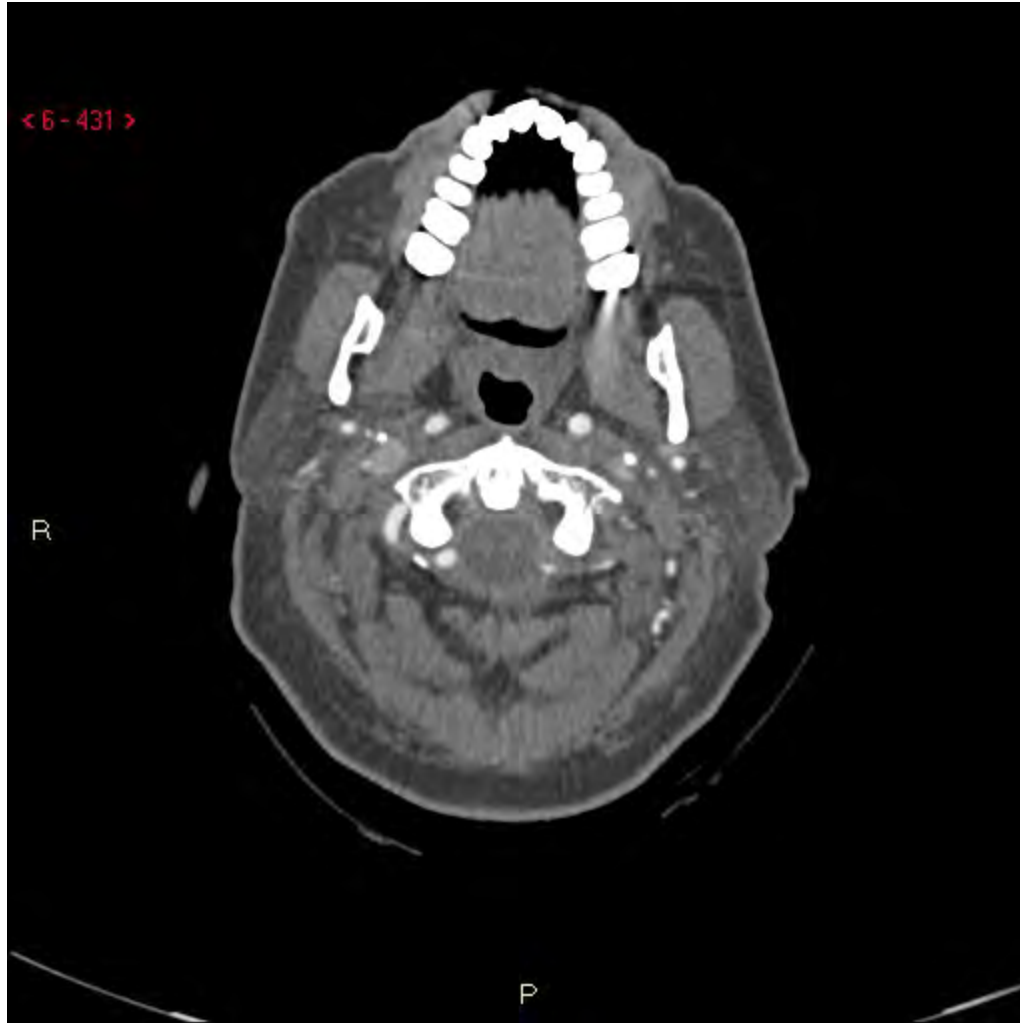


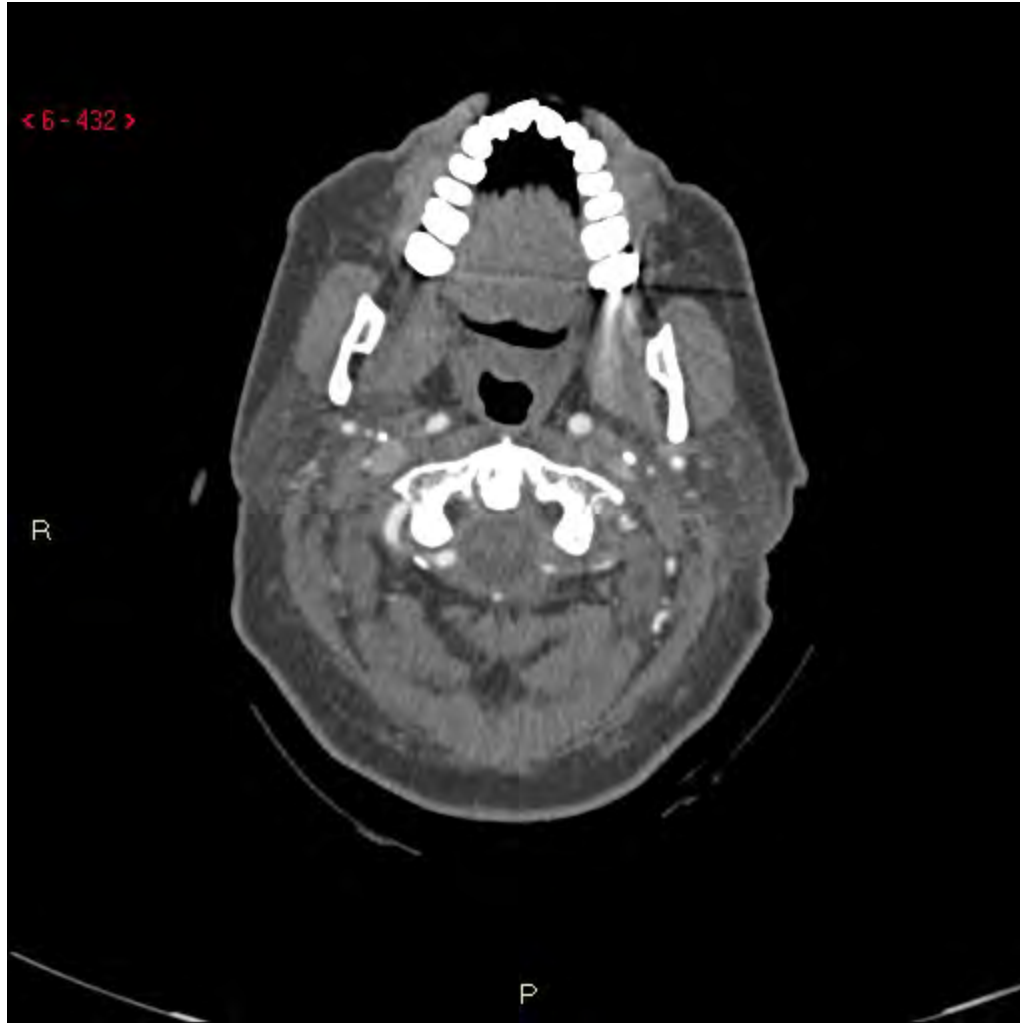


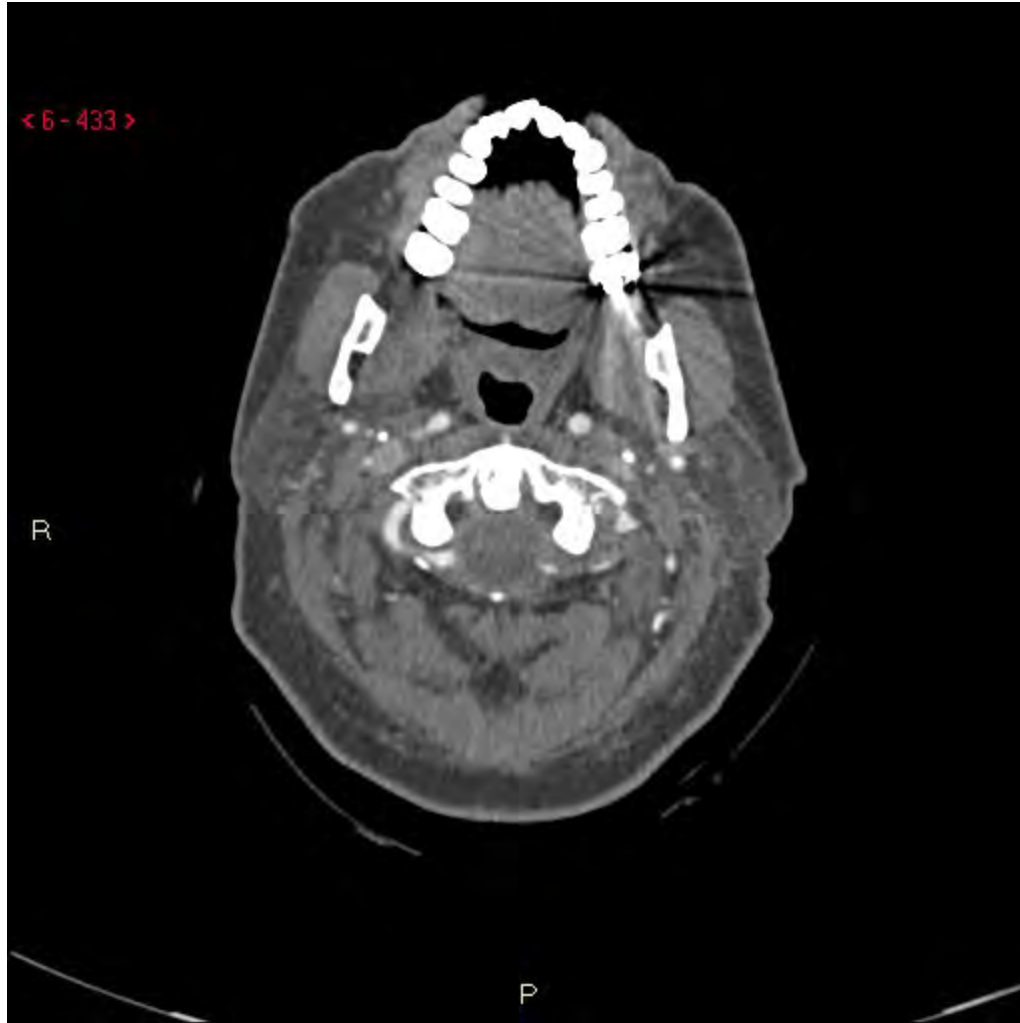


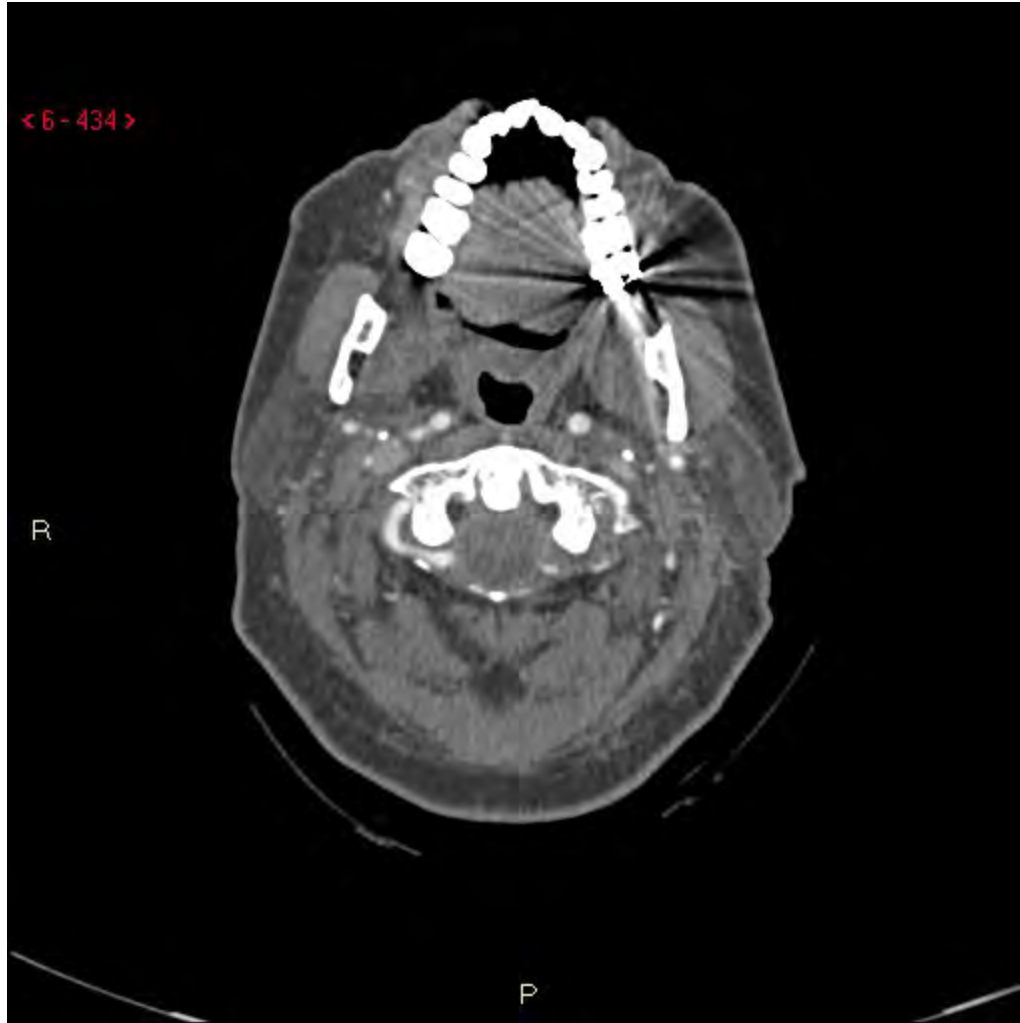


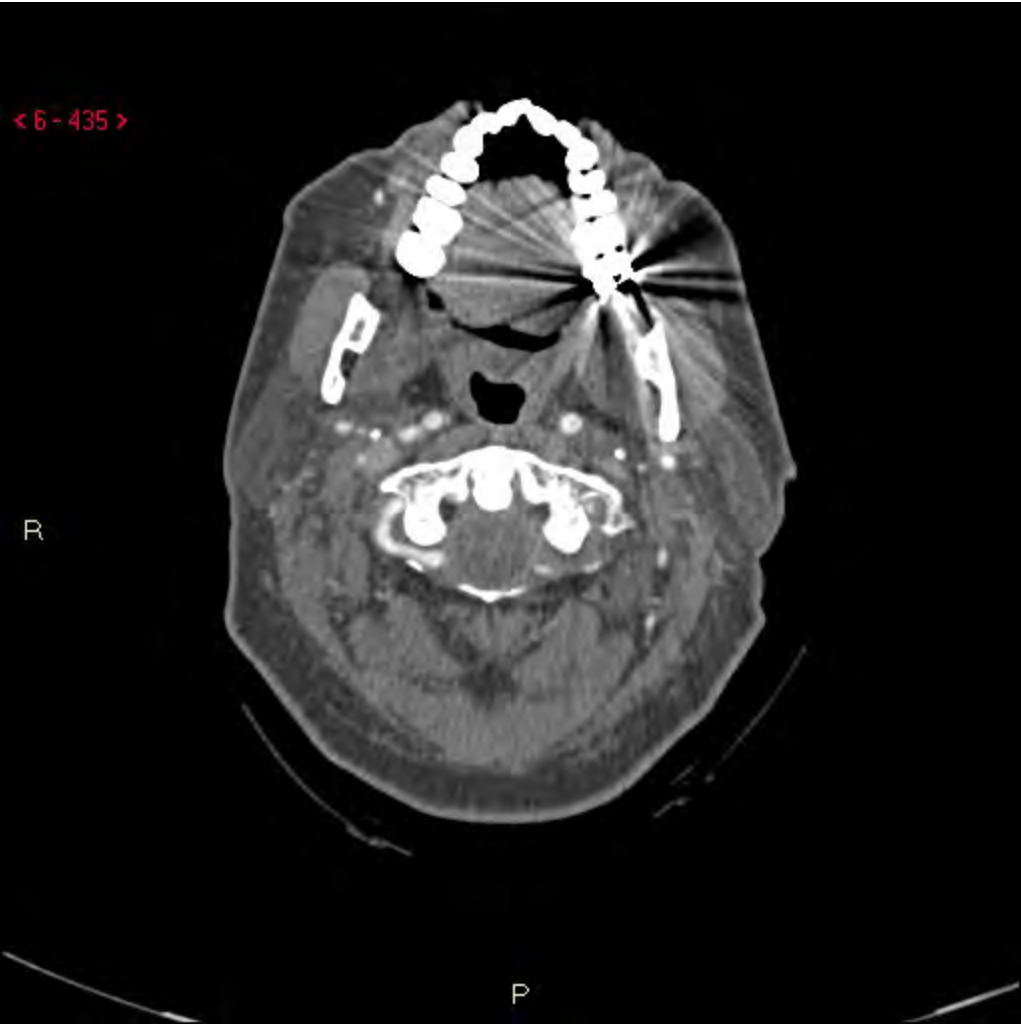


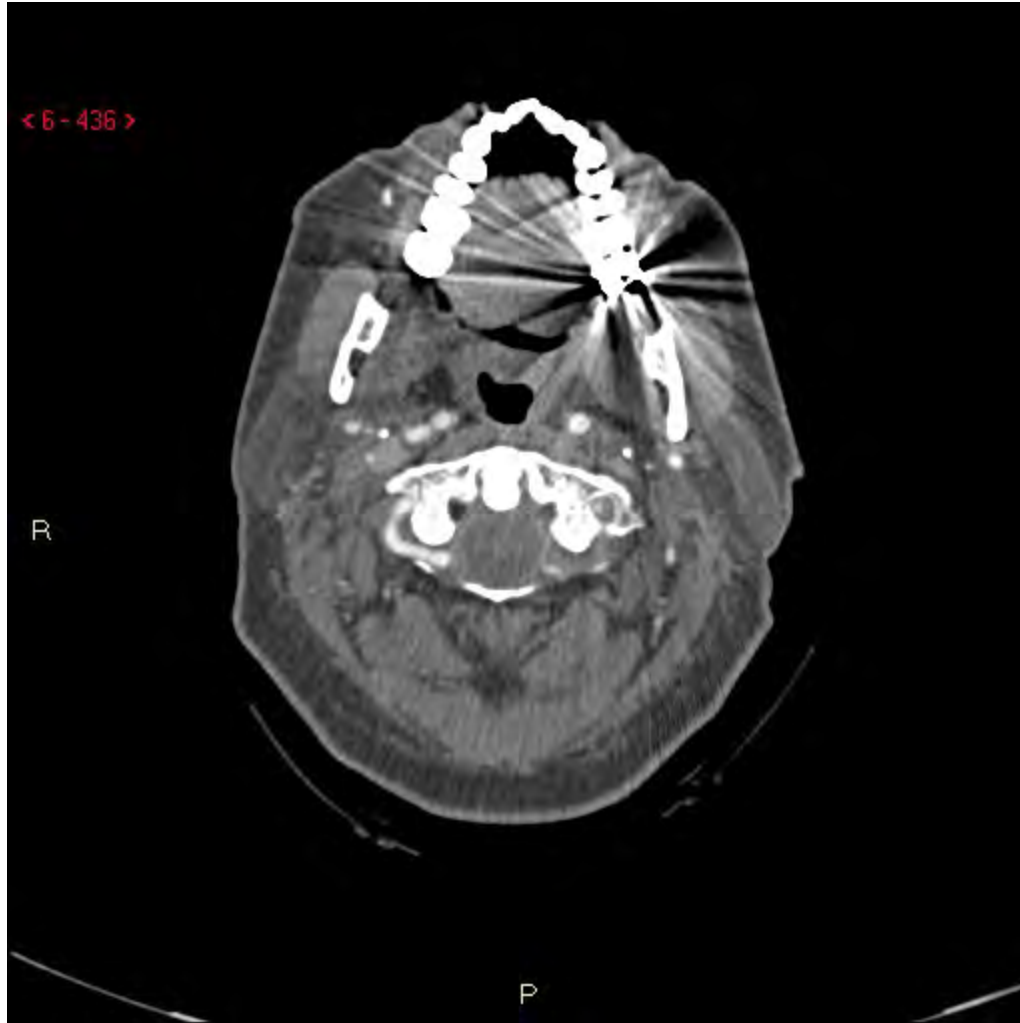


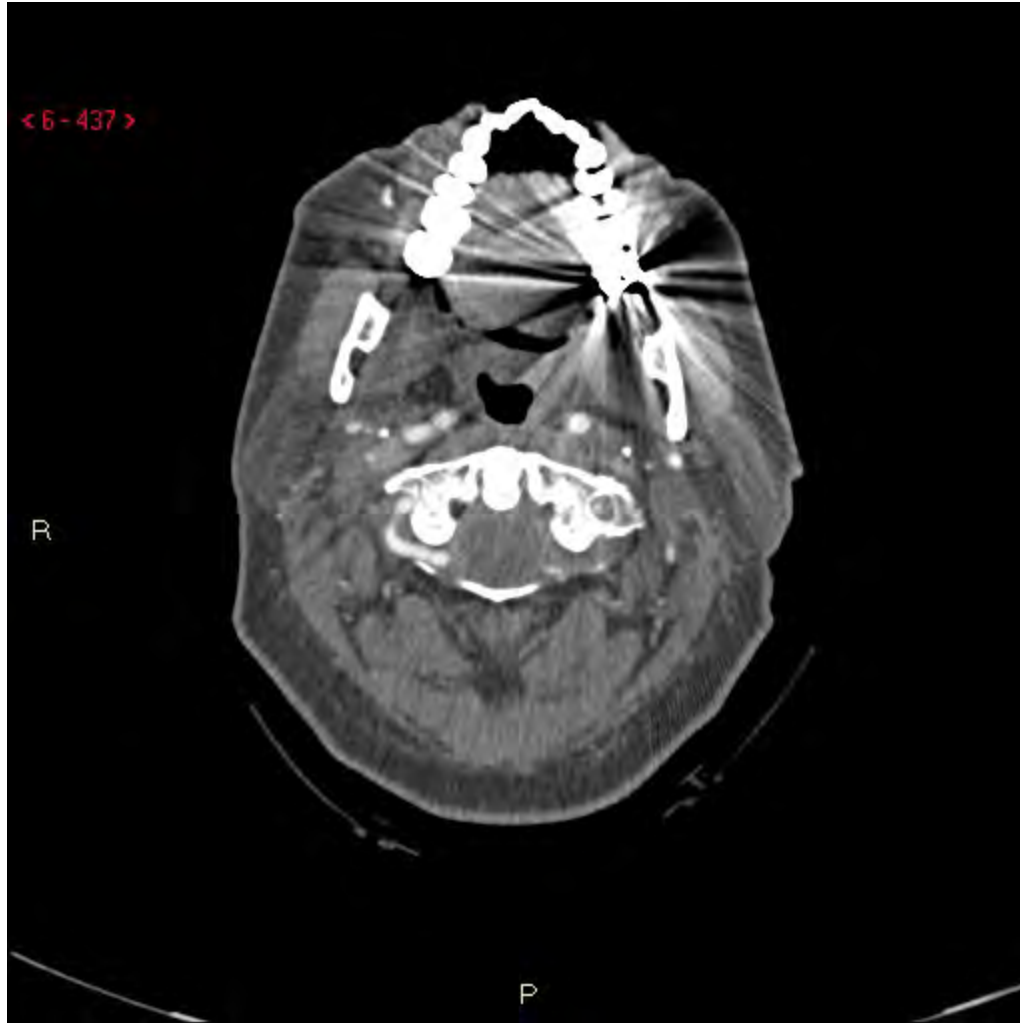


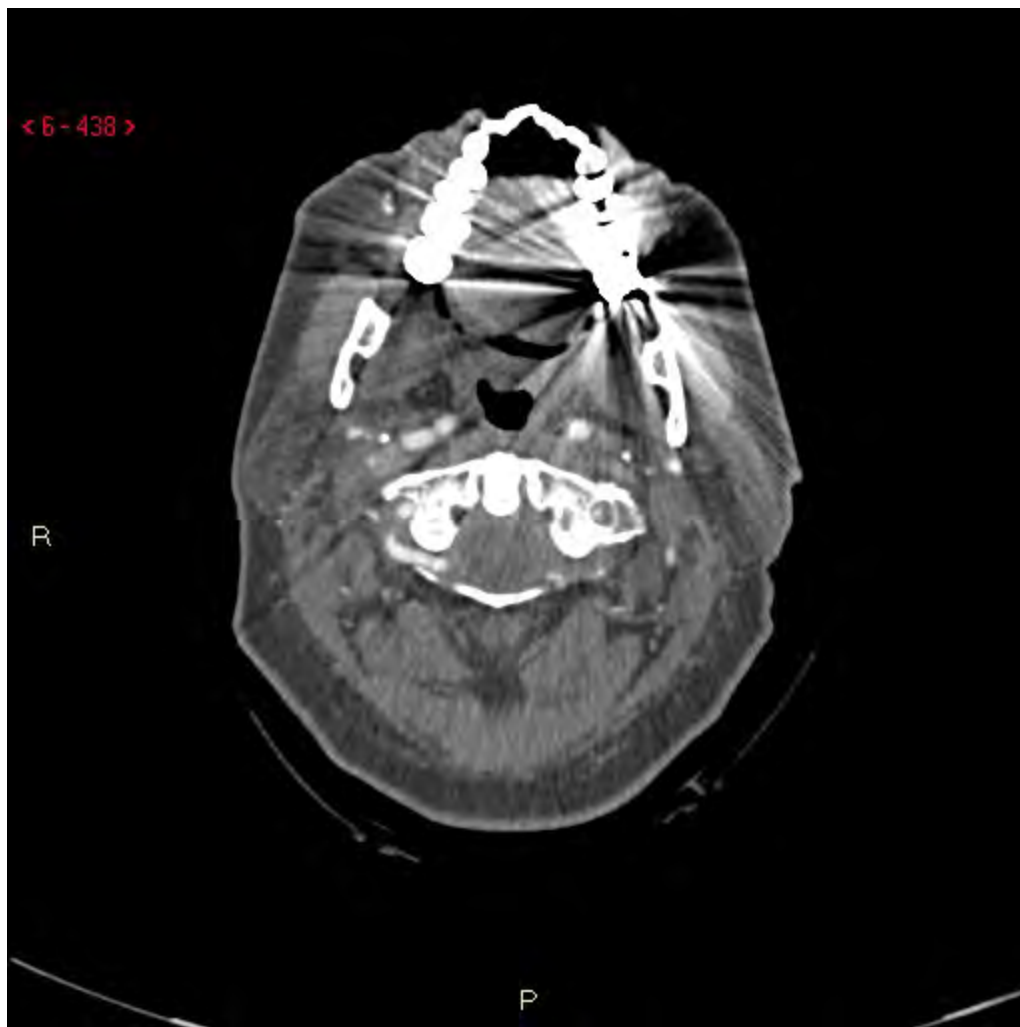




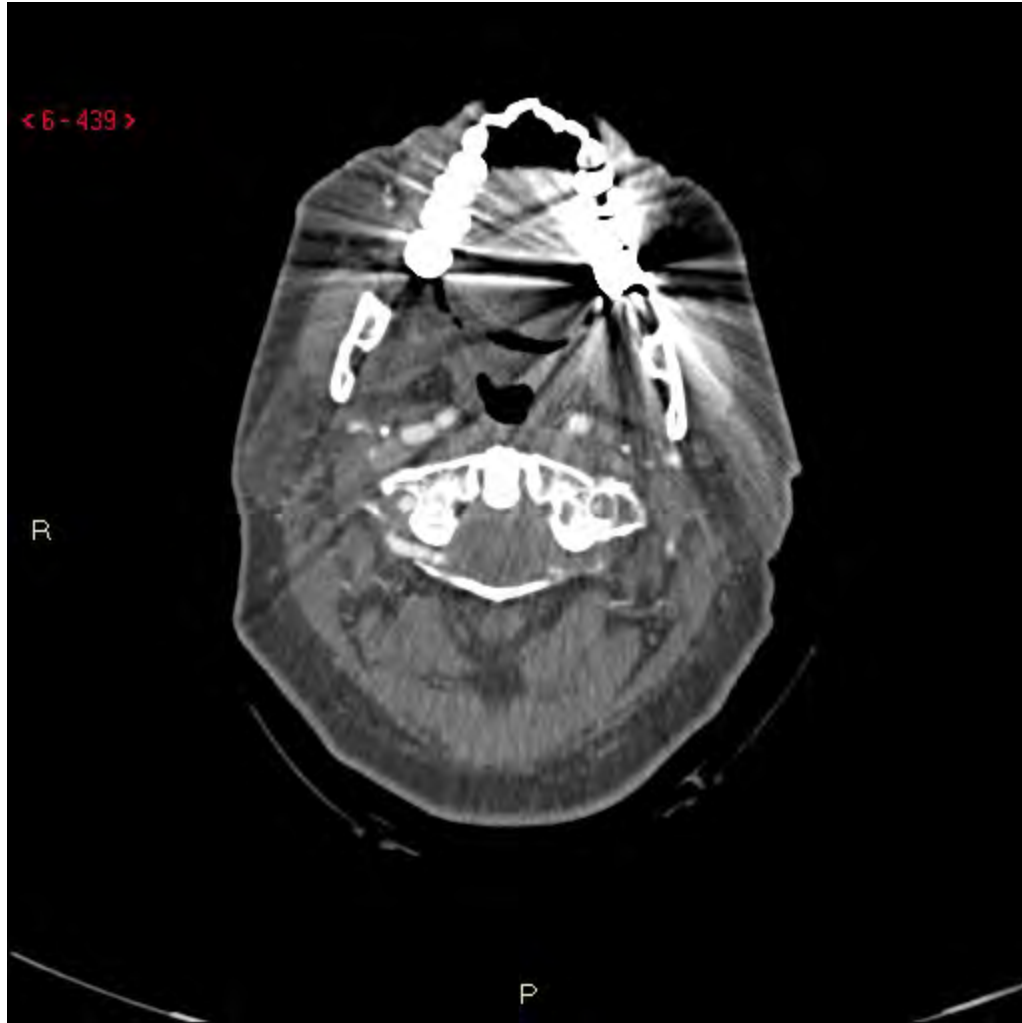


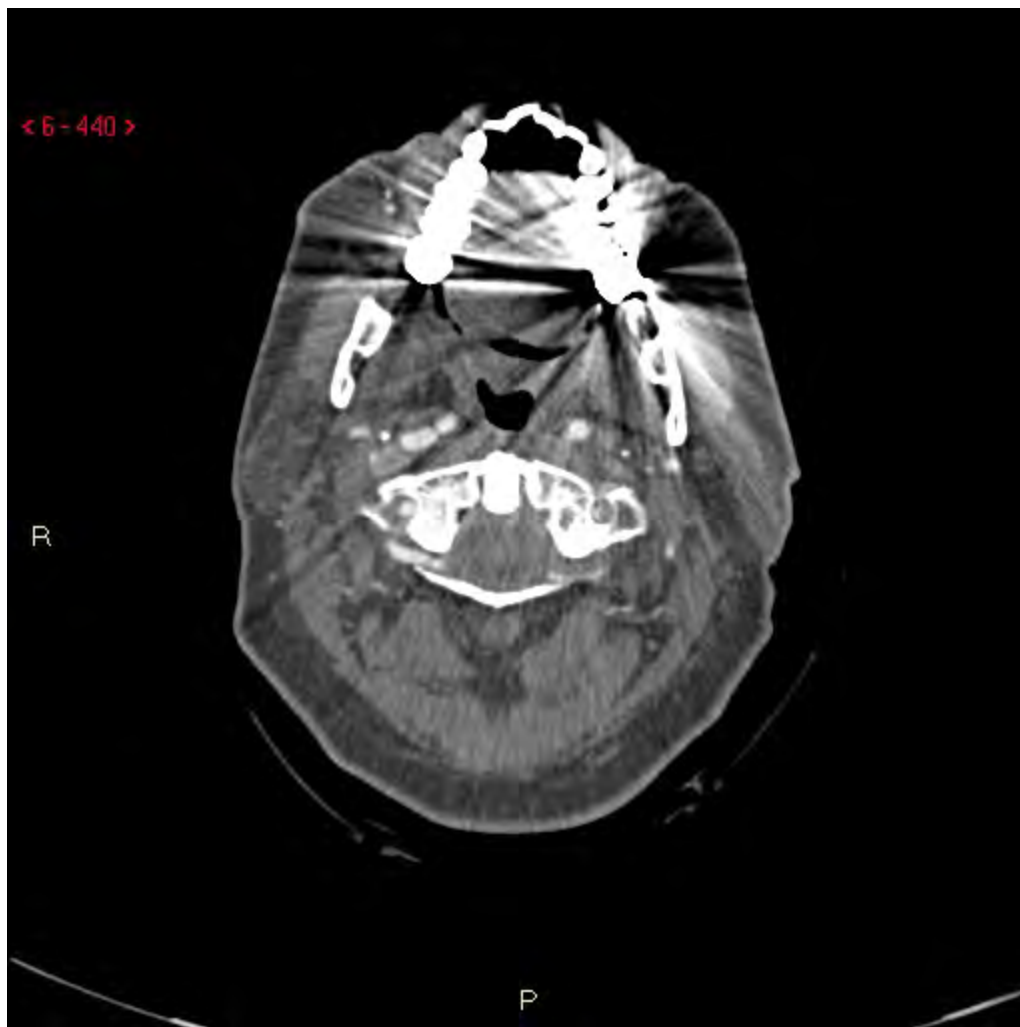


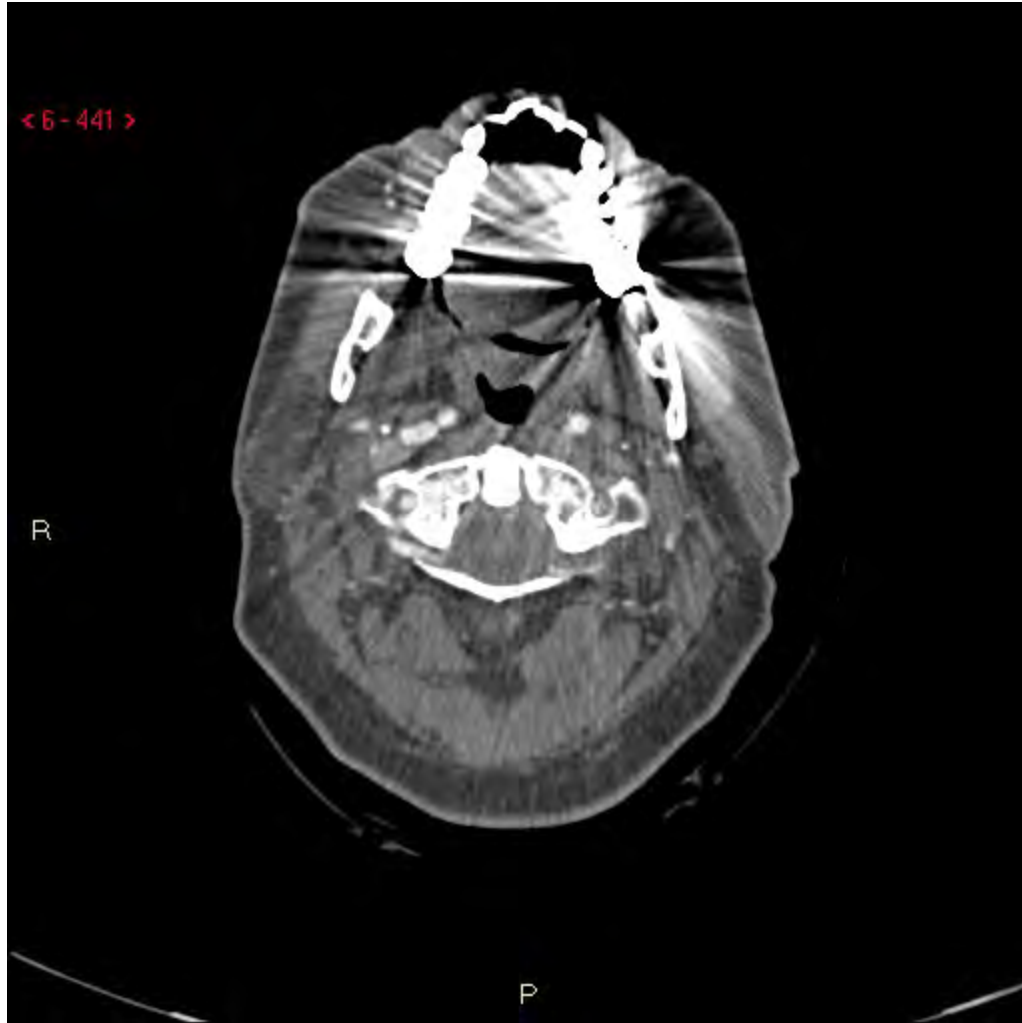


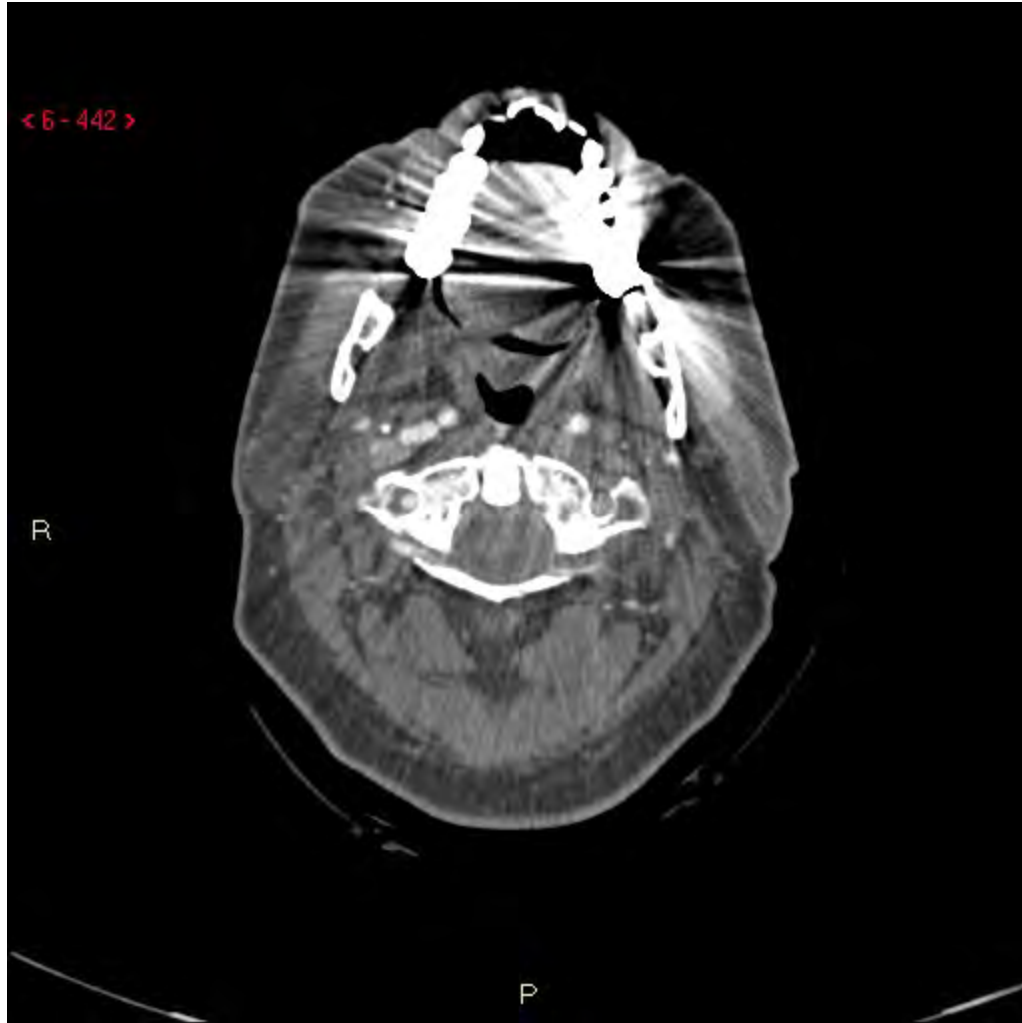


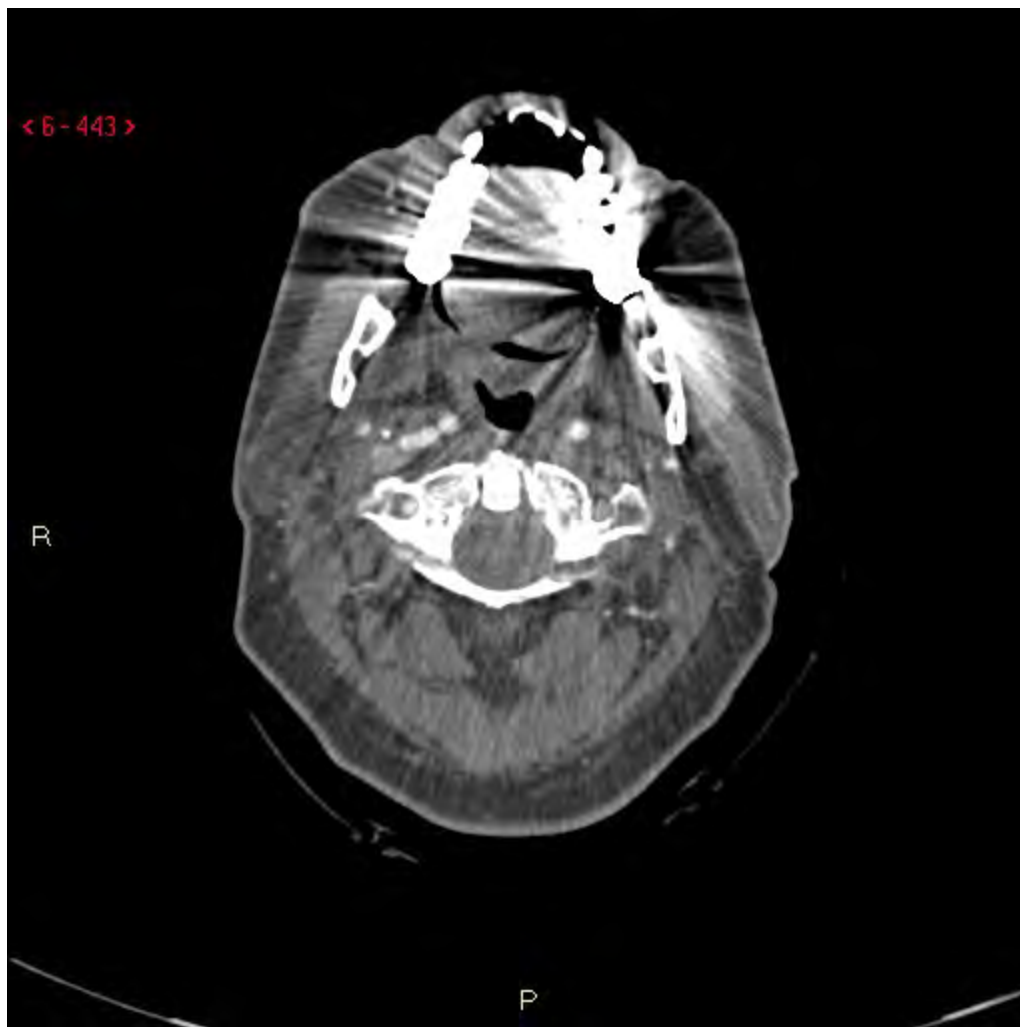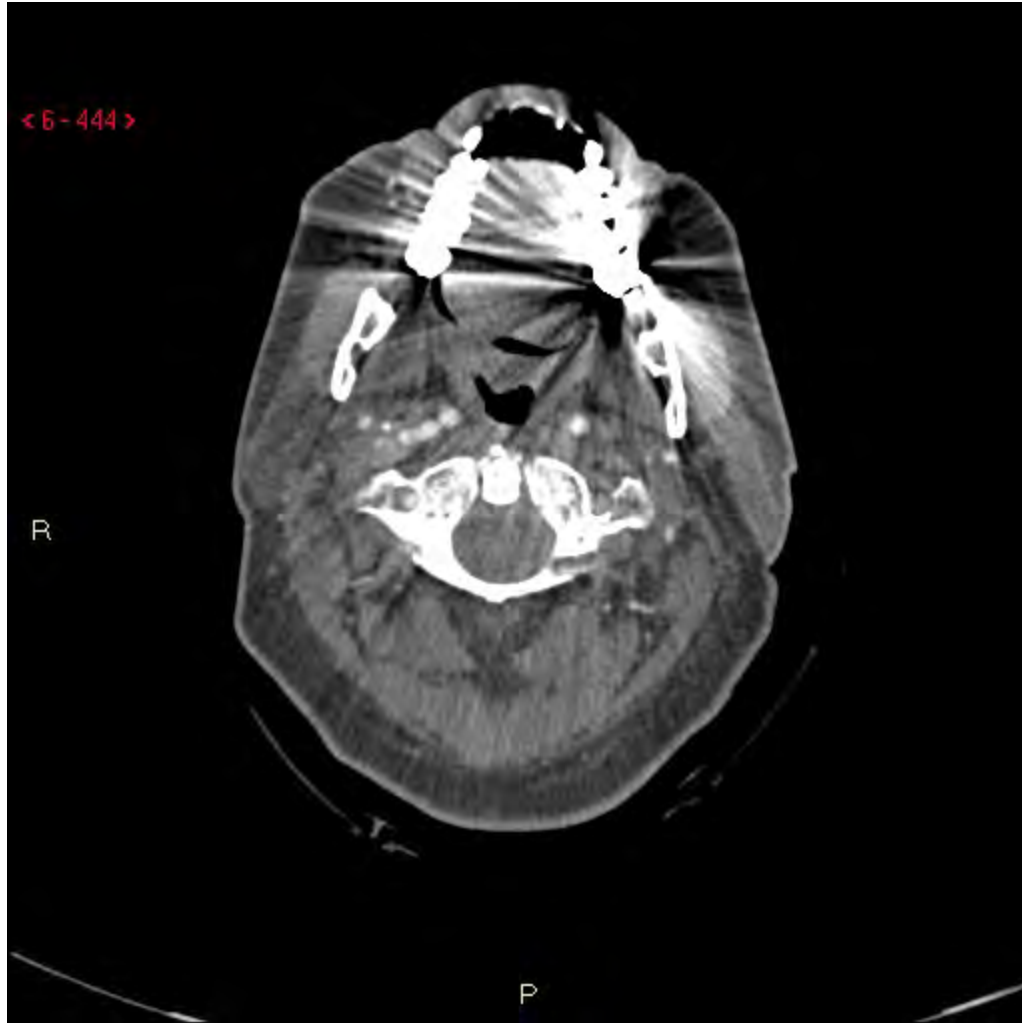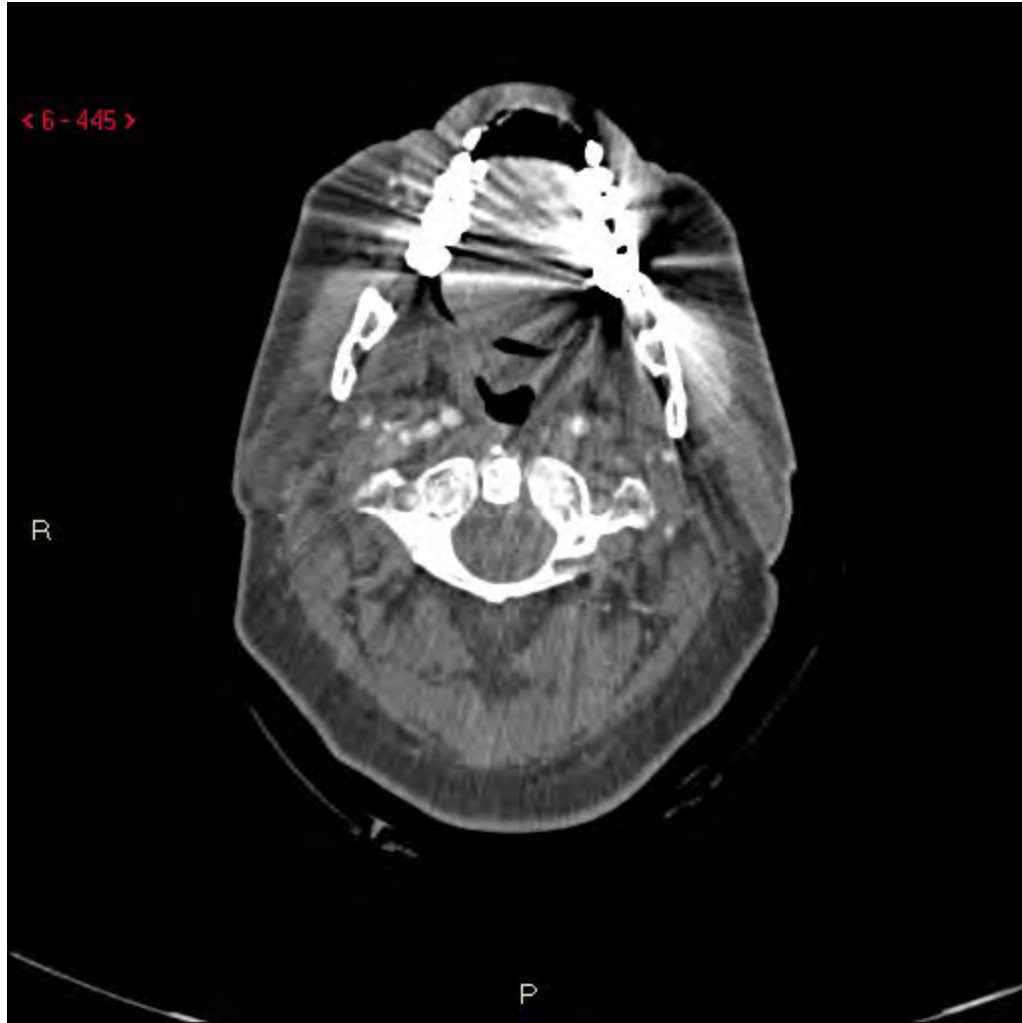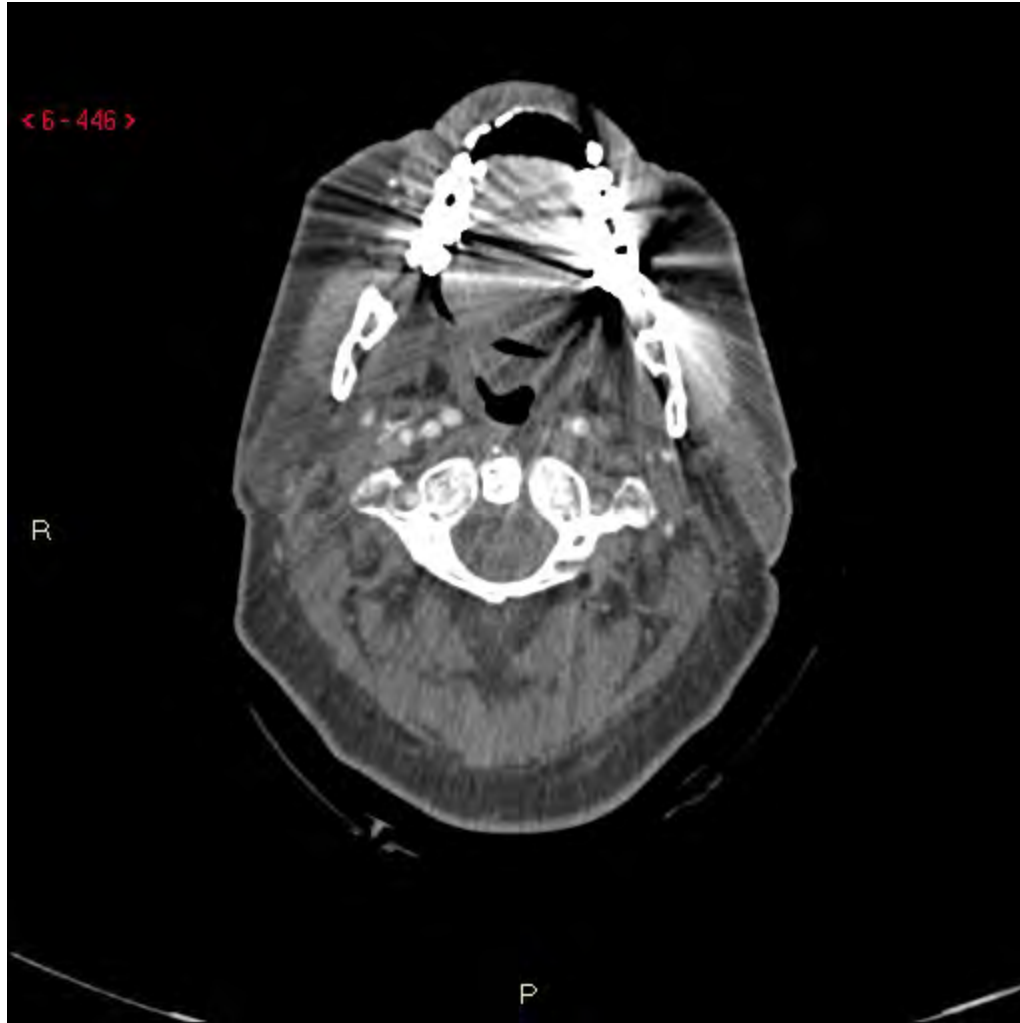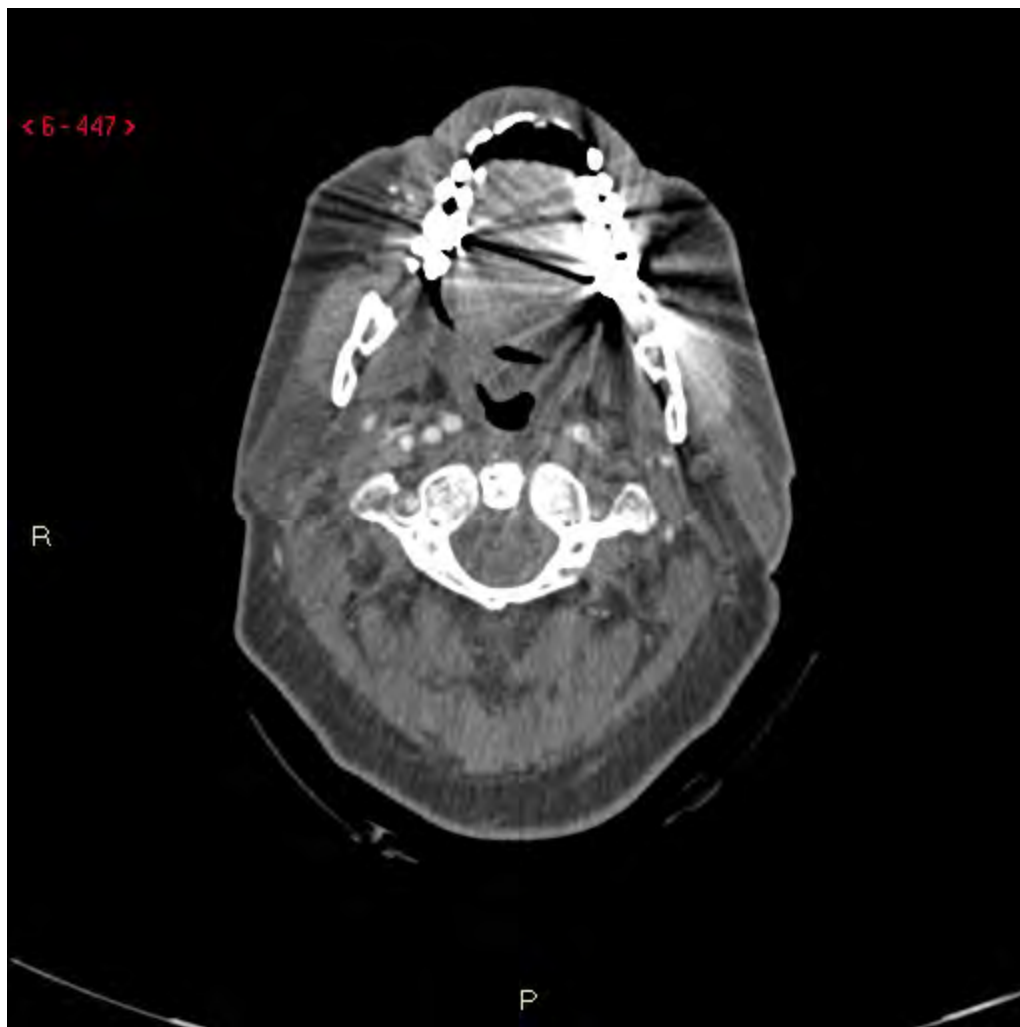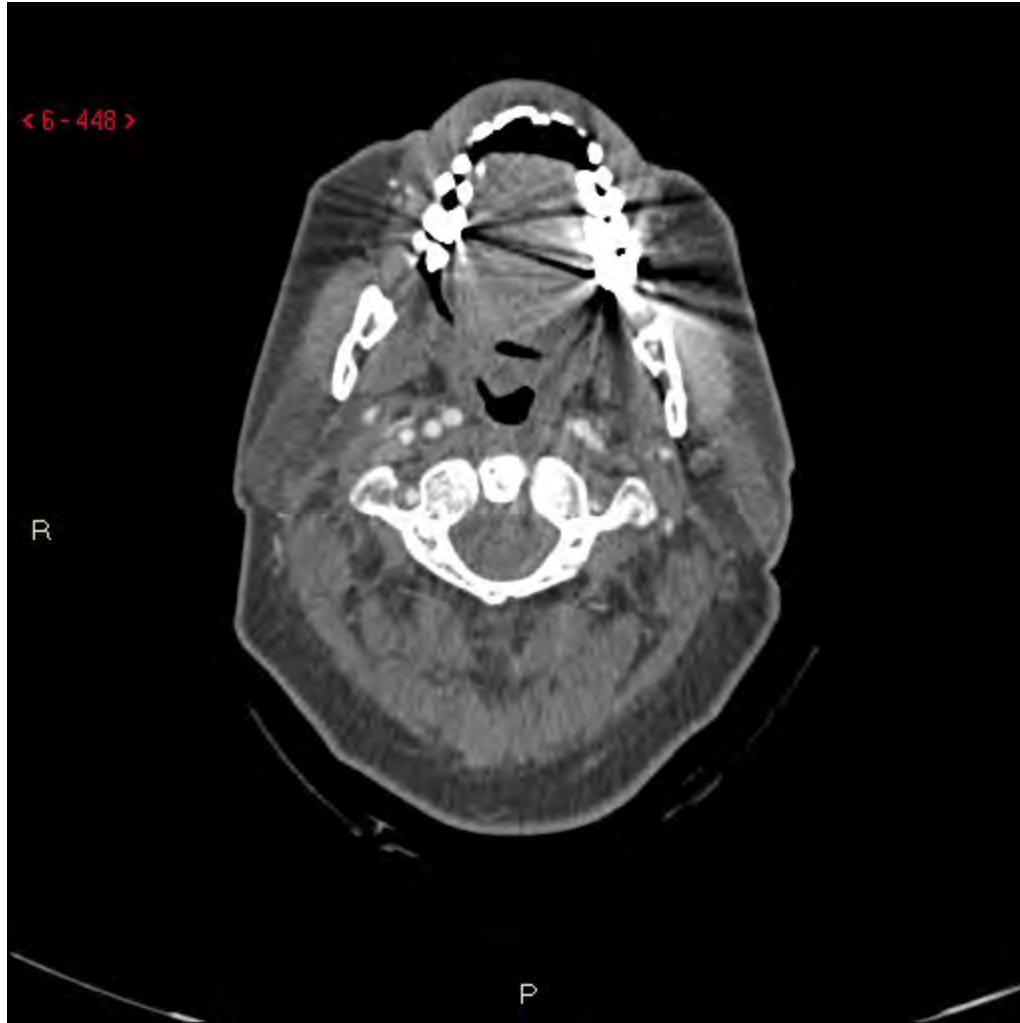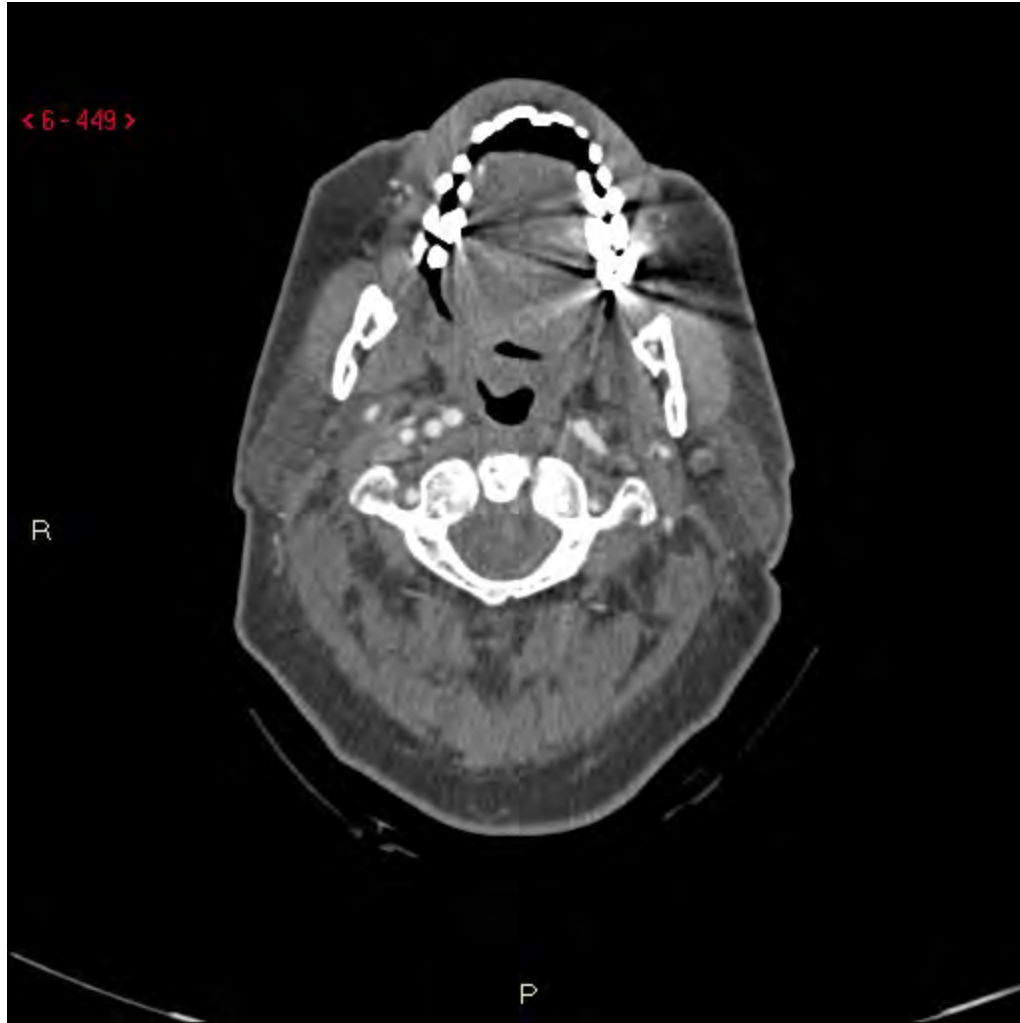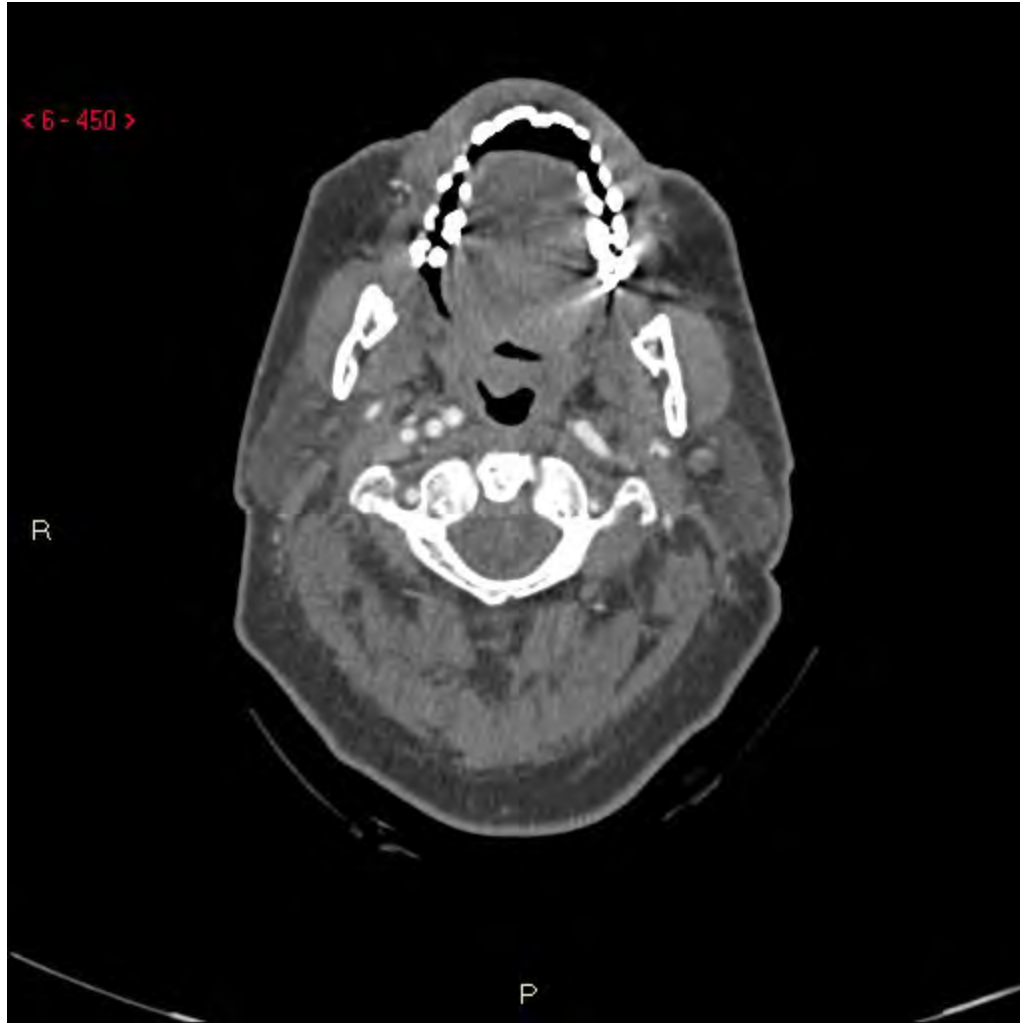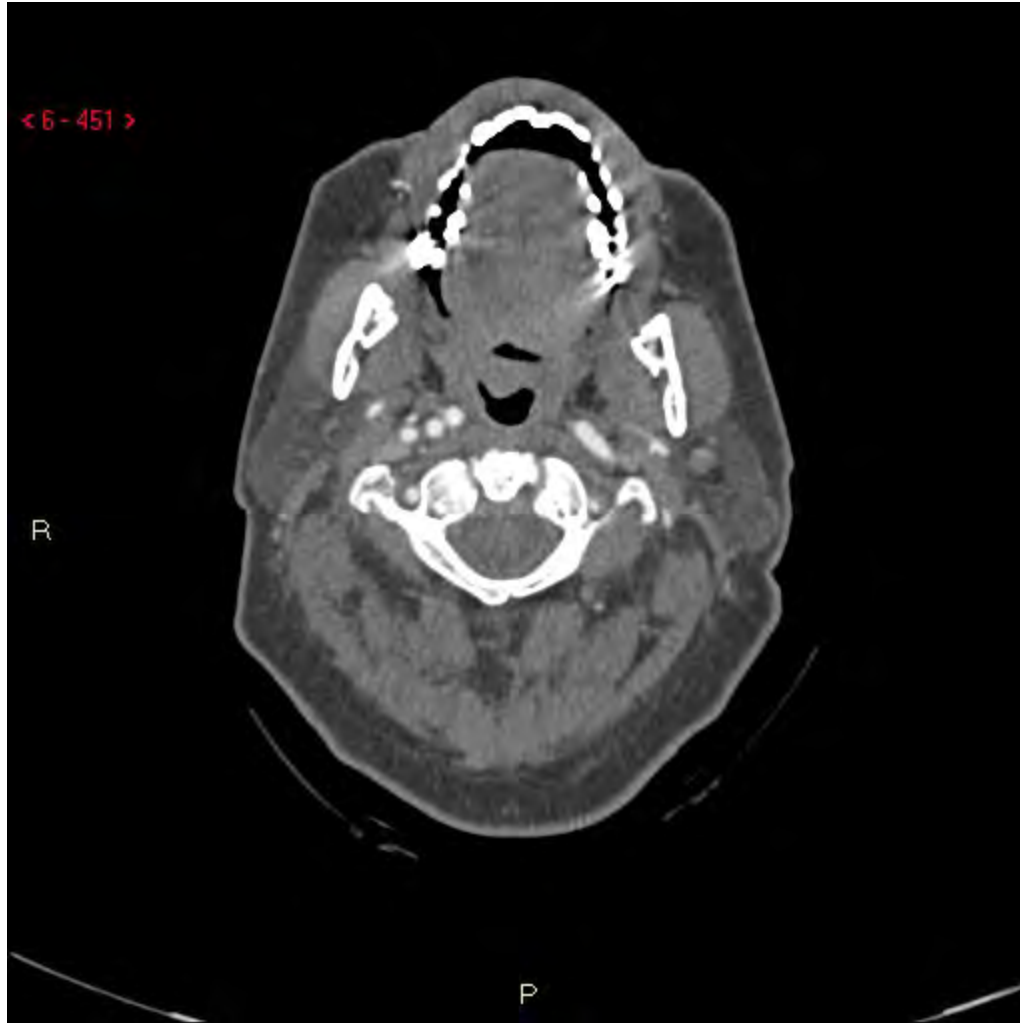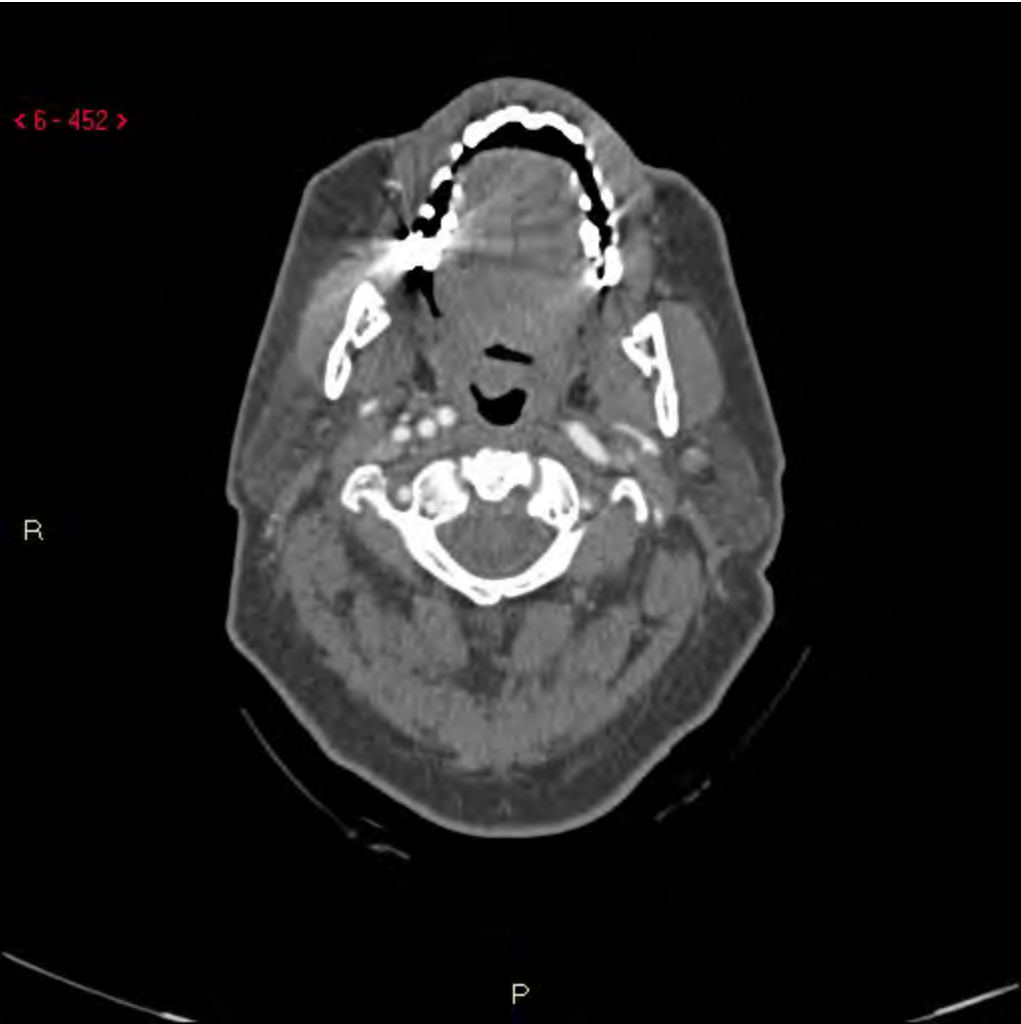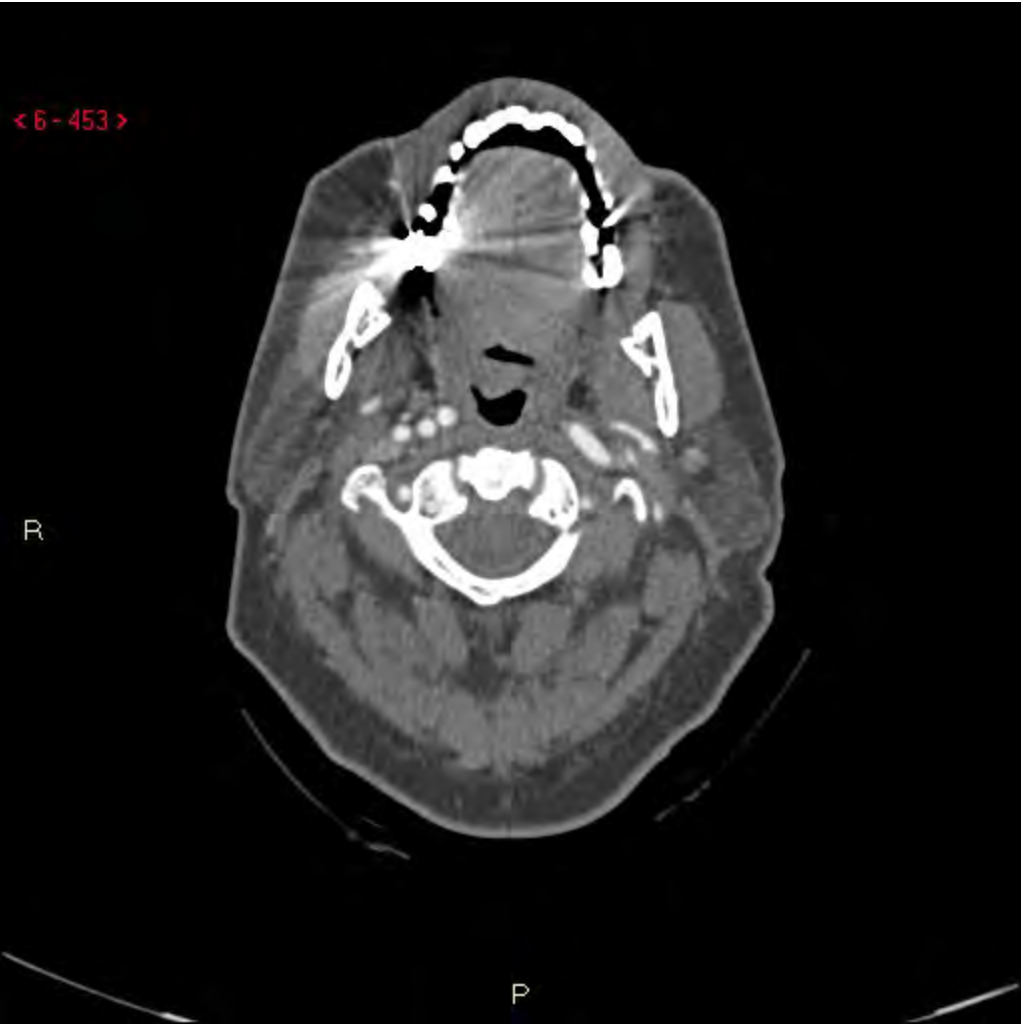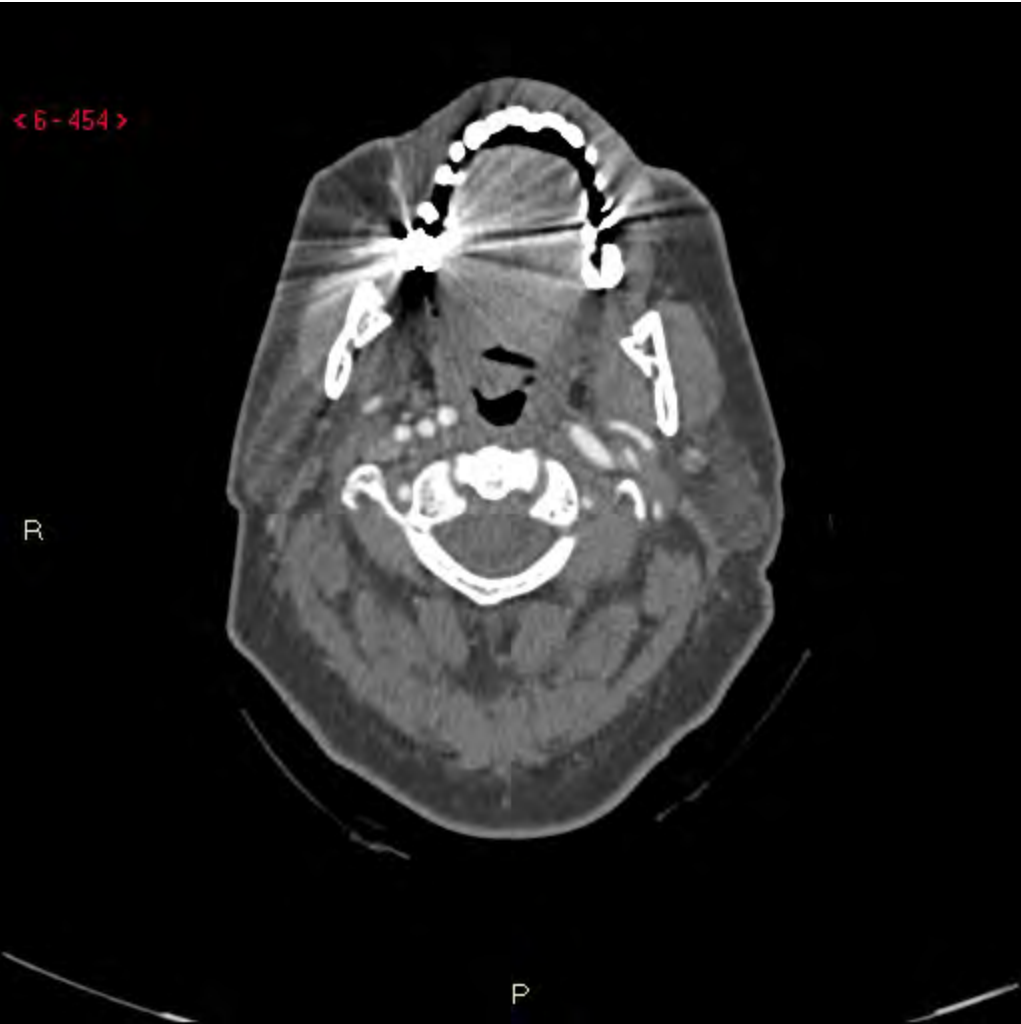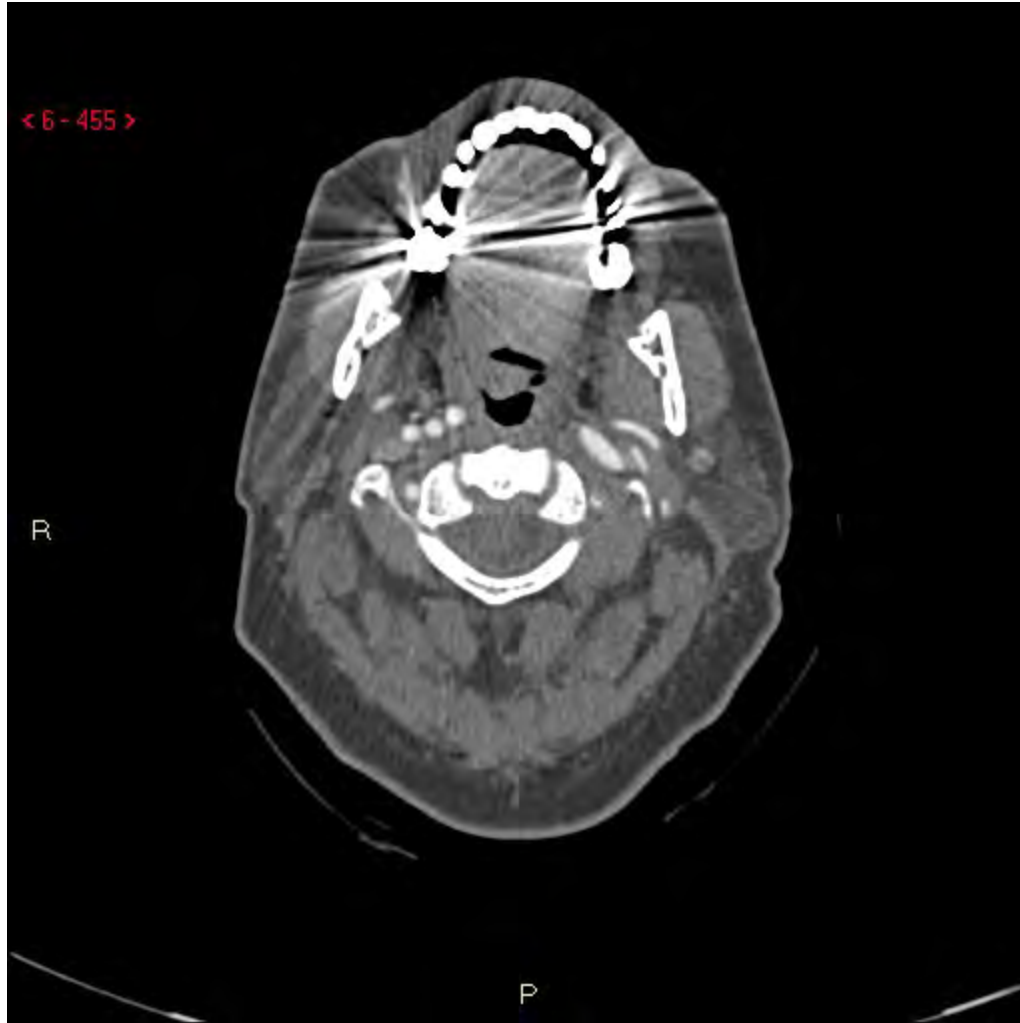










































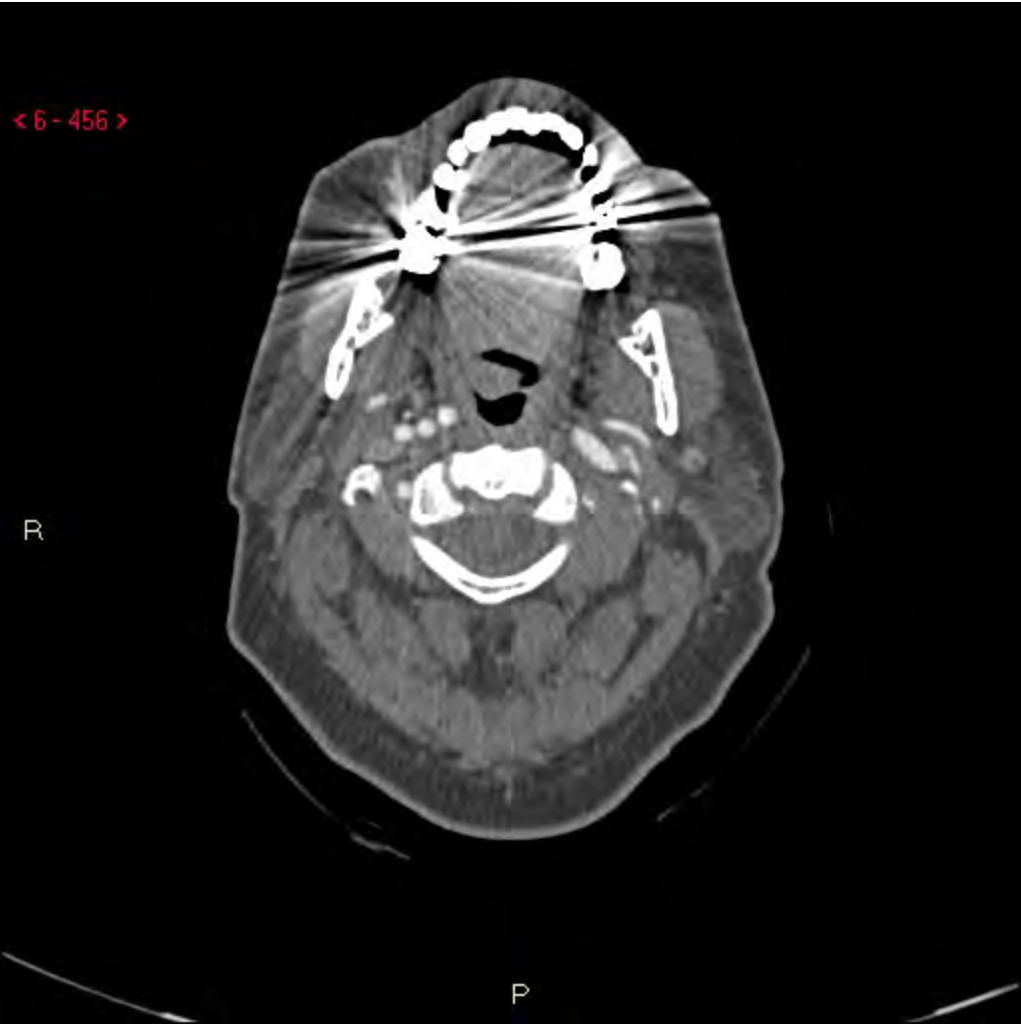


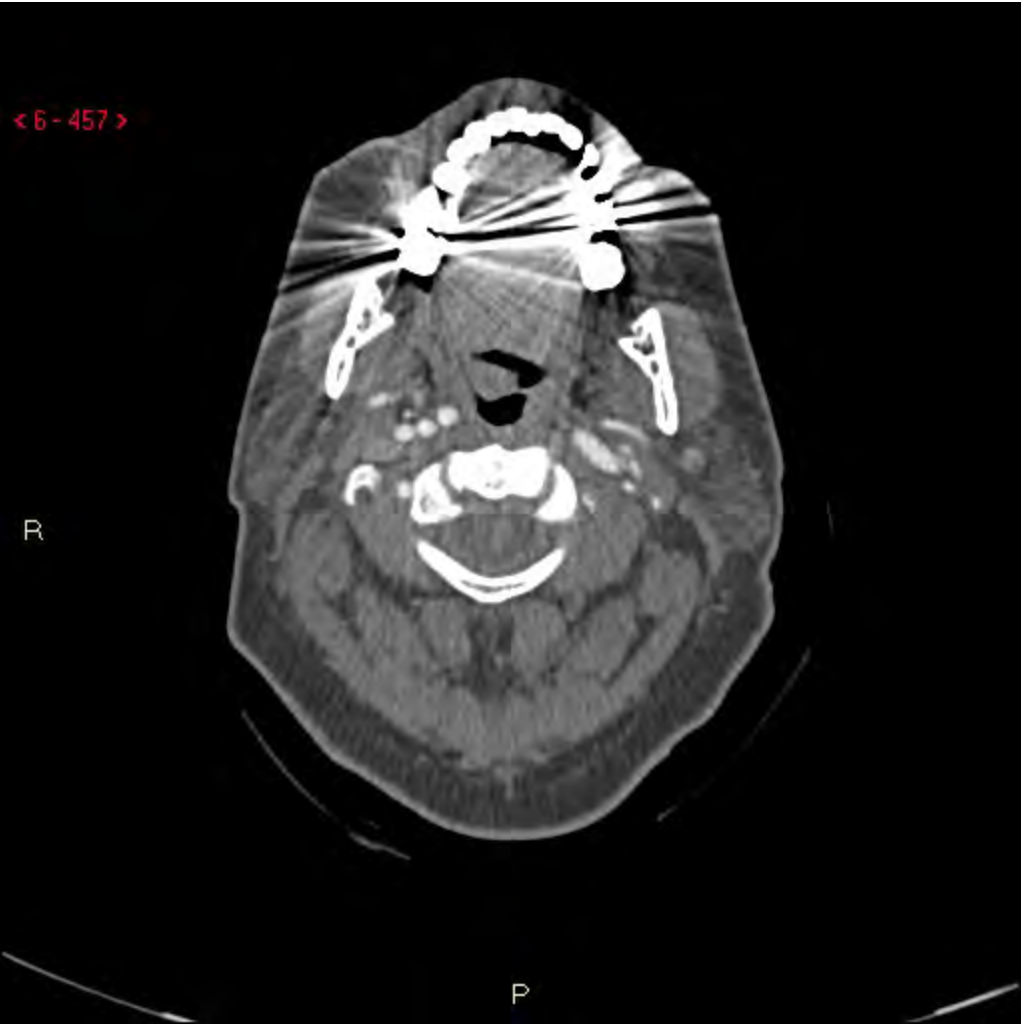


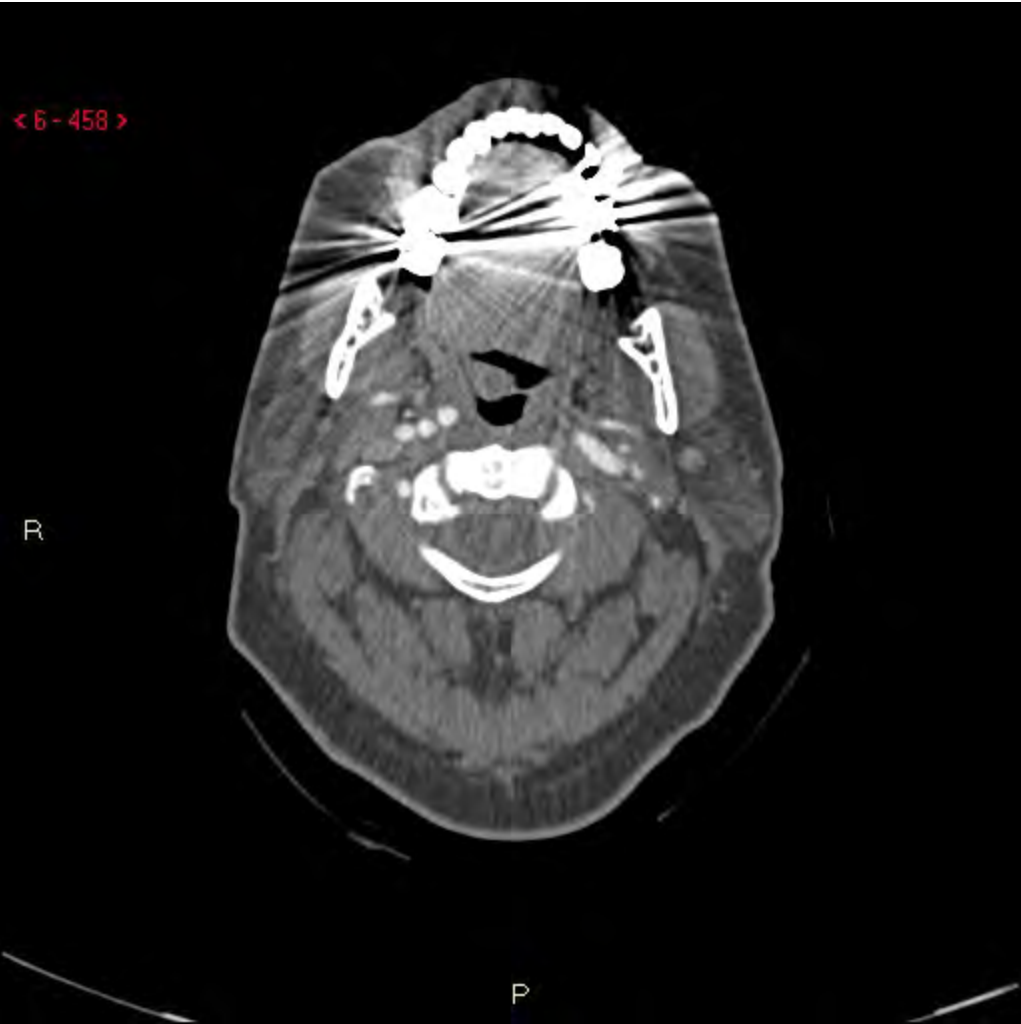


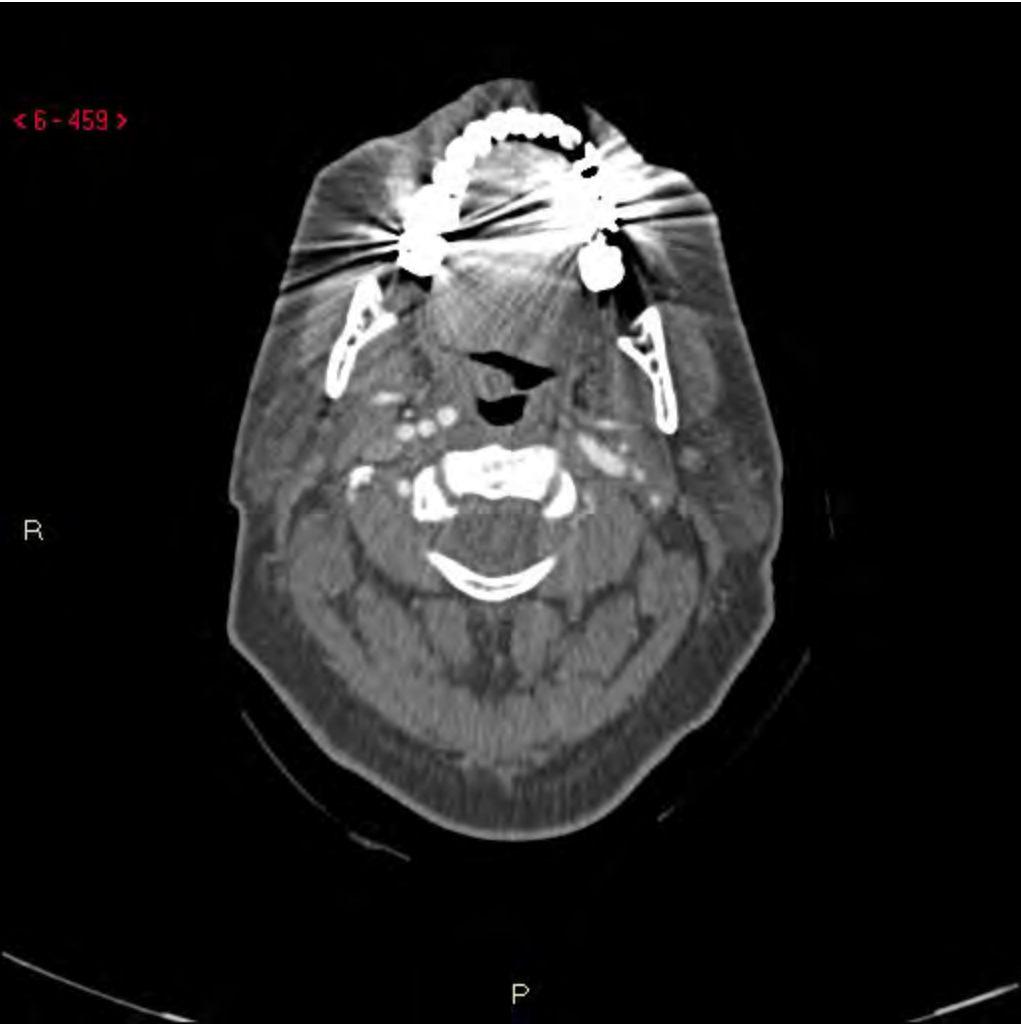


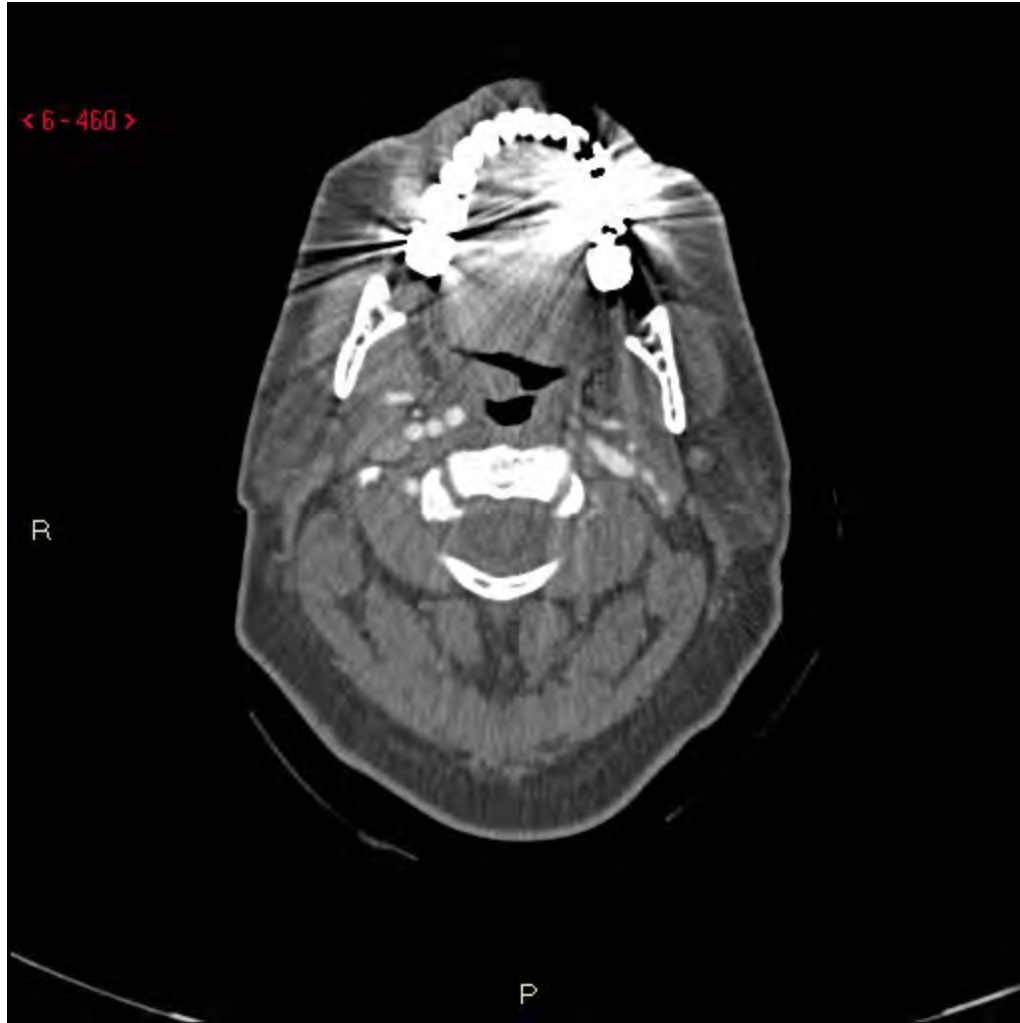


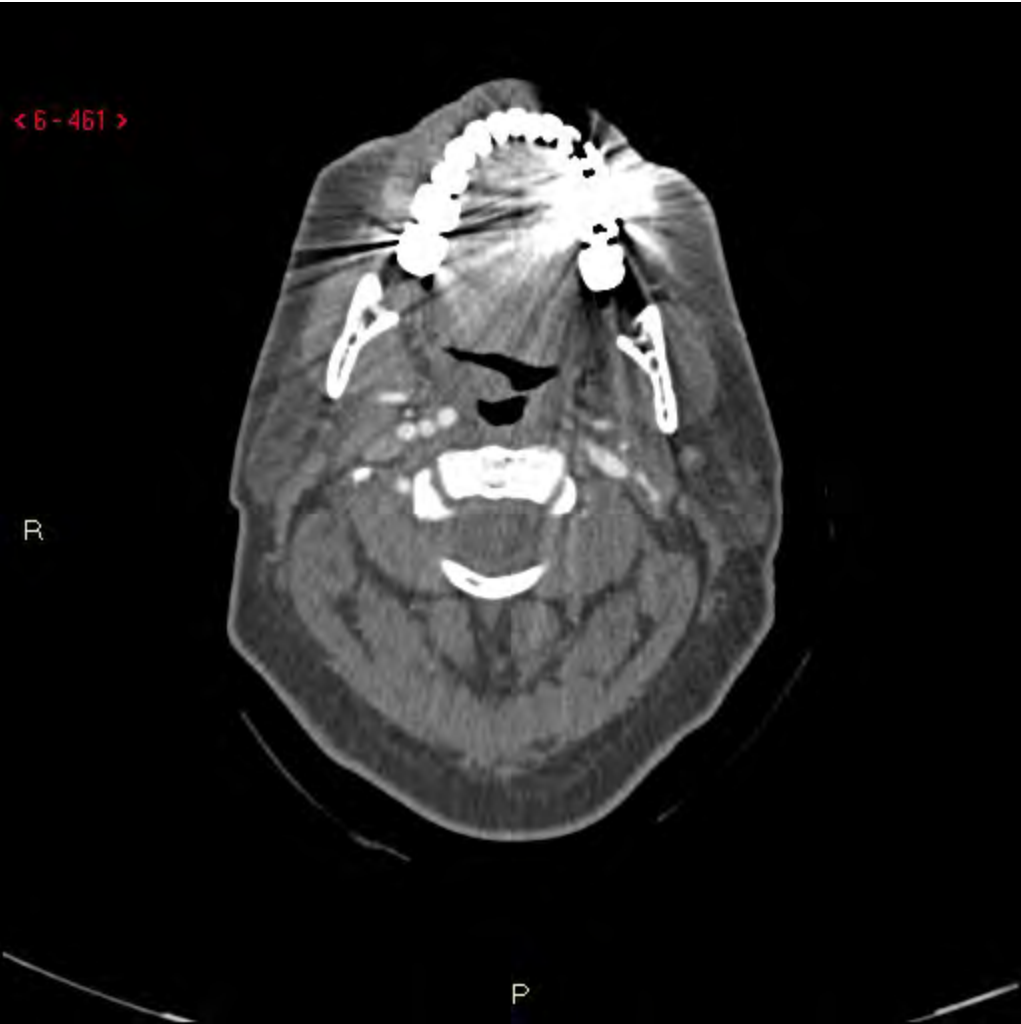


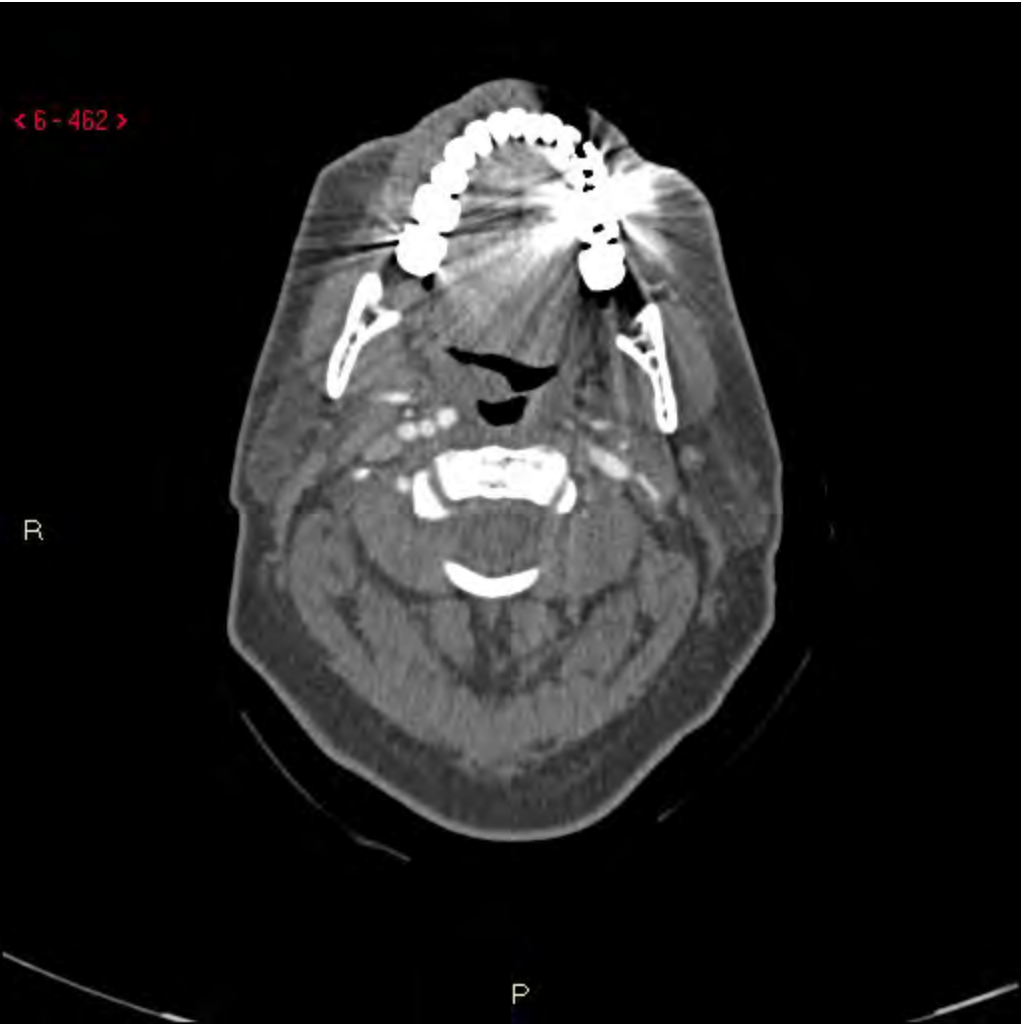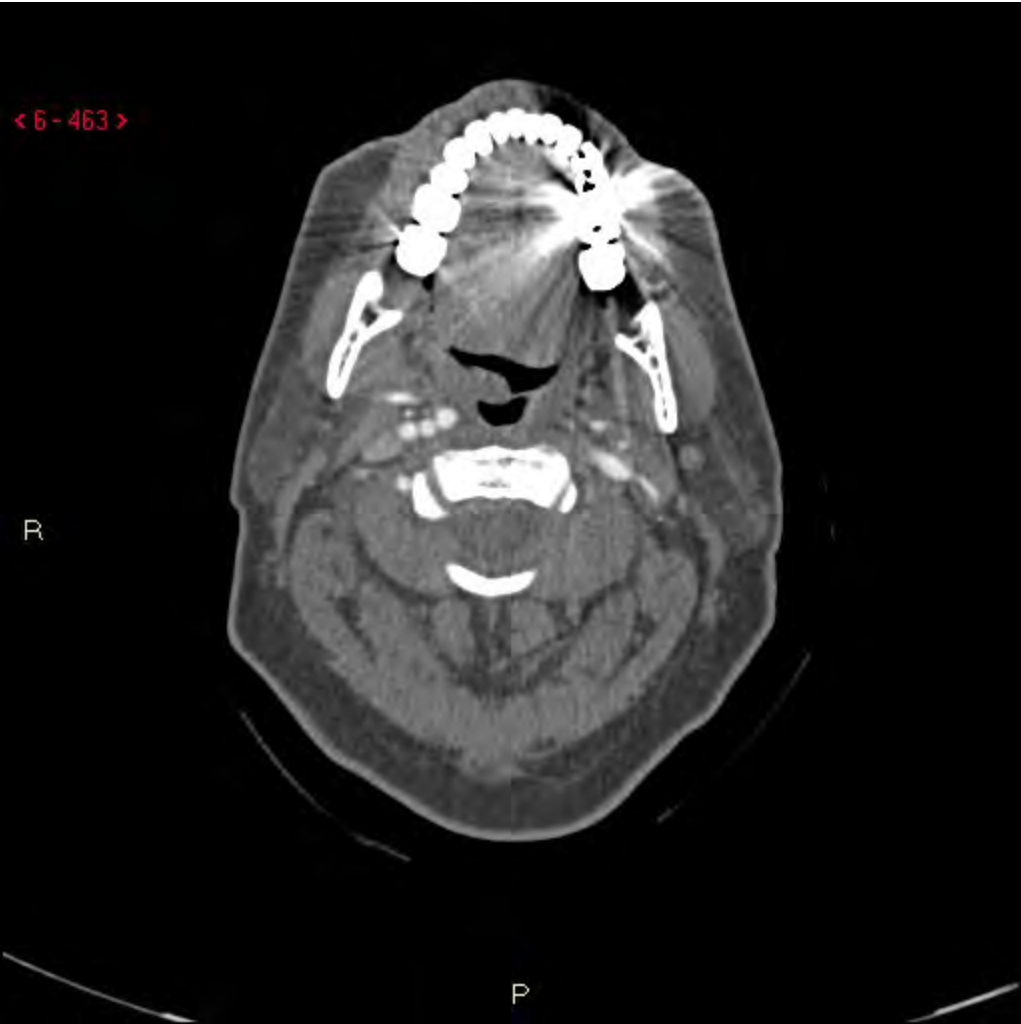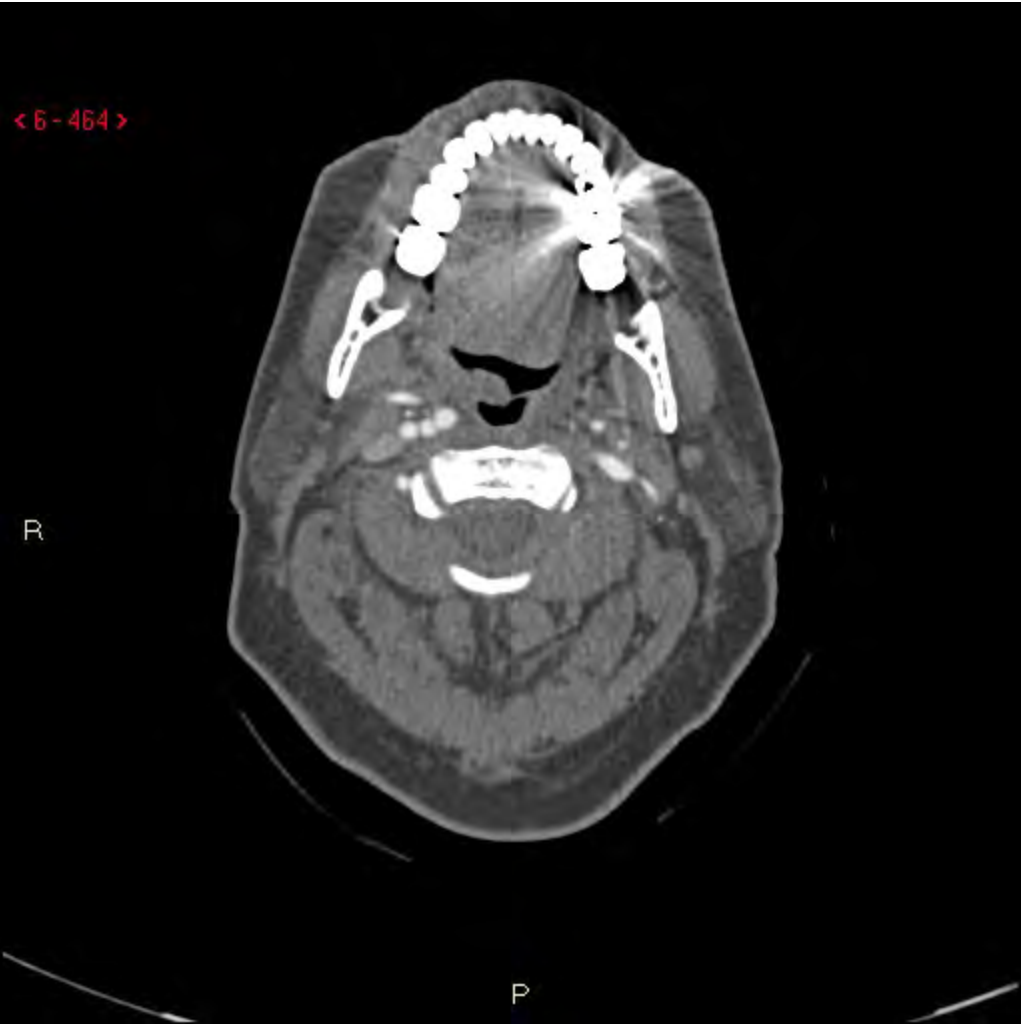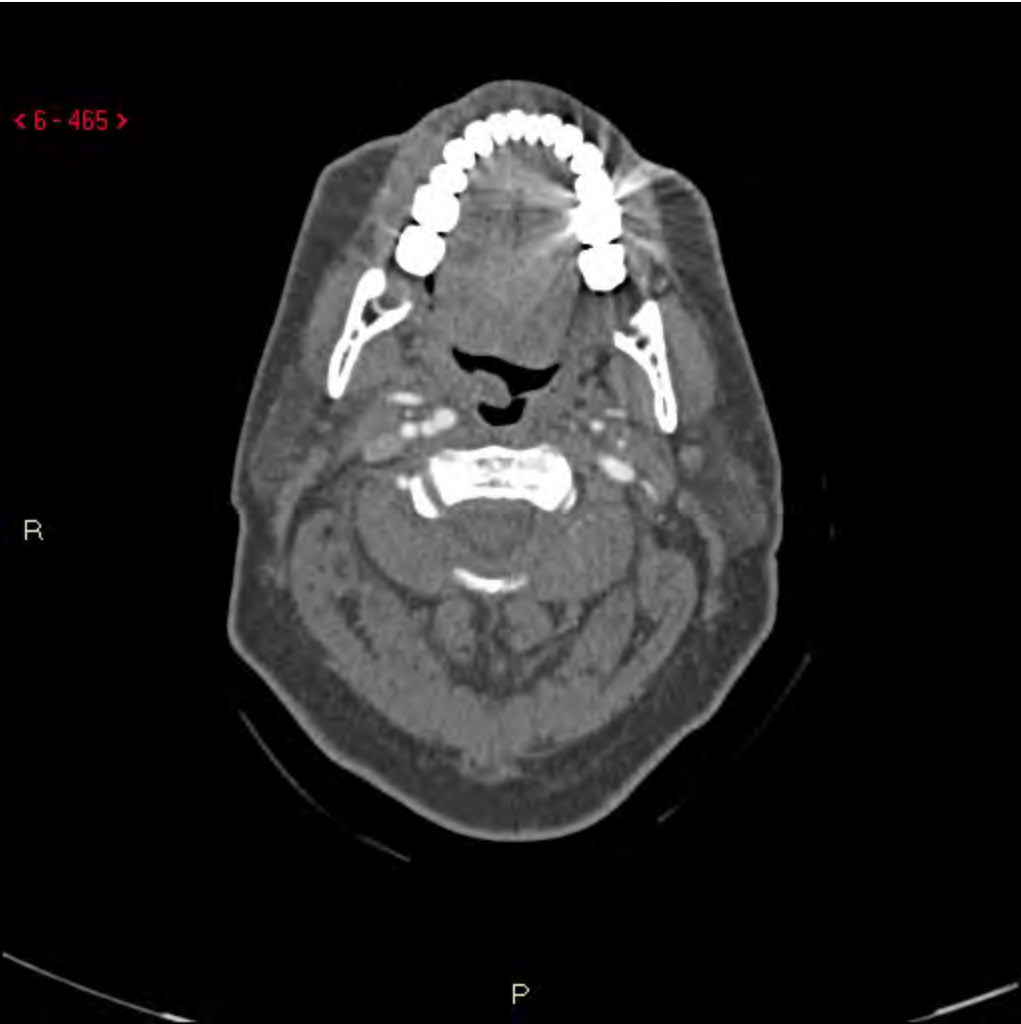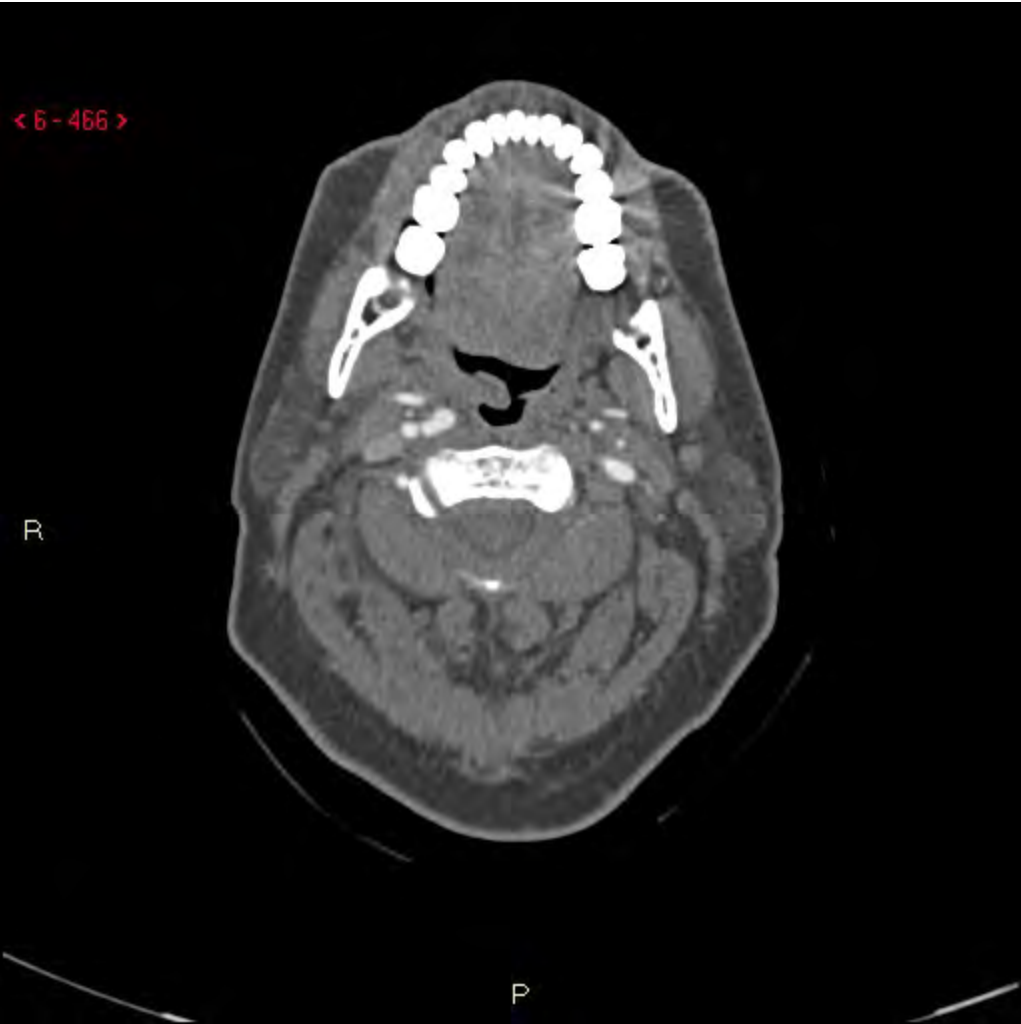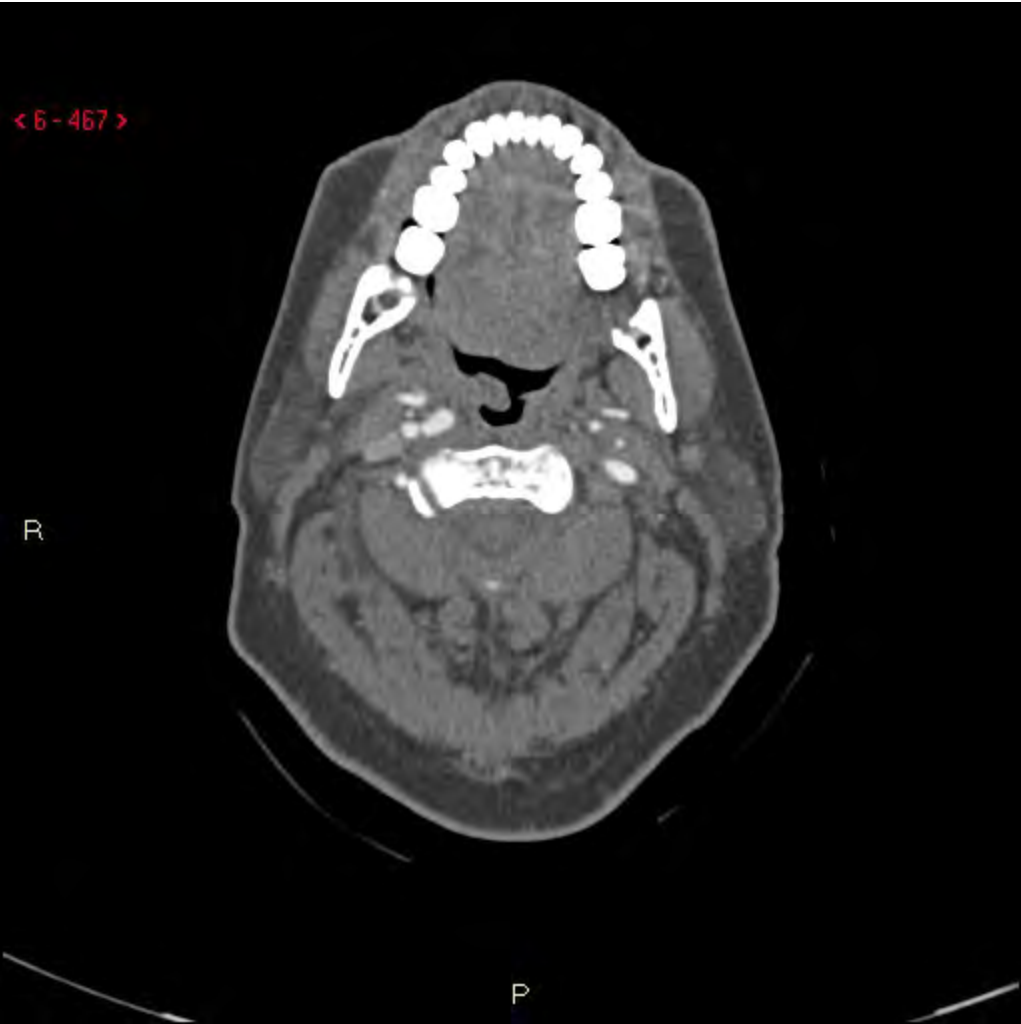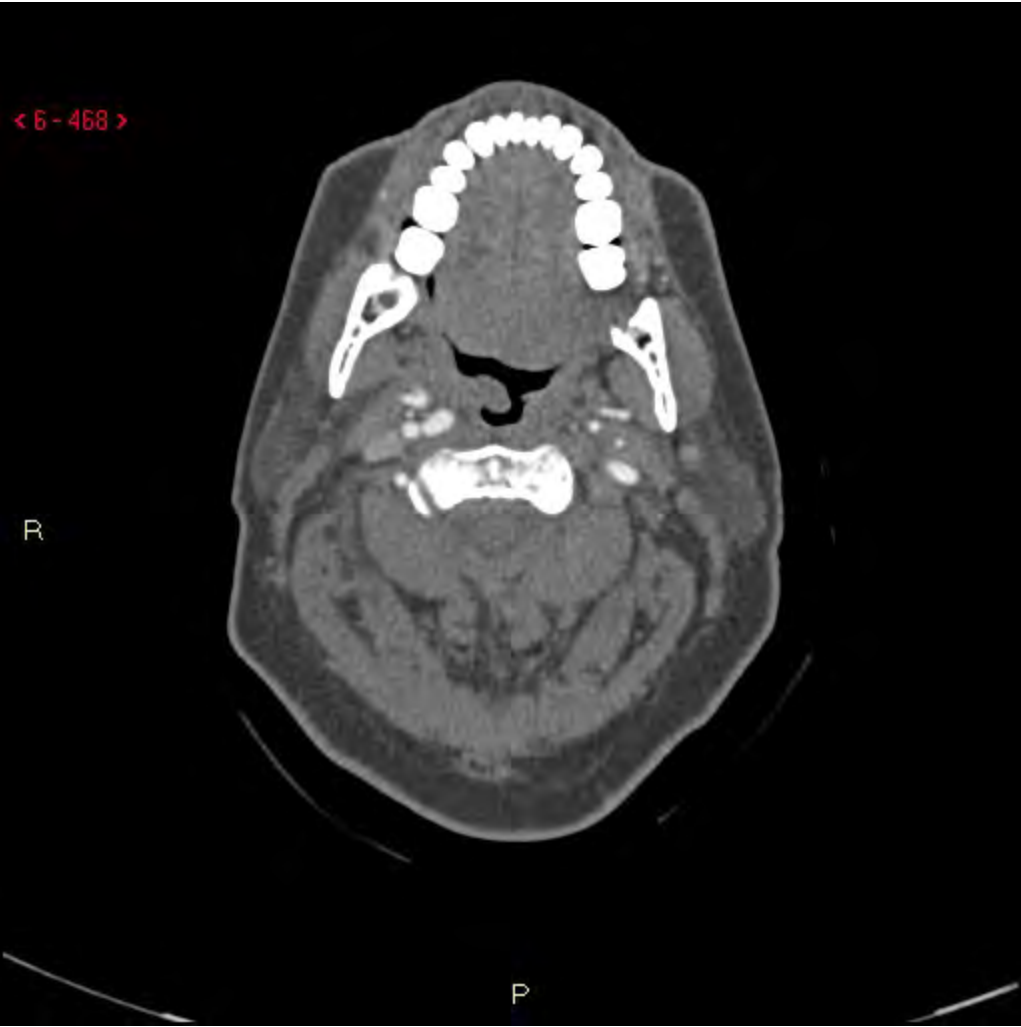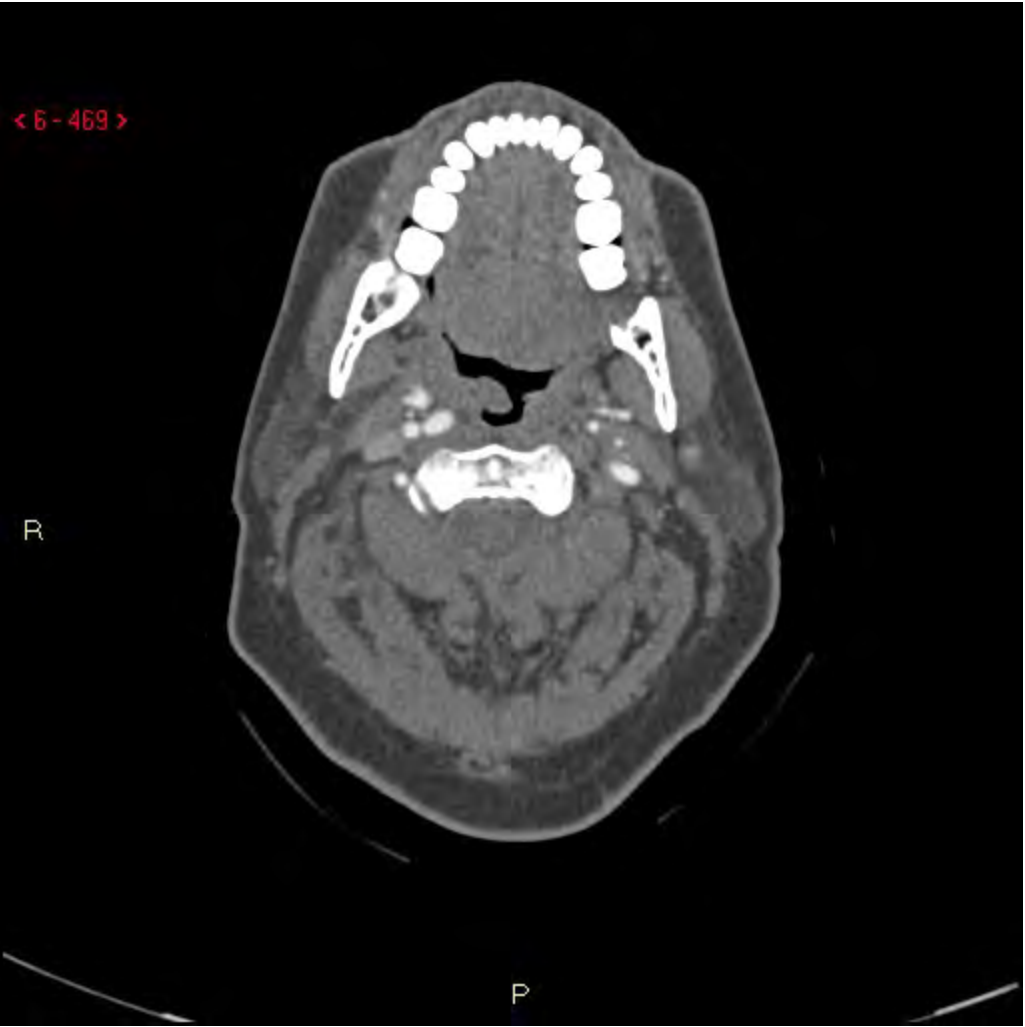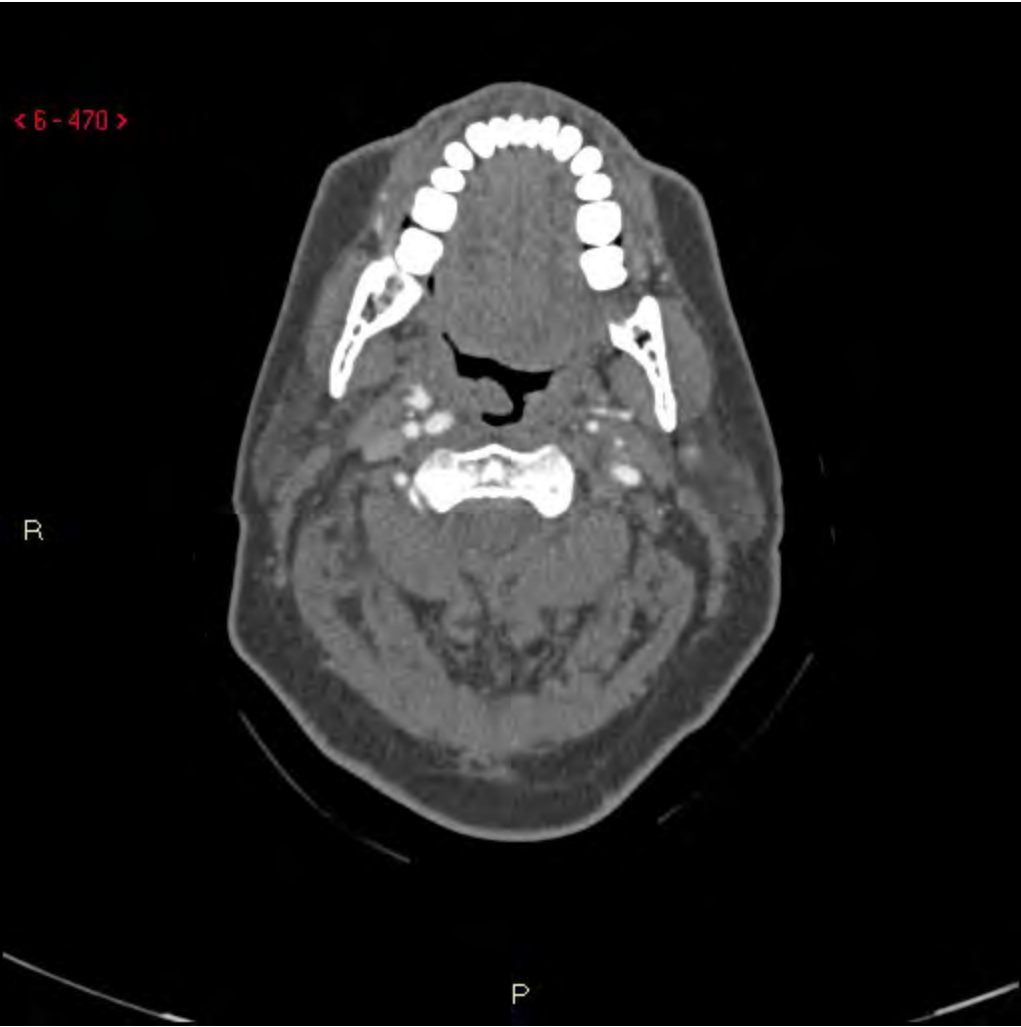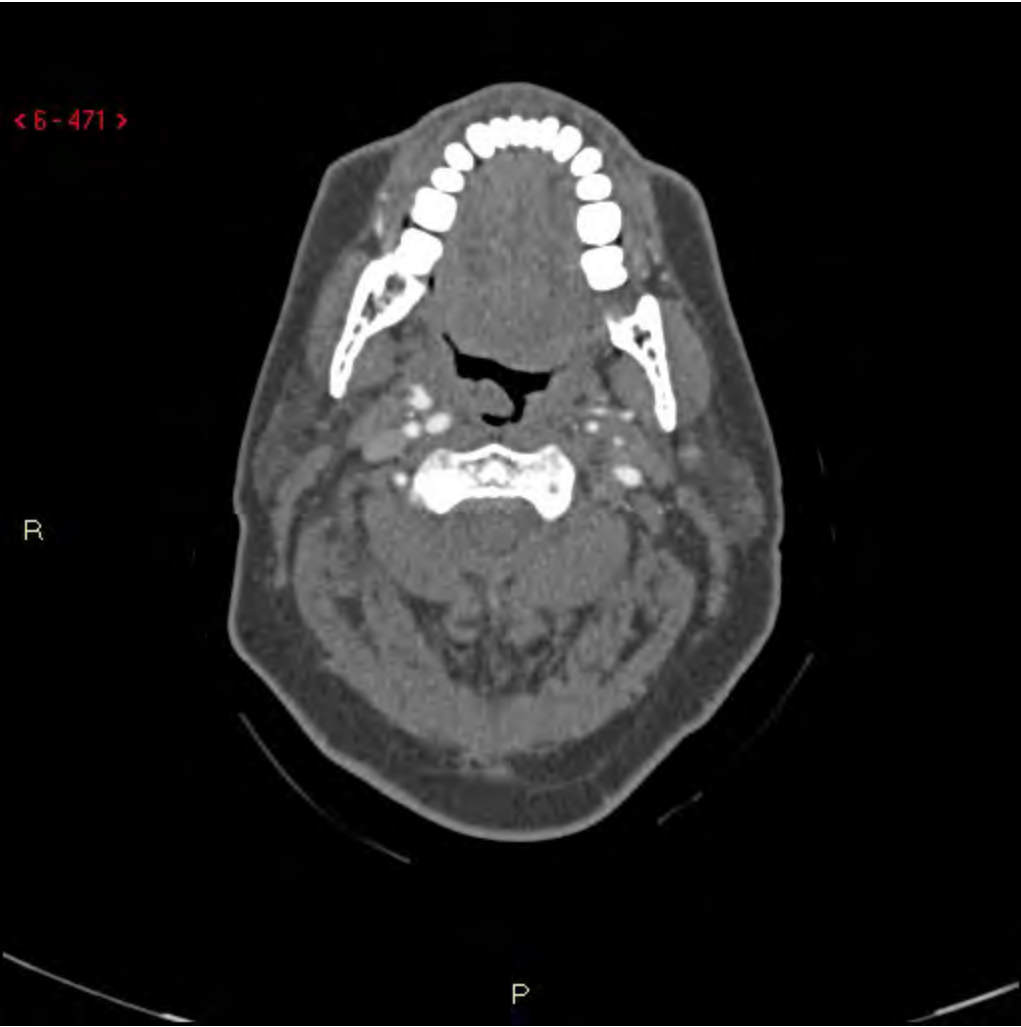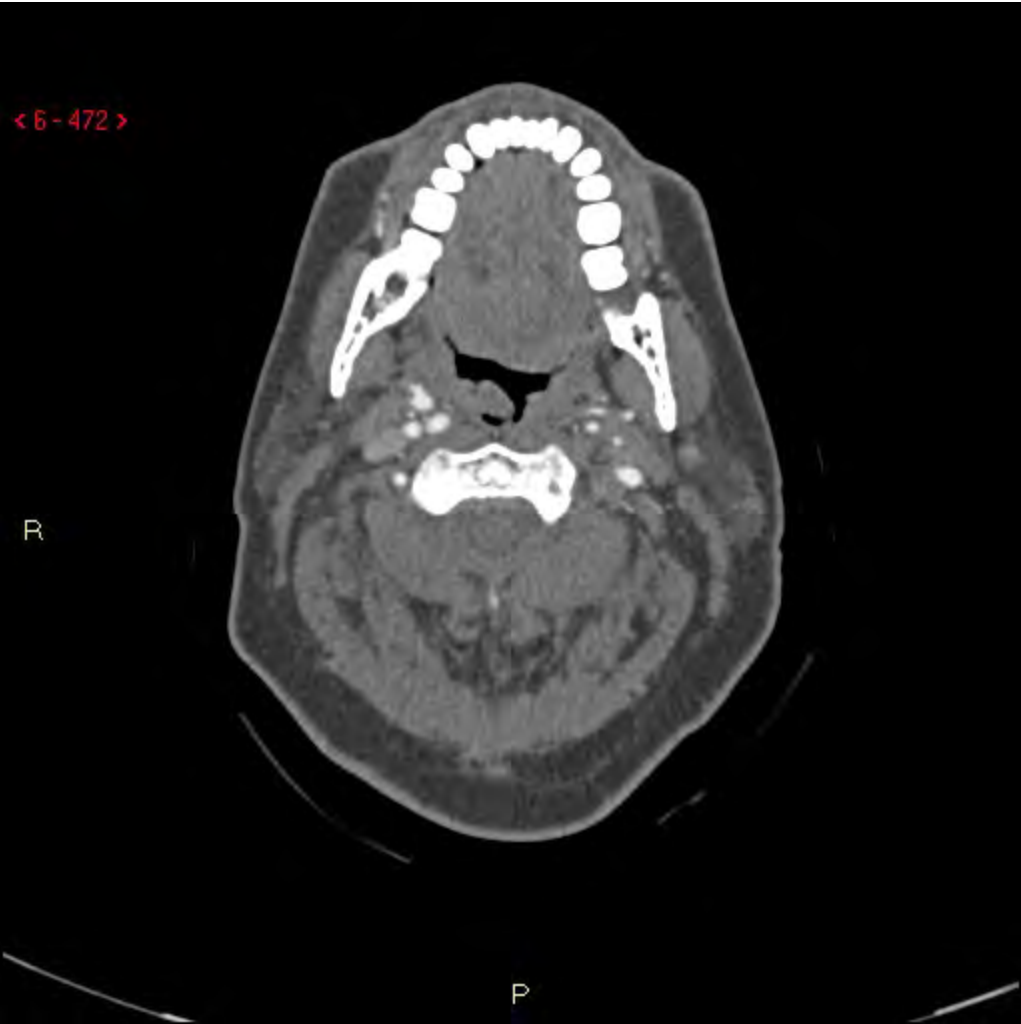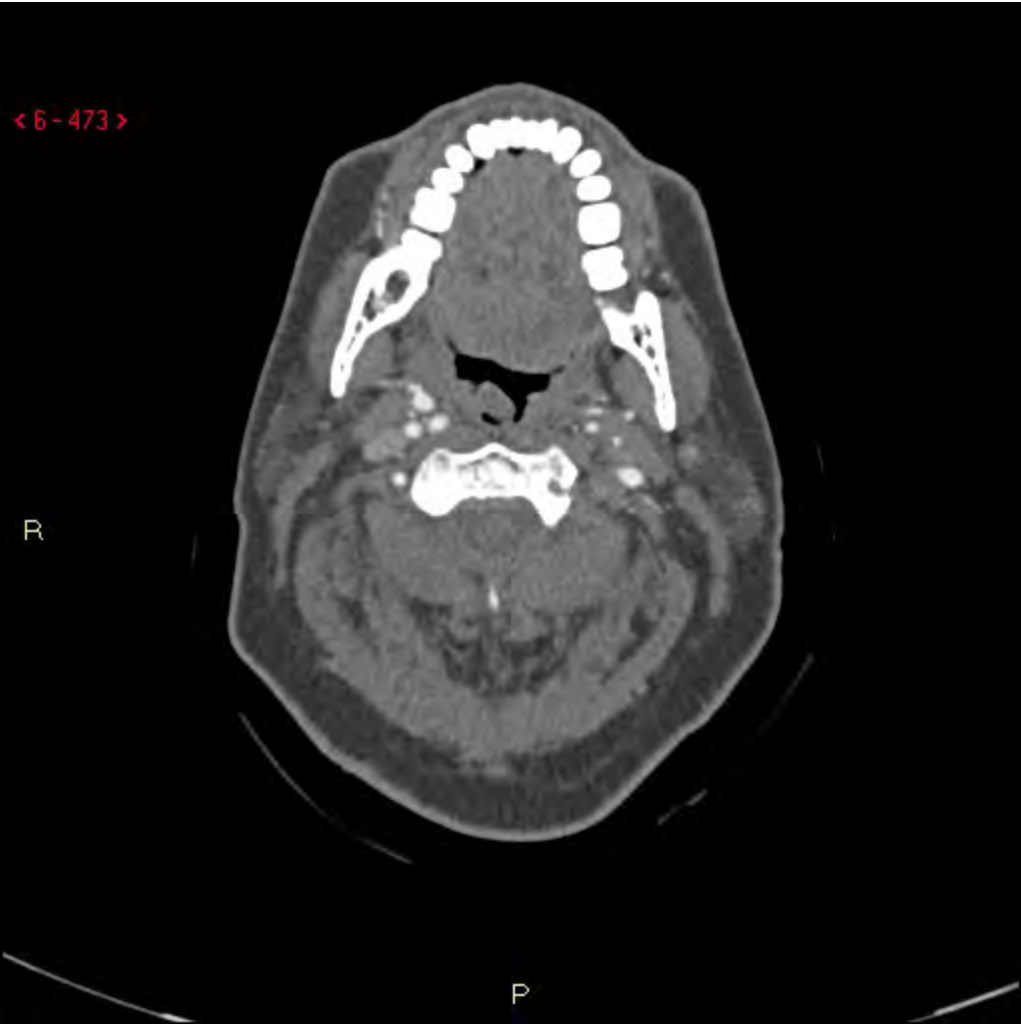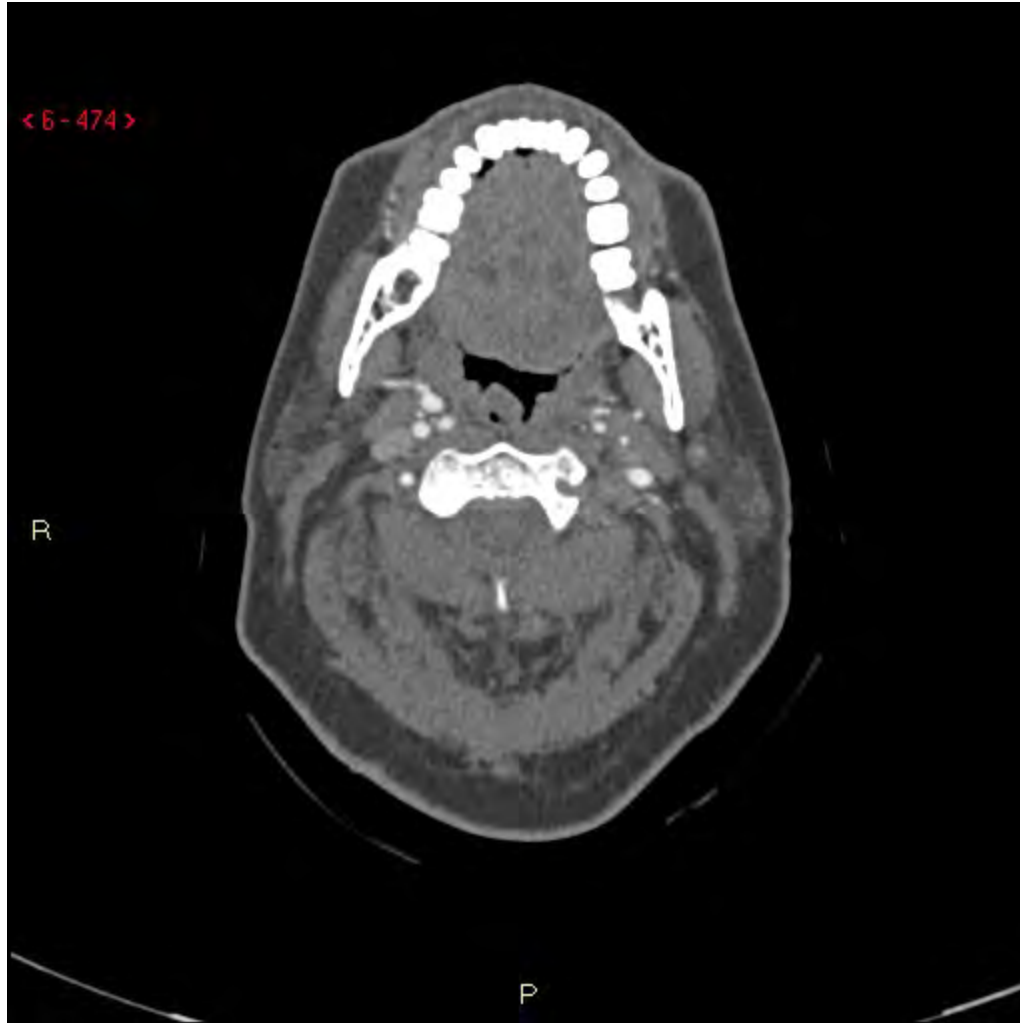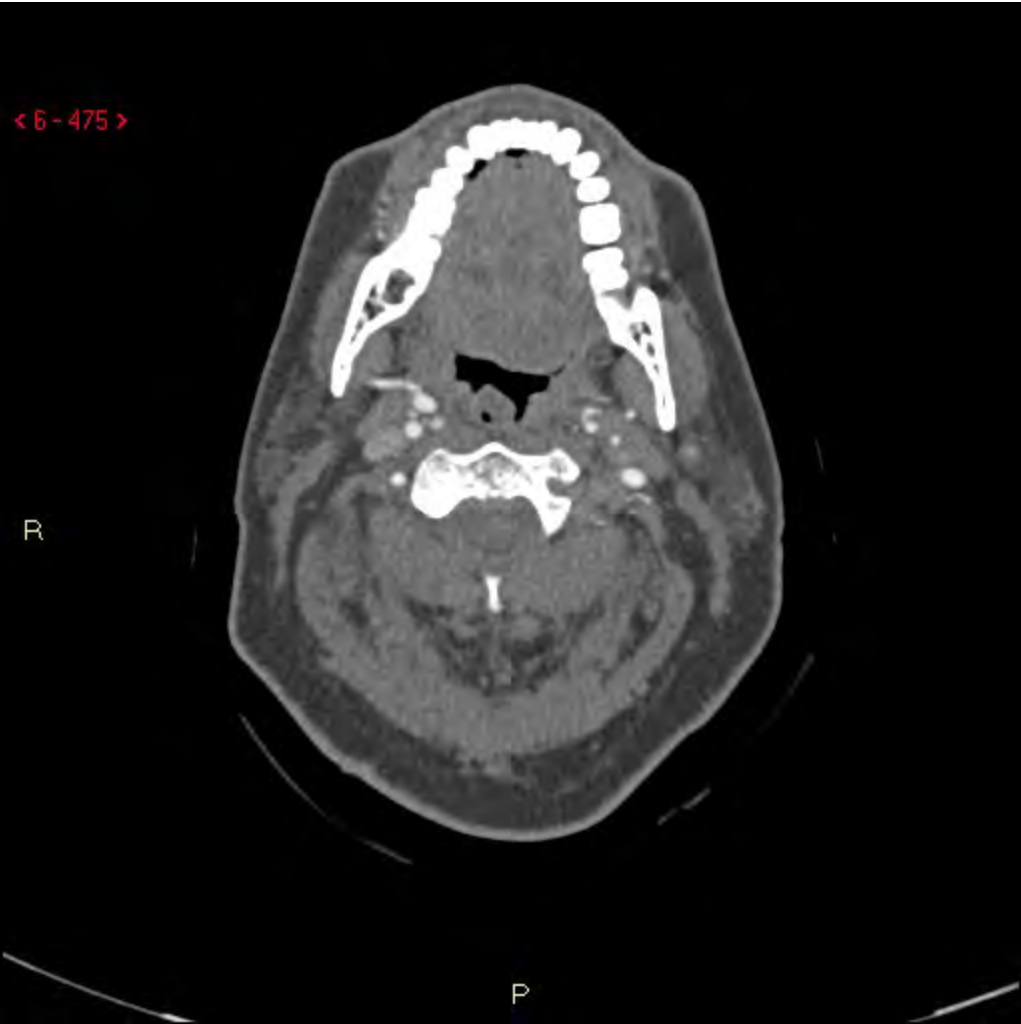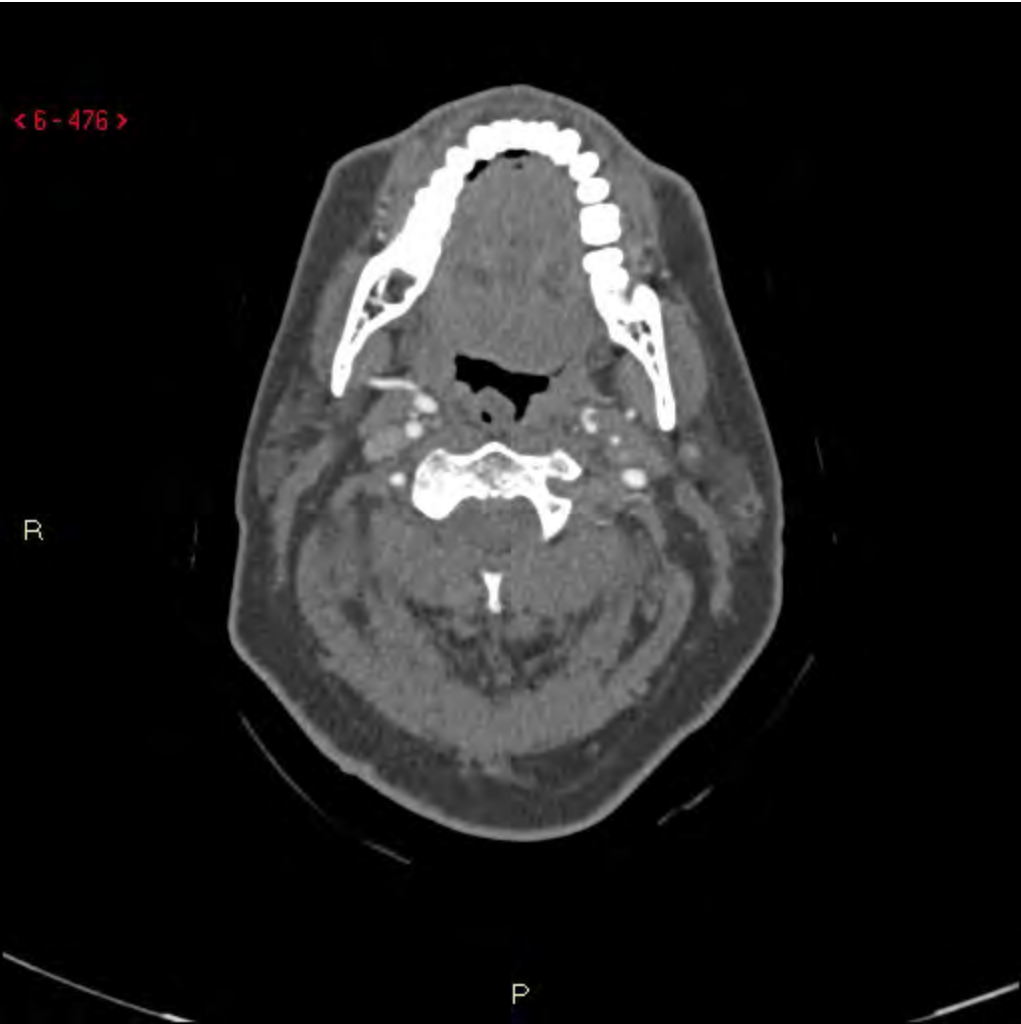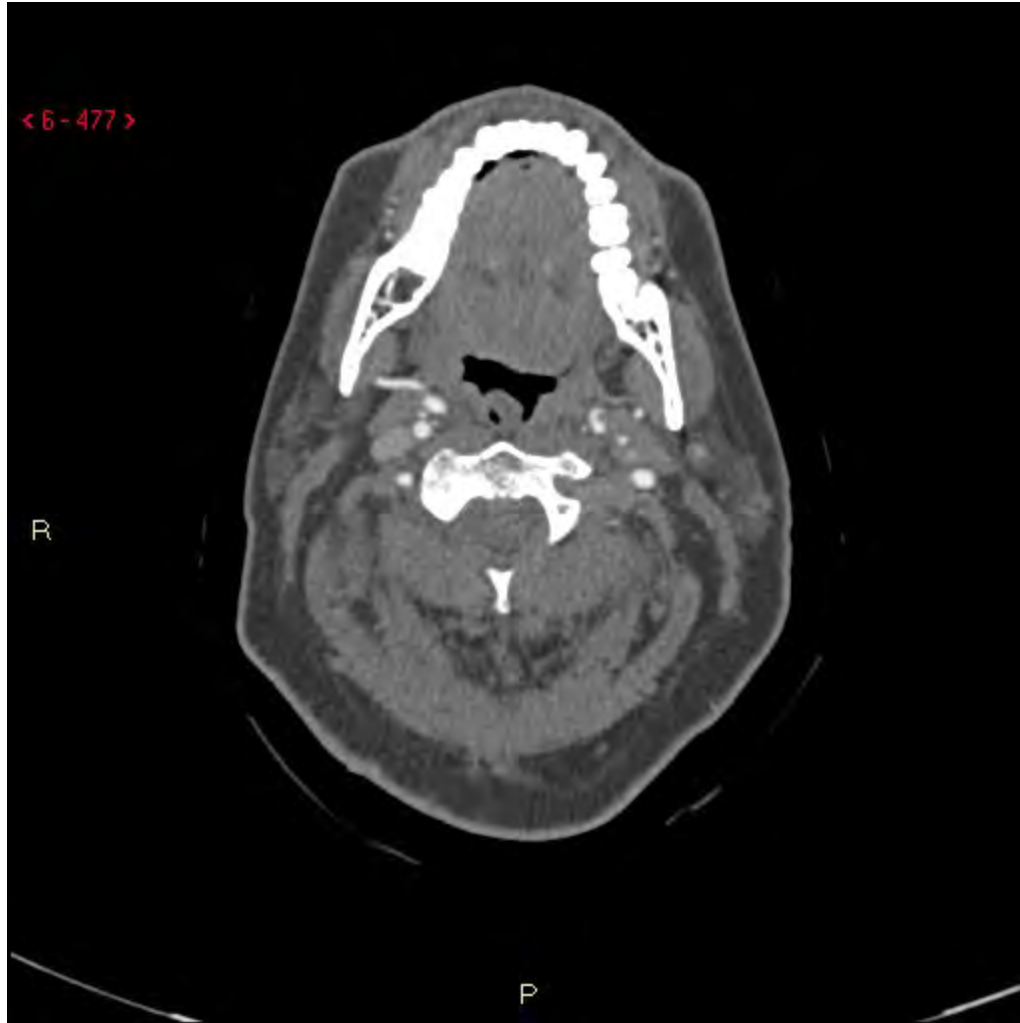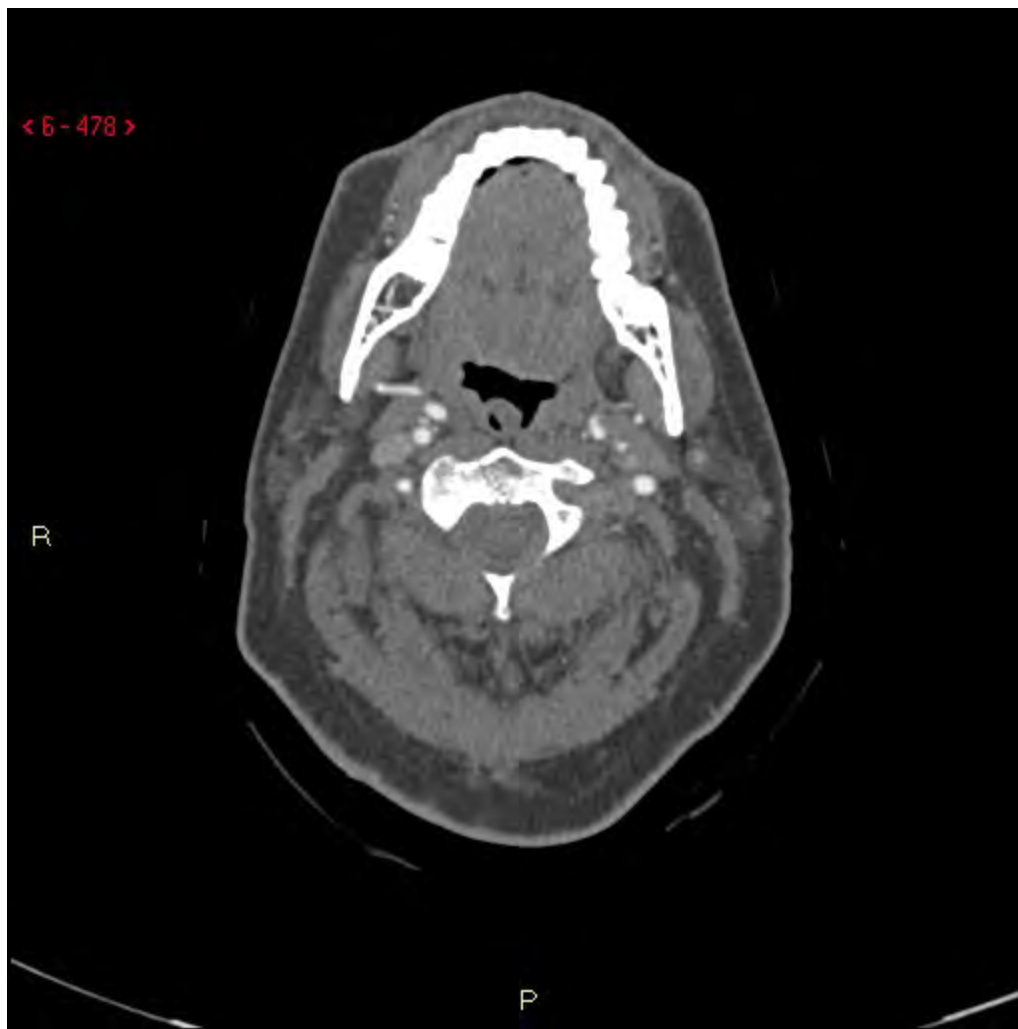< 6 - 478 >

R

P

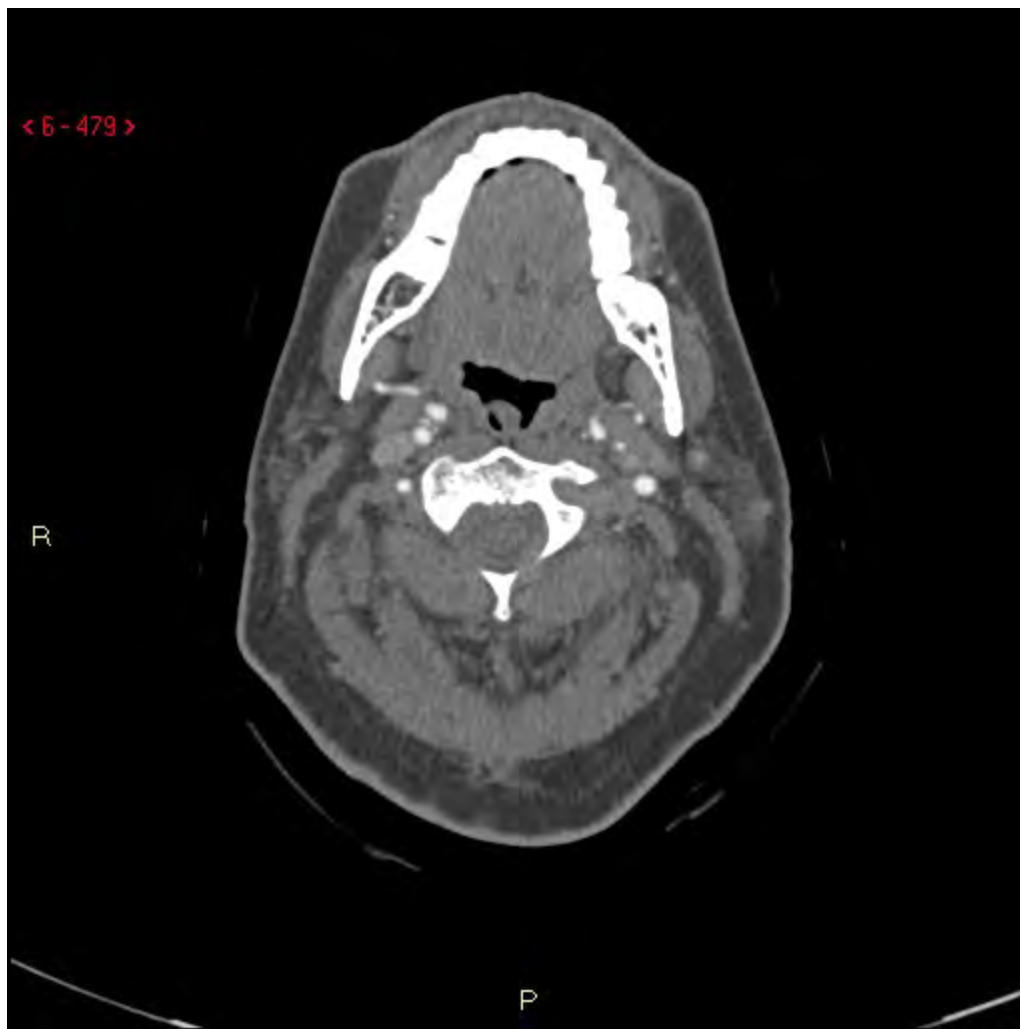


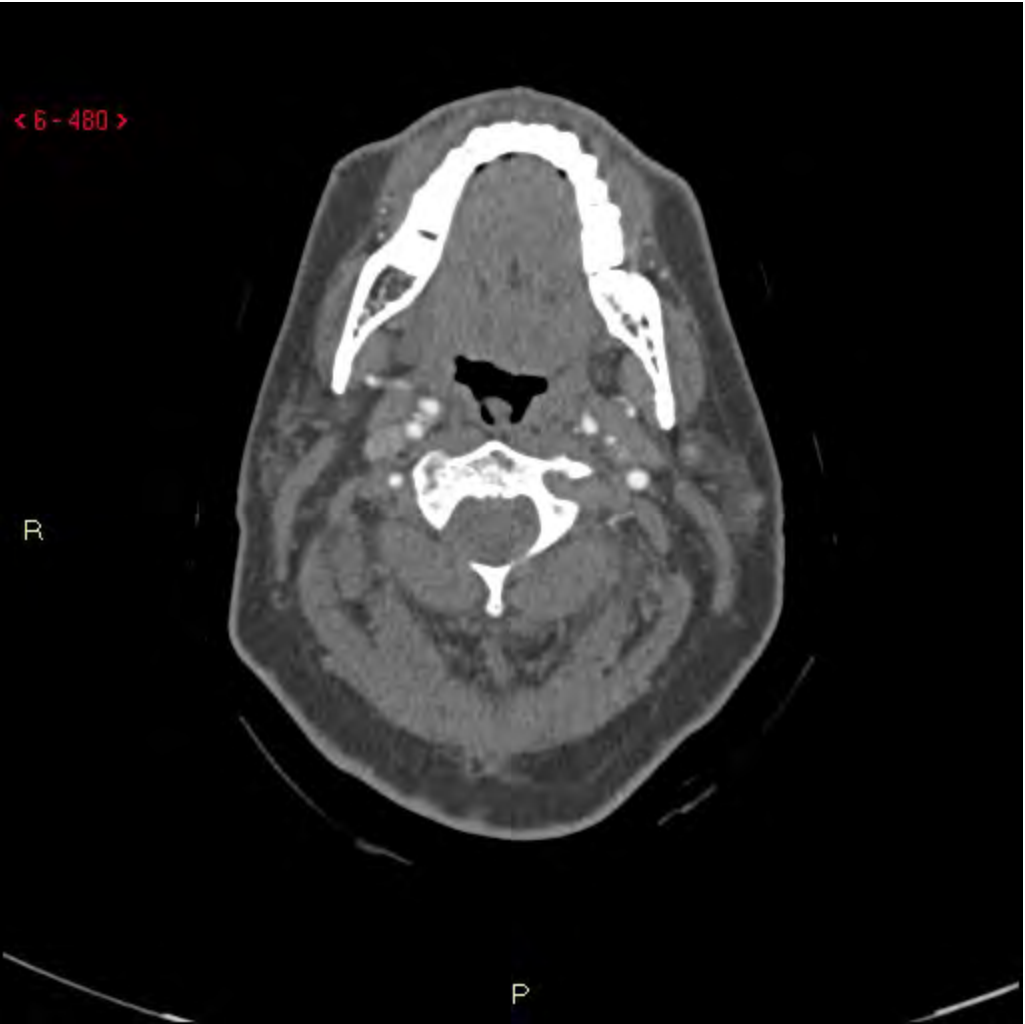
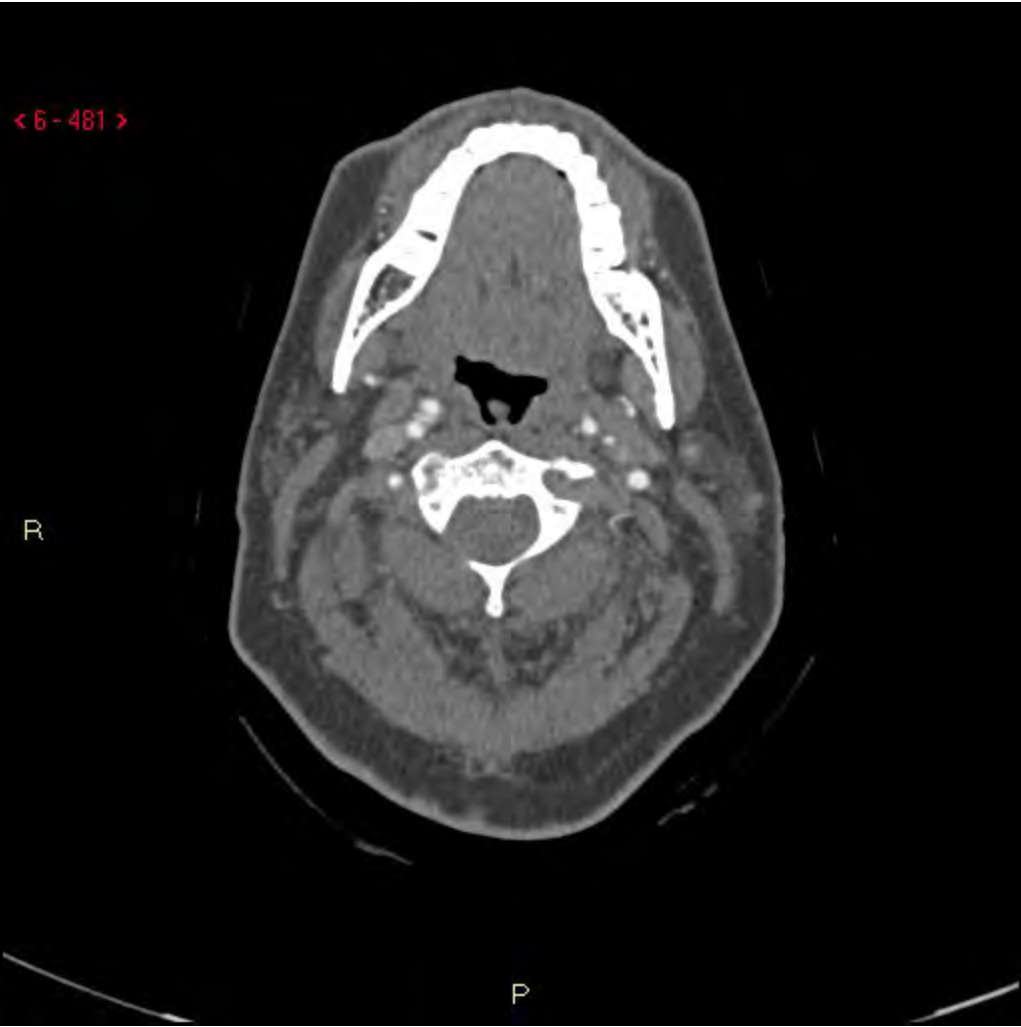
< 6 - 479 >

R

P



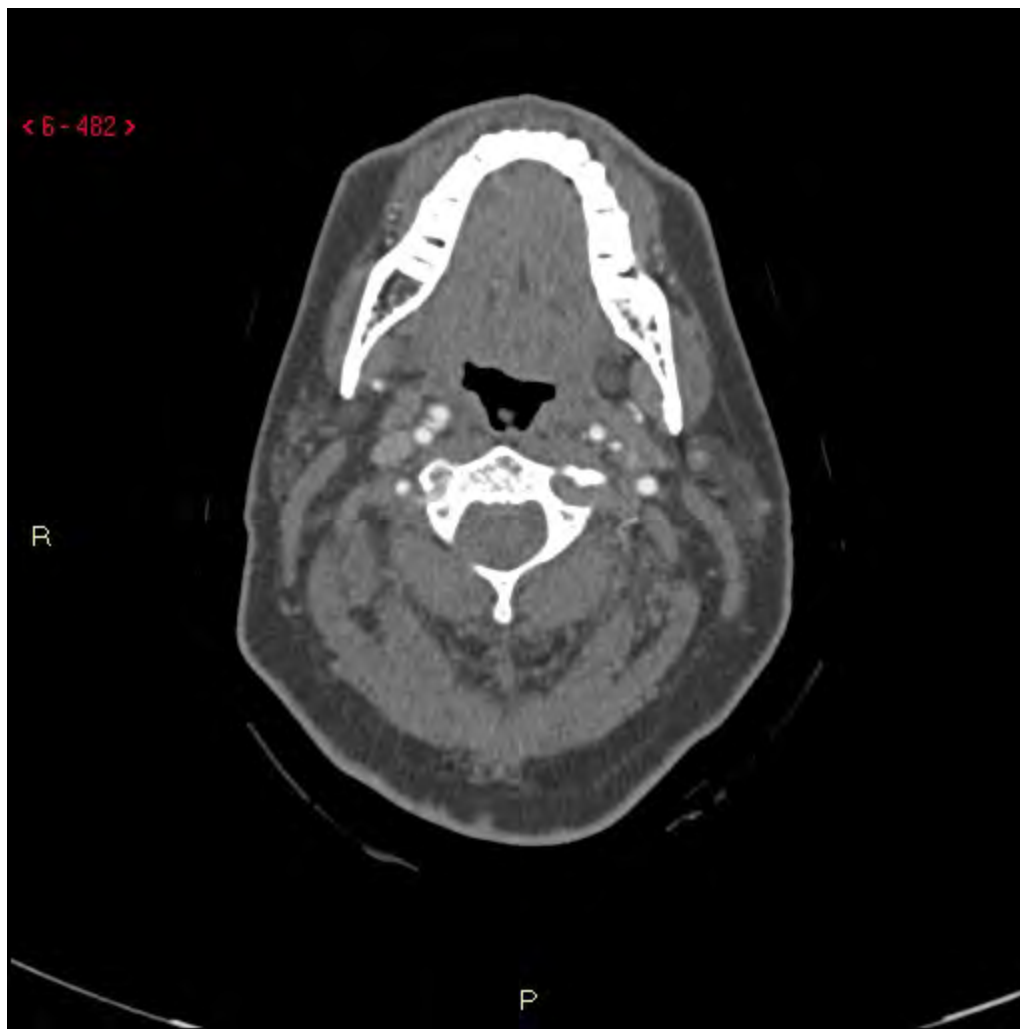



< 6 - 482 >

R

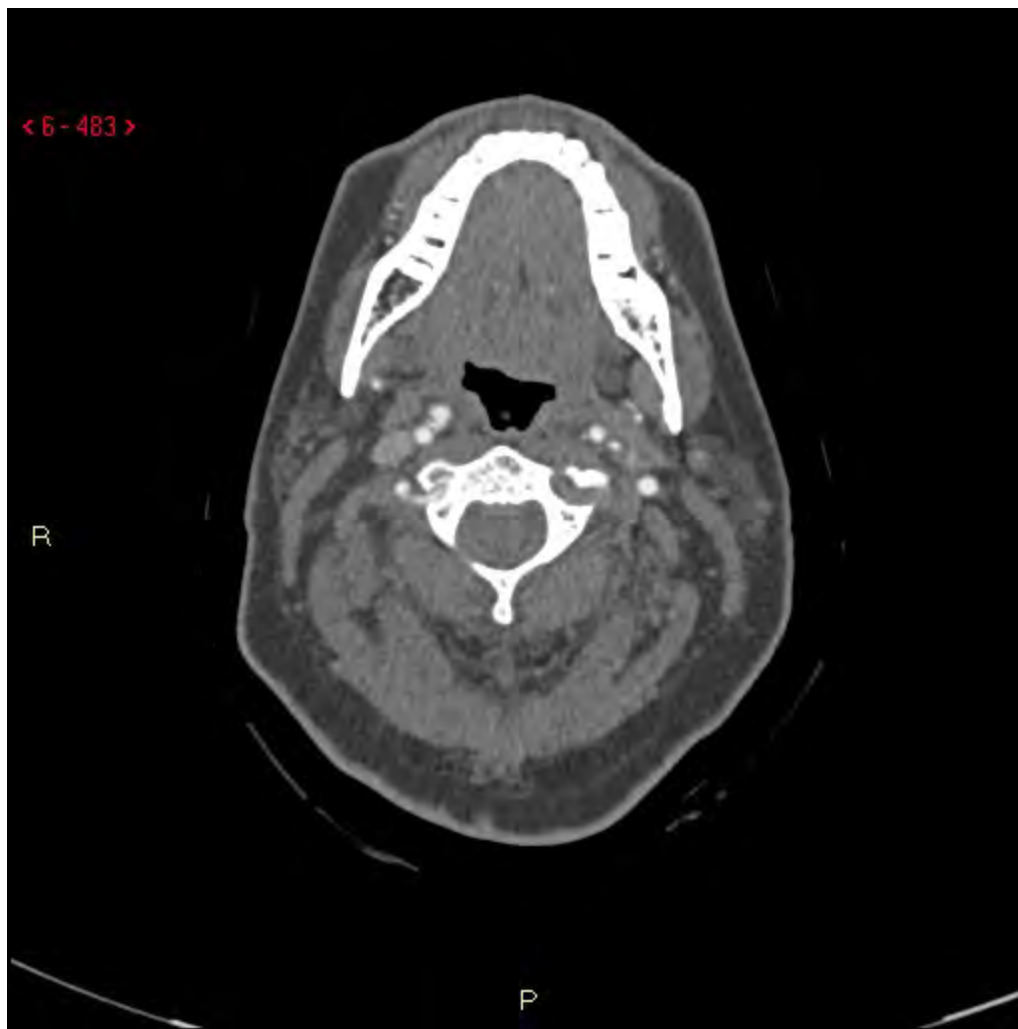P



< 6 - 483 >

R

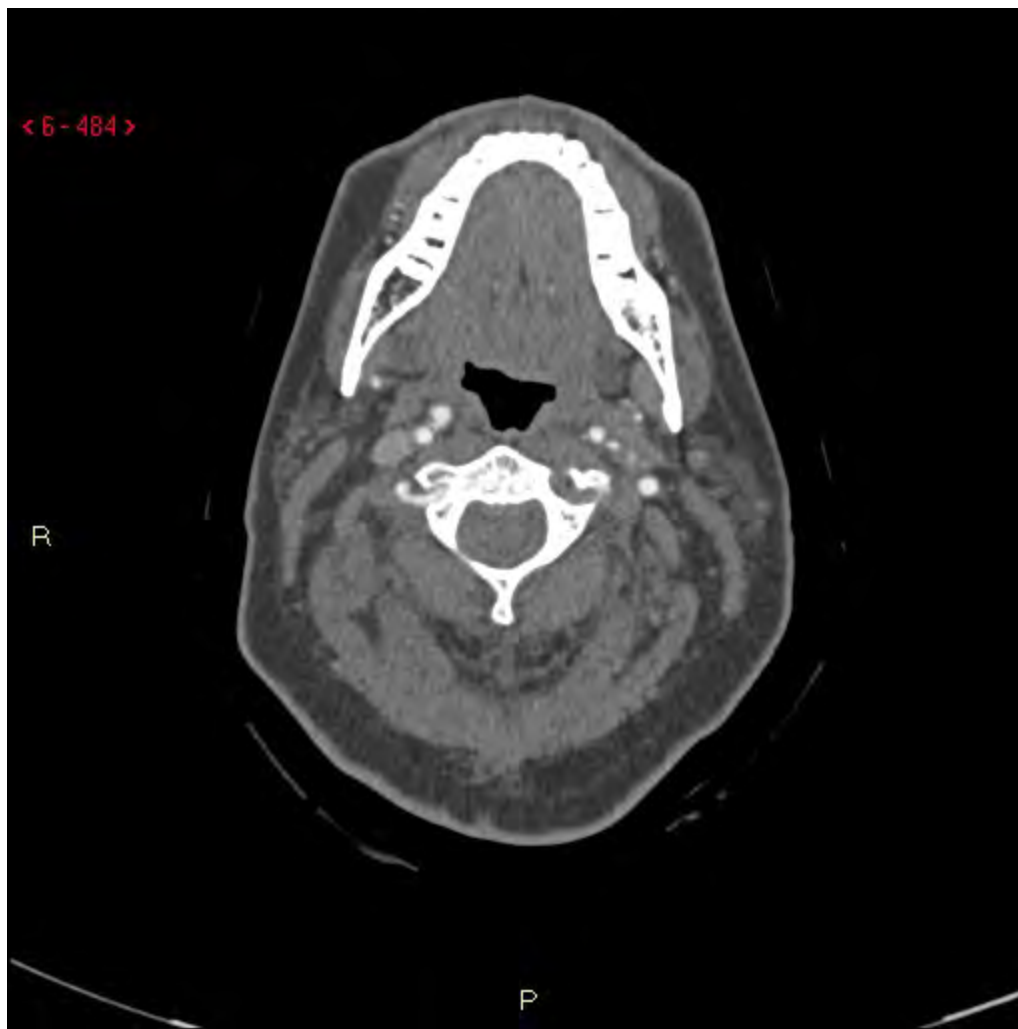P



< 6 - 484 >

R

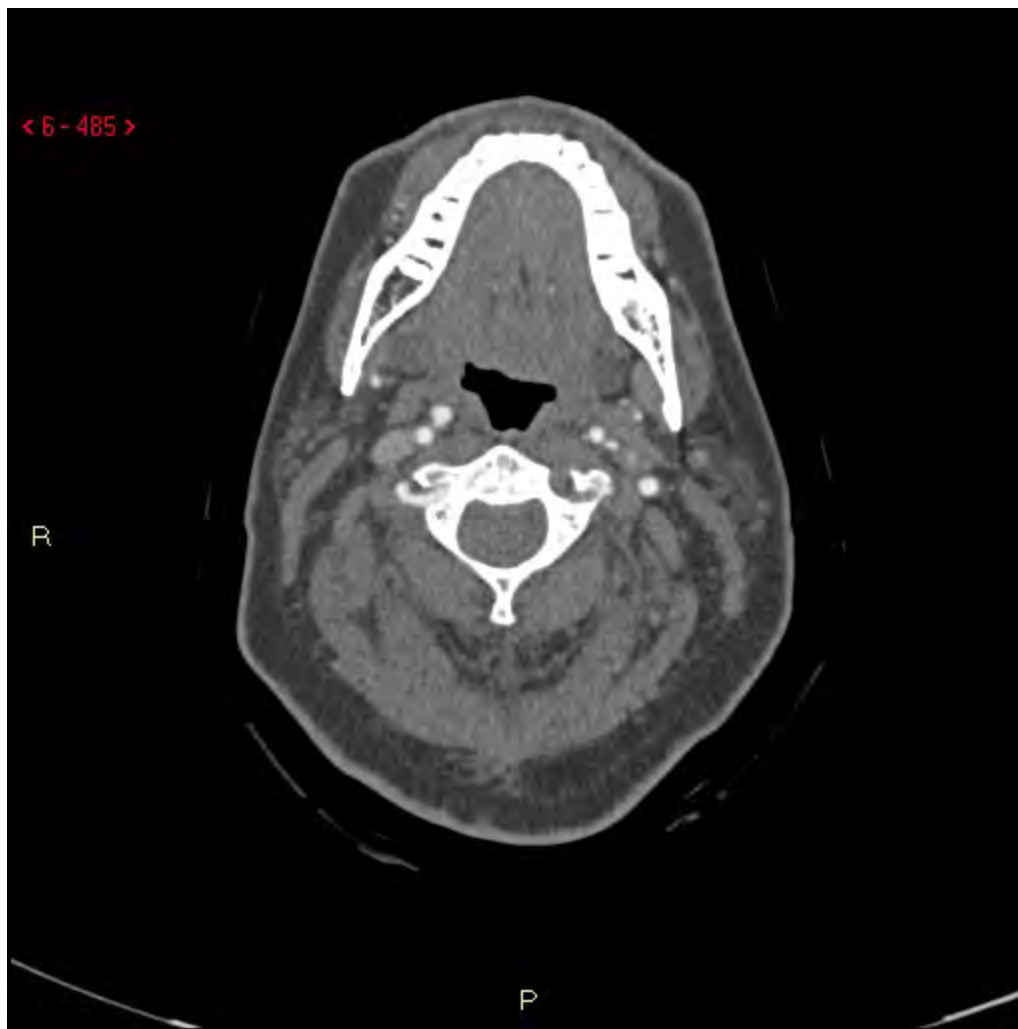P



< 6 - 485 >

R

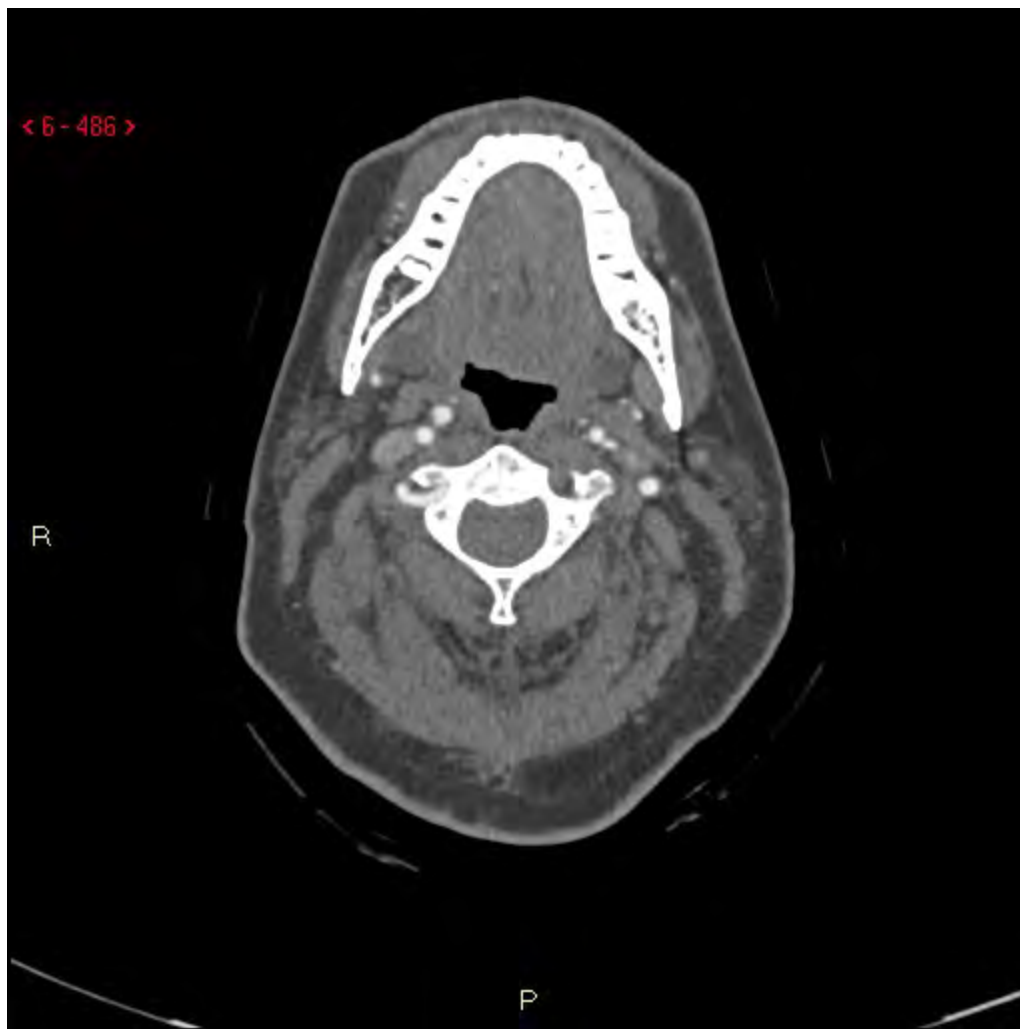P



< 6 - 486 >

R

P

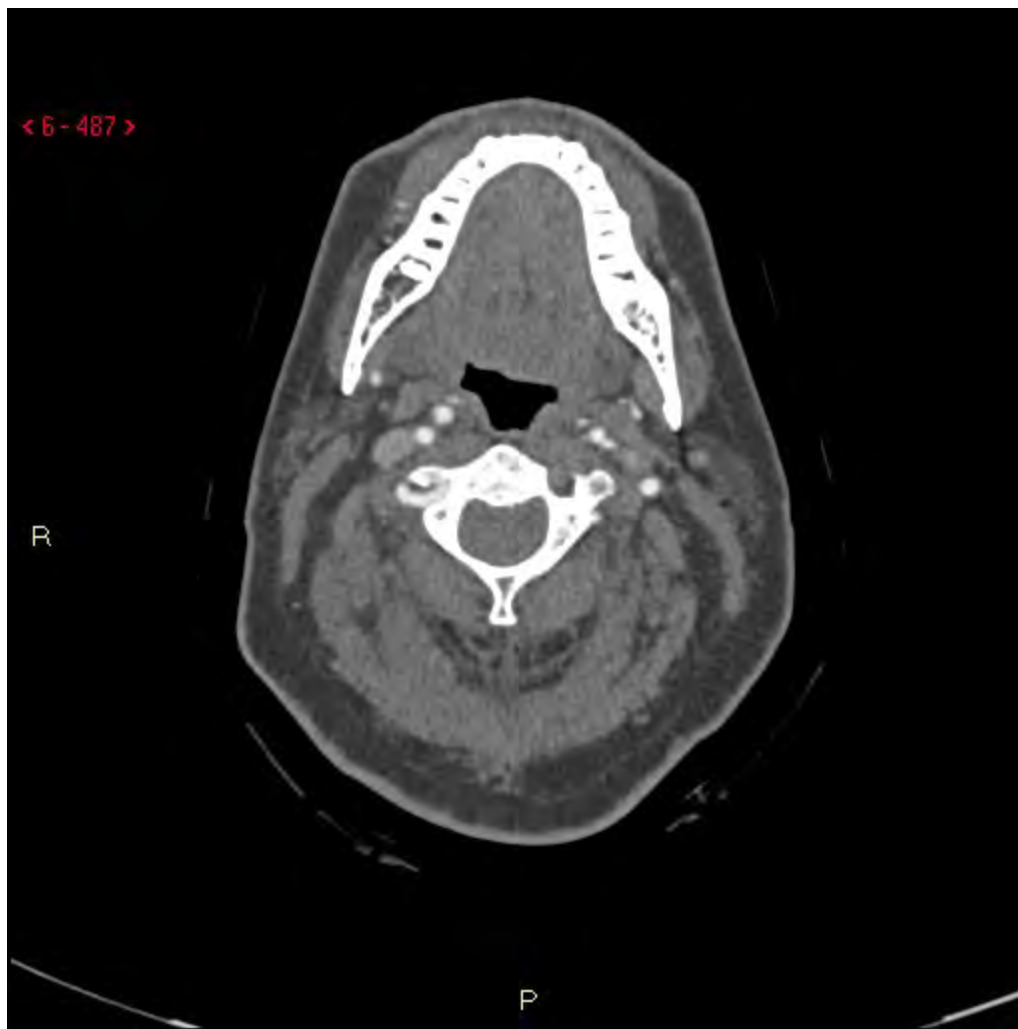


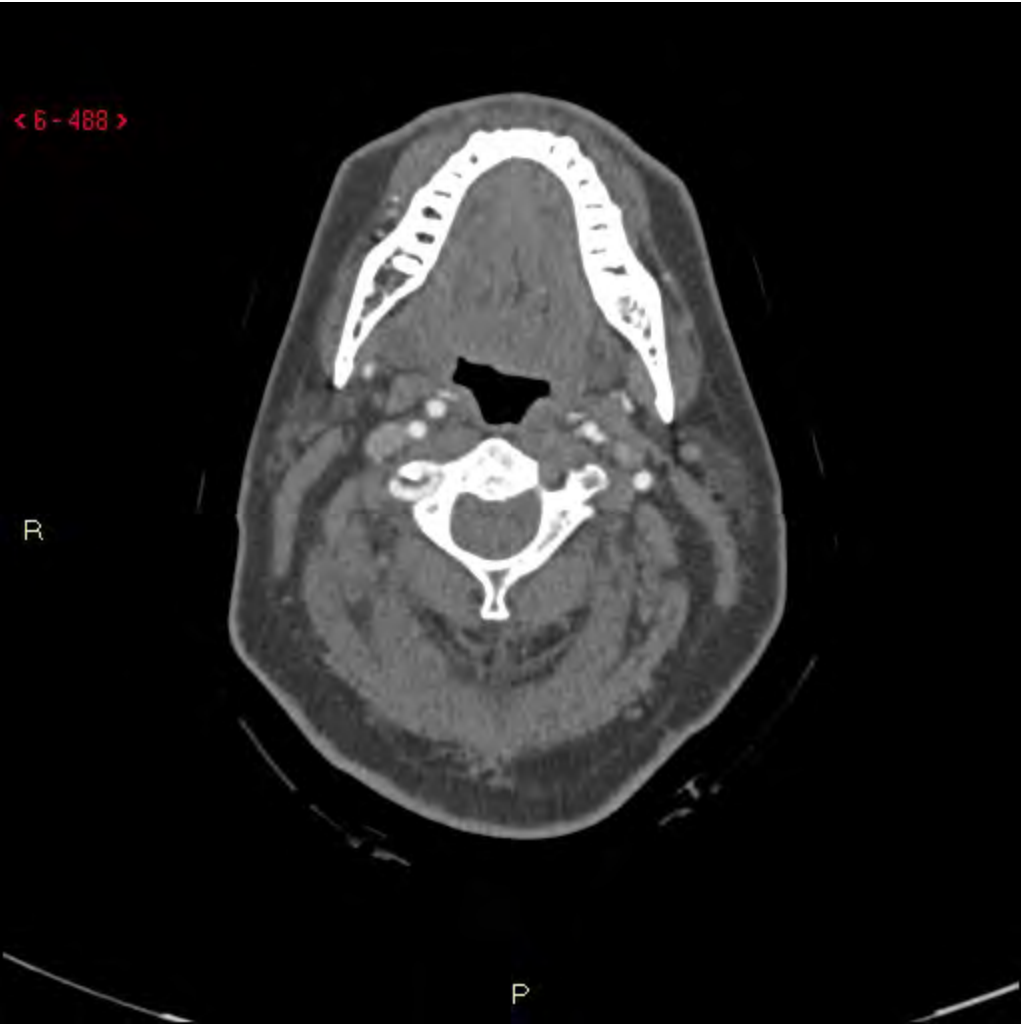
< 6 - 487 >

R

P

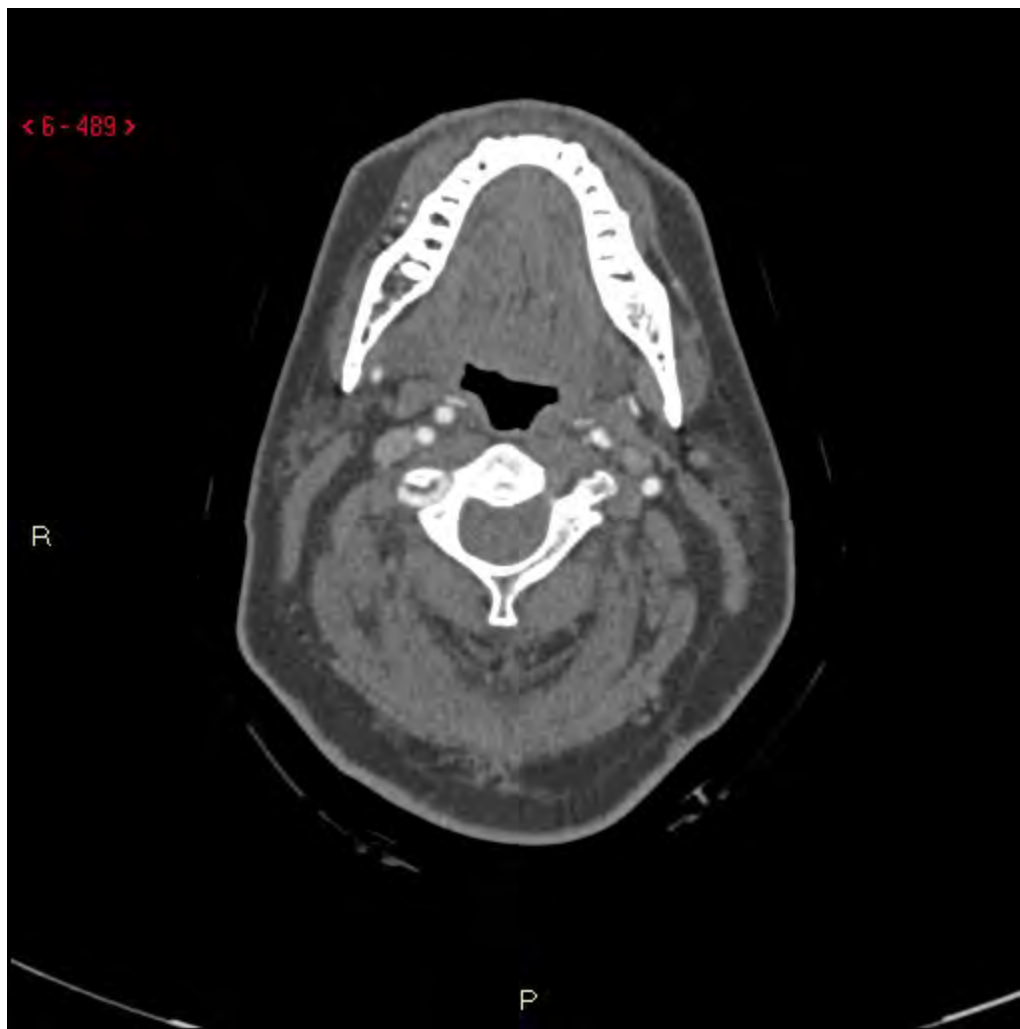


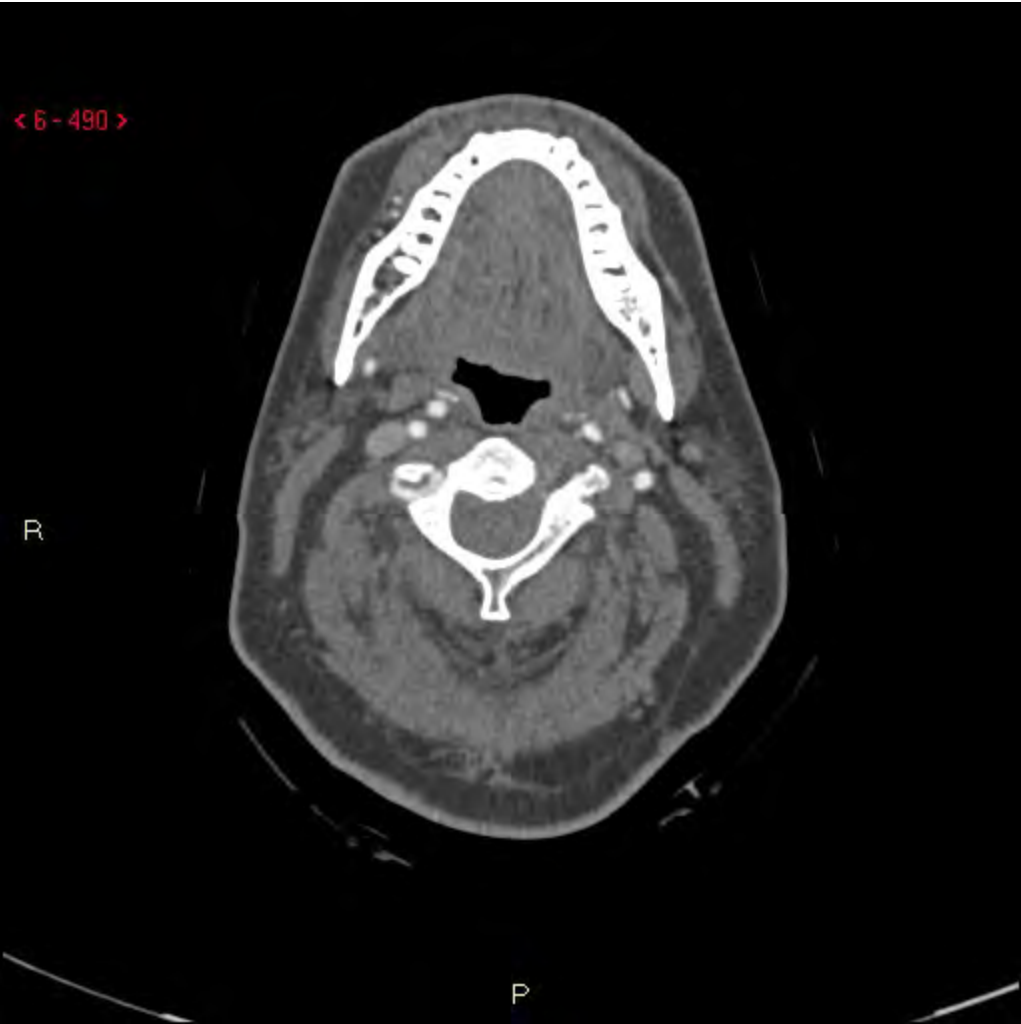
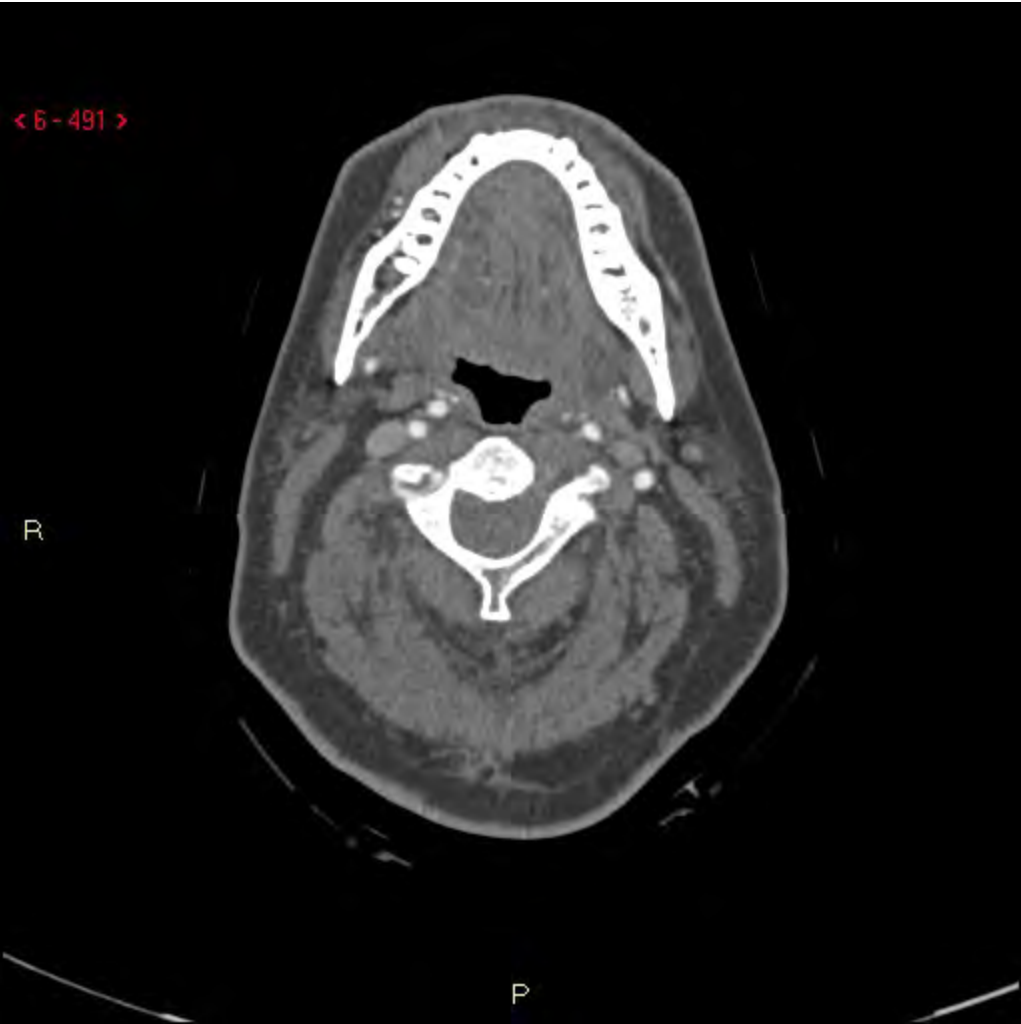< 6 - 489 >

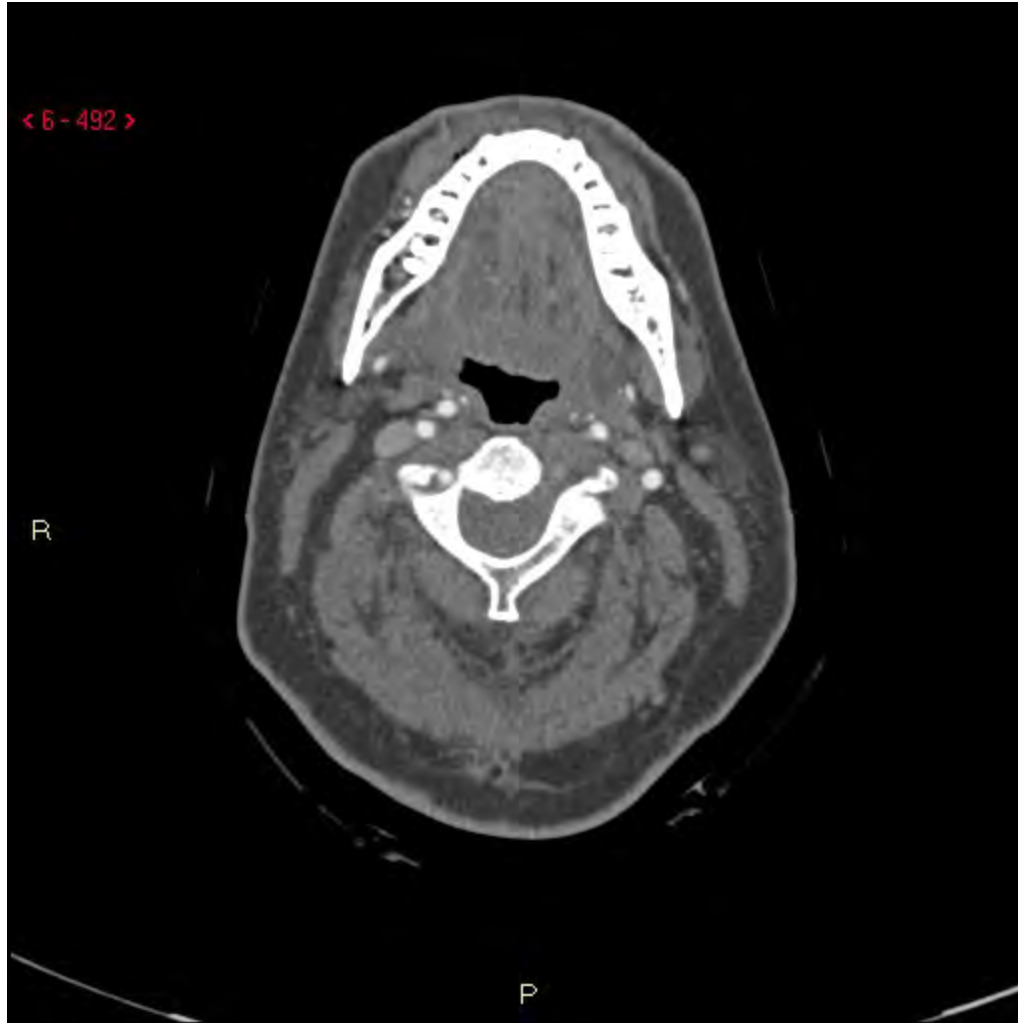R

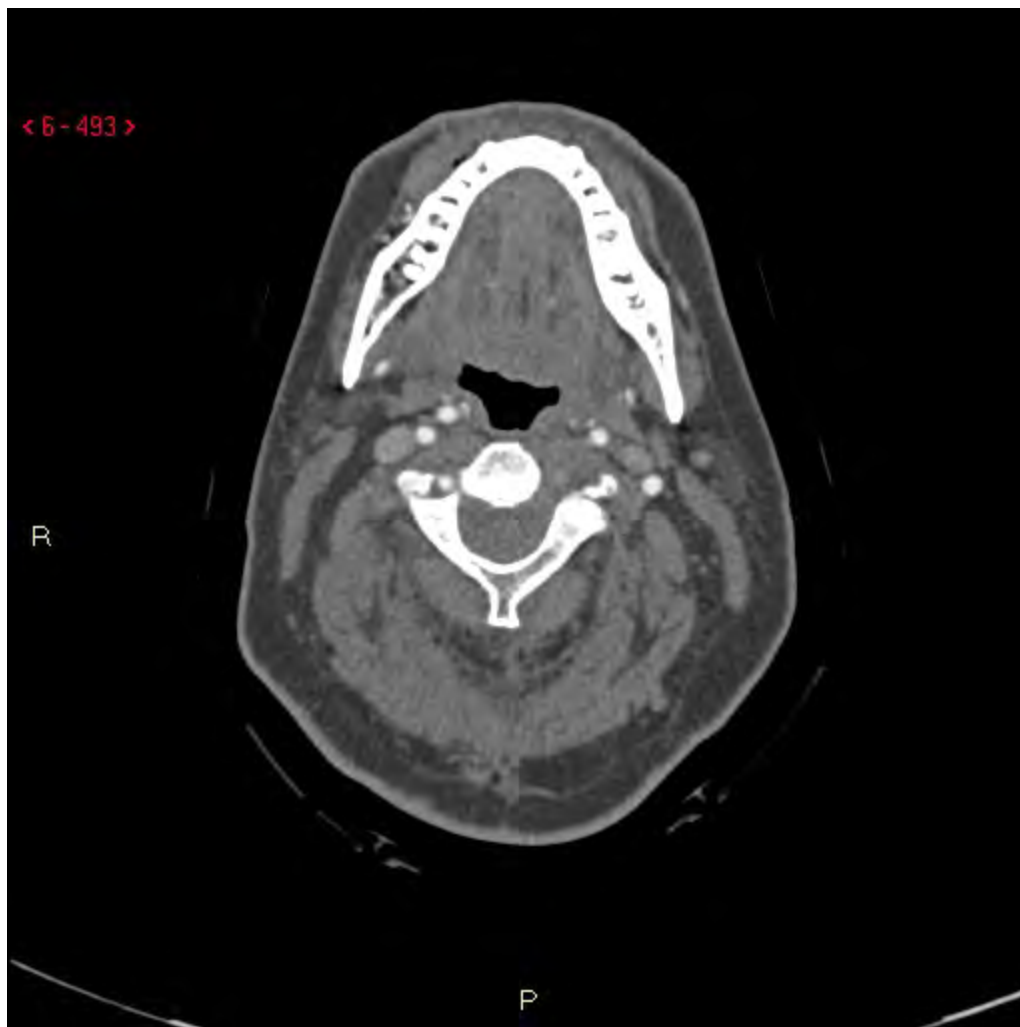P

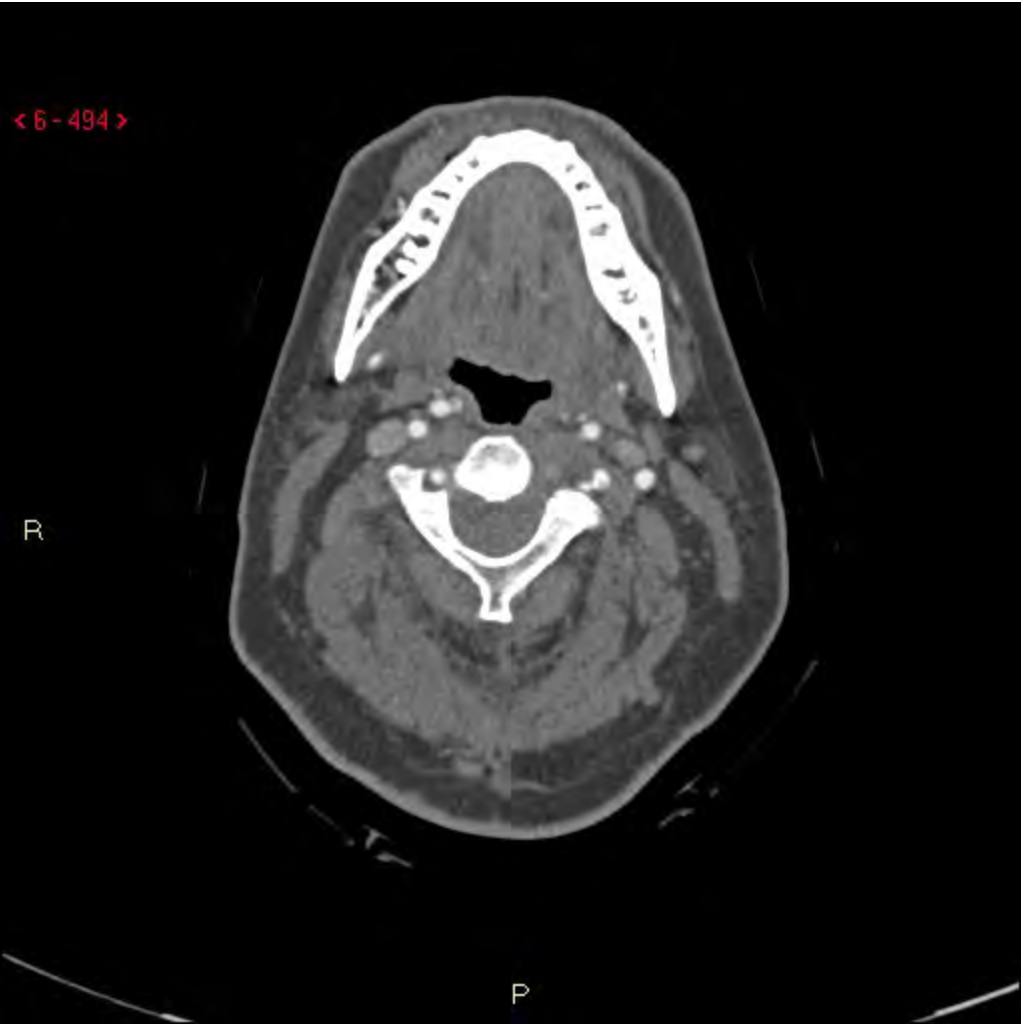




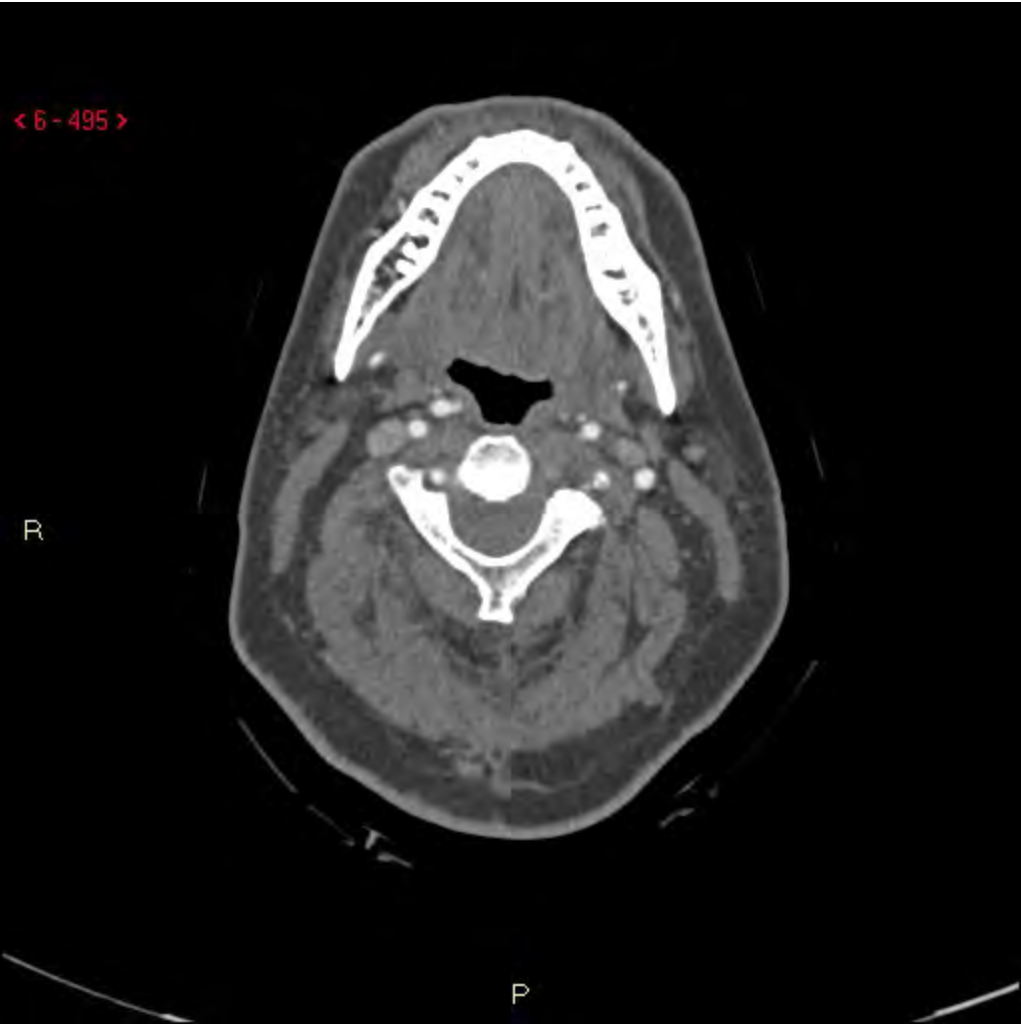


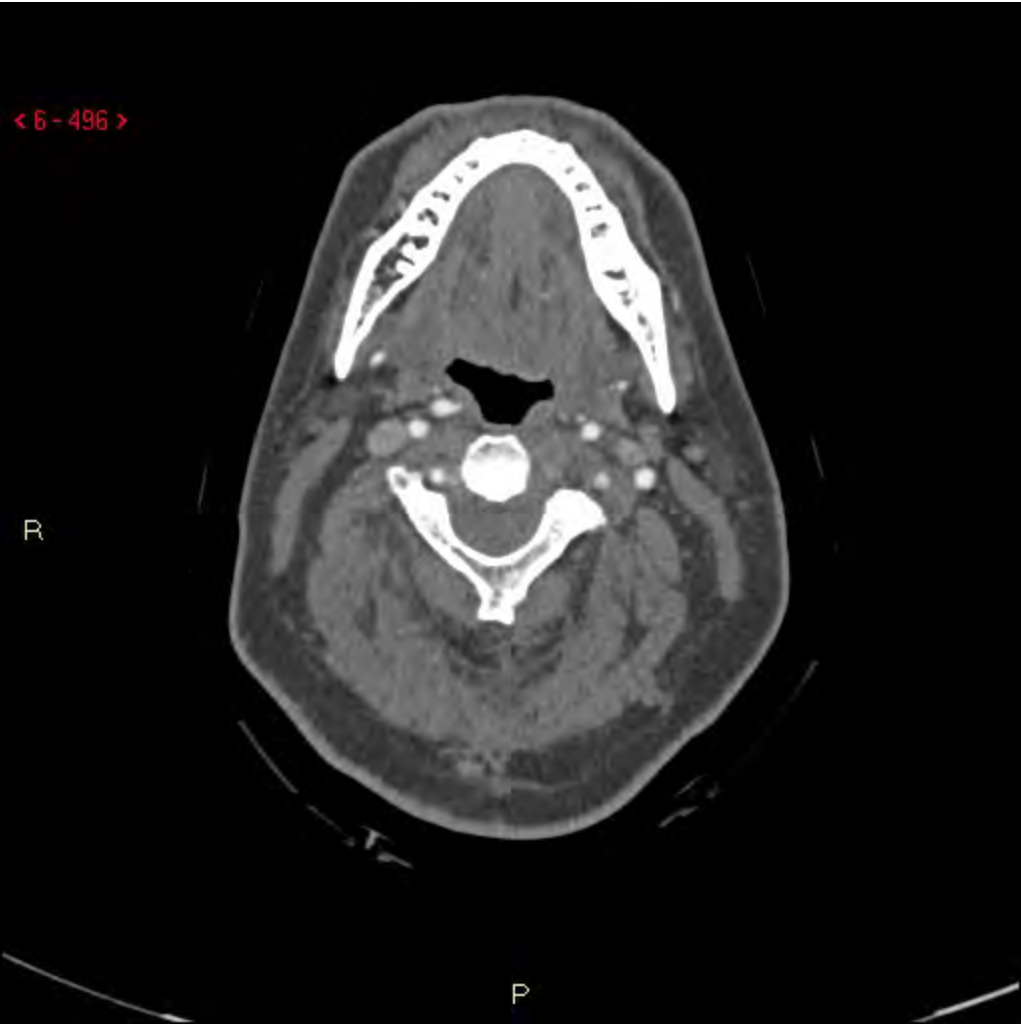


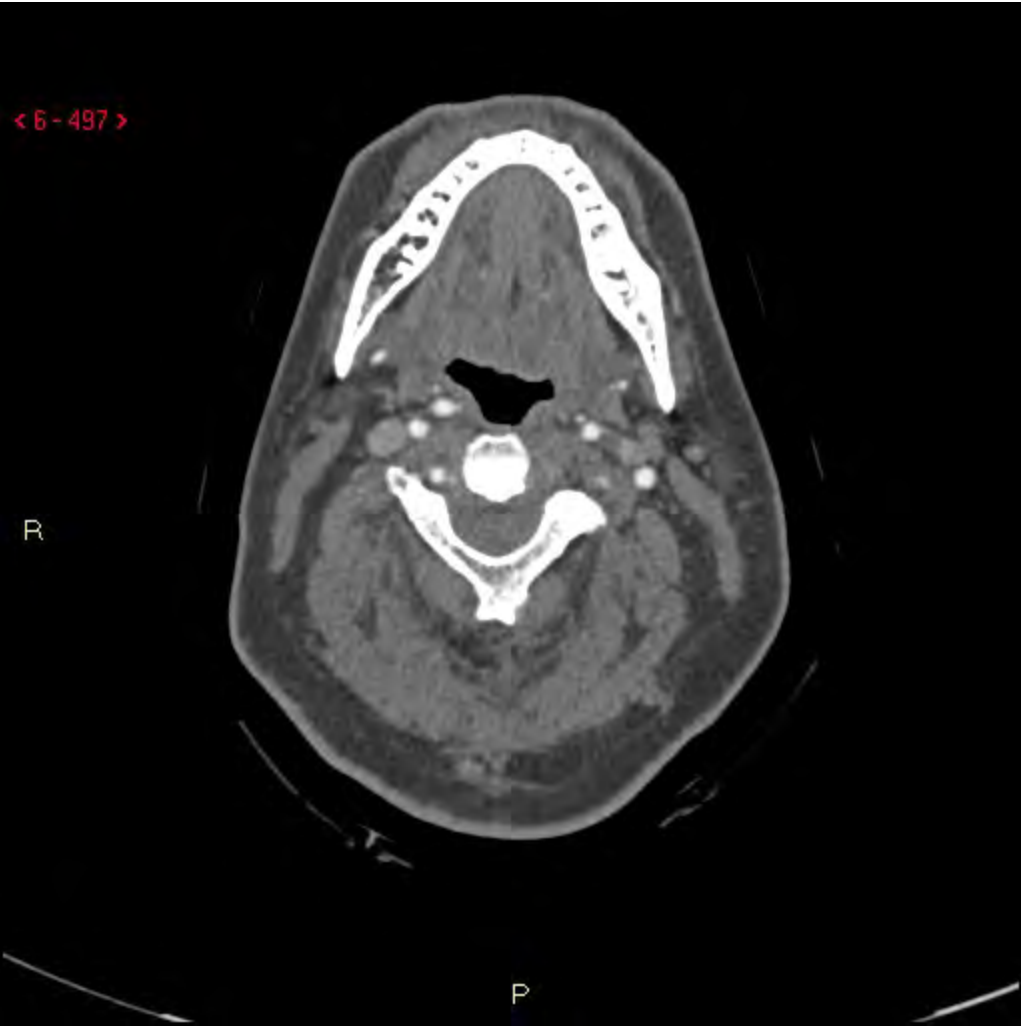


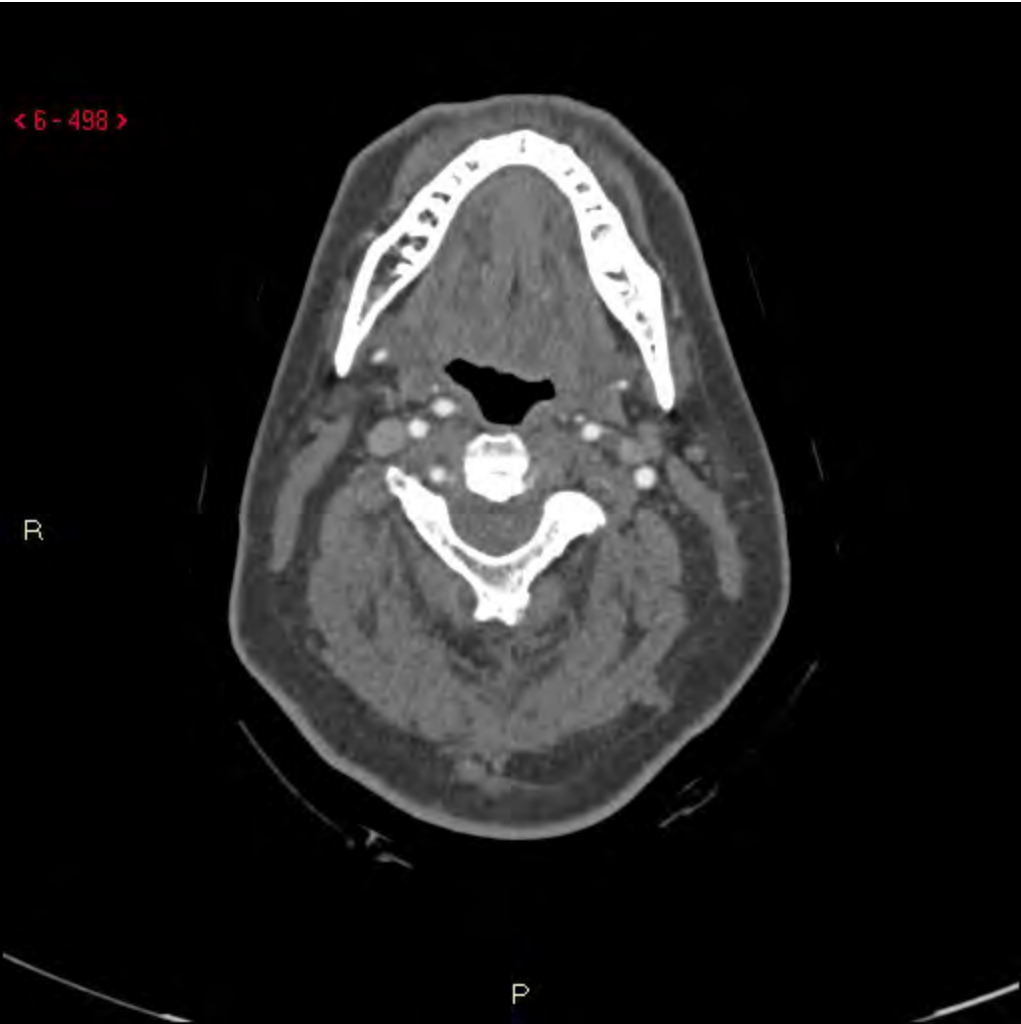


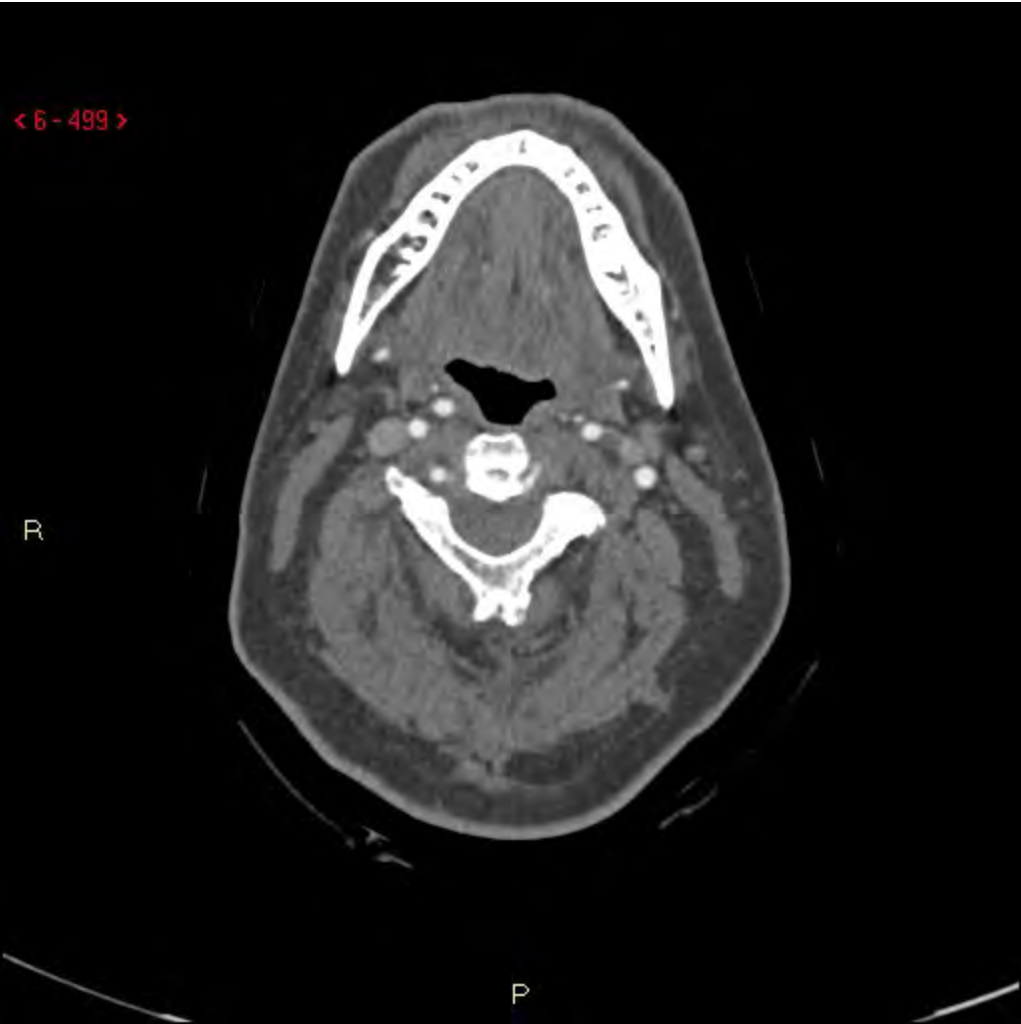


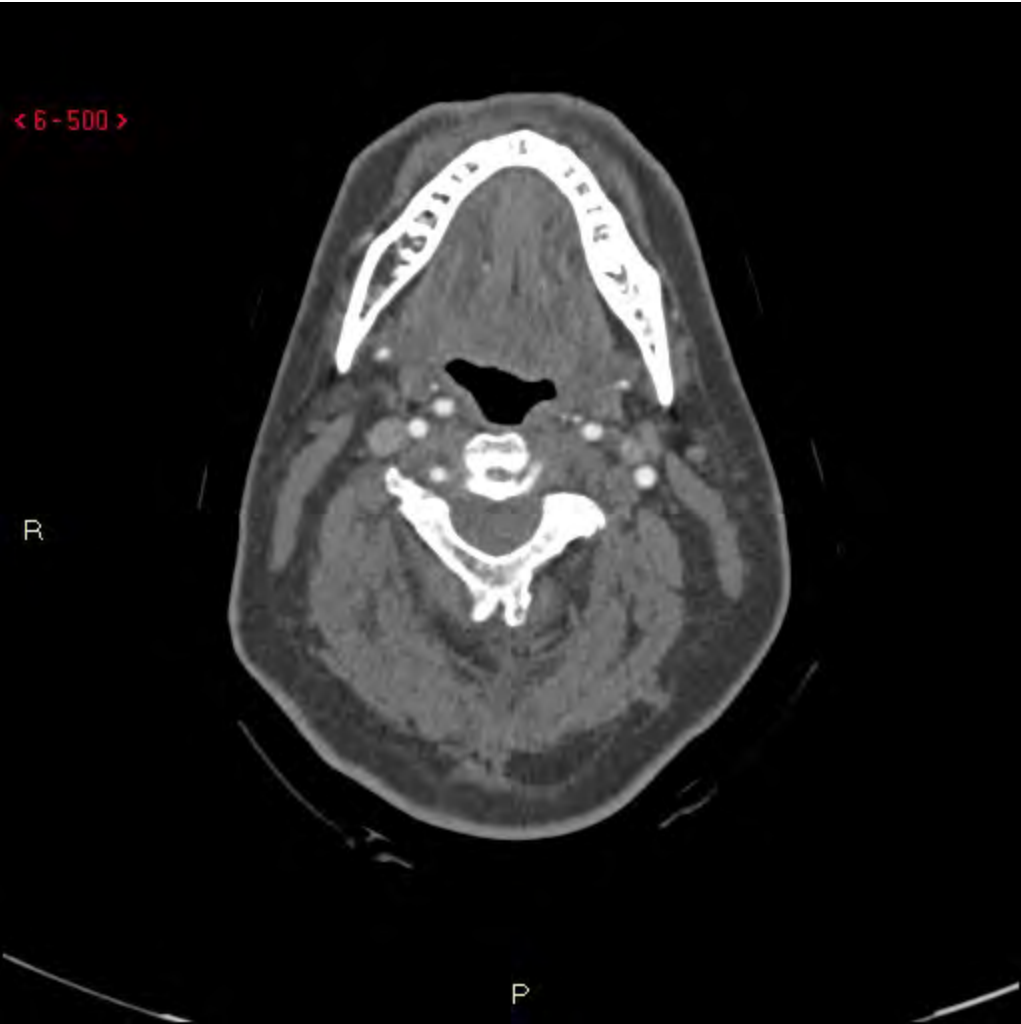


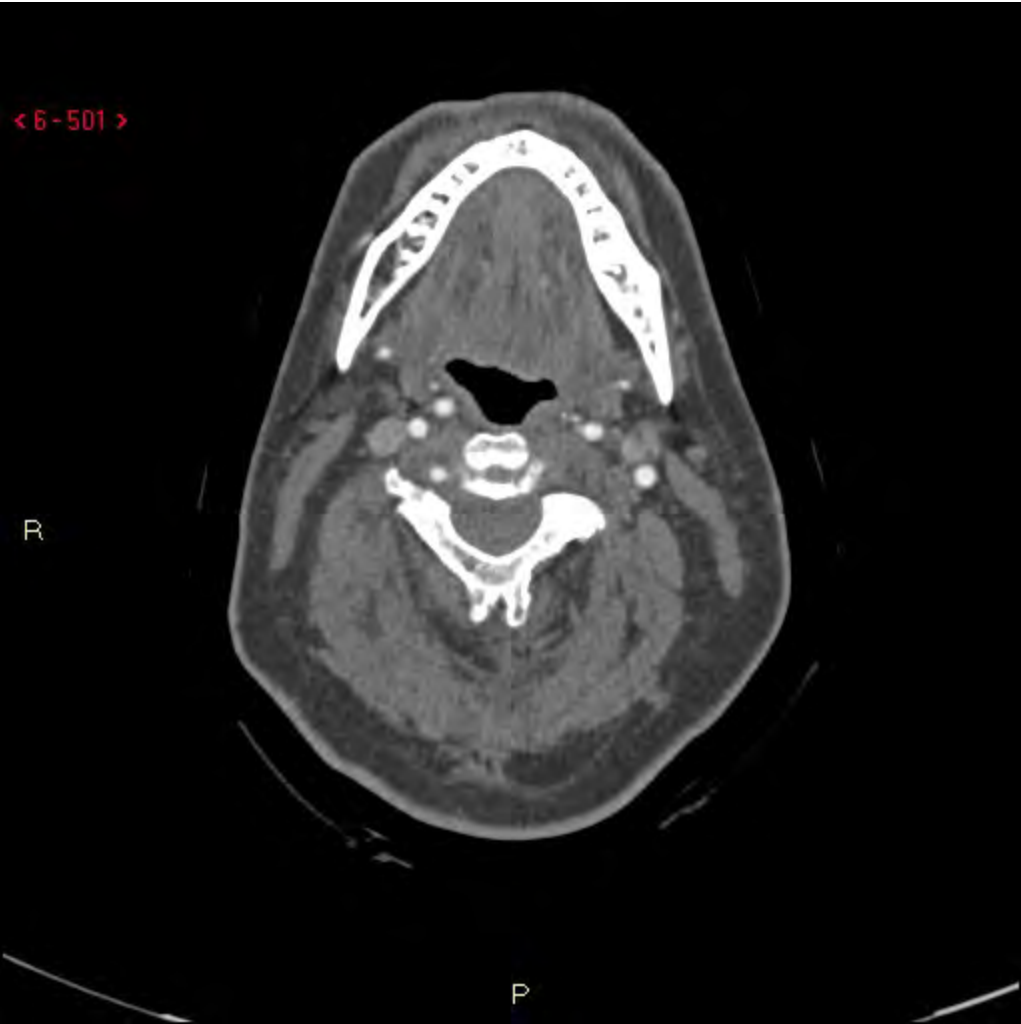




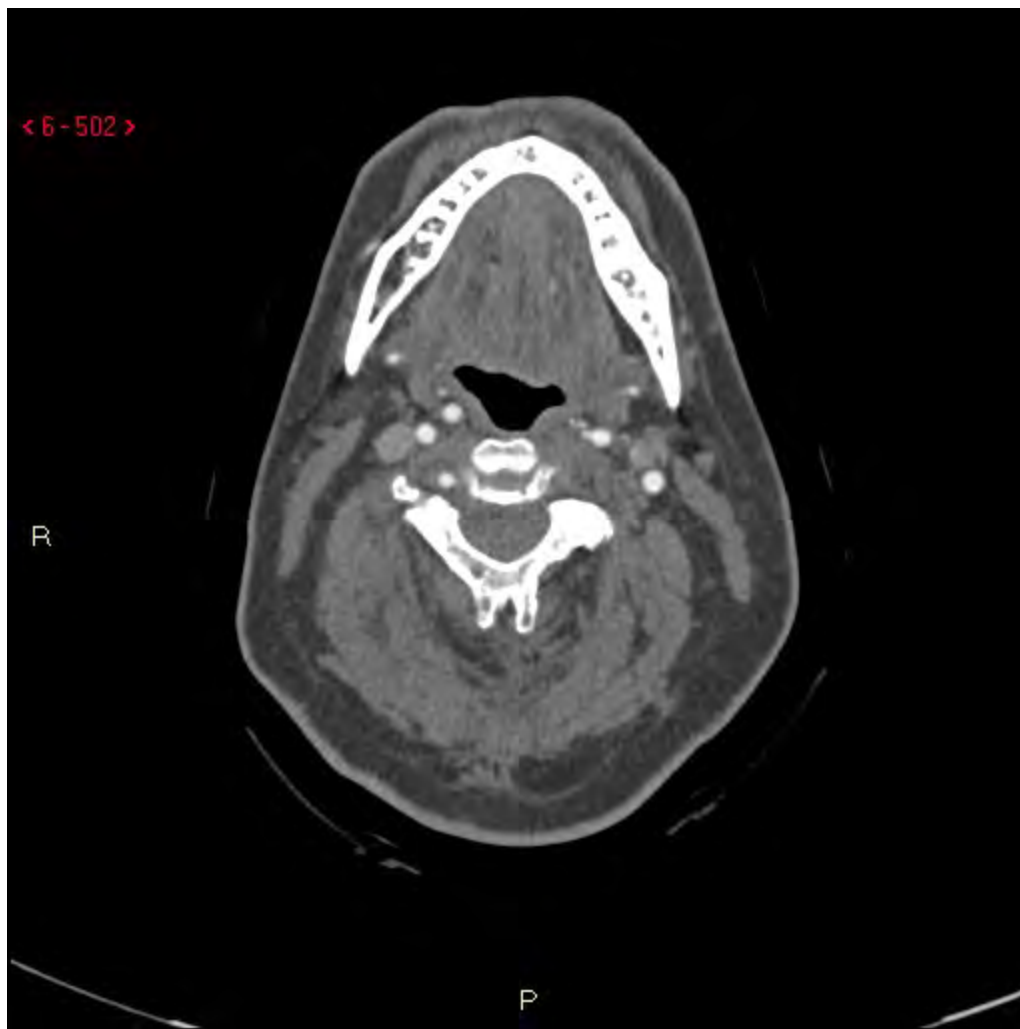< 6 - 502 >

R

P

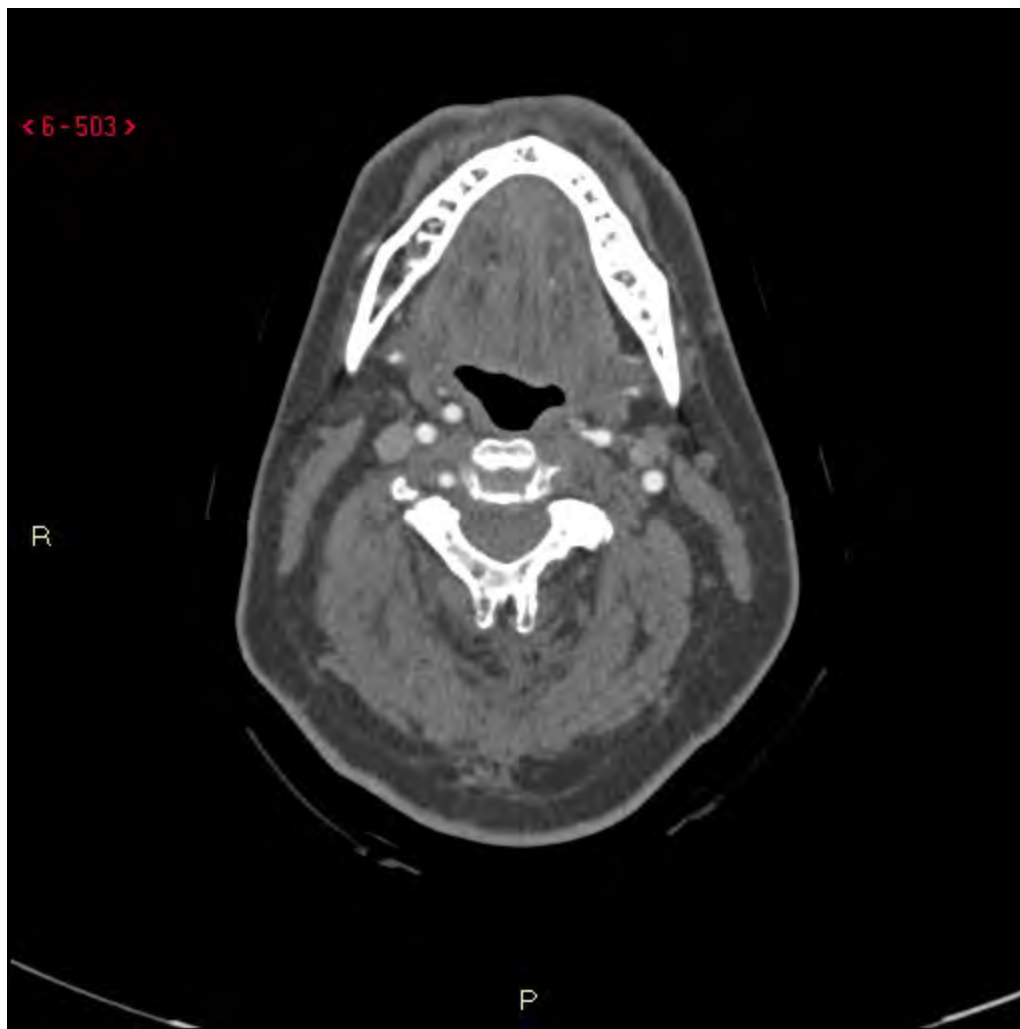


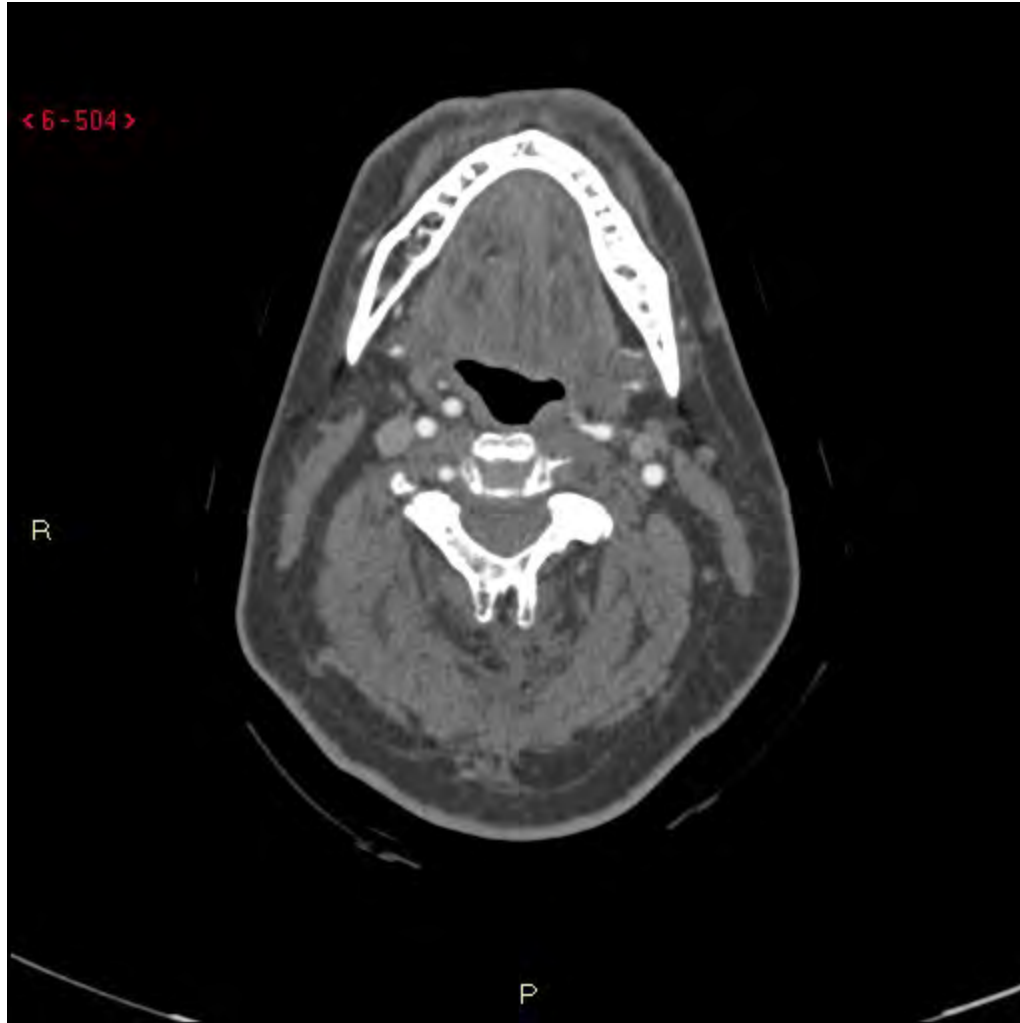
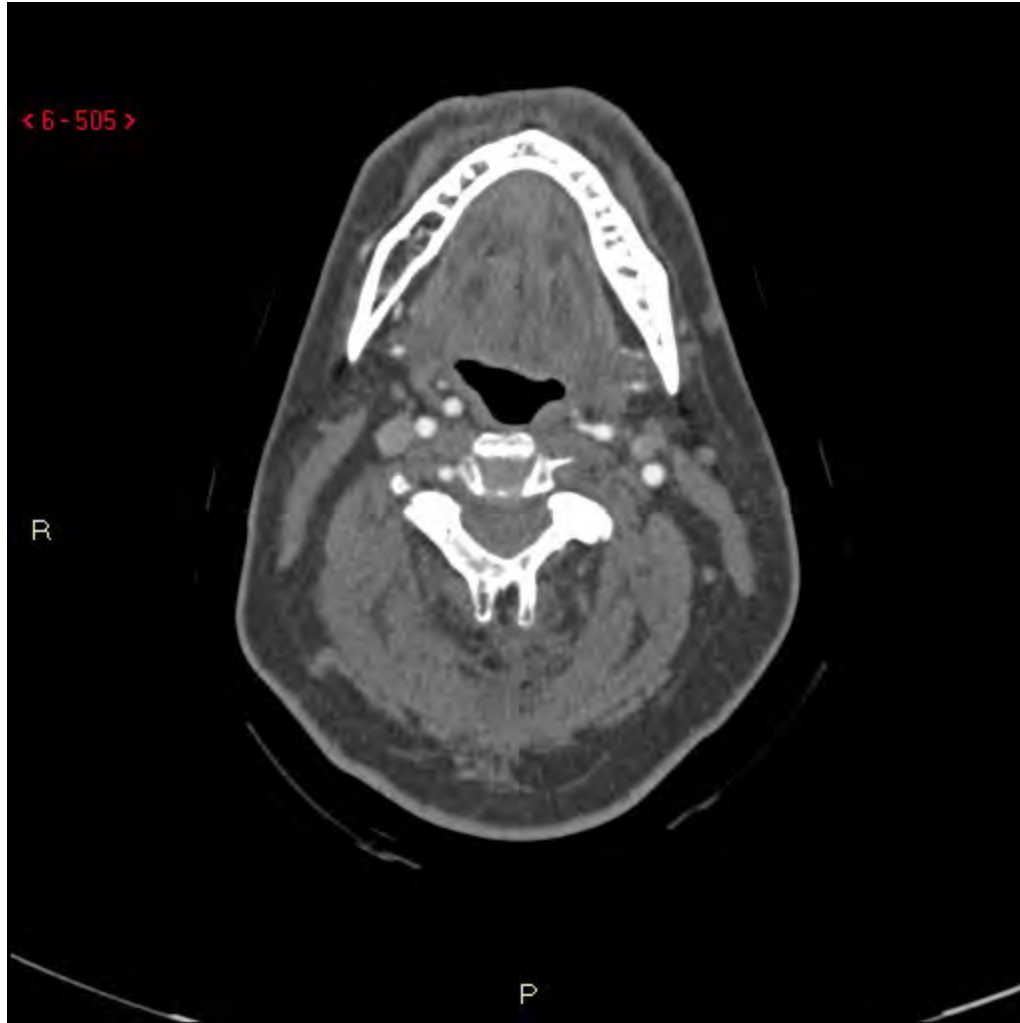< 6-503 >

R

P



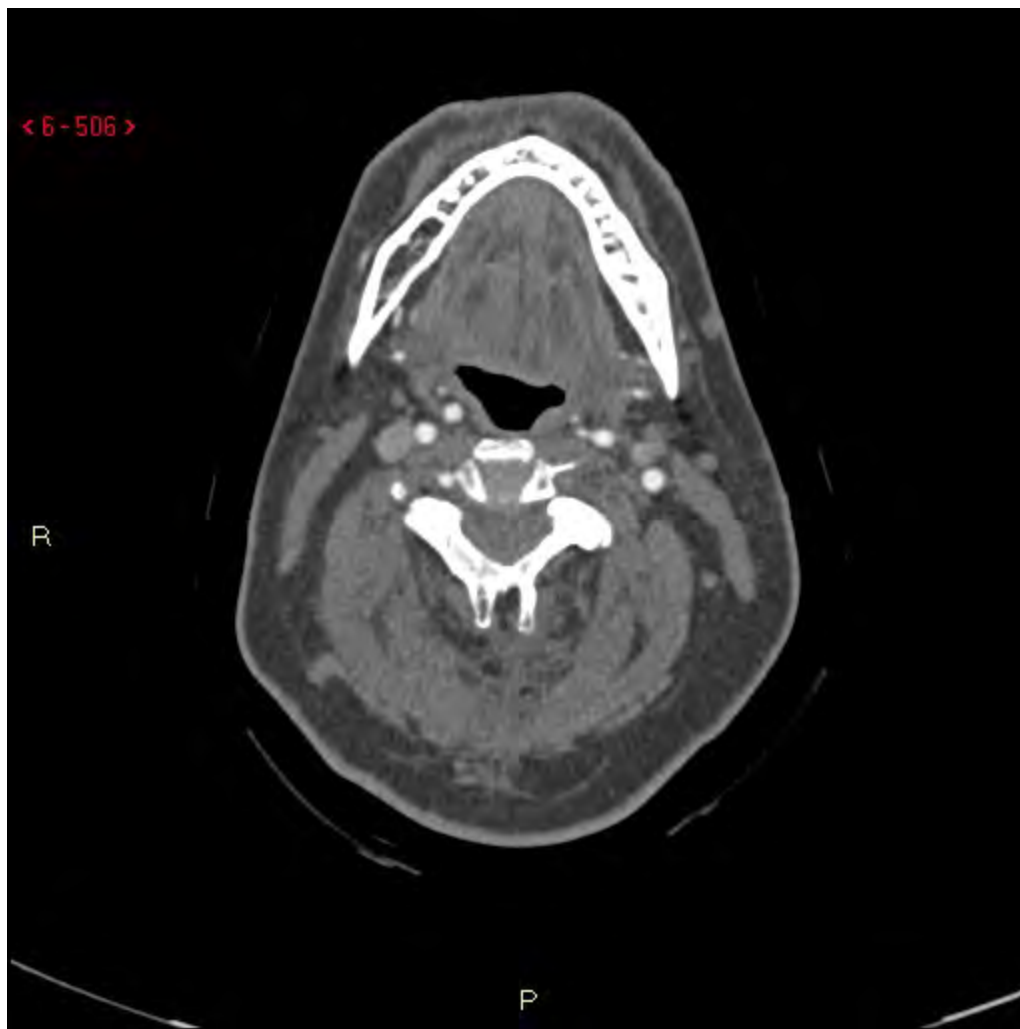



< 6-506 >

R

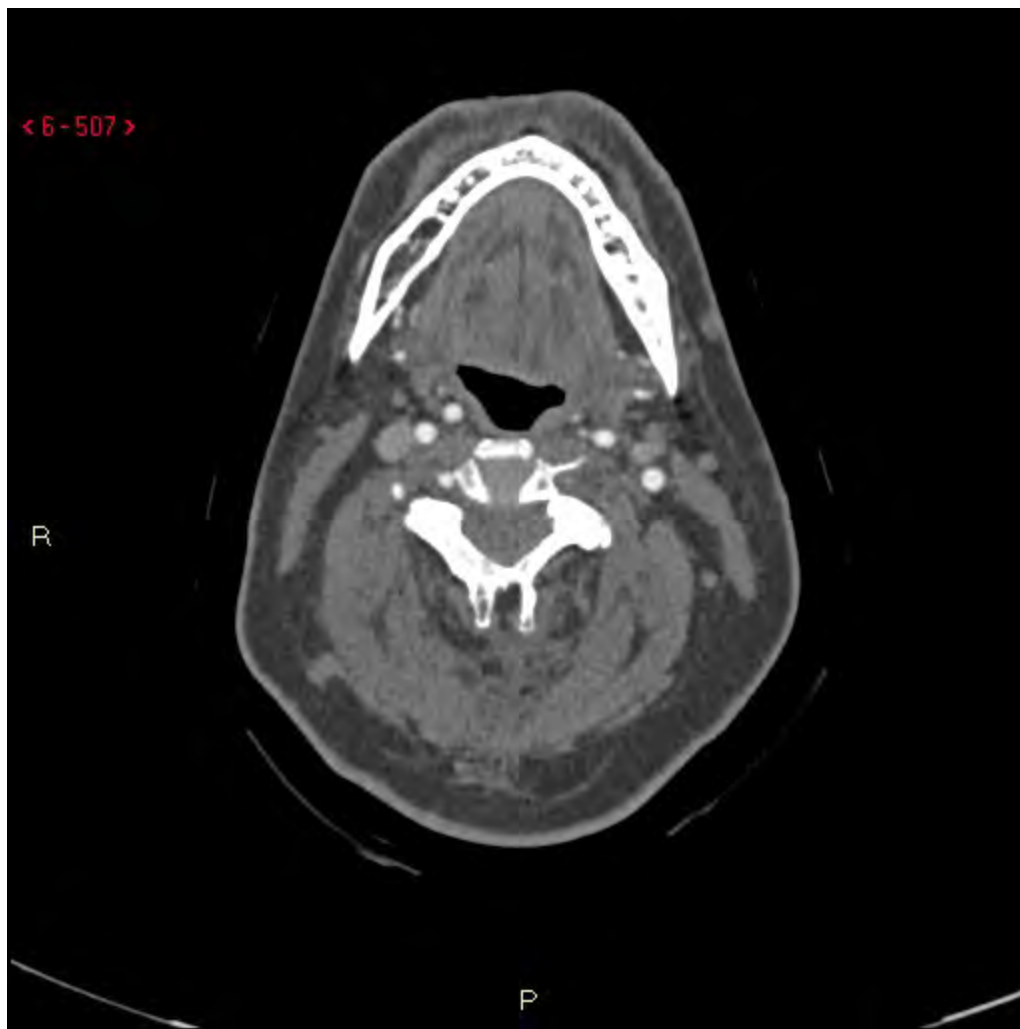P

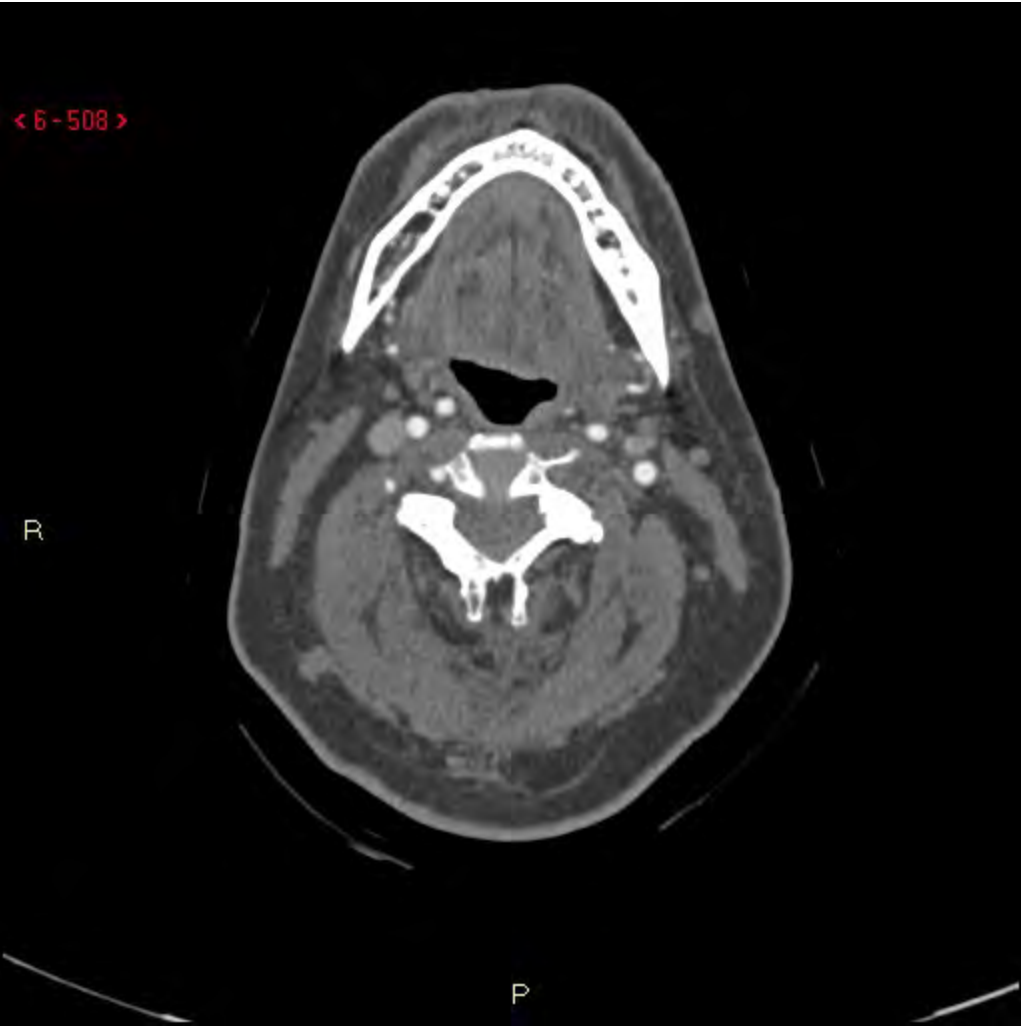


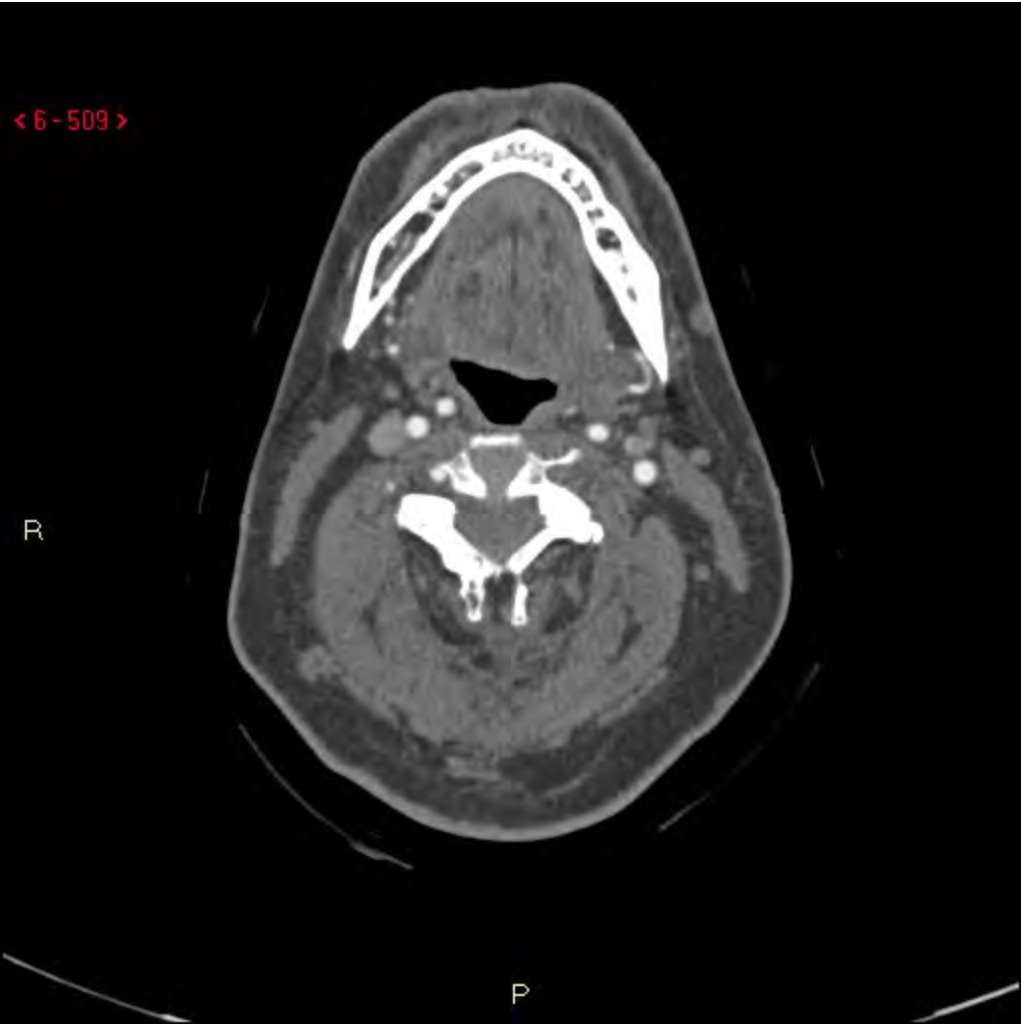
< 6-507 >

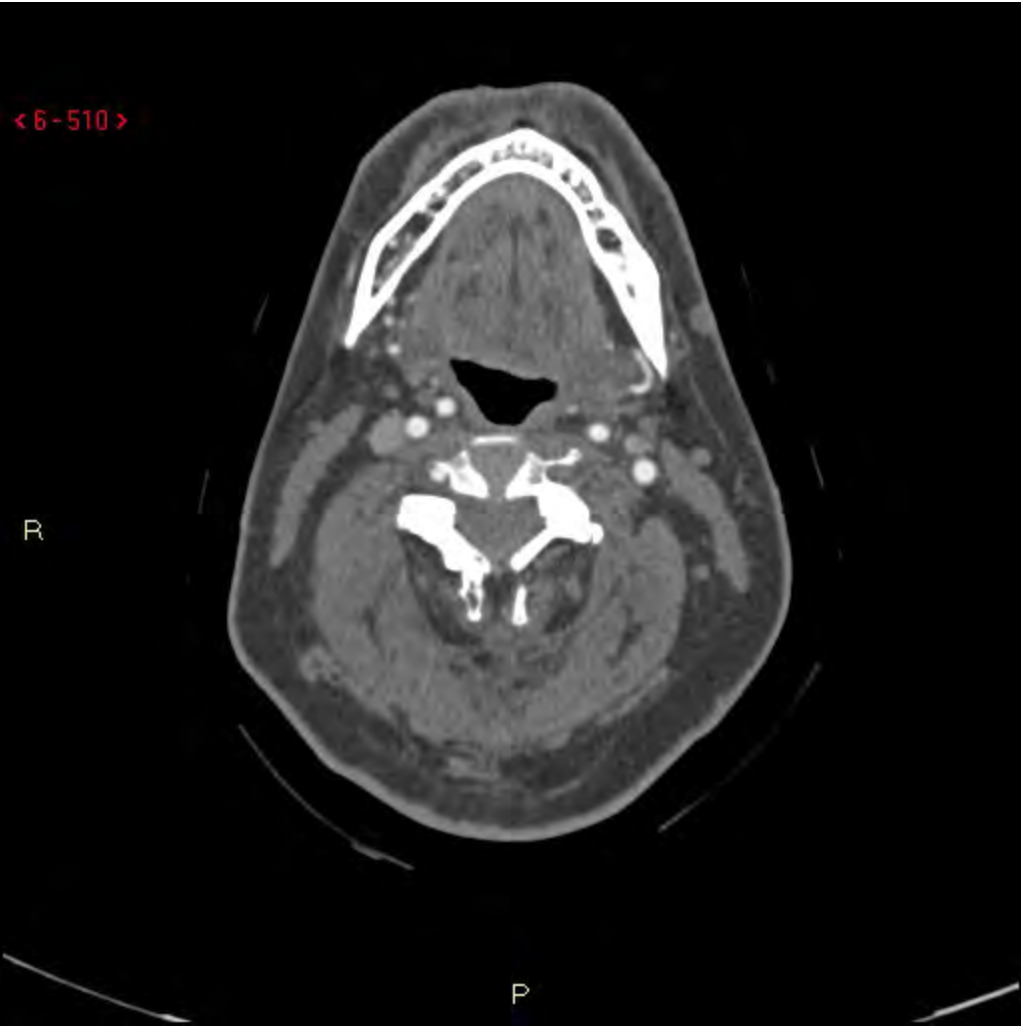
R

P

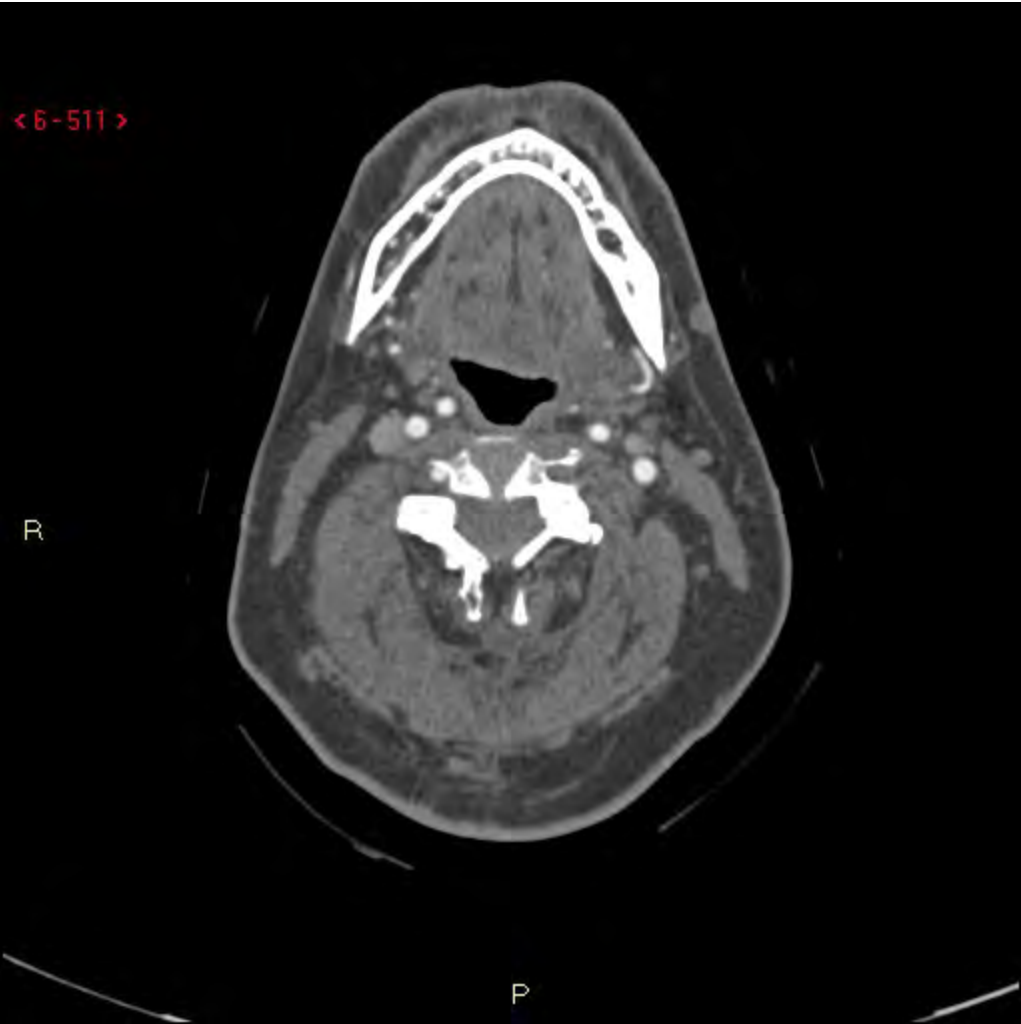


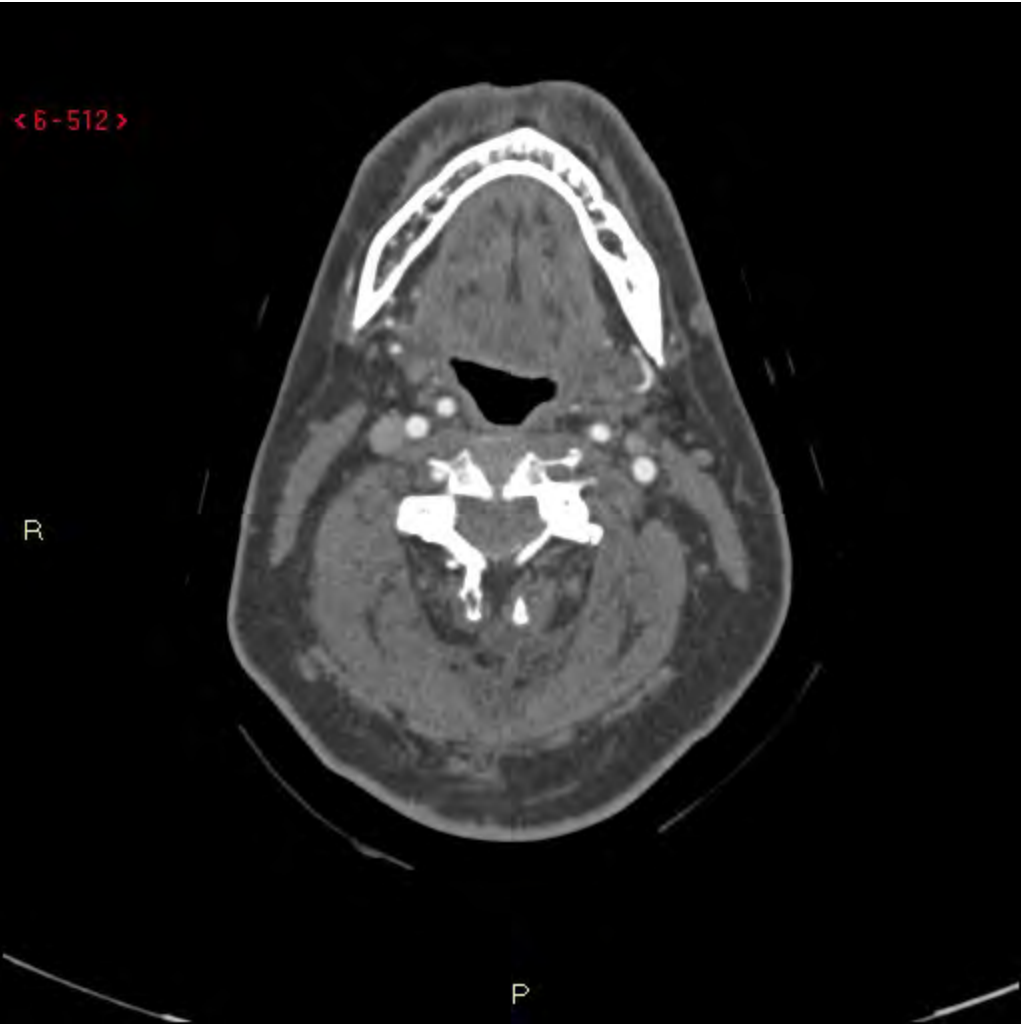


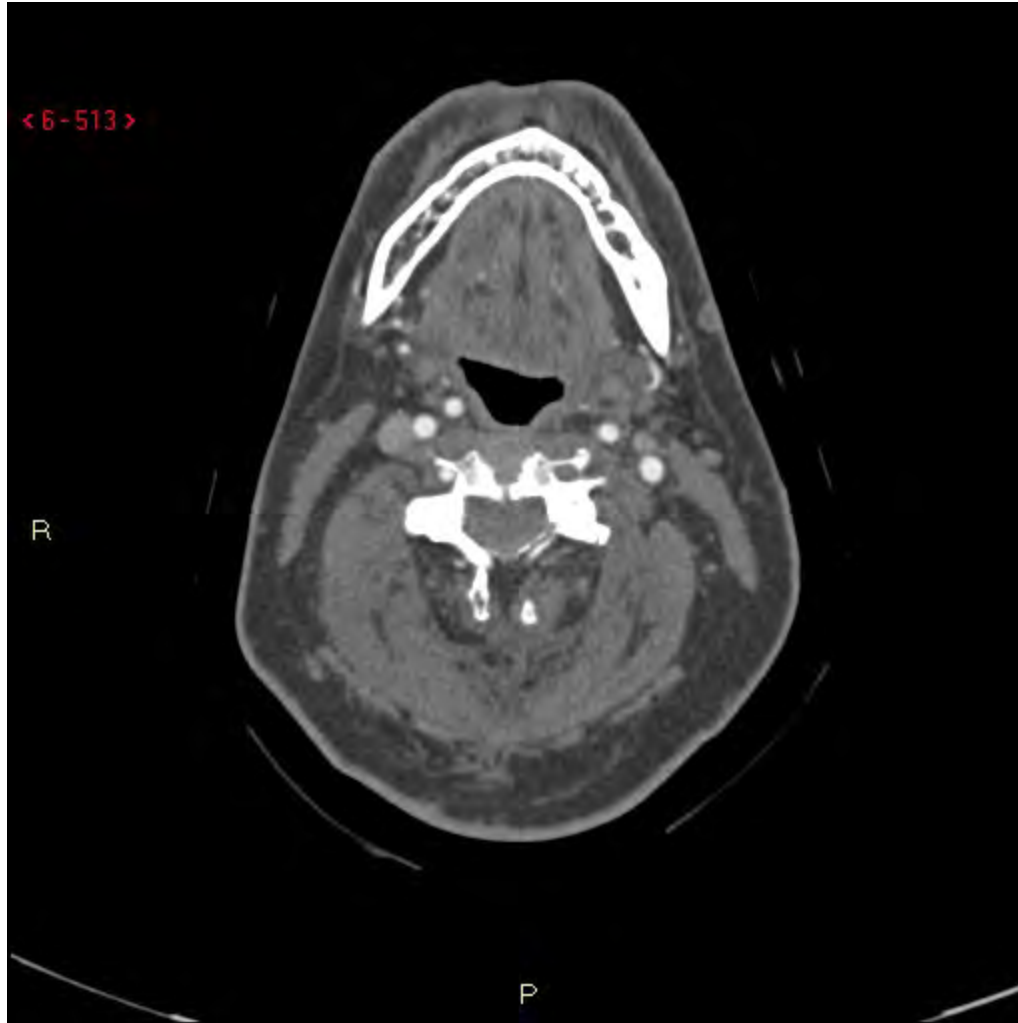


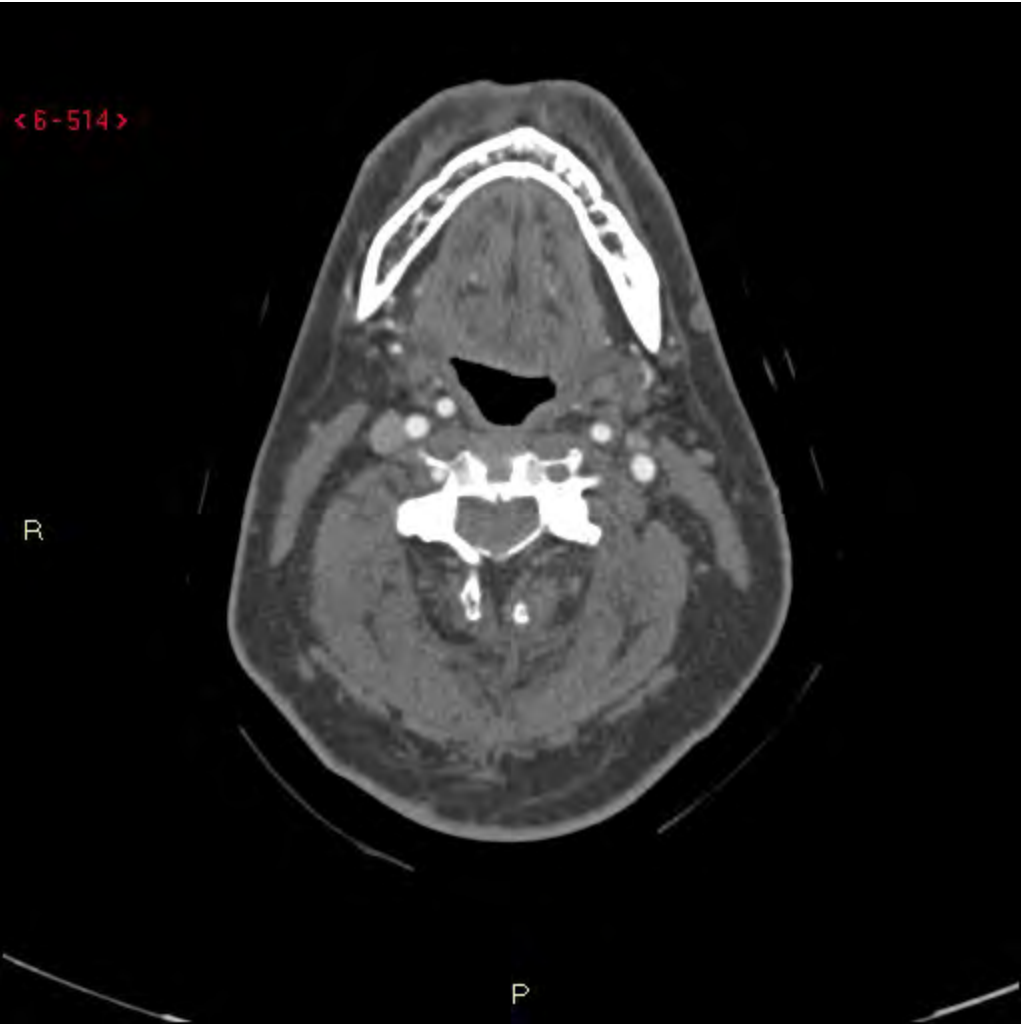


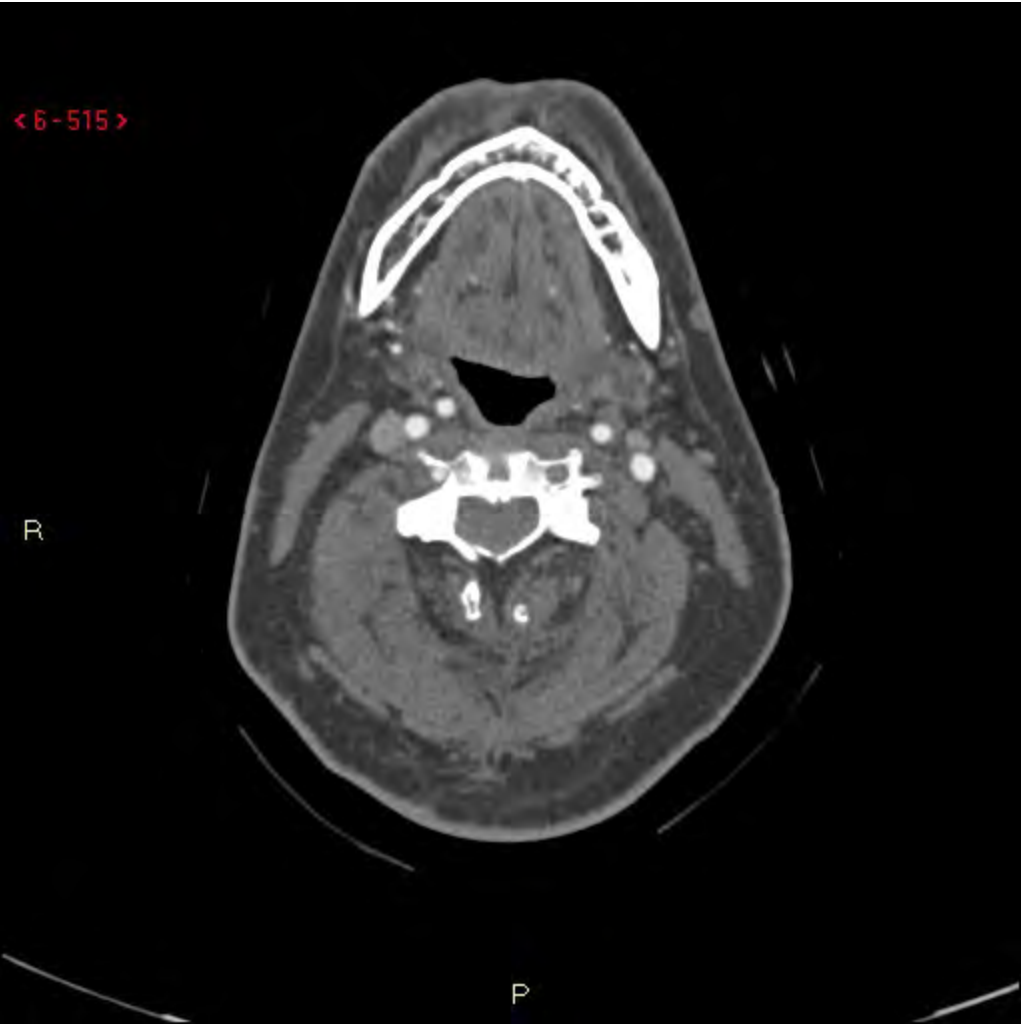


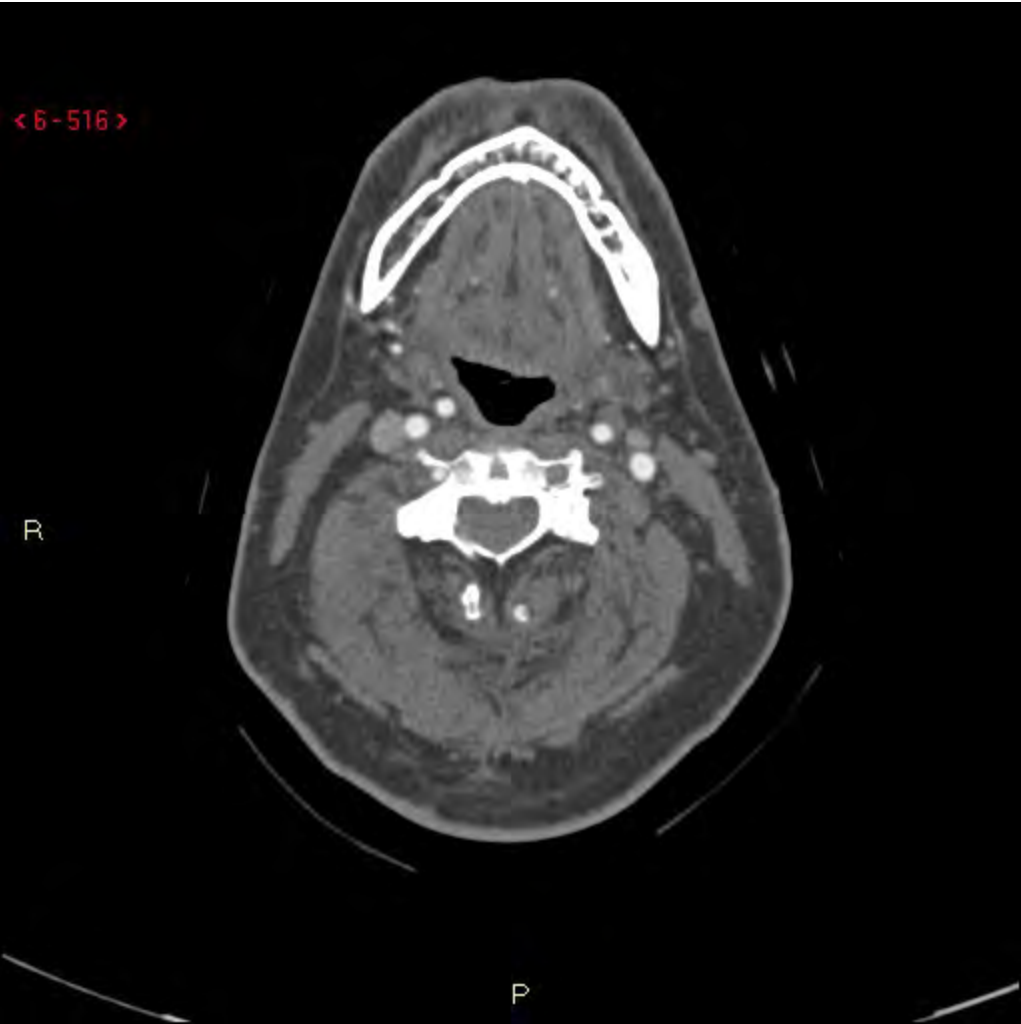


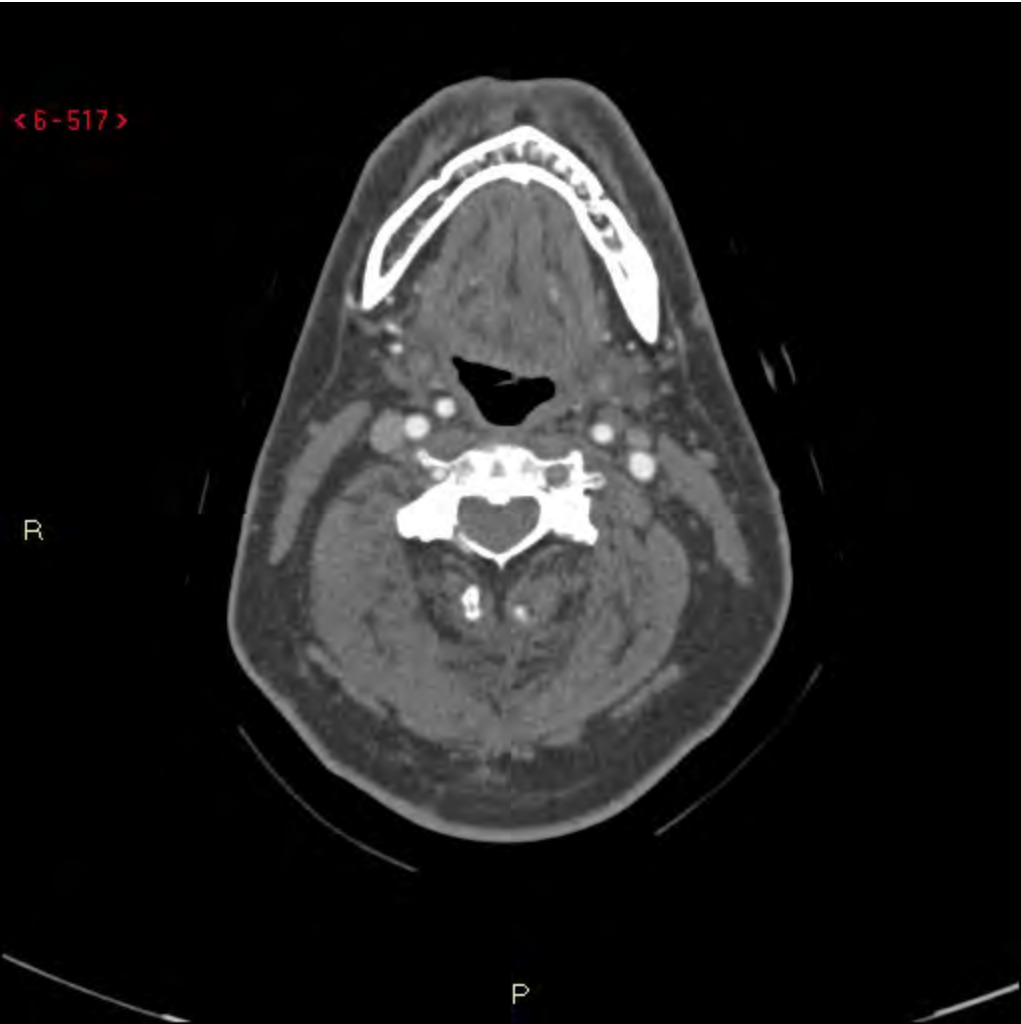


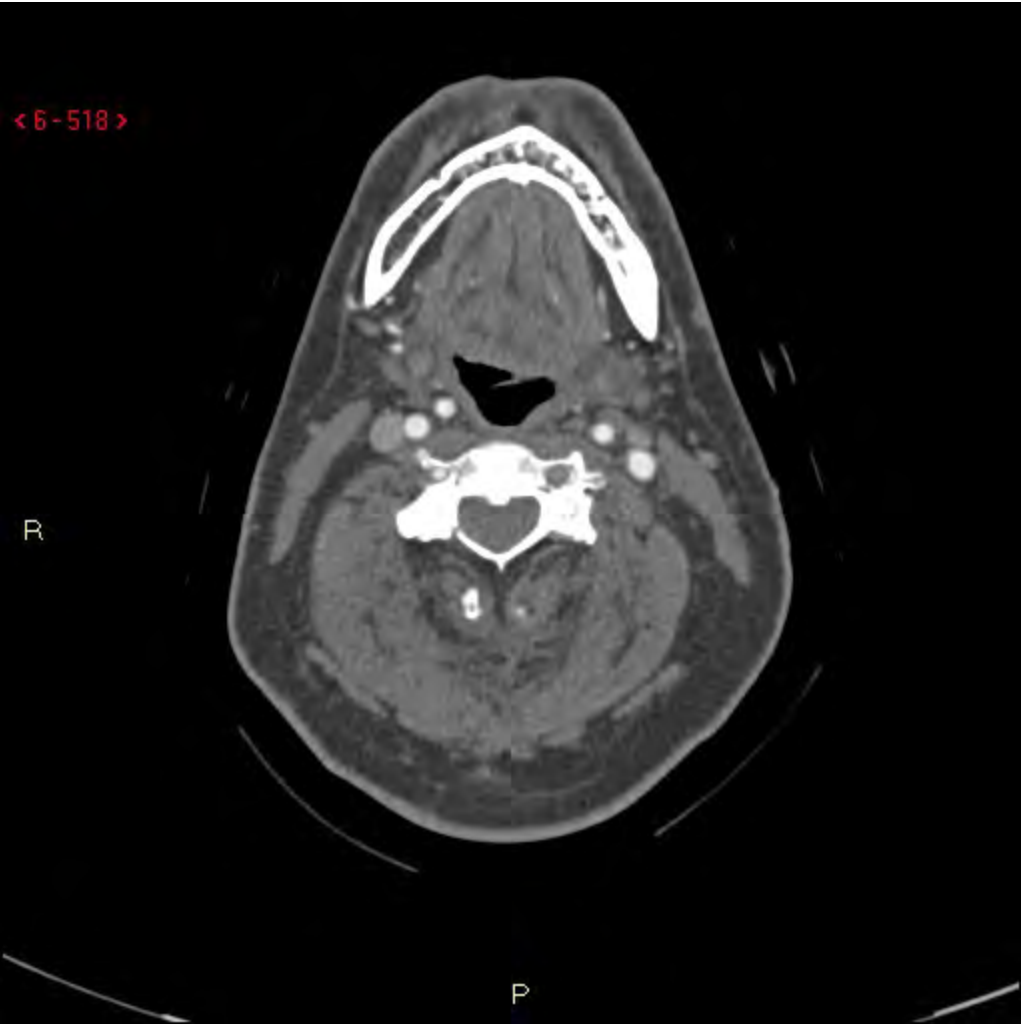




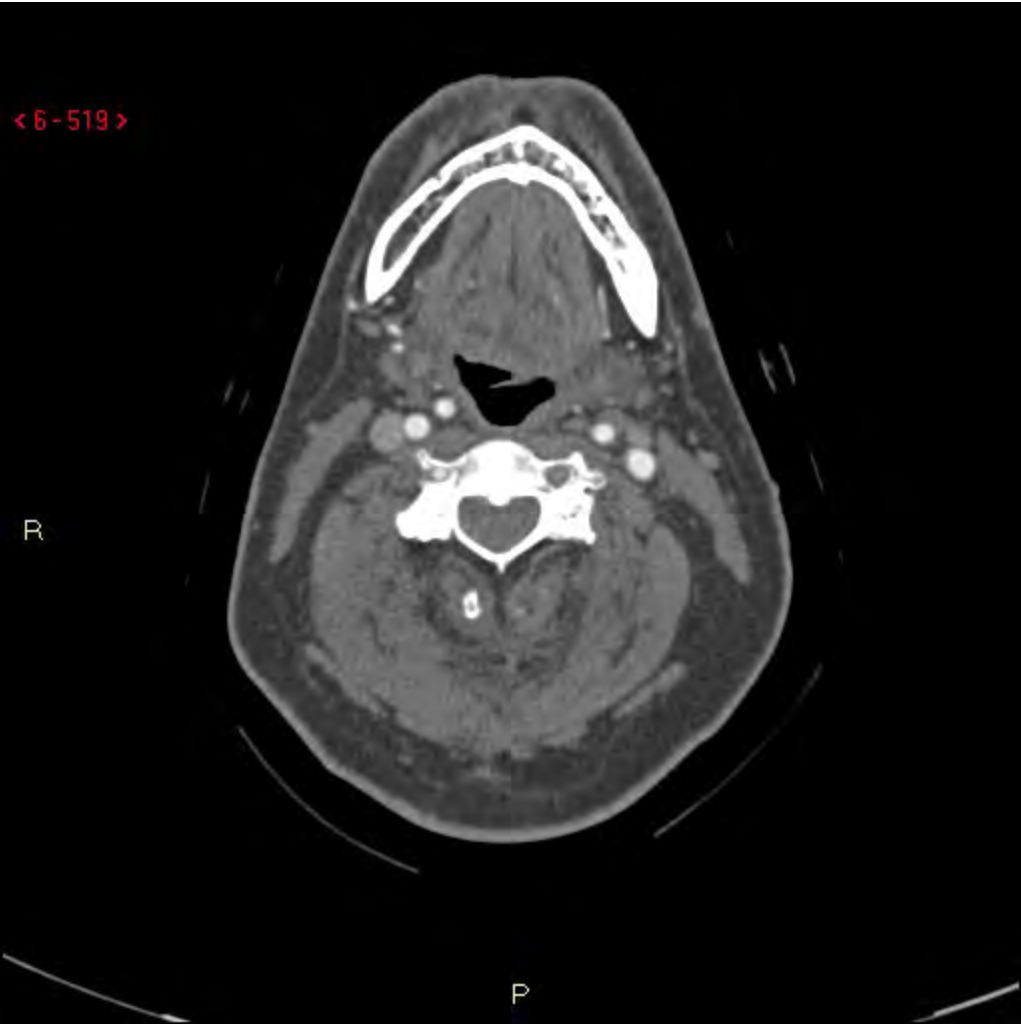


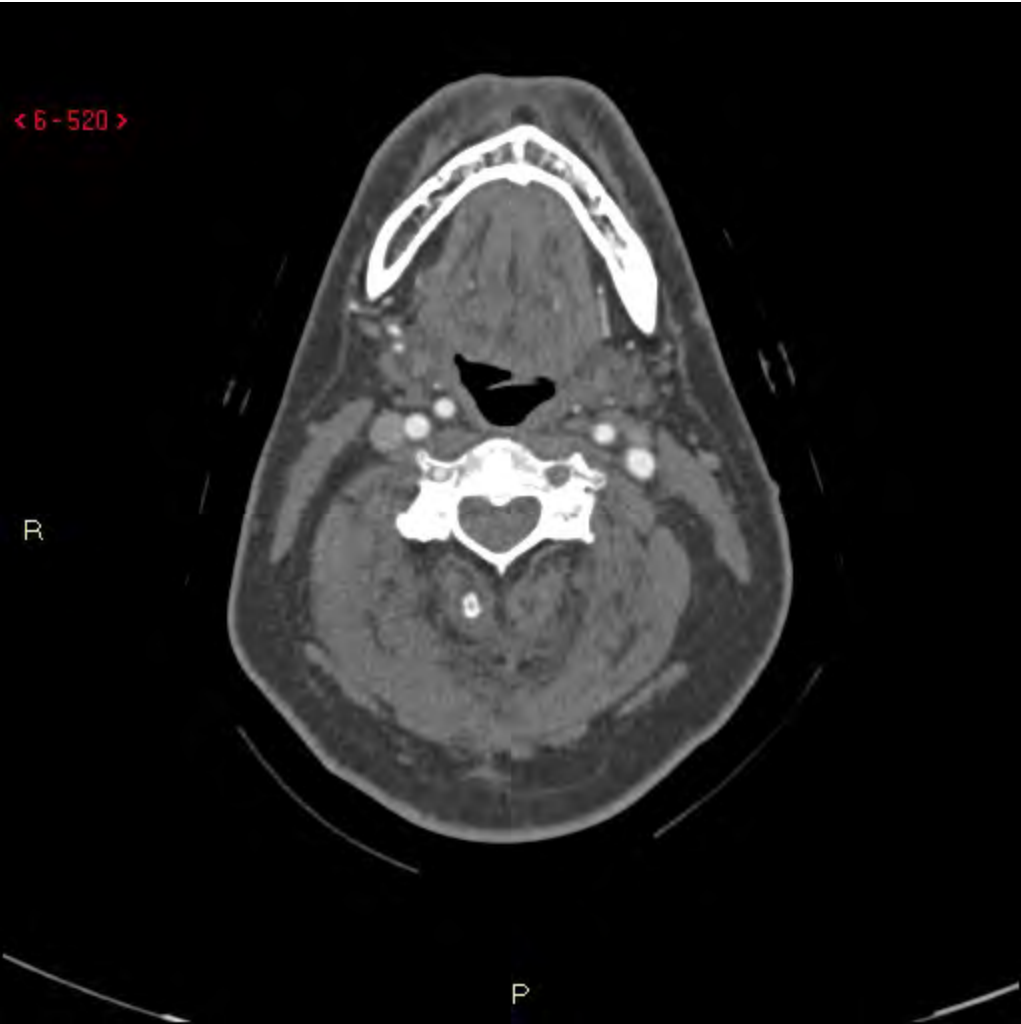


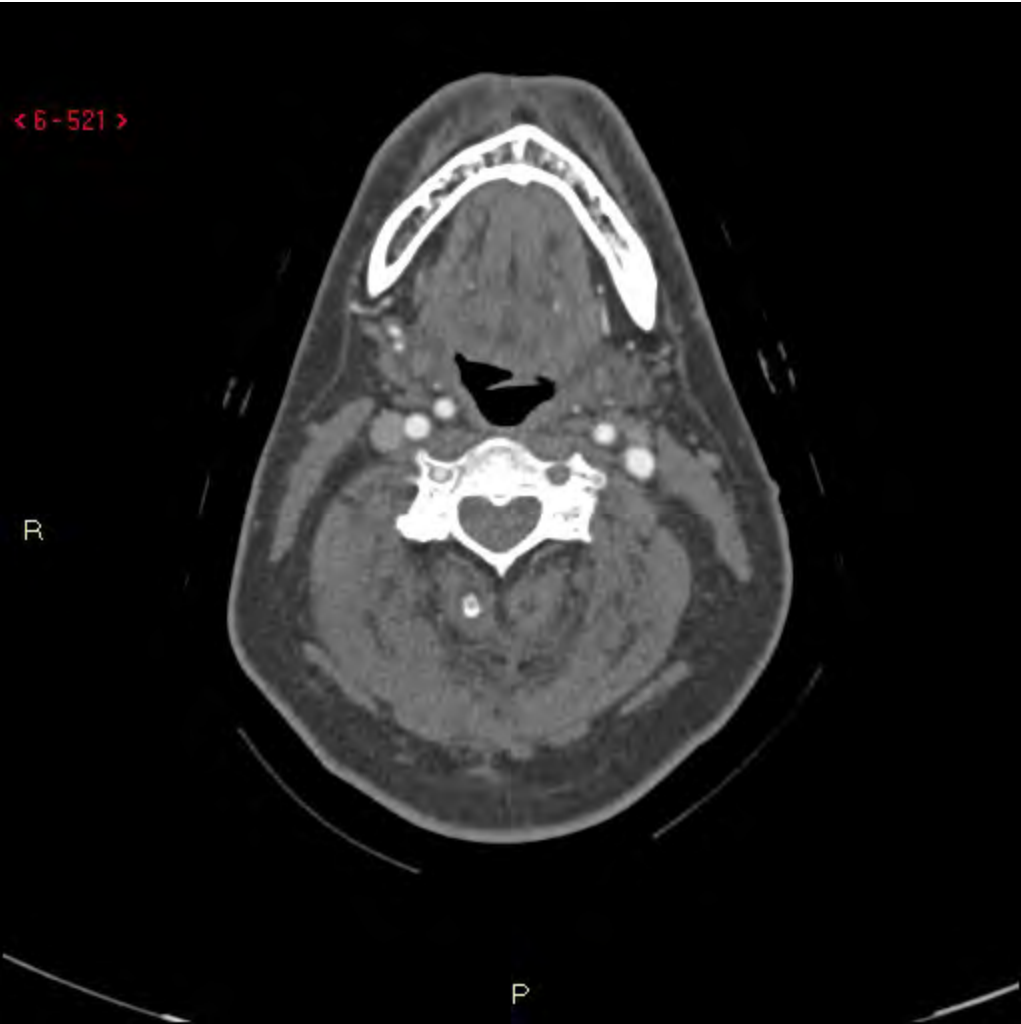
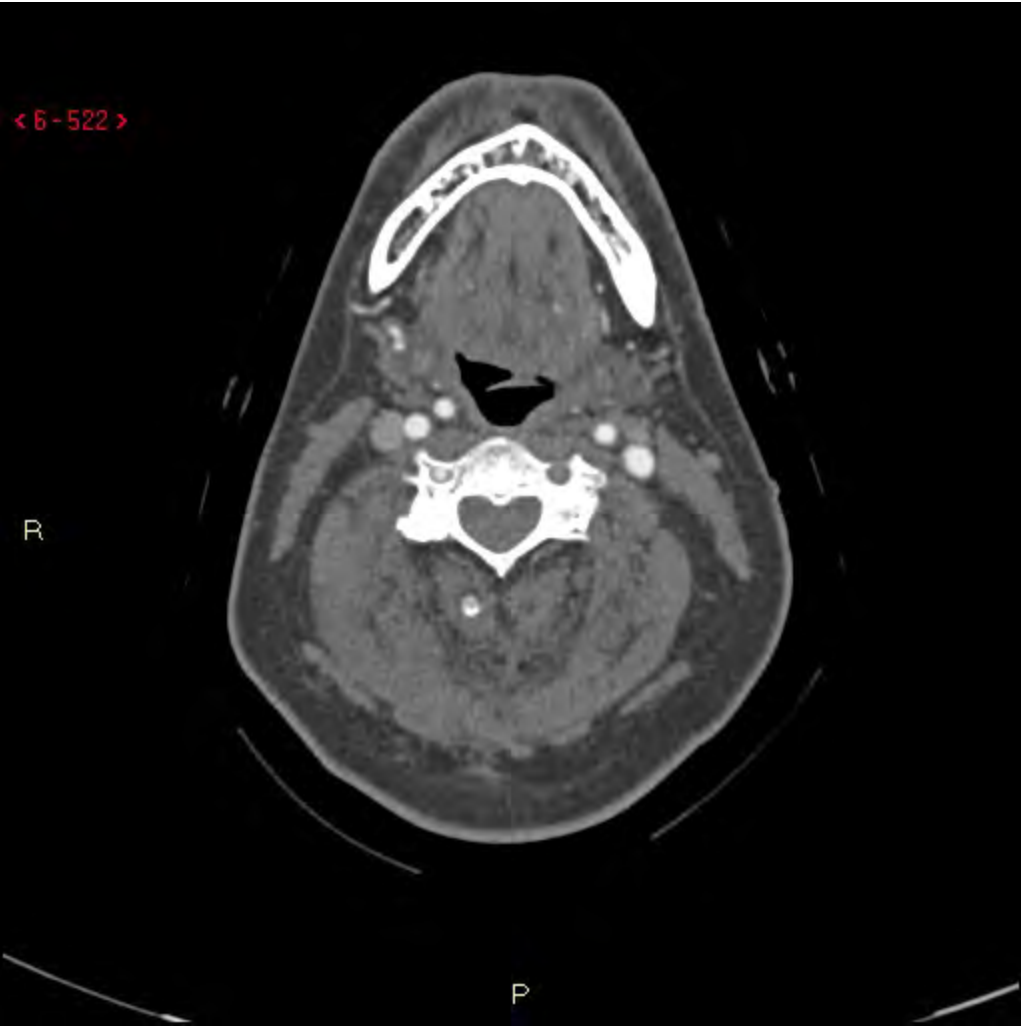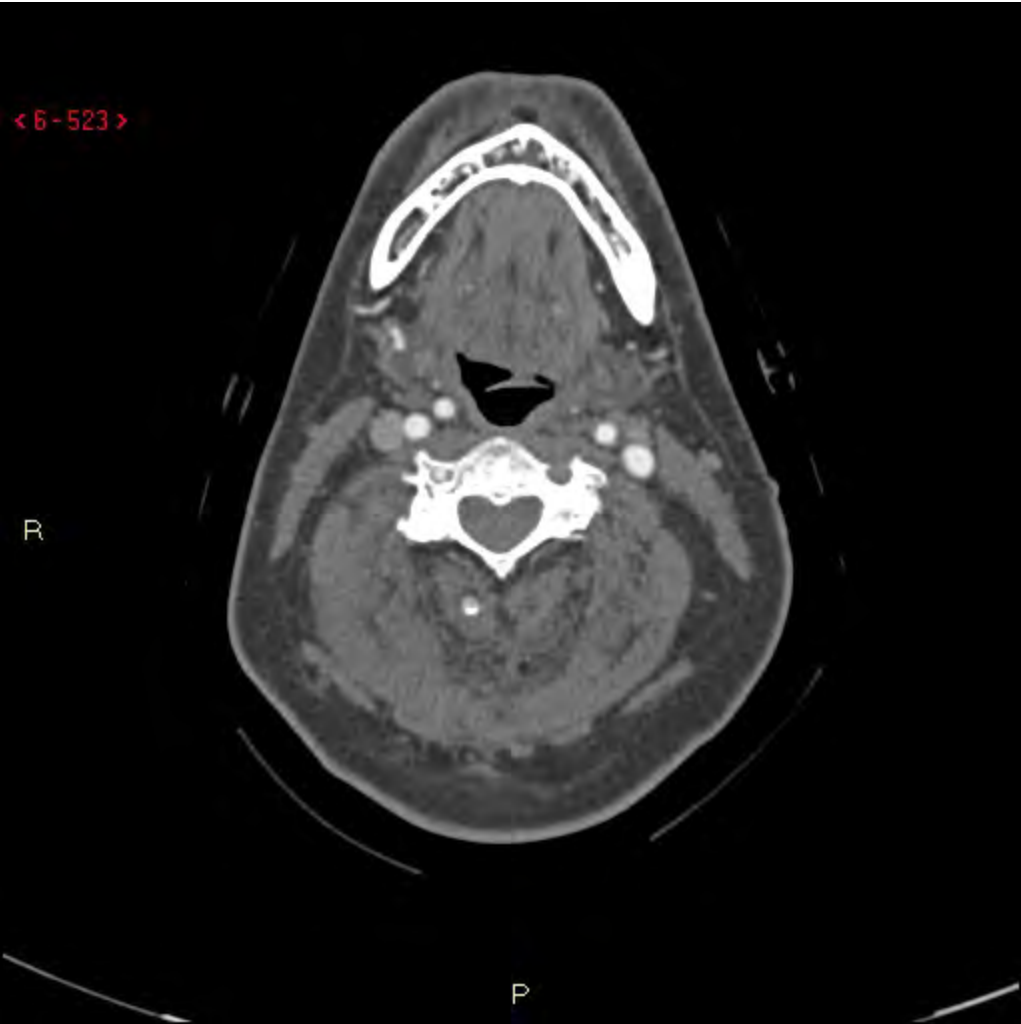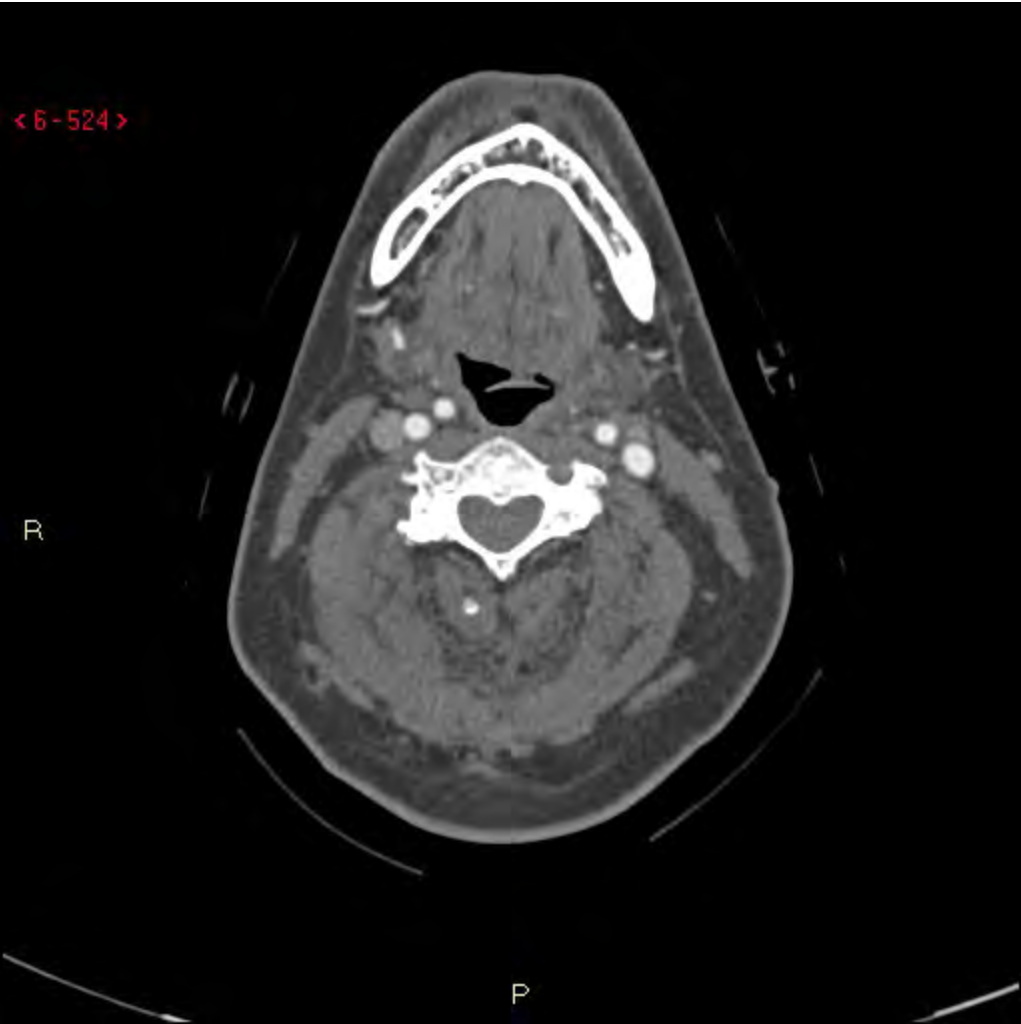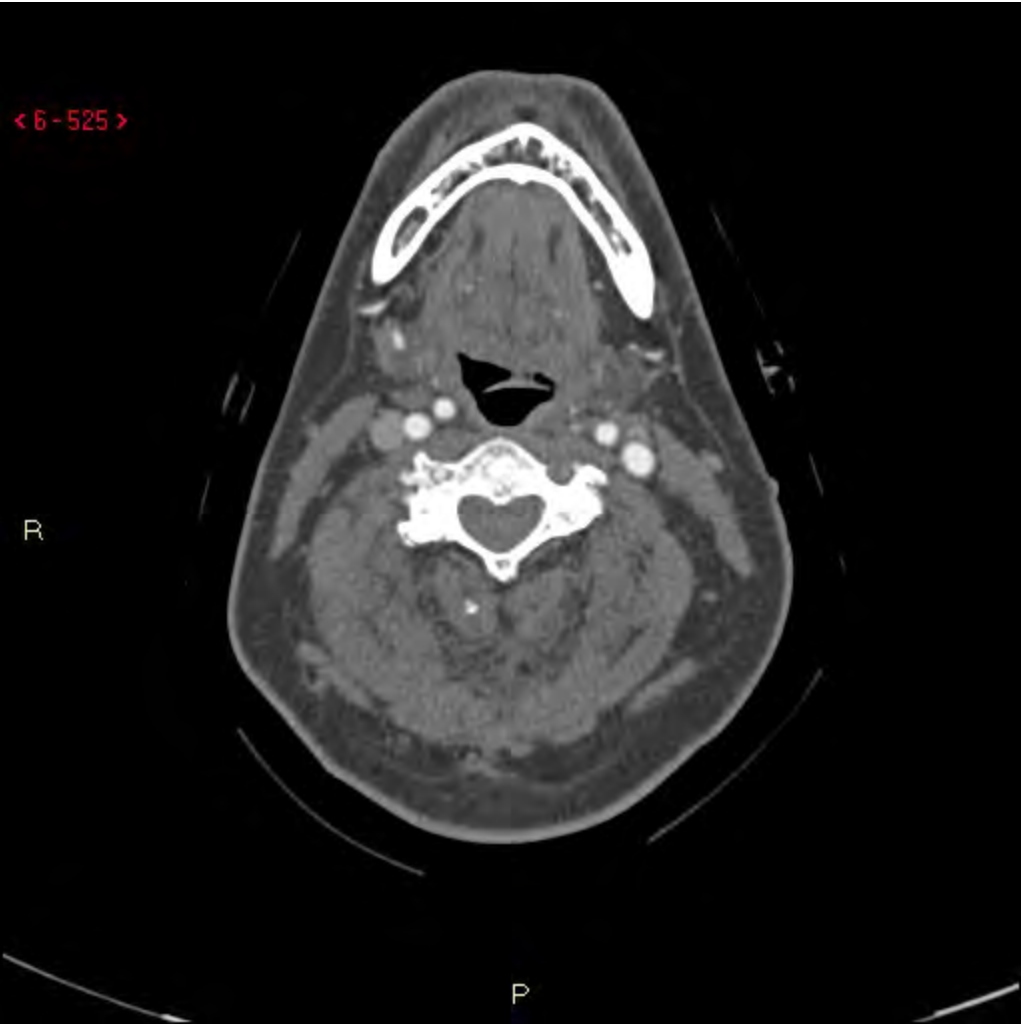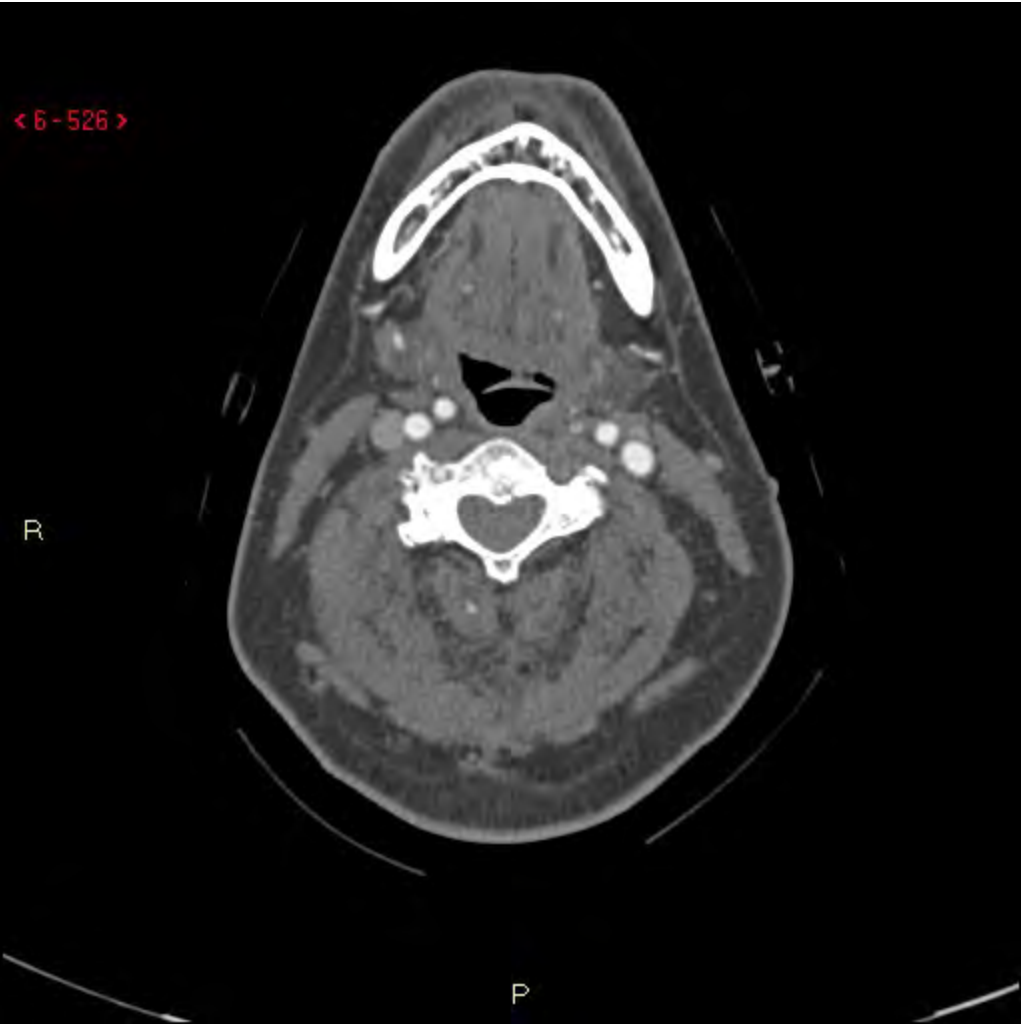




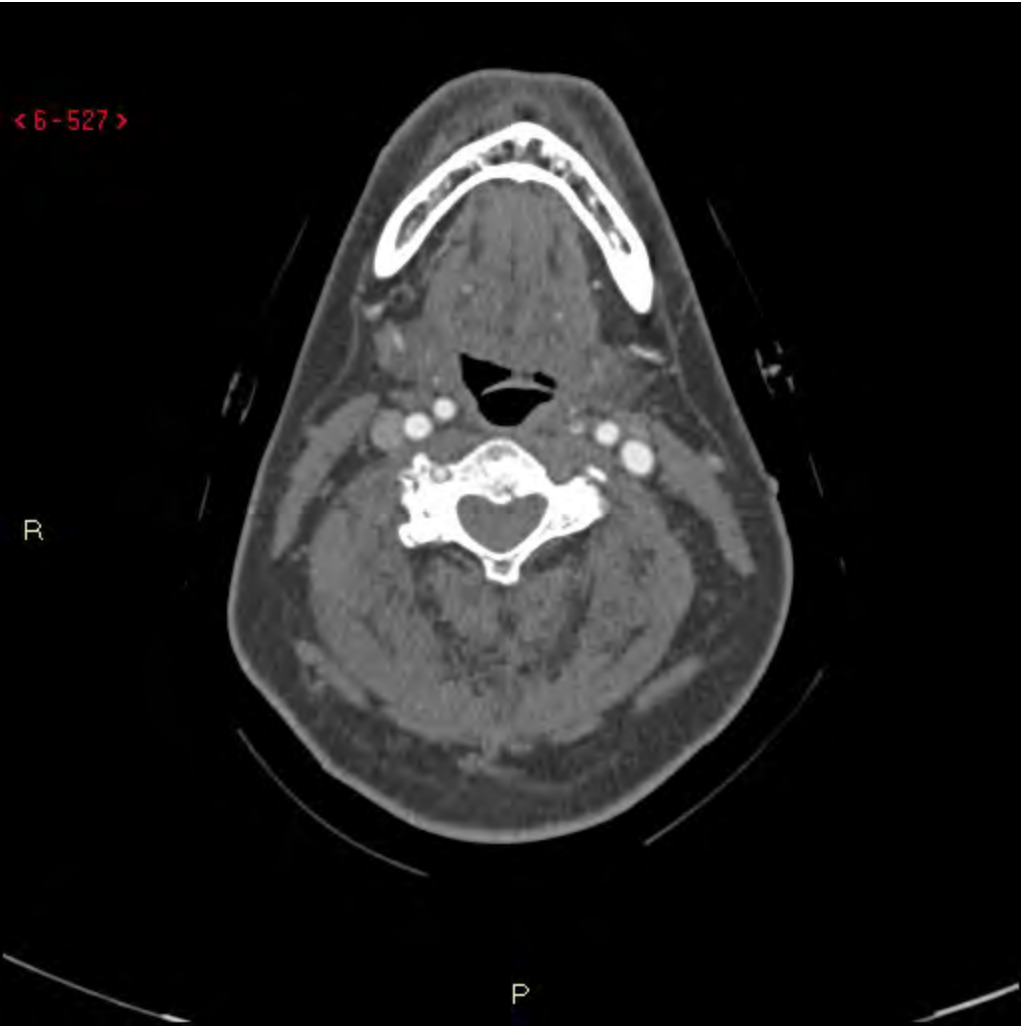
















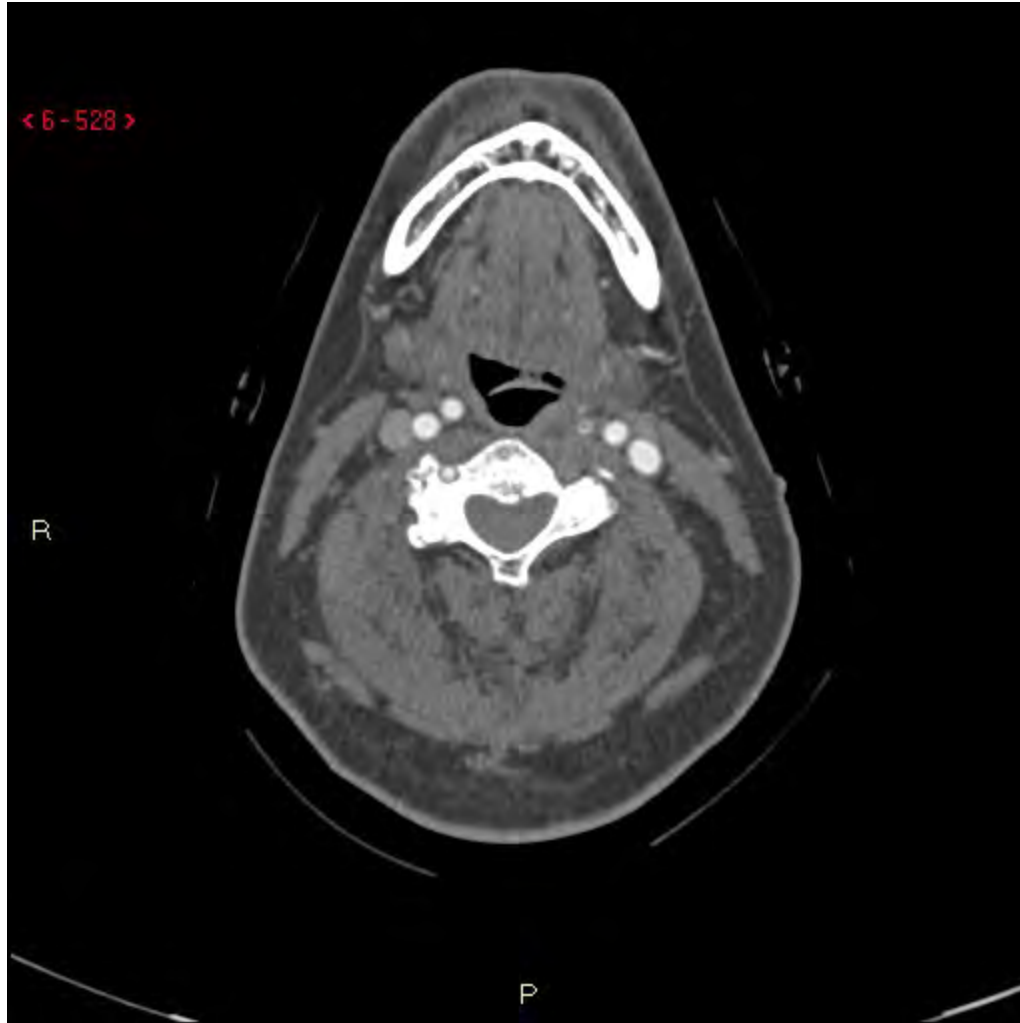


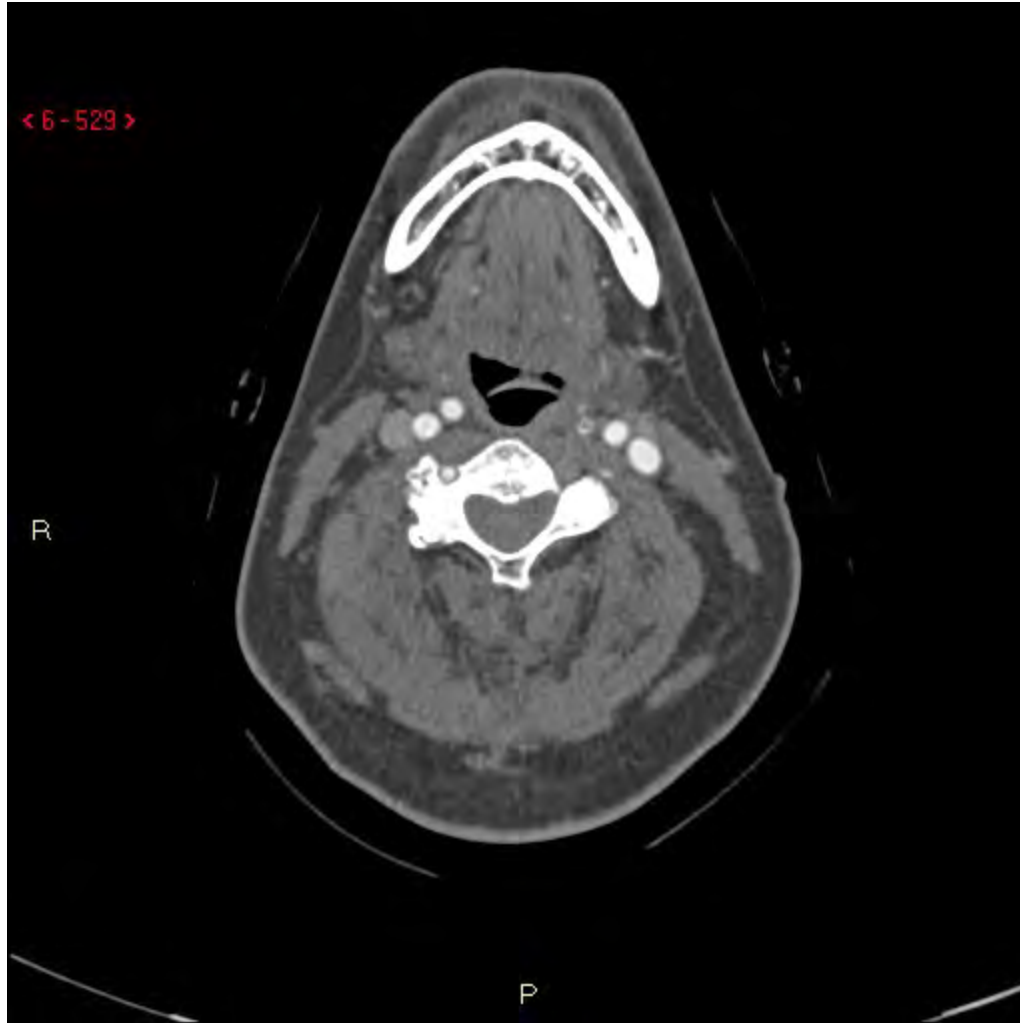


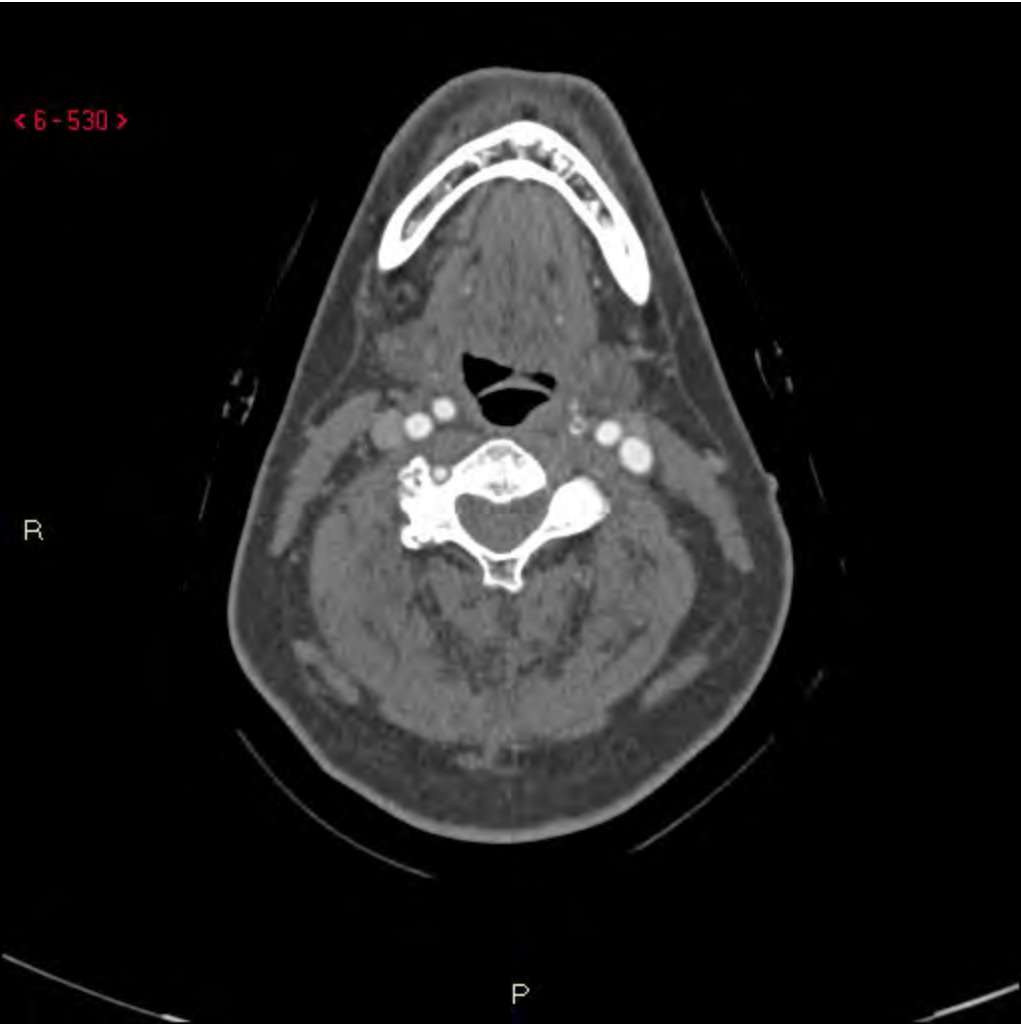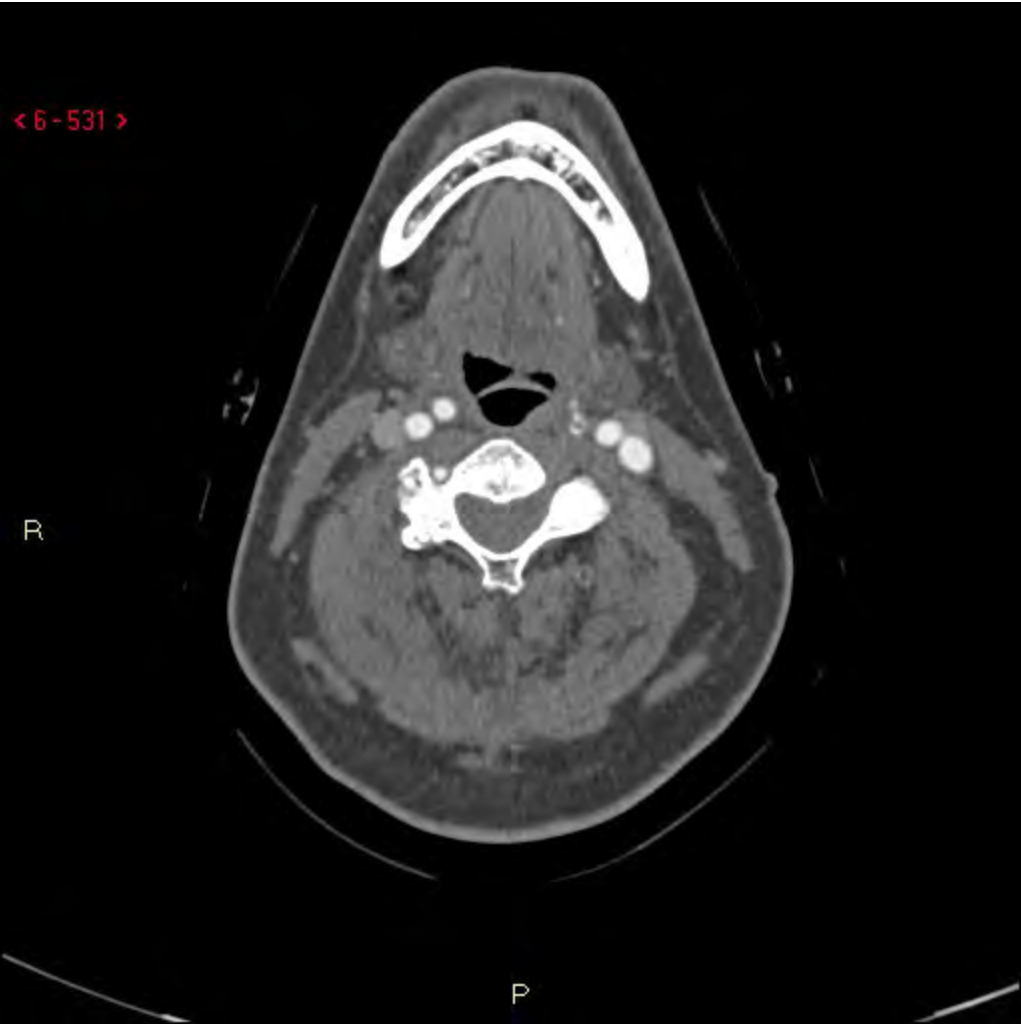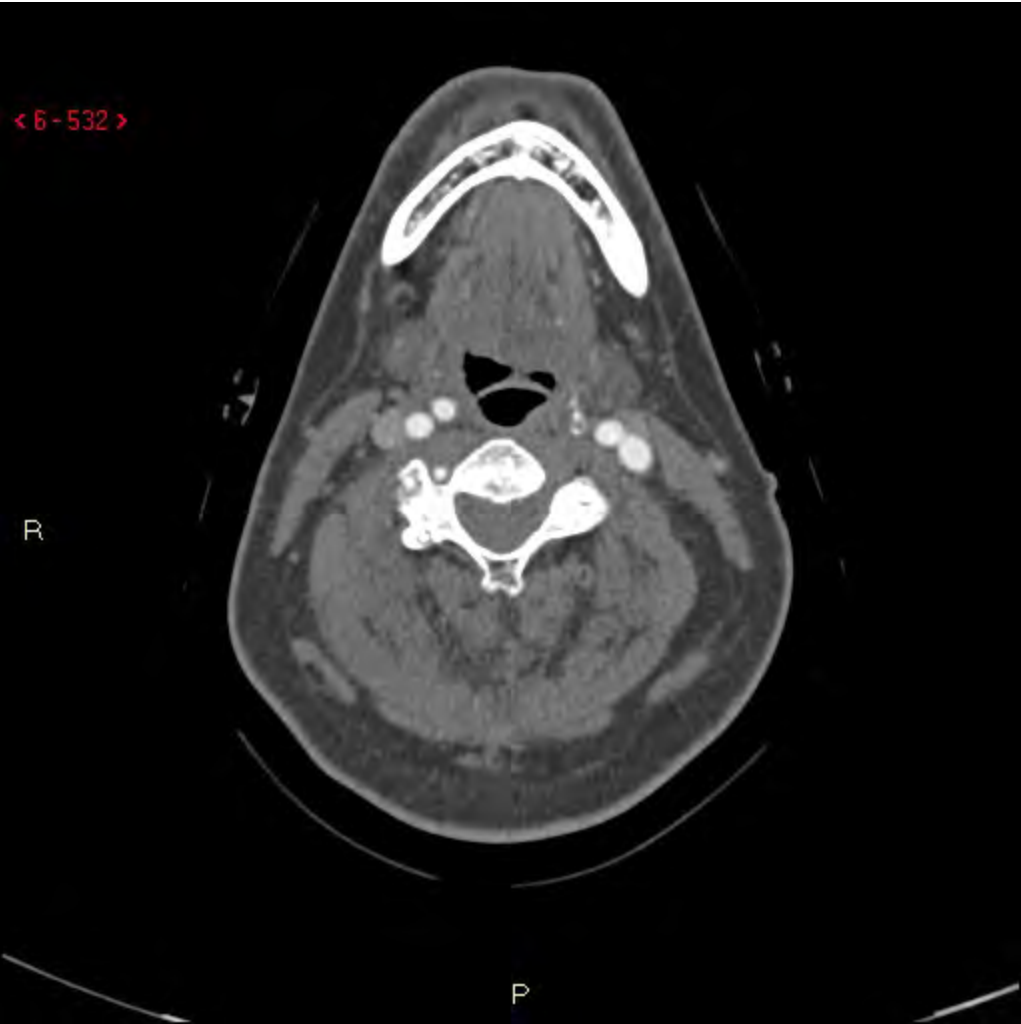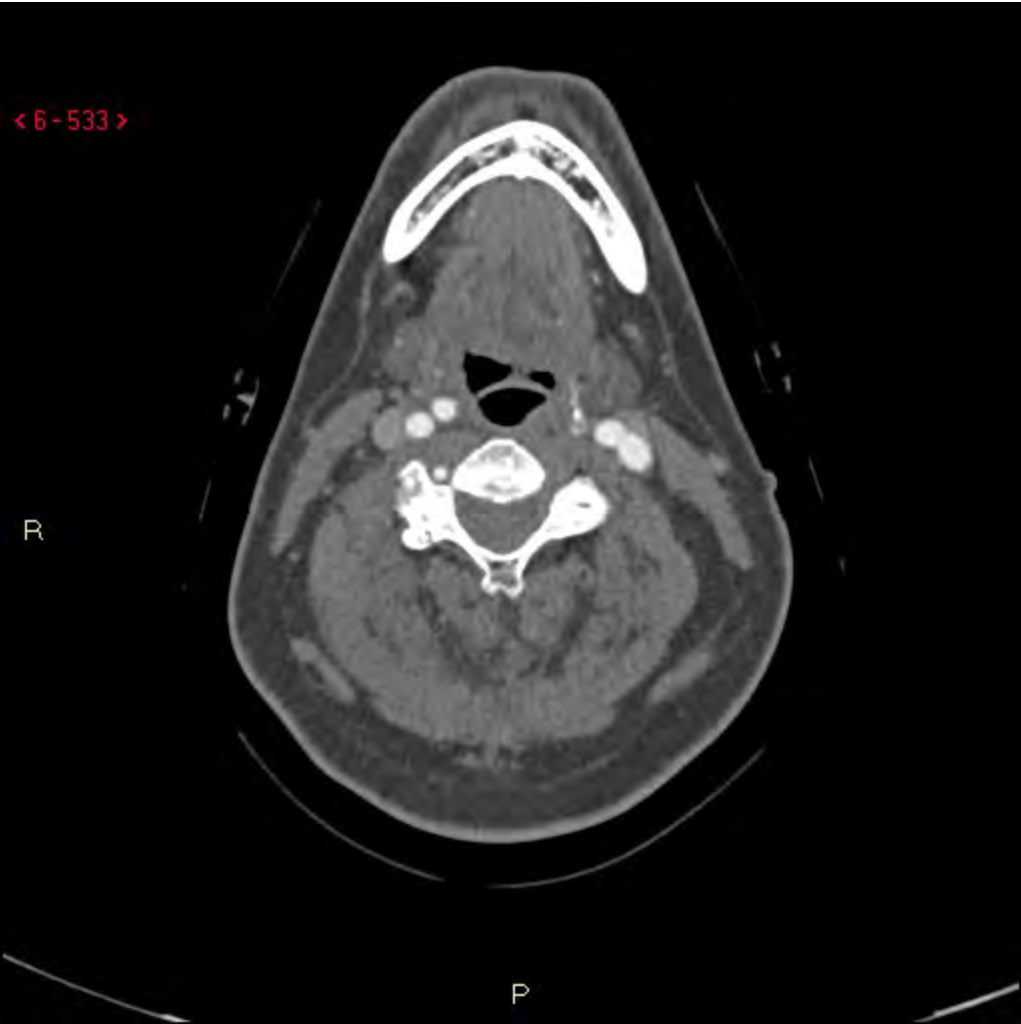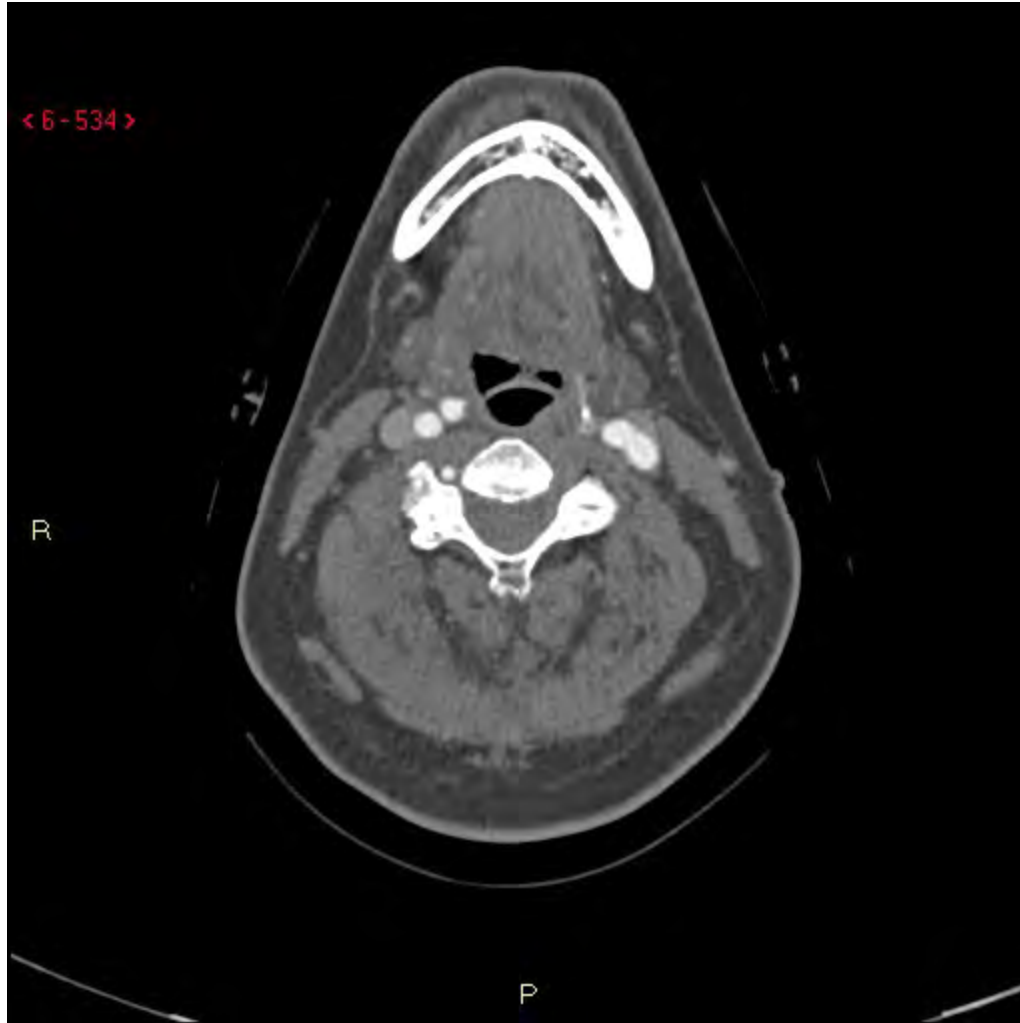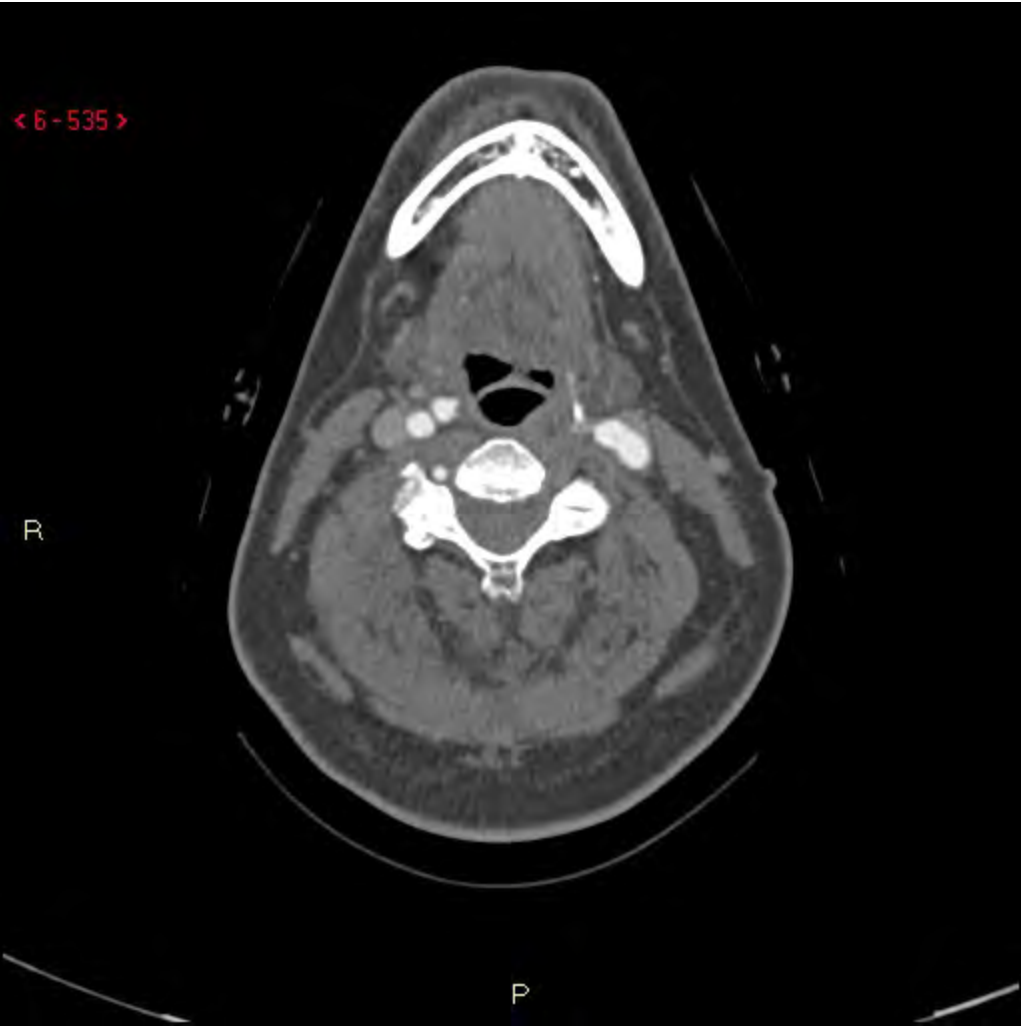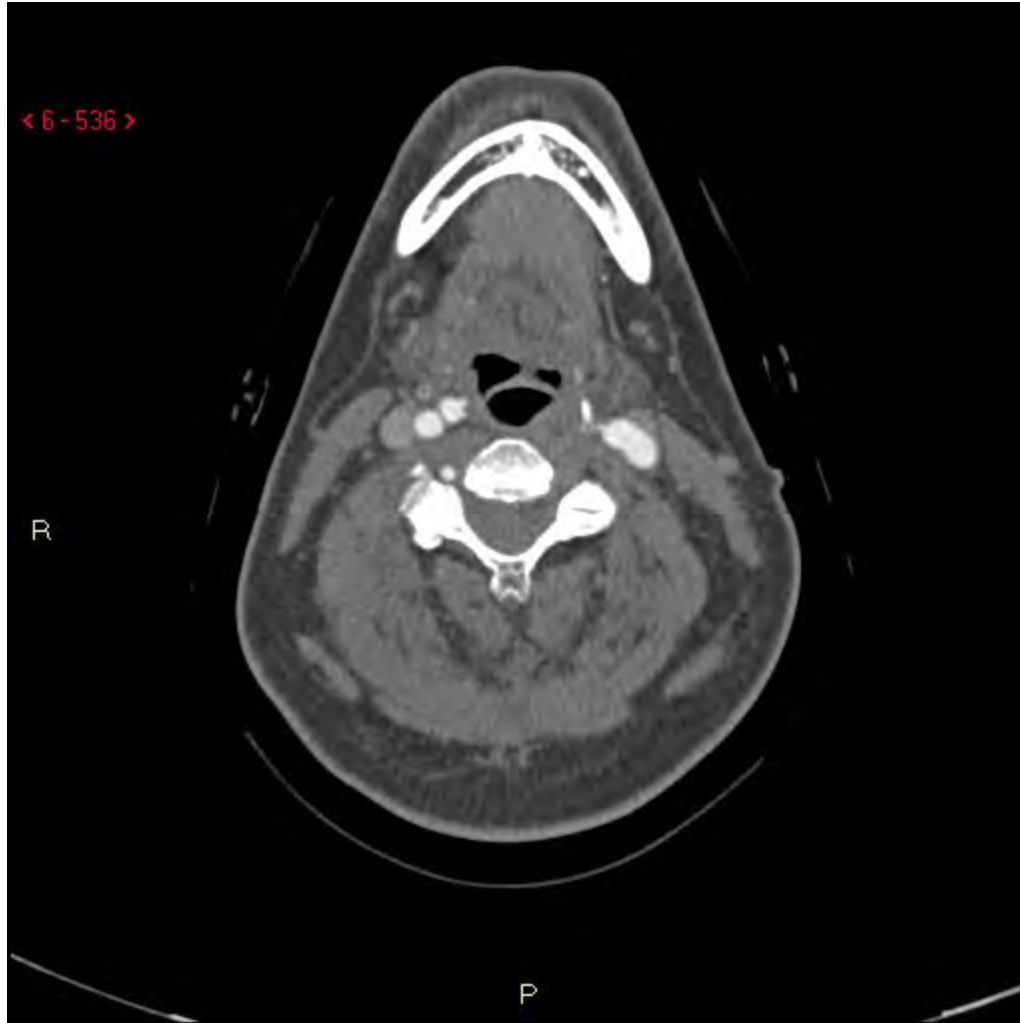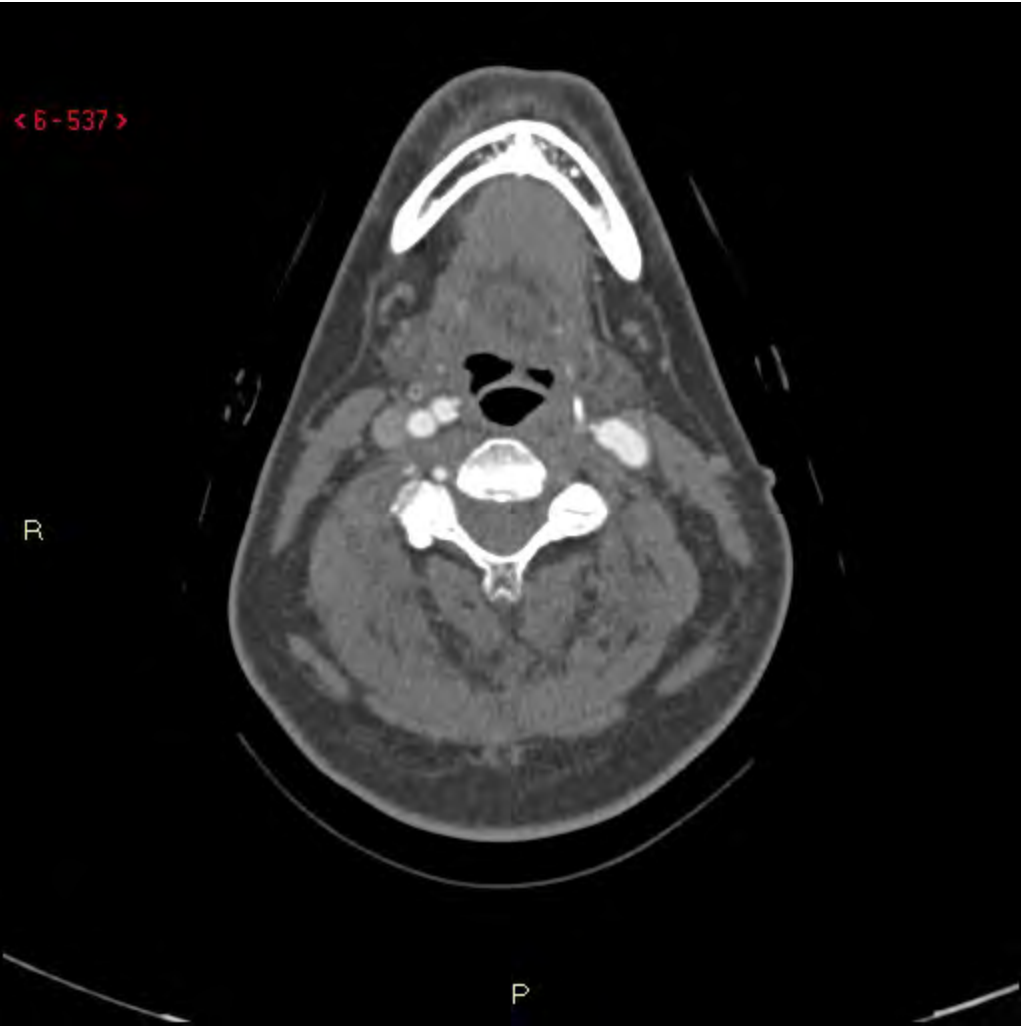


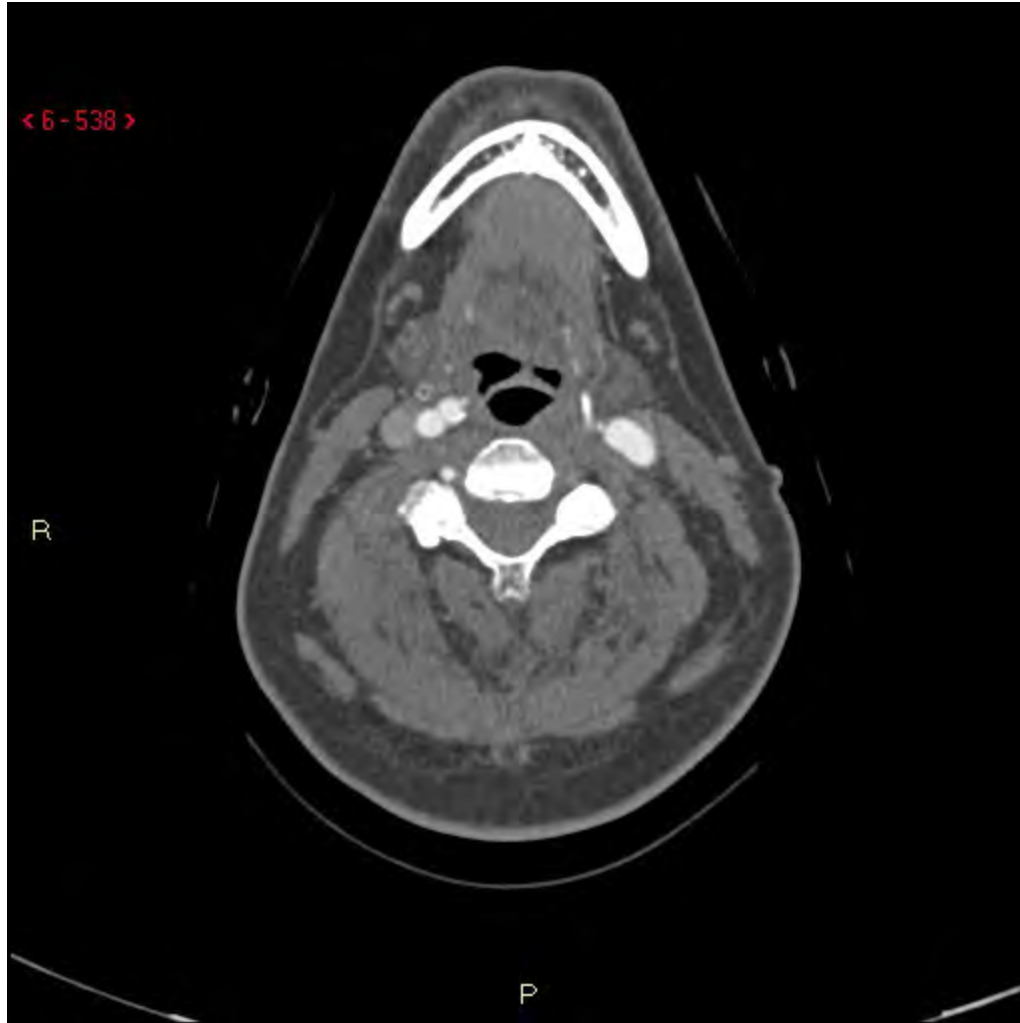


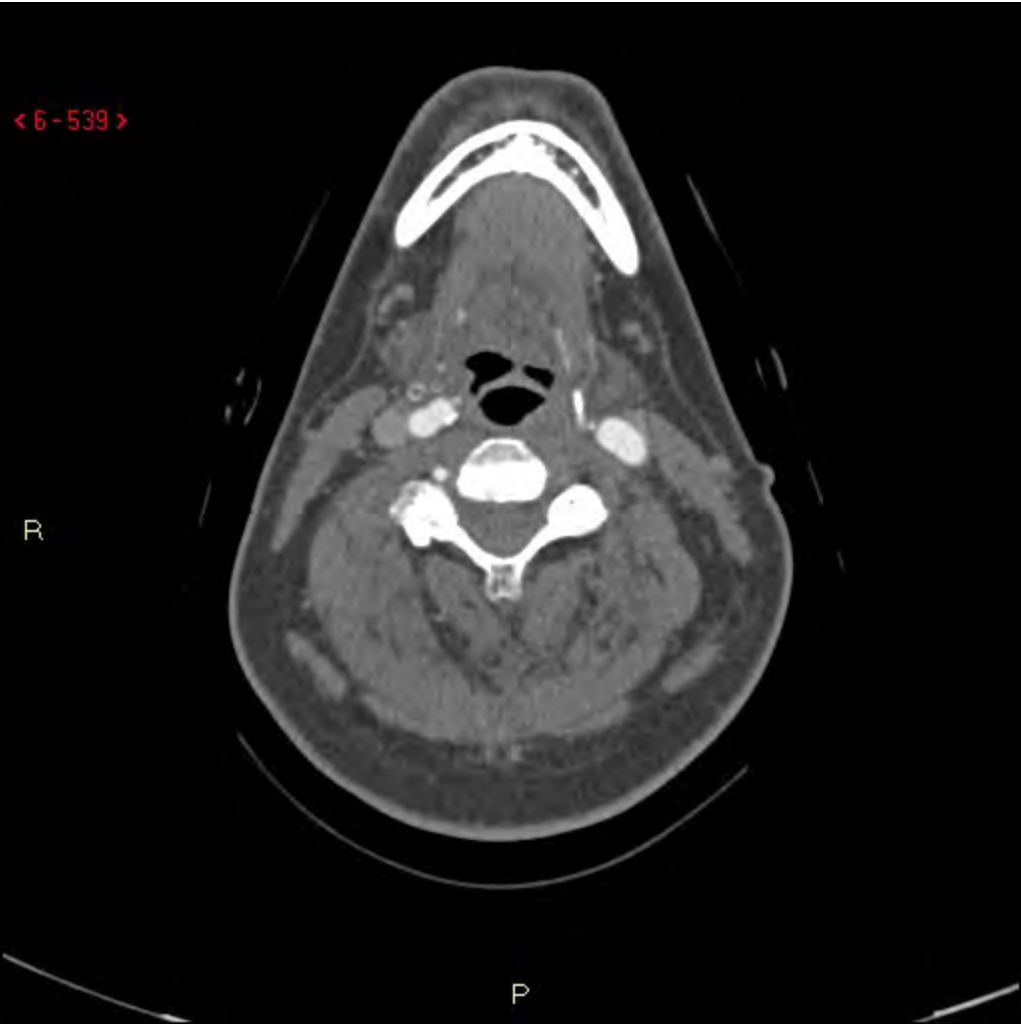




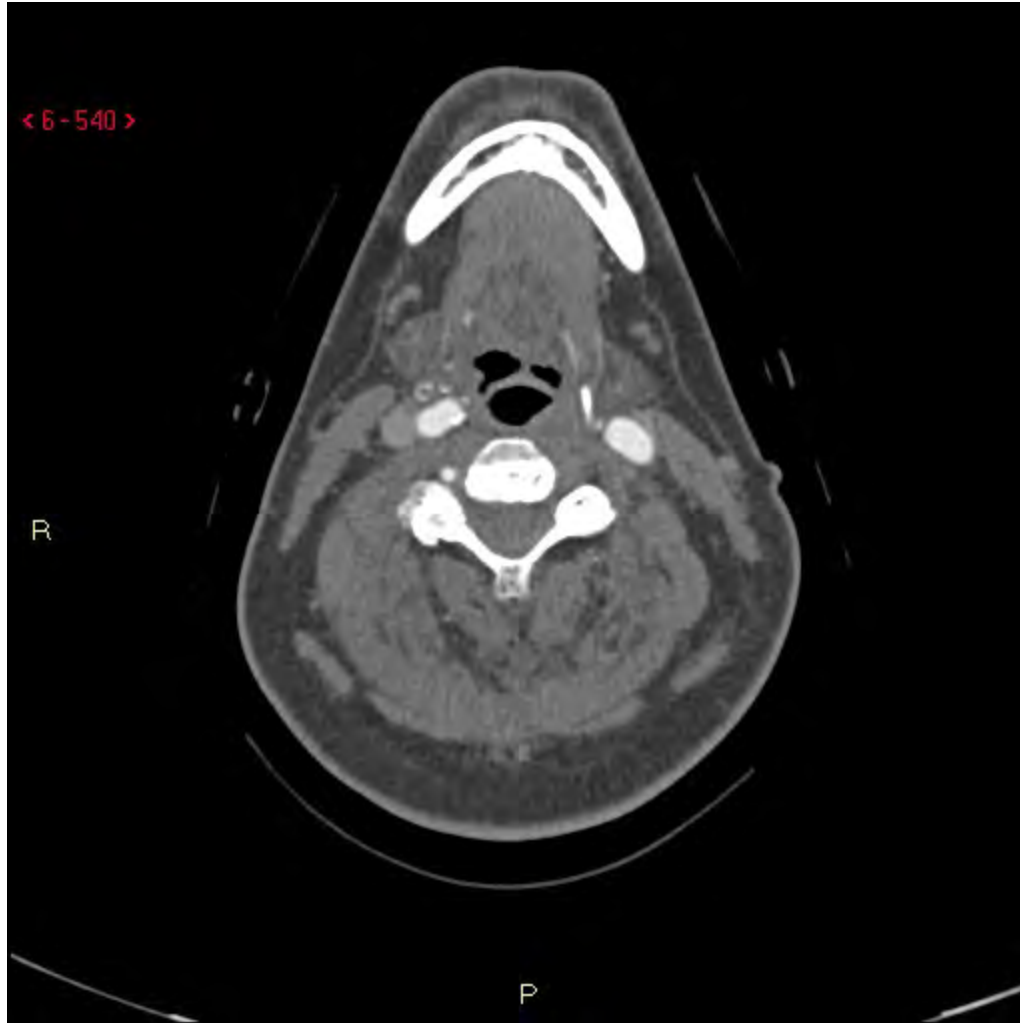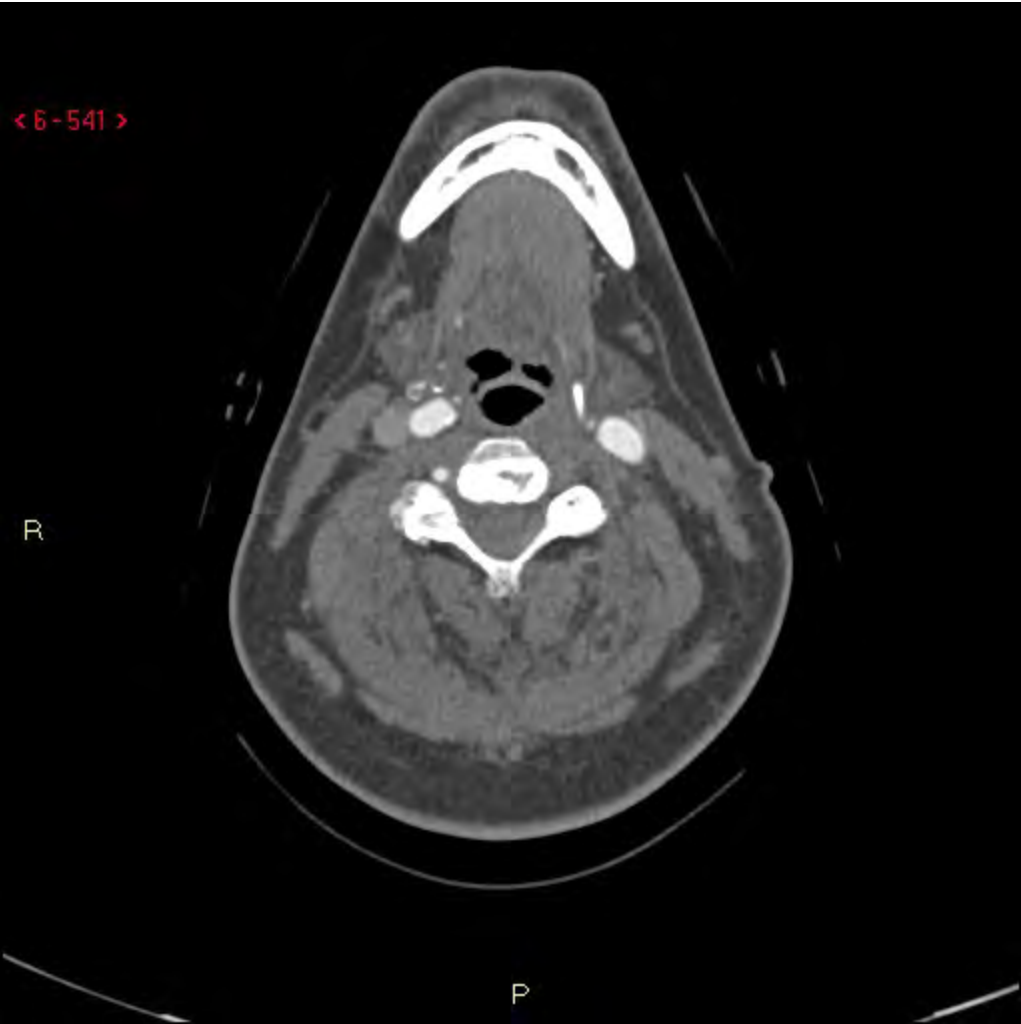


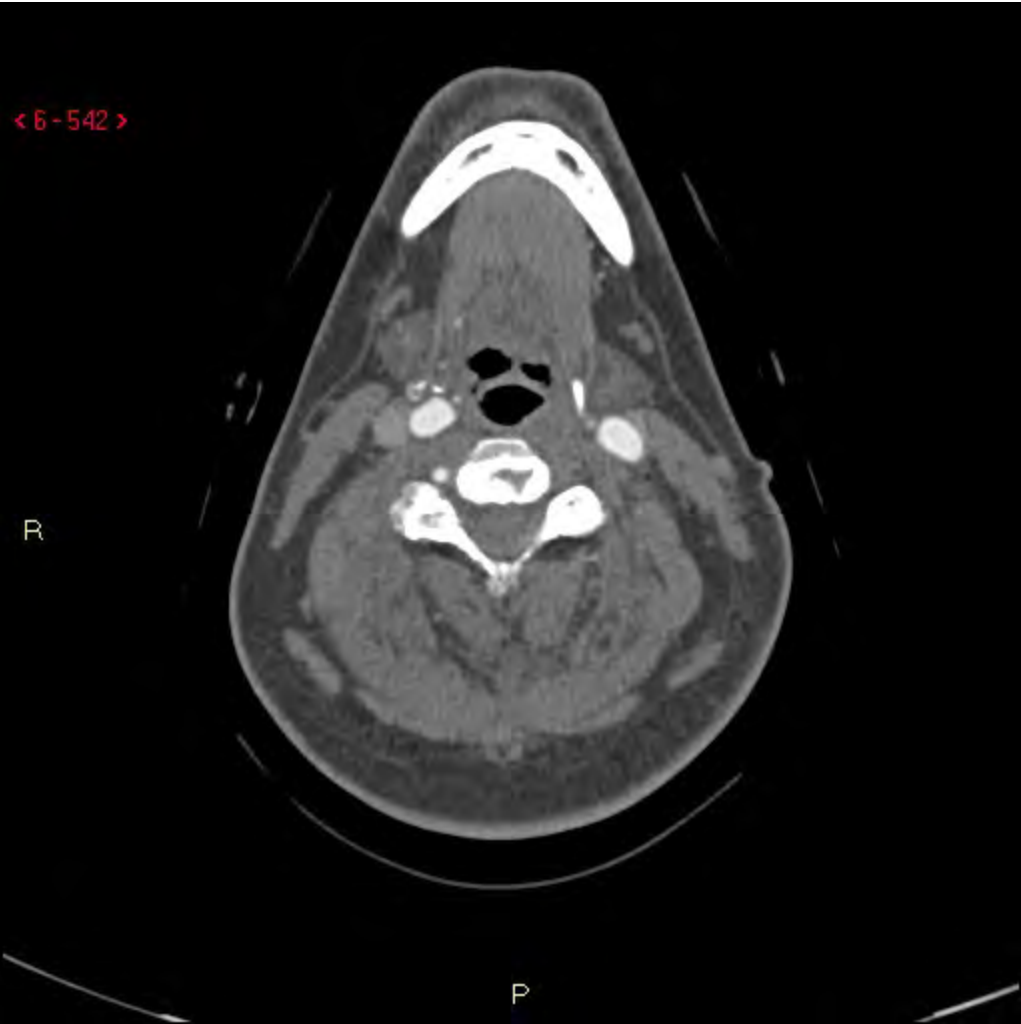






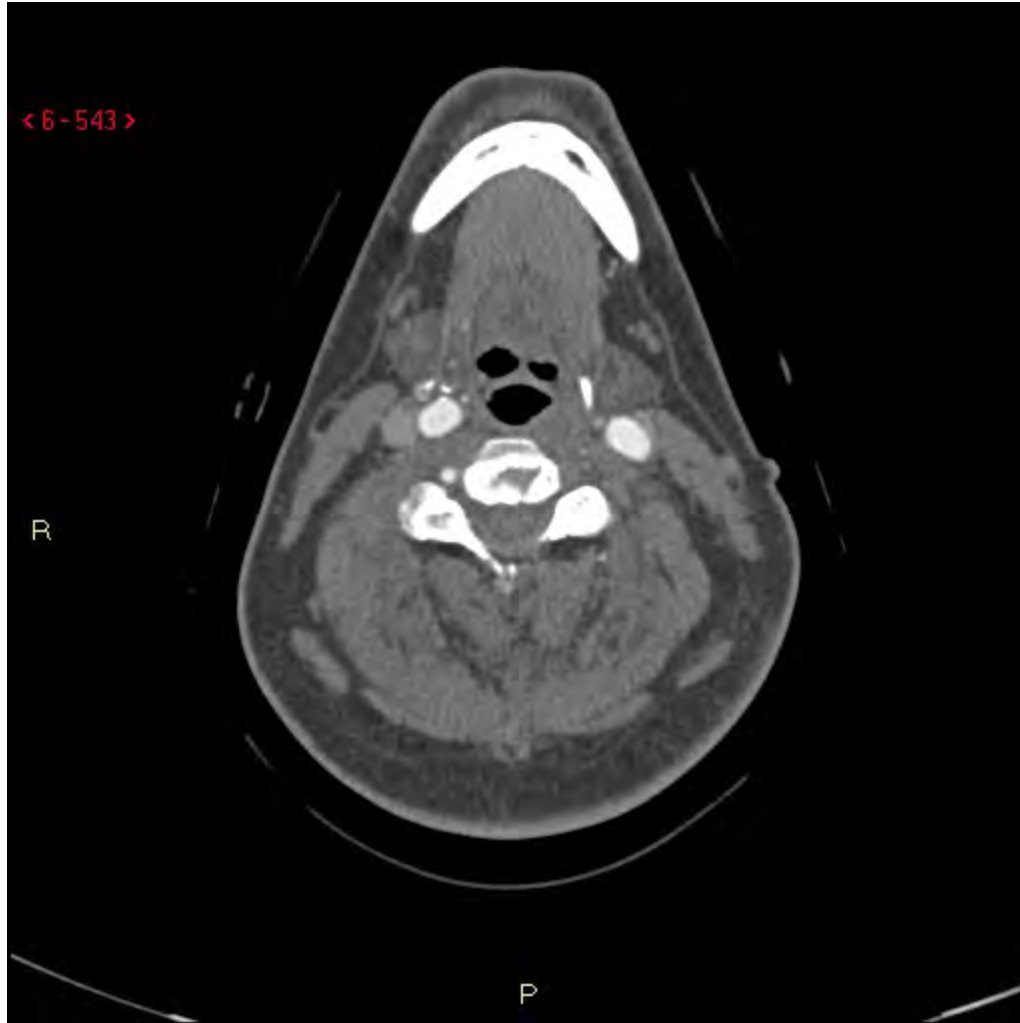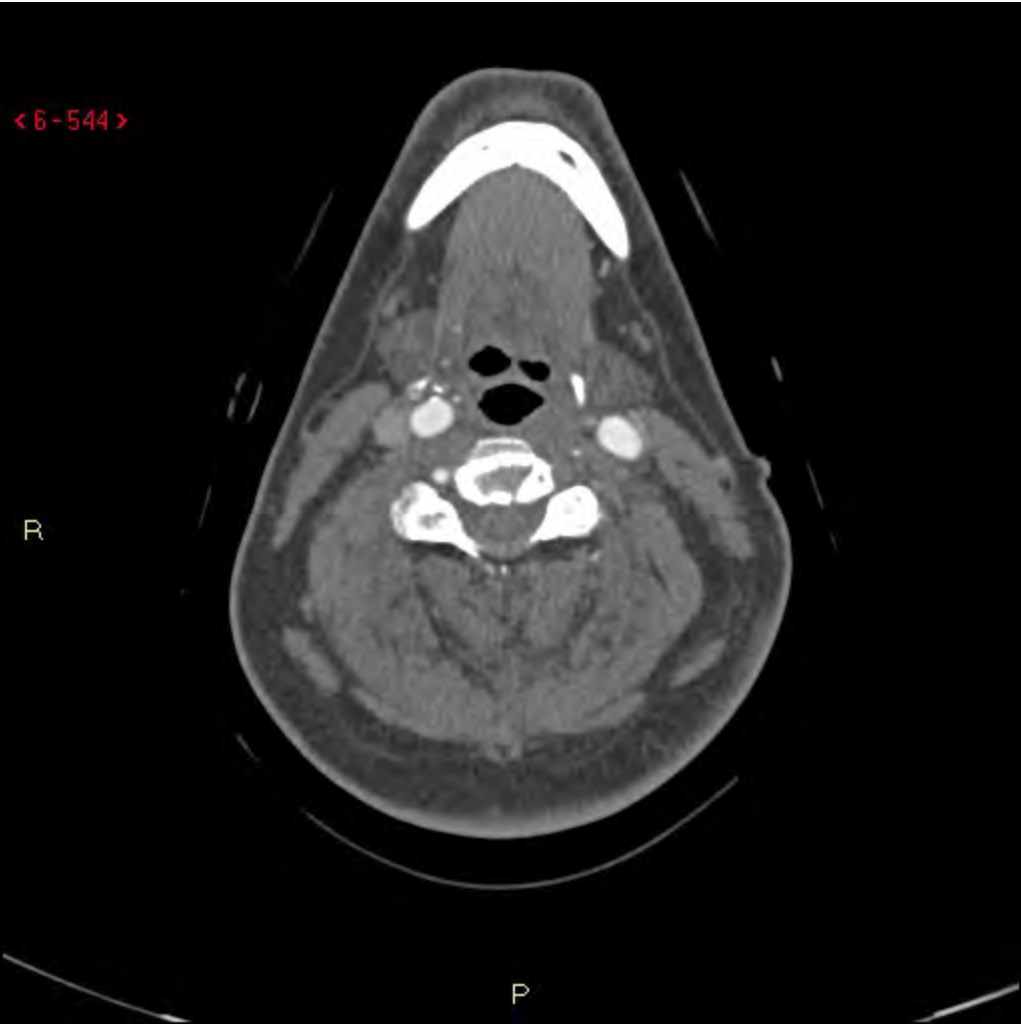




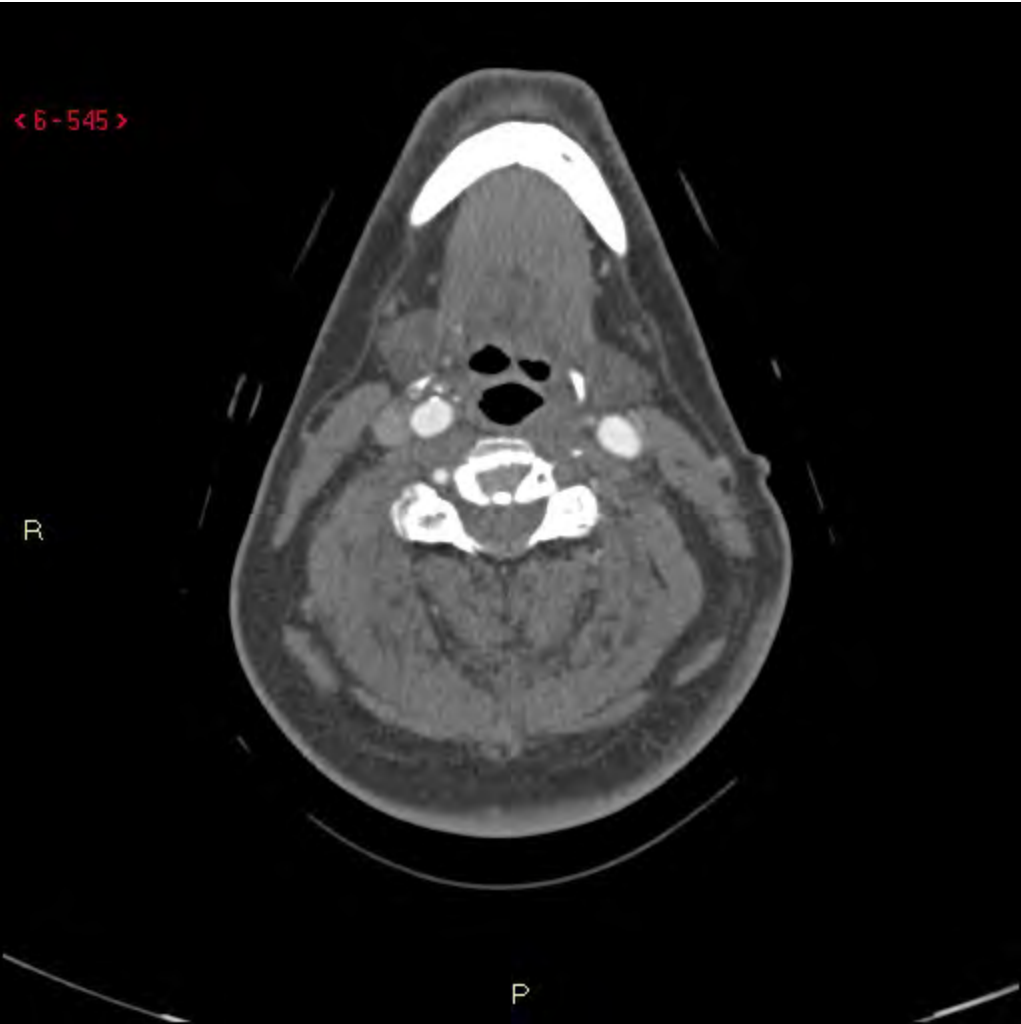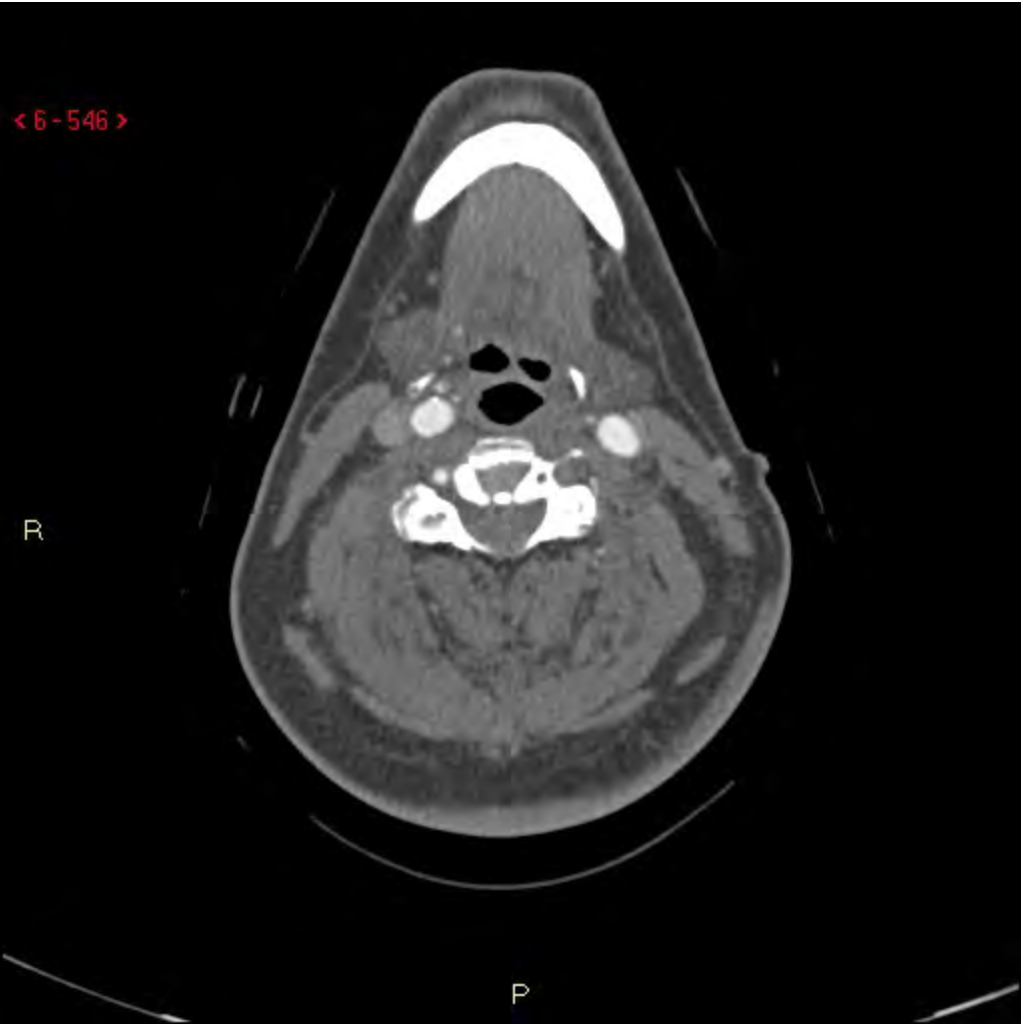


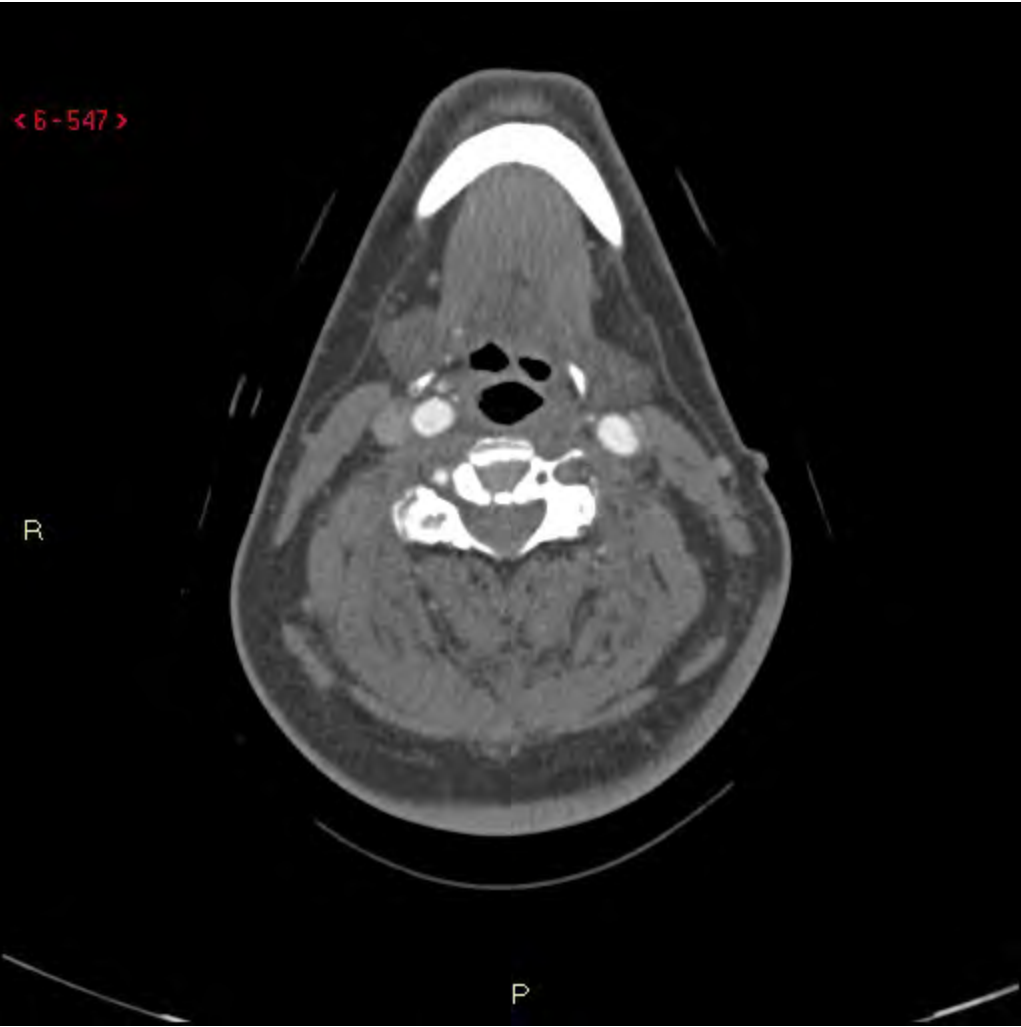


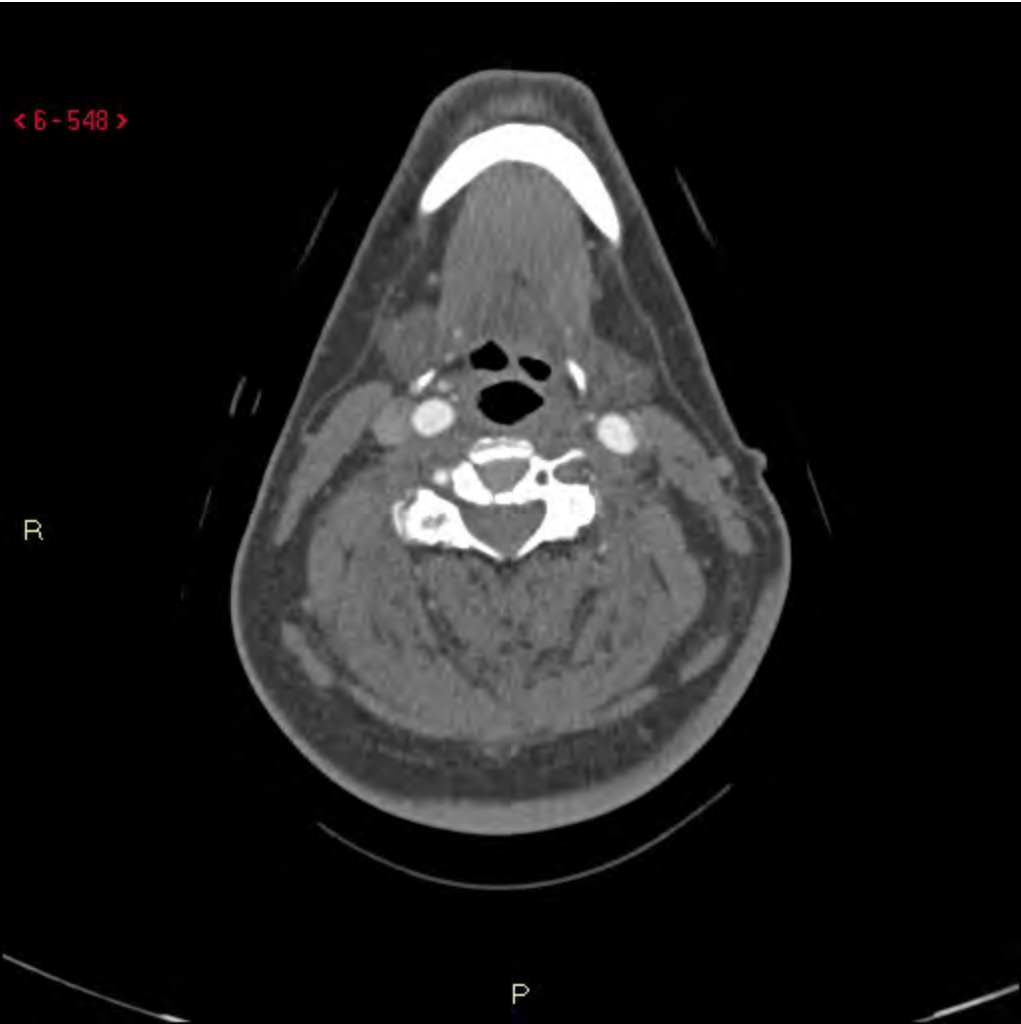


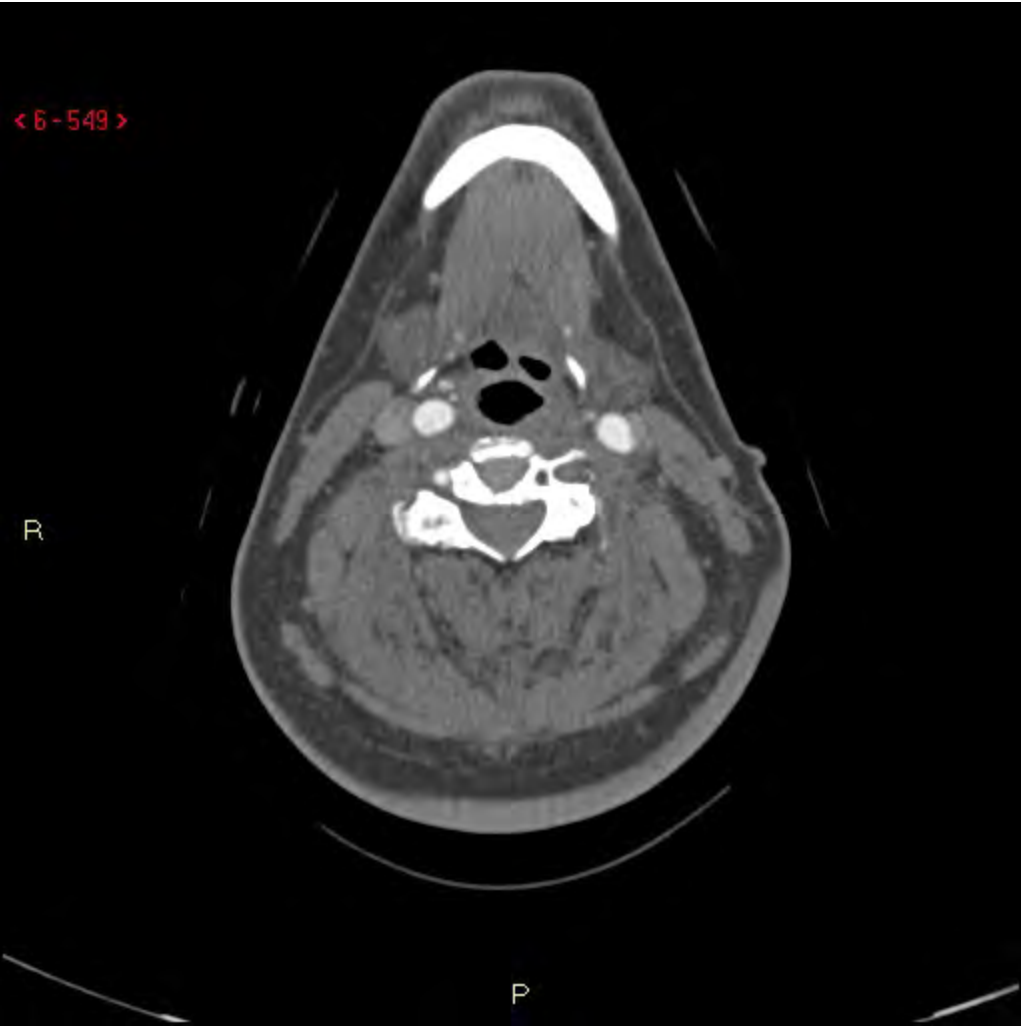


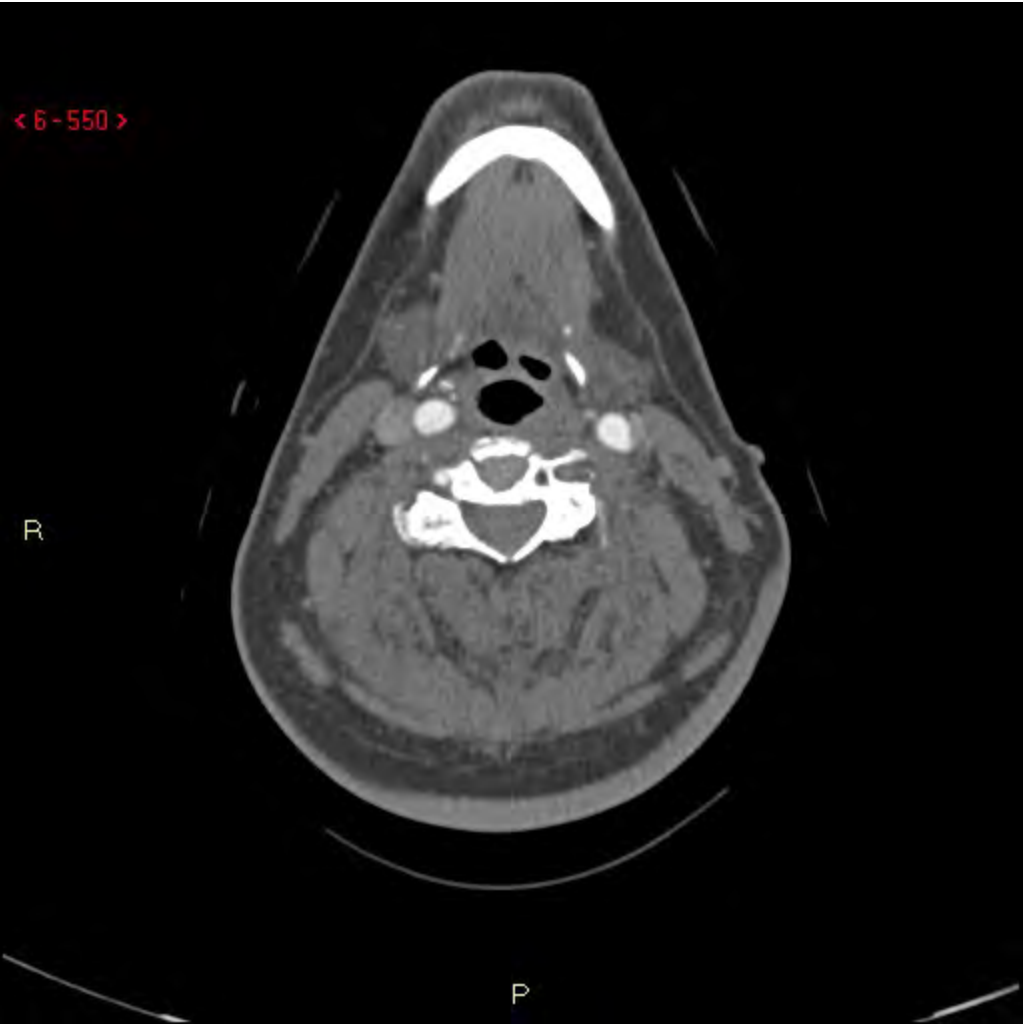




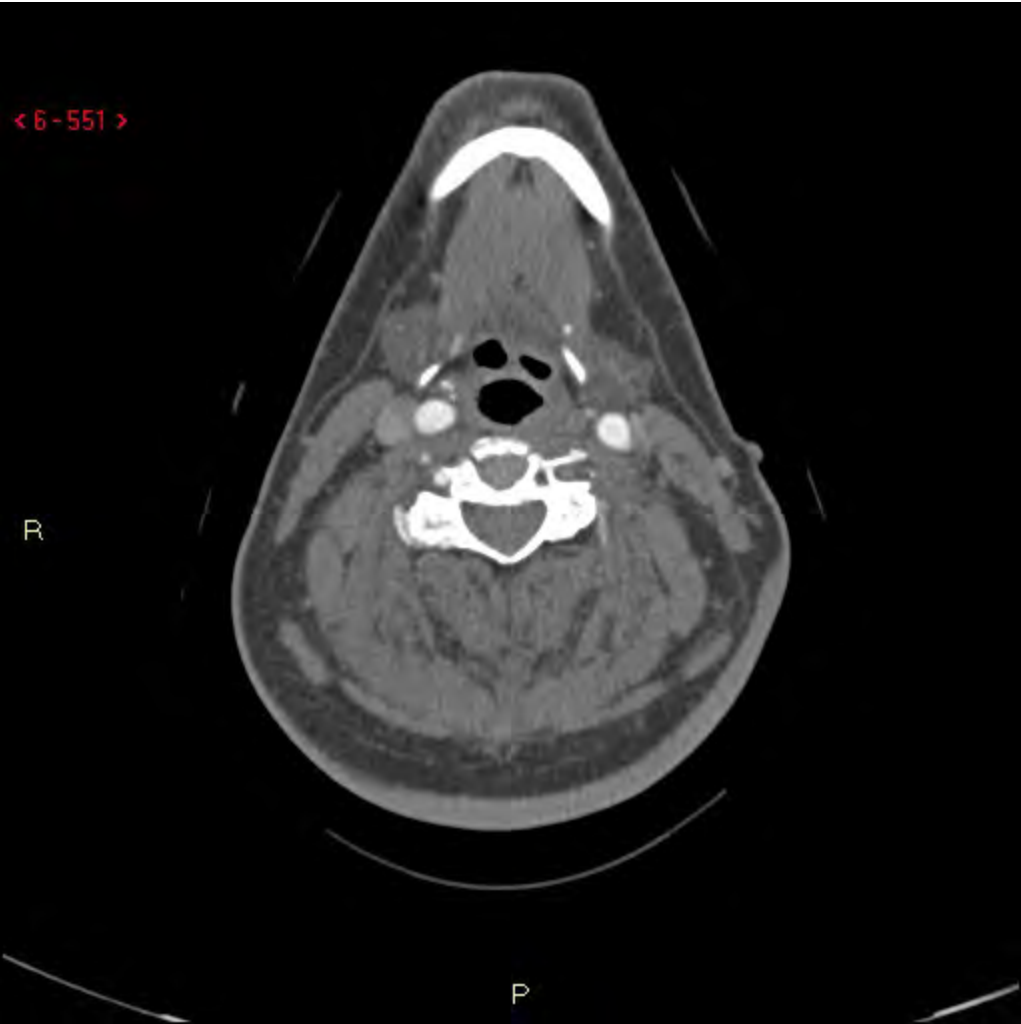


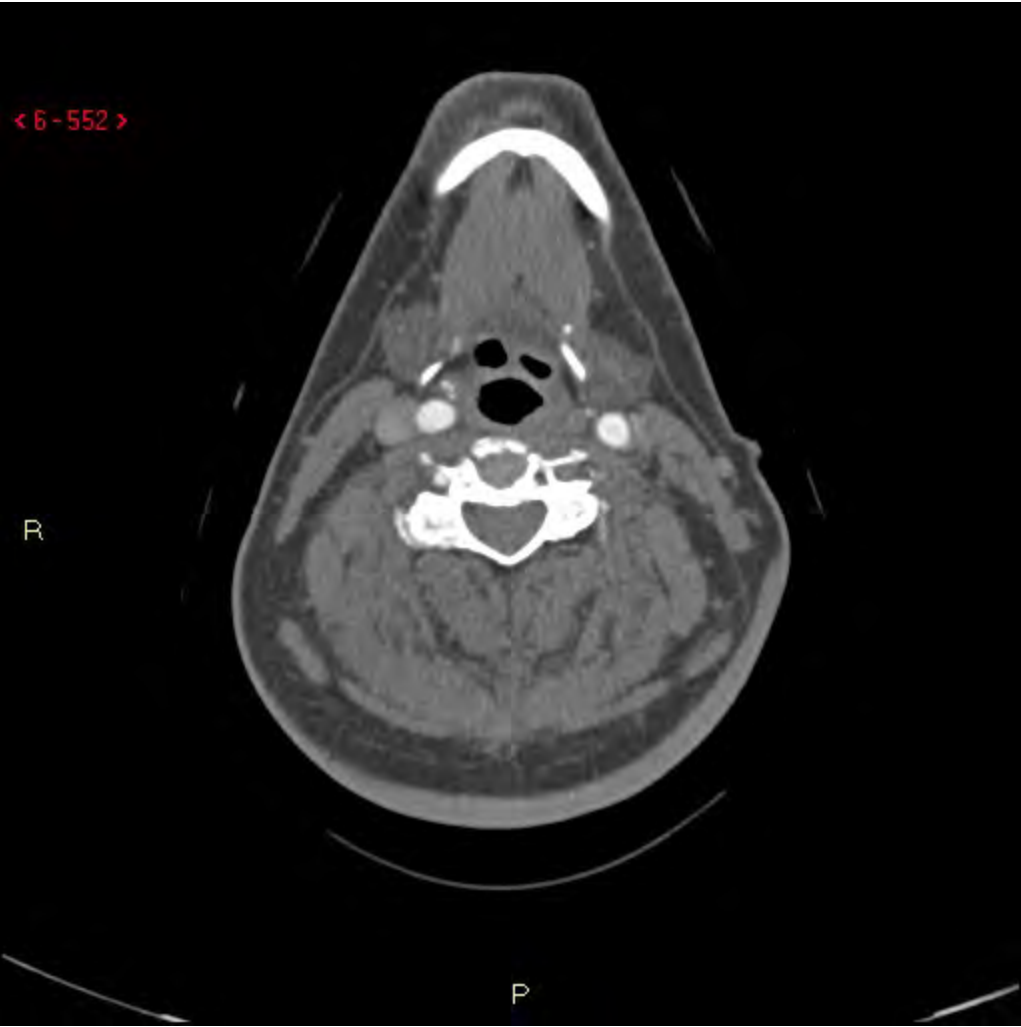


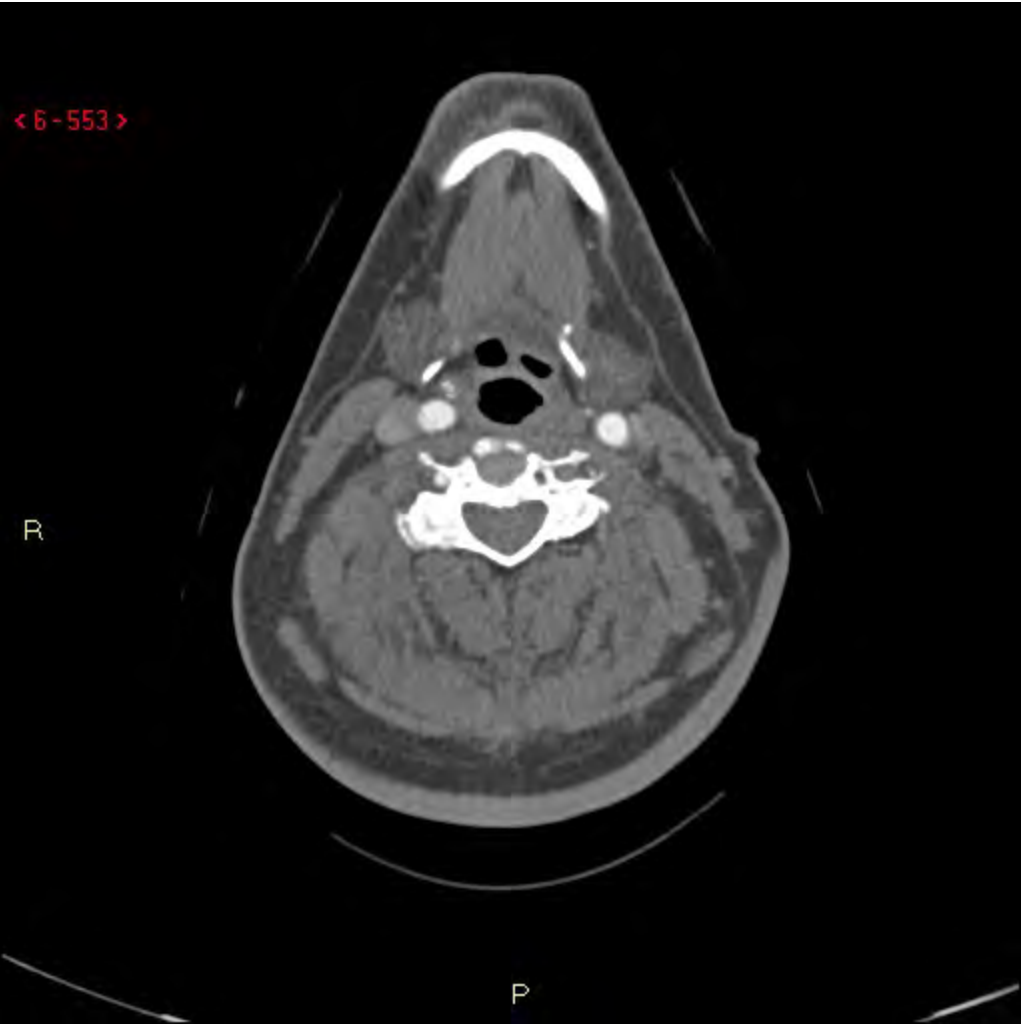




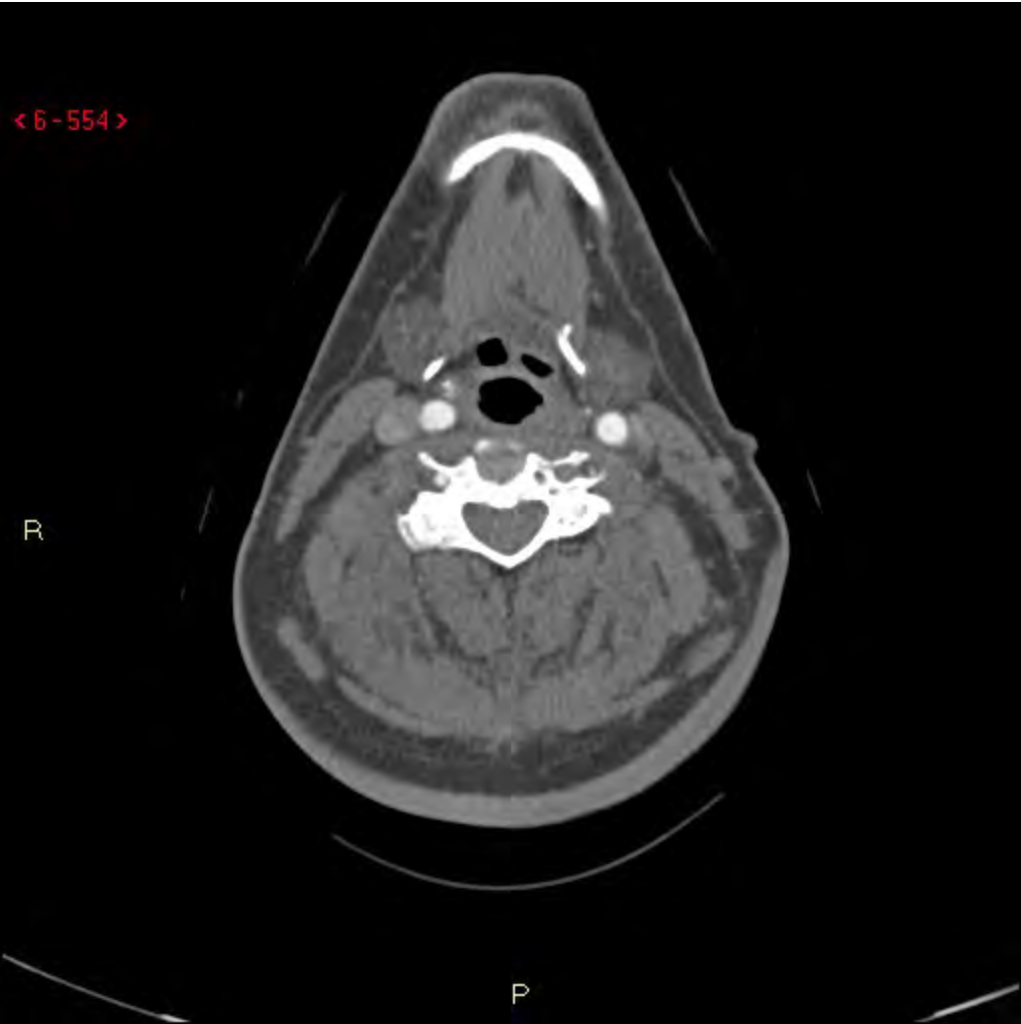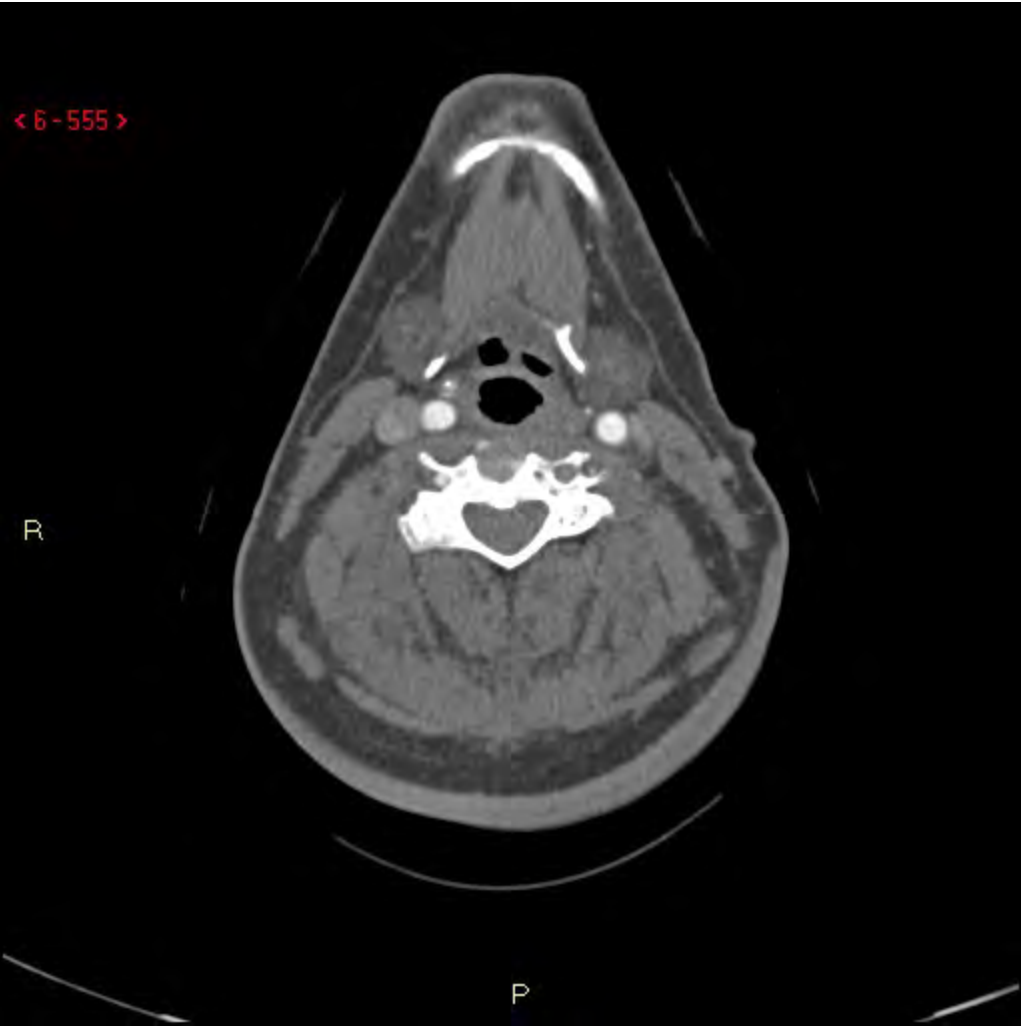


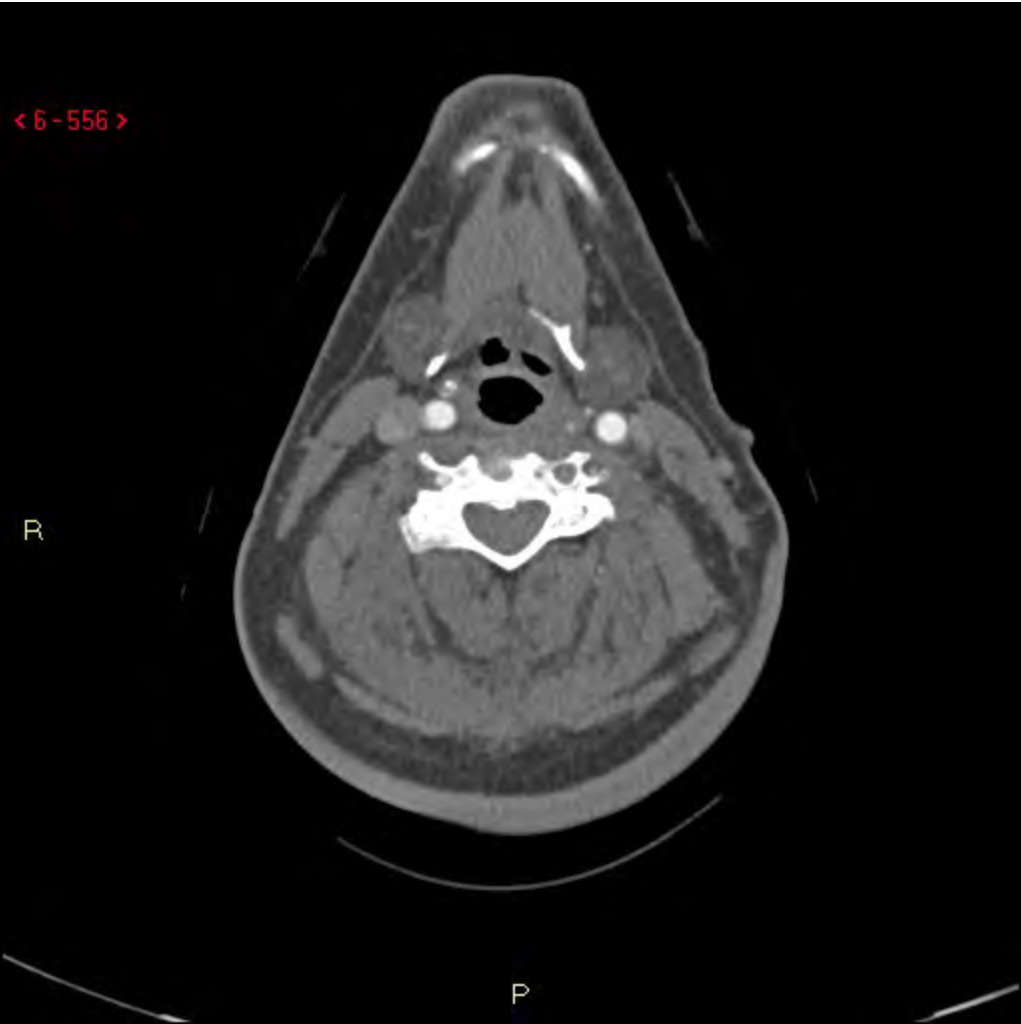


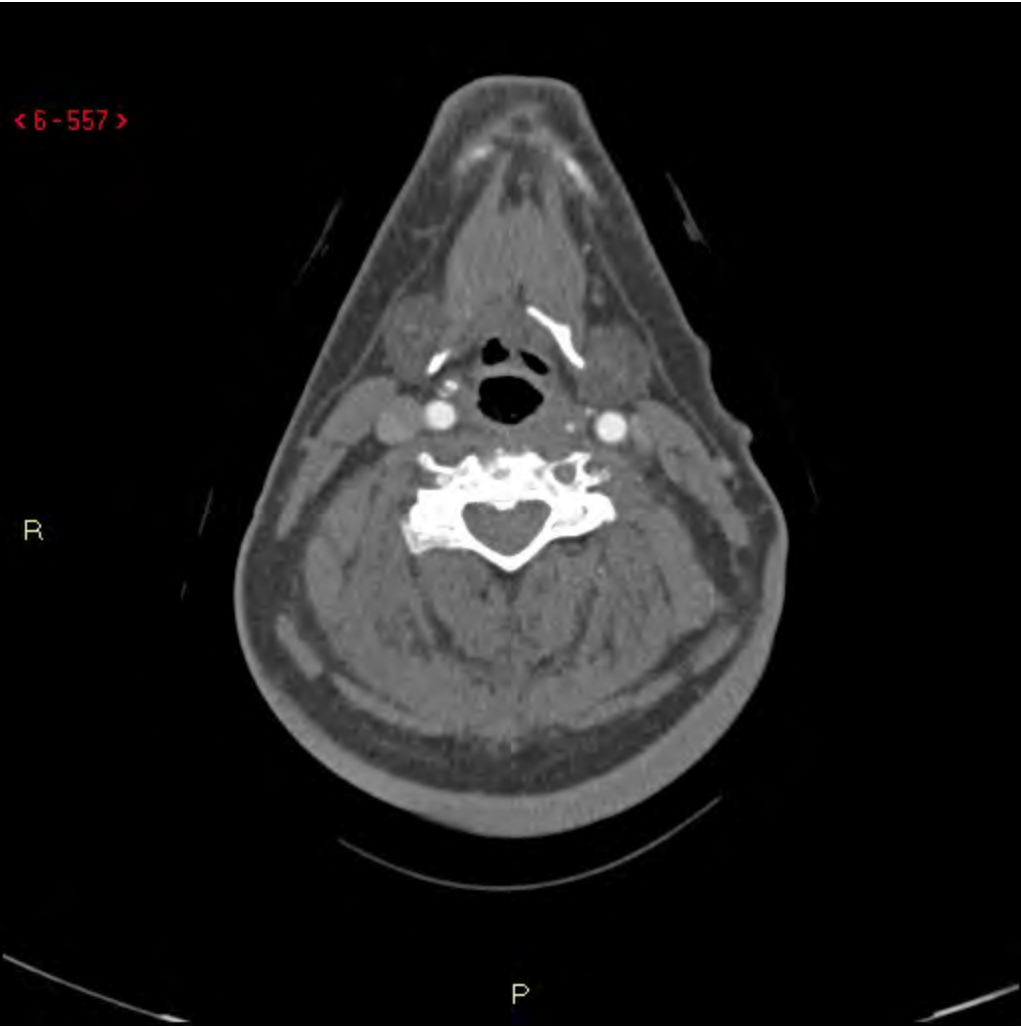


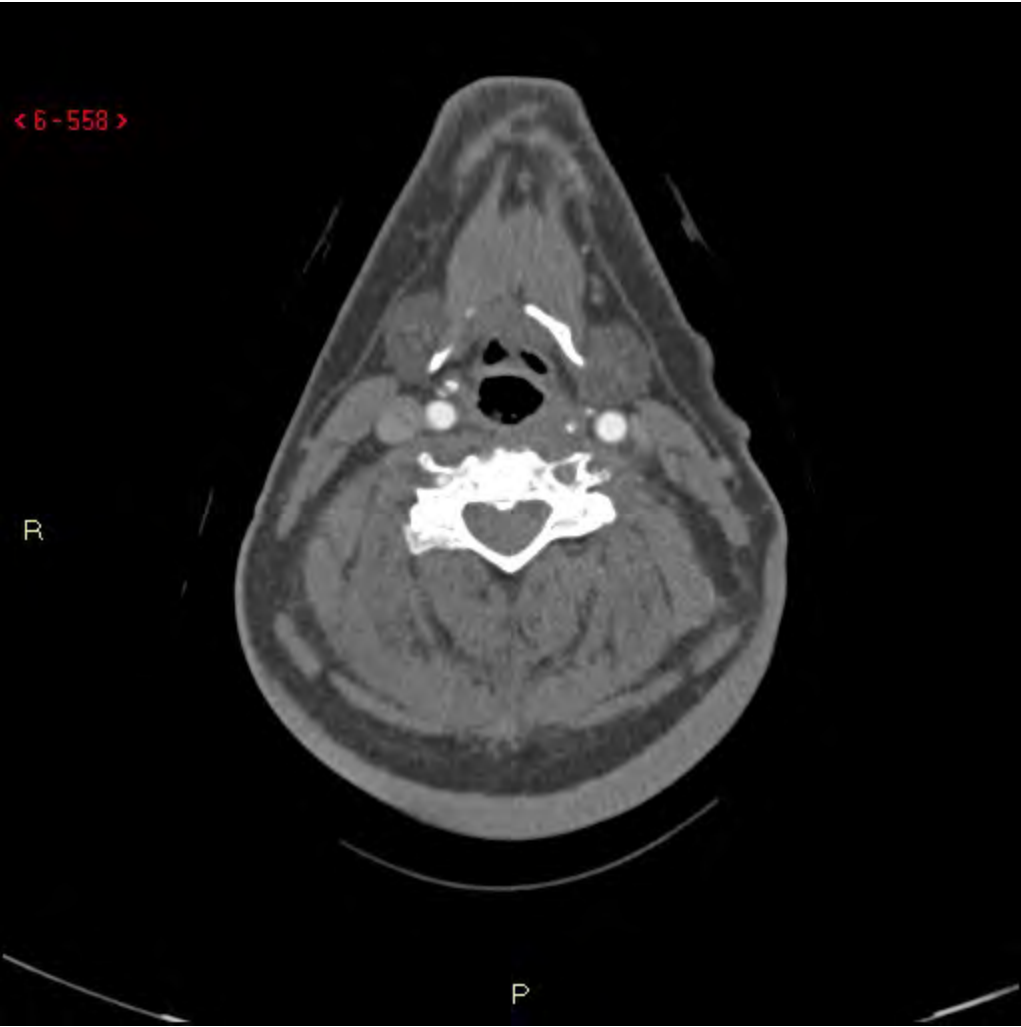




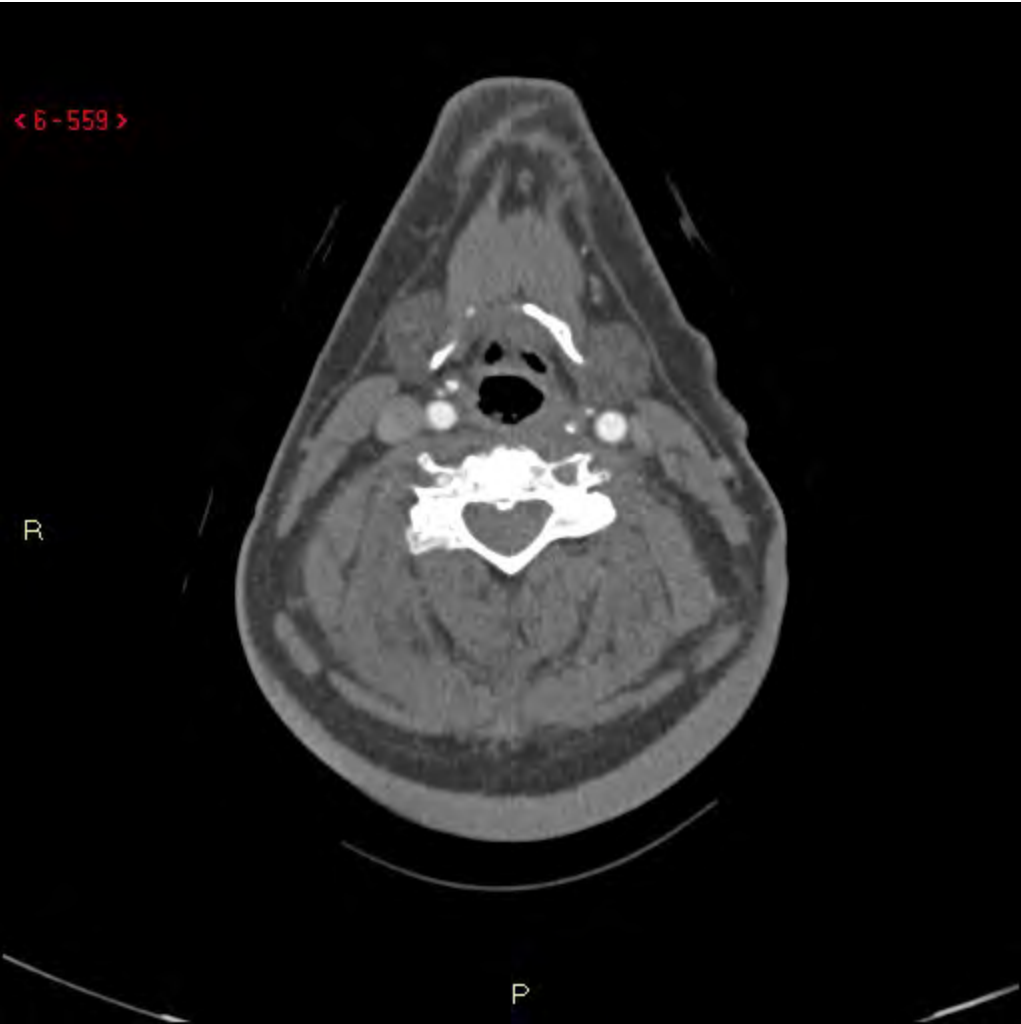


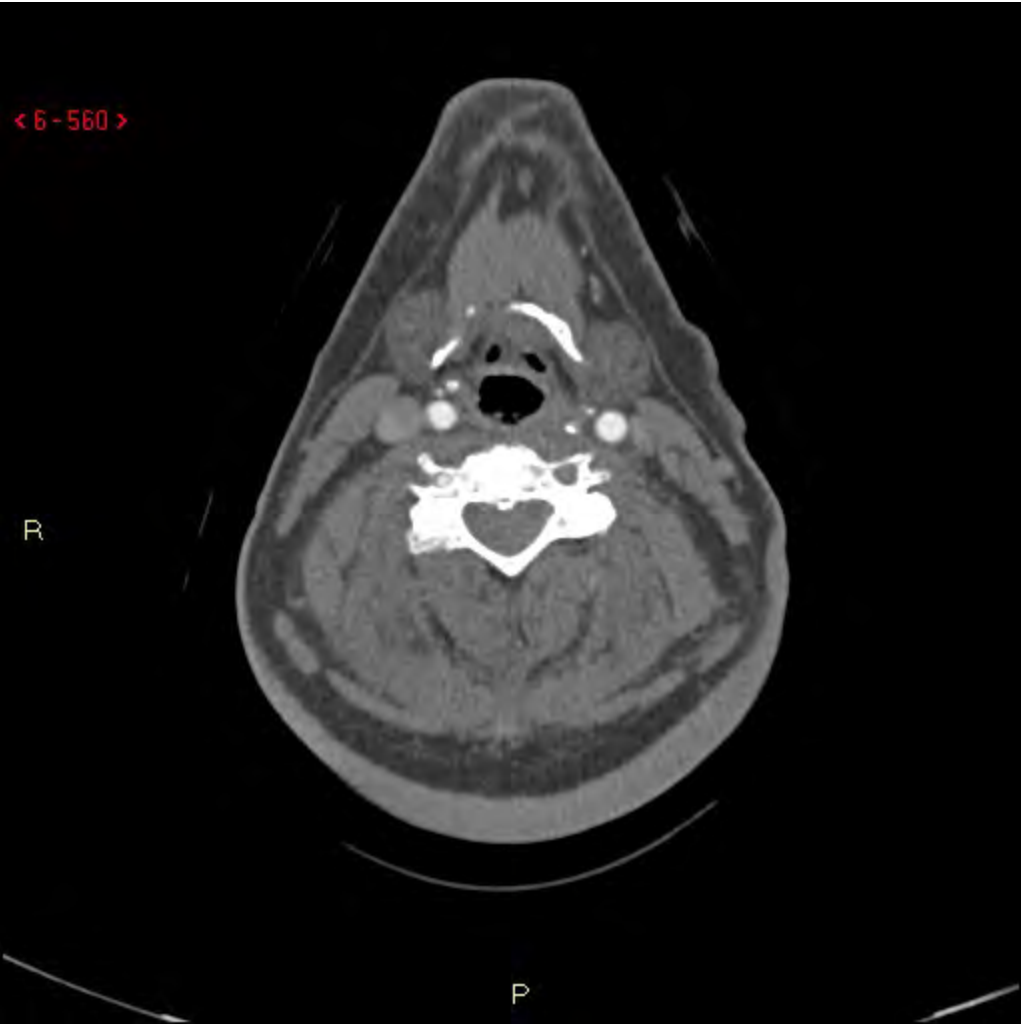




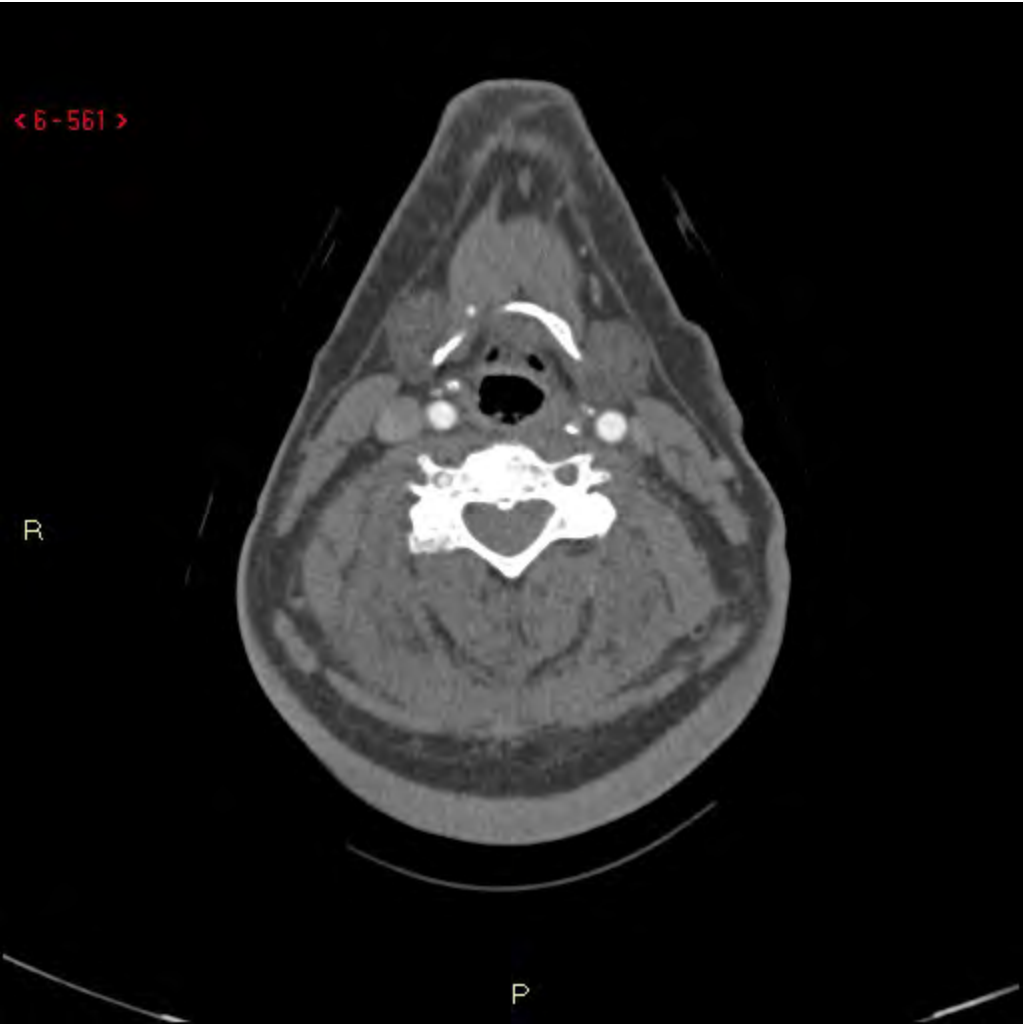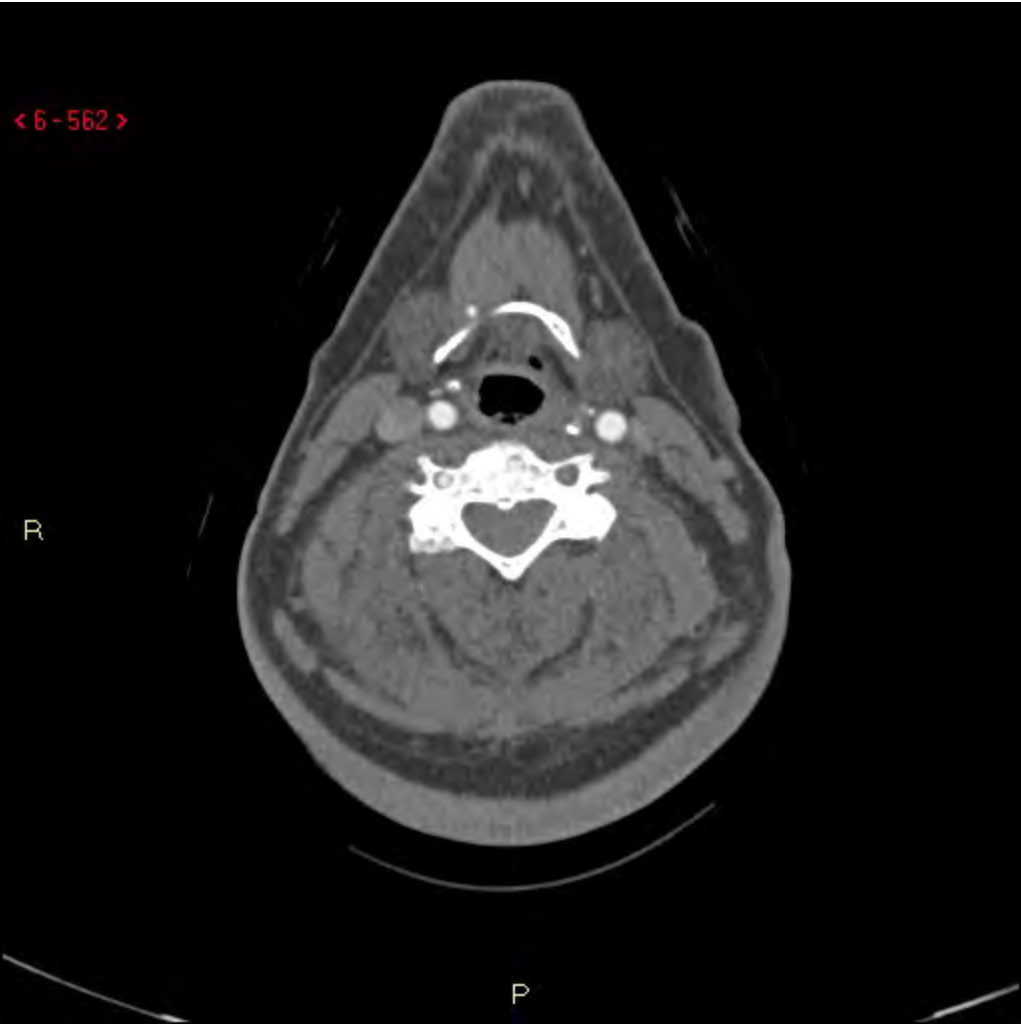


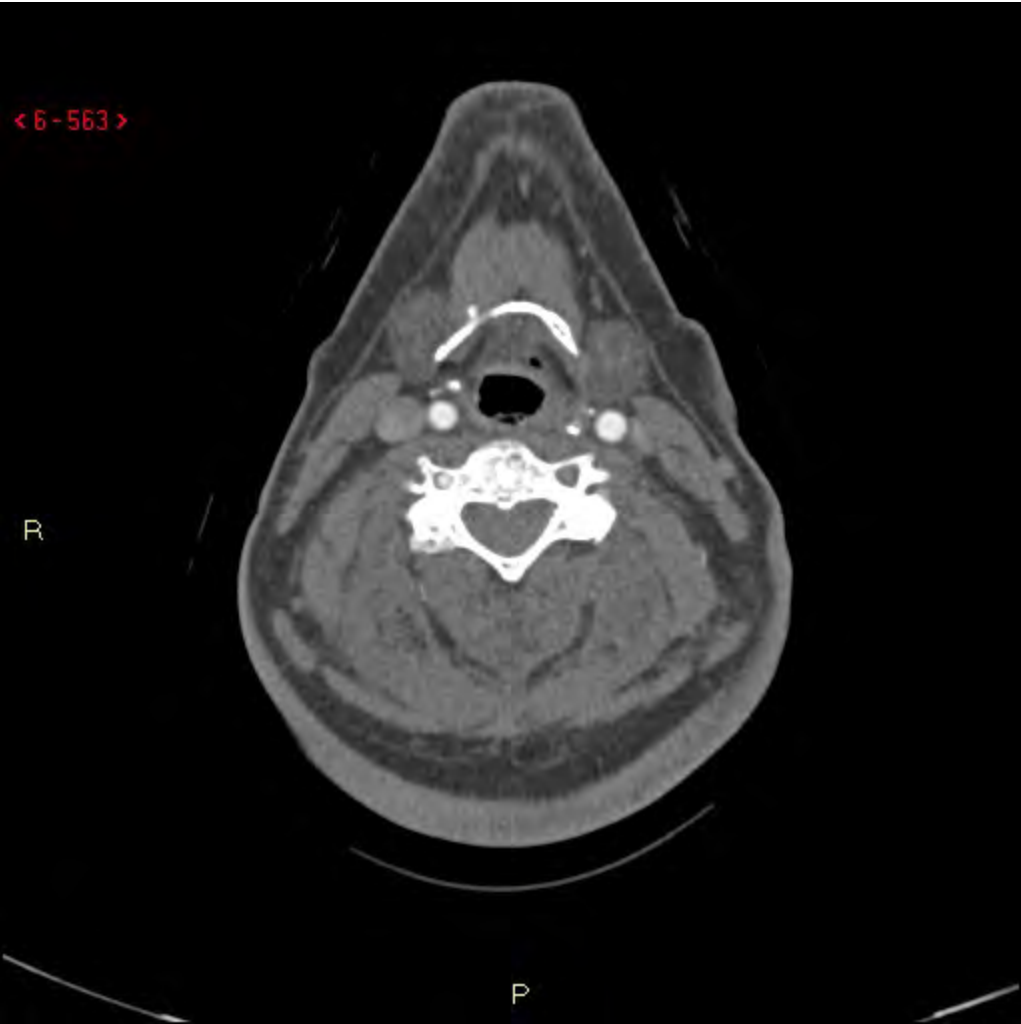




















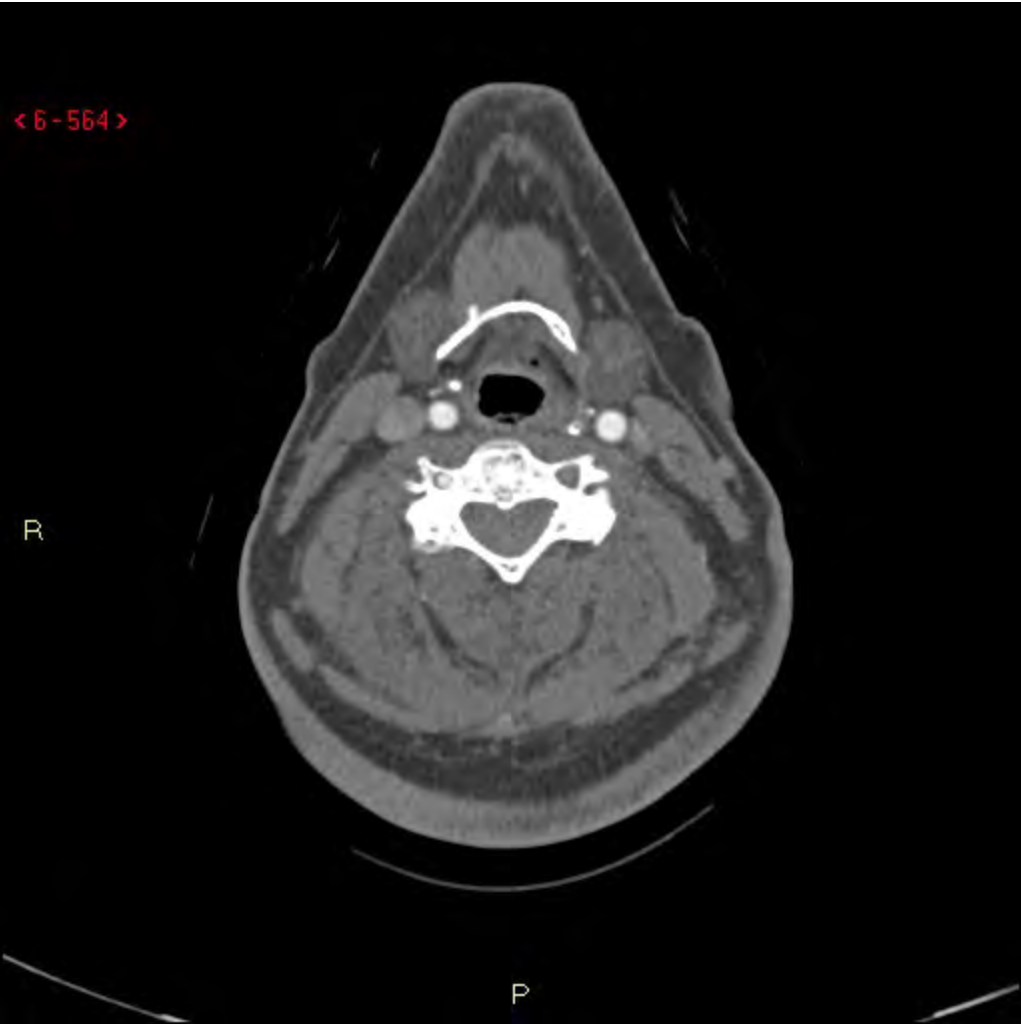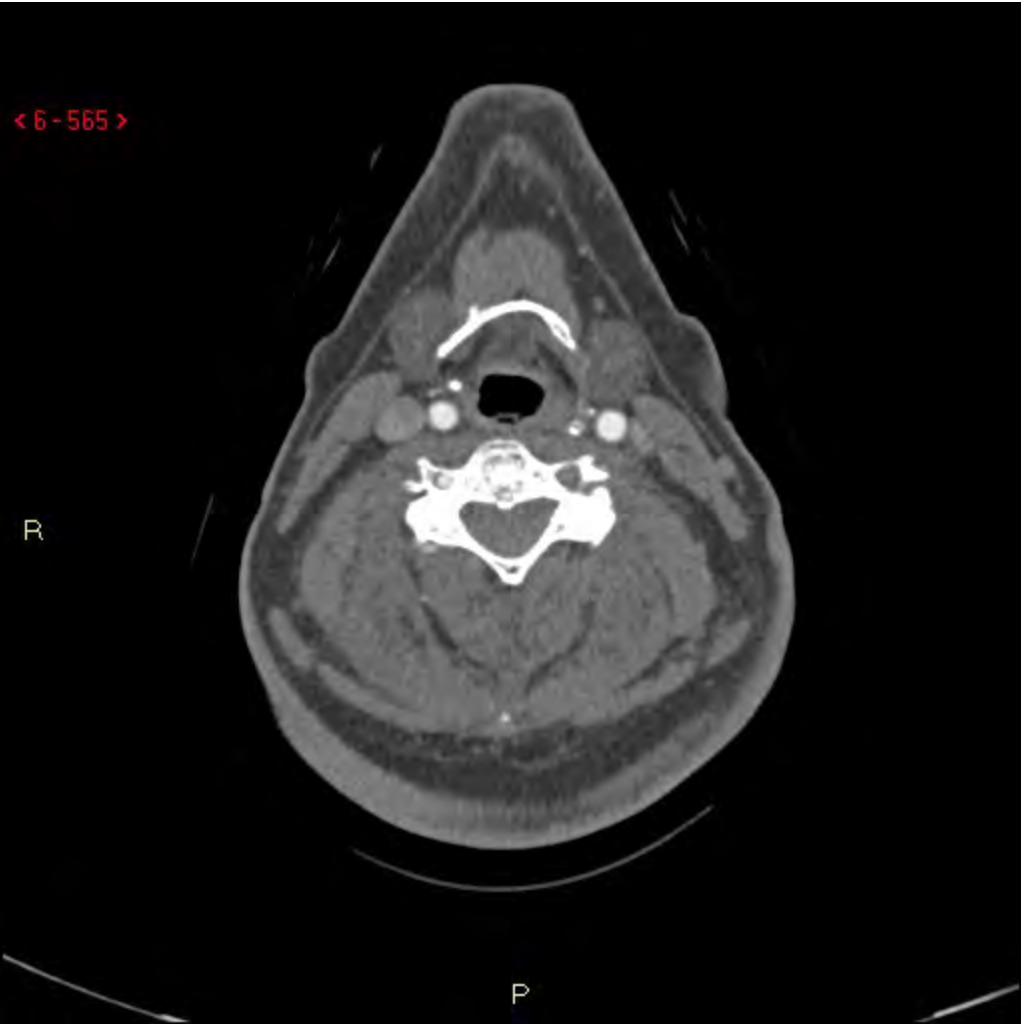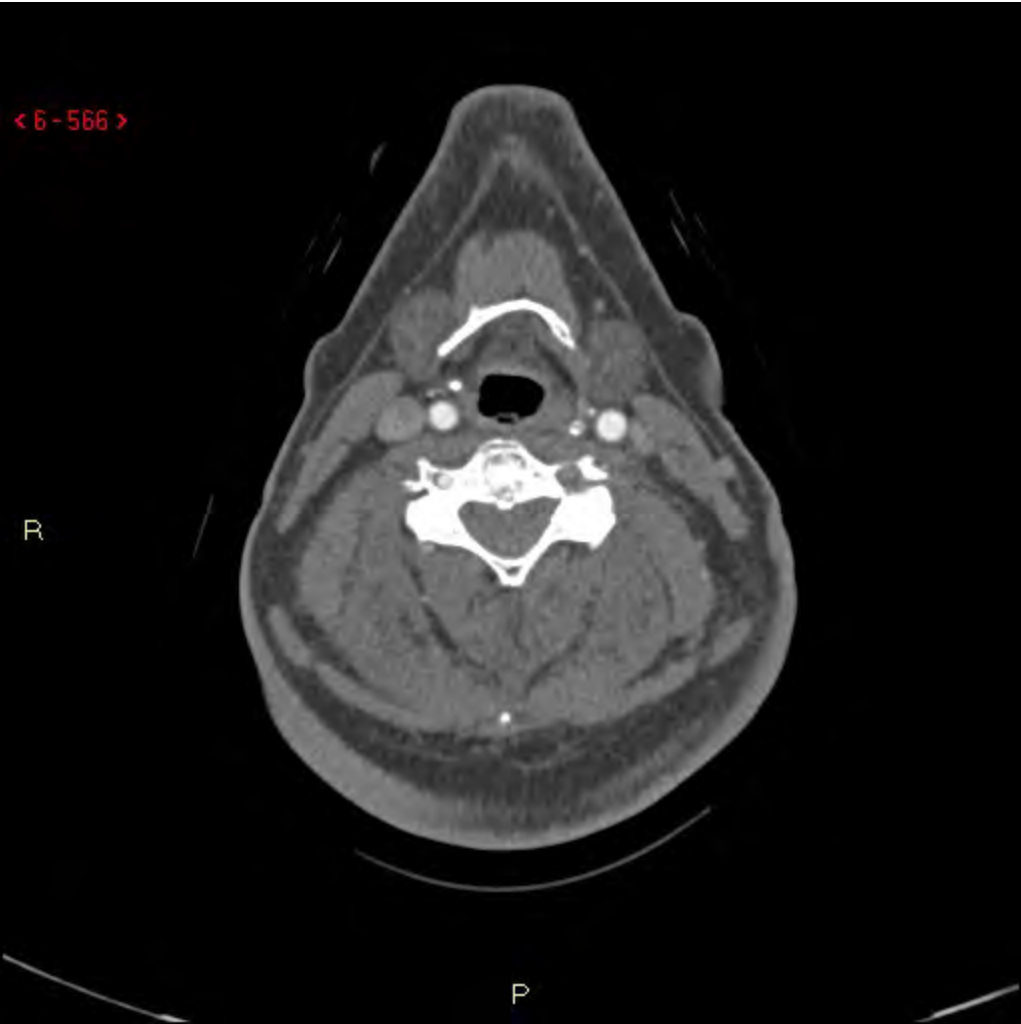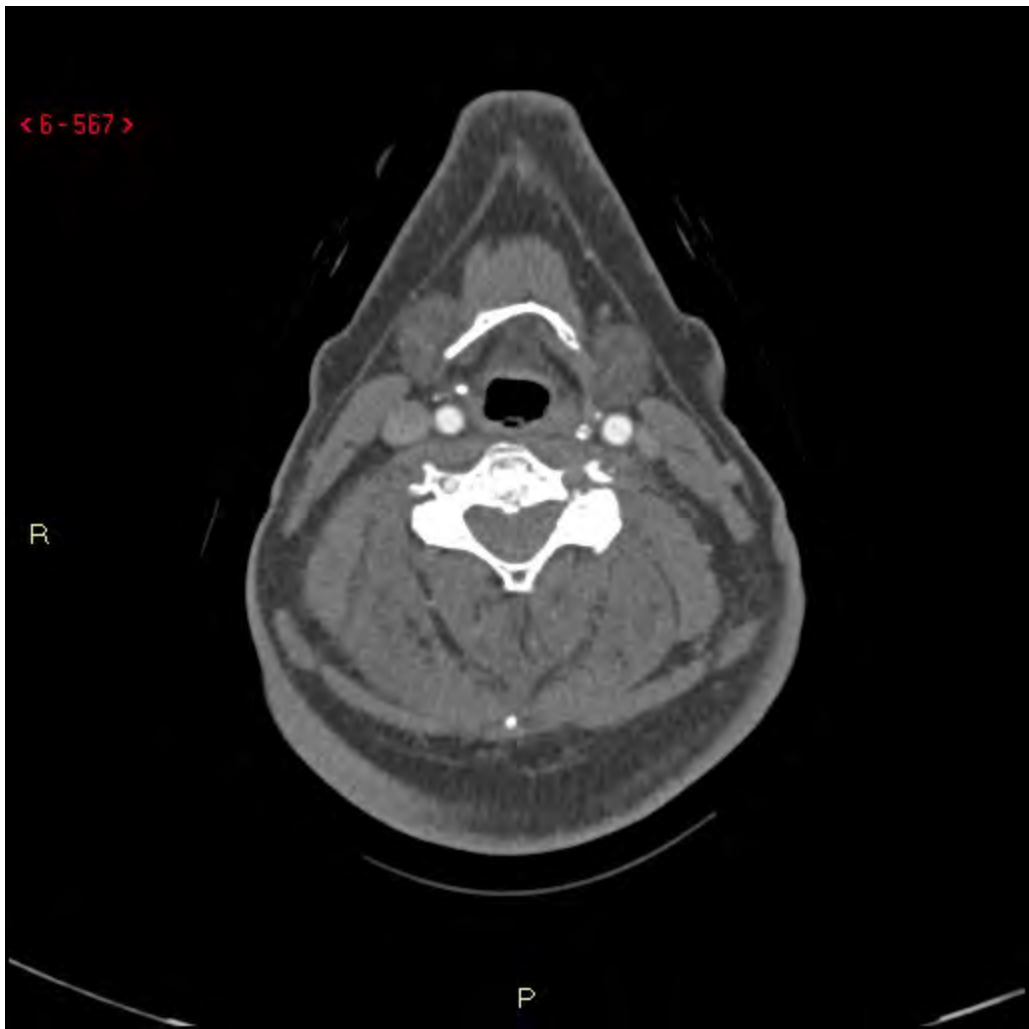< 6-567 >

R

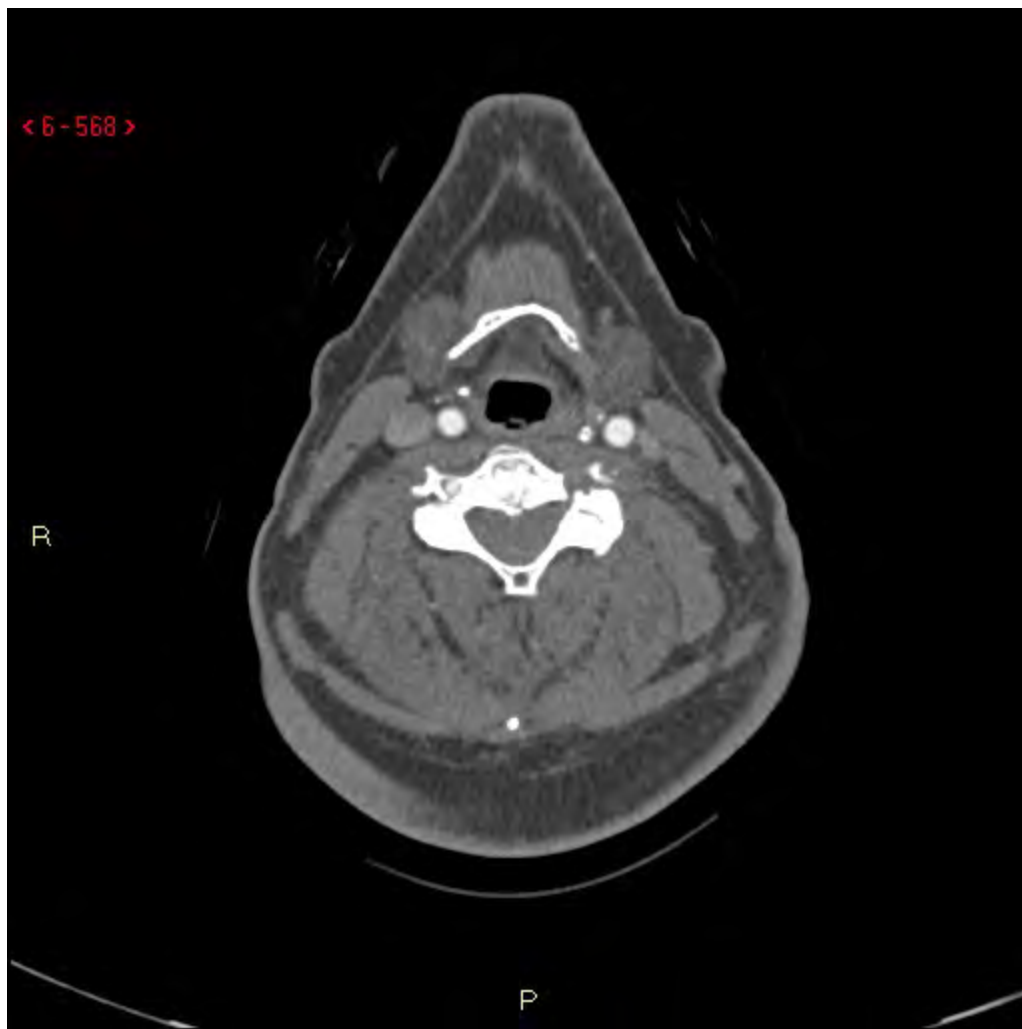P

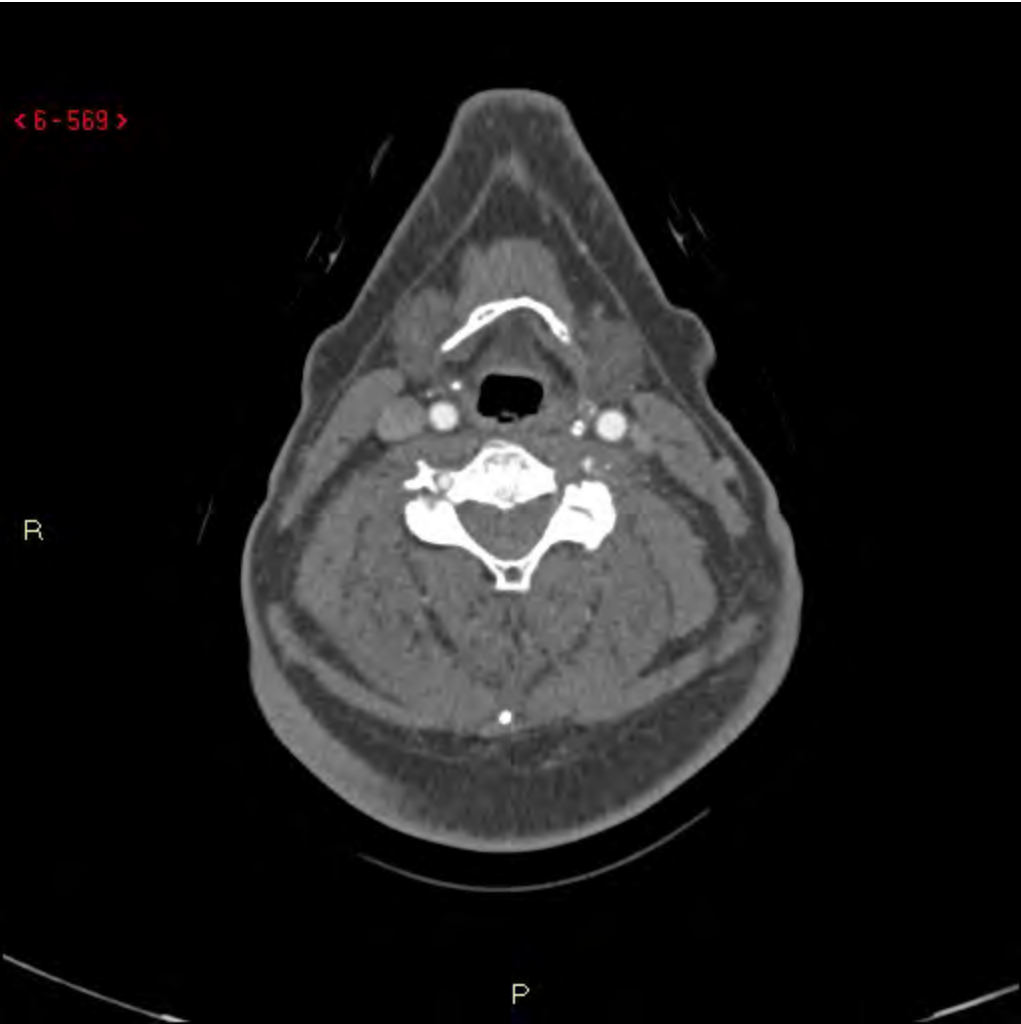


< 6-568 >

R

P

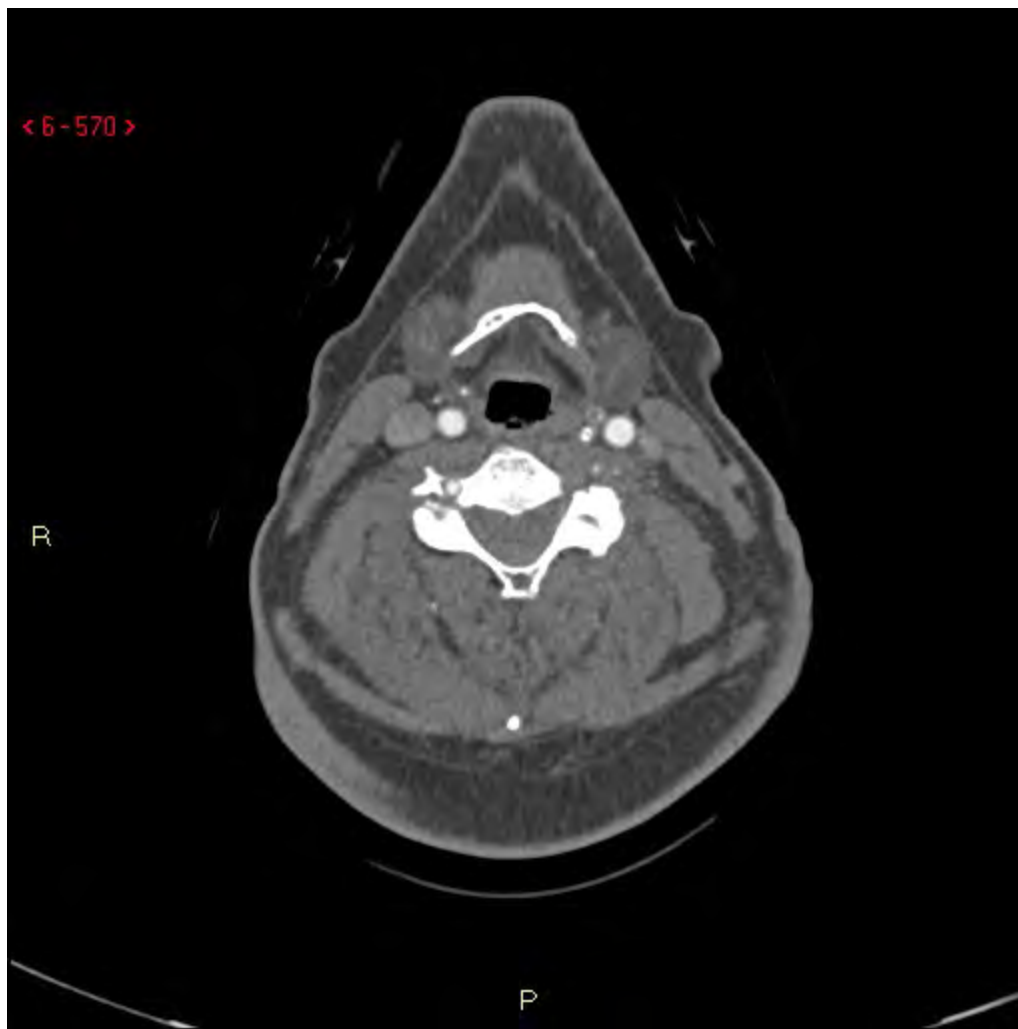




< 6-570 >

R

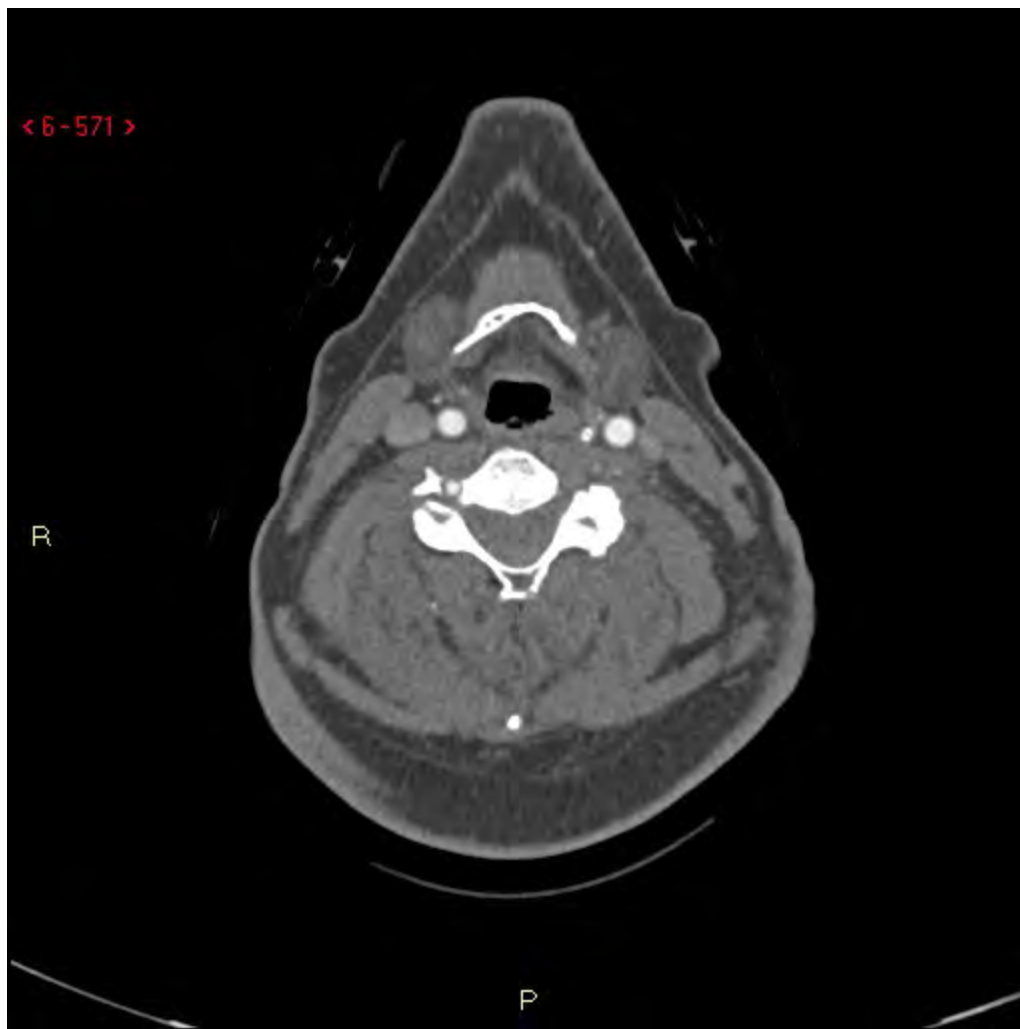
P

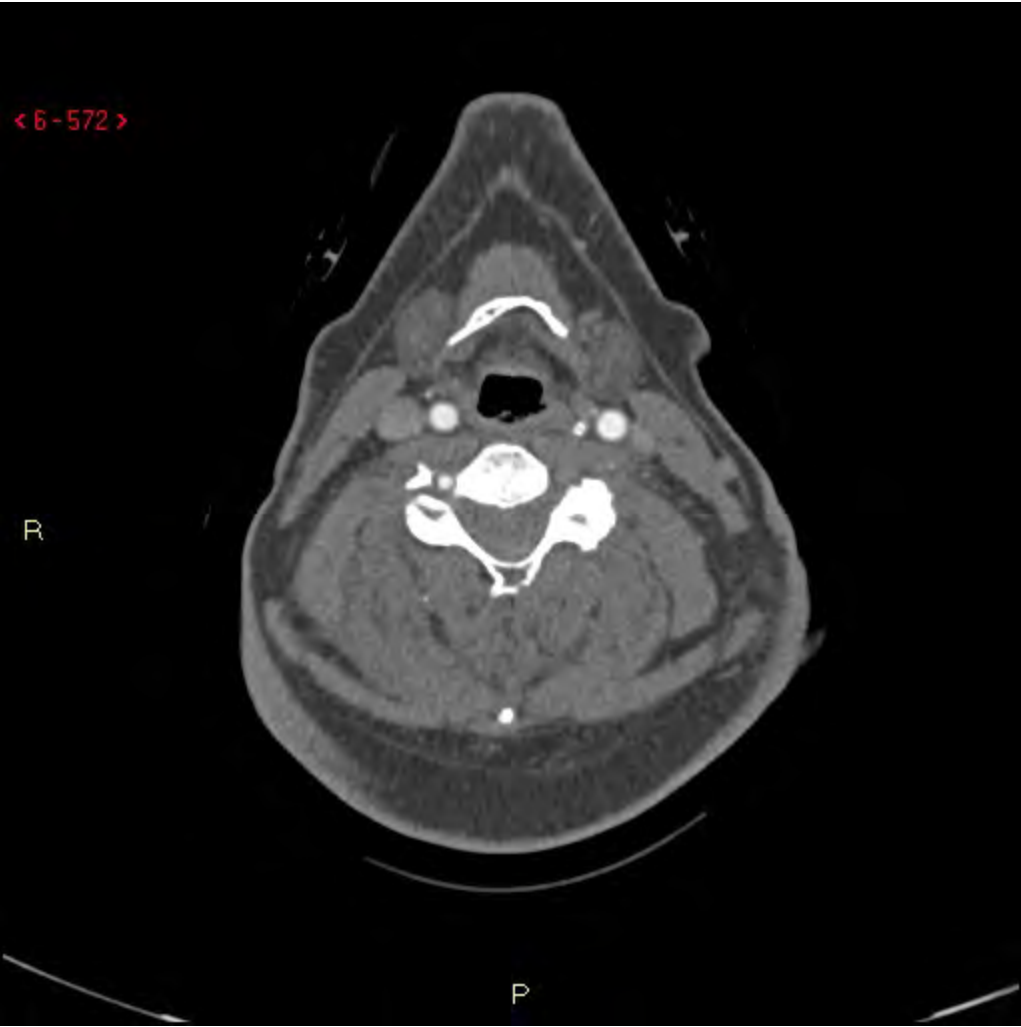


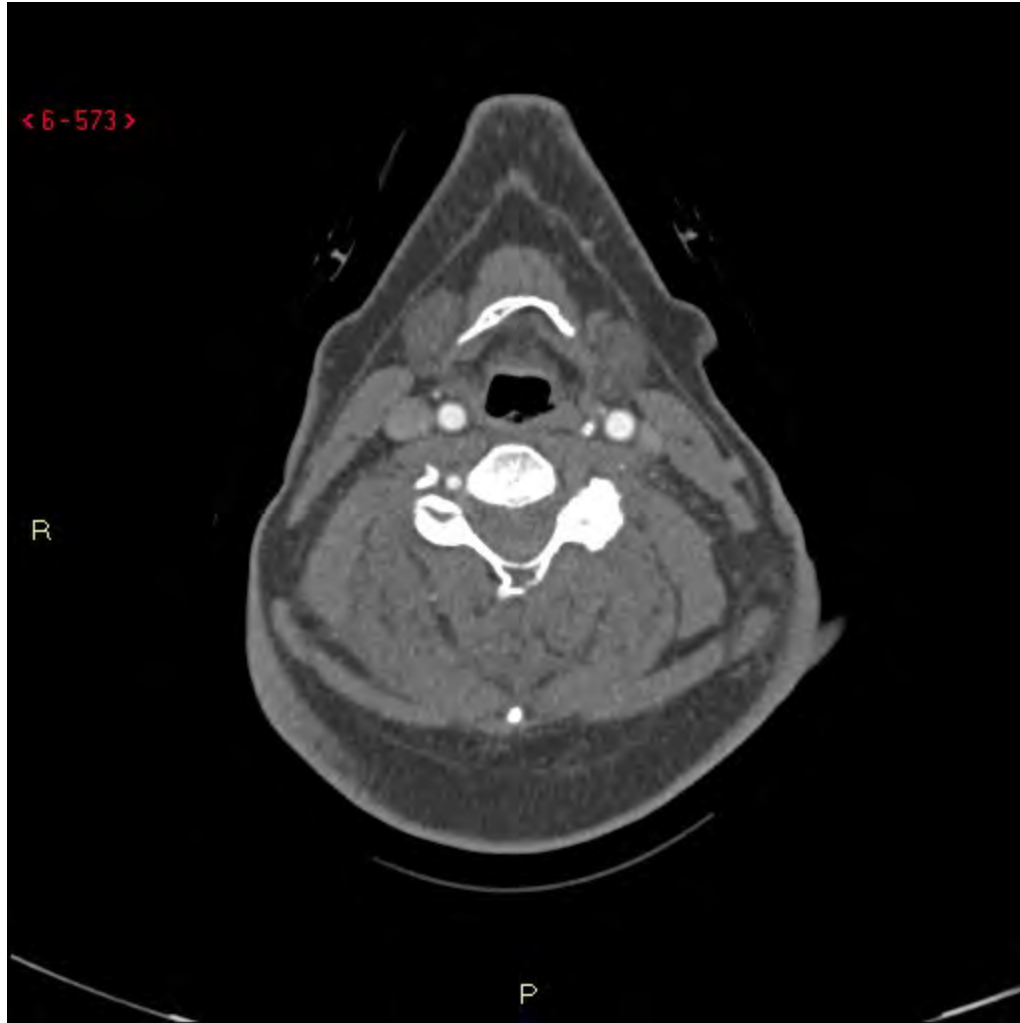
< 6-571 >

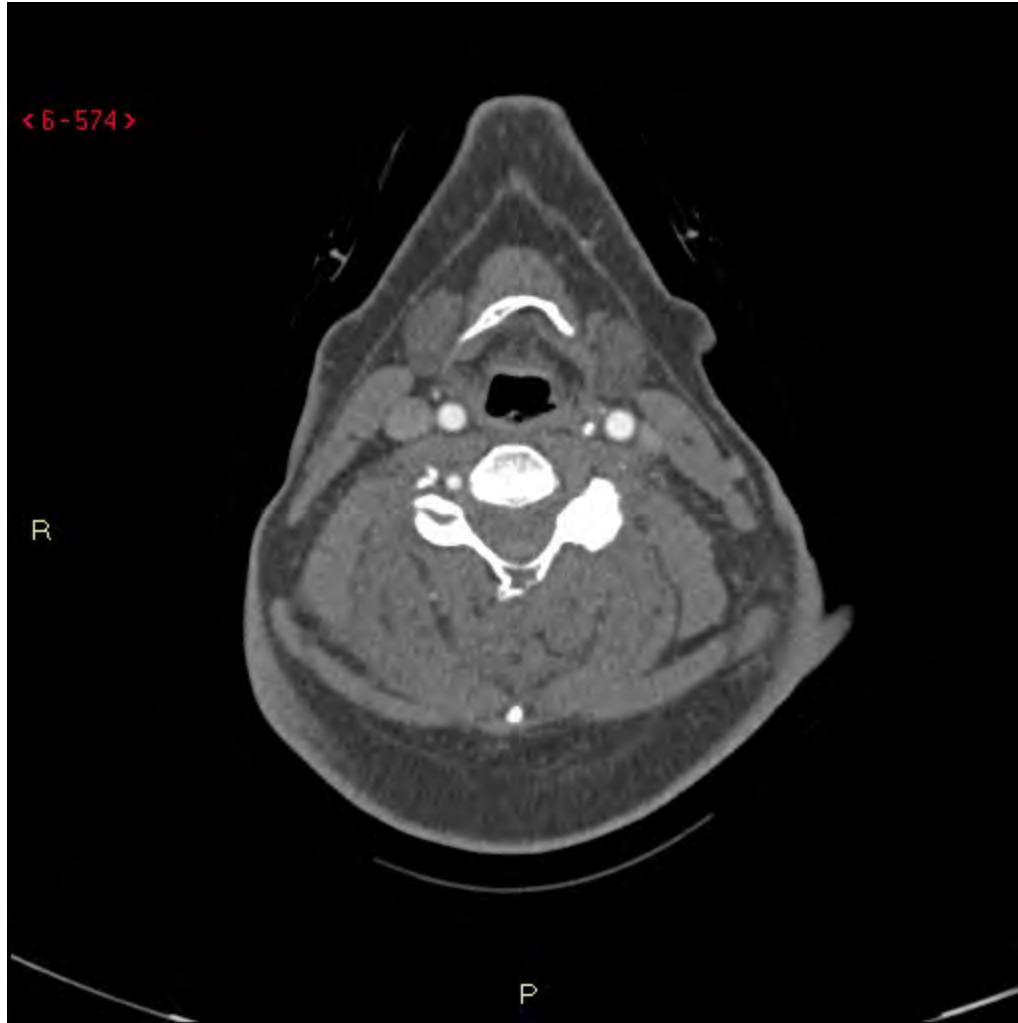
R

P

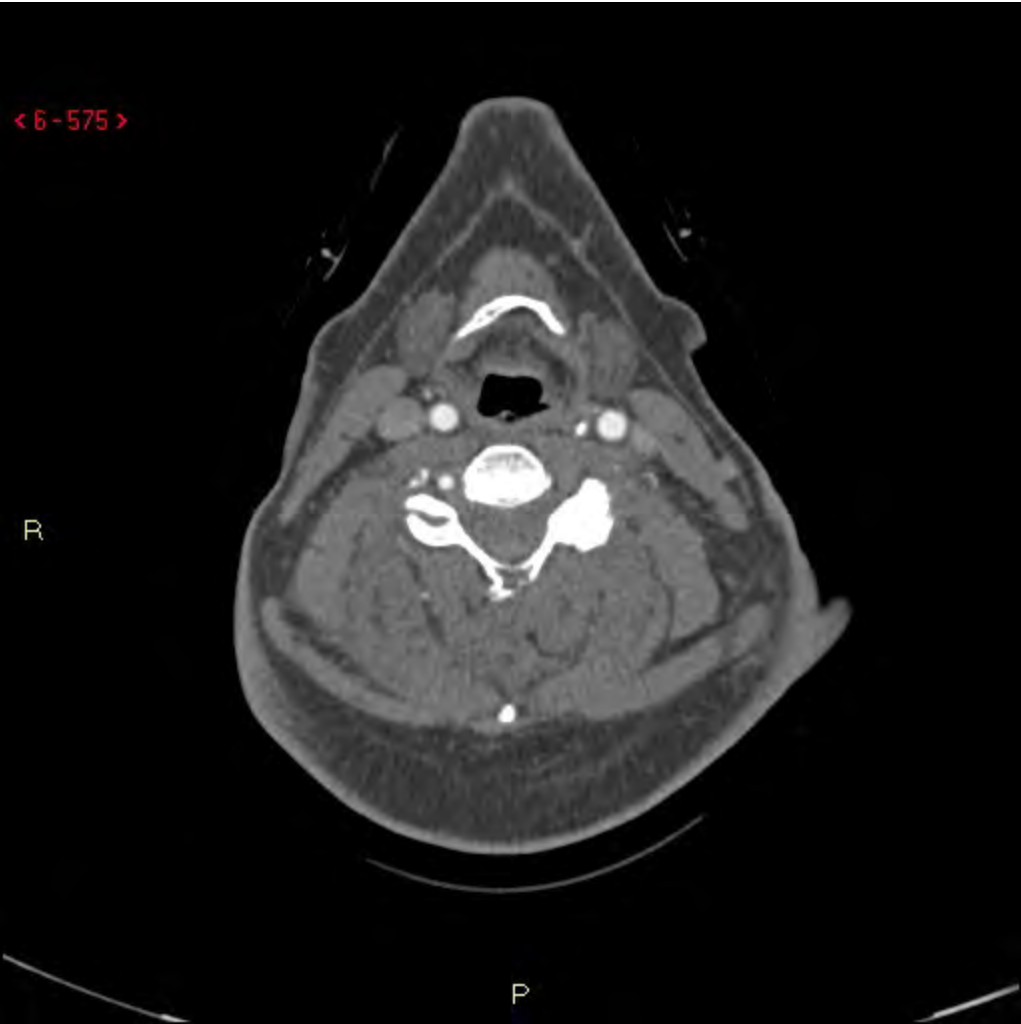


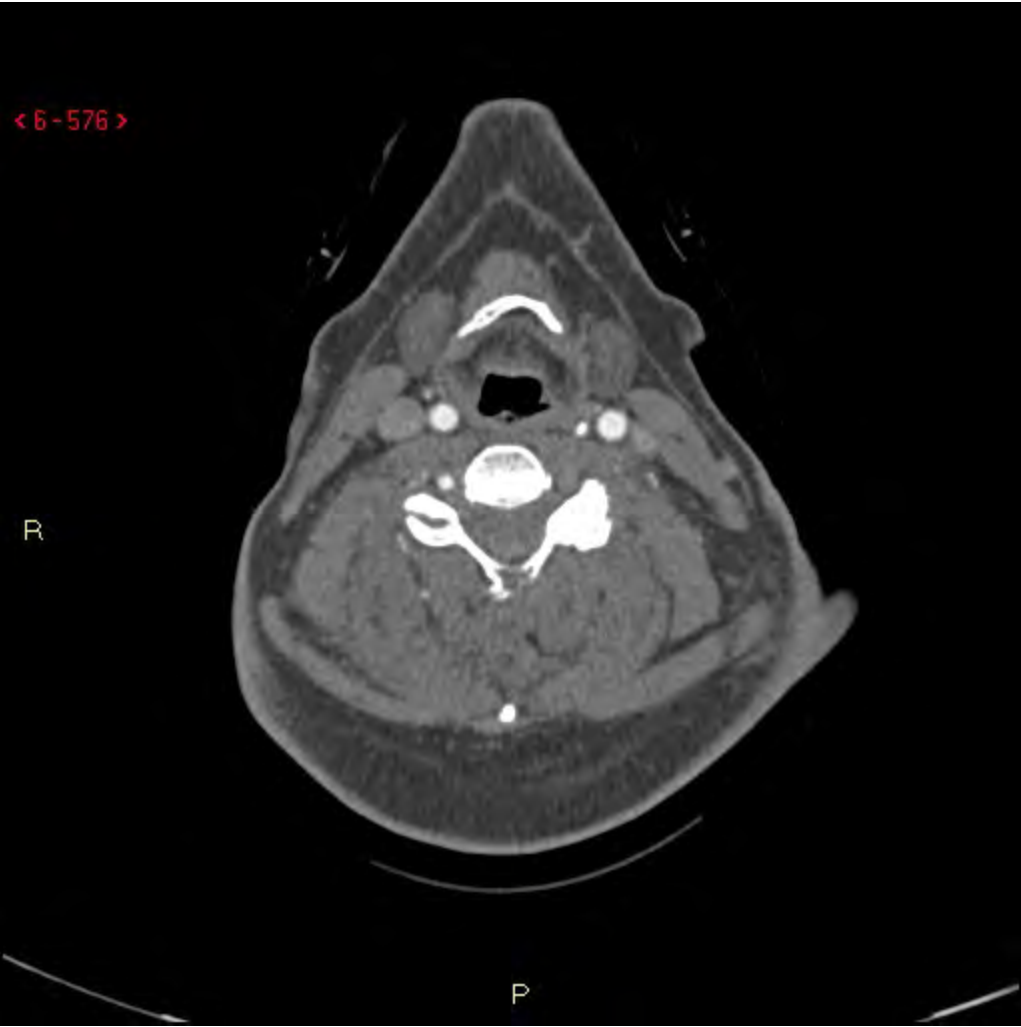


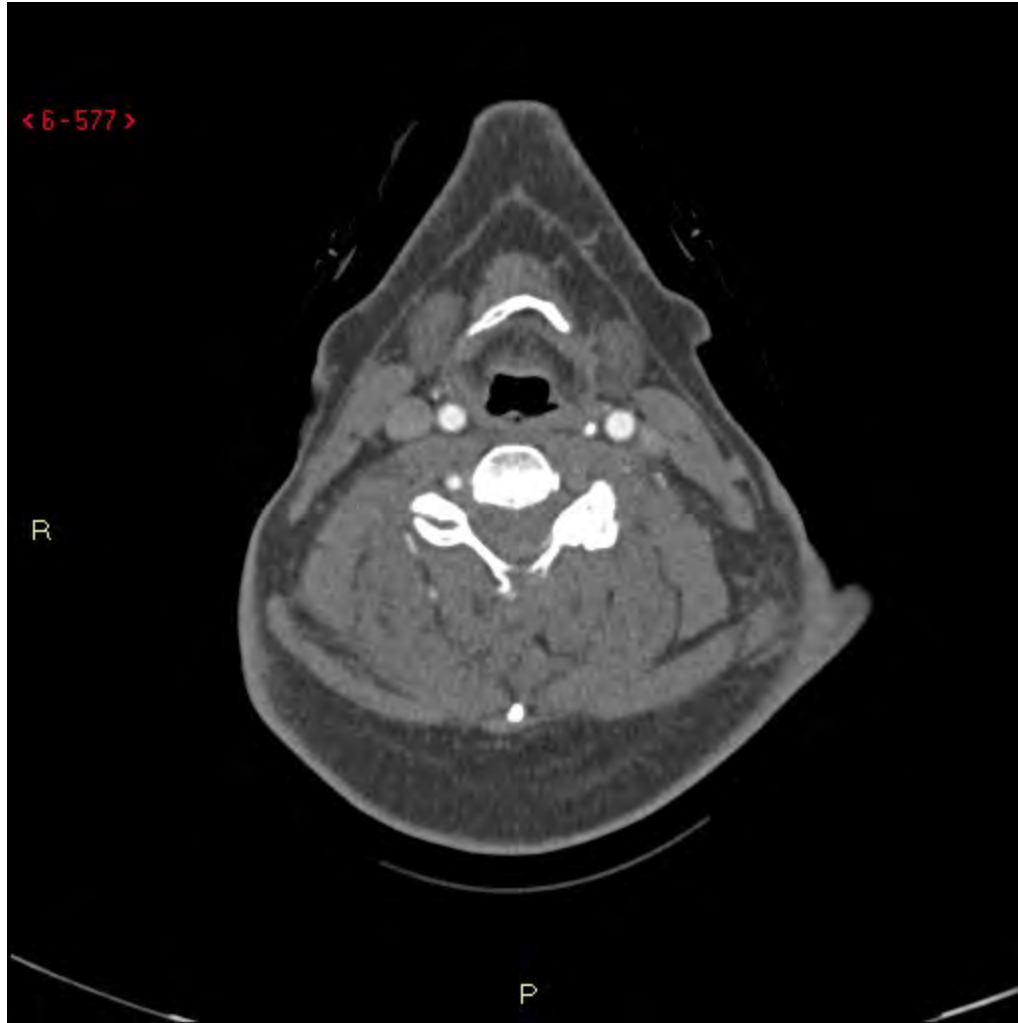


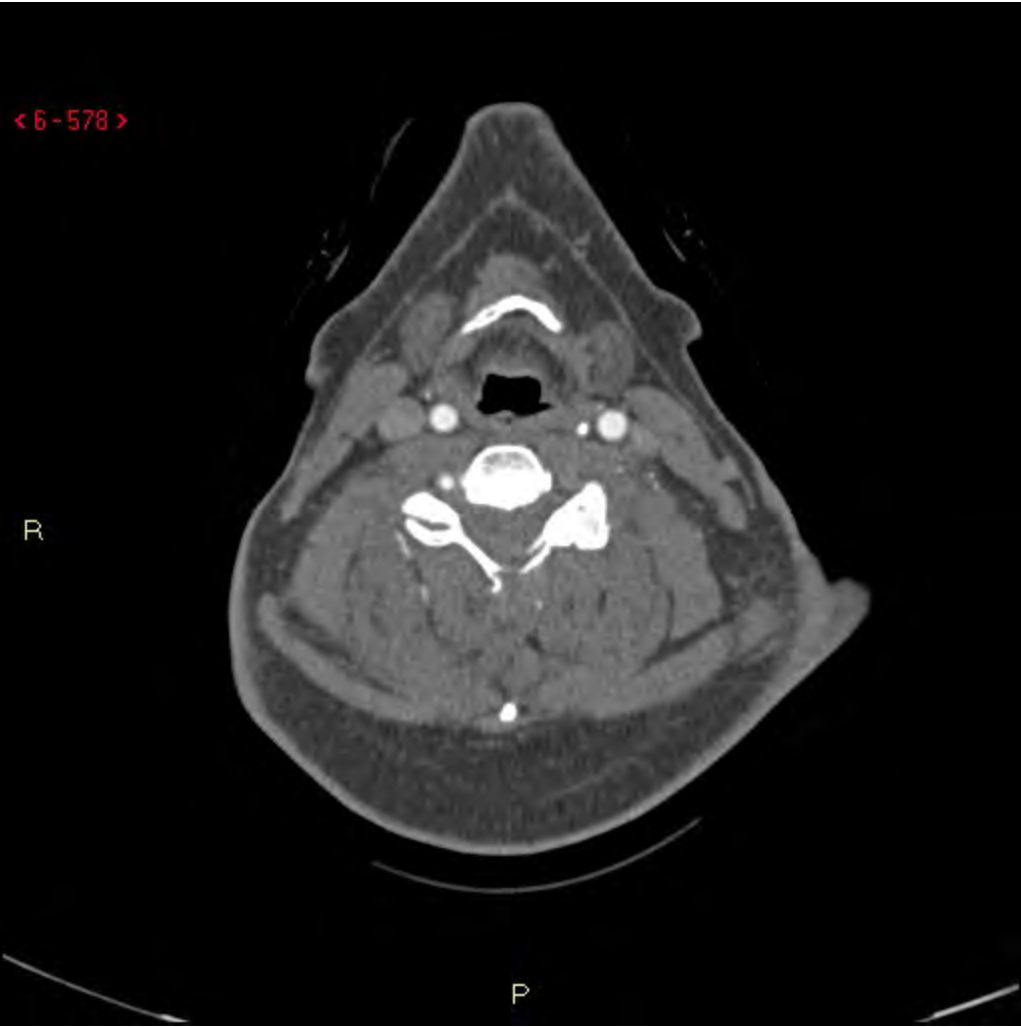








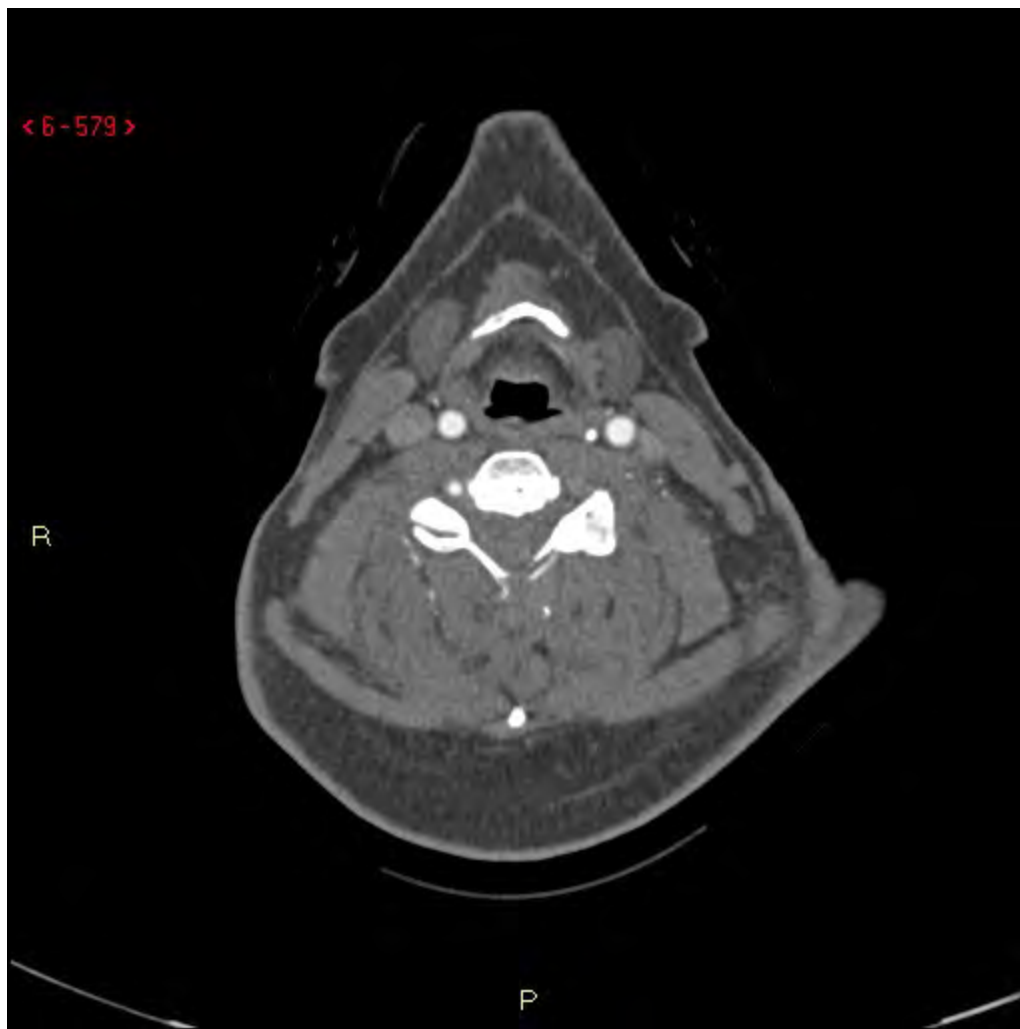
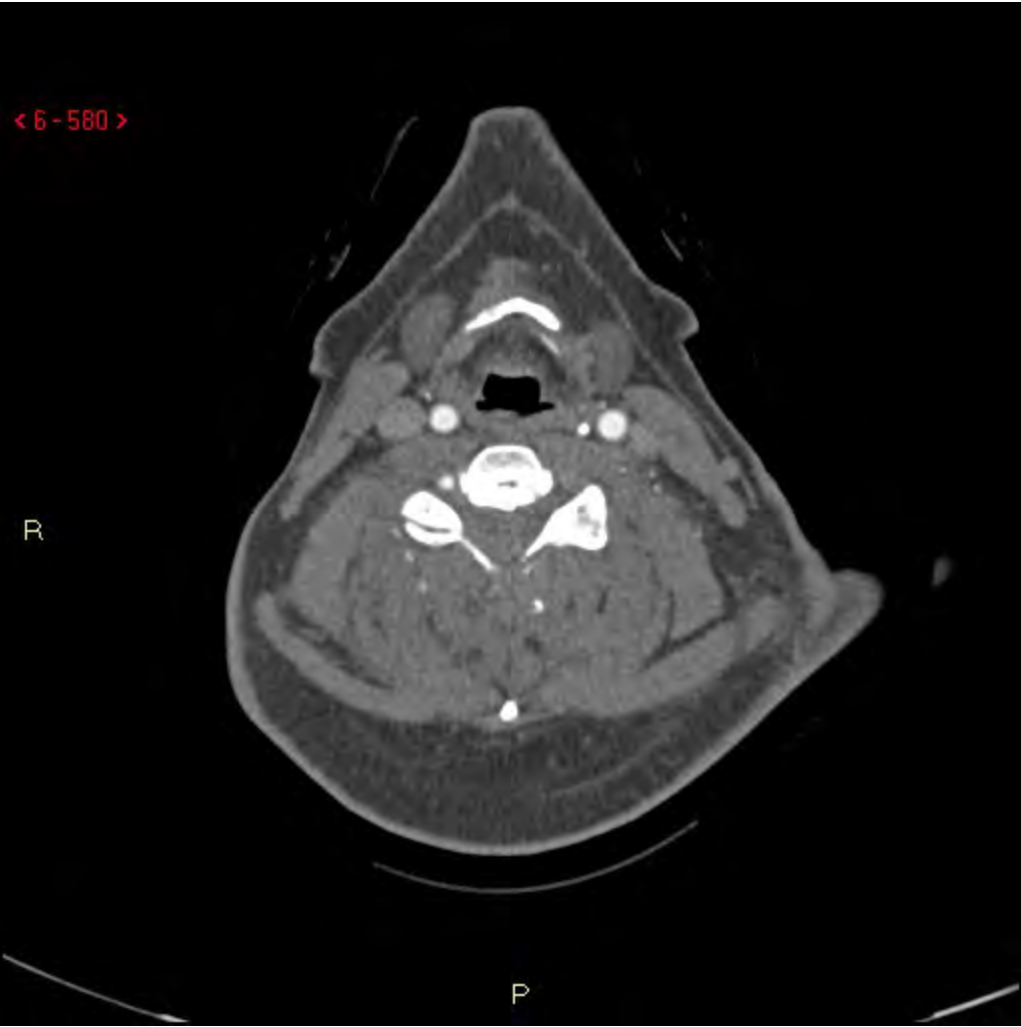


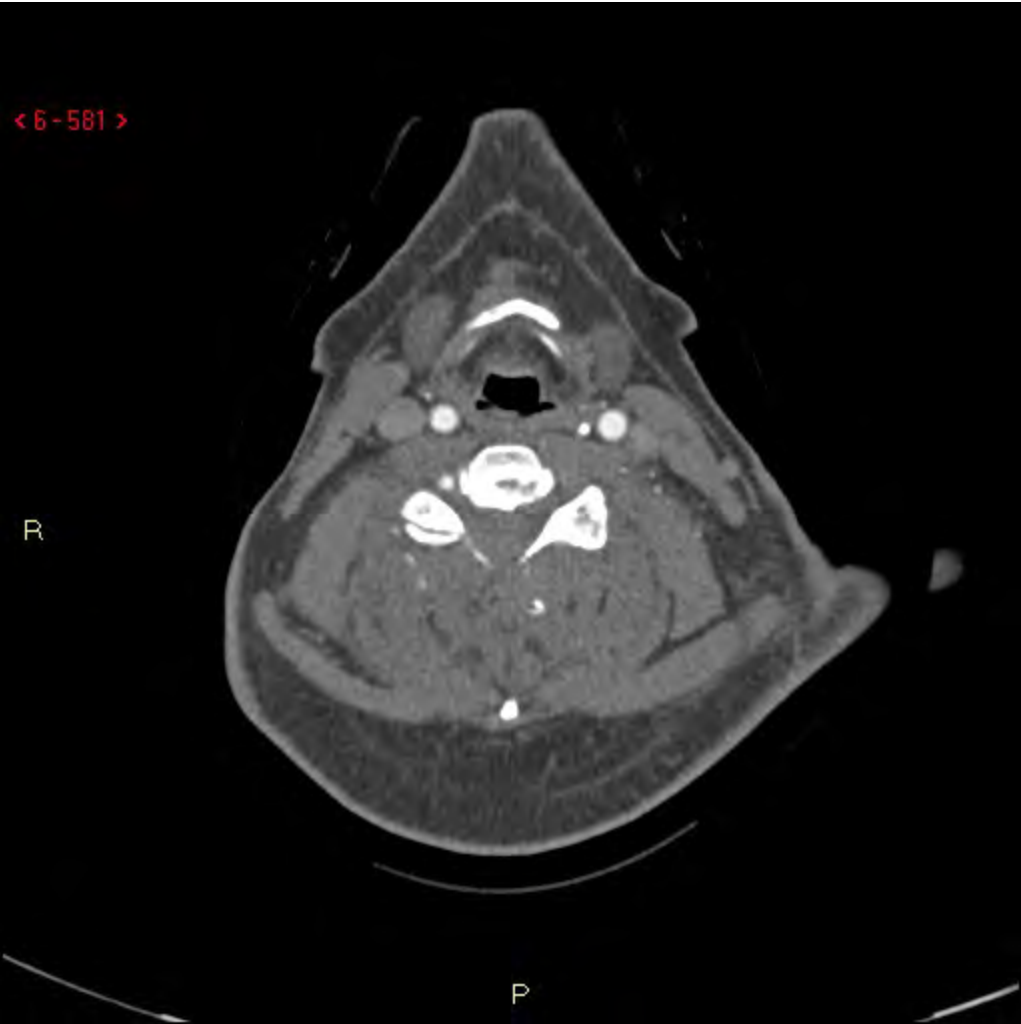
< 6-579 >

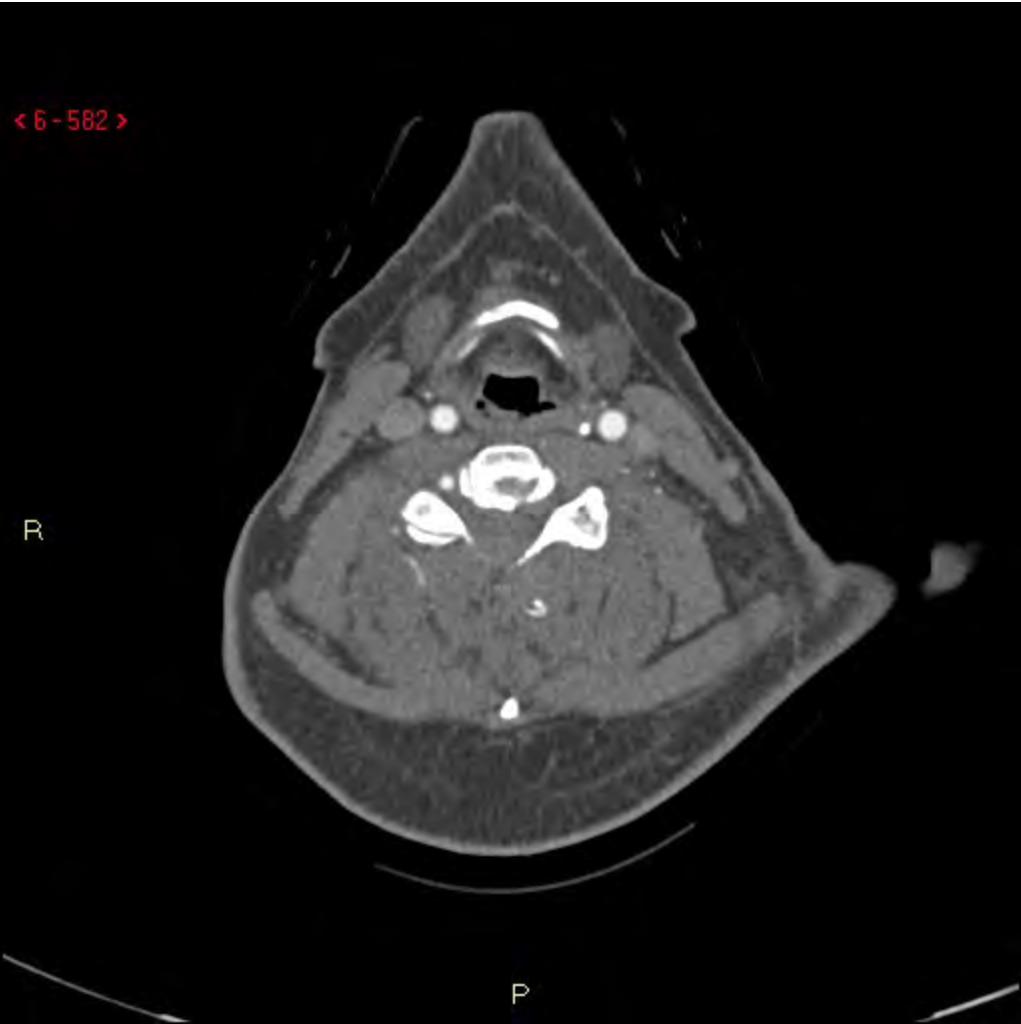
R

P

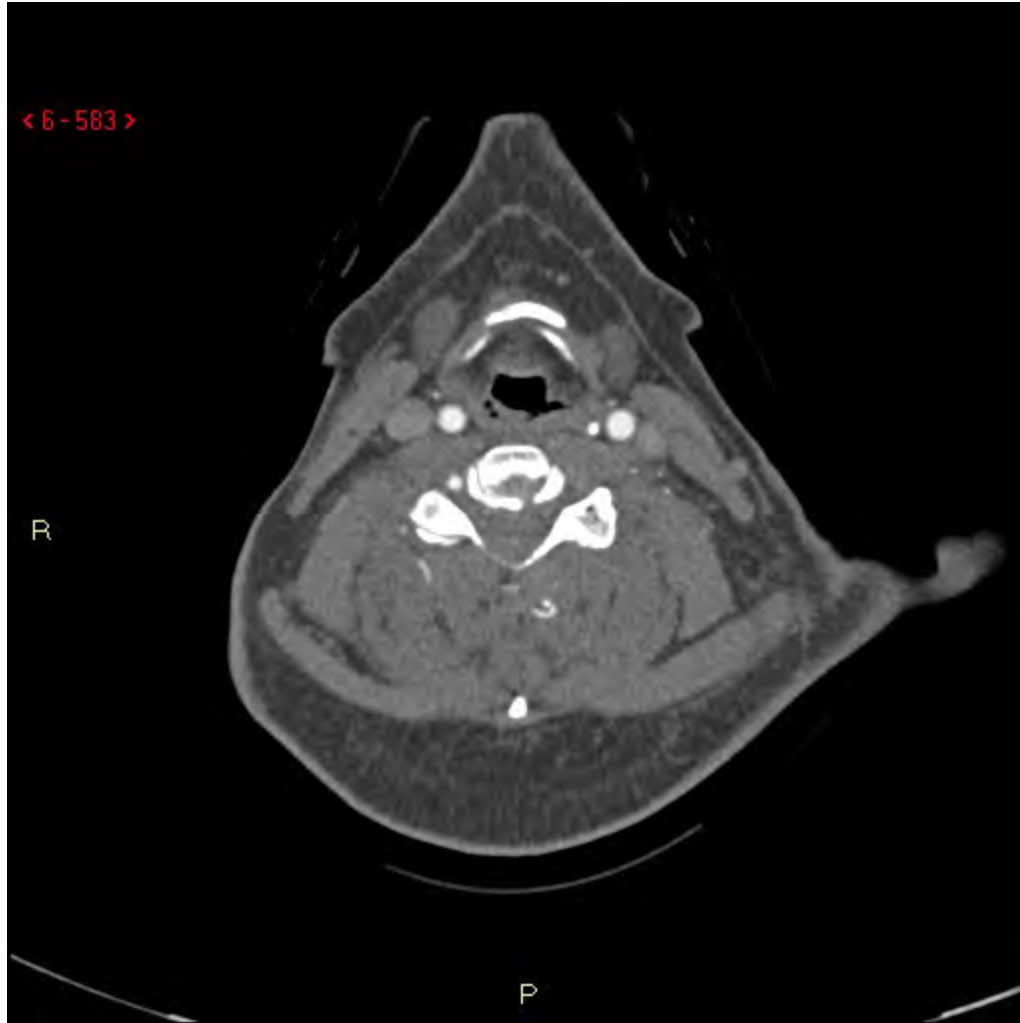


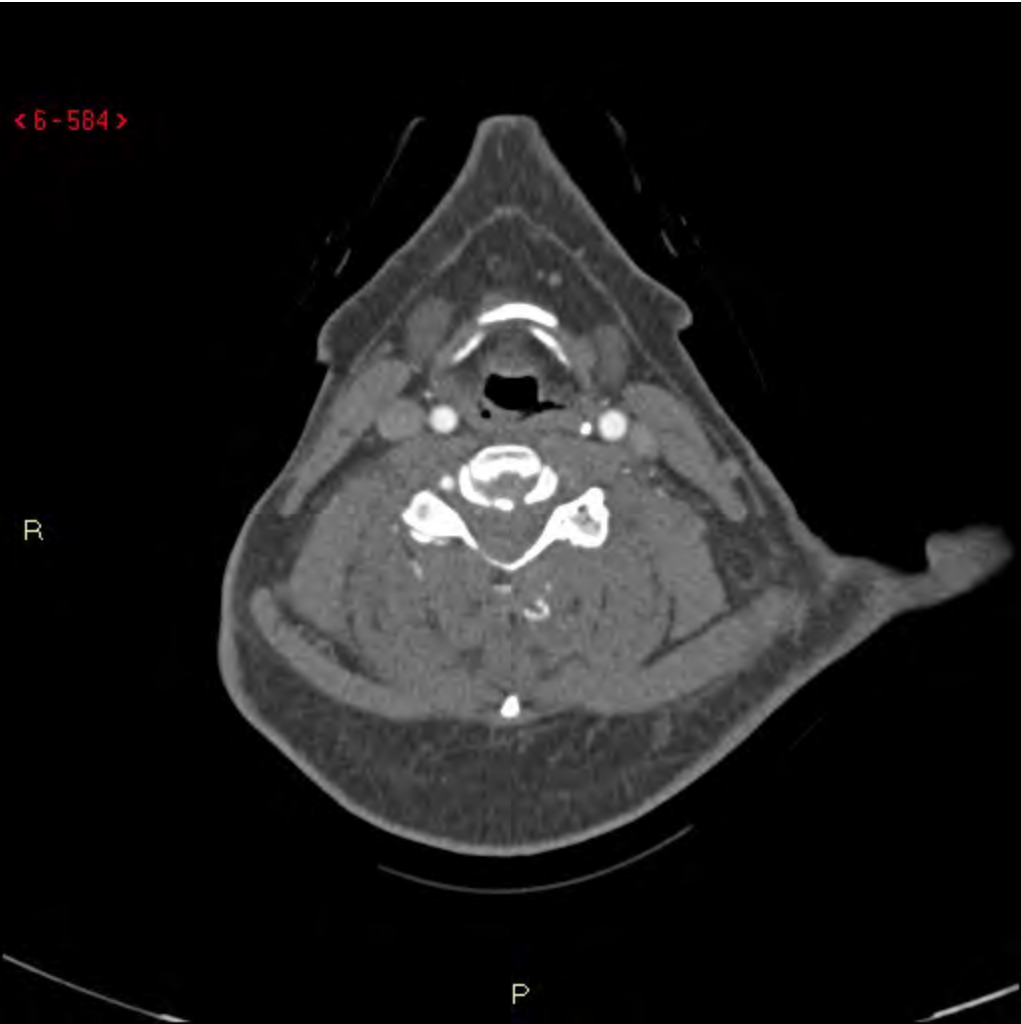

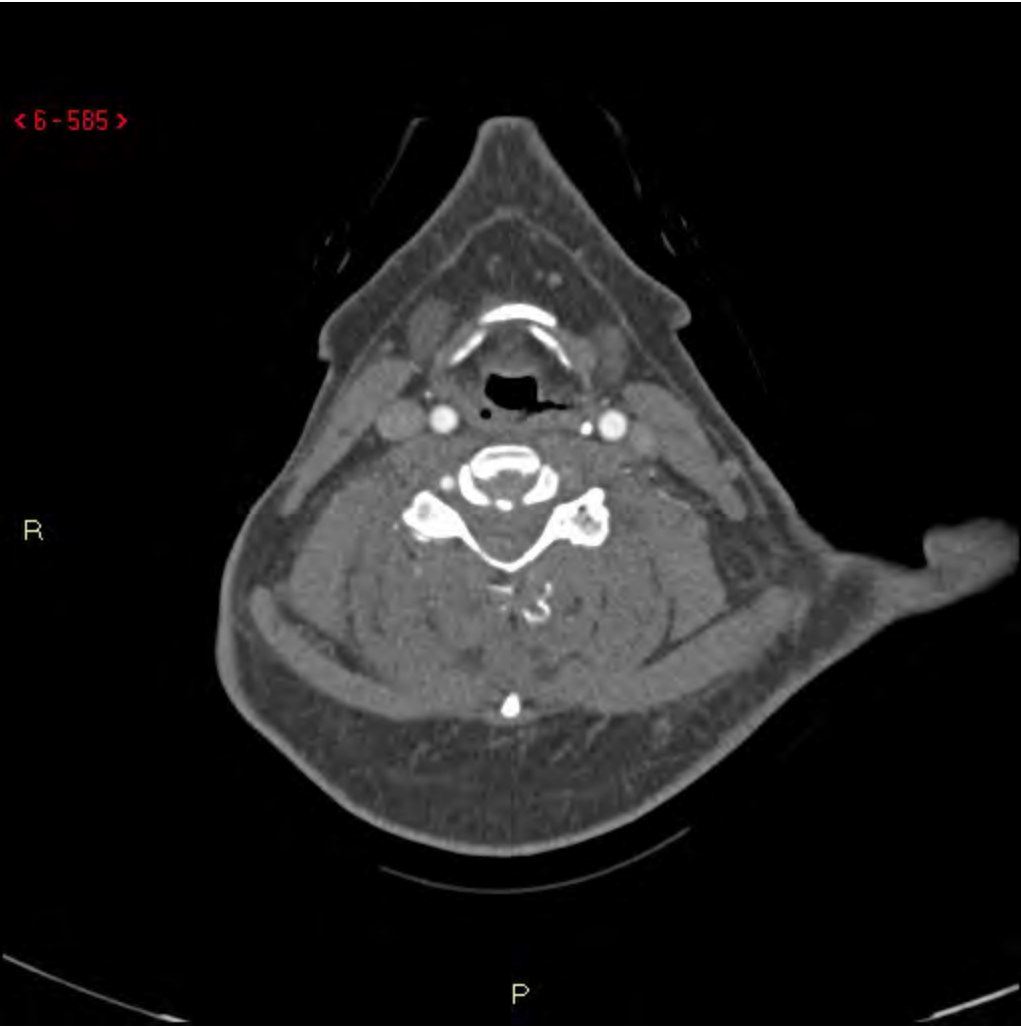



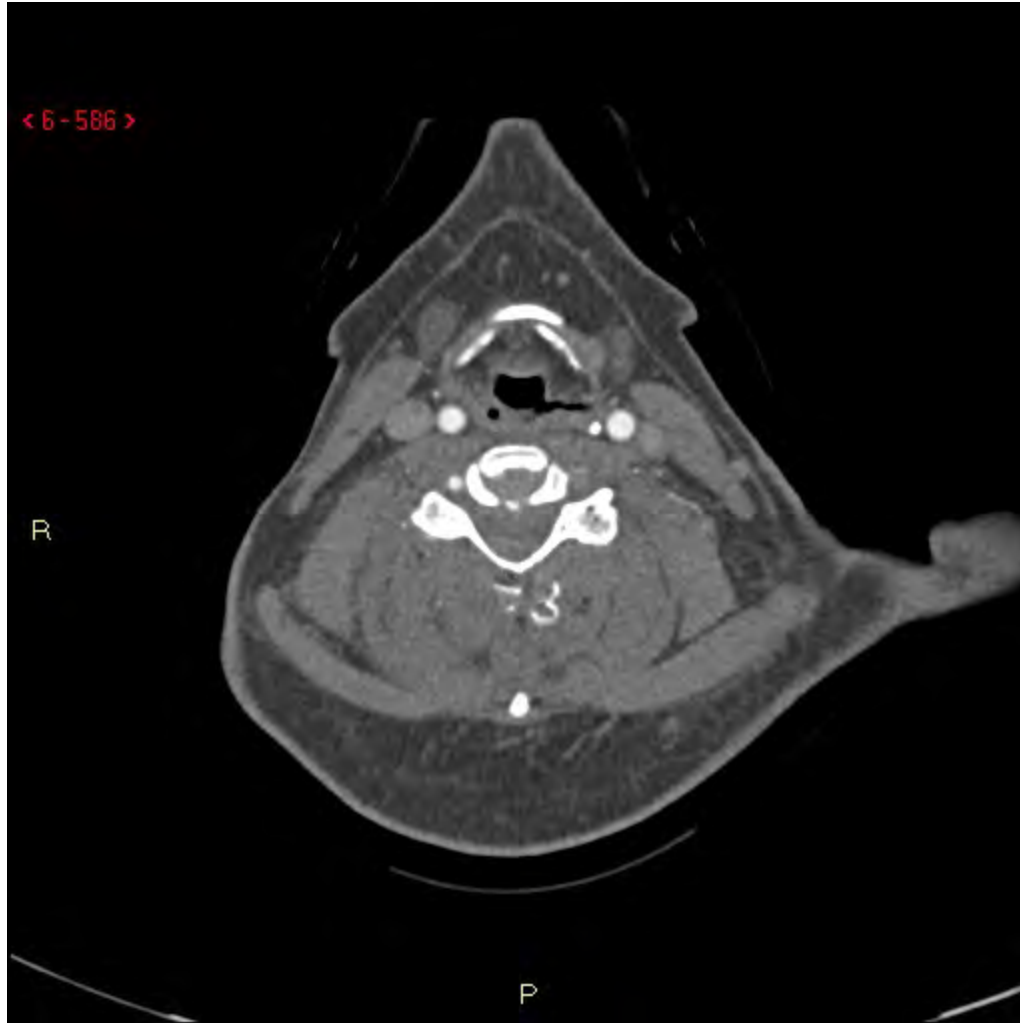


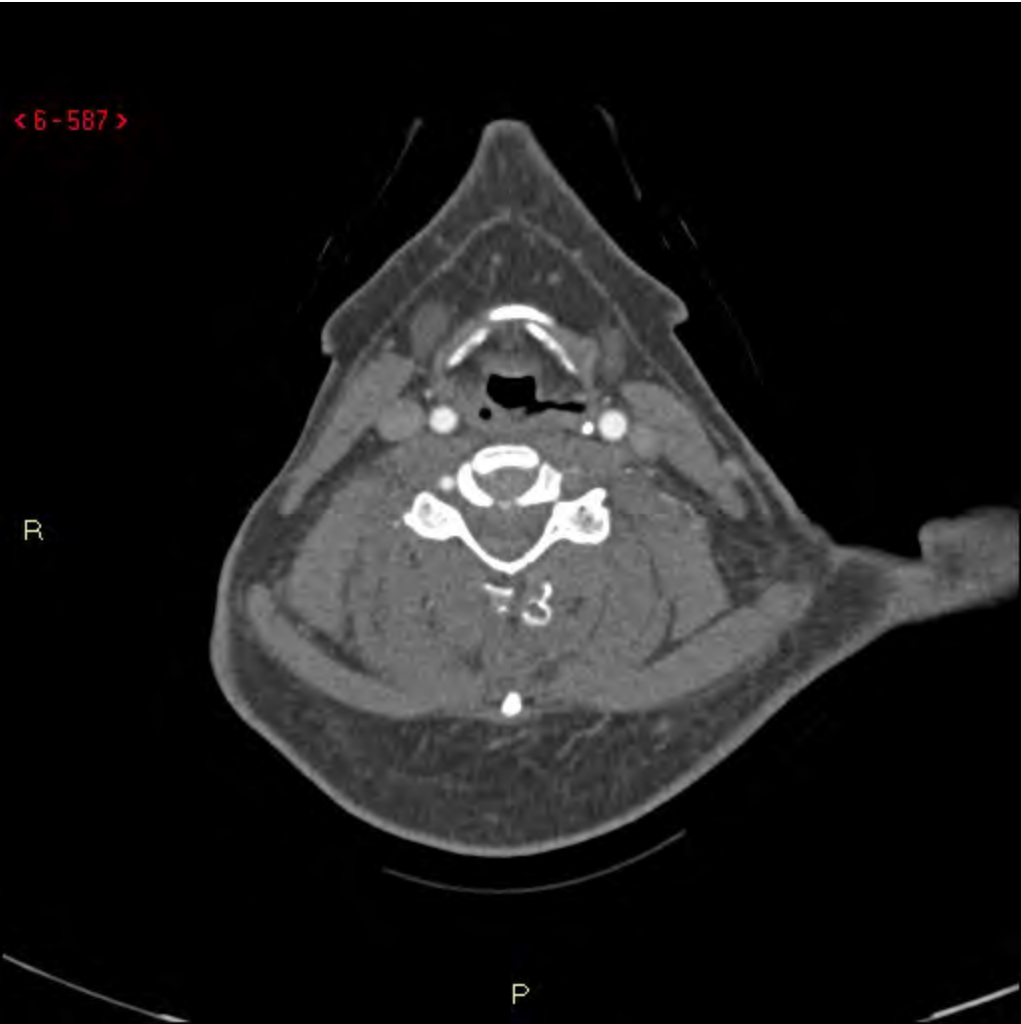


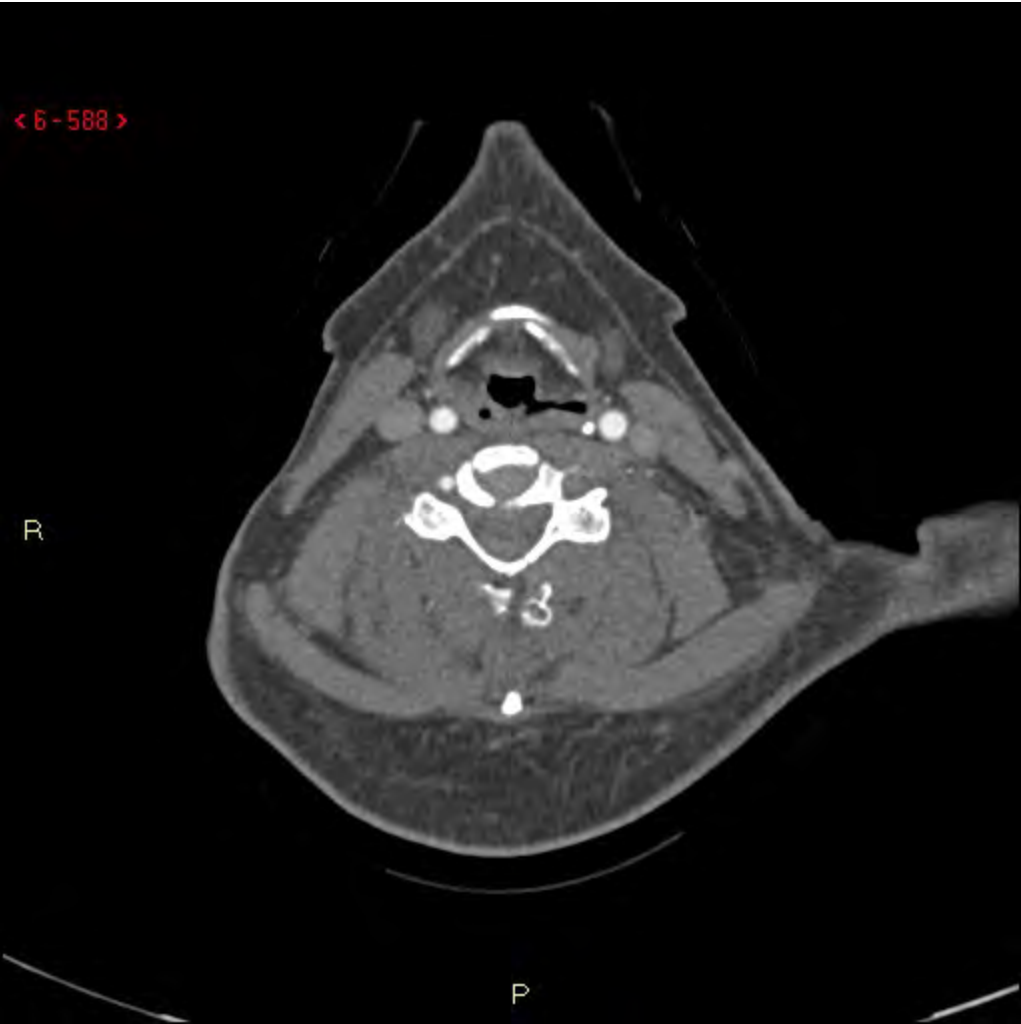


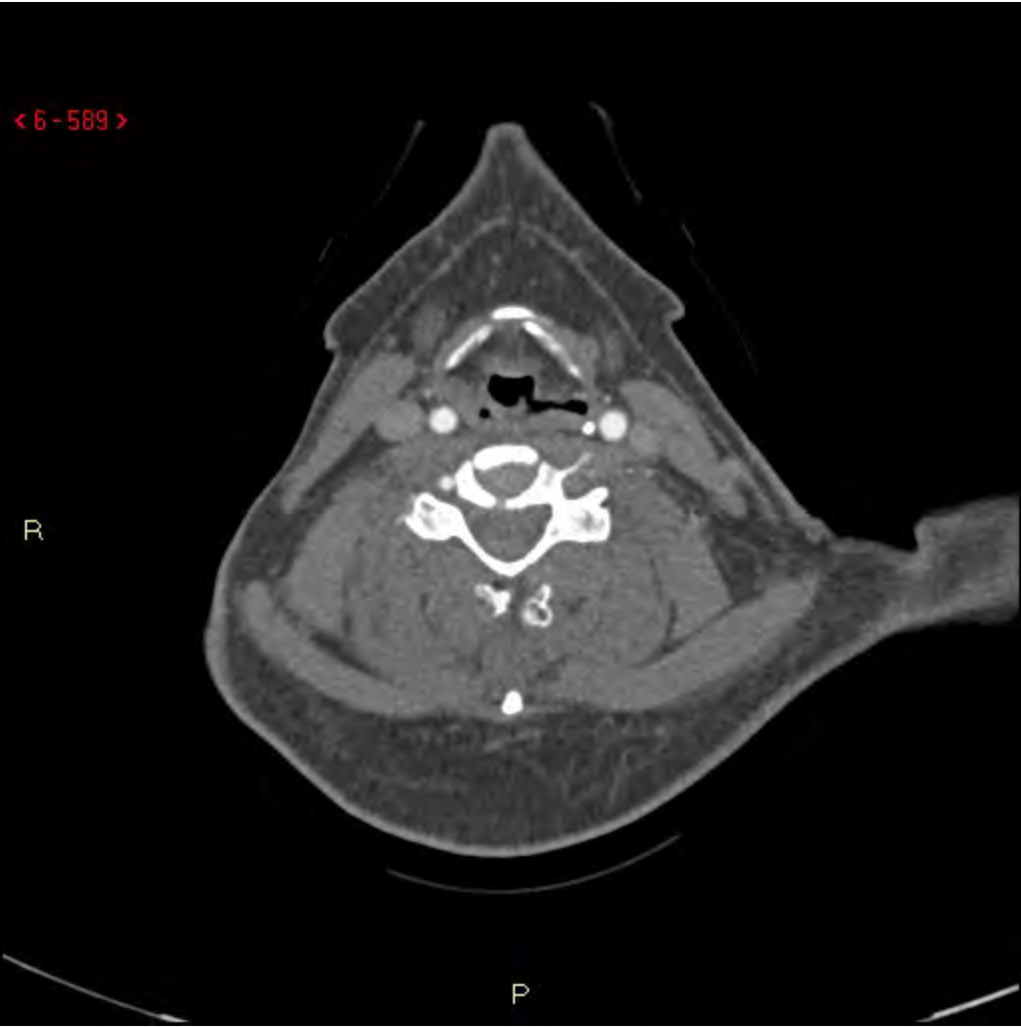


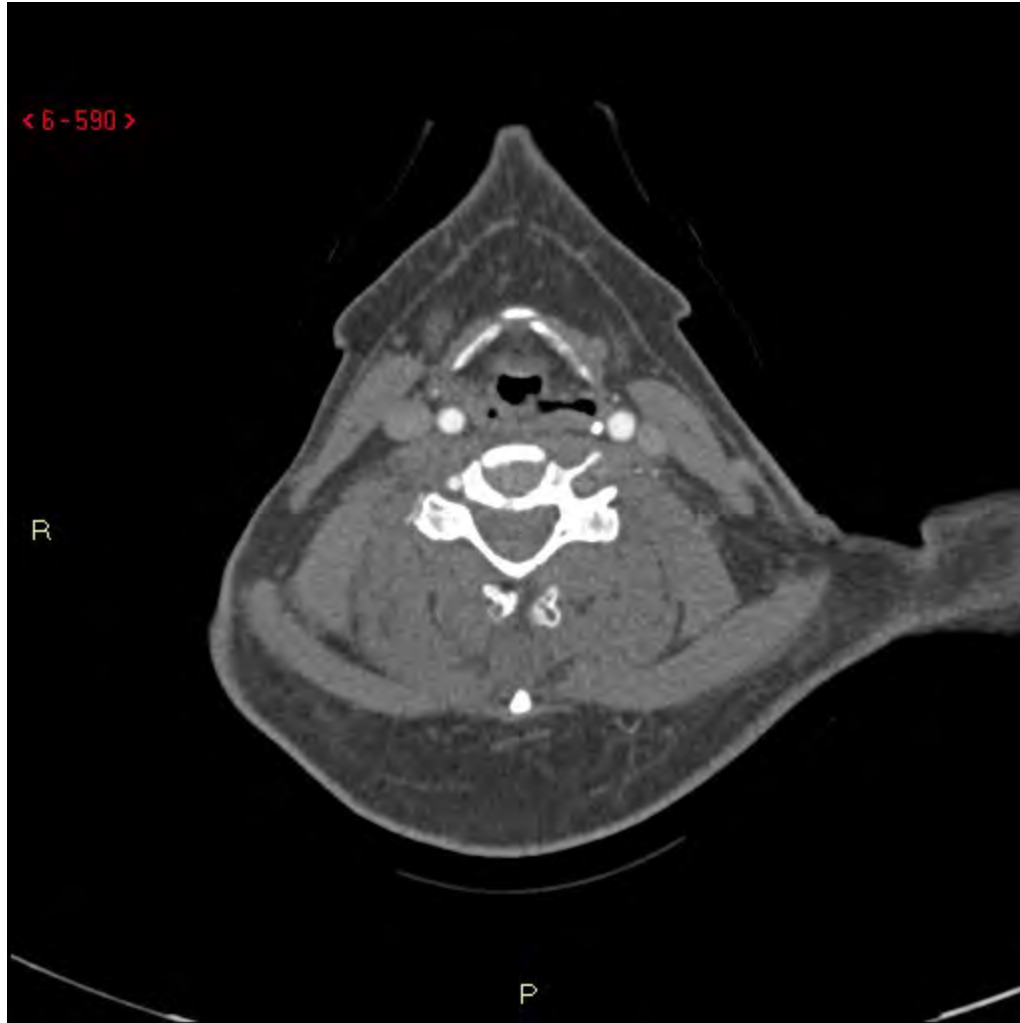




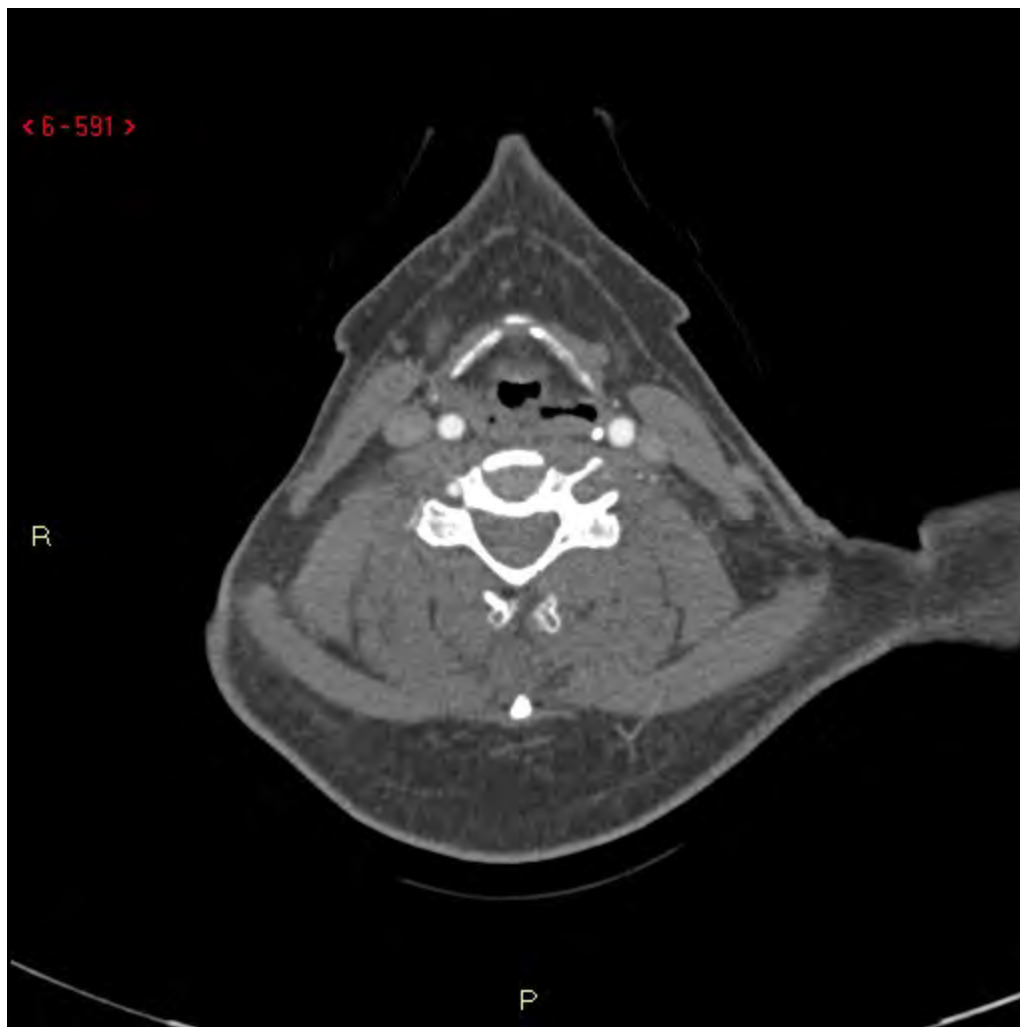


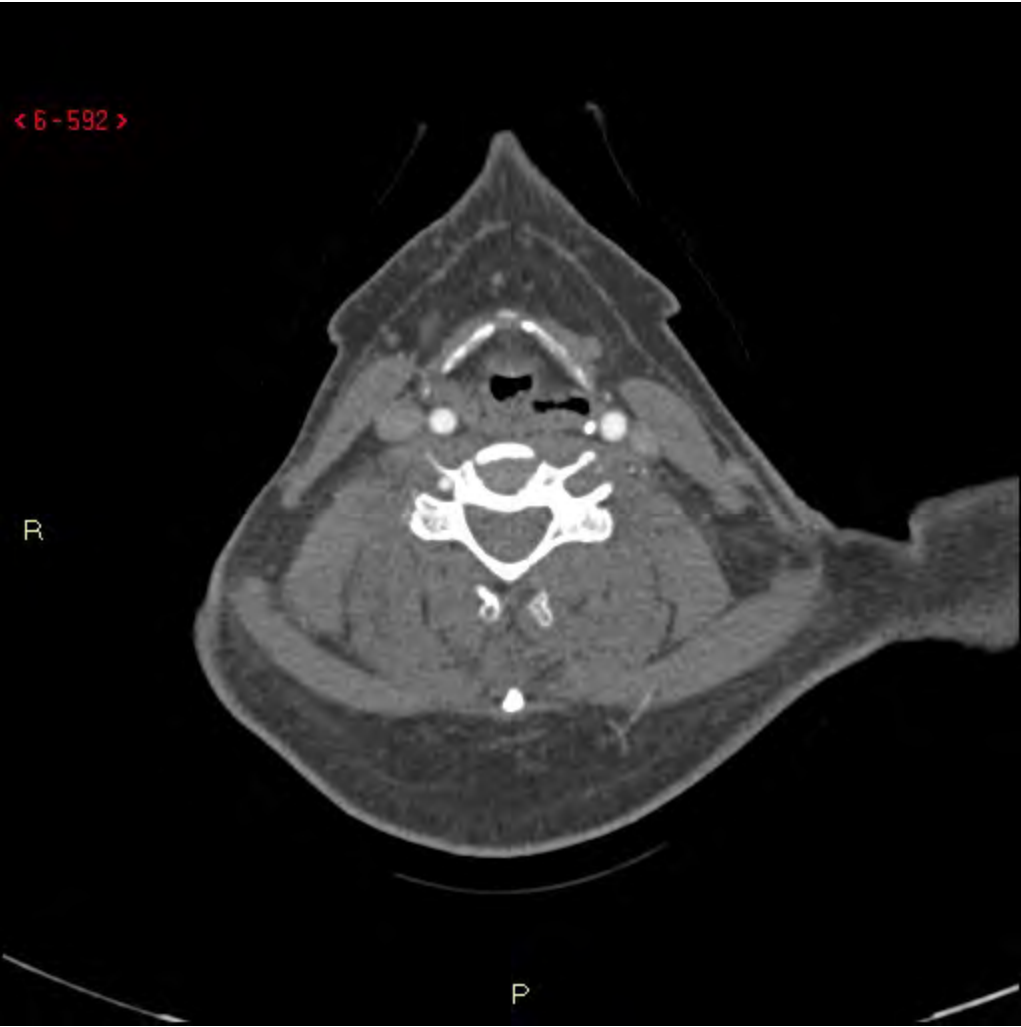




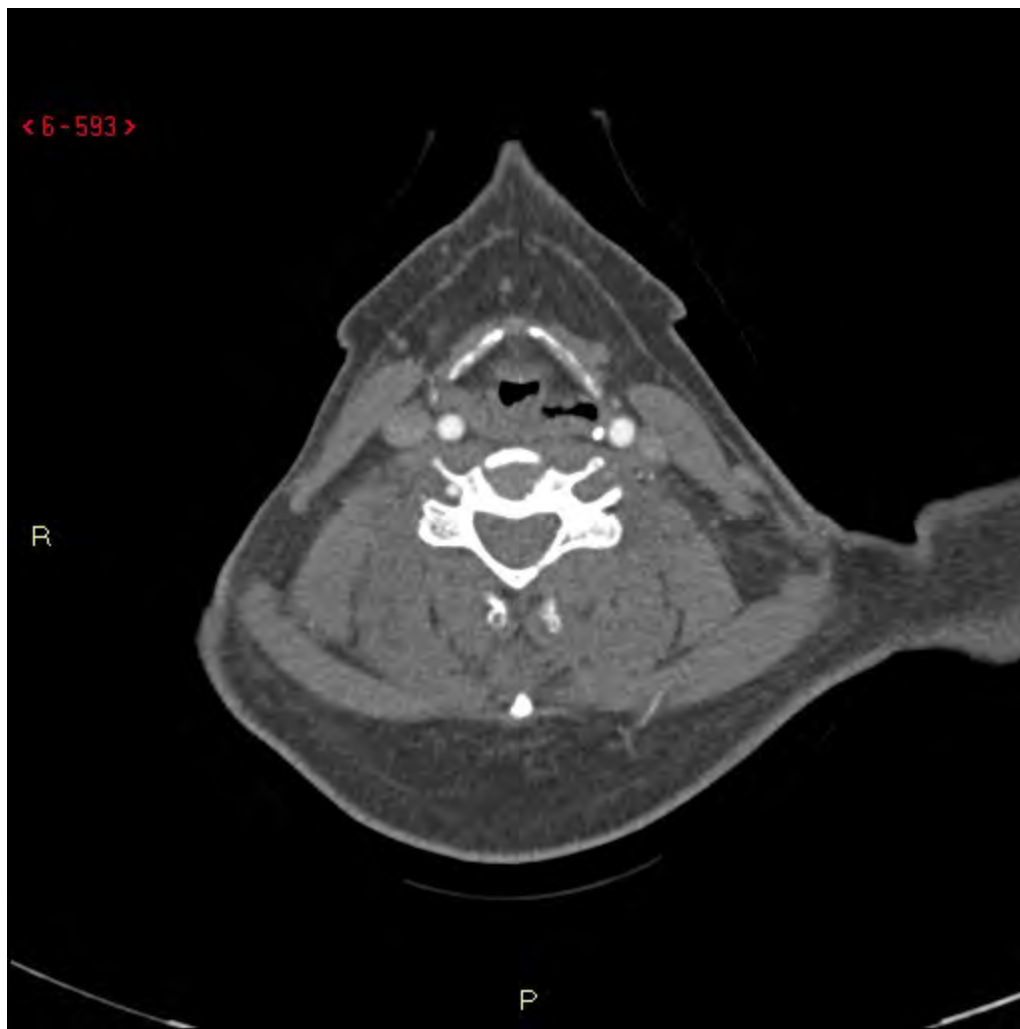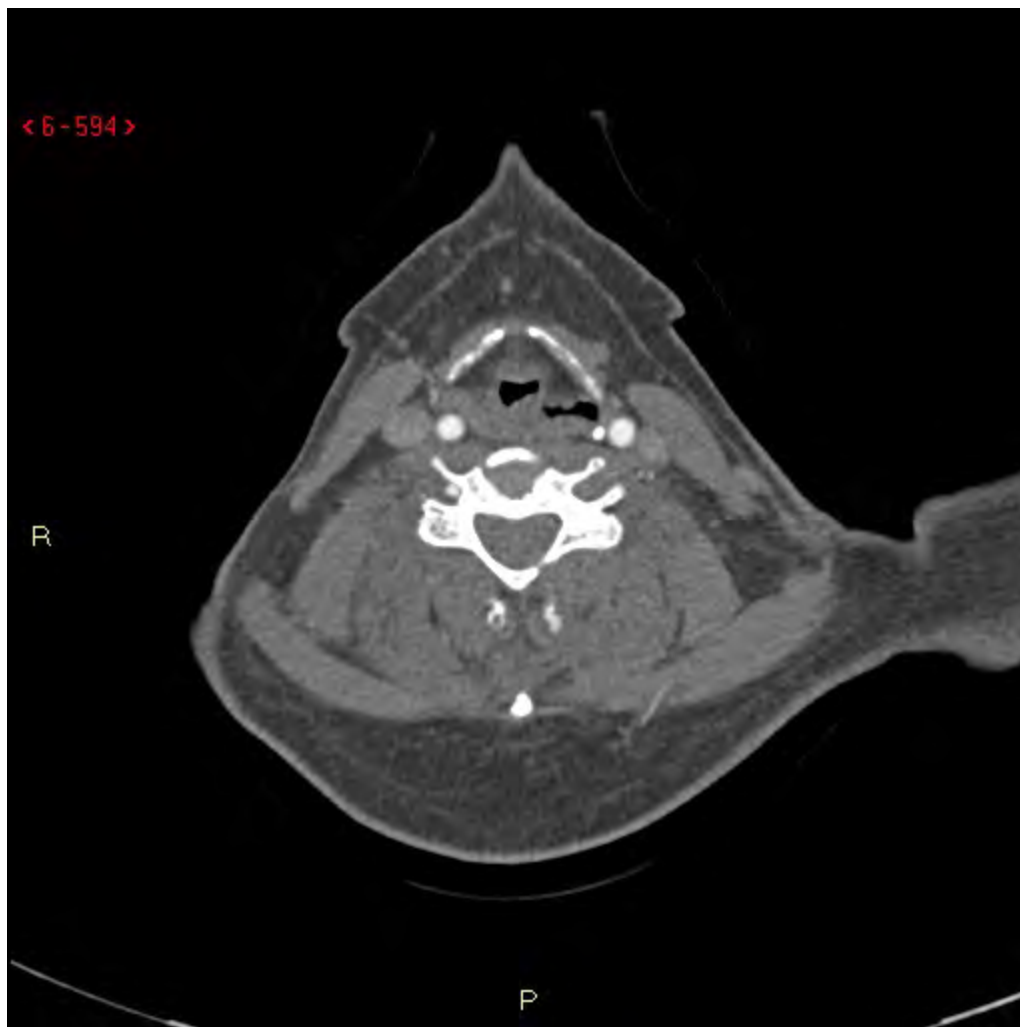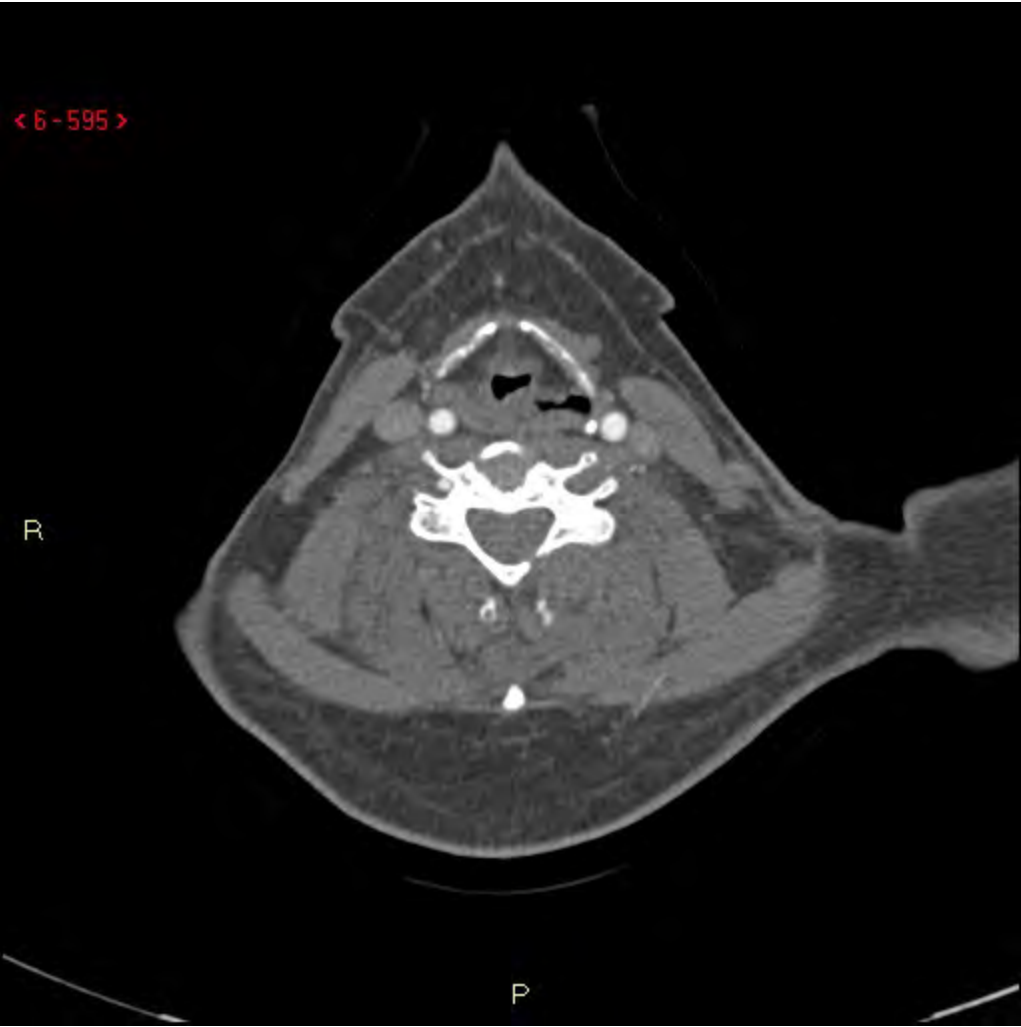< 6-593 >

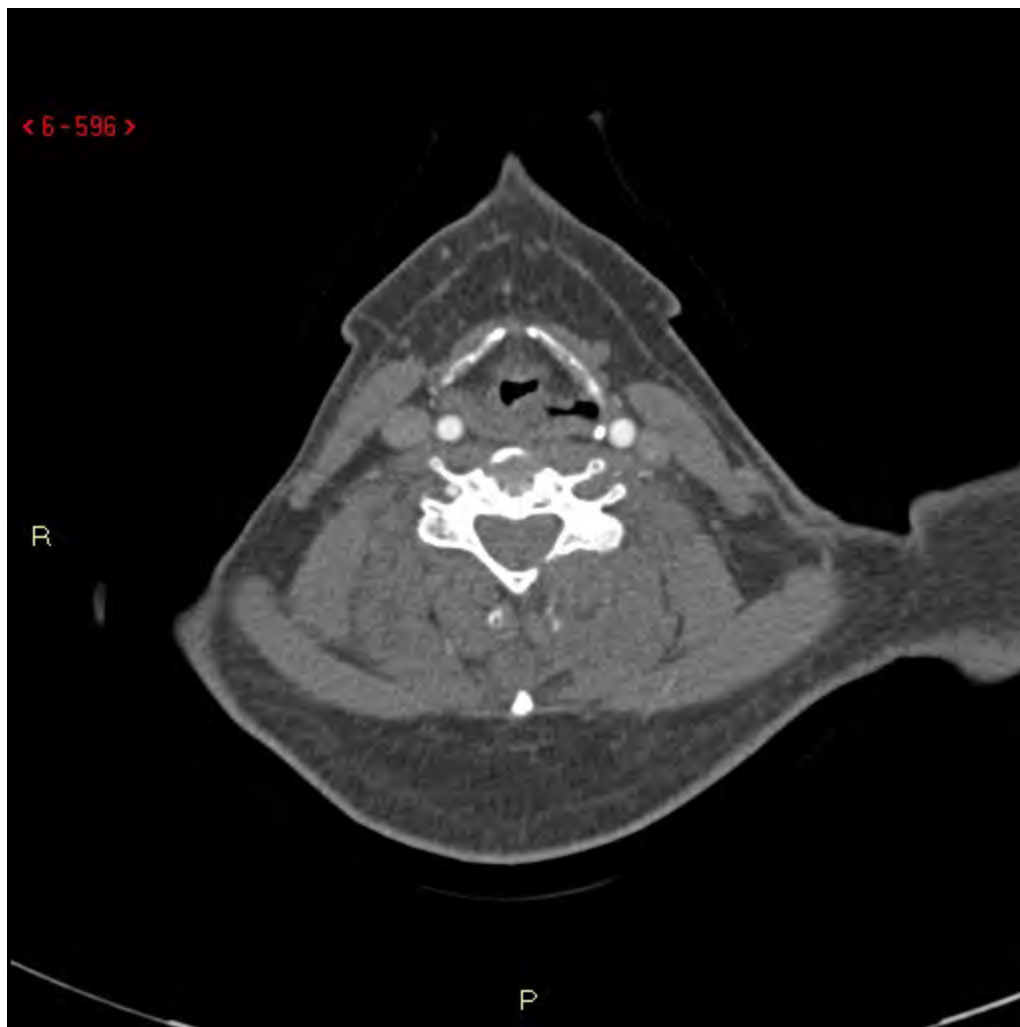R

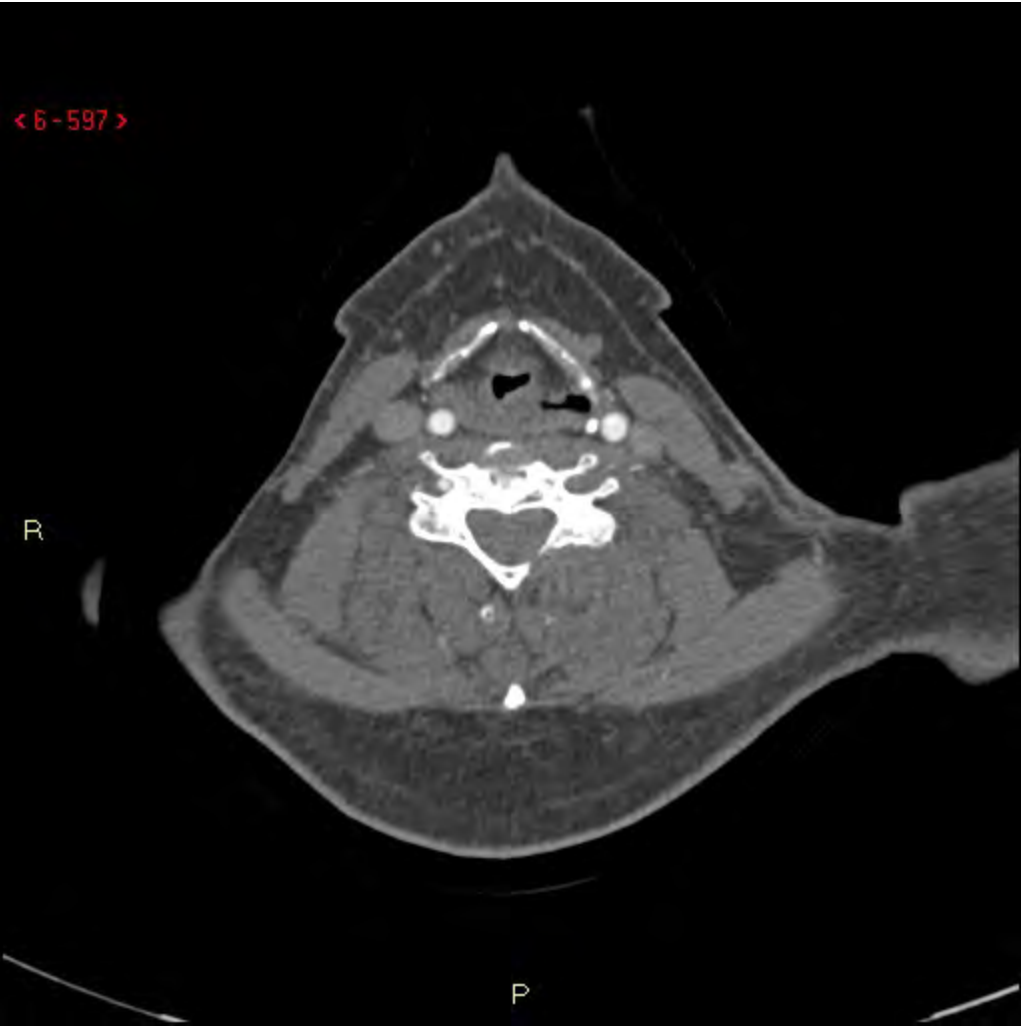P

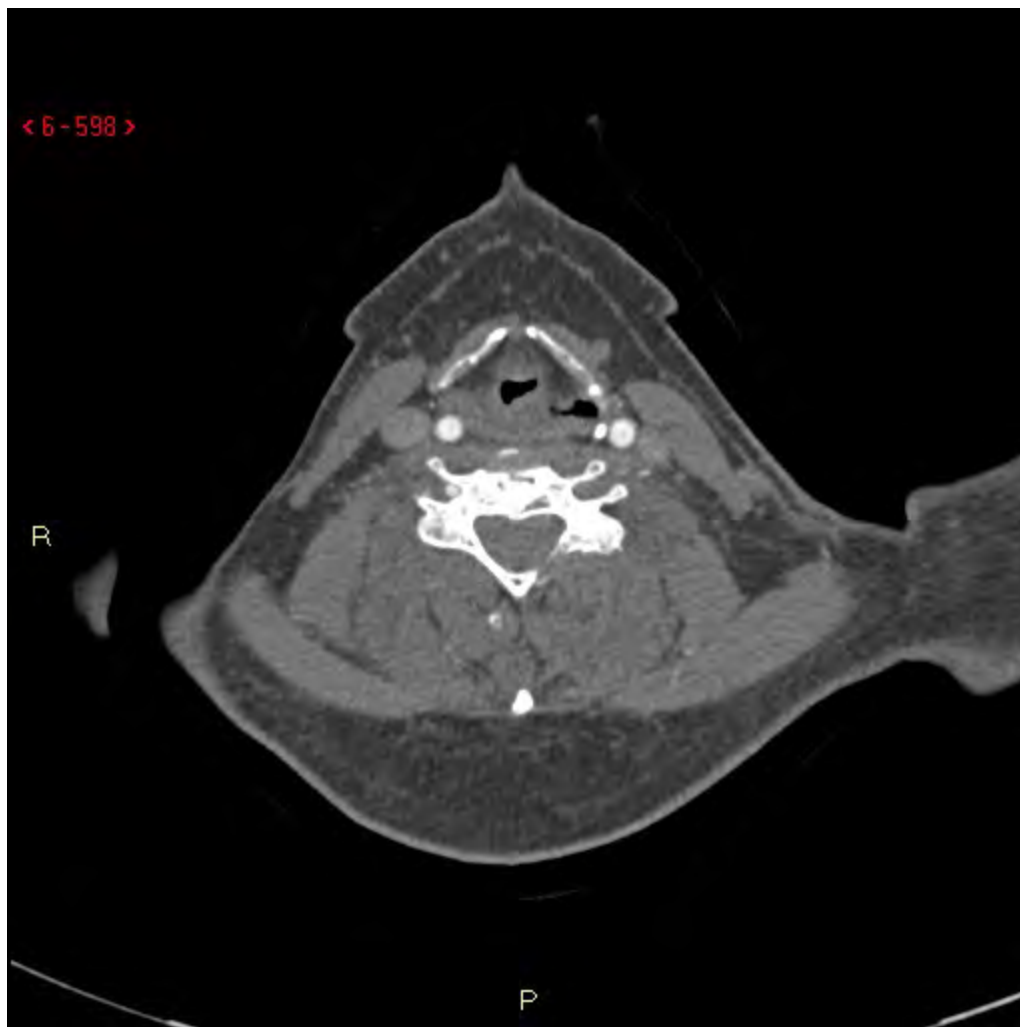




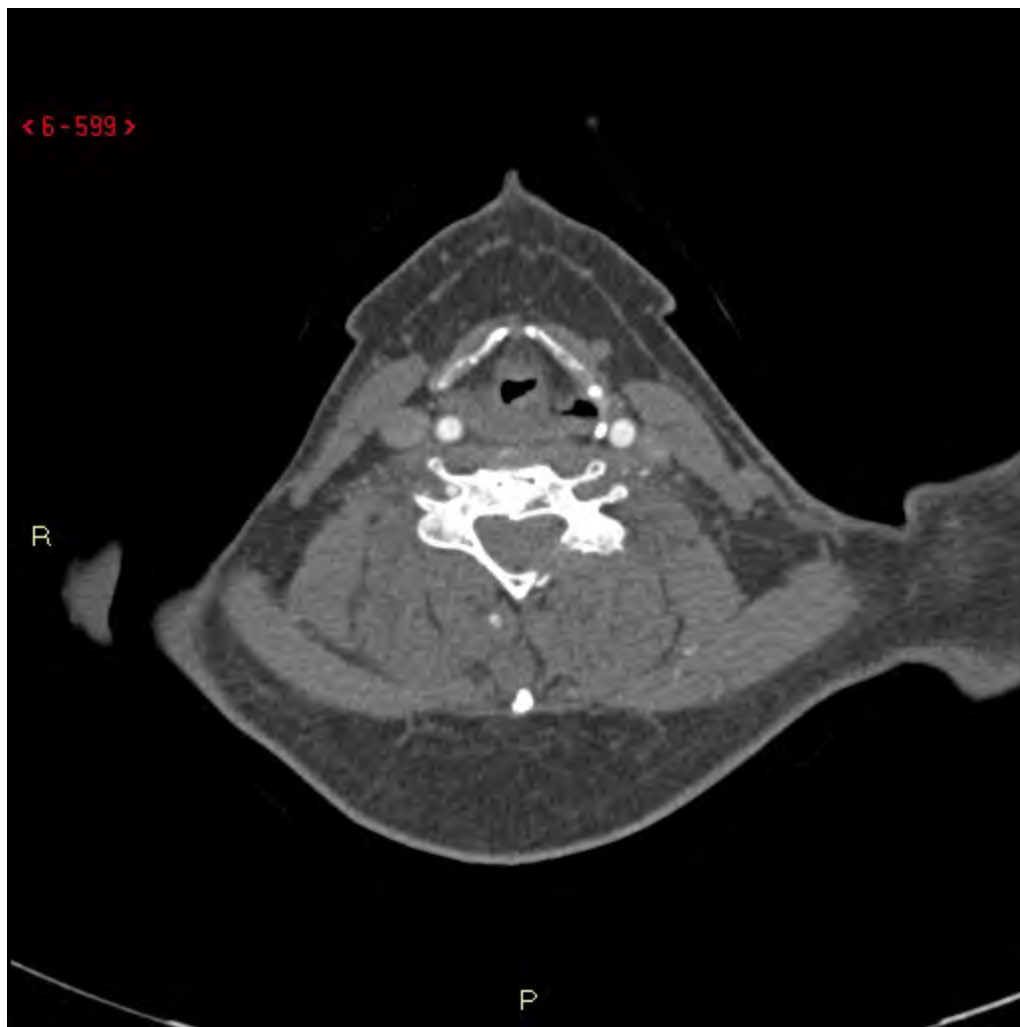


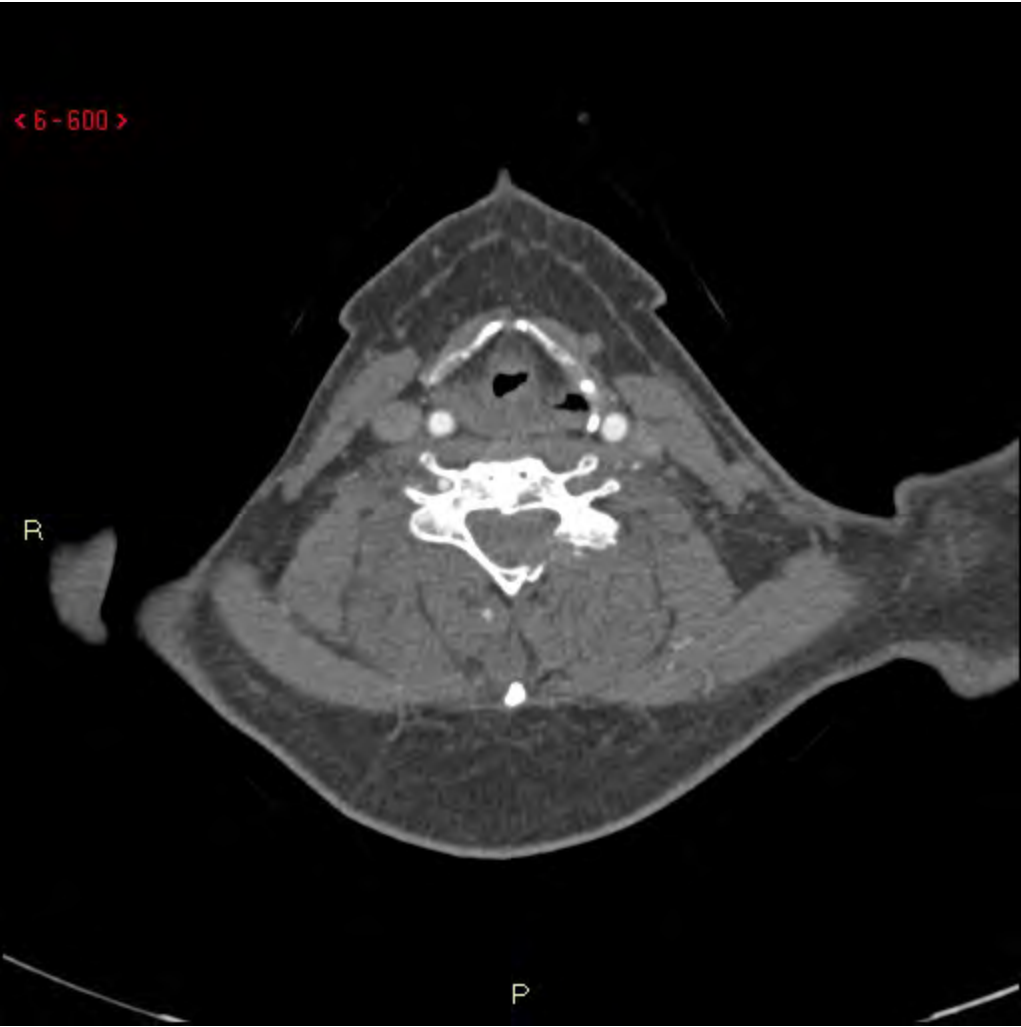


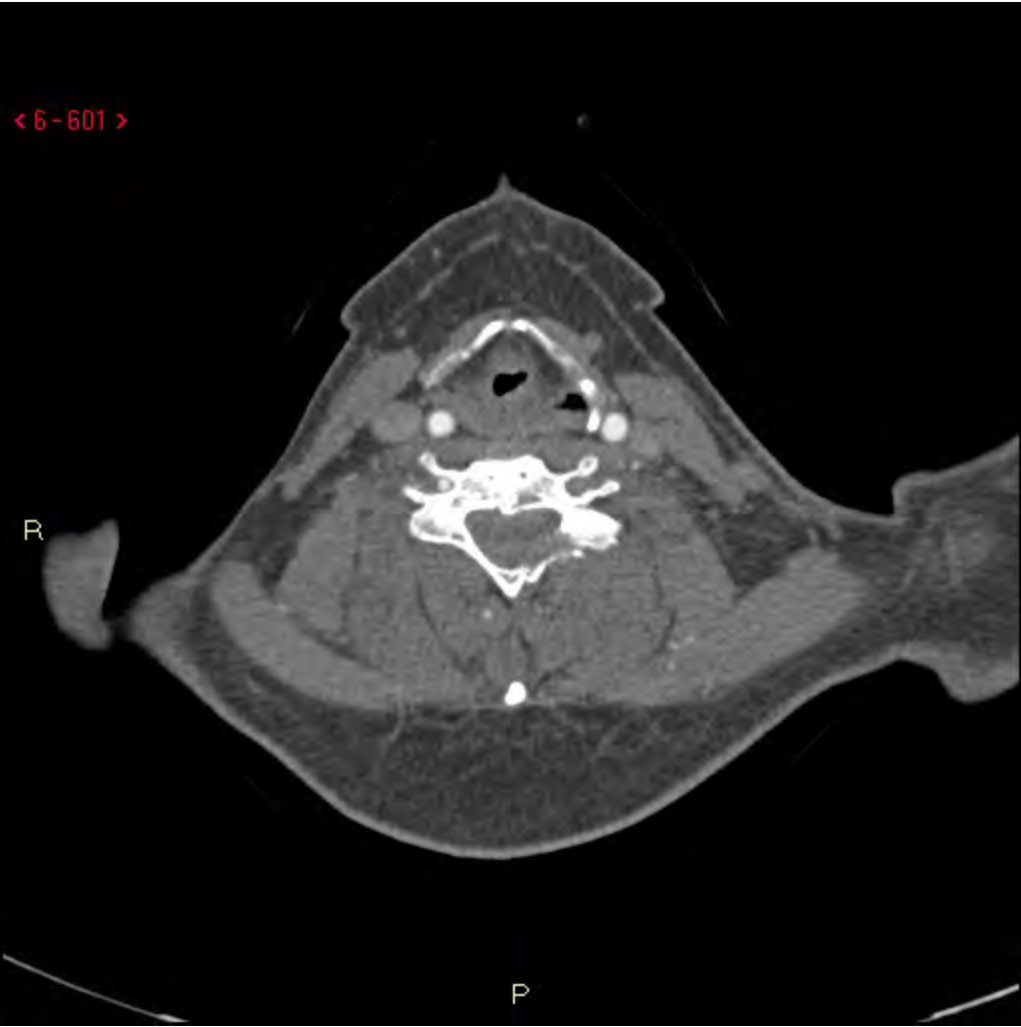


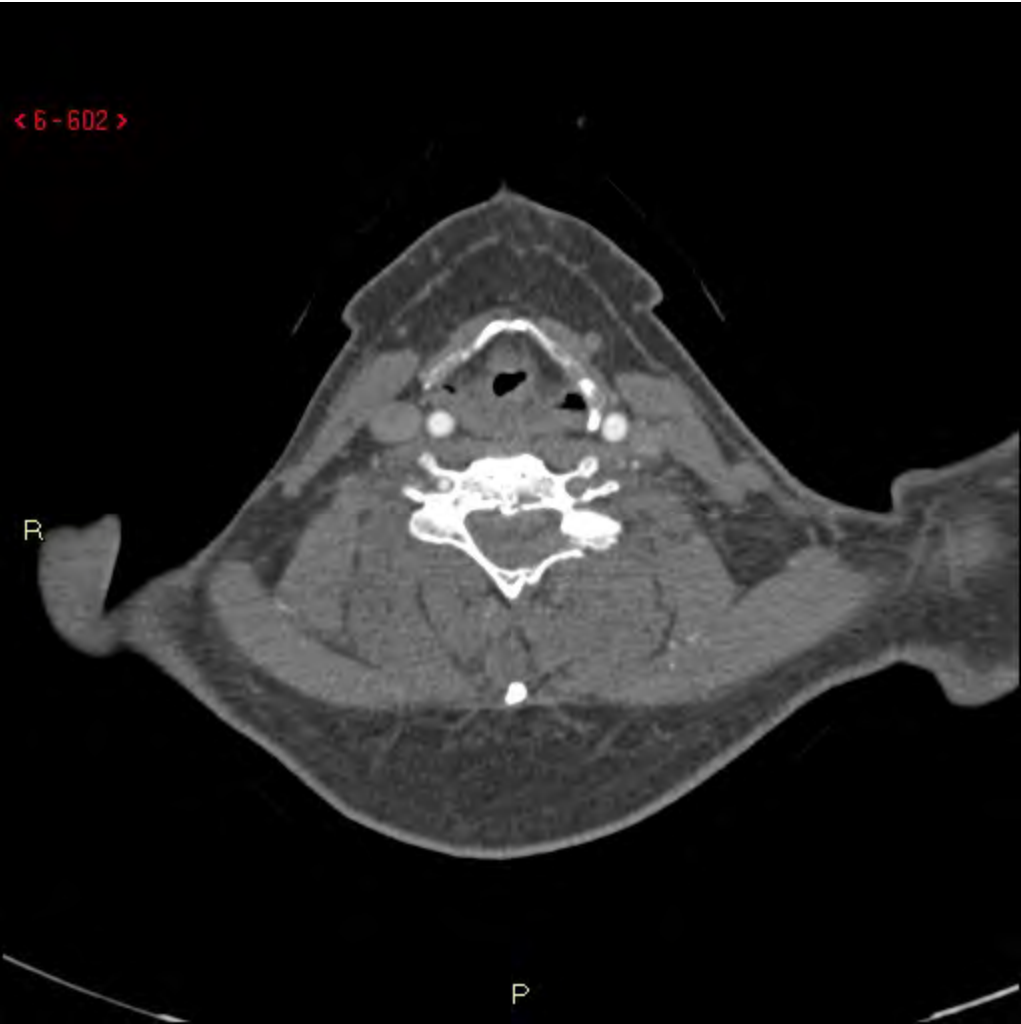


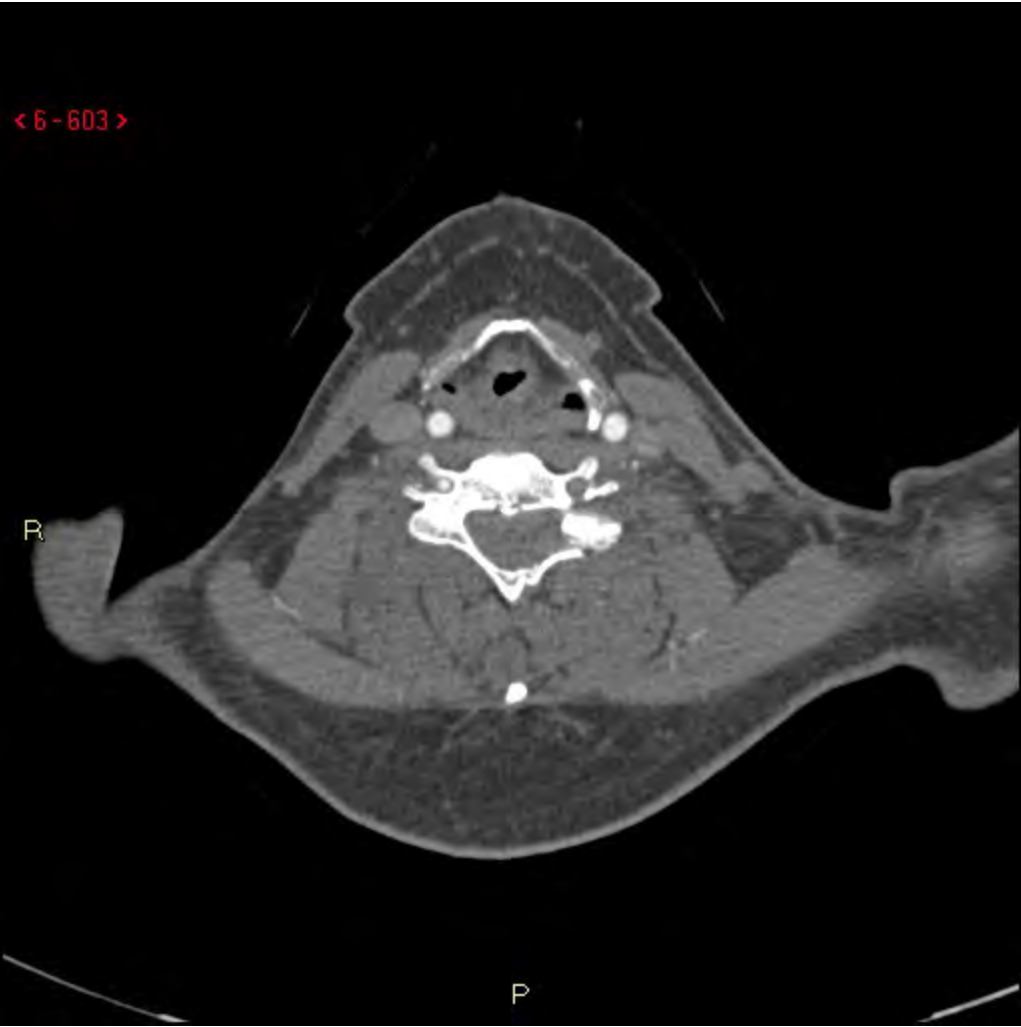


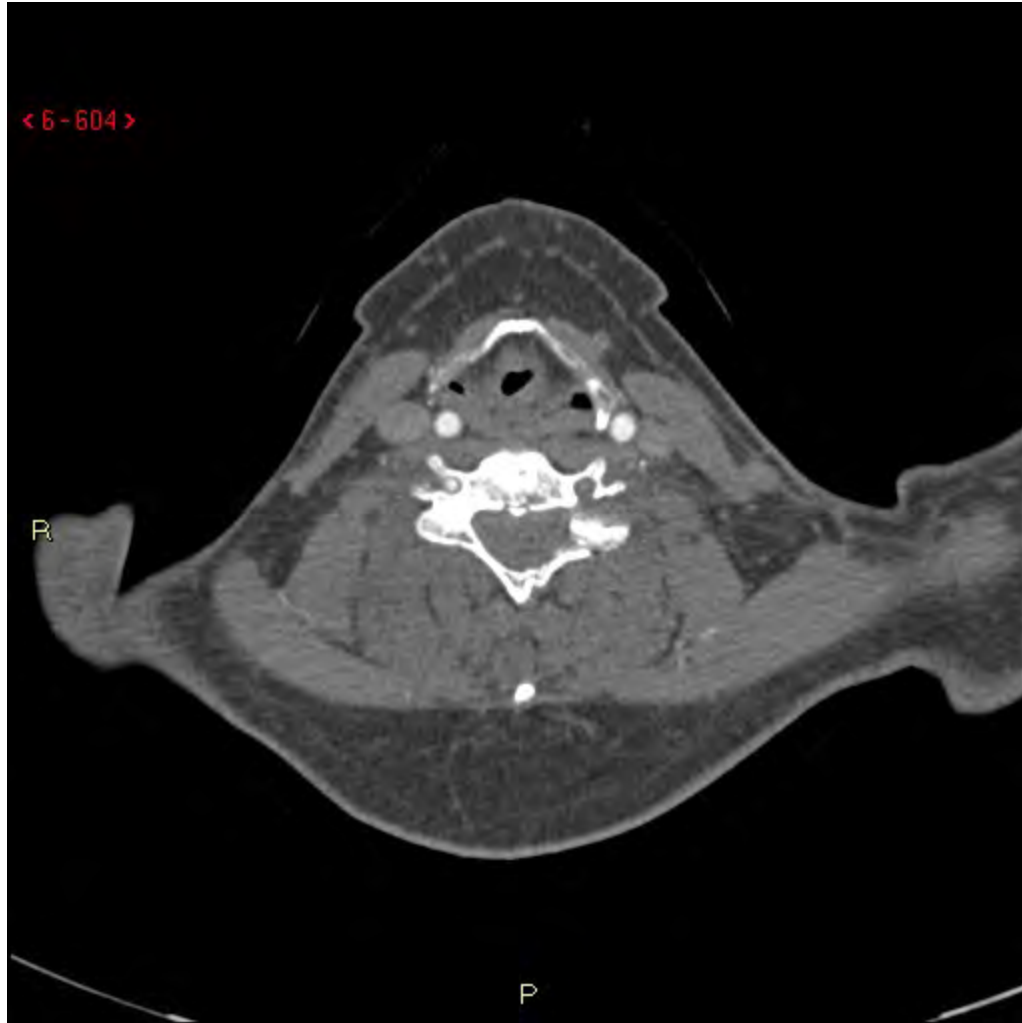


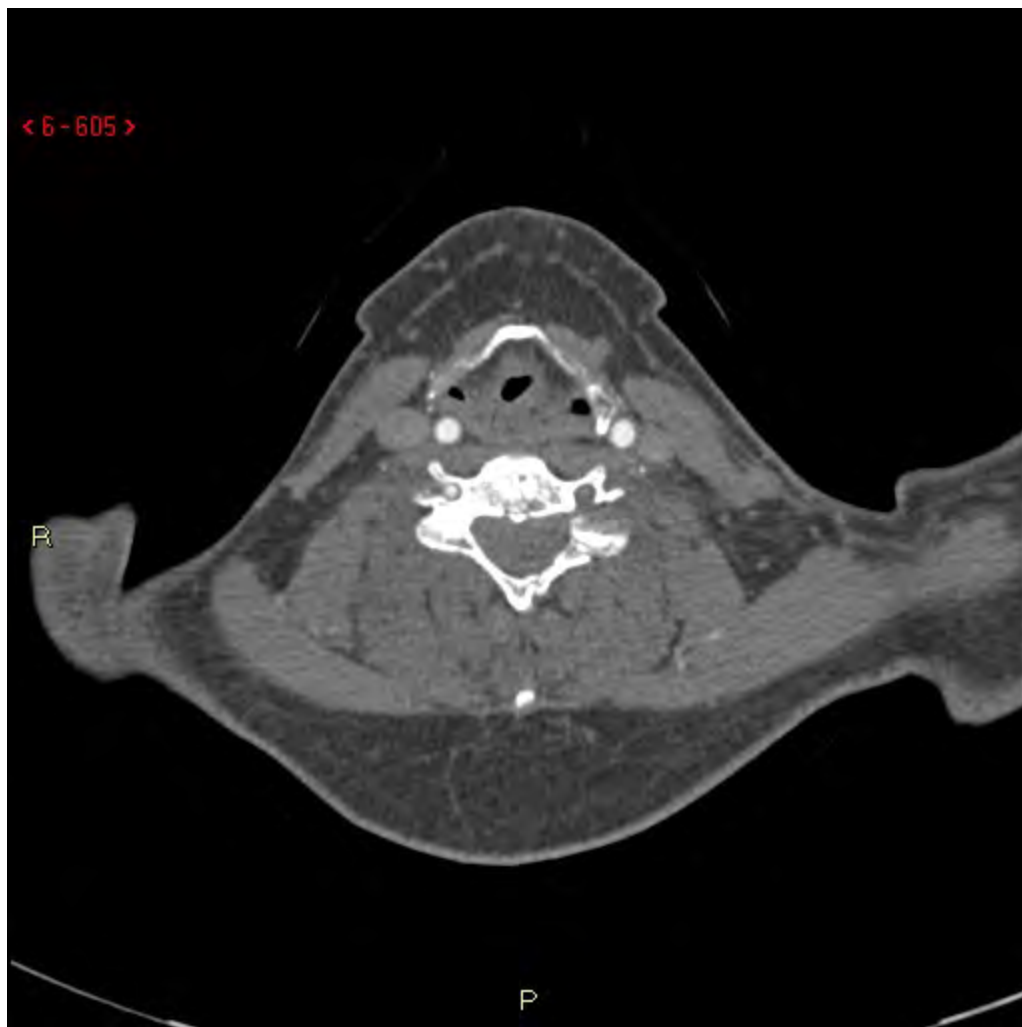


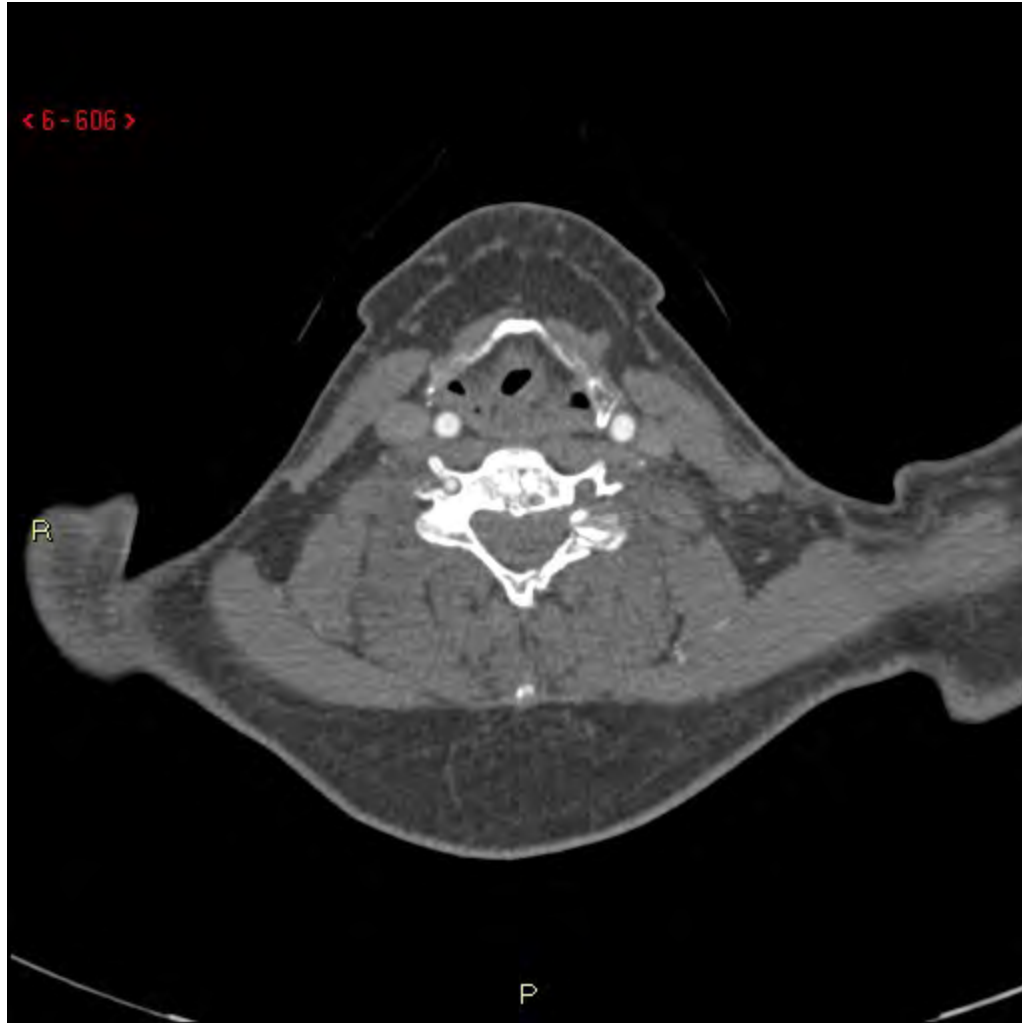




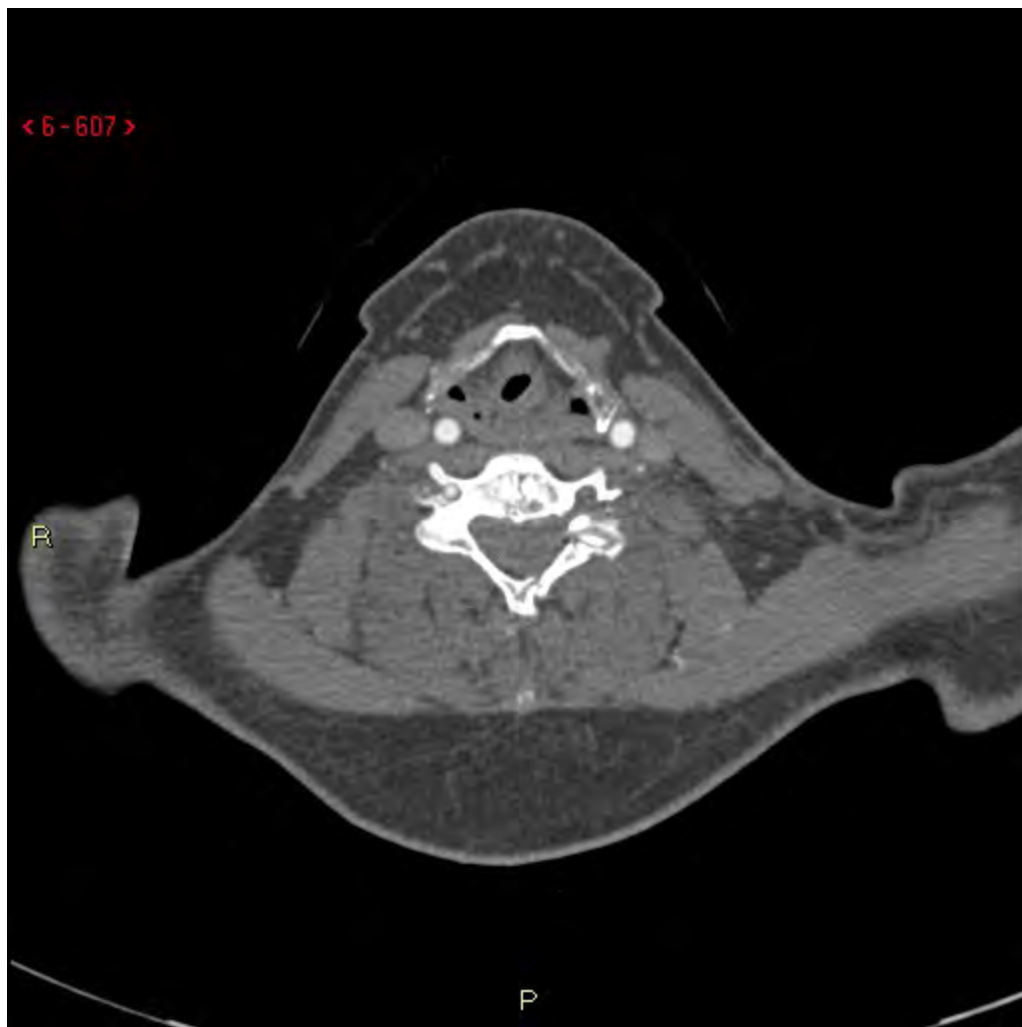


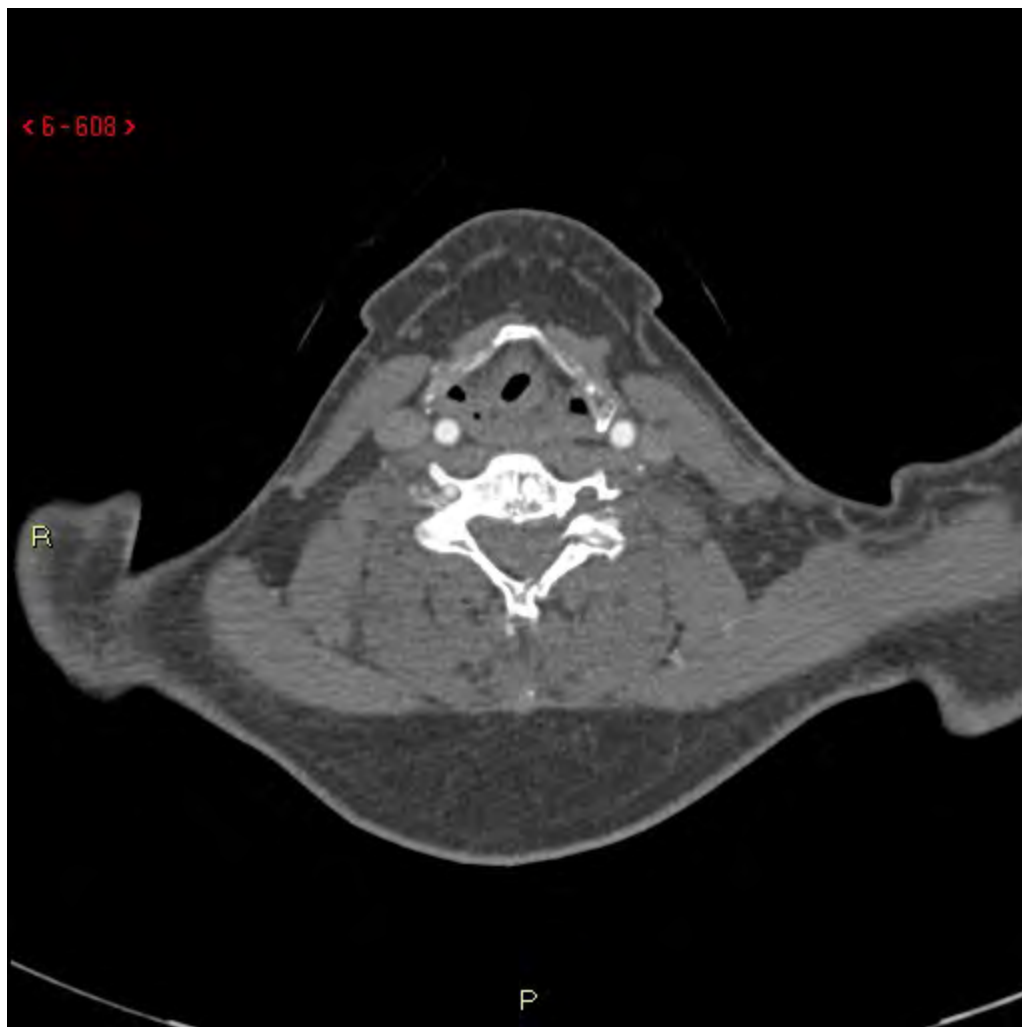


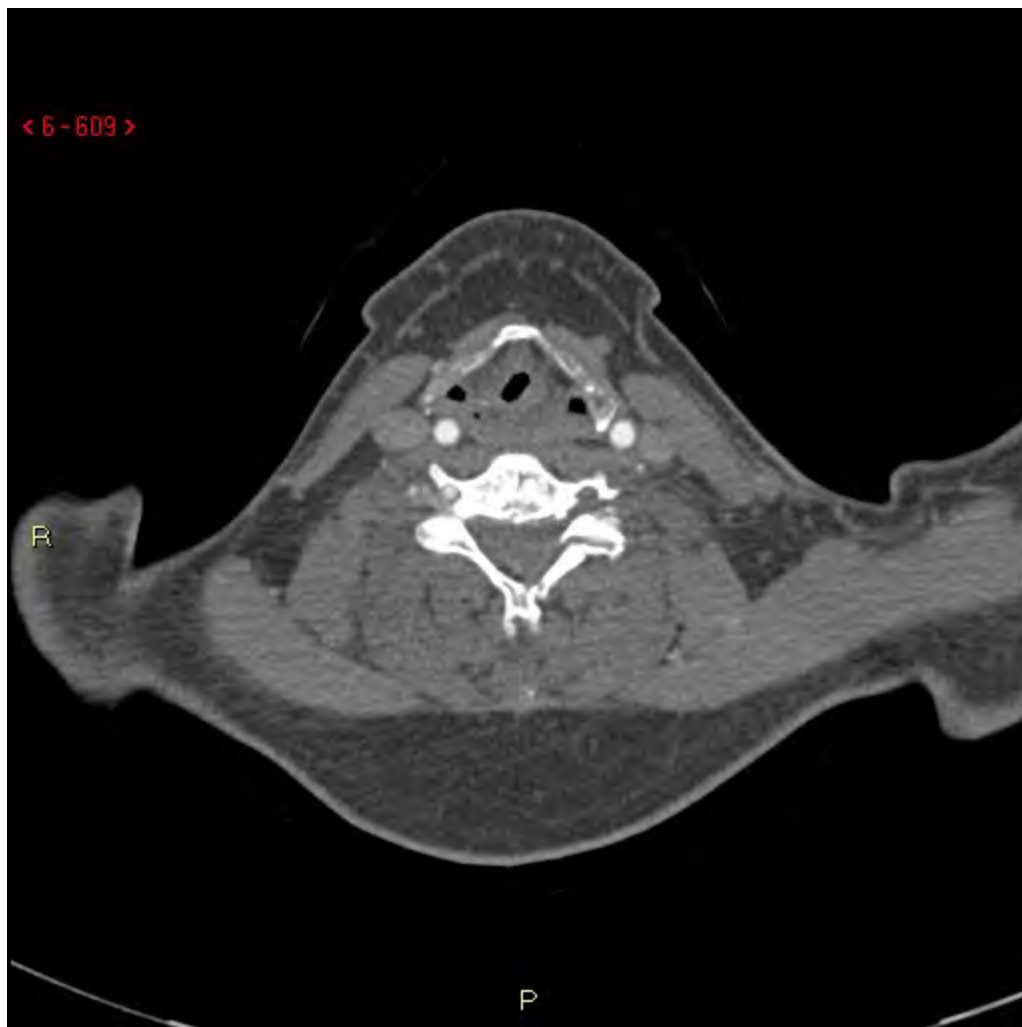


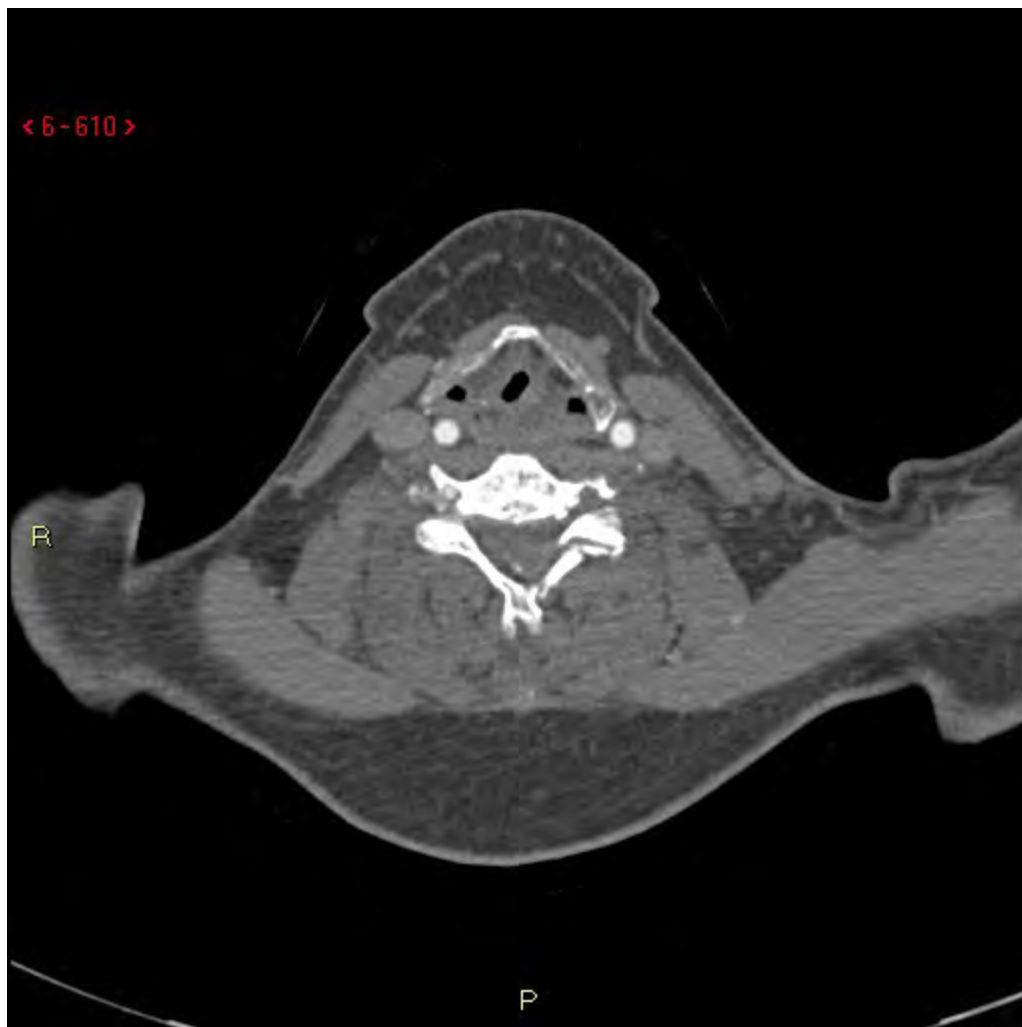


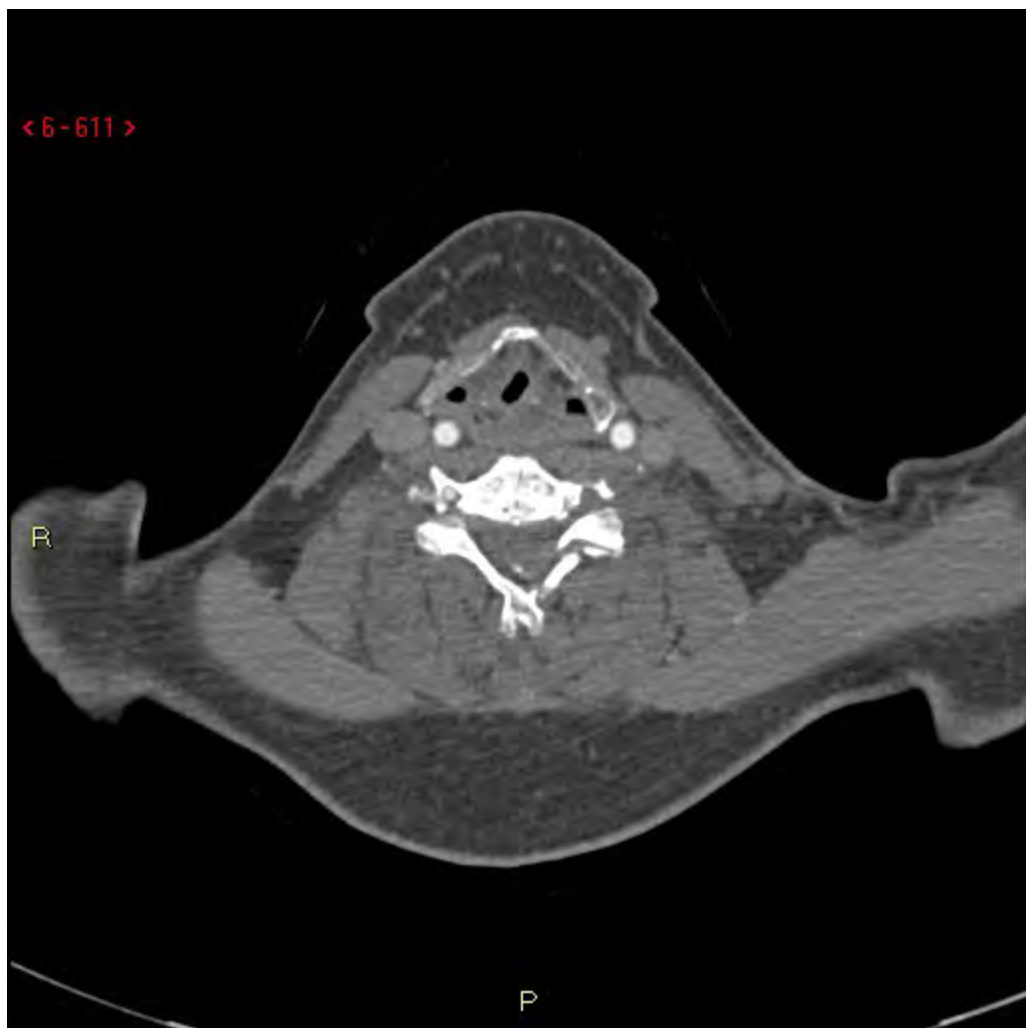


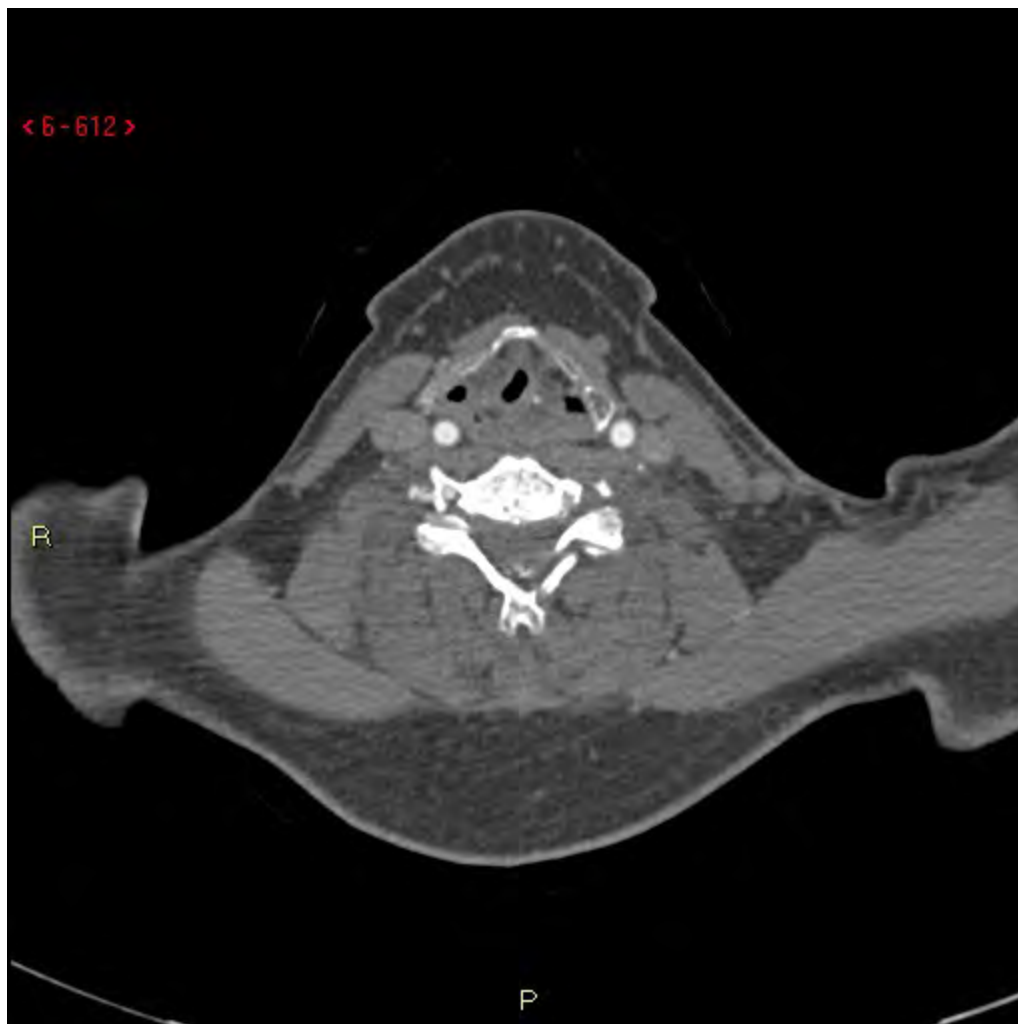


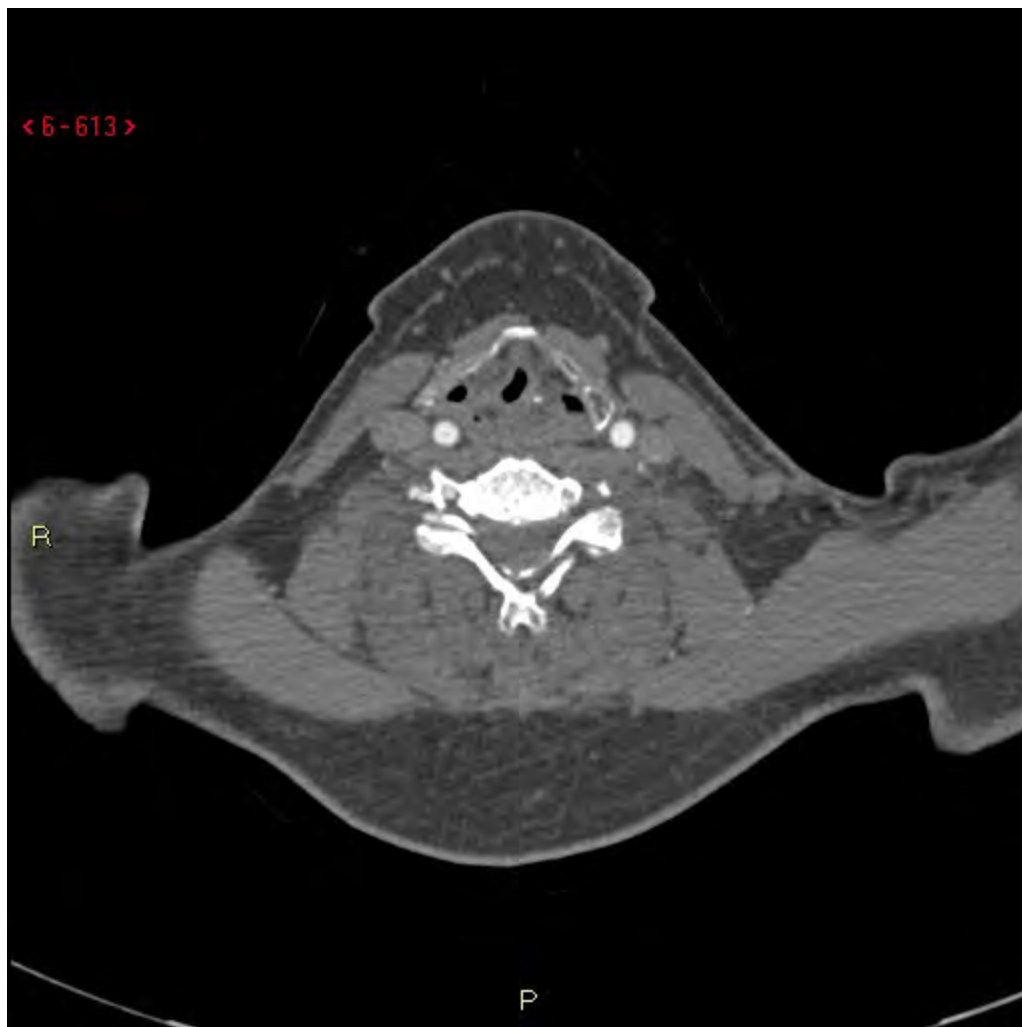


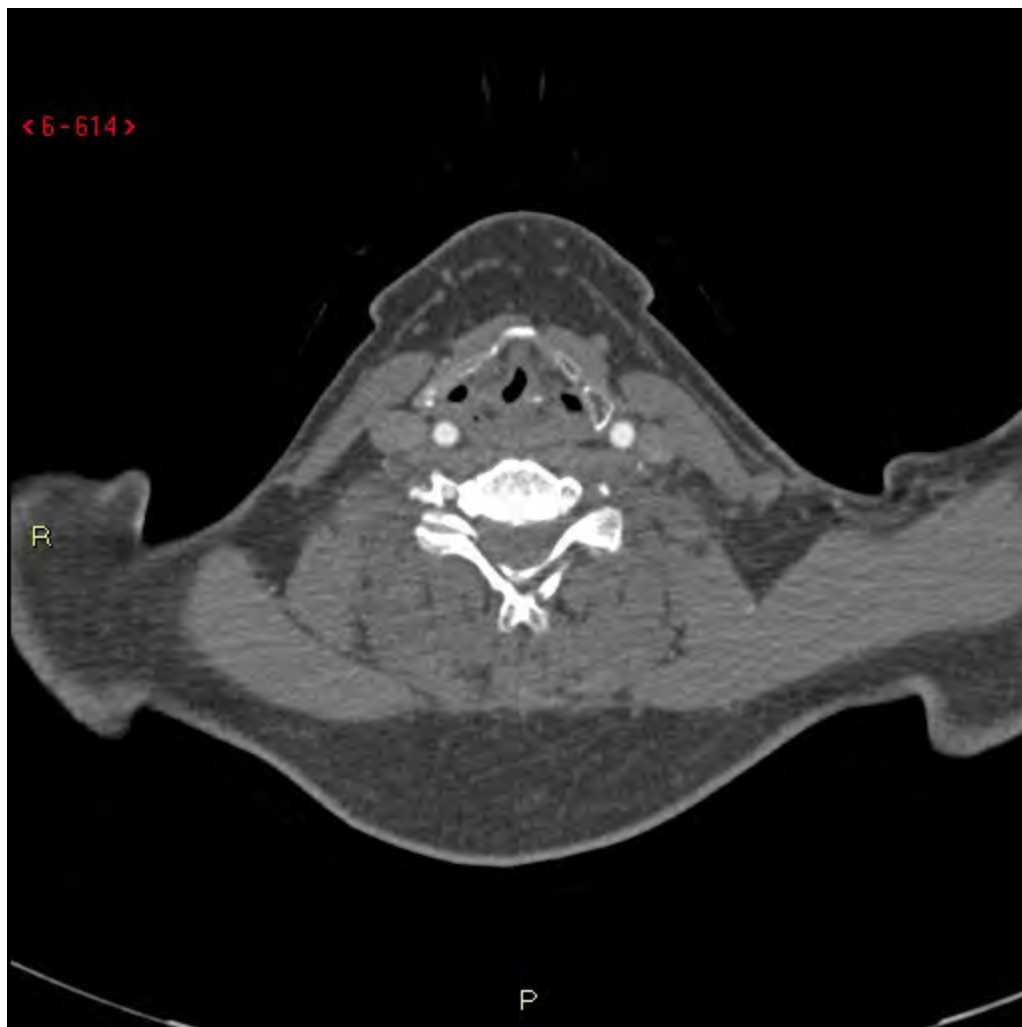




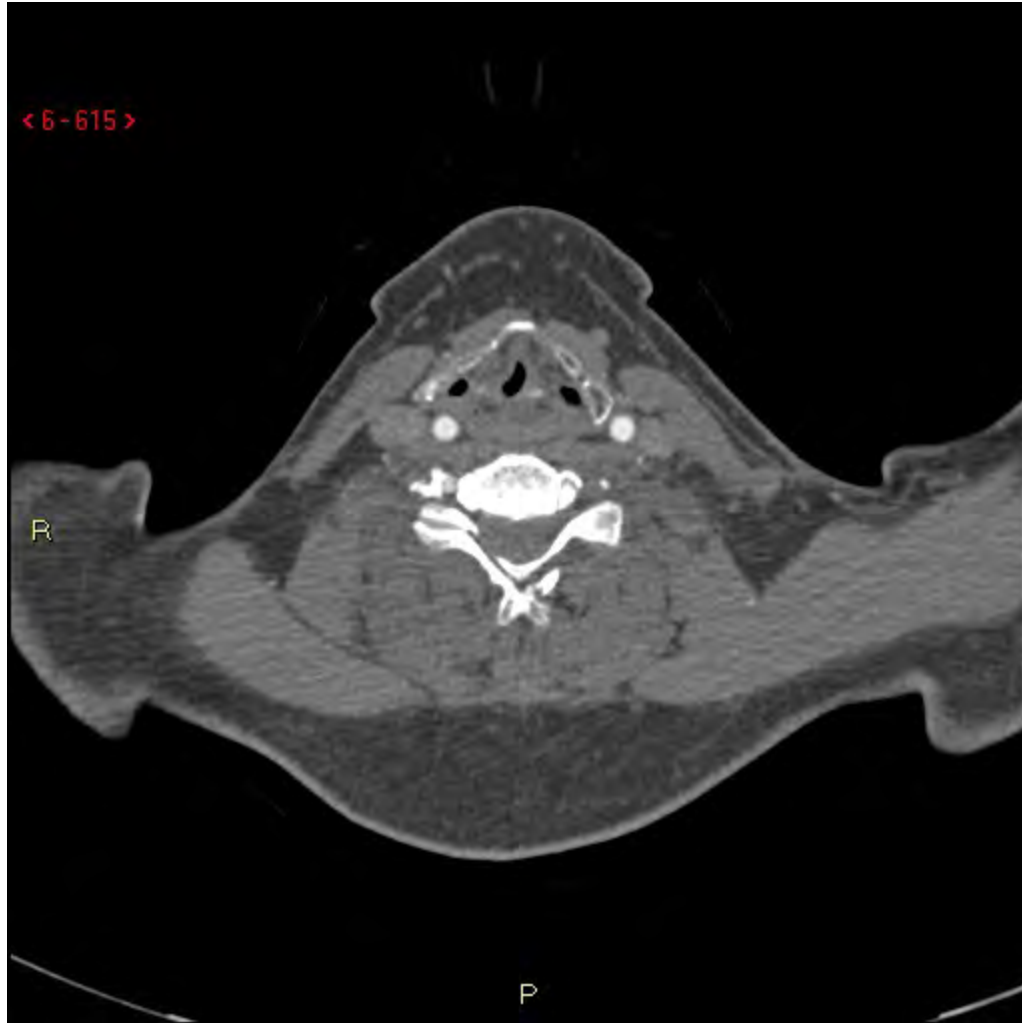


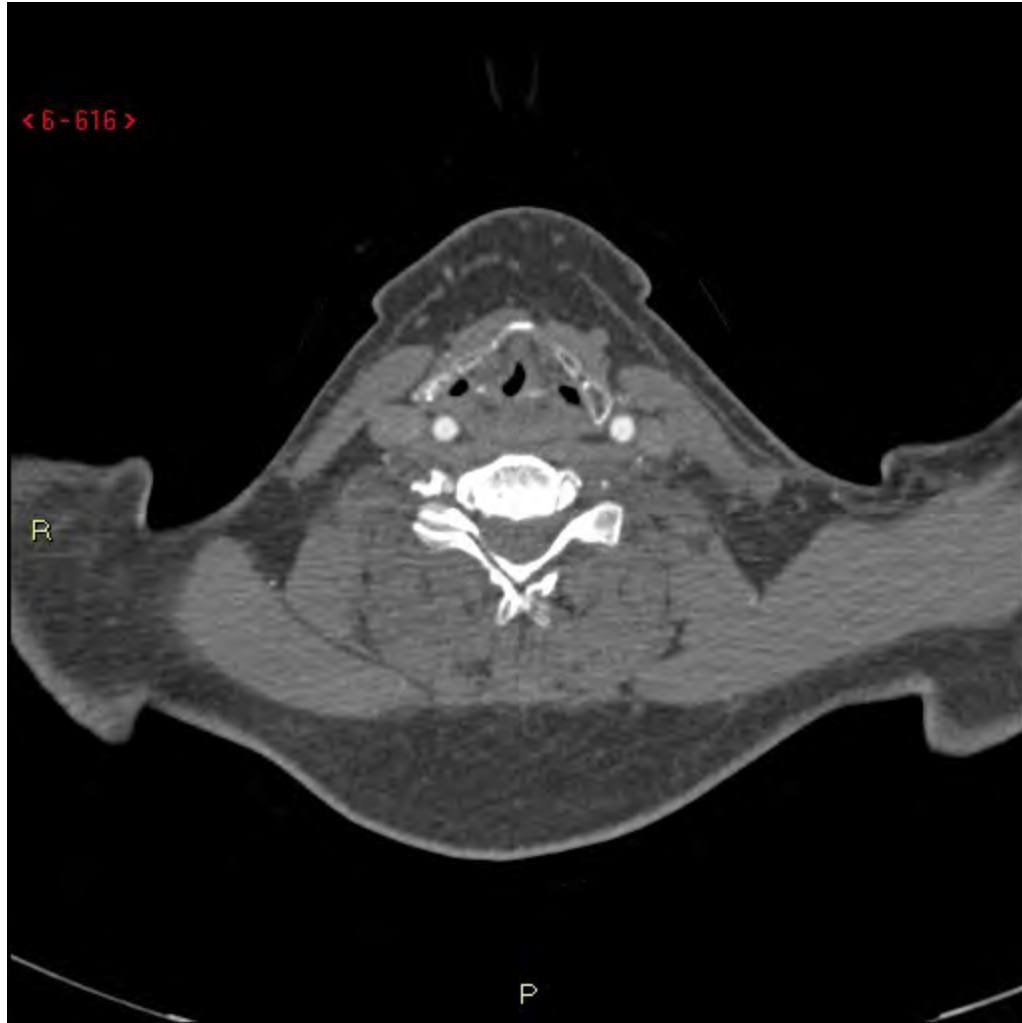


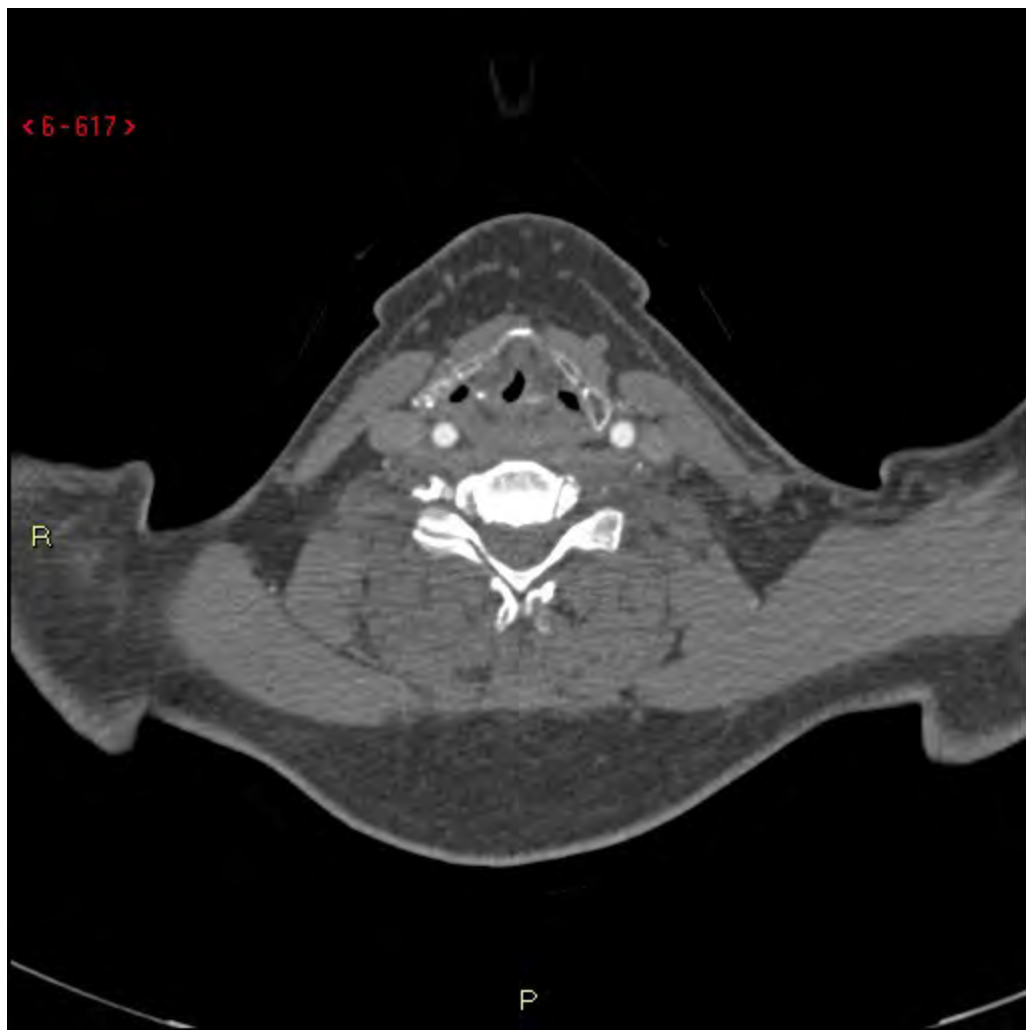


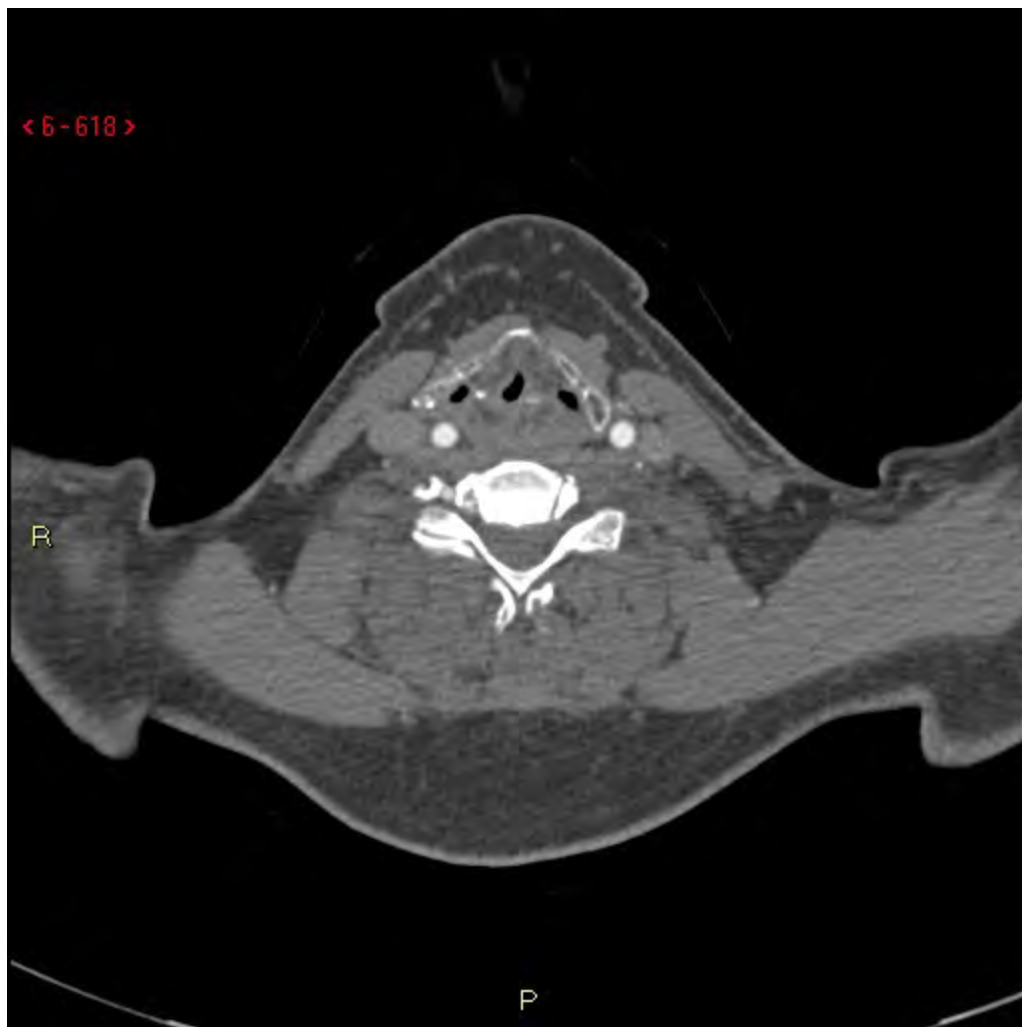


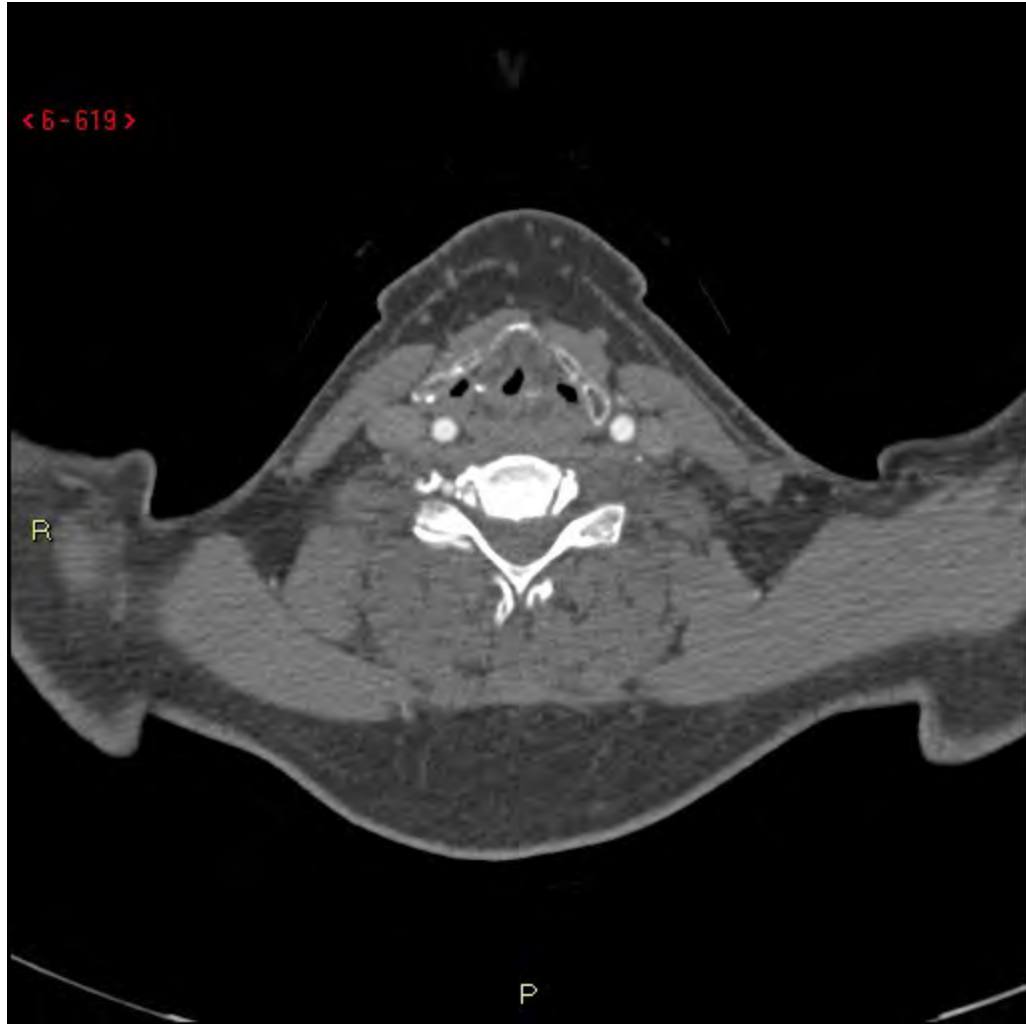


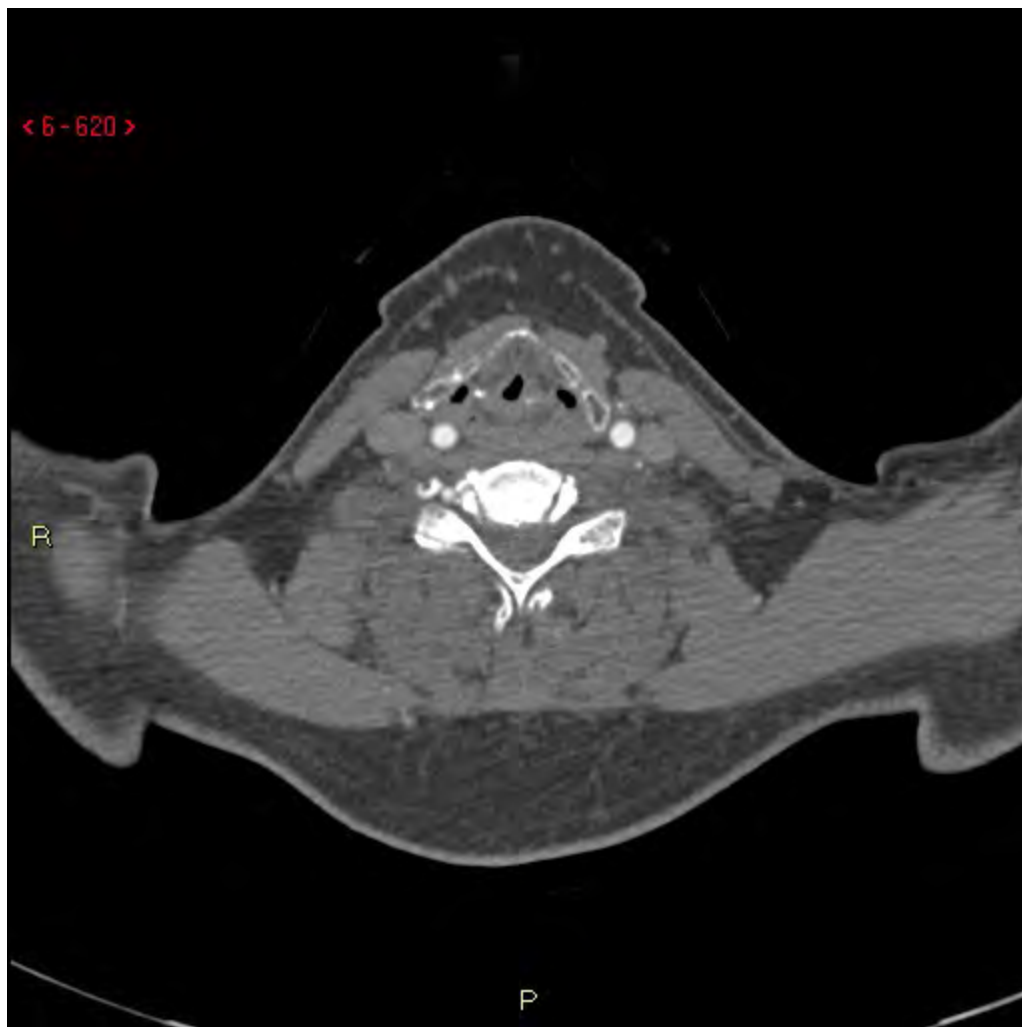


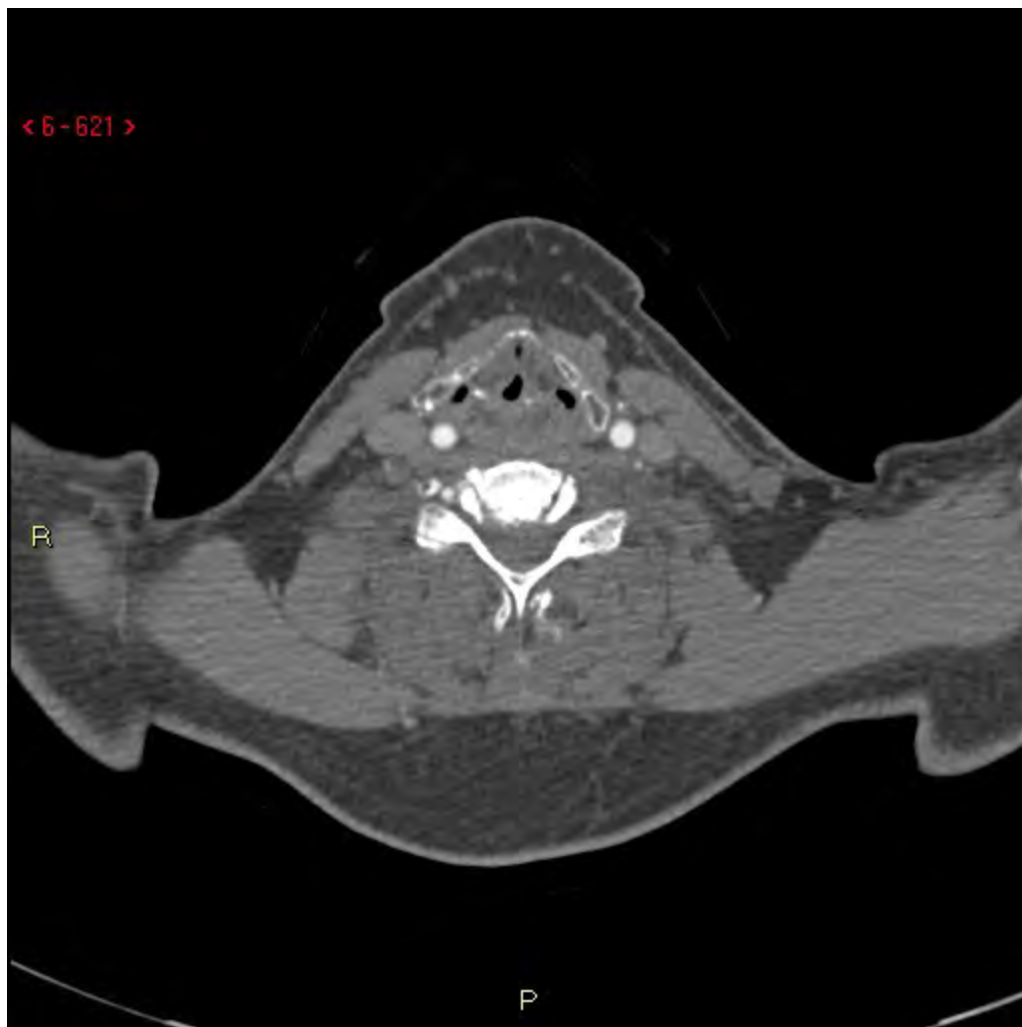


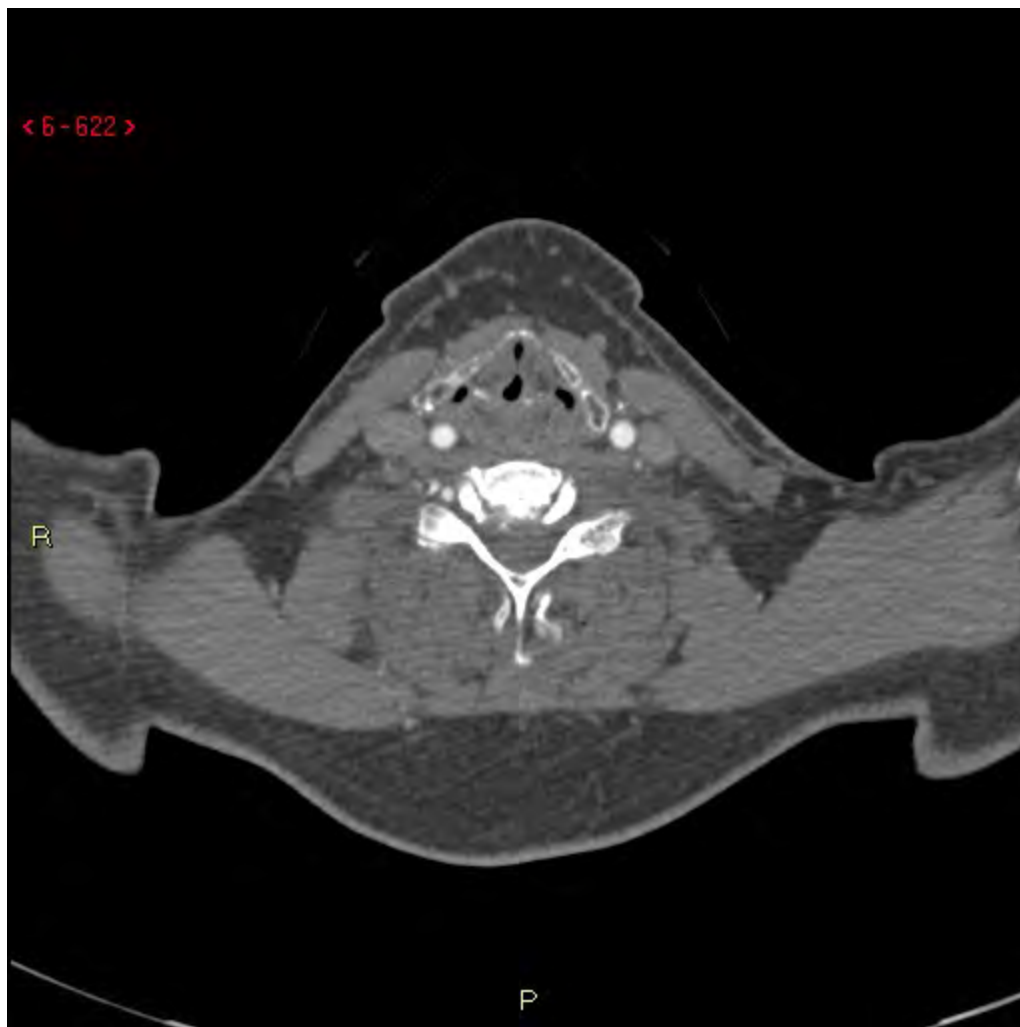




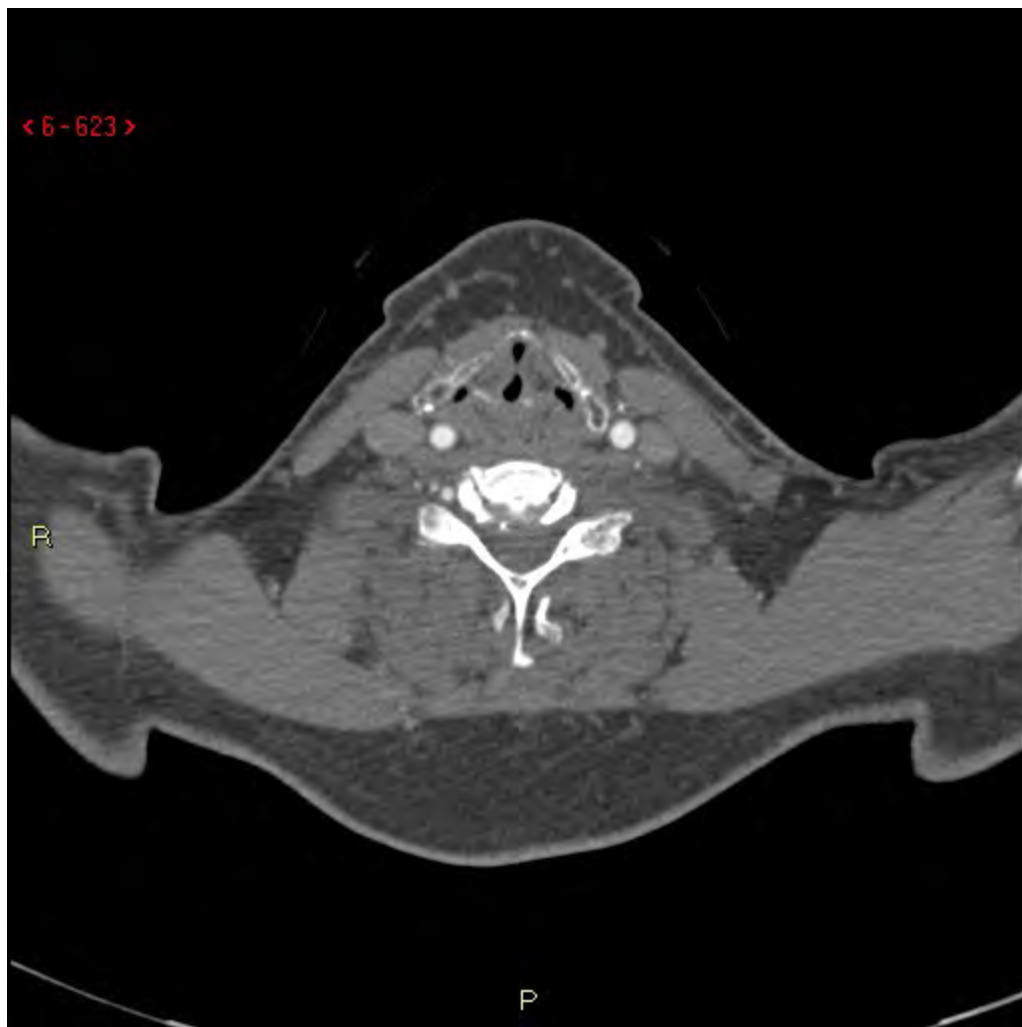


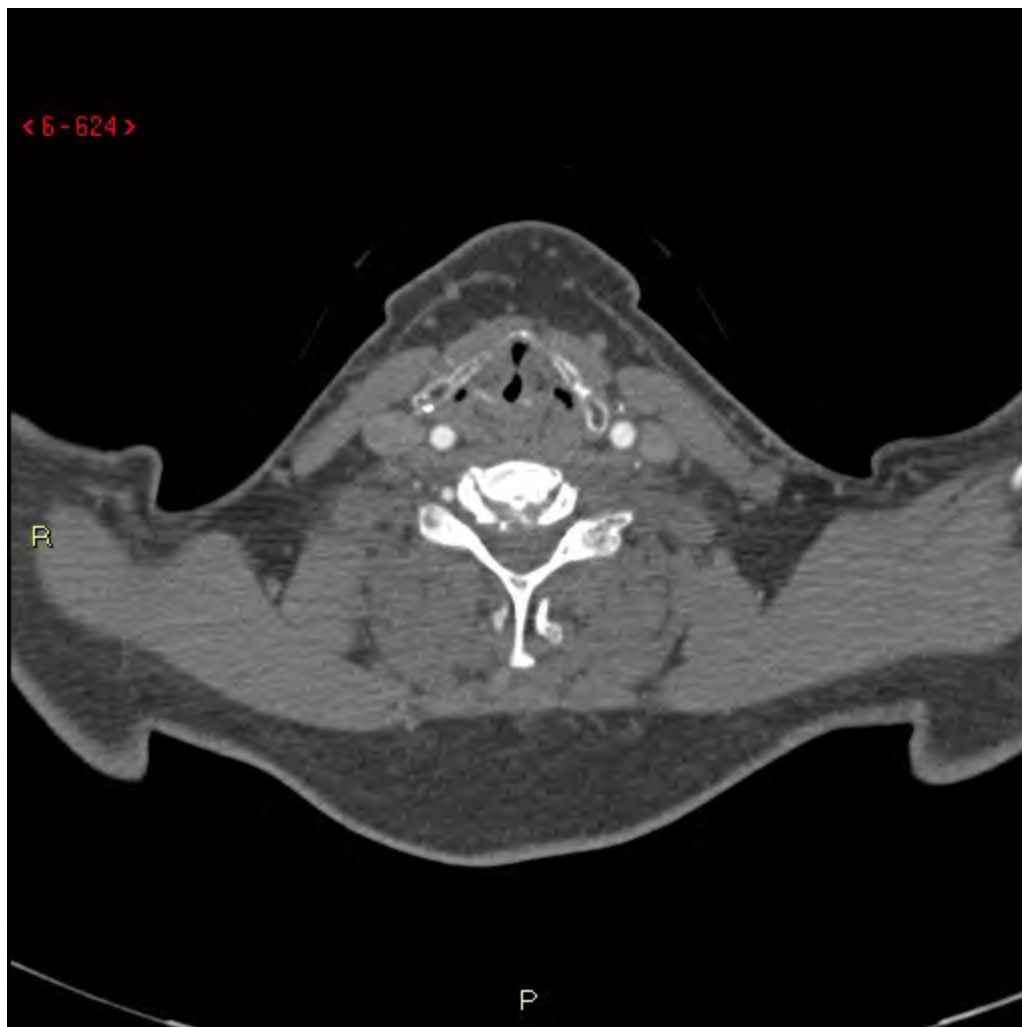


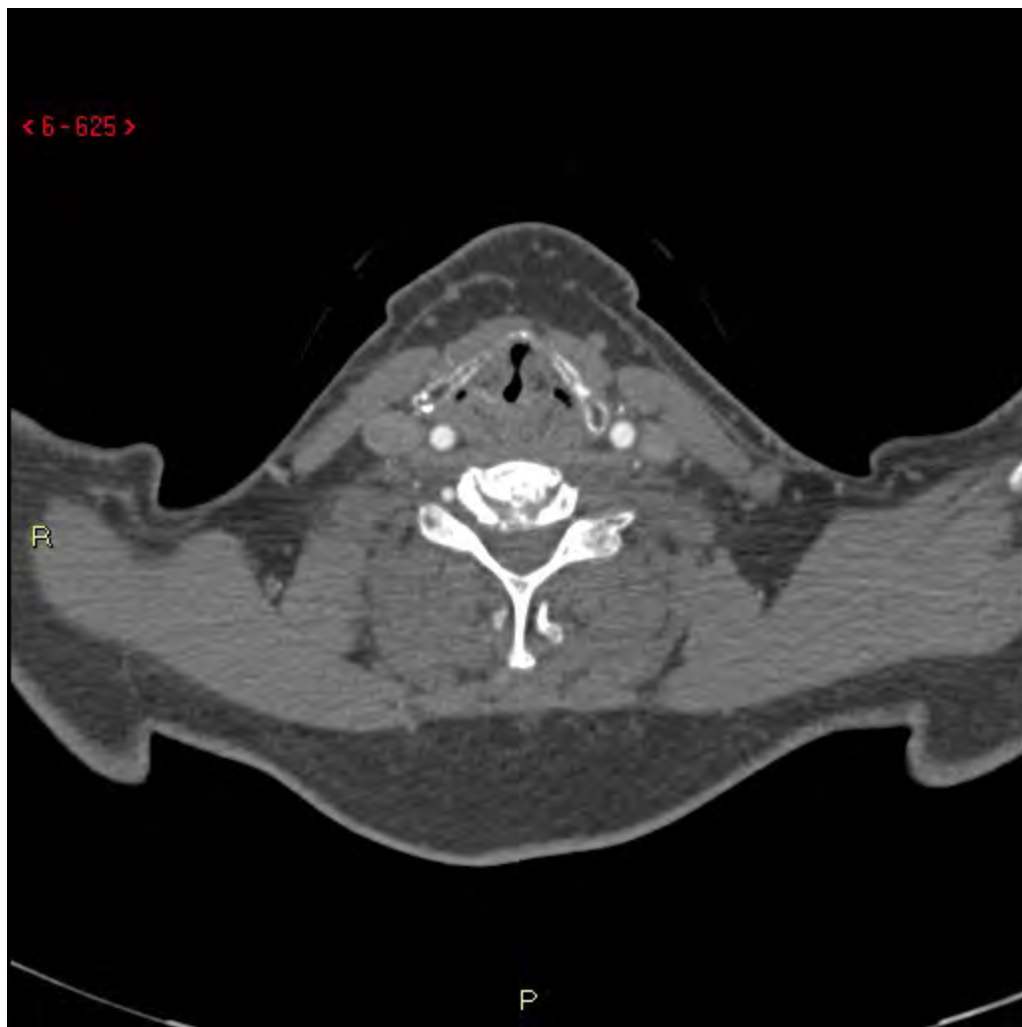


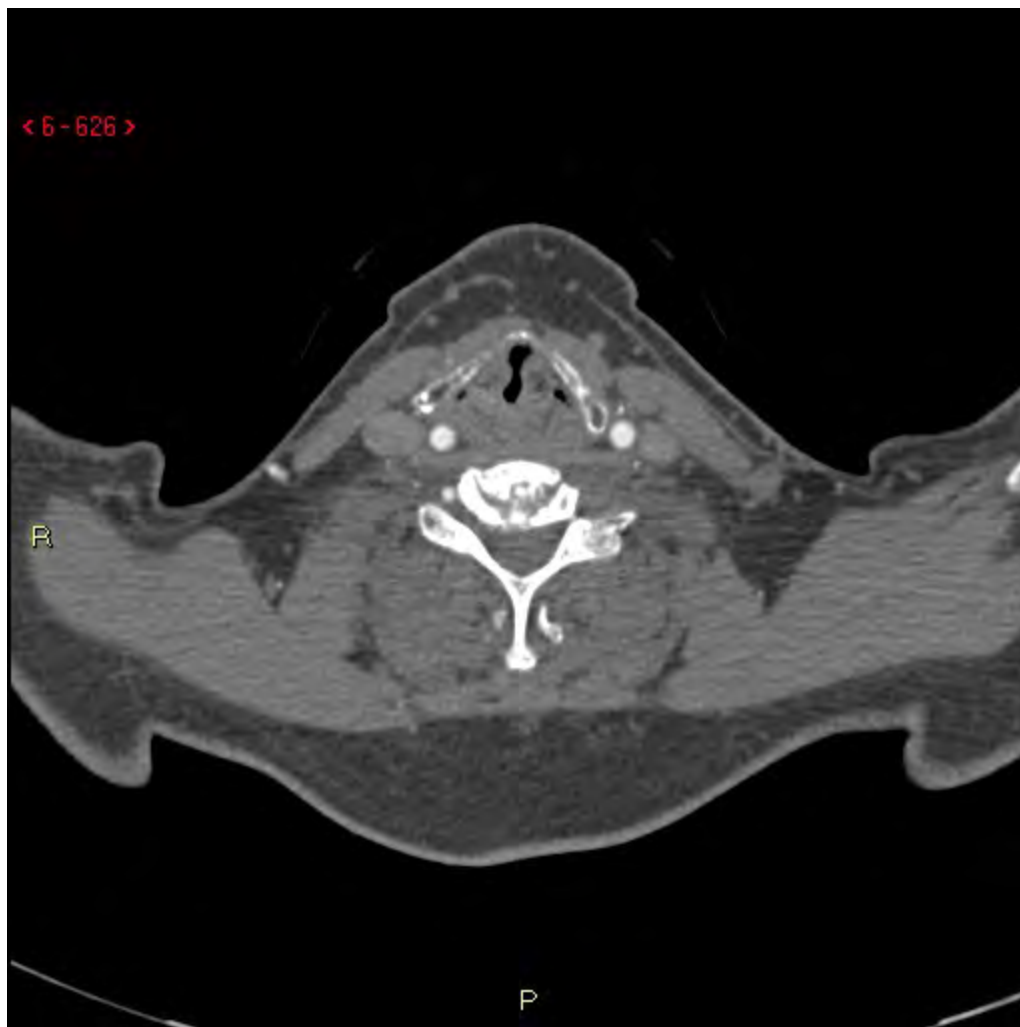


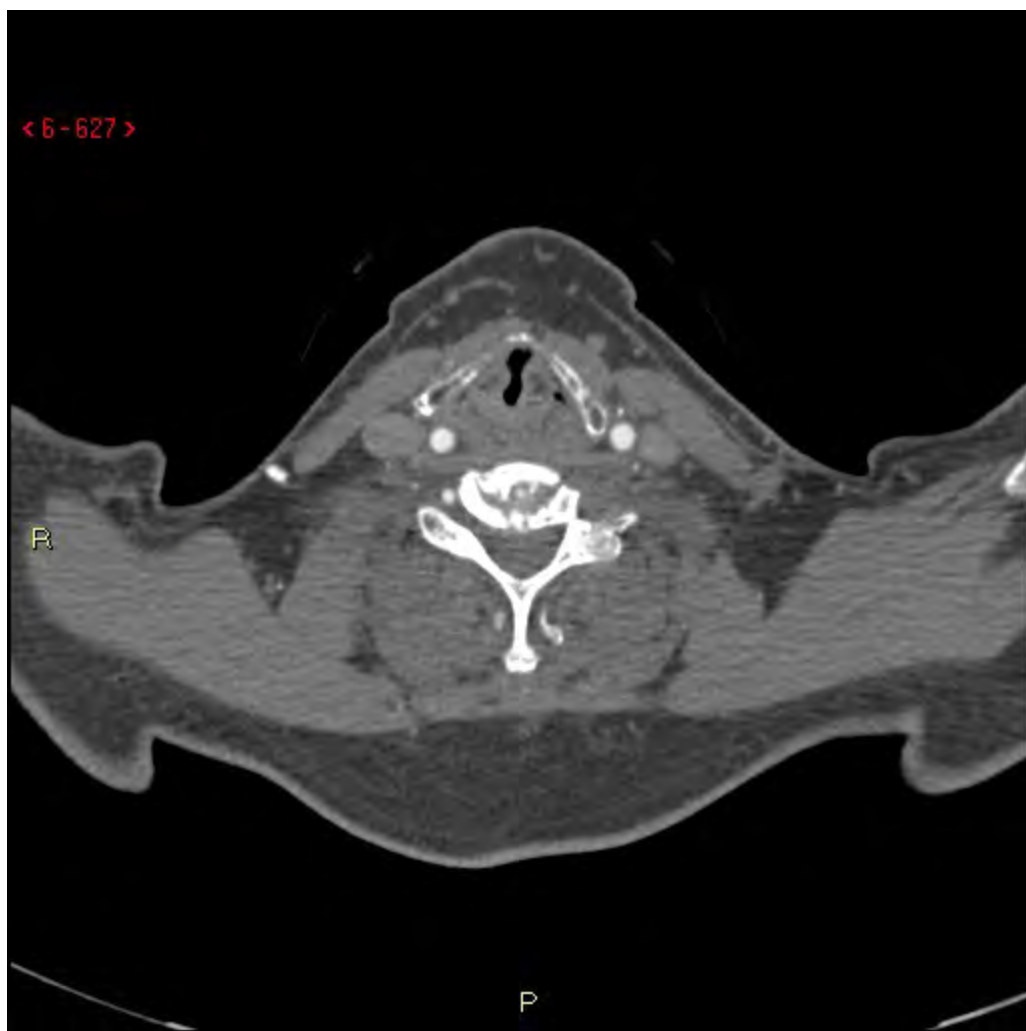


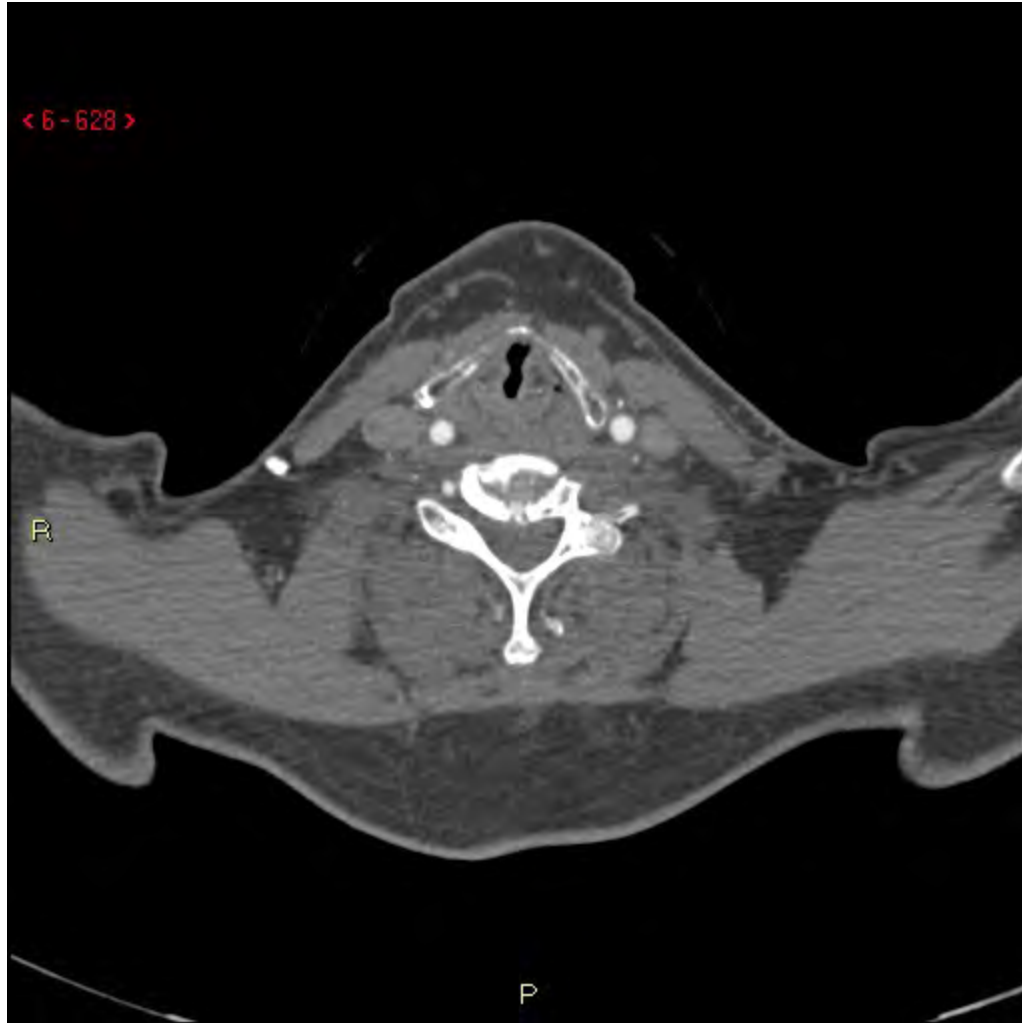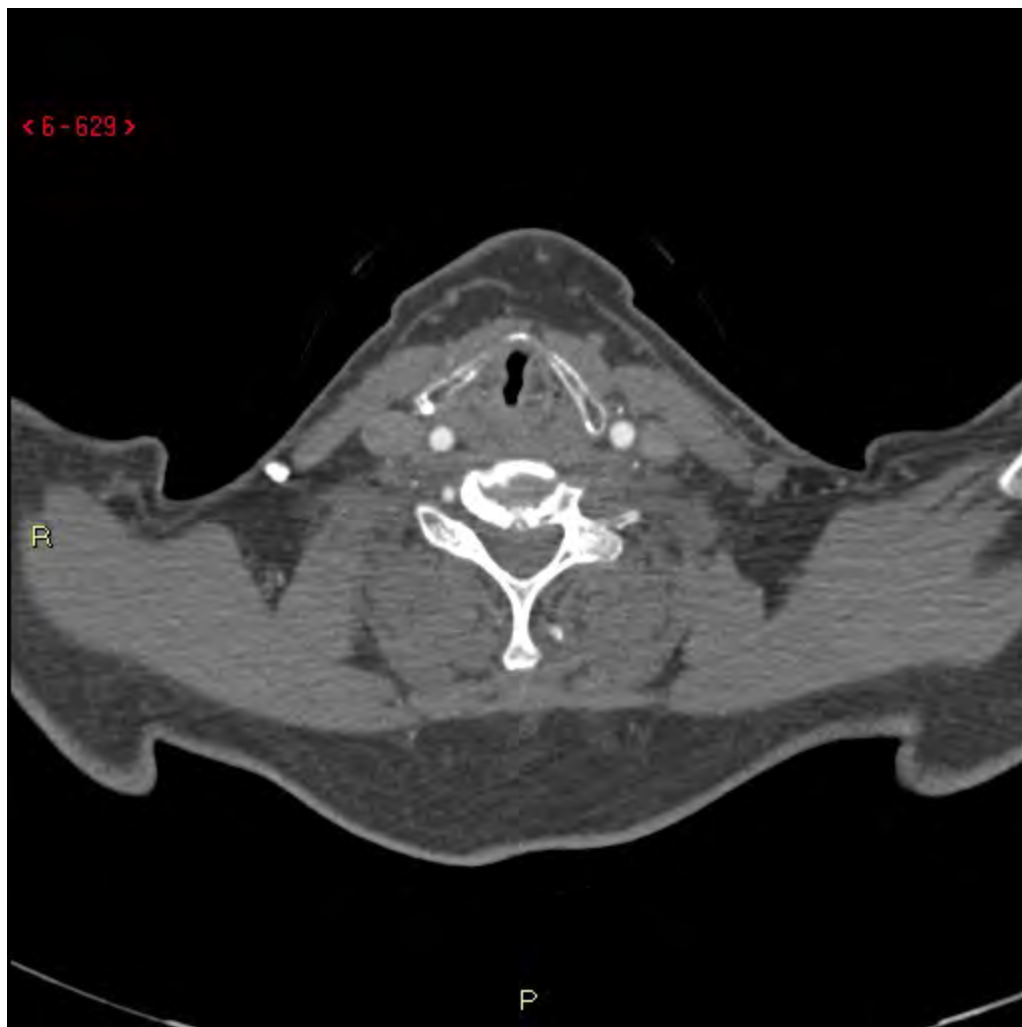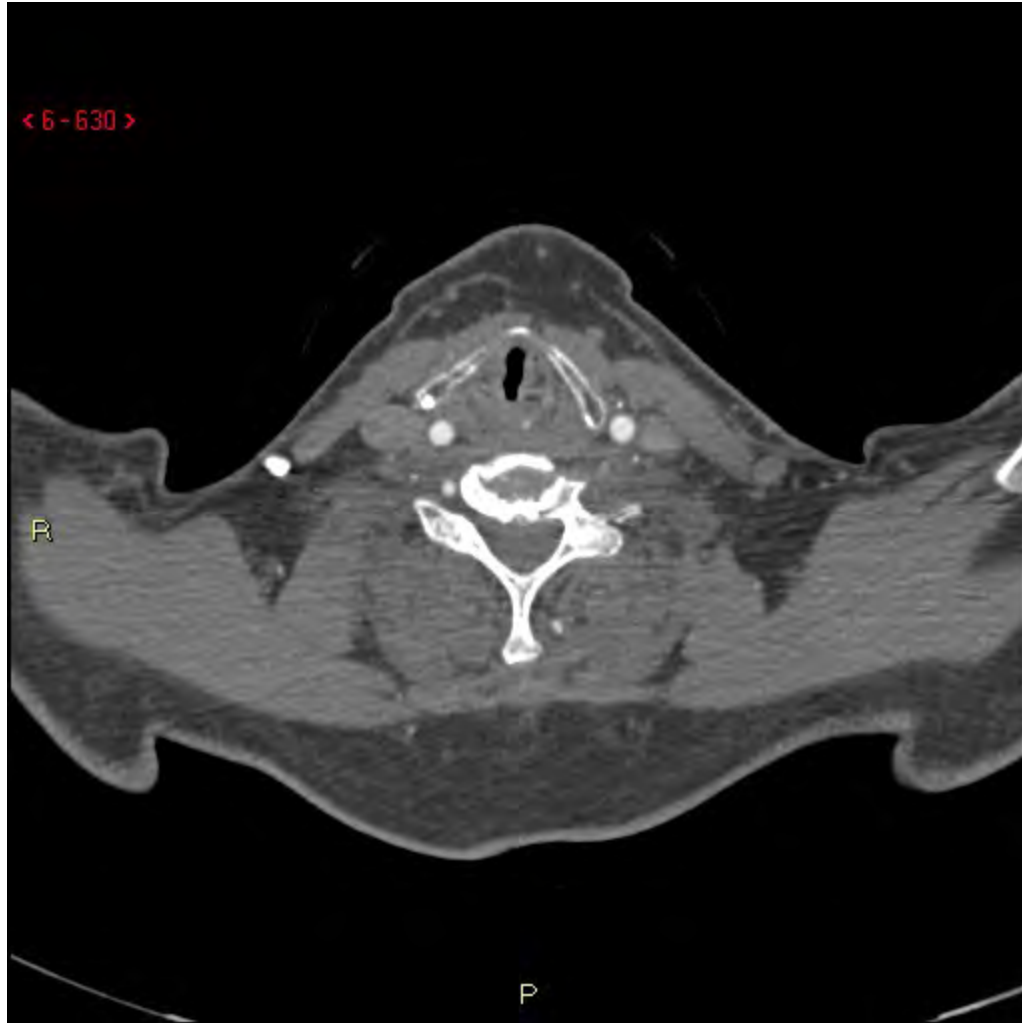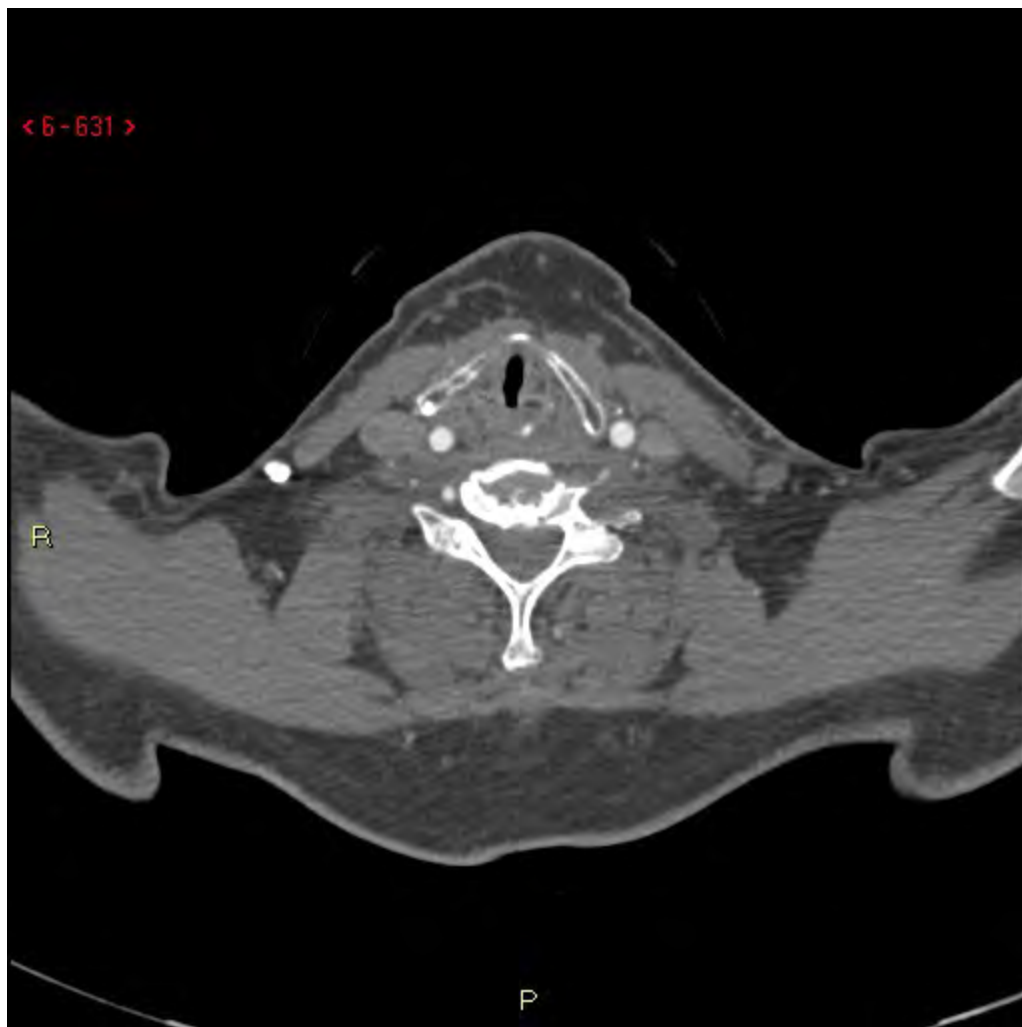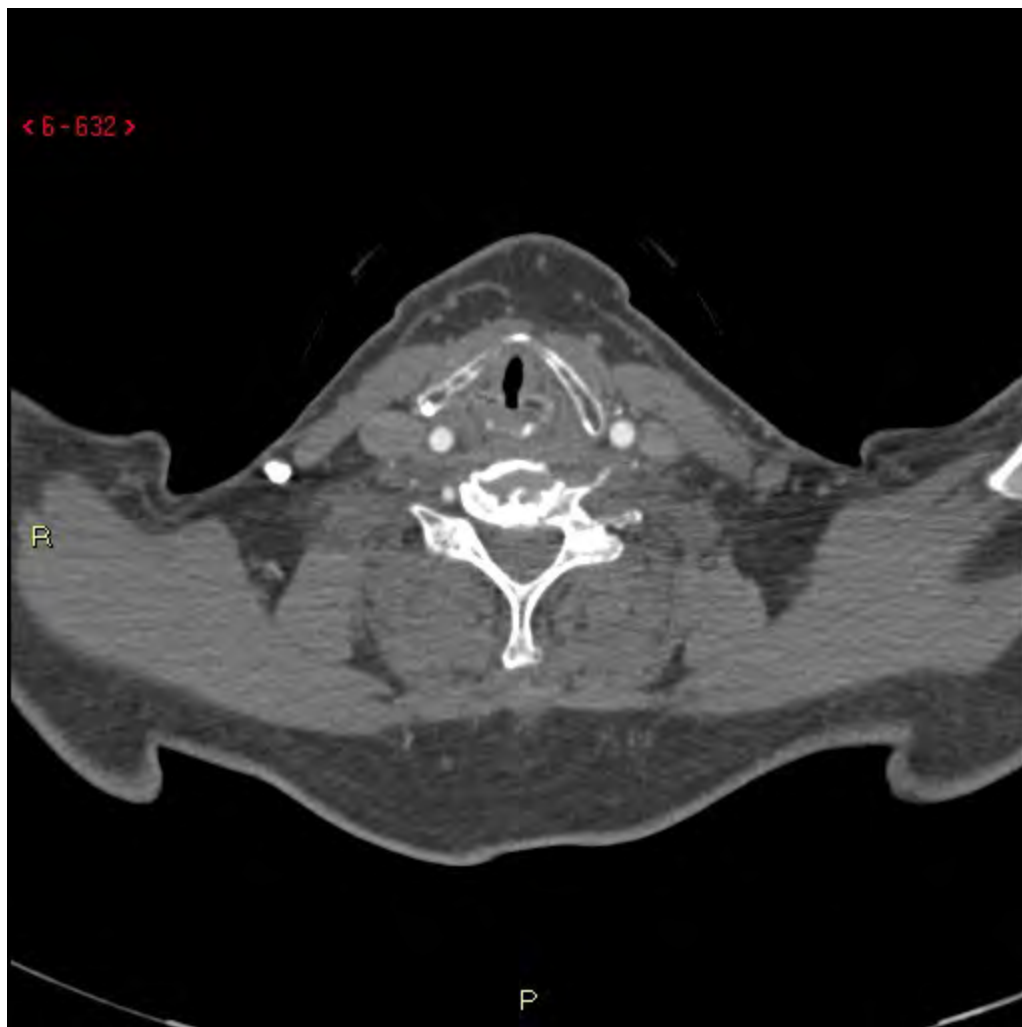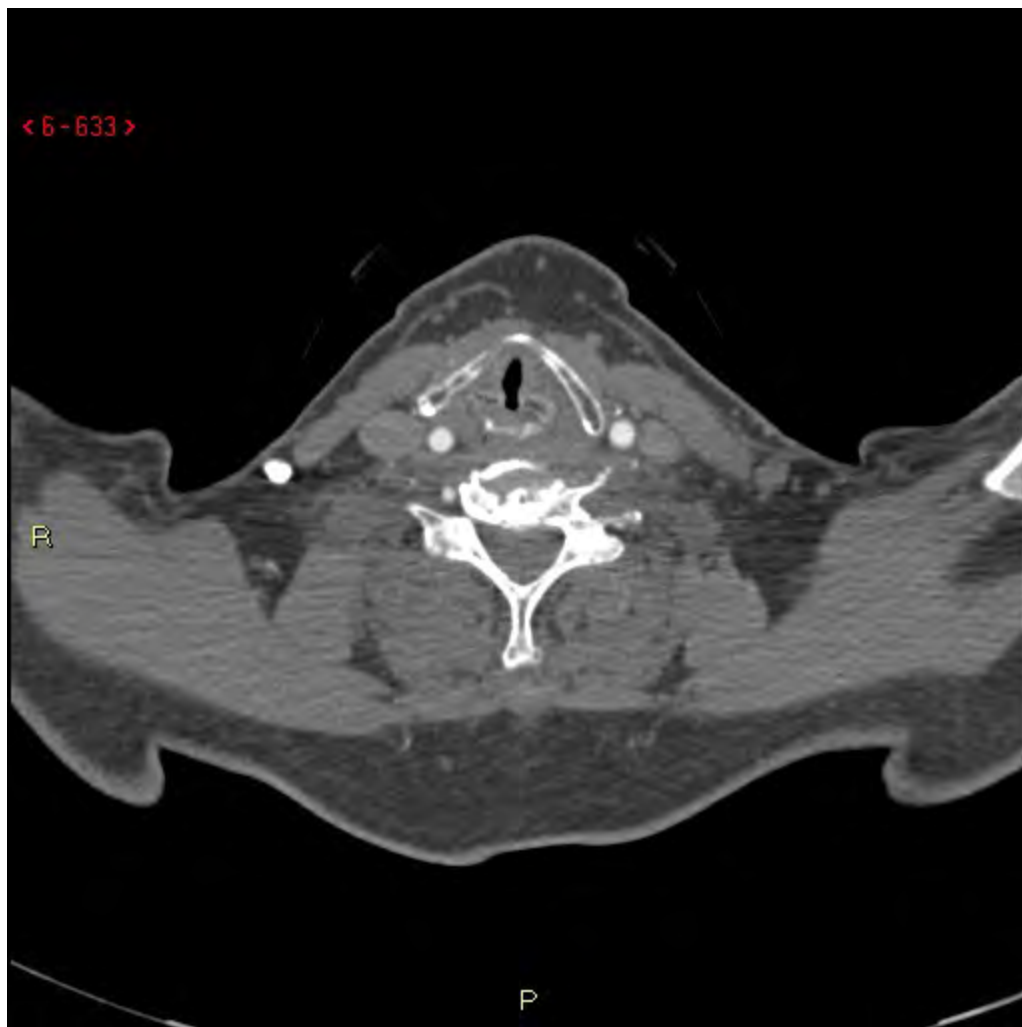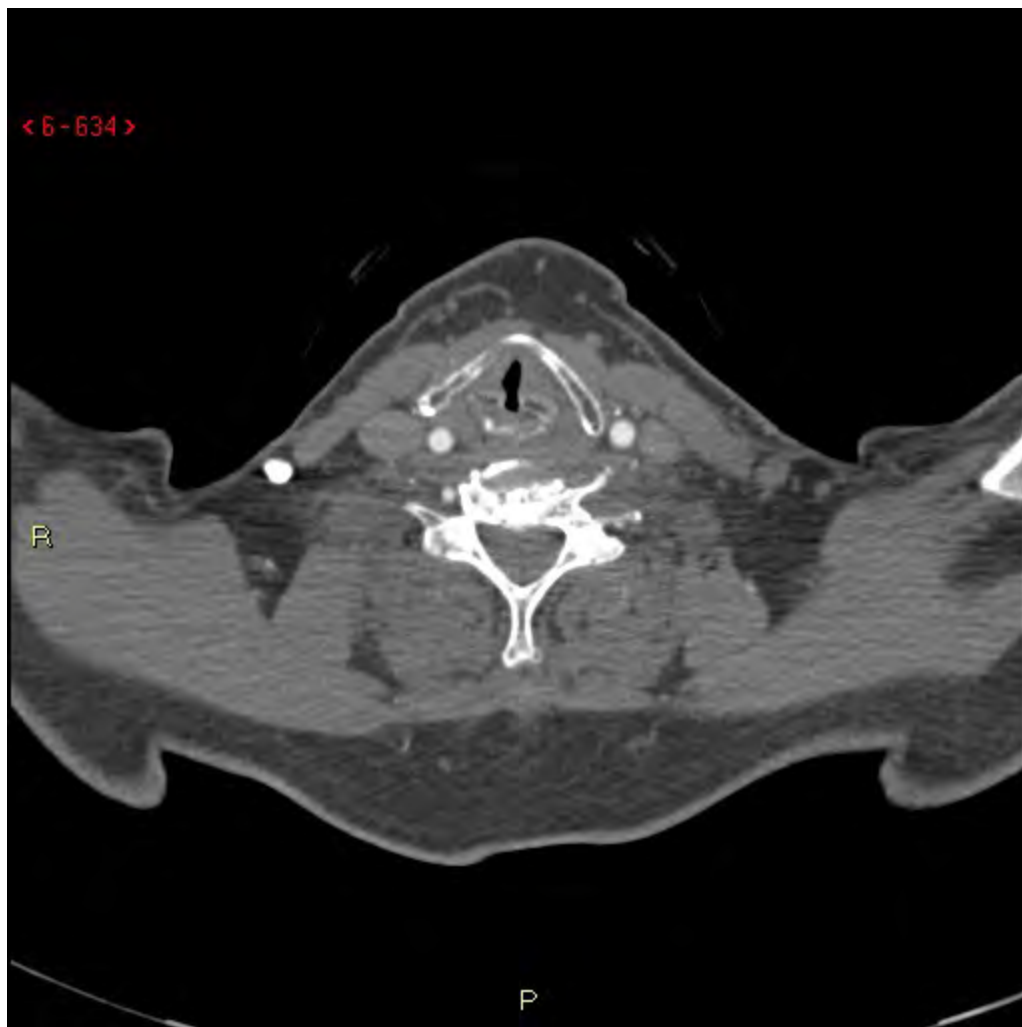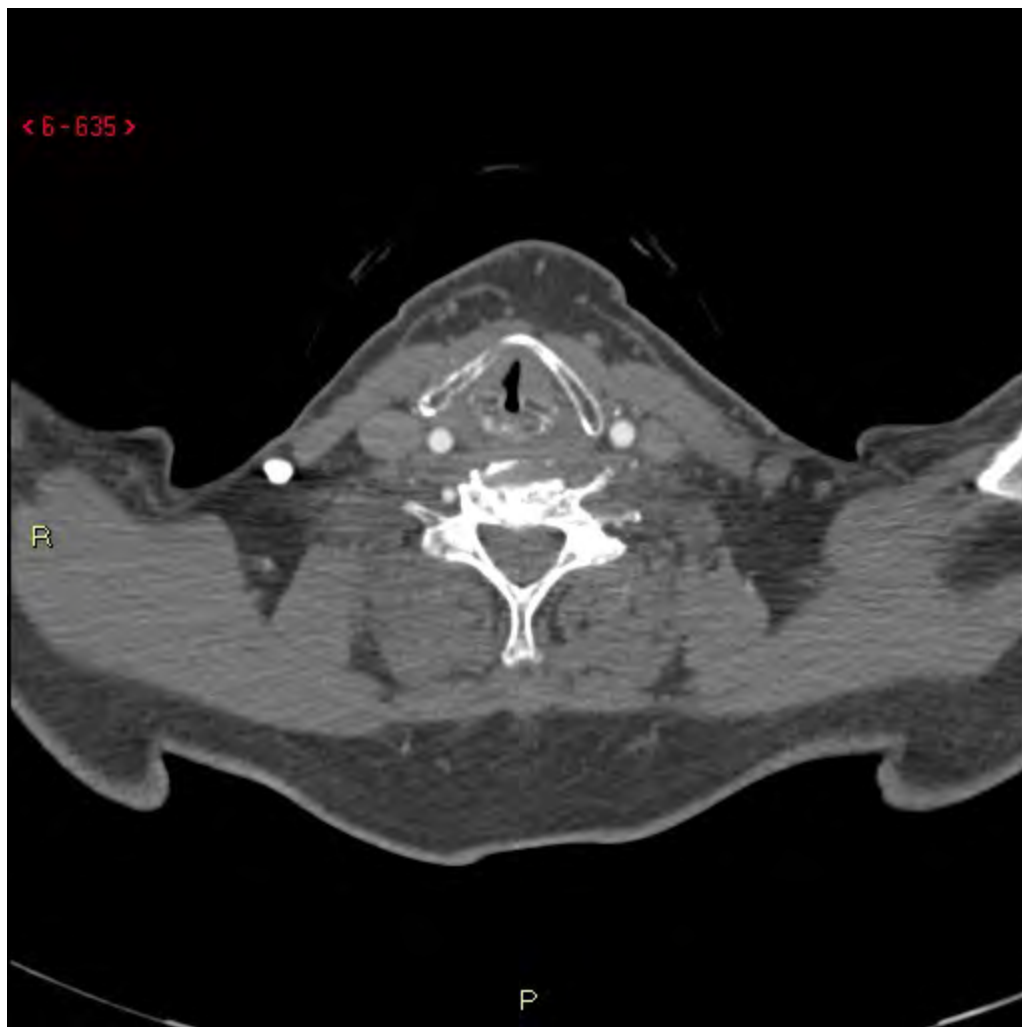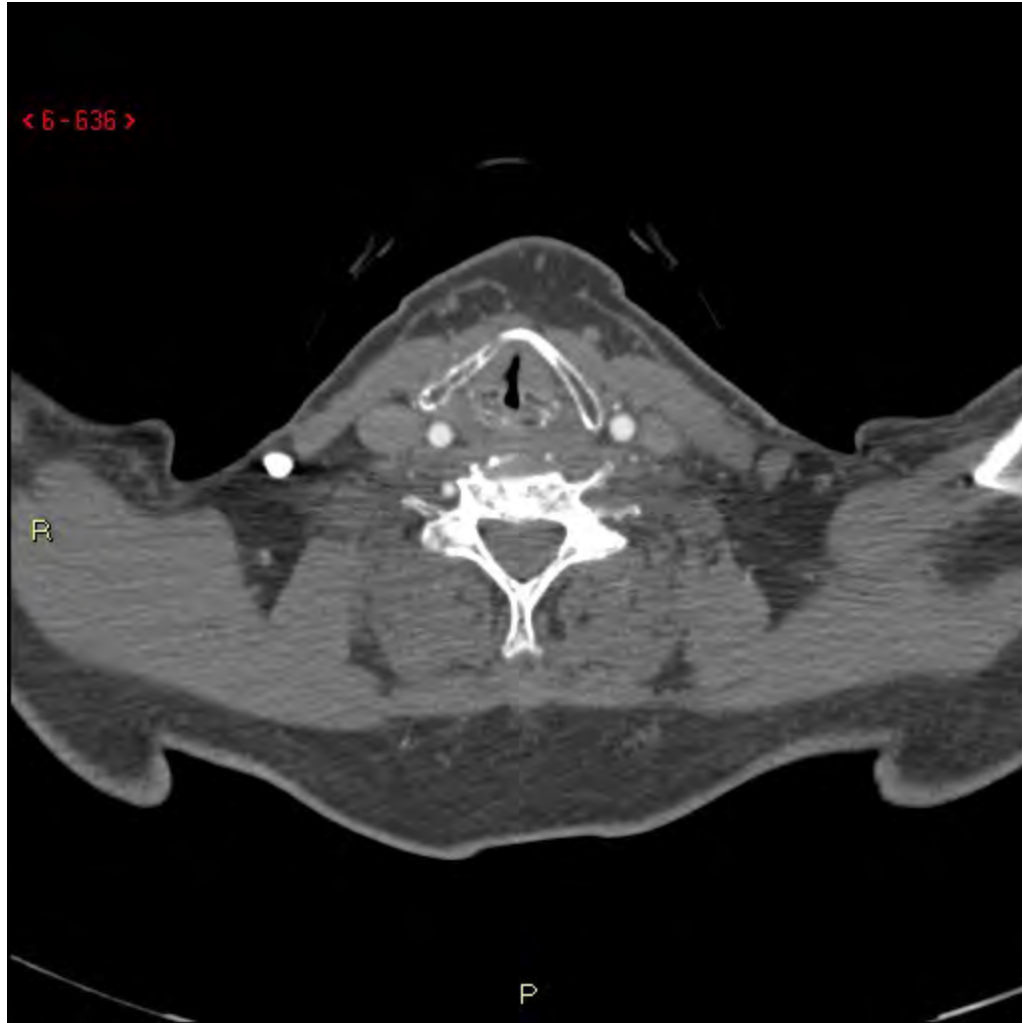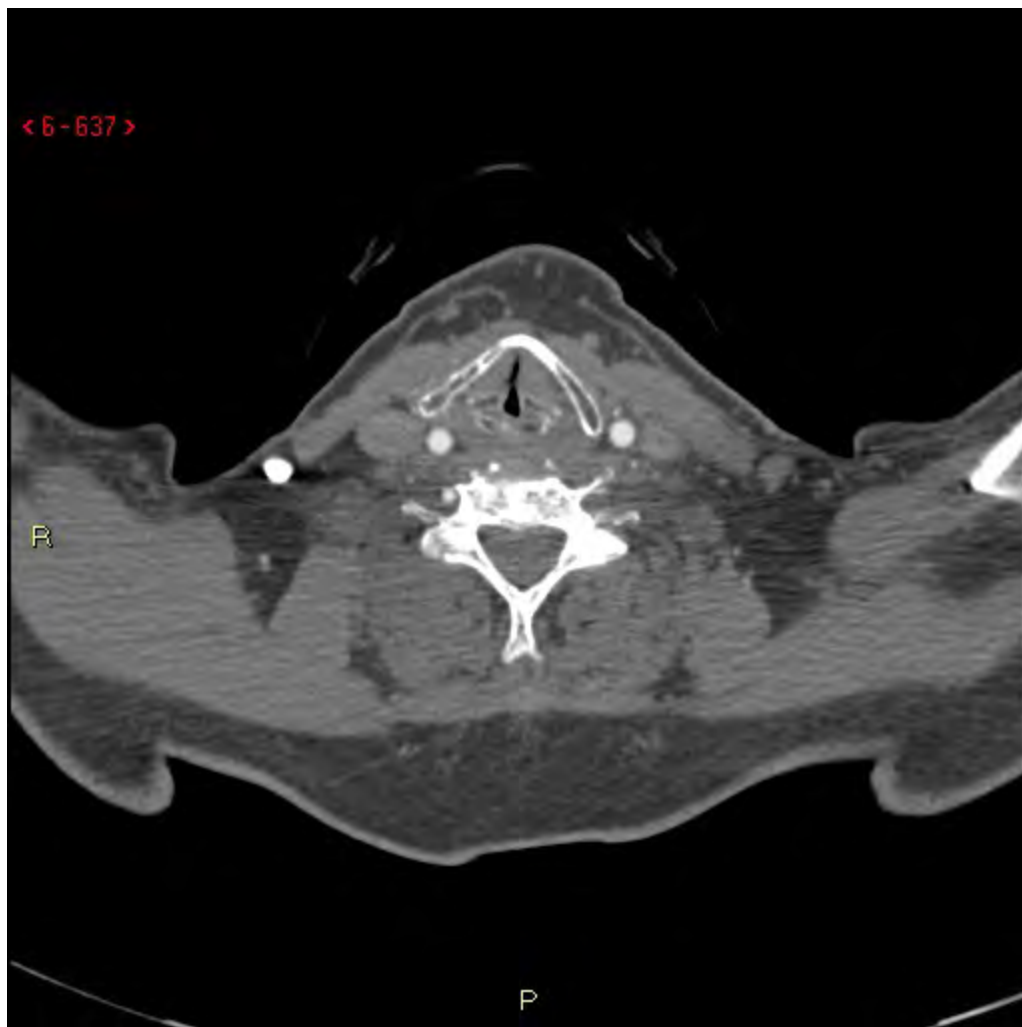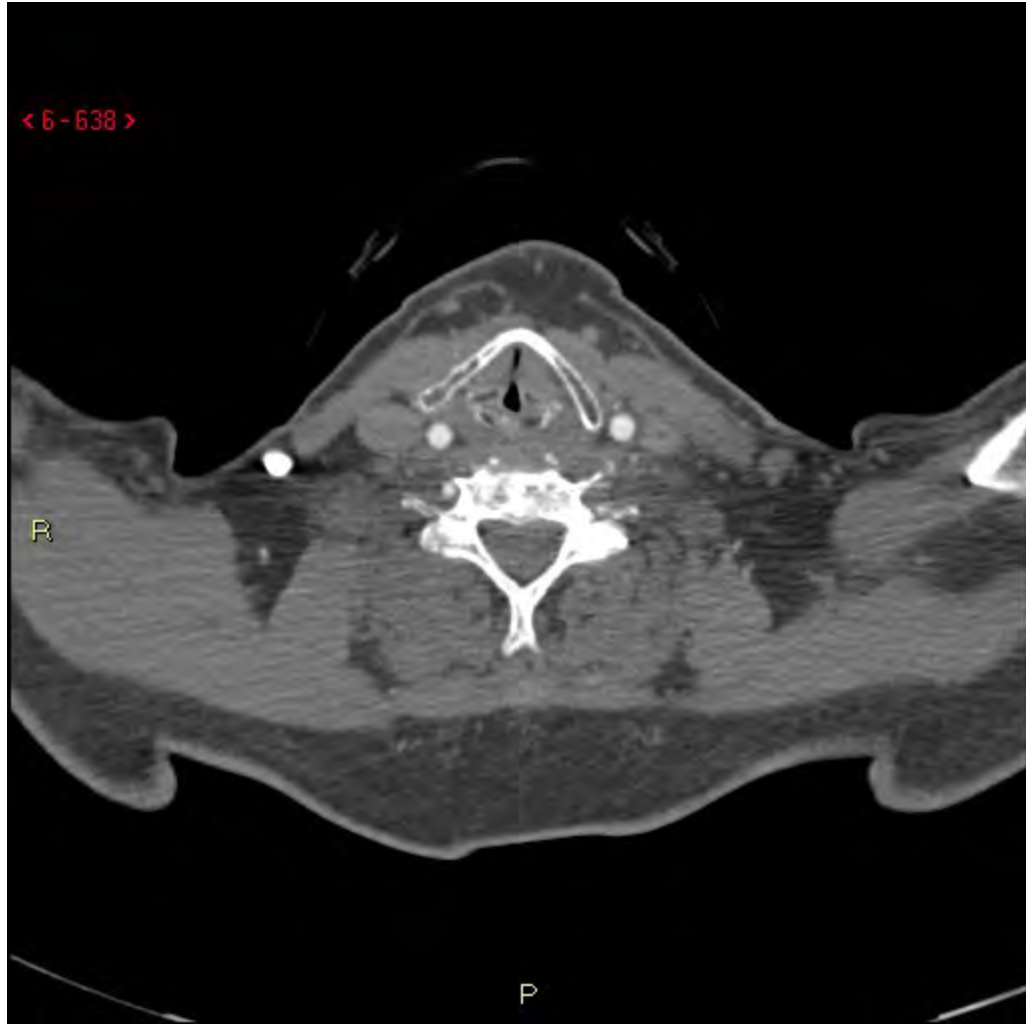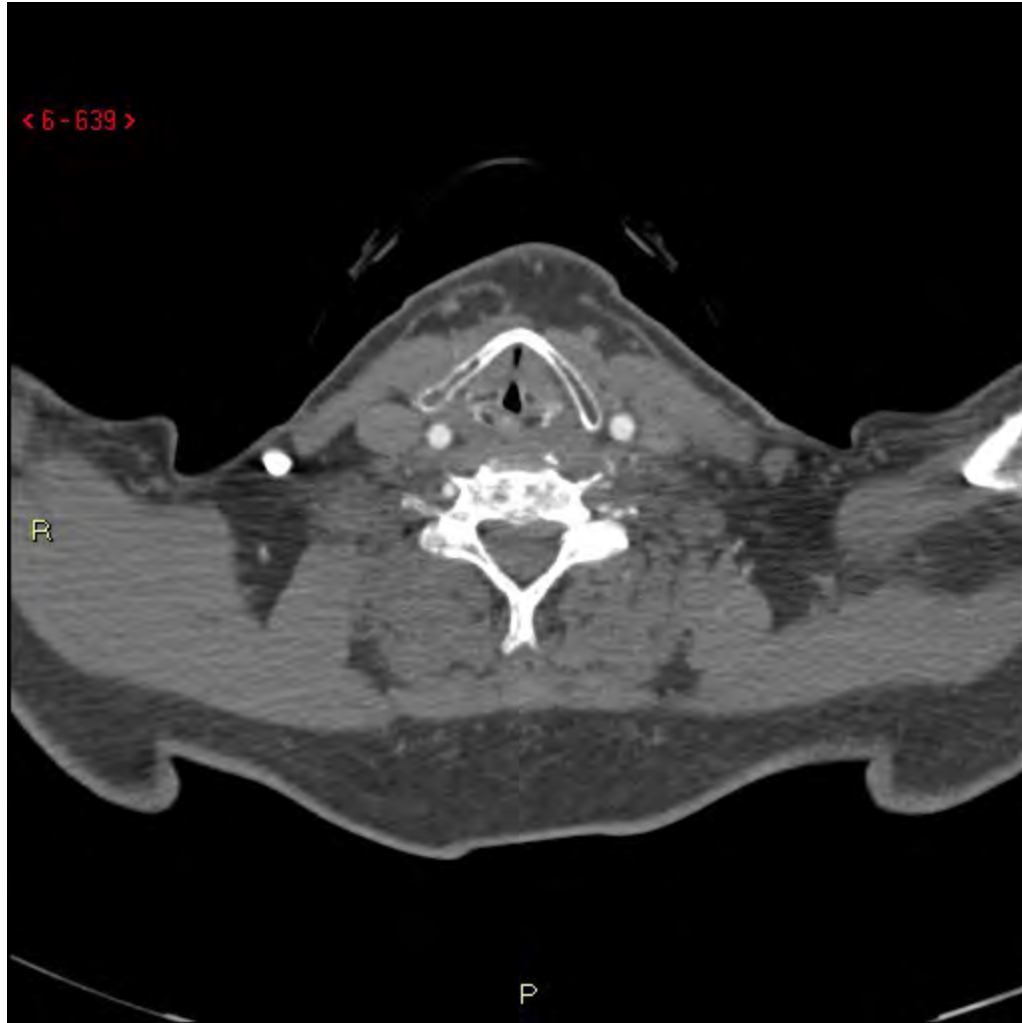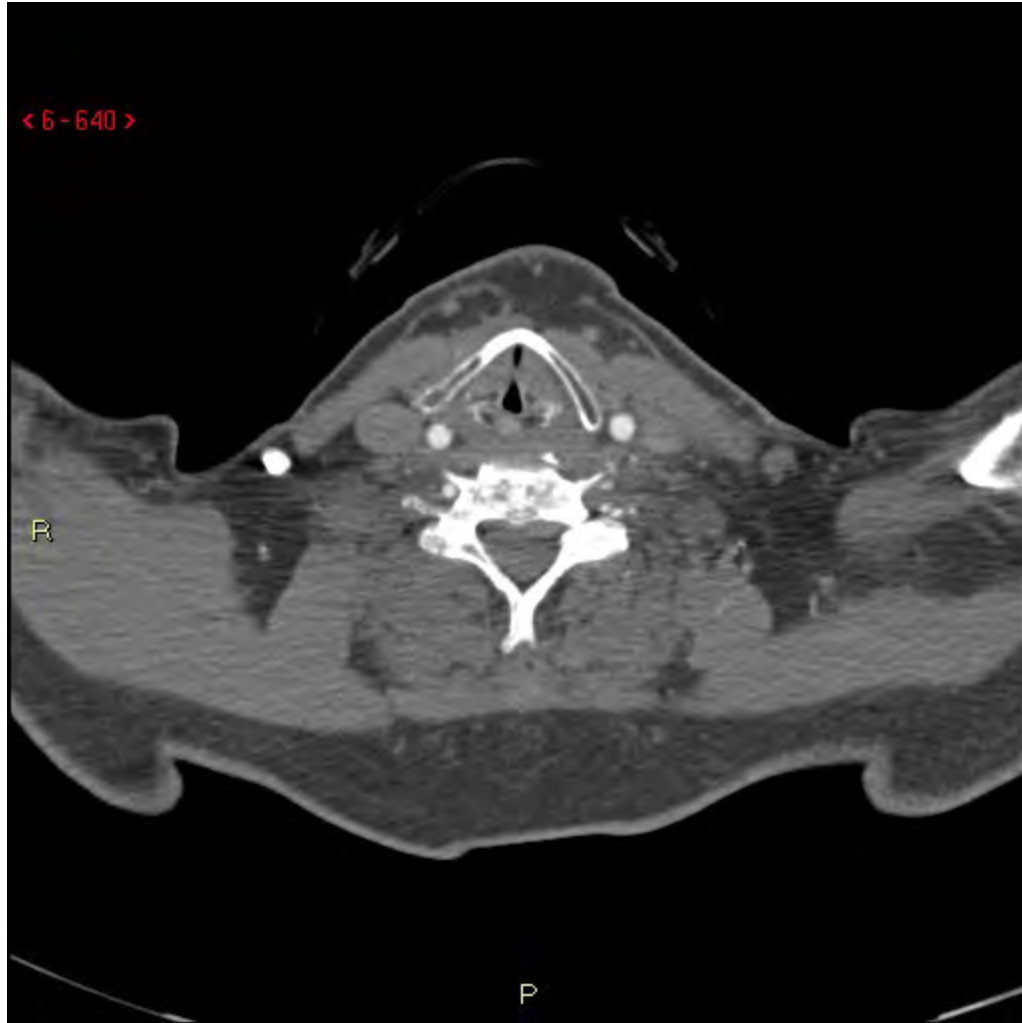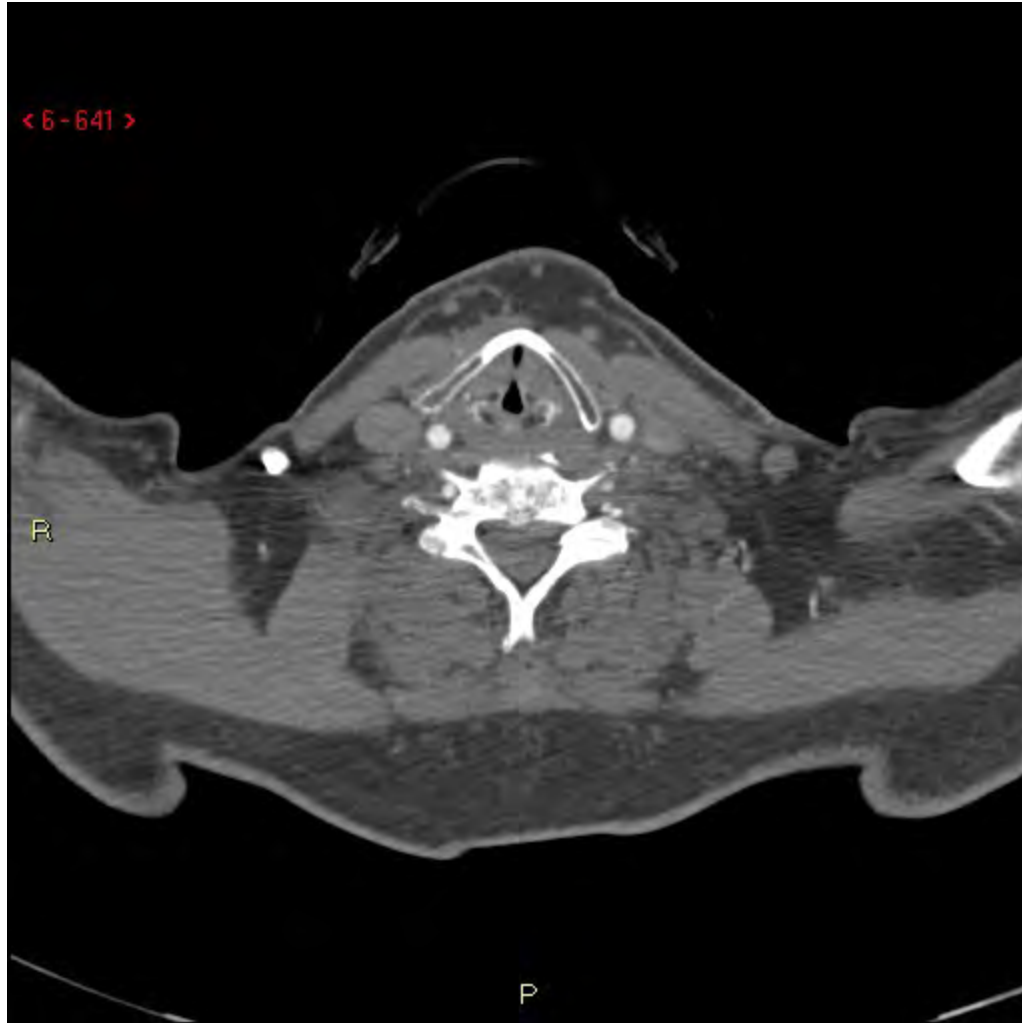













































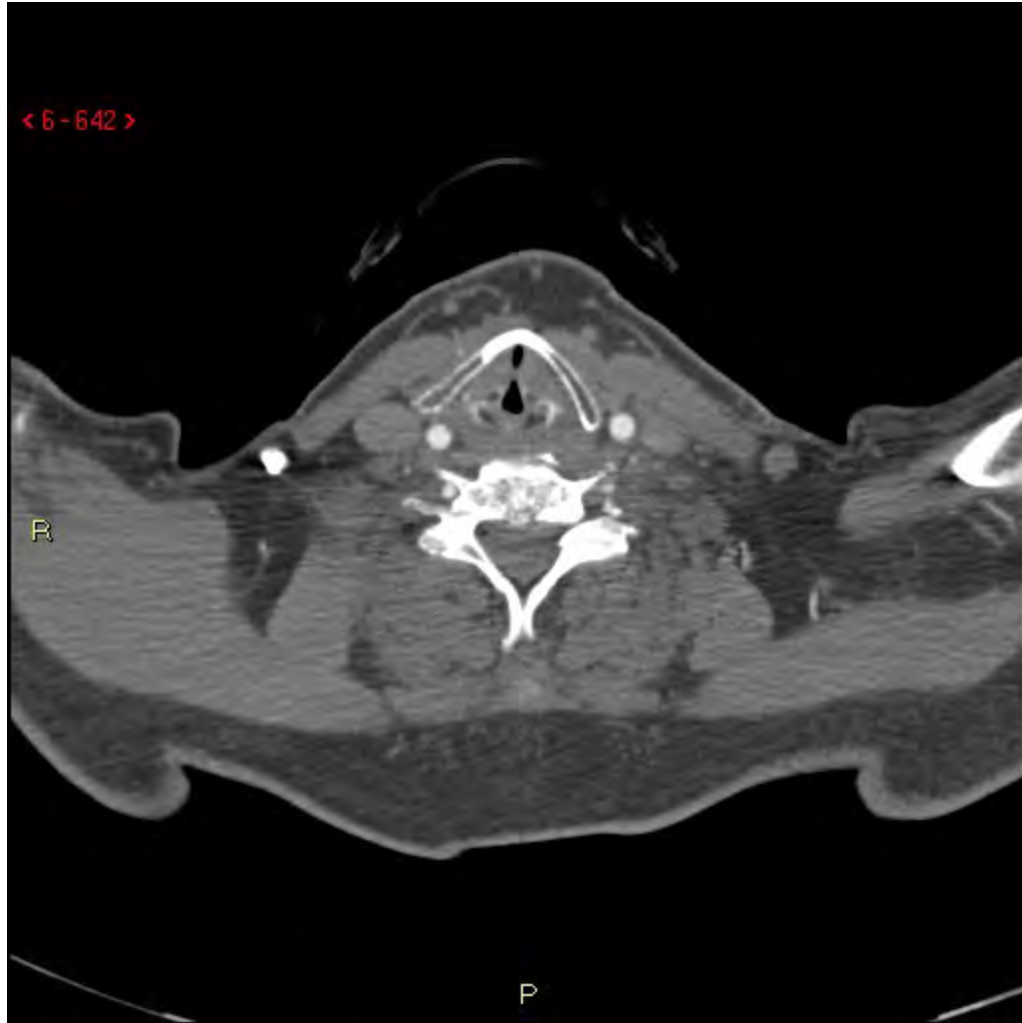


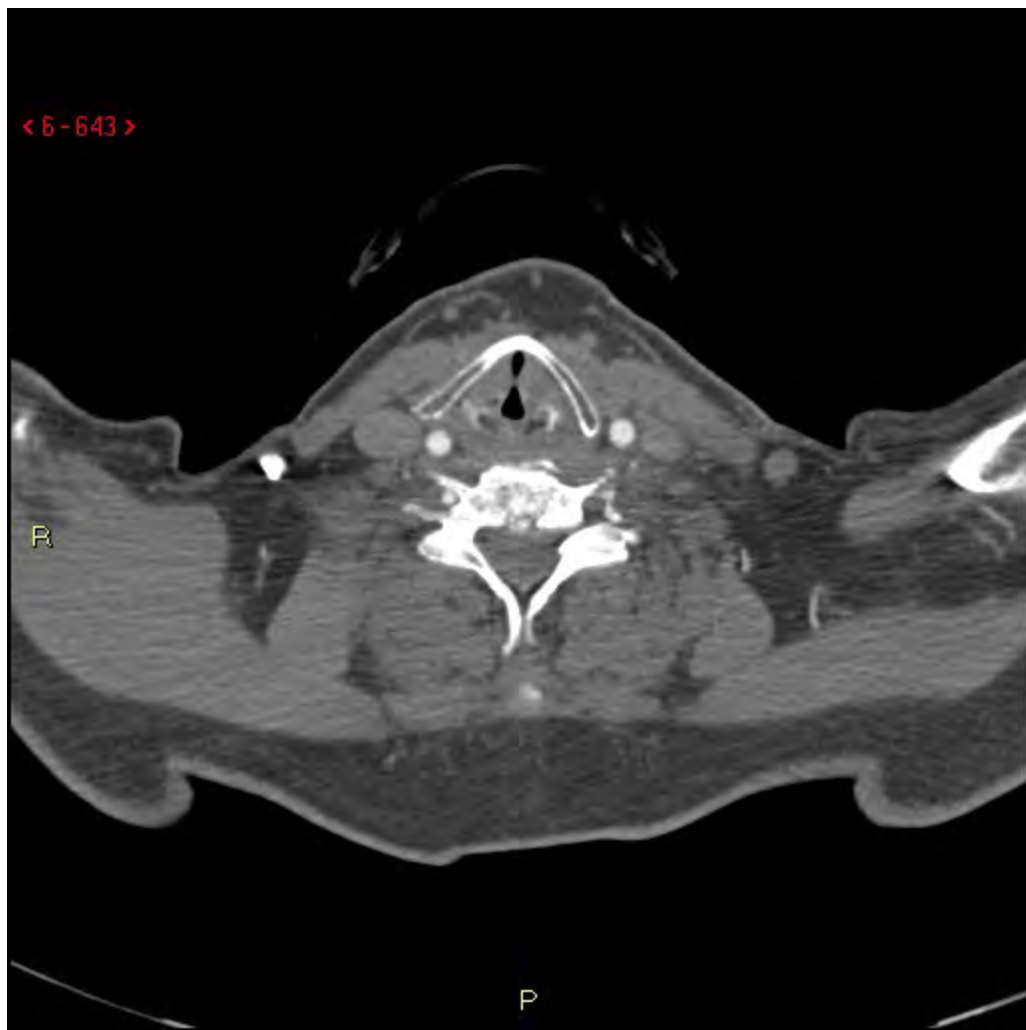


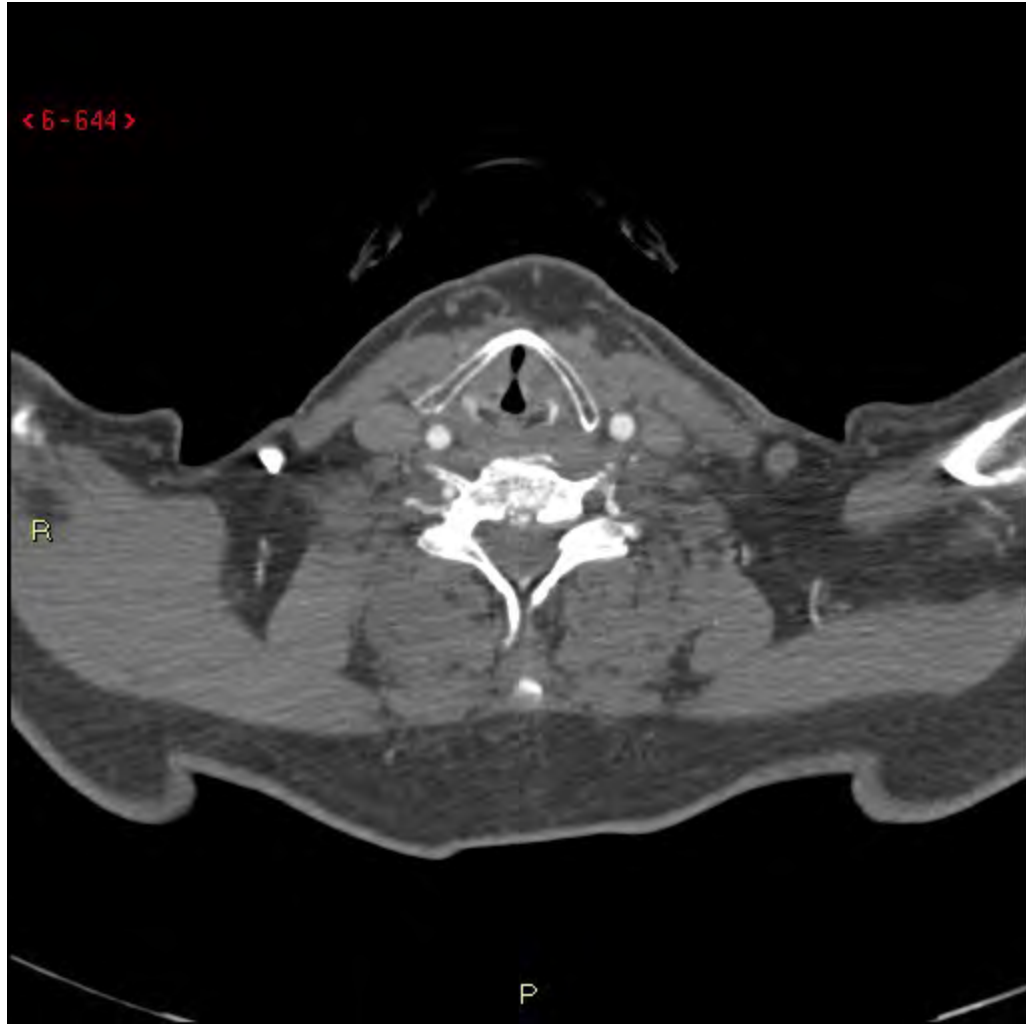


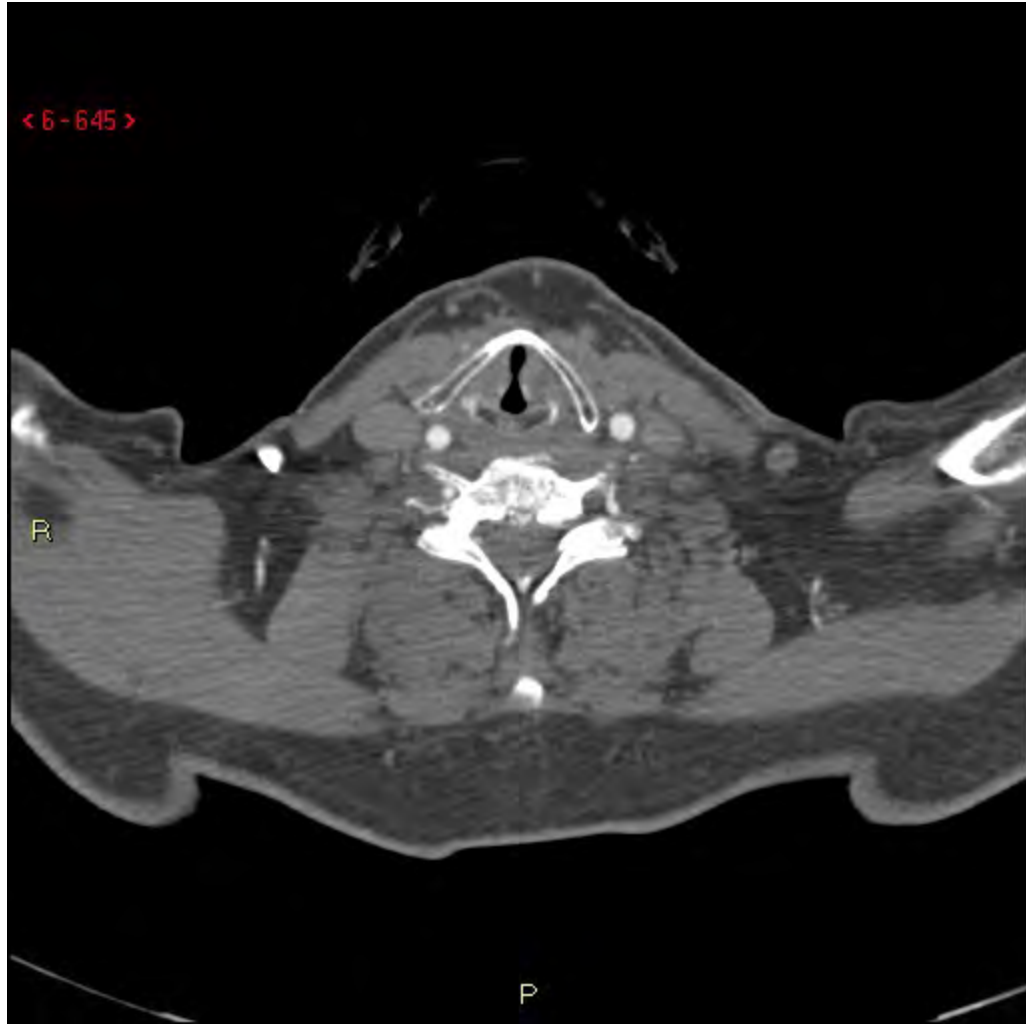


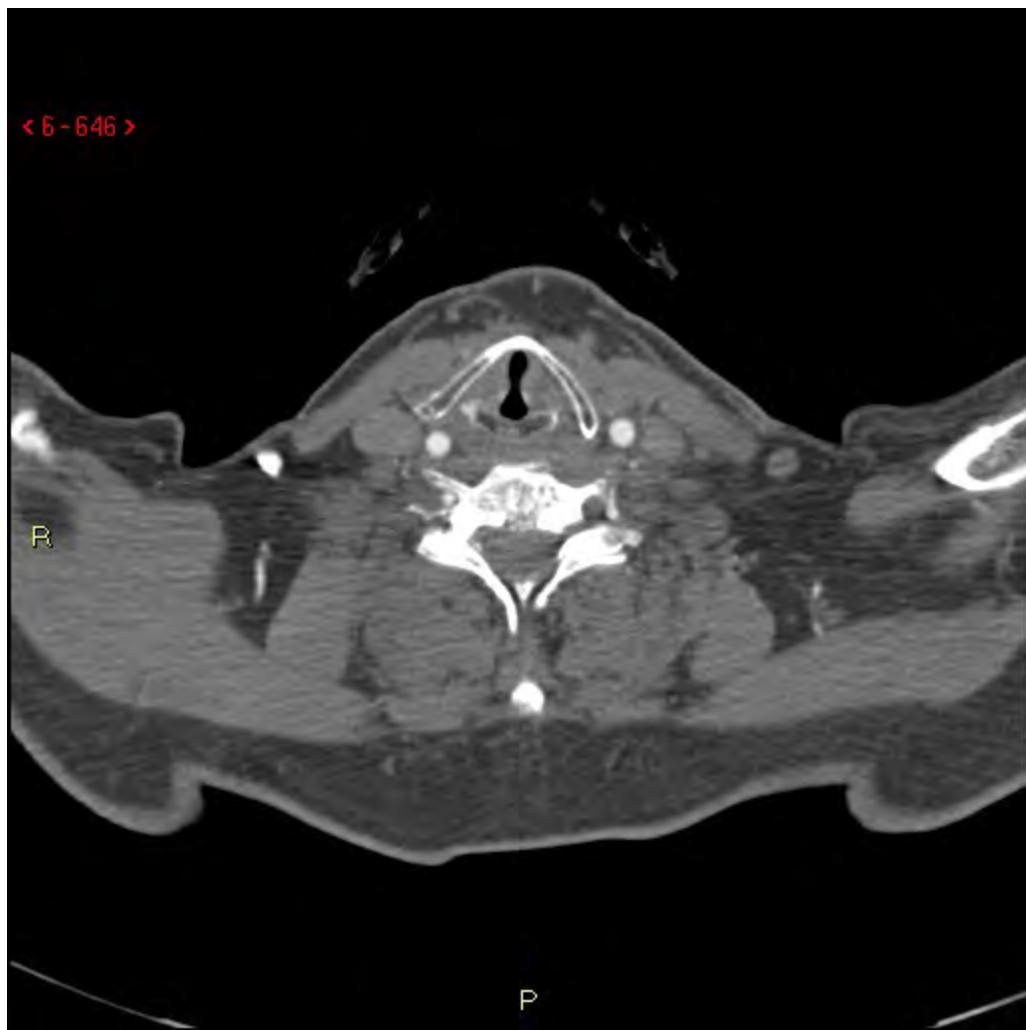




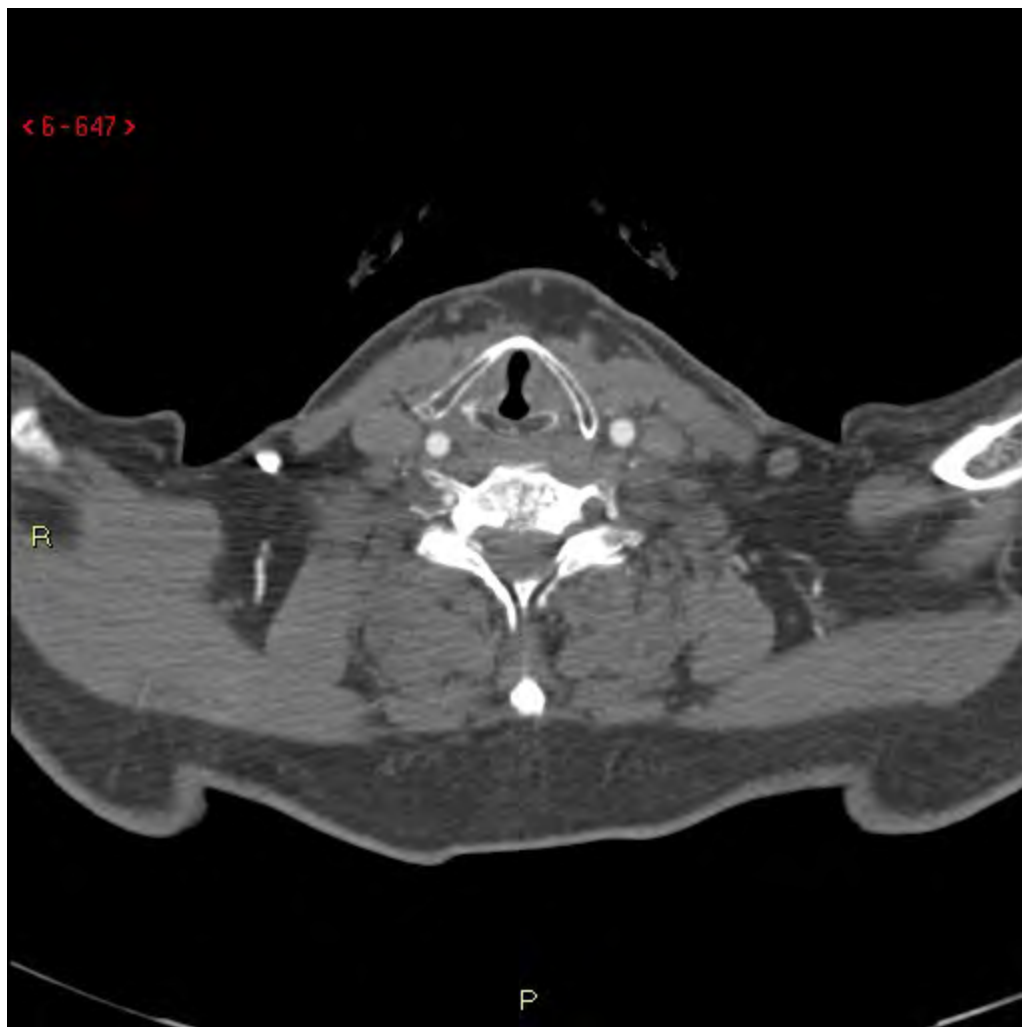

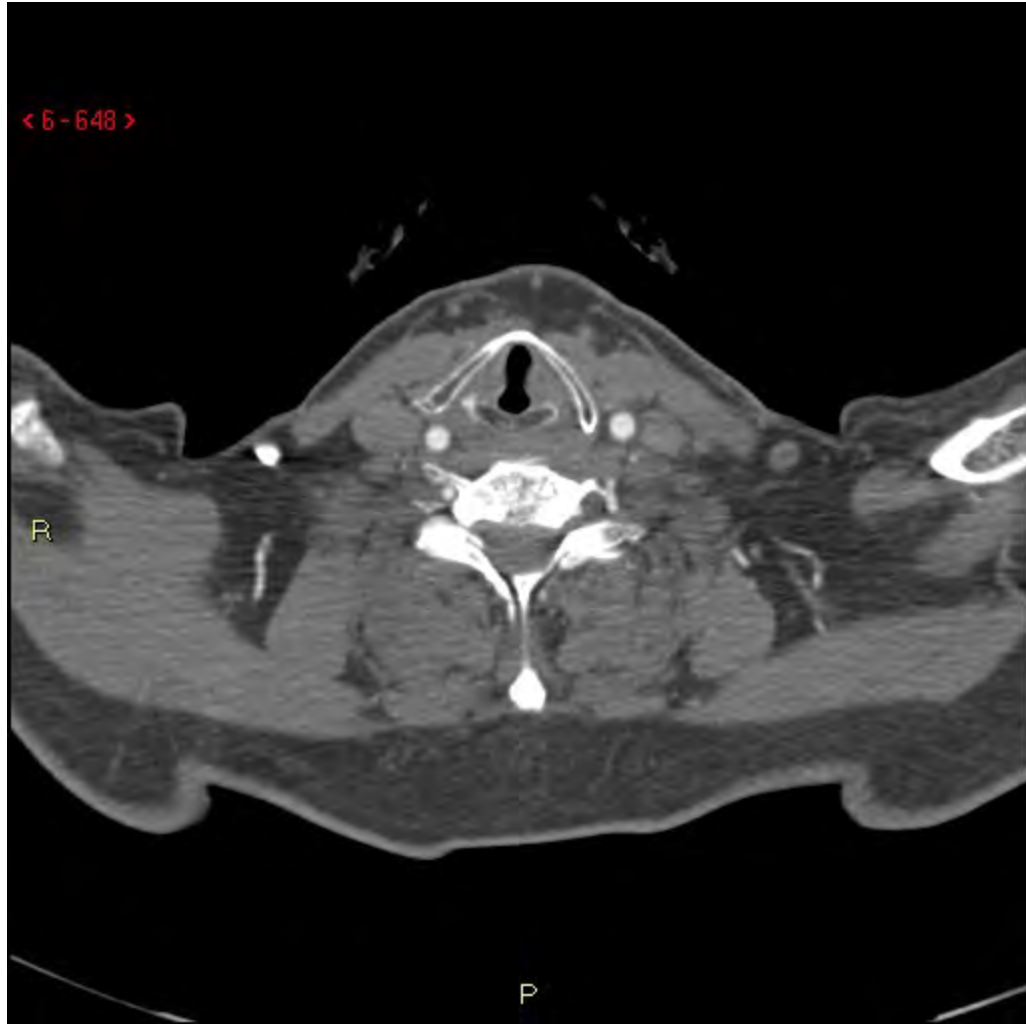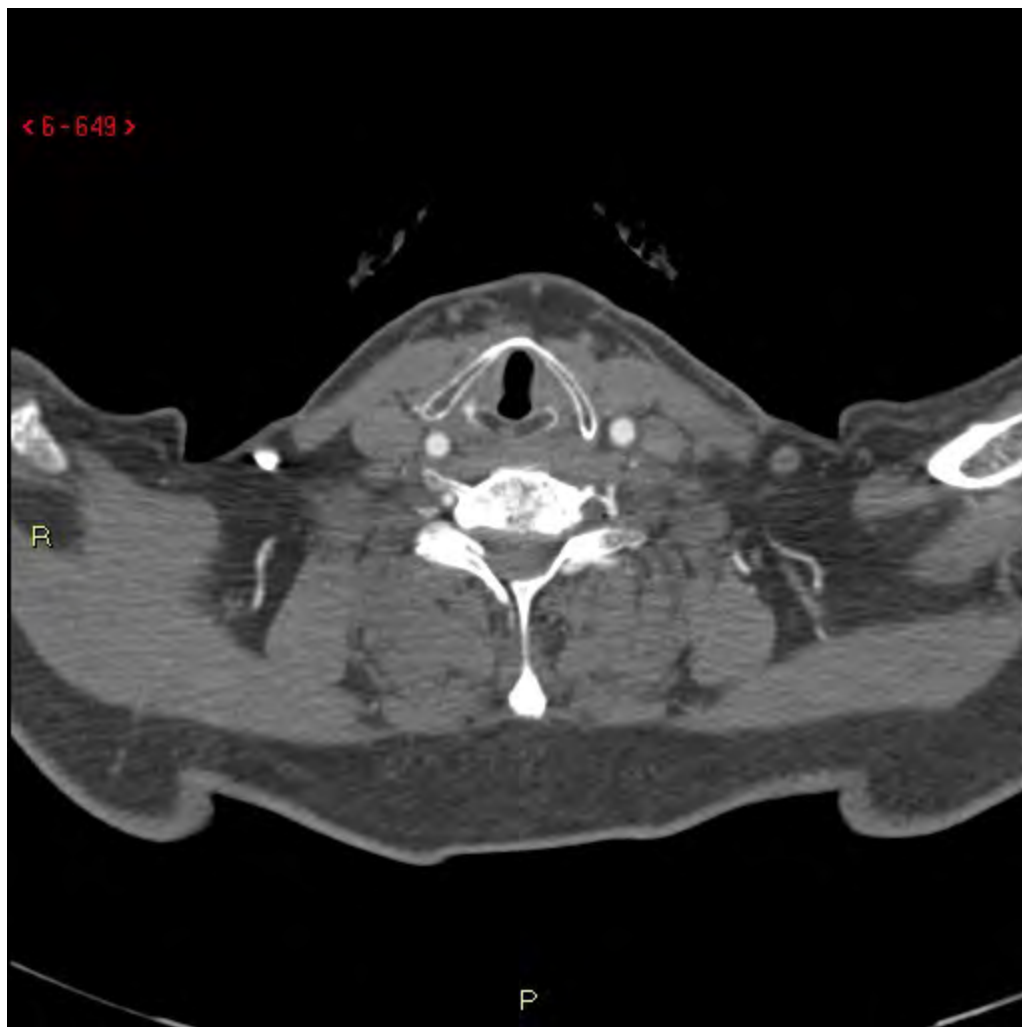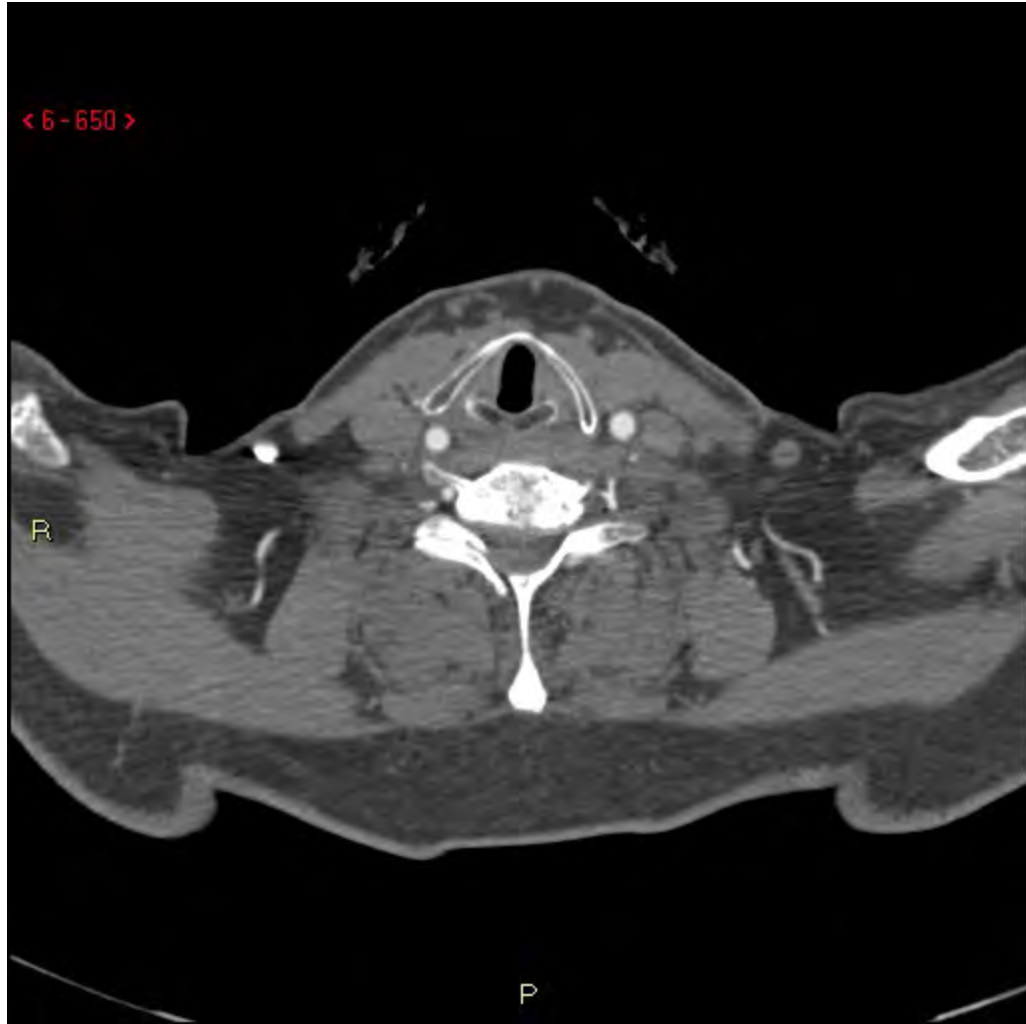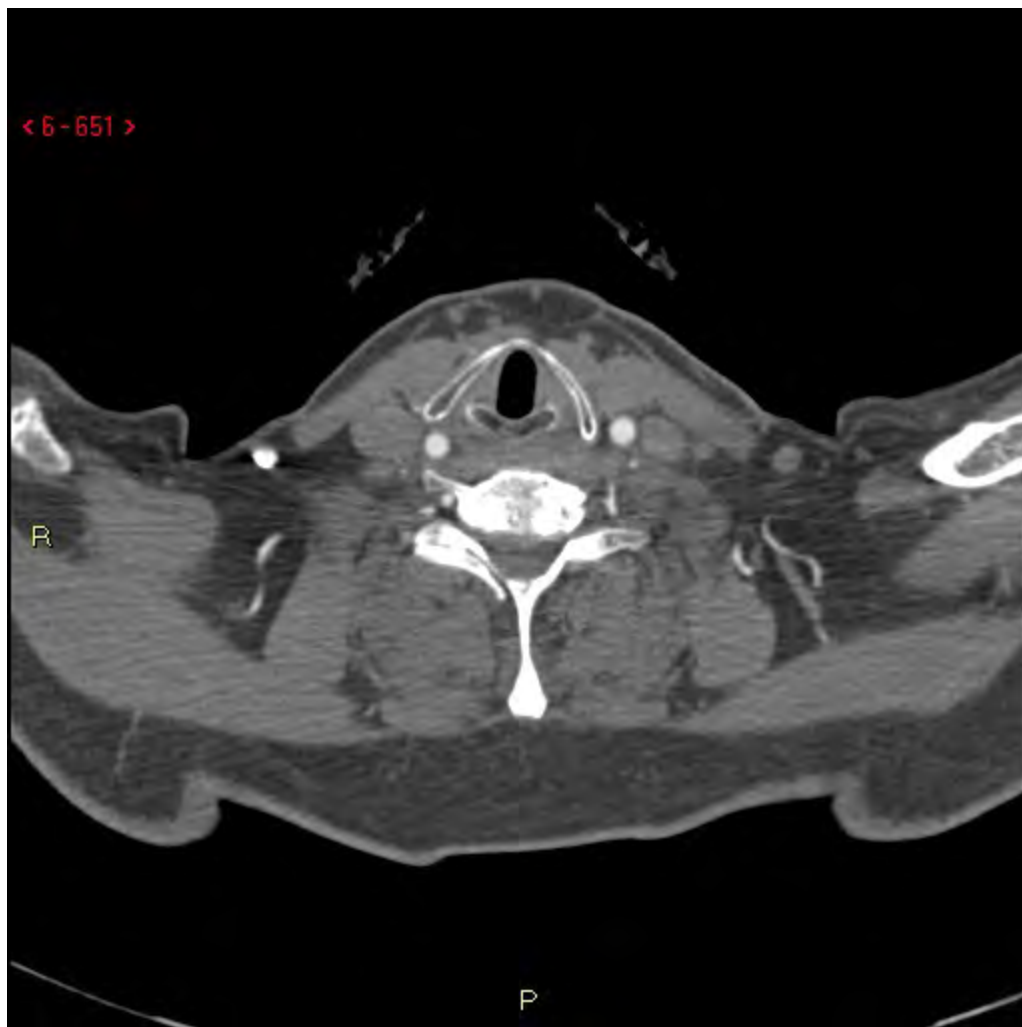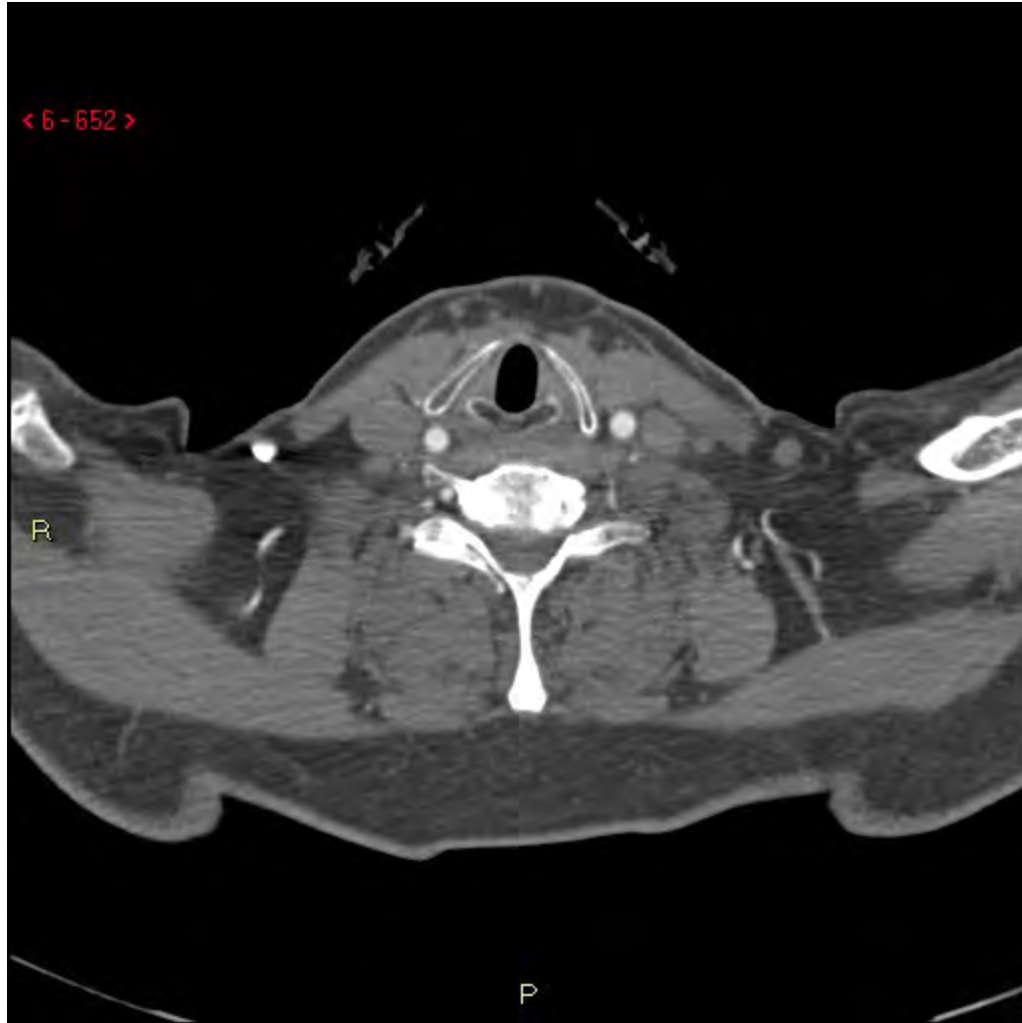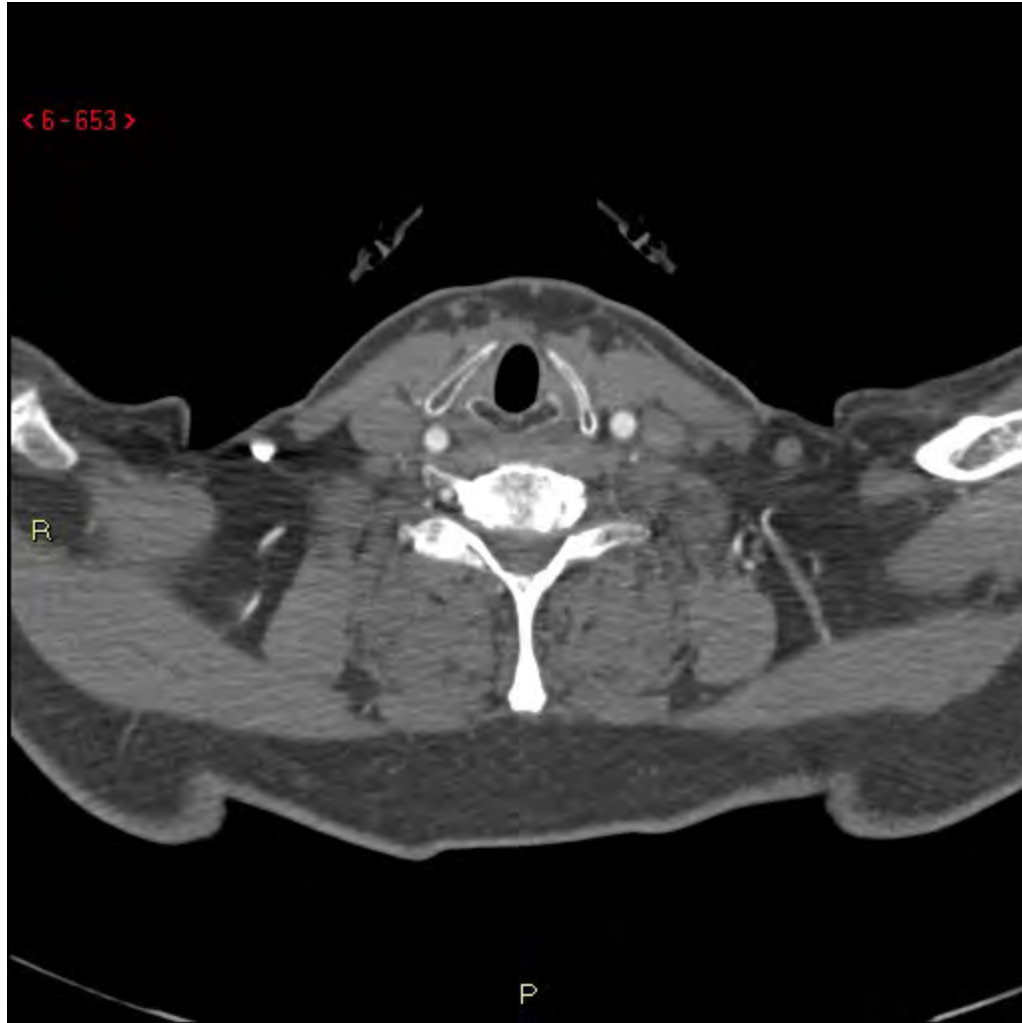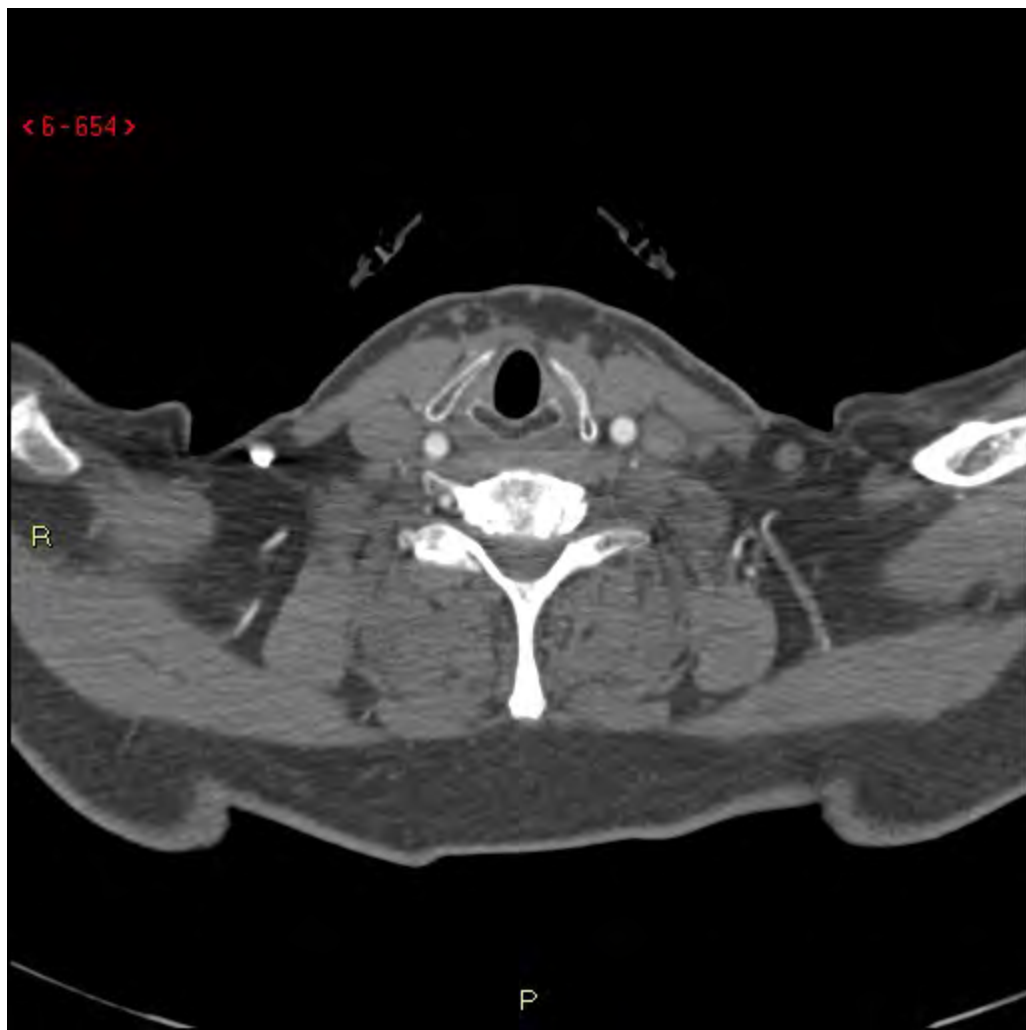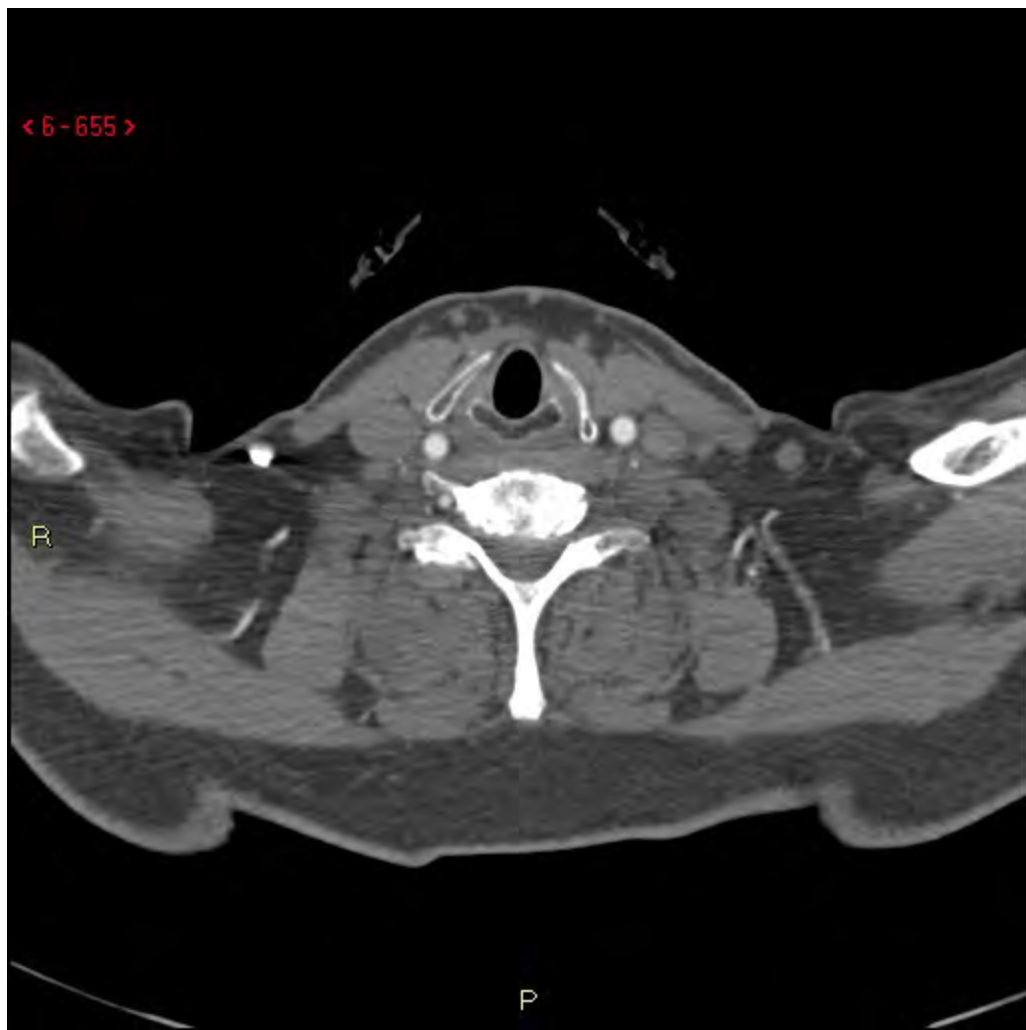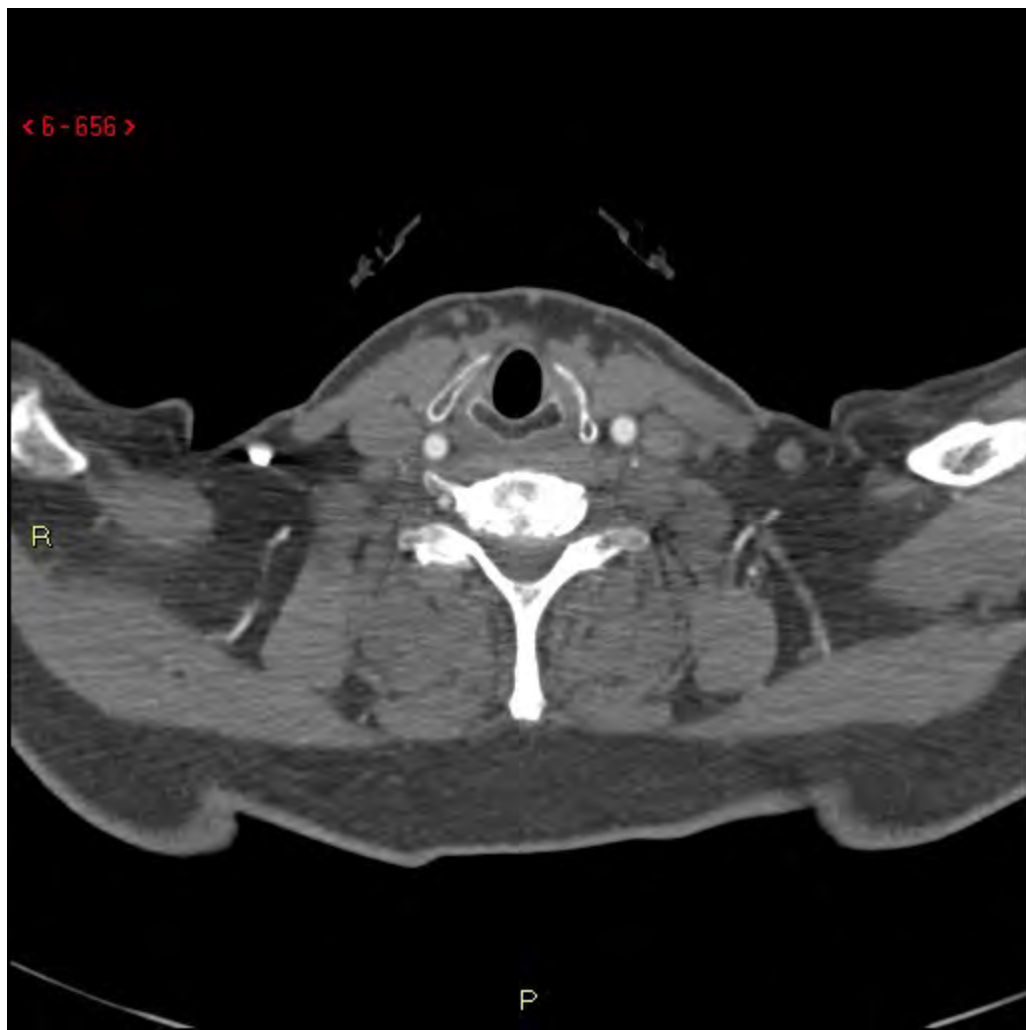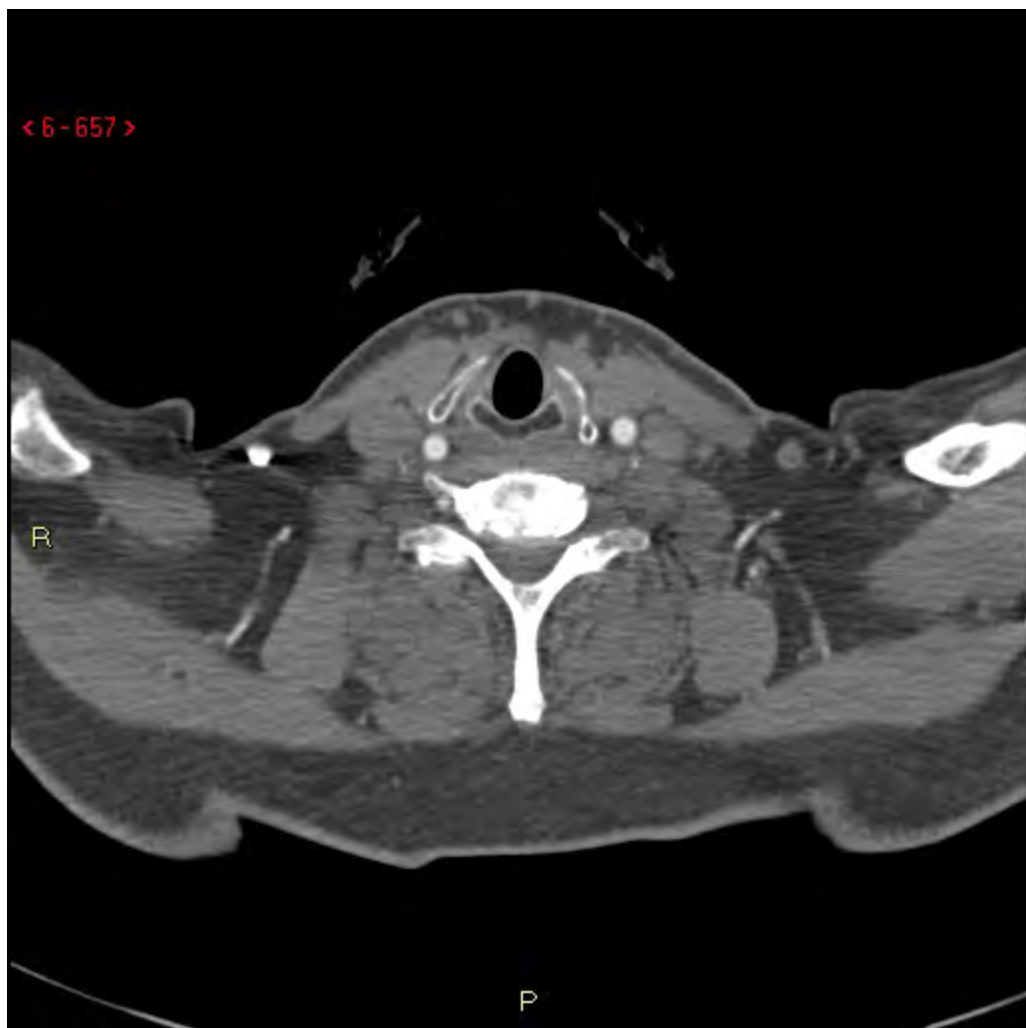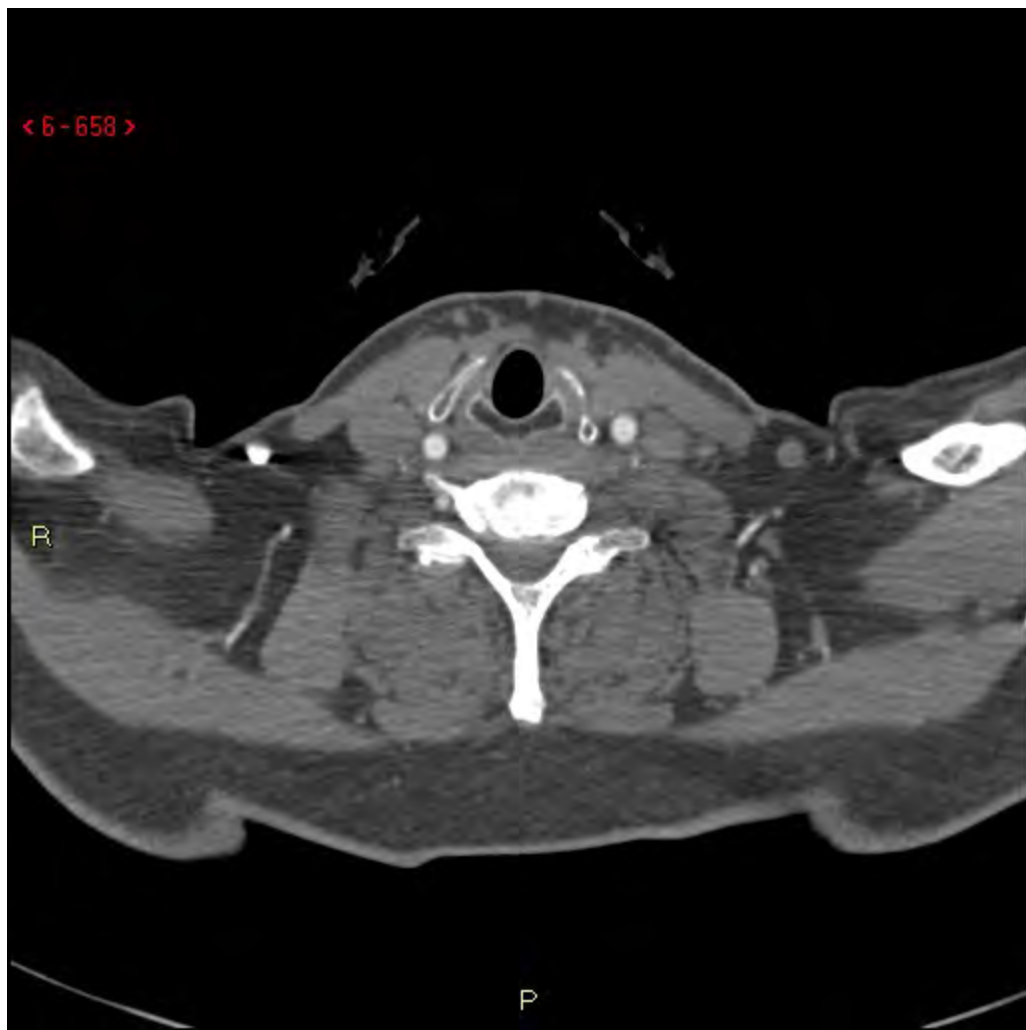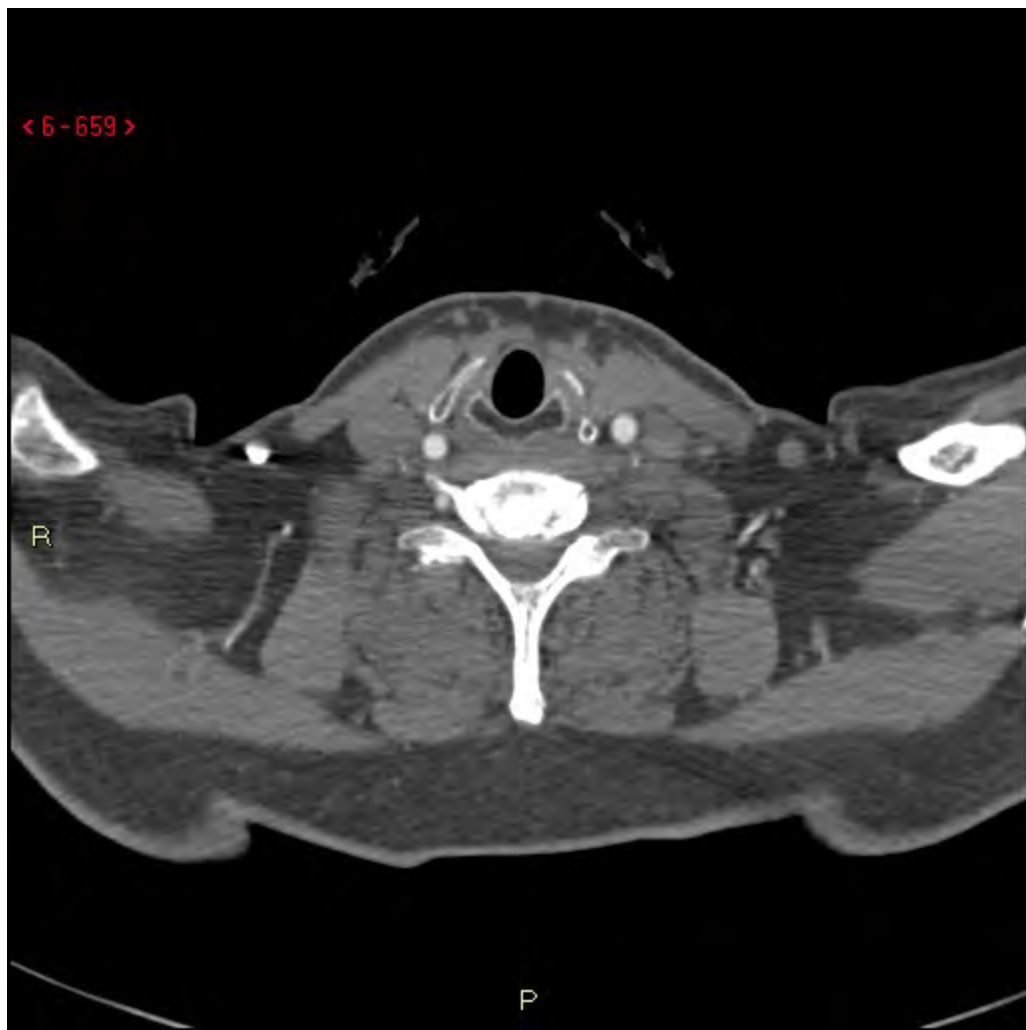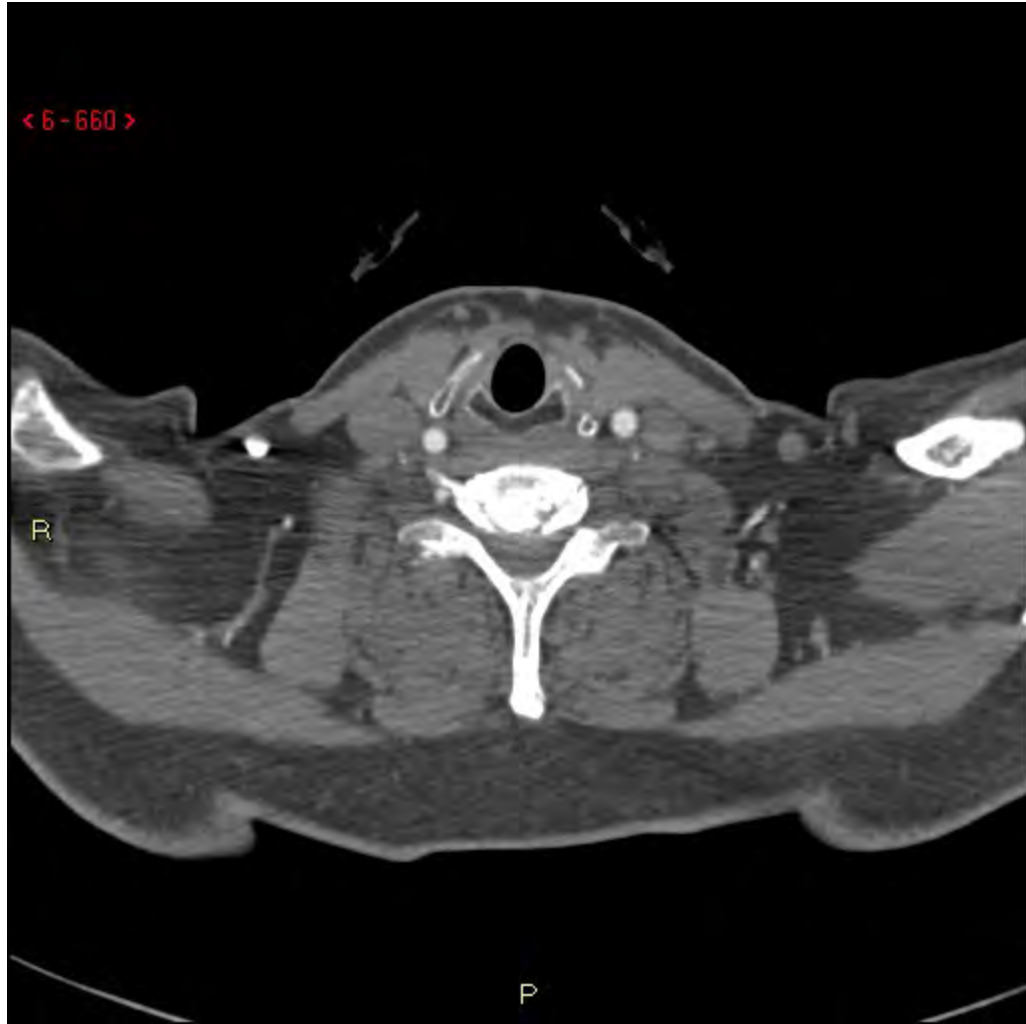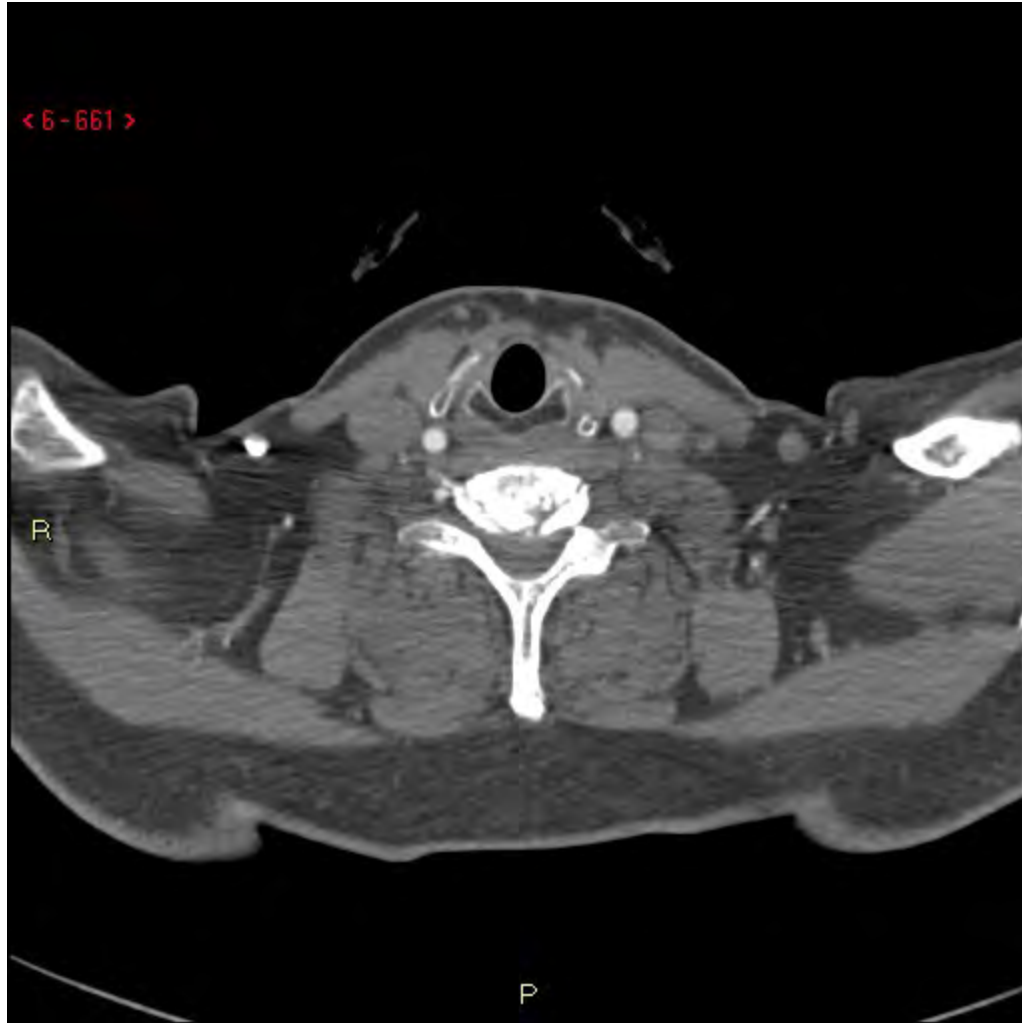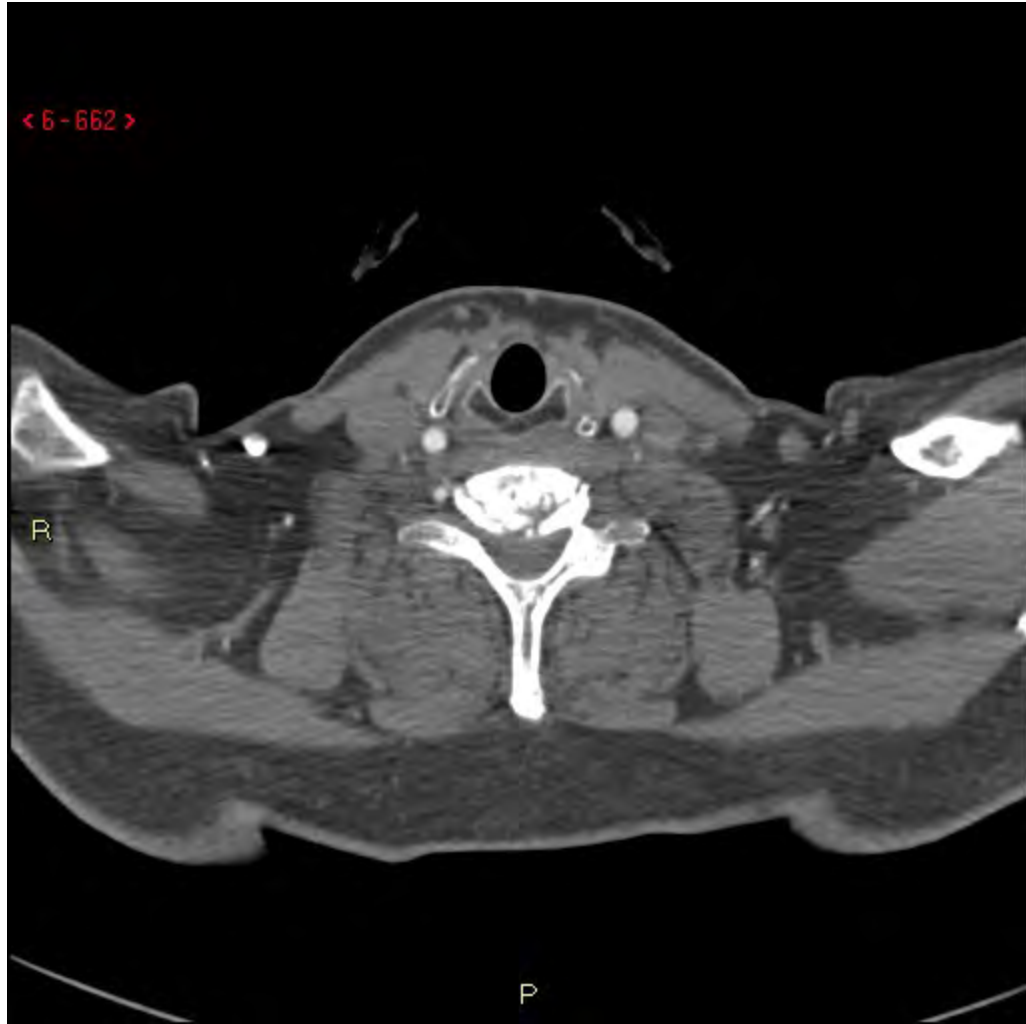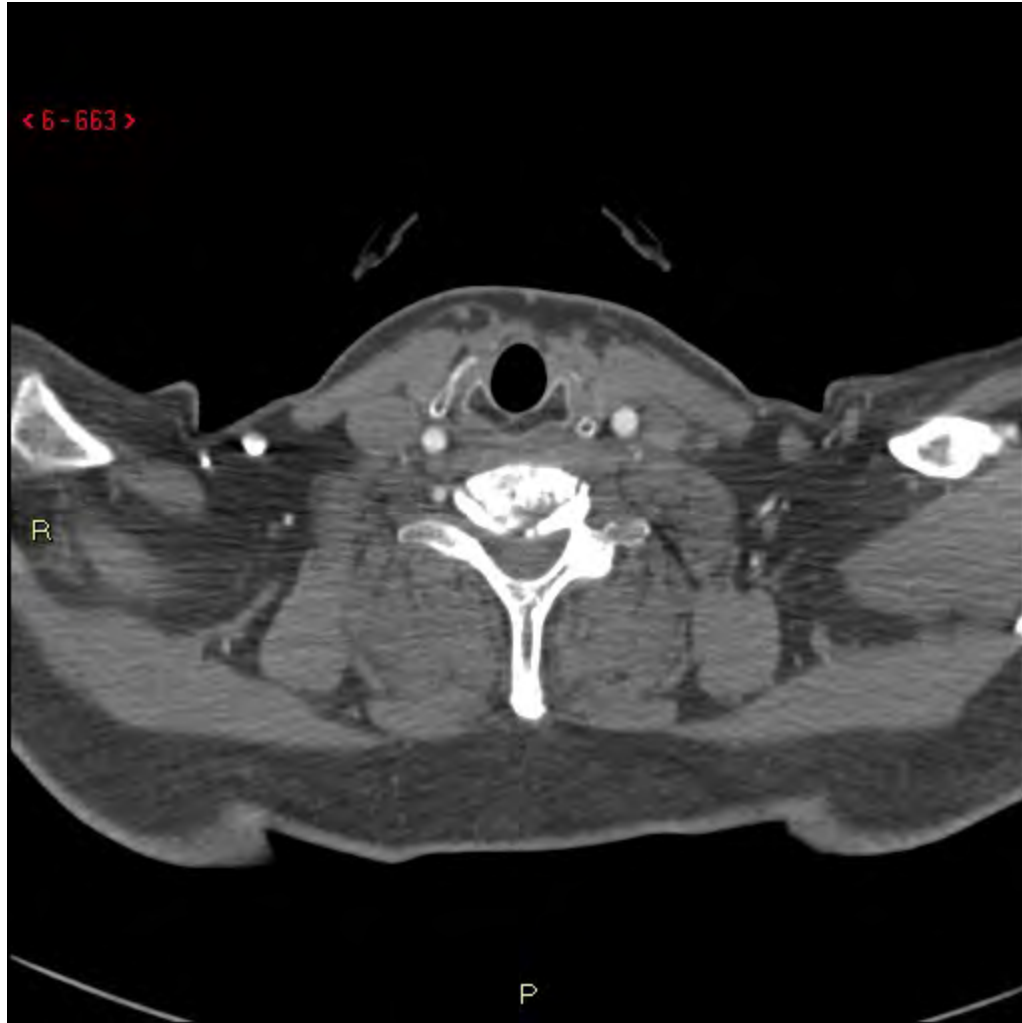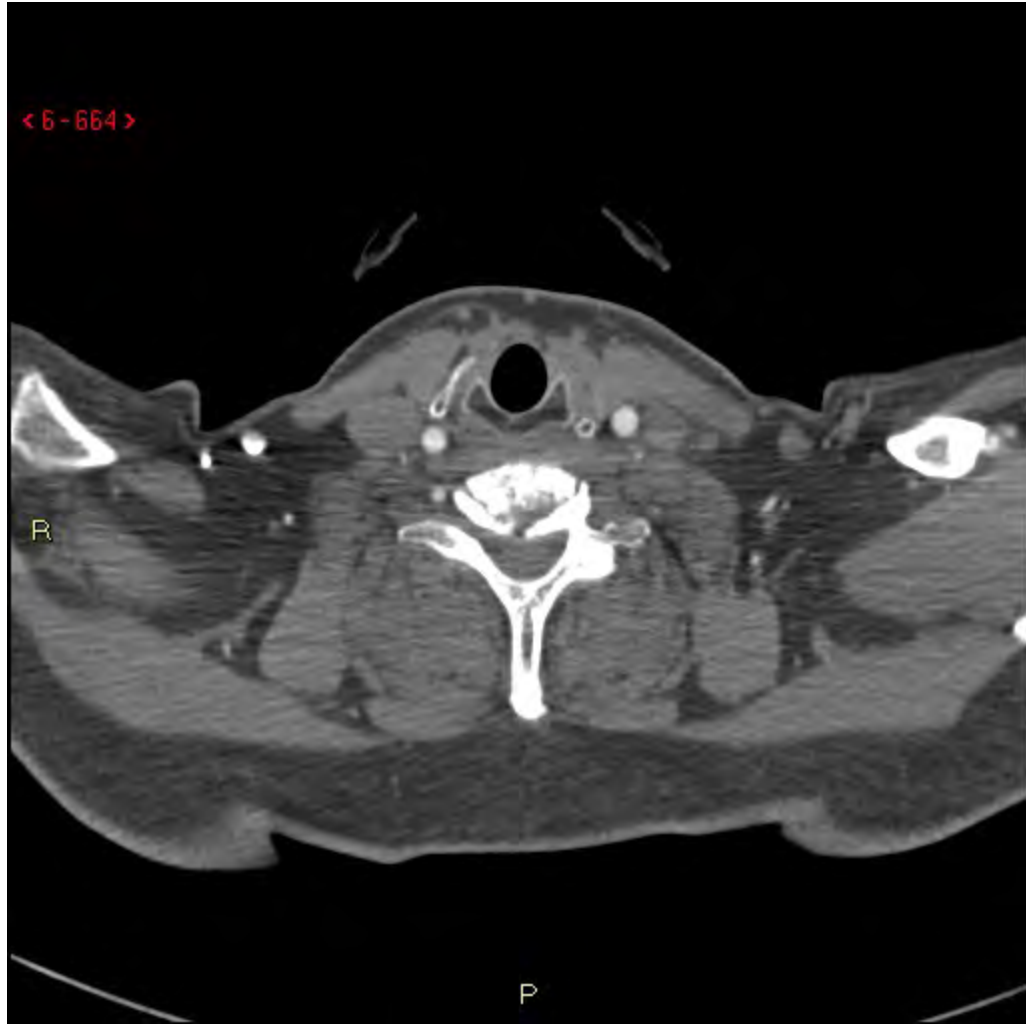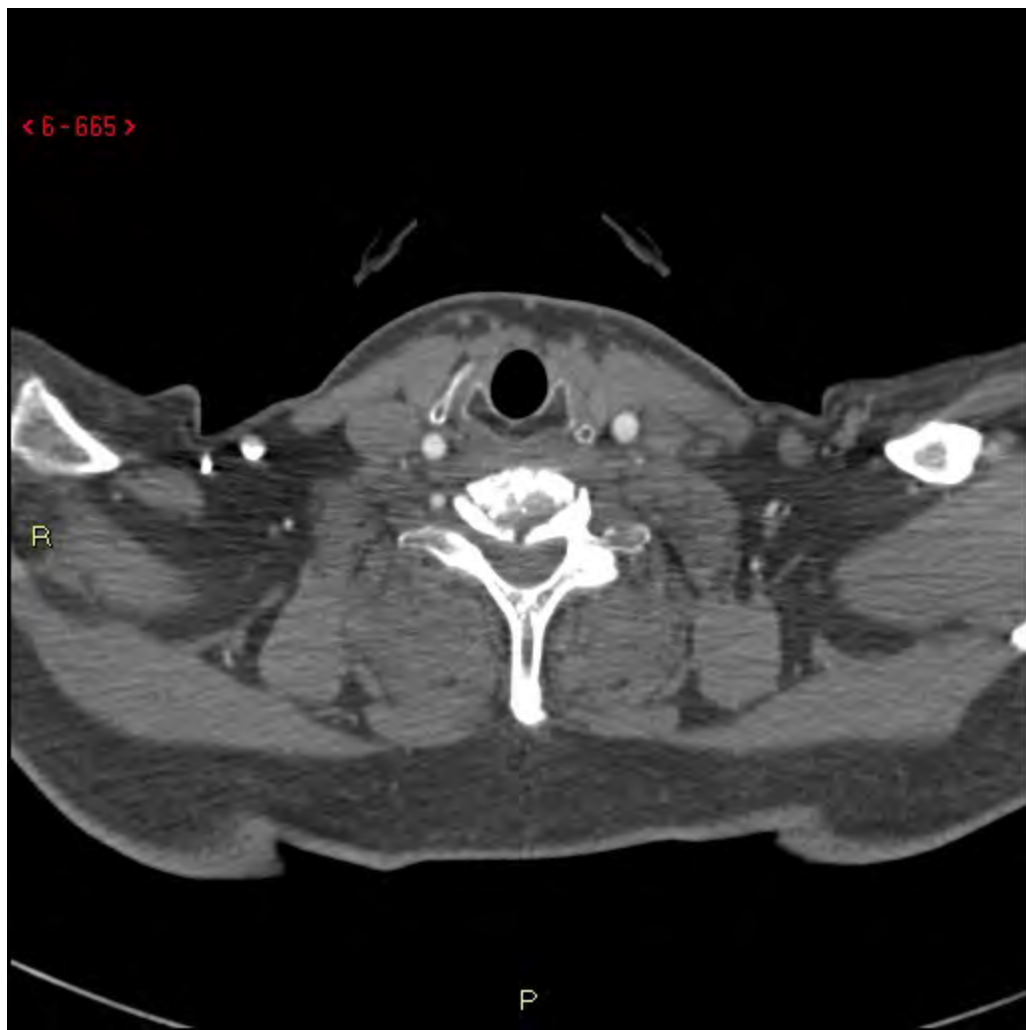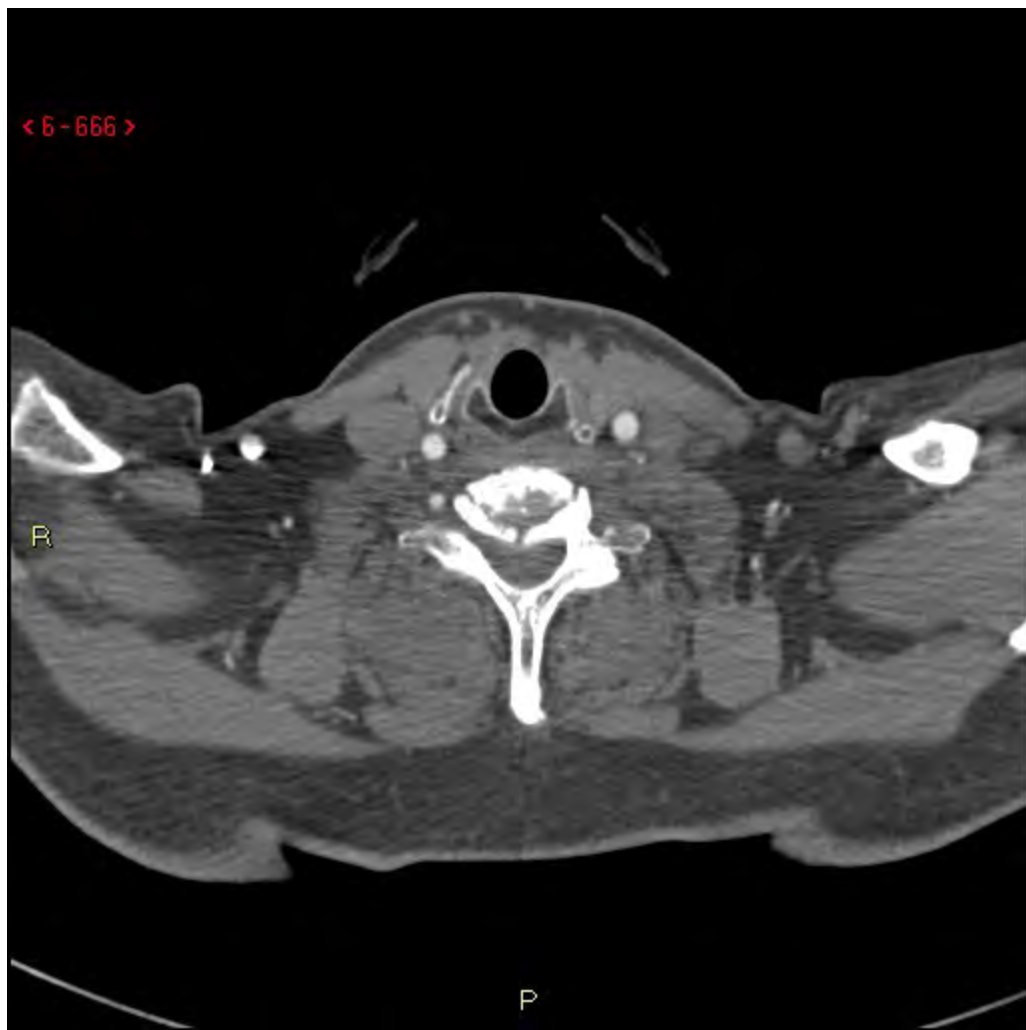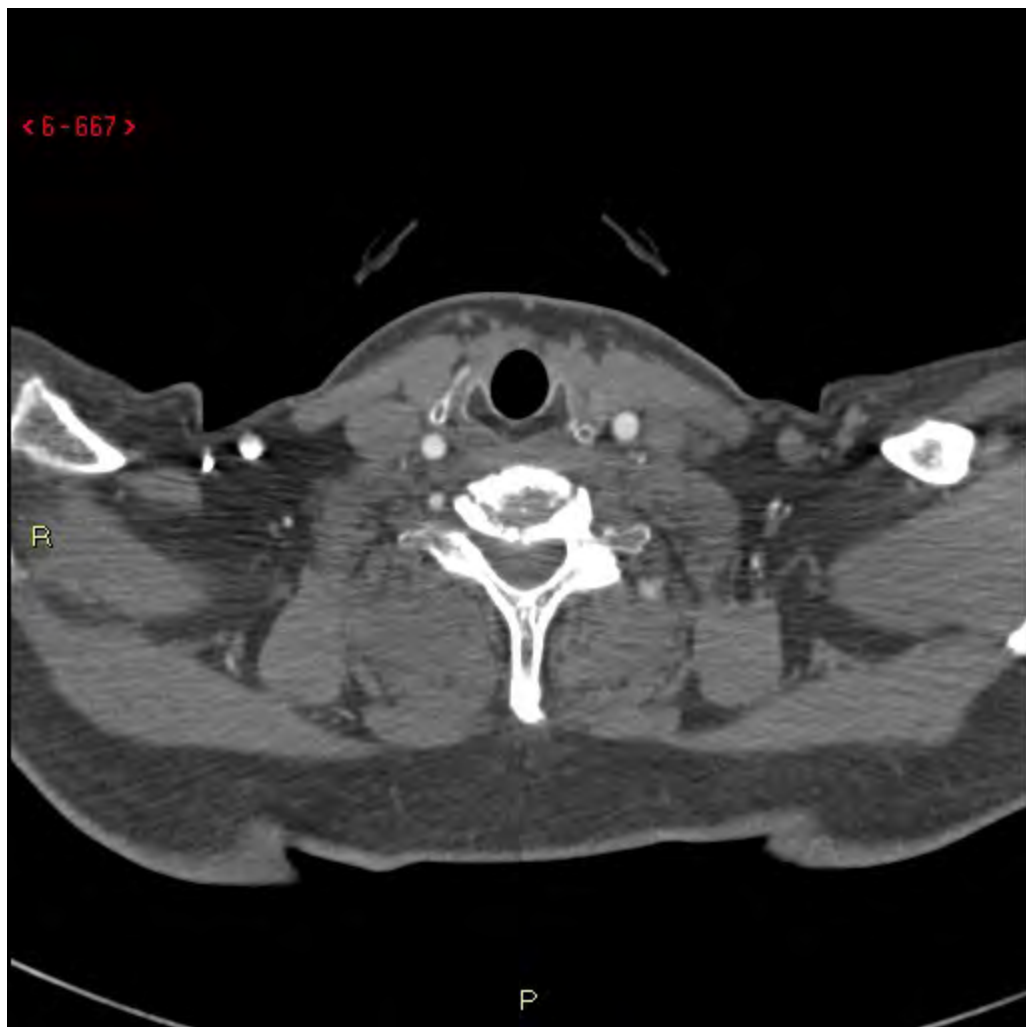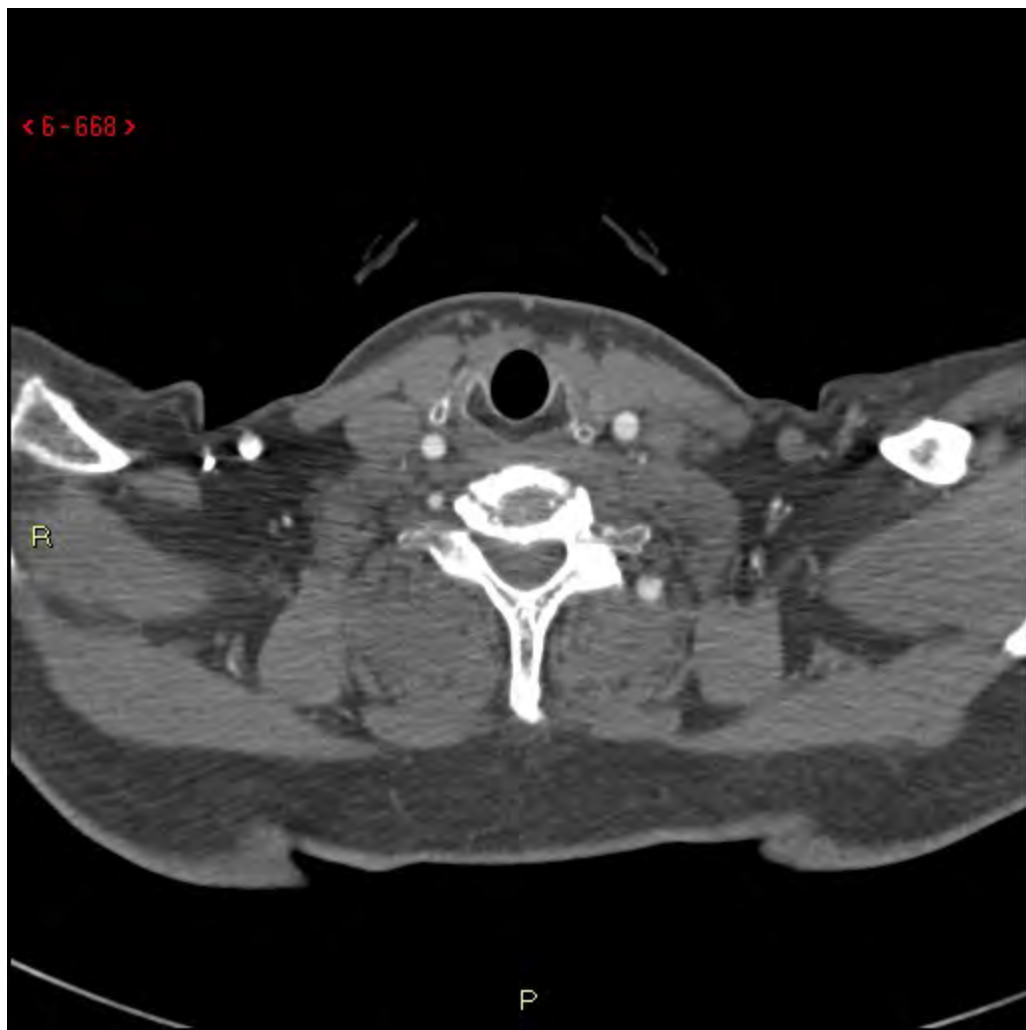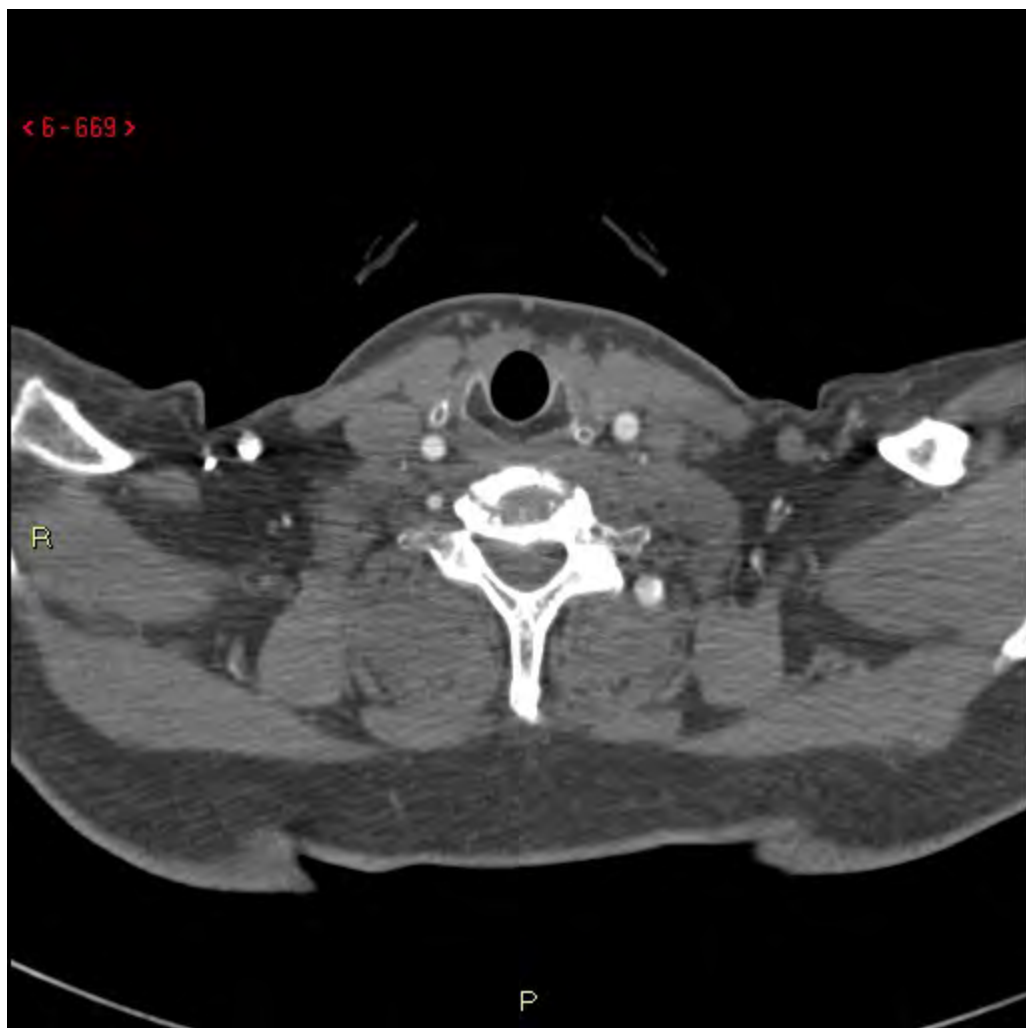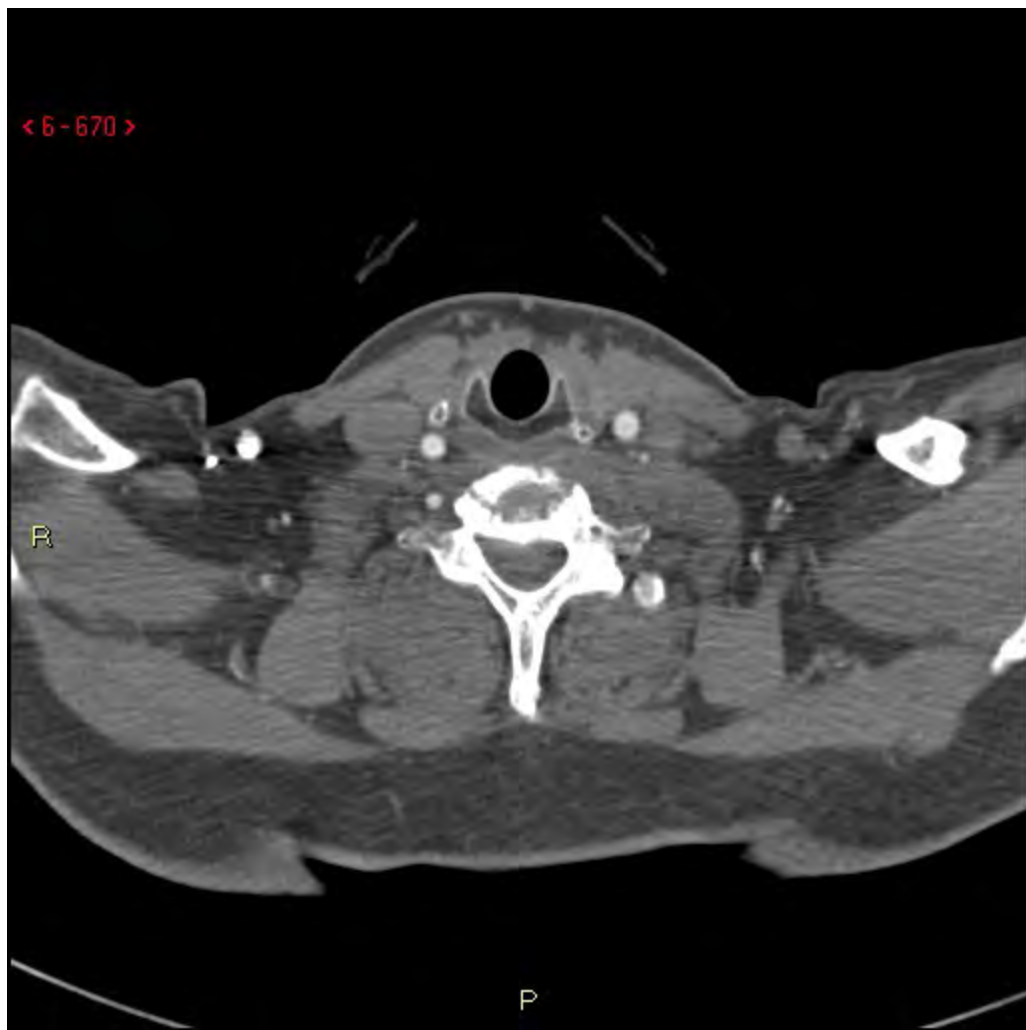











































































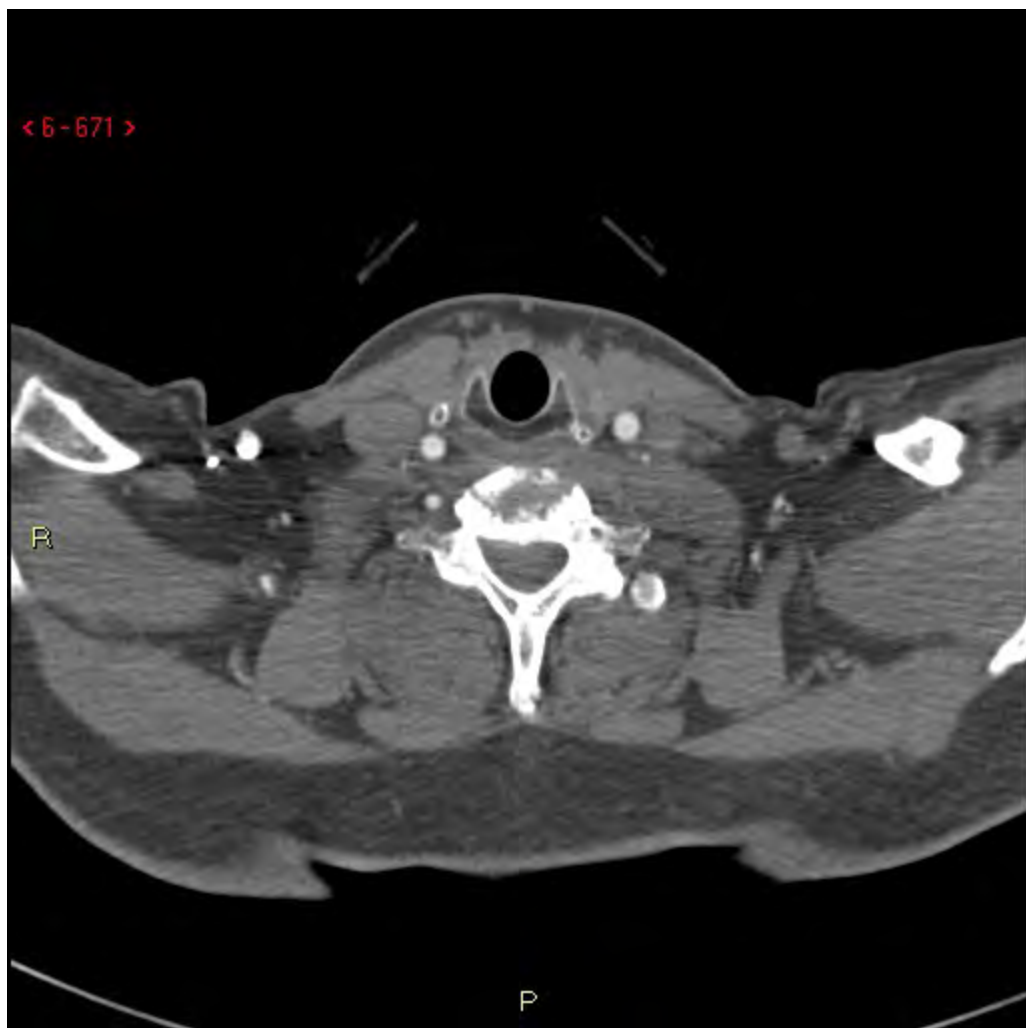


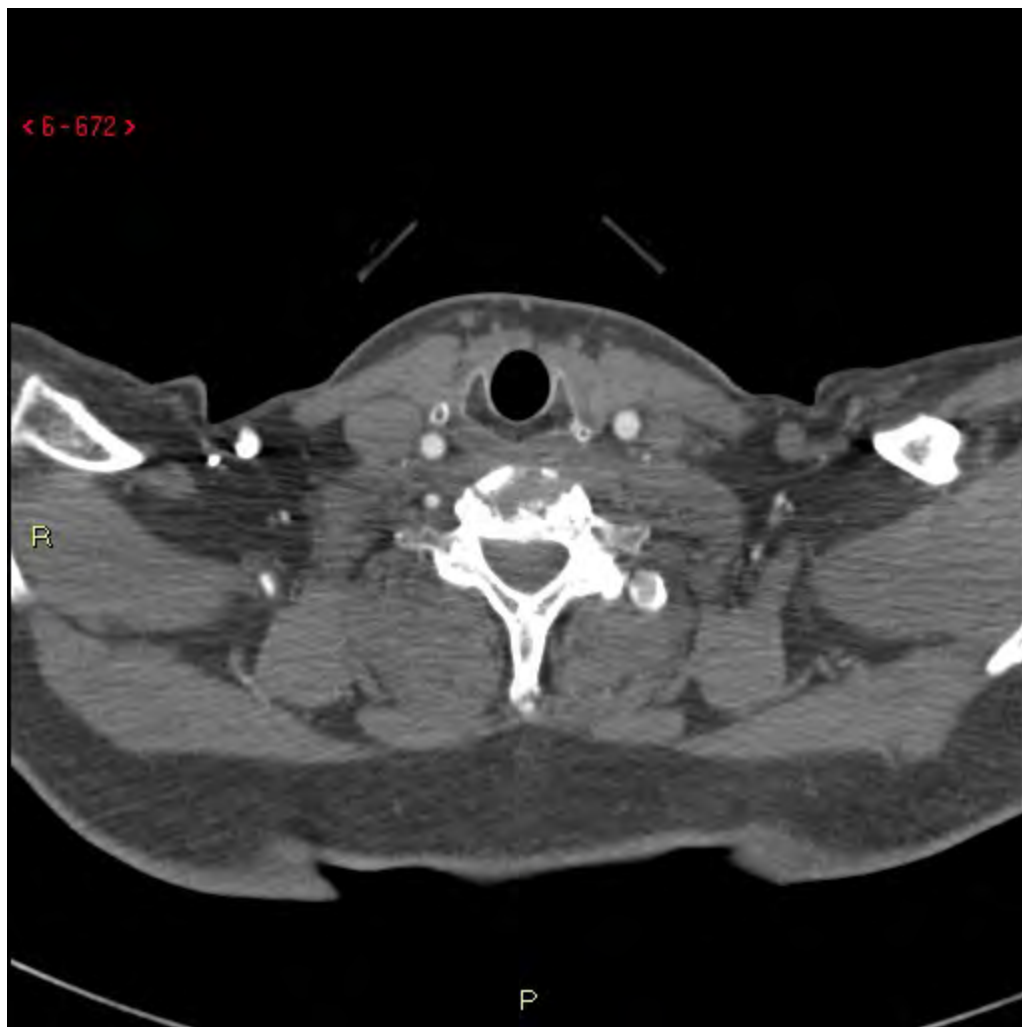


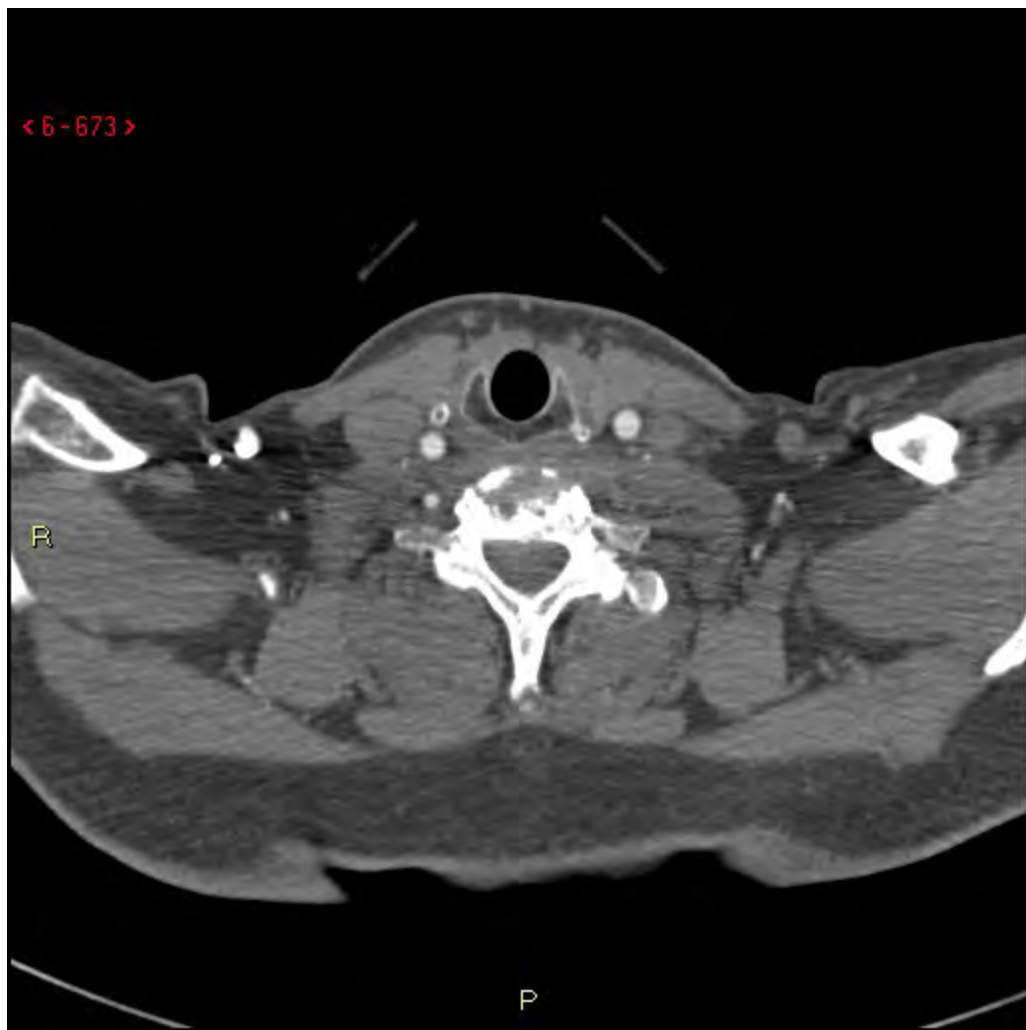


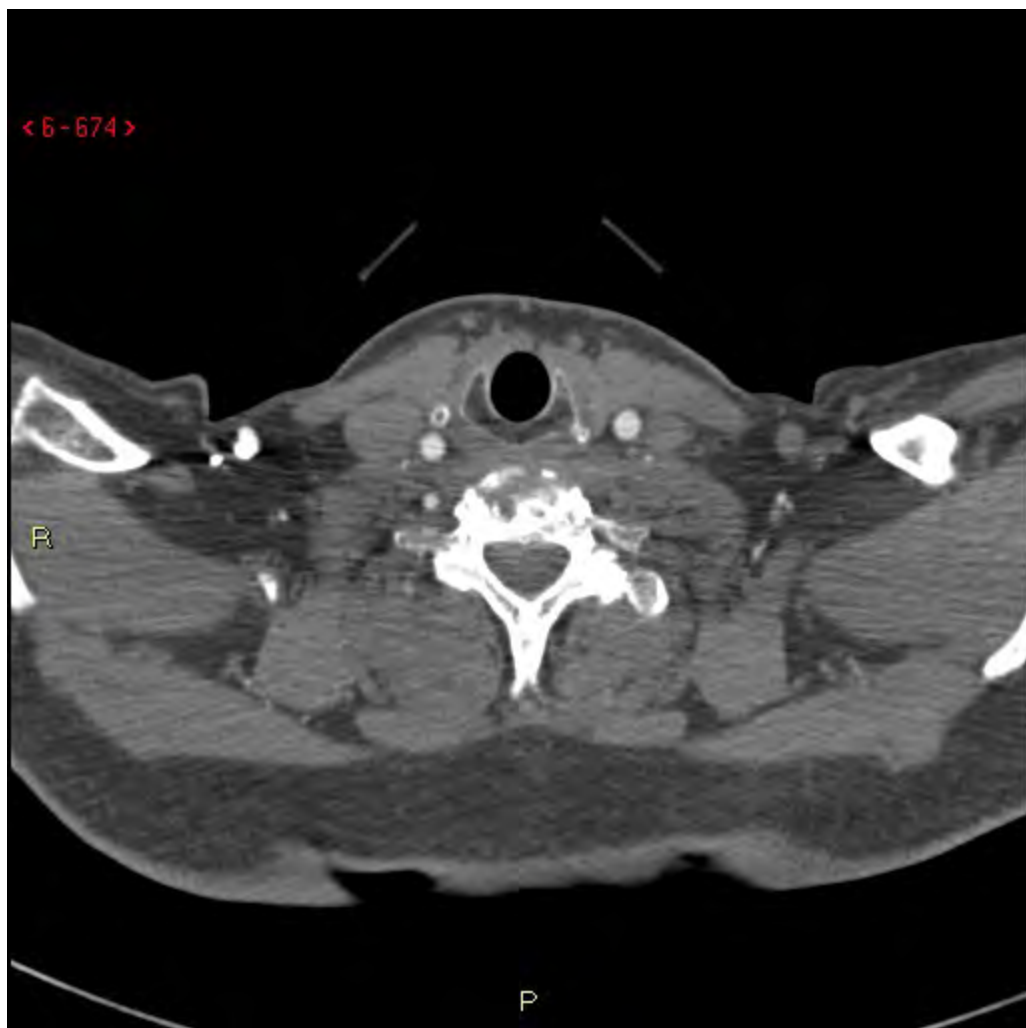


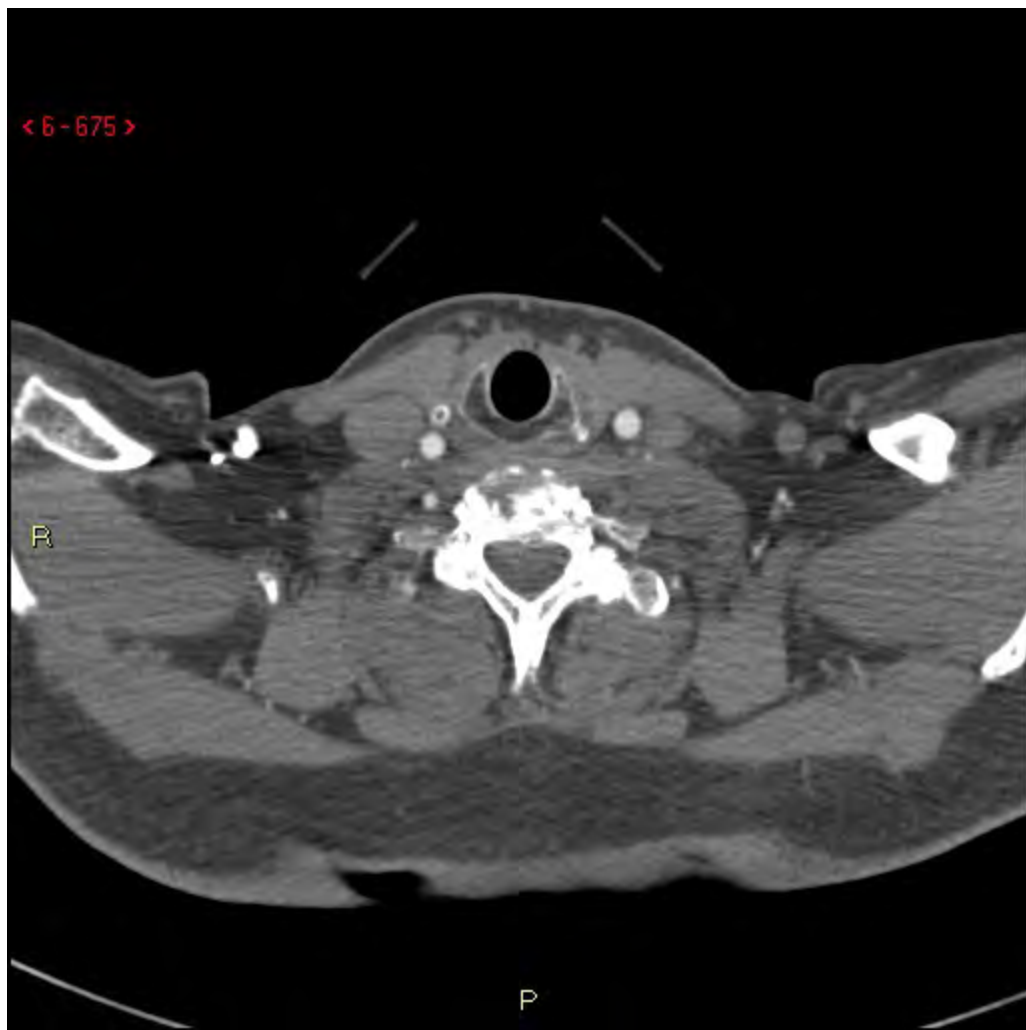


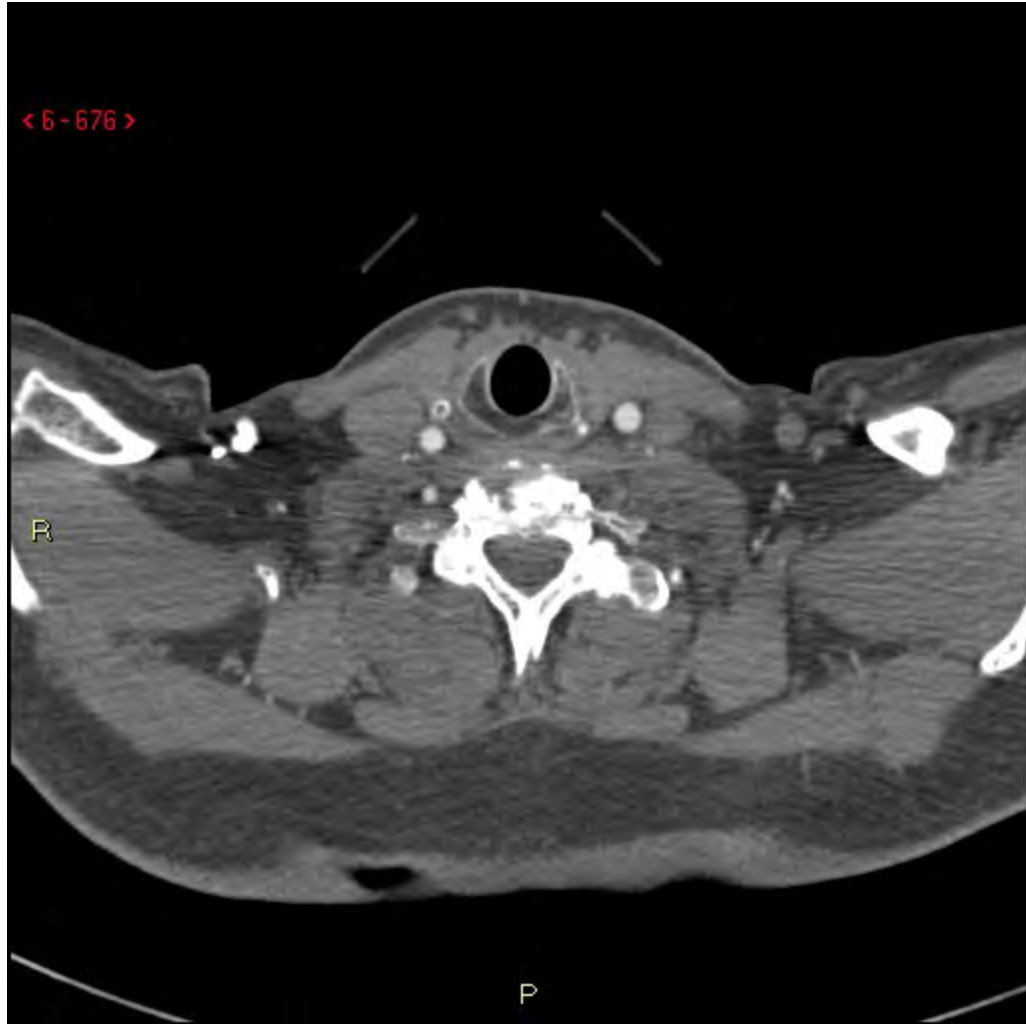


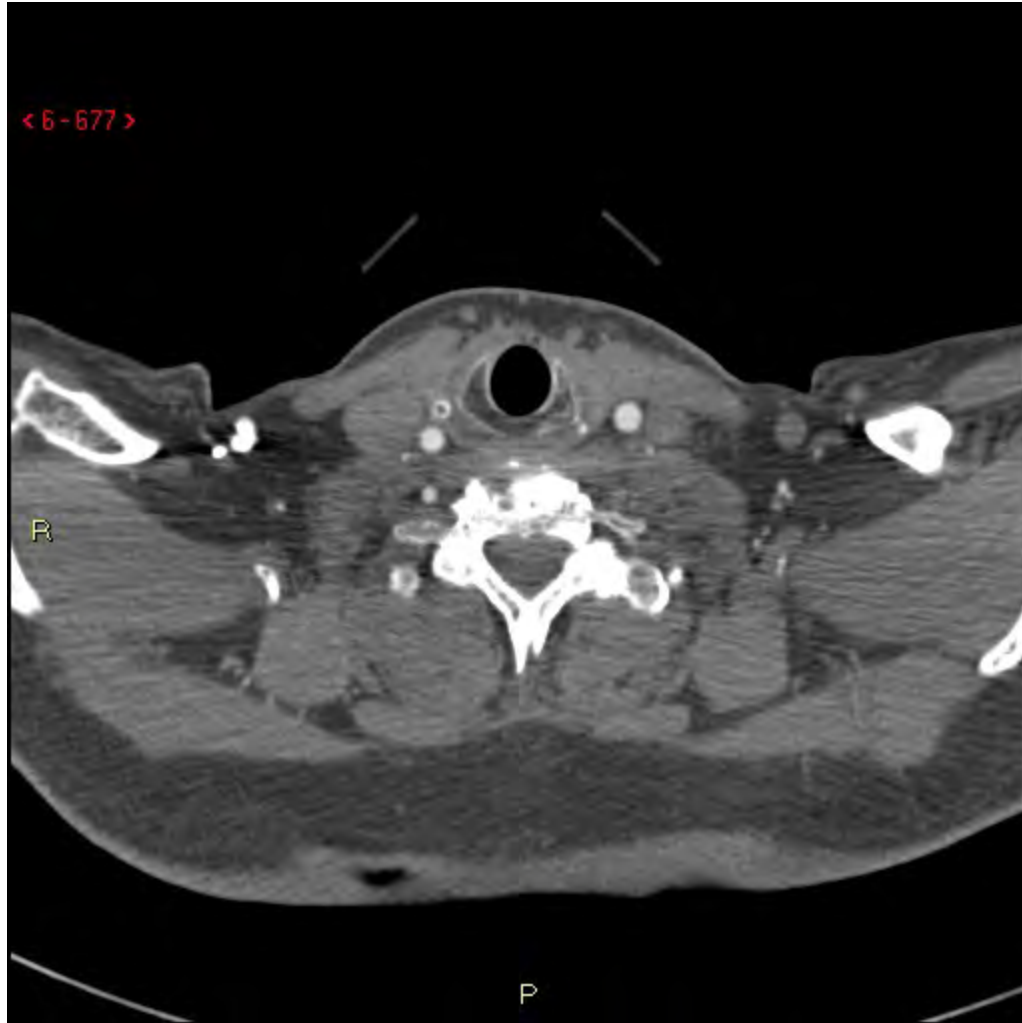


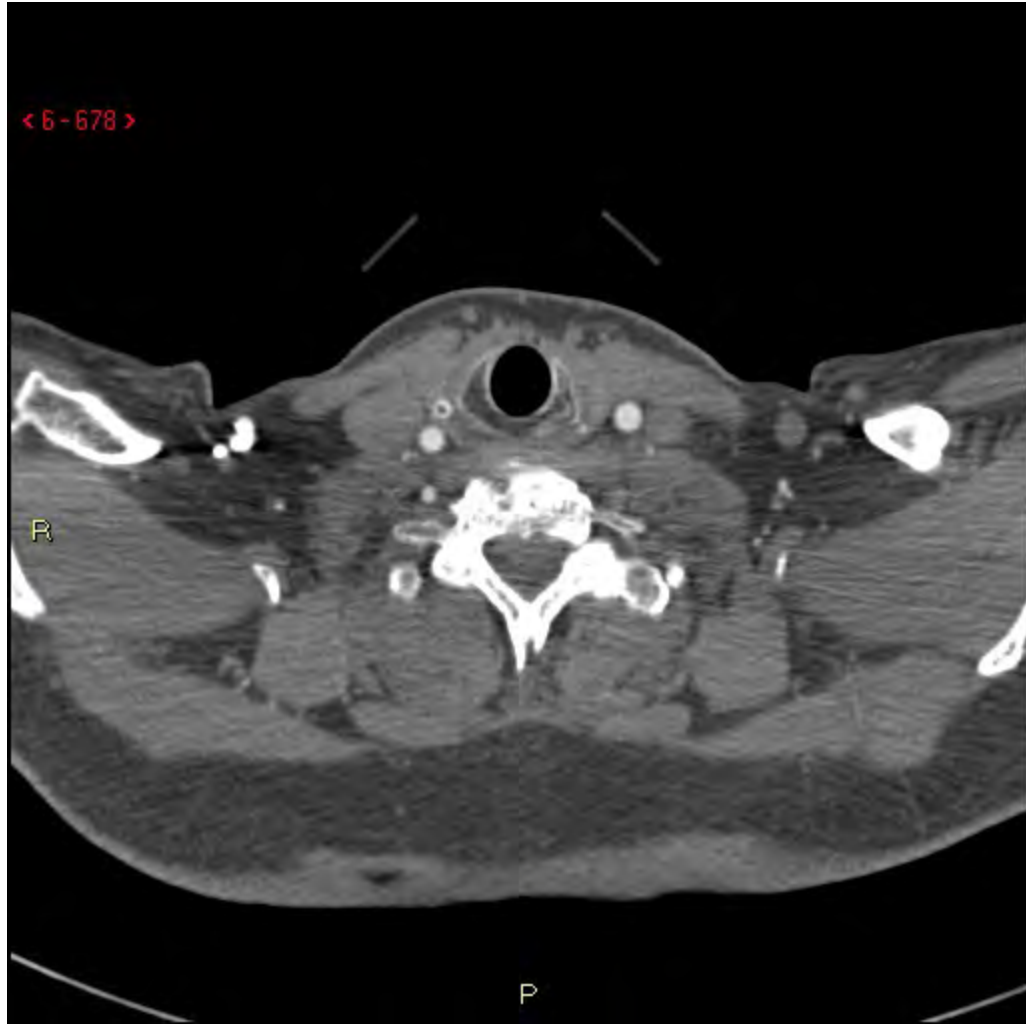




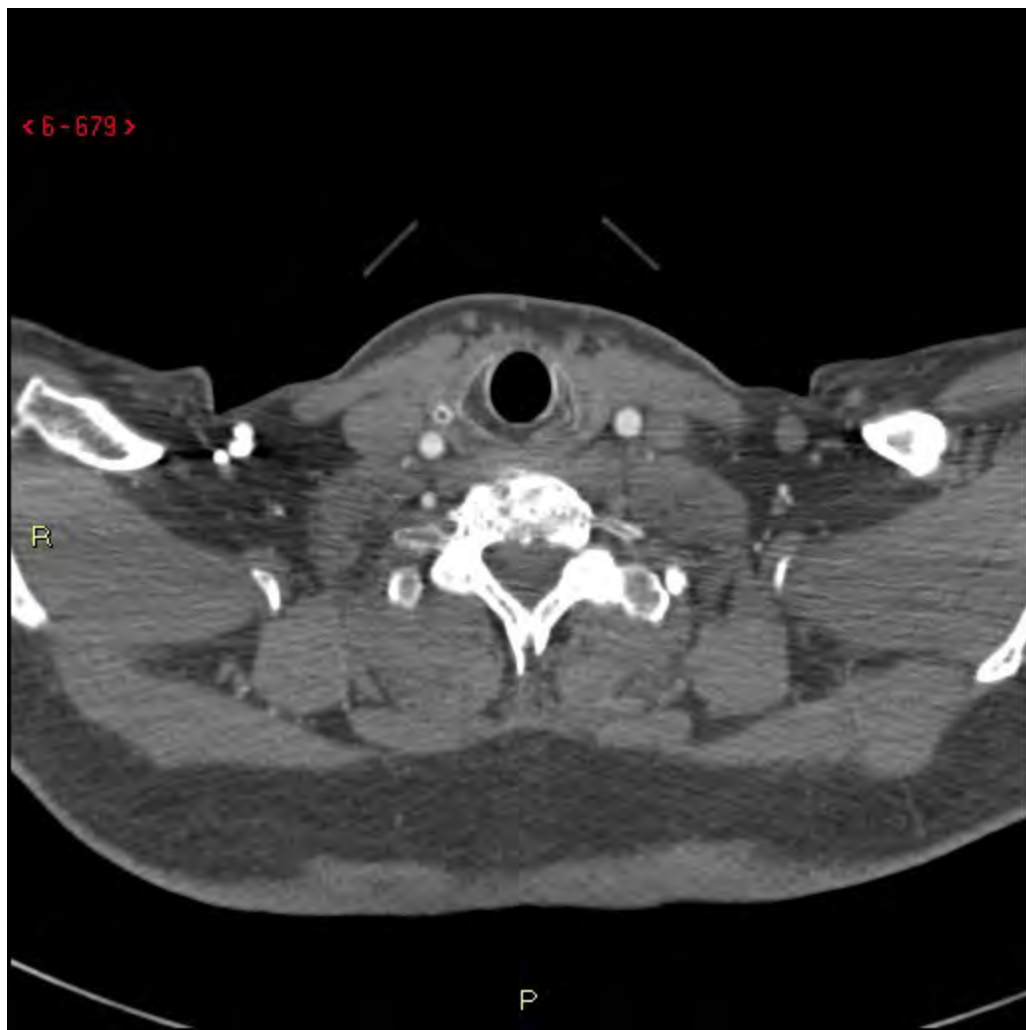


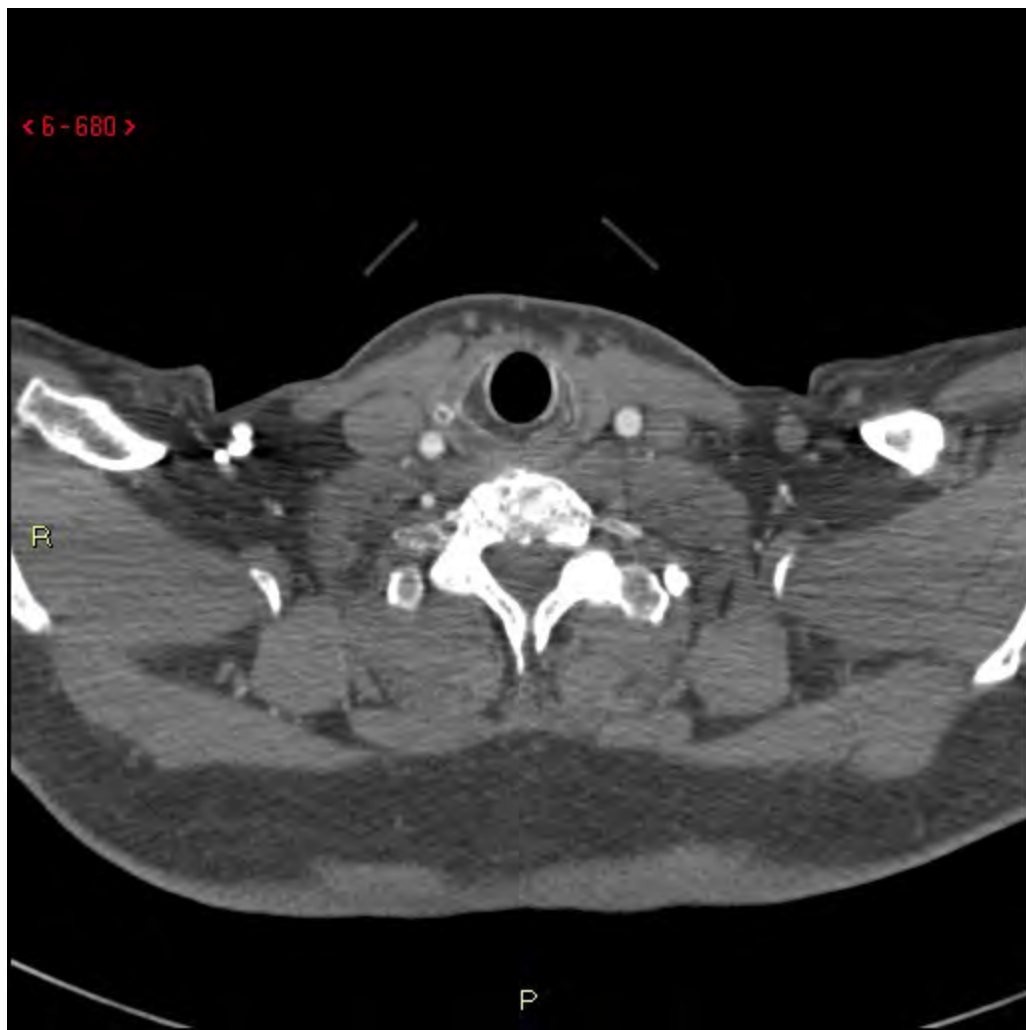


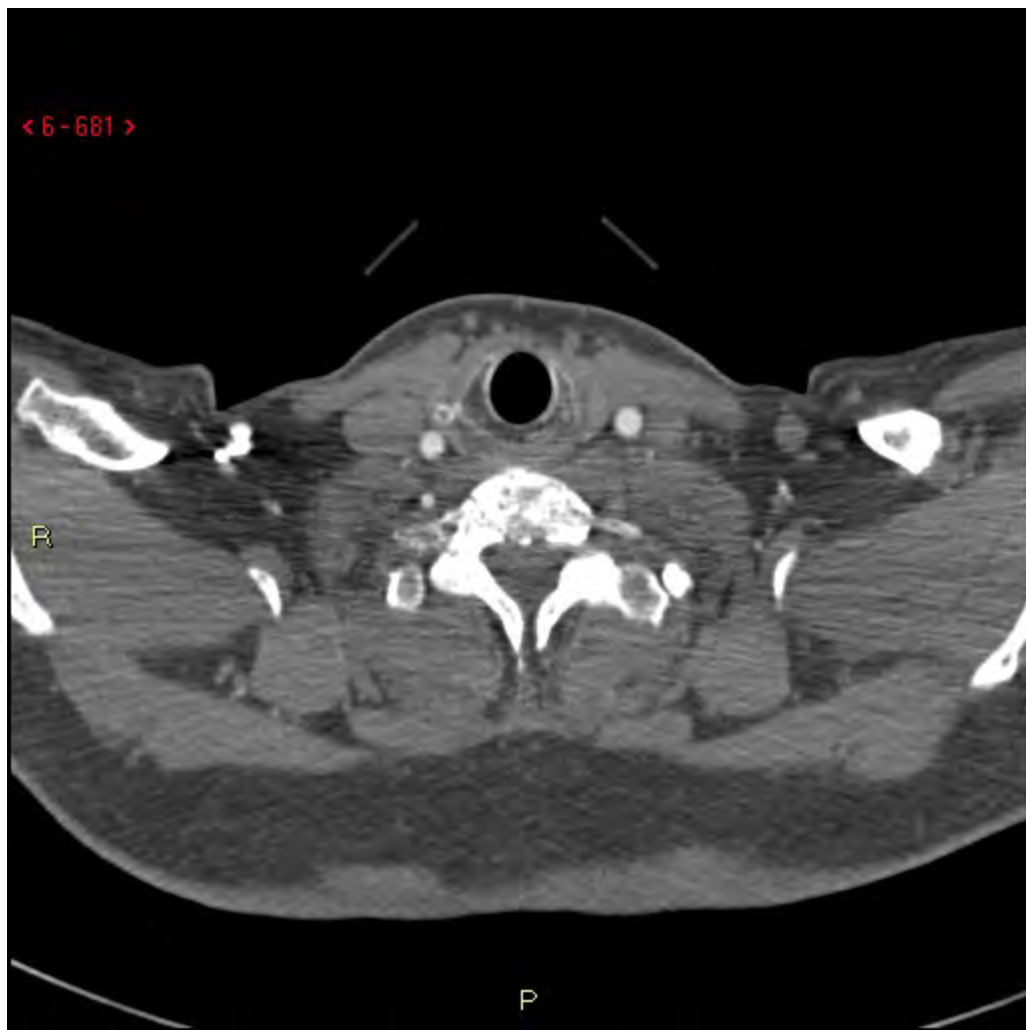


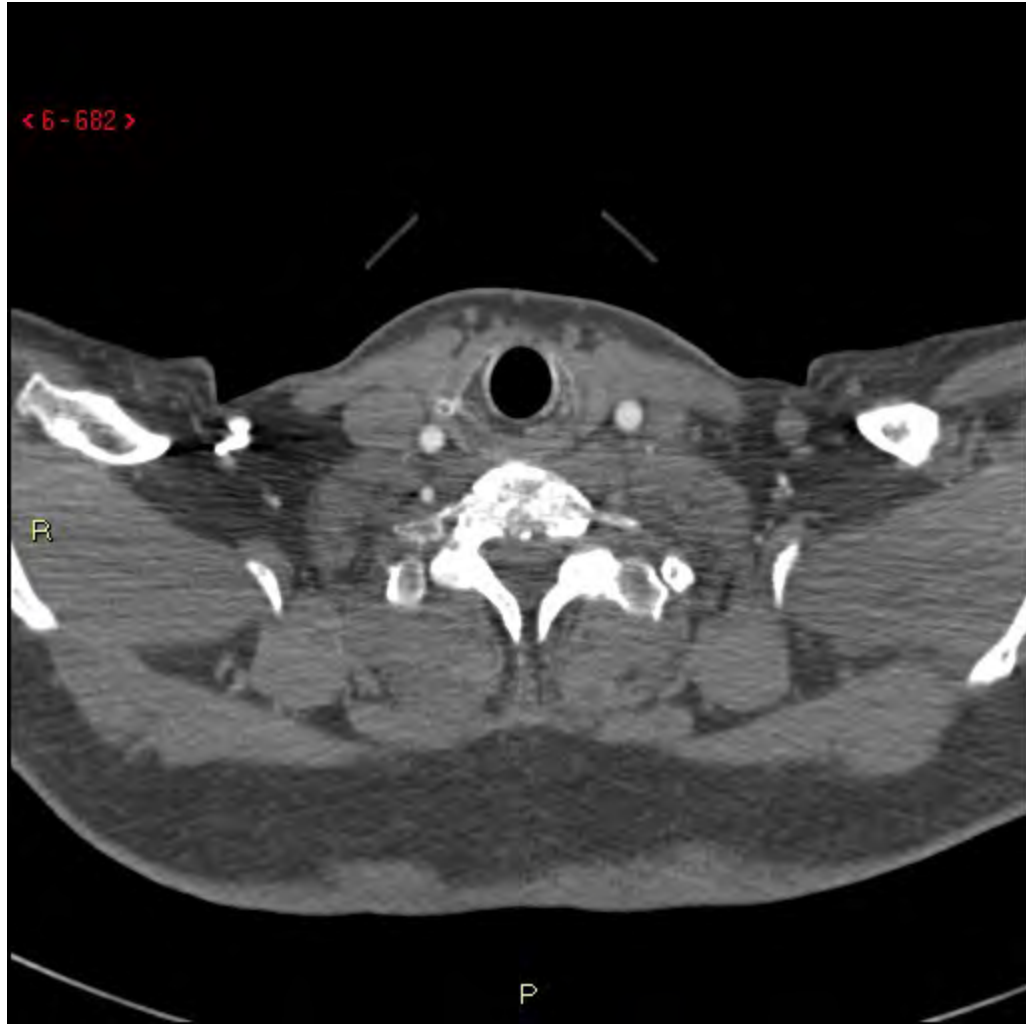


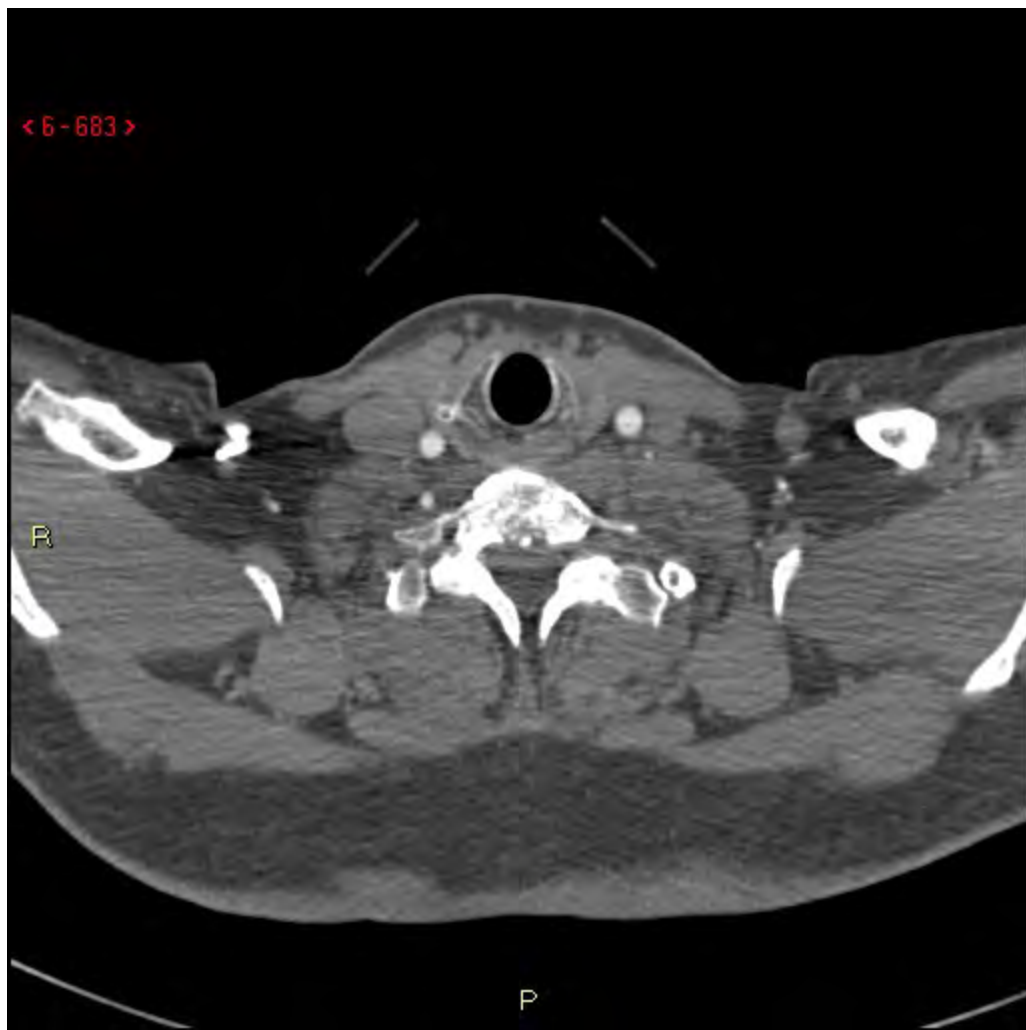


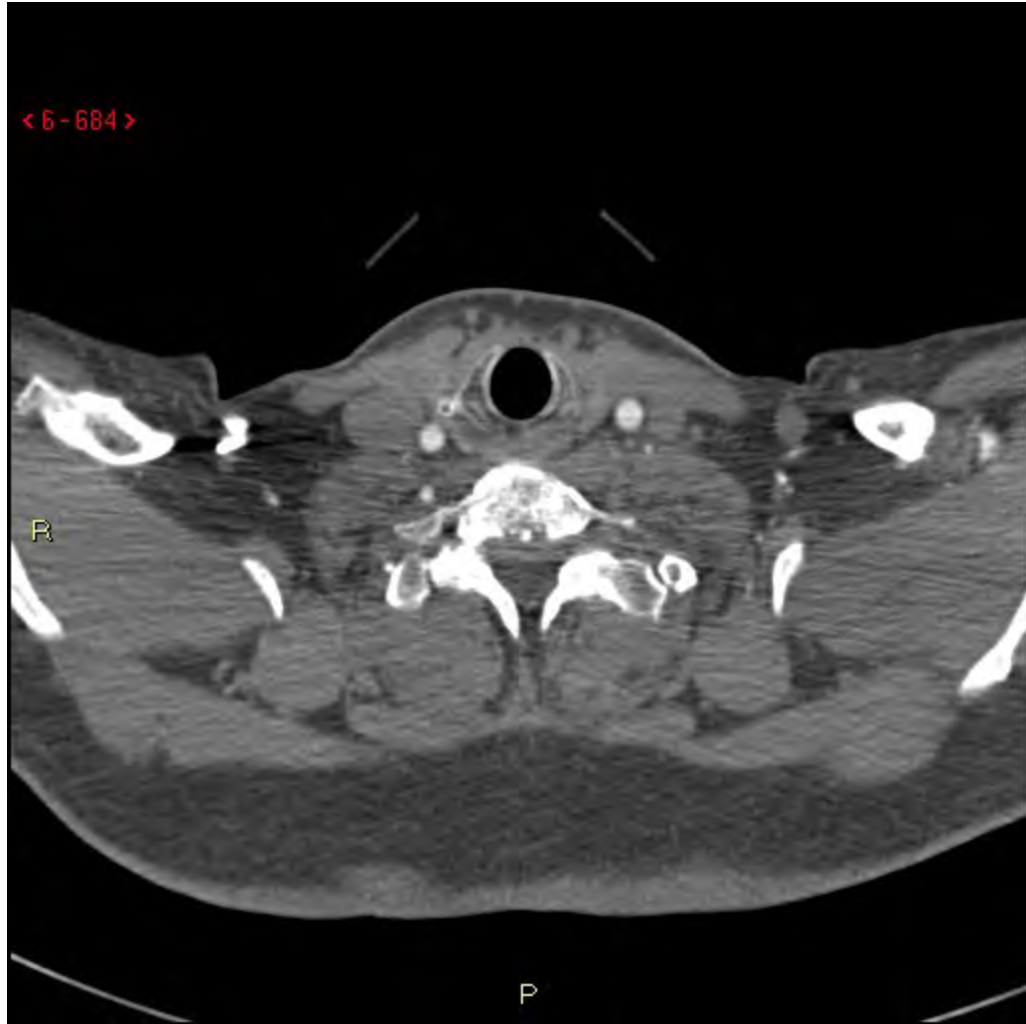


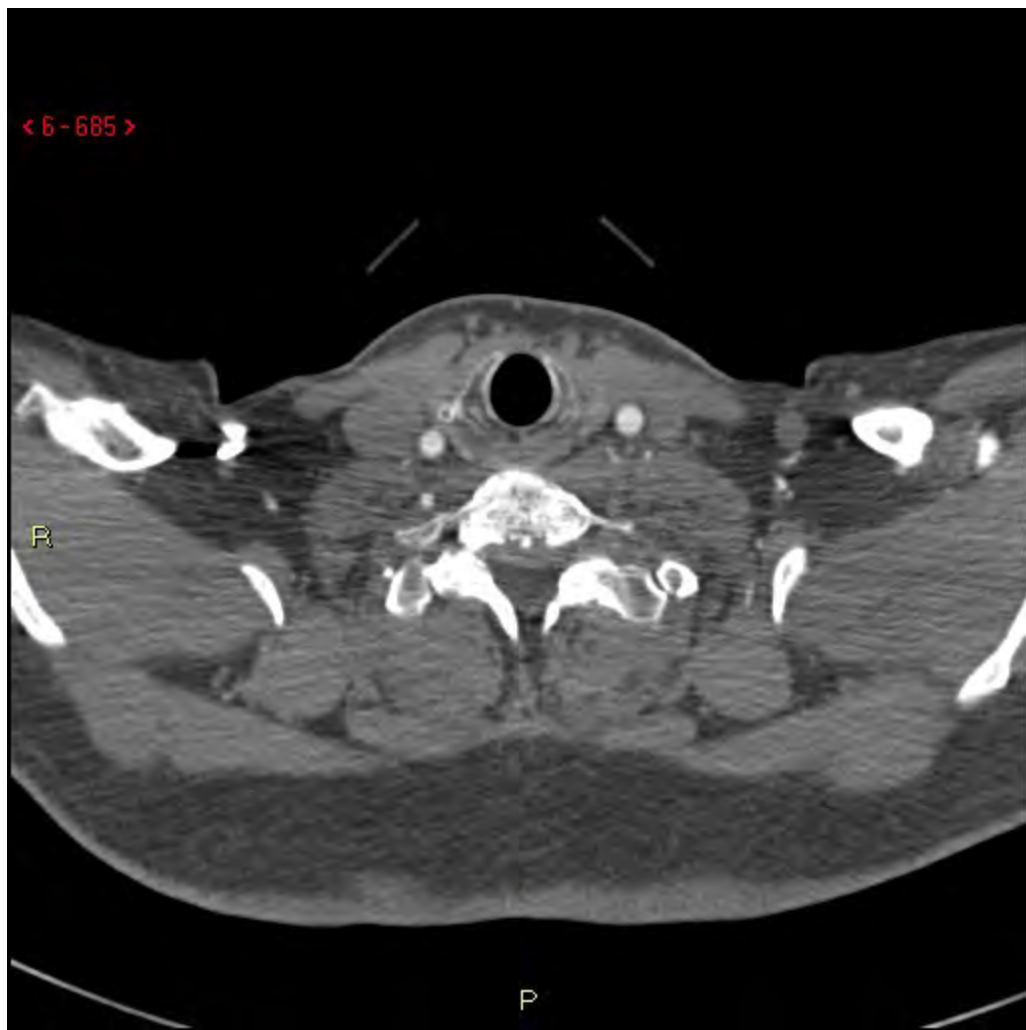


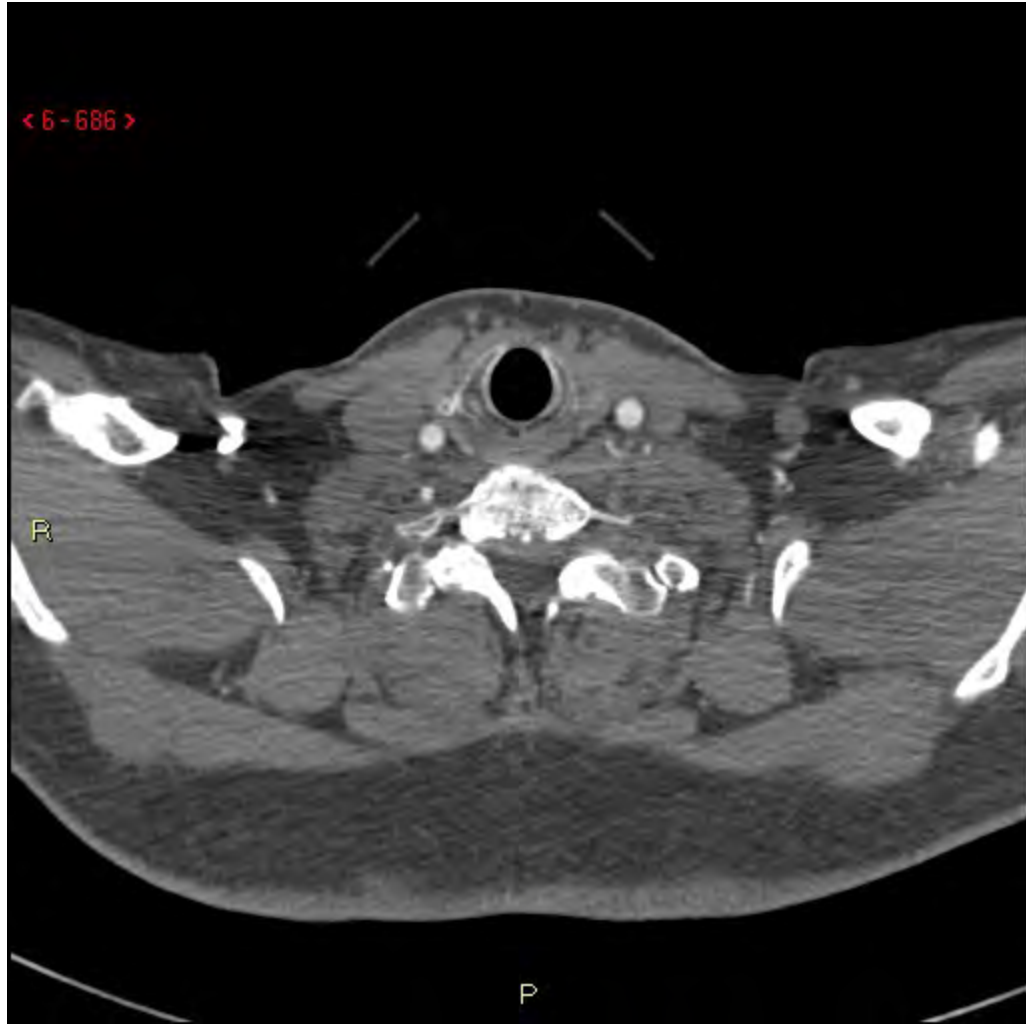

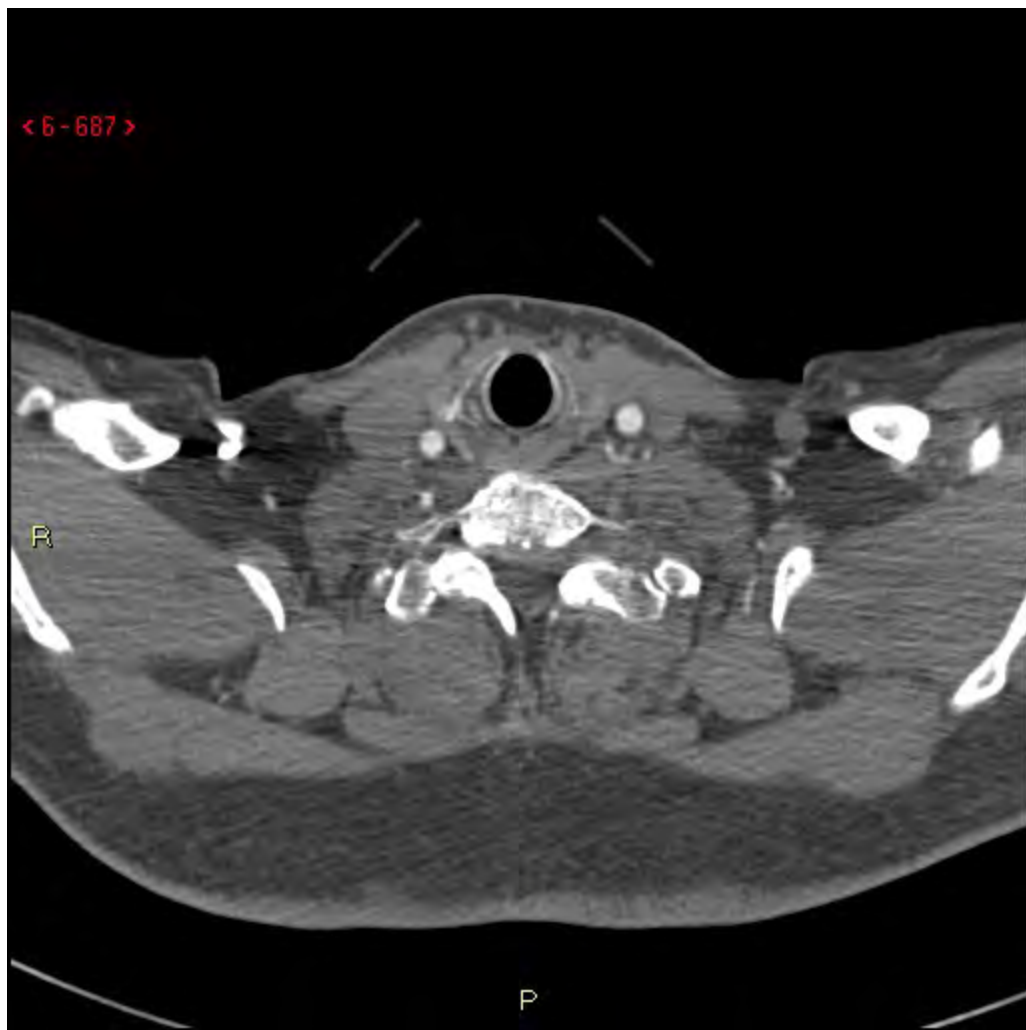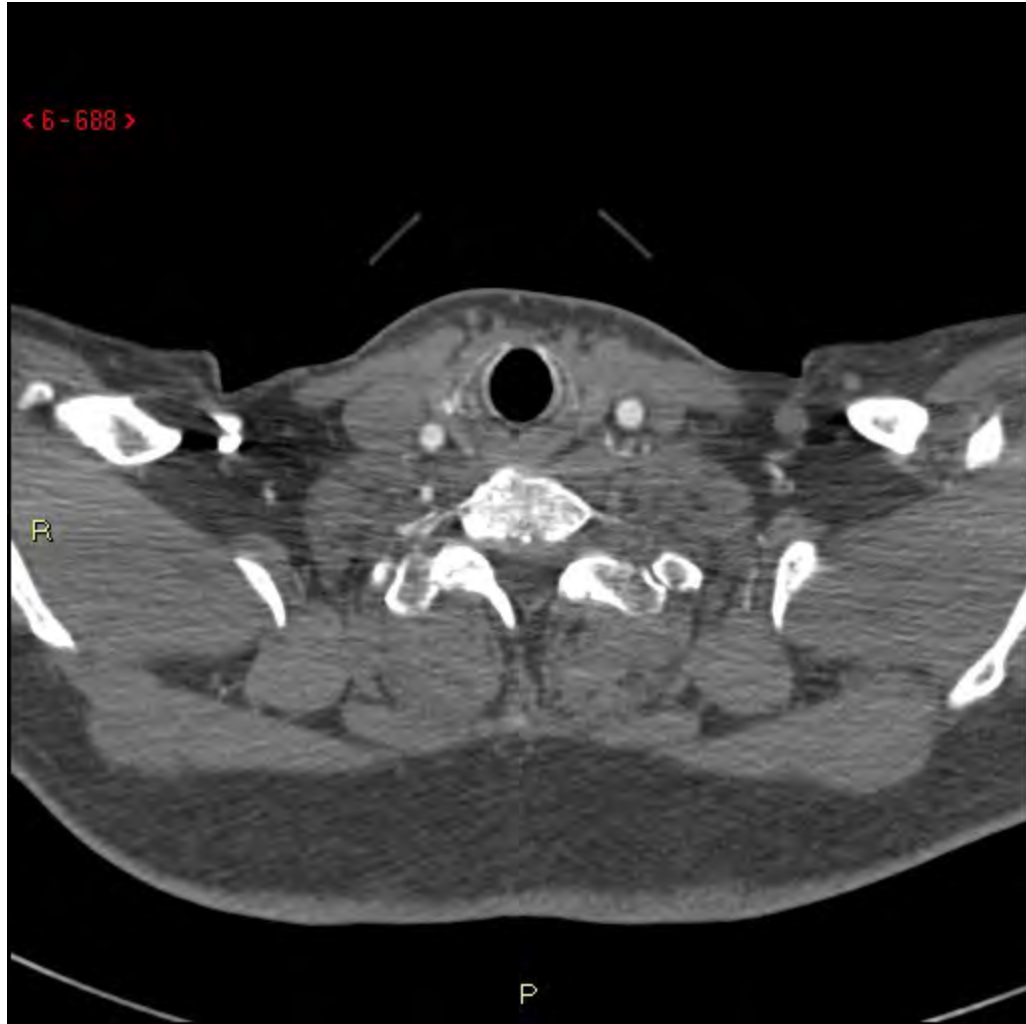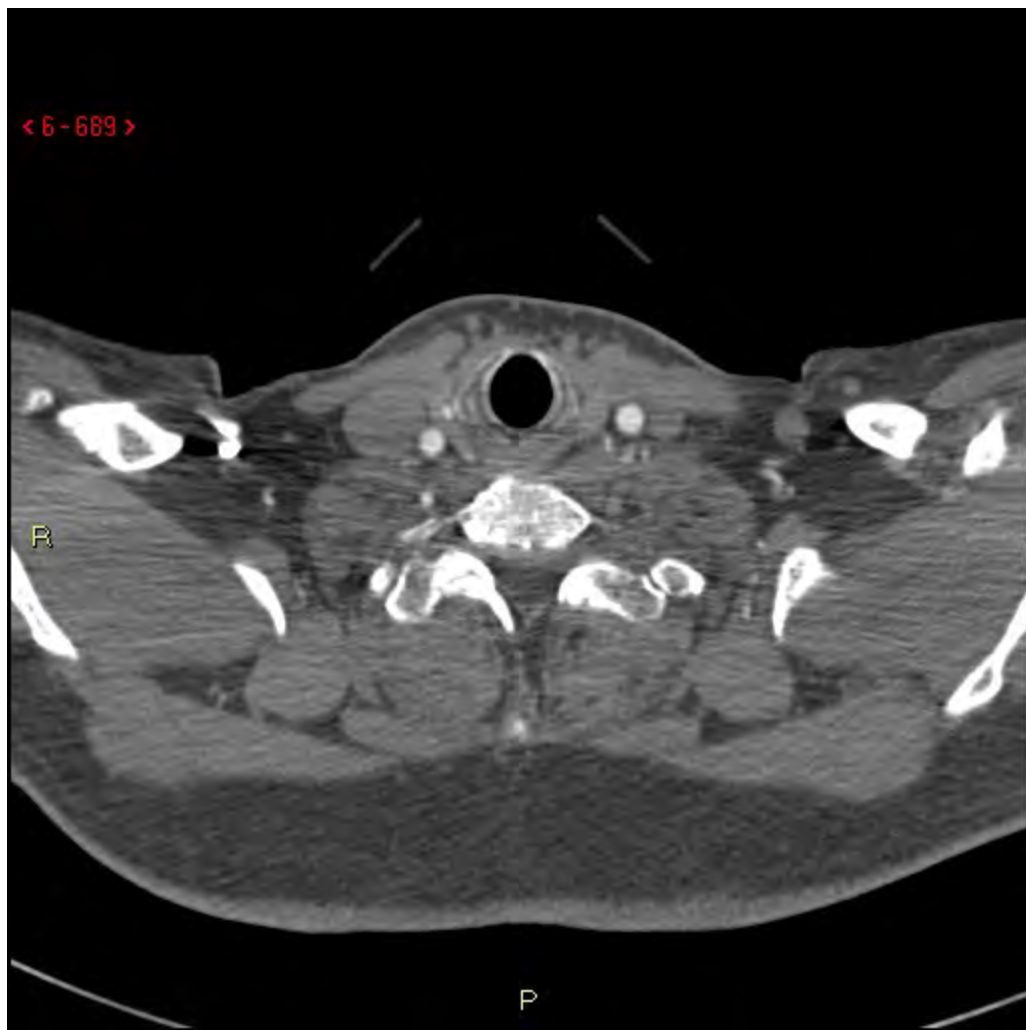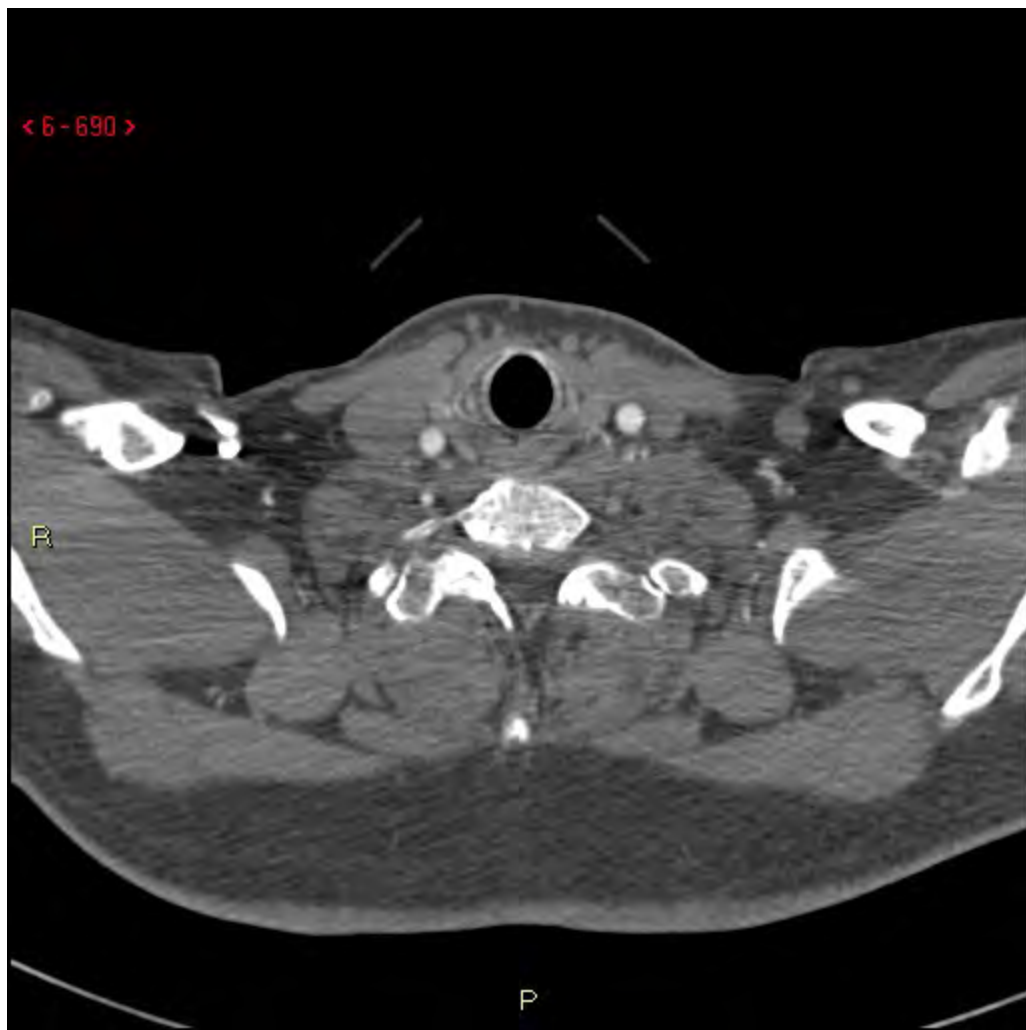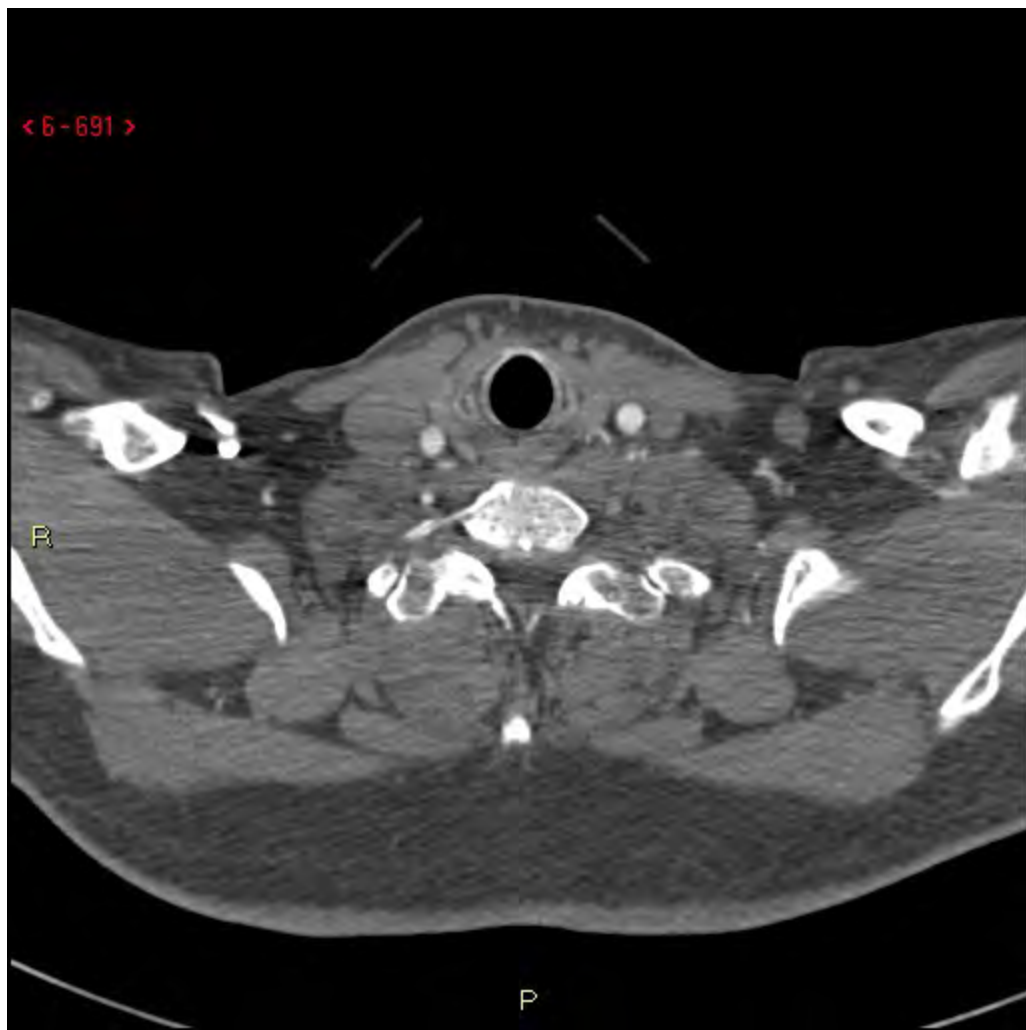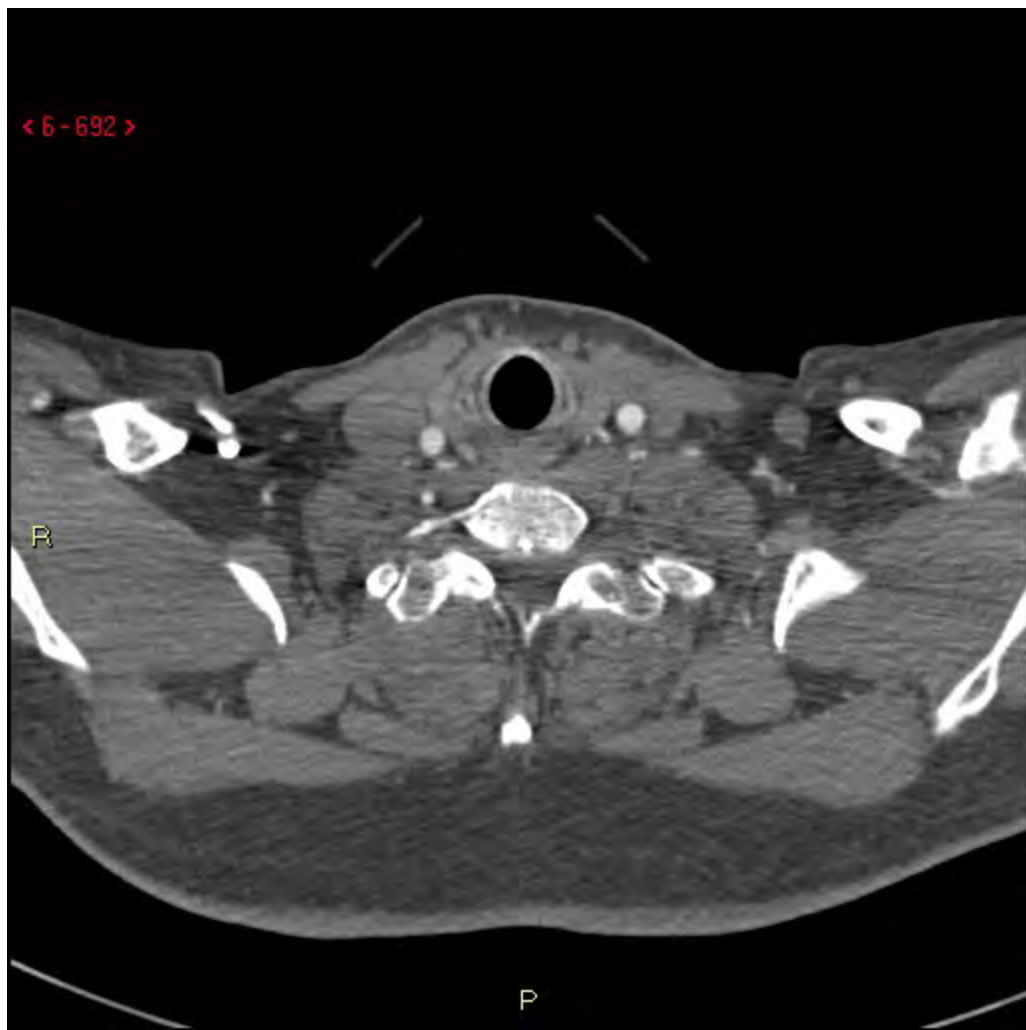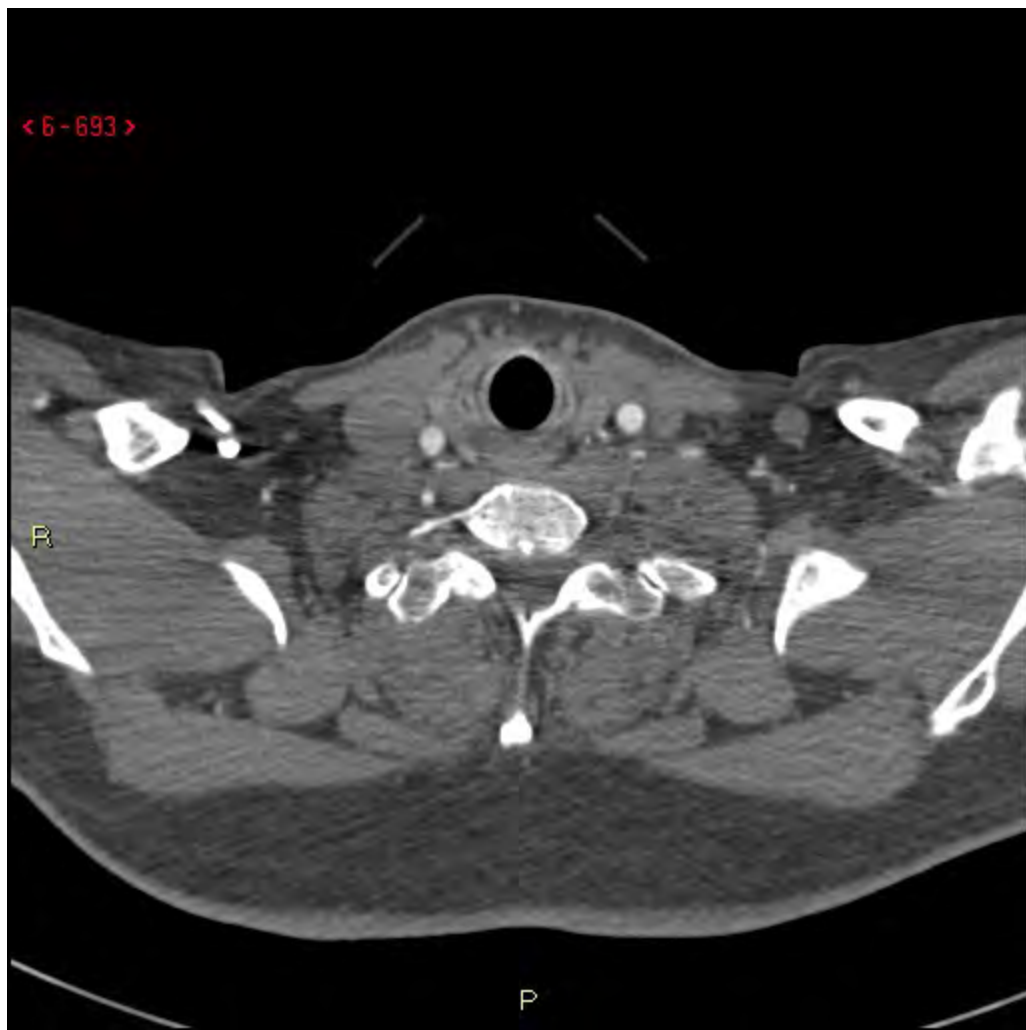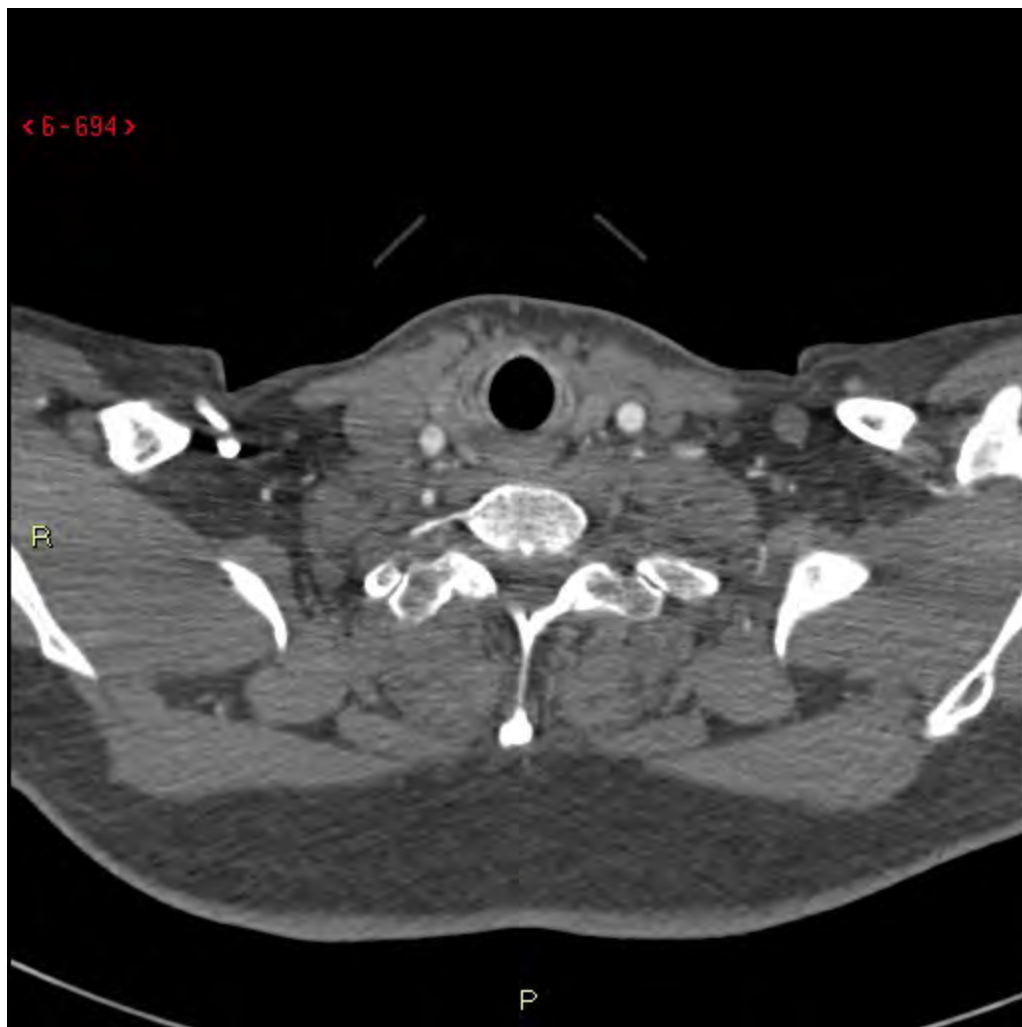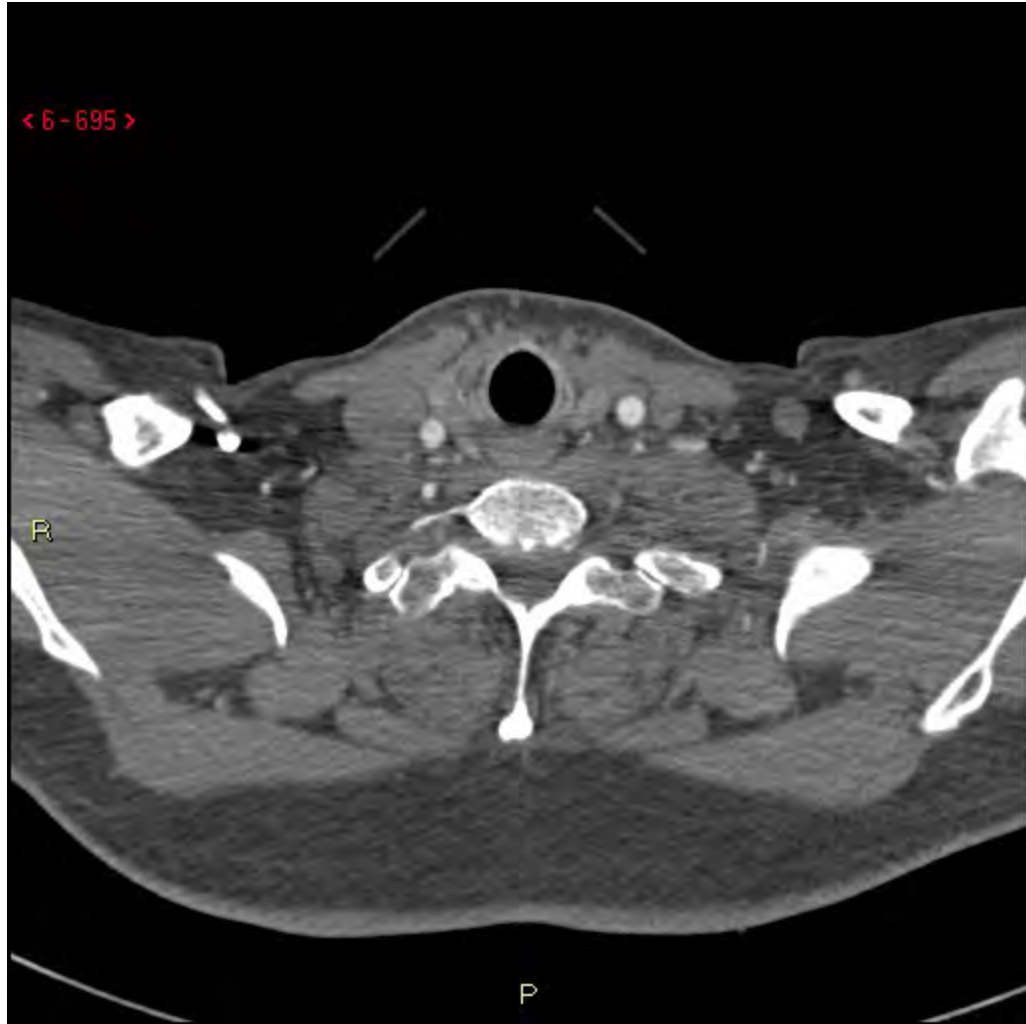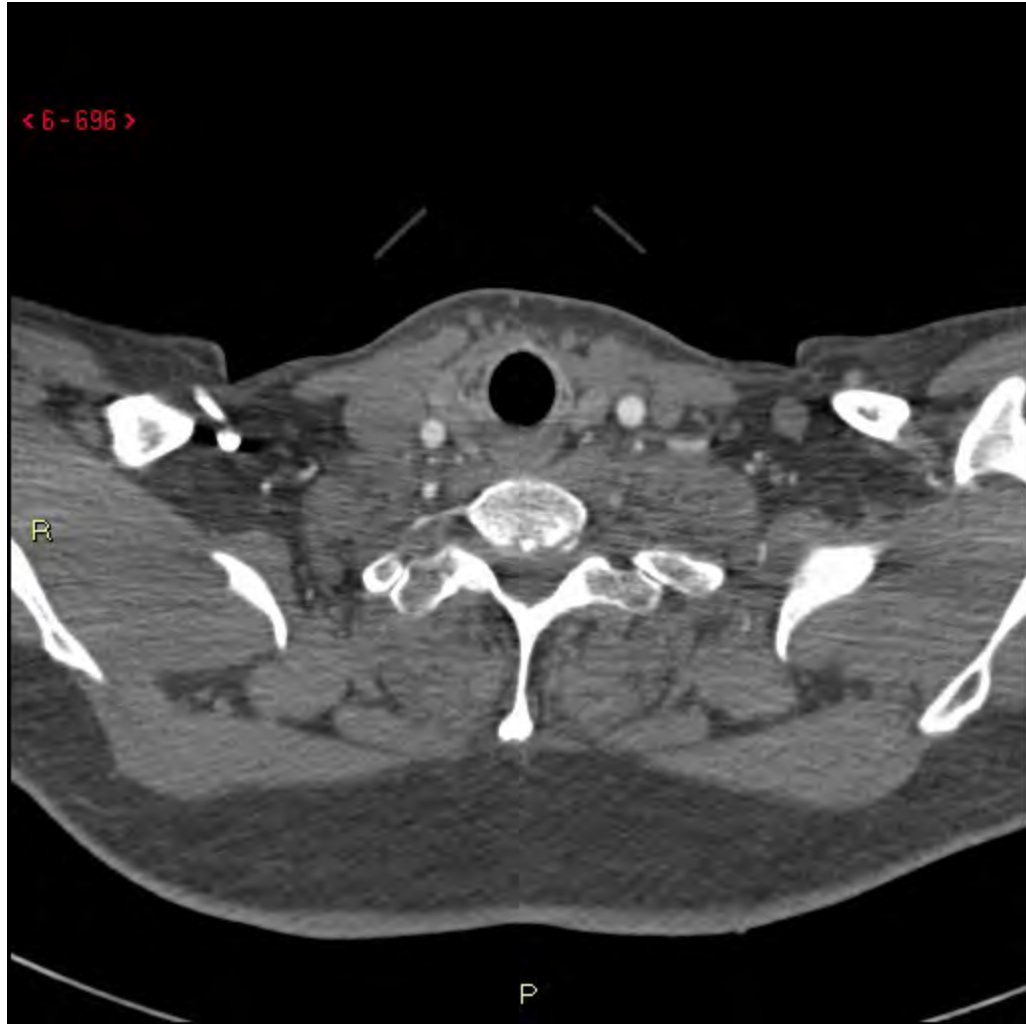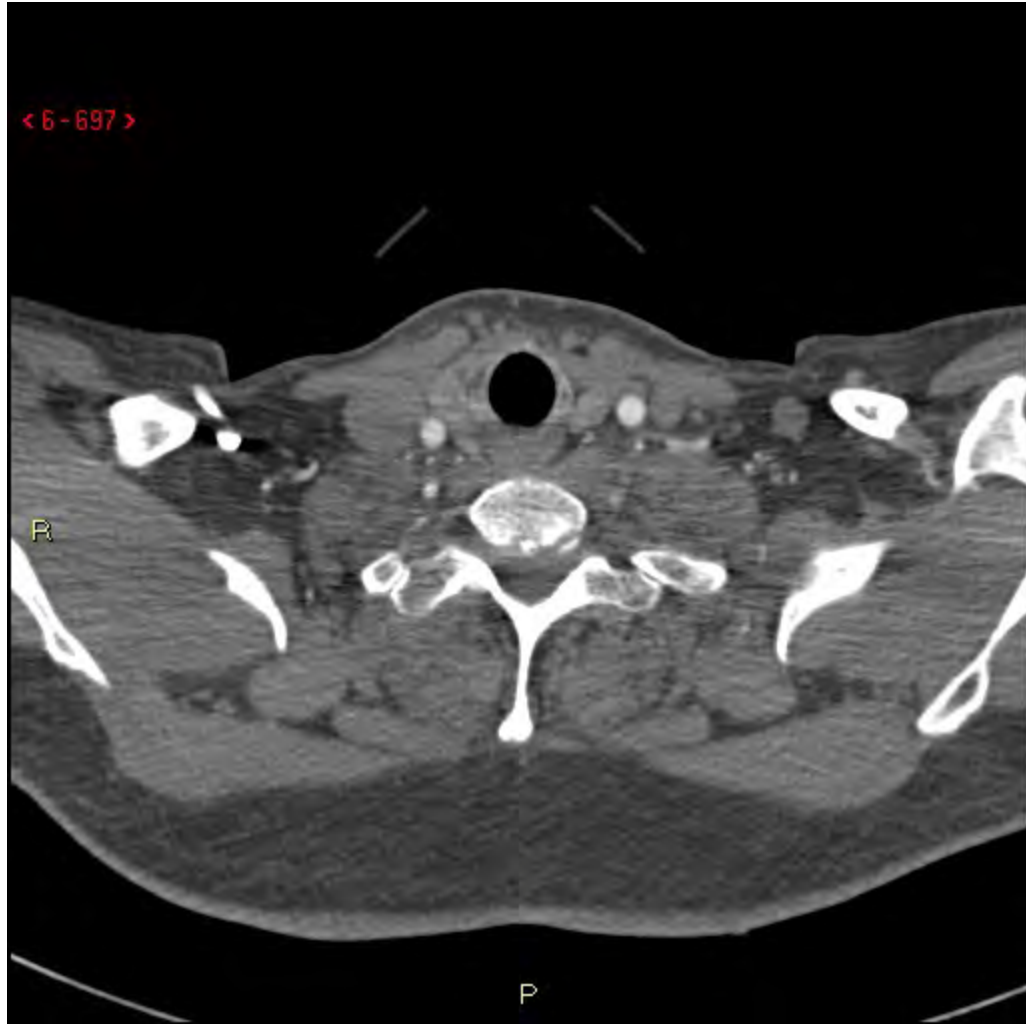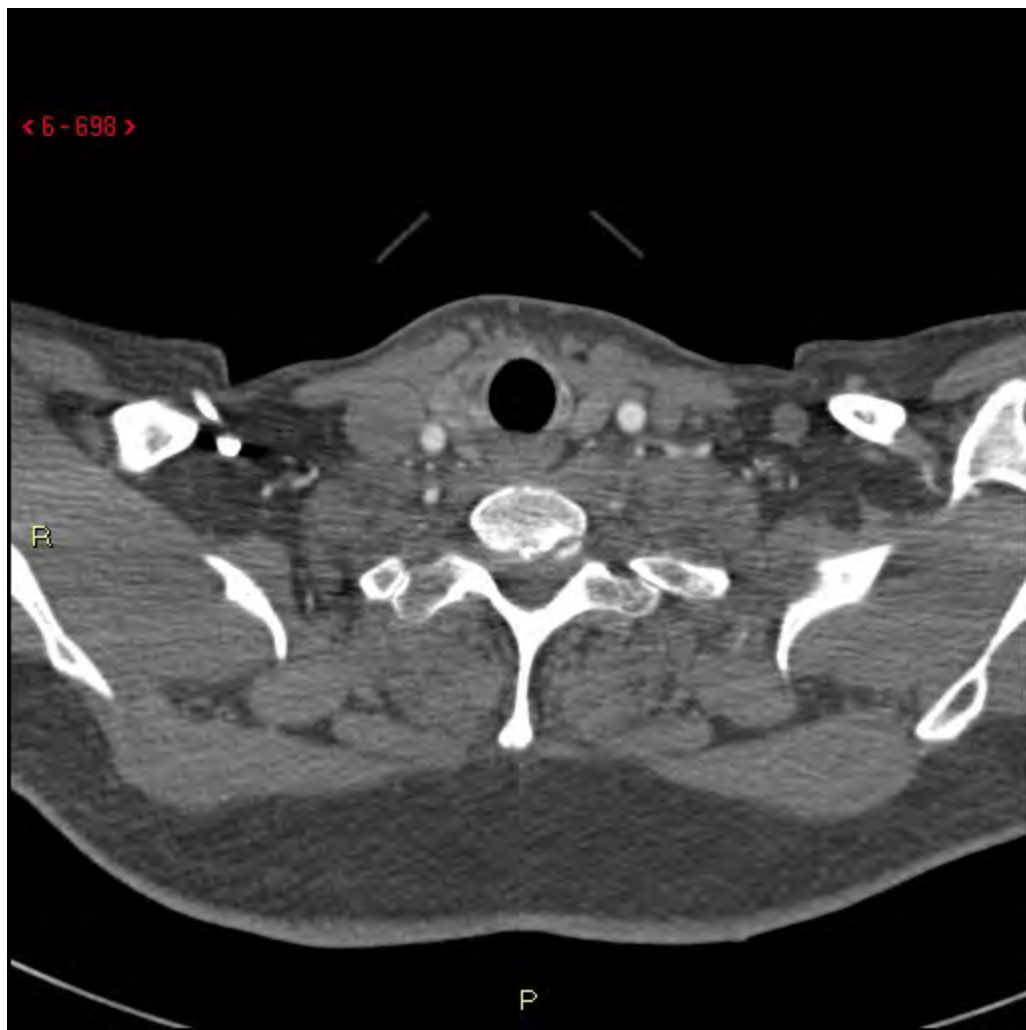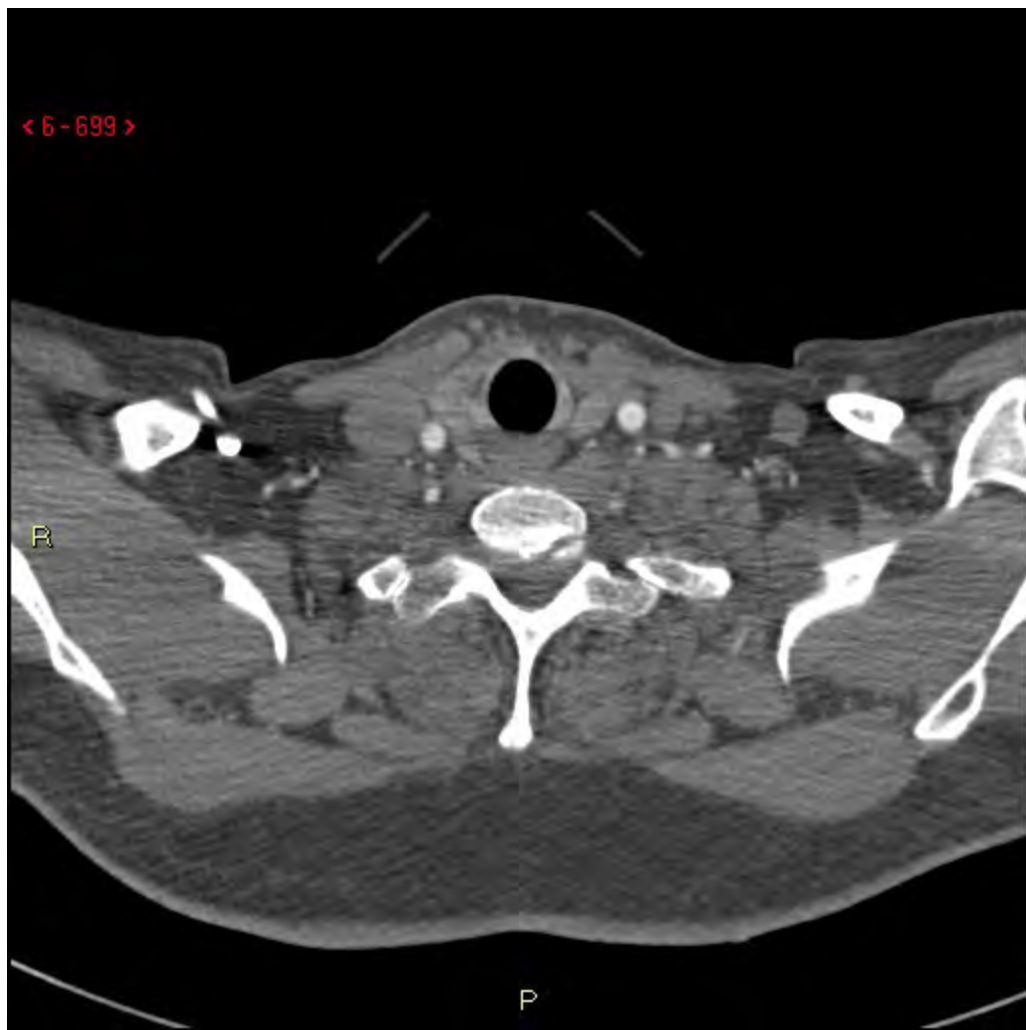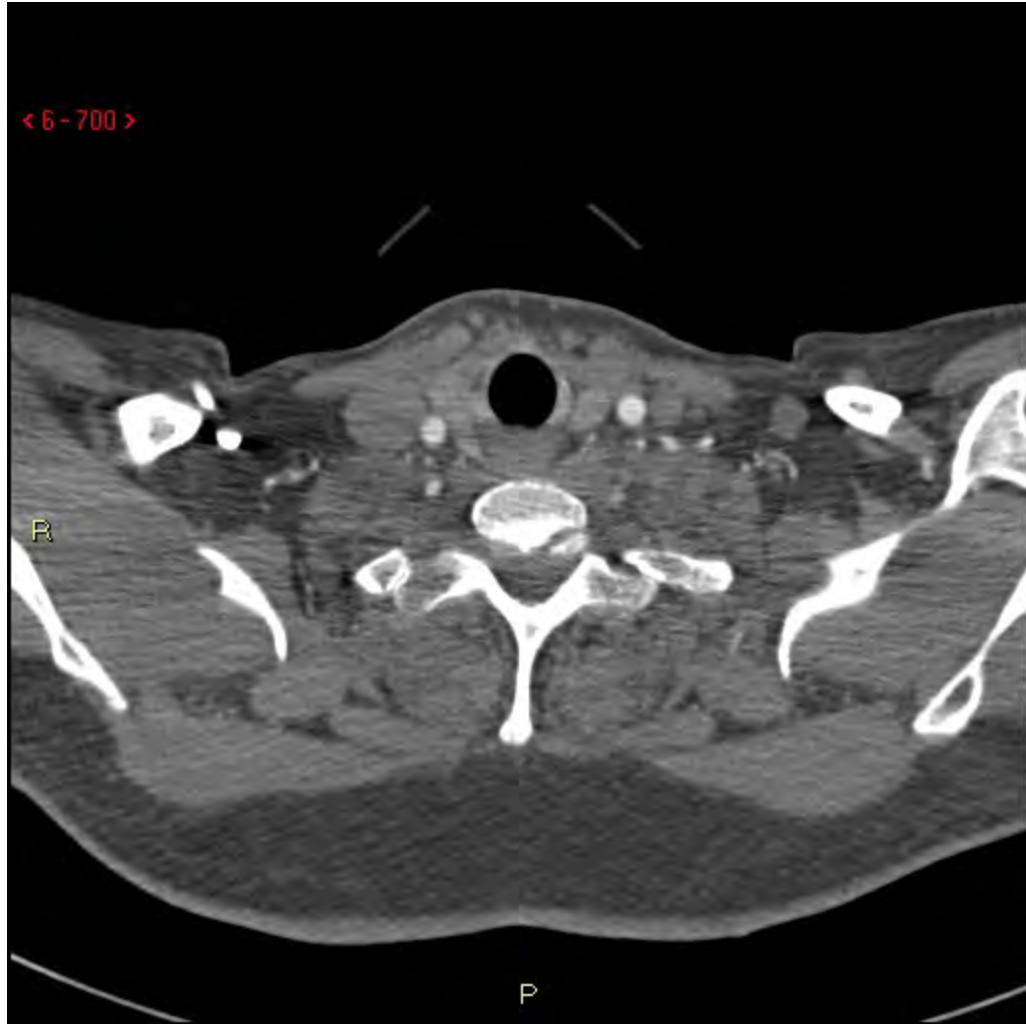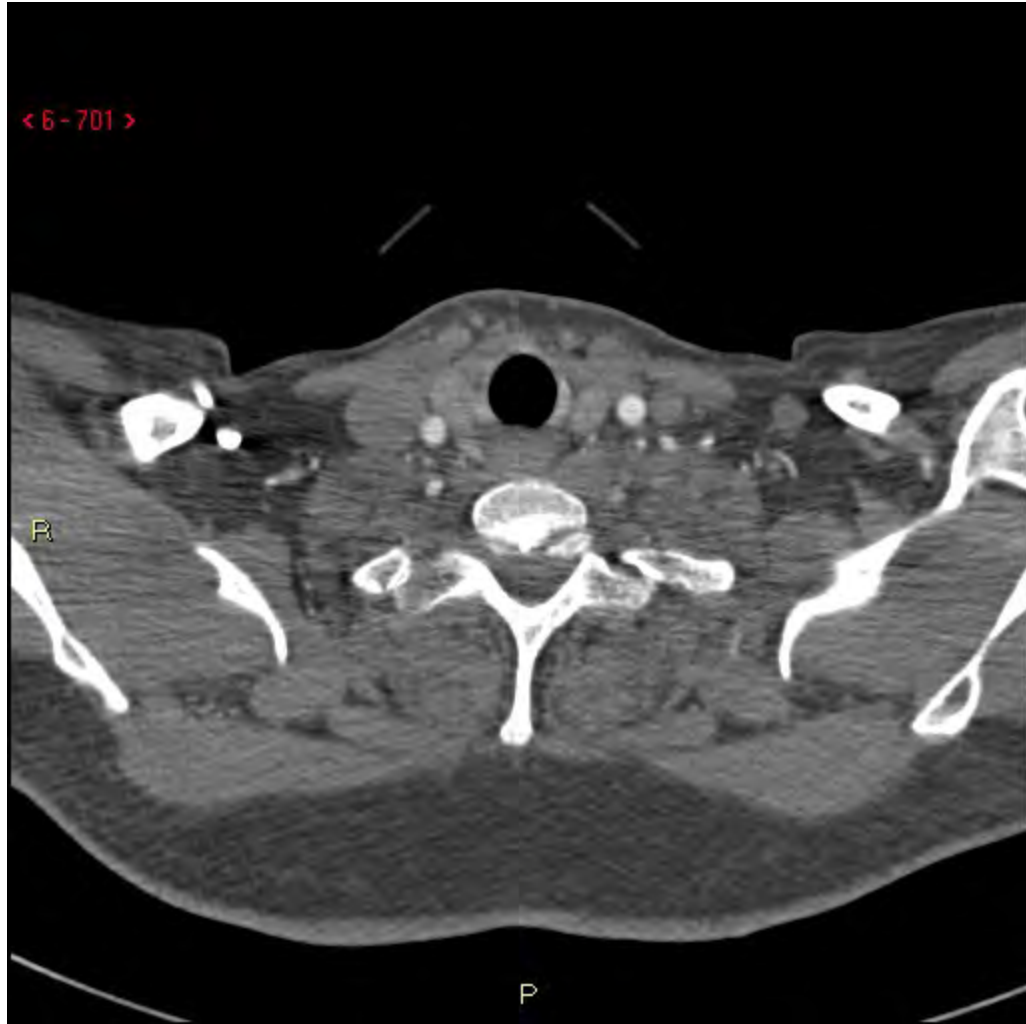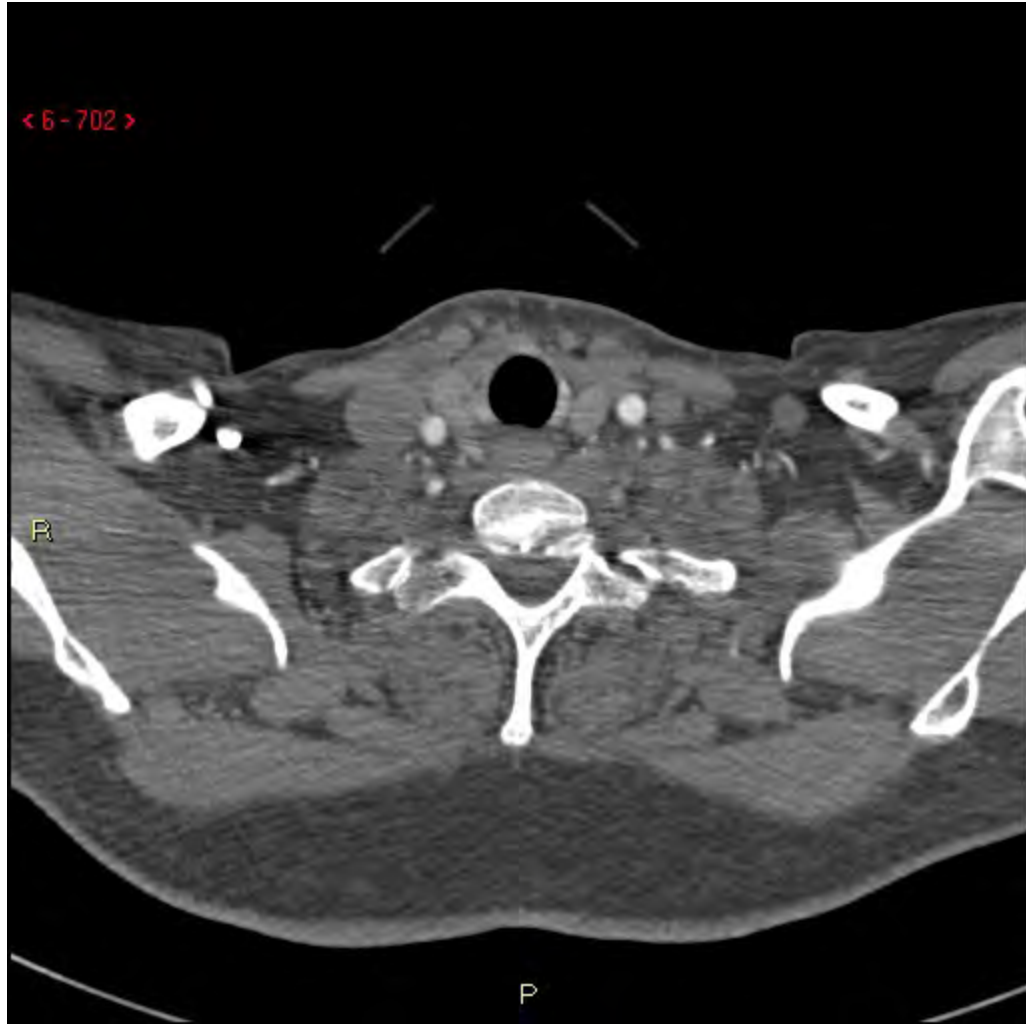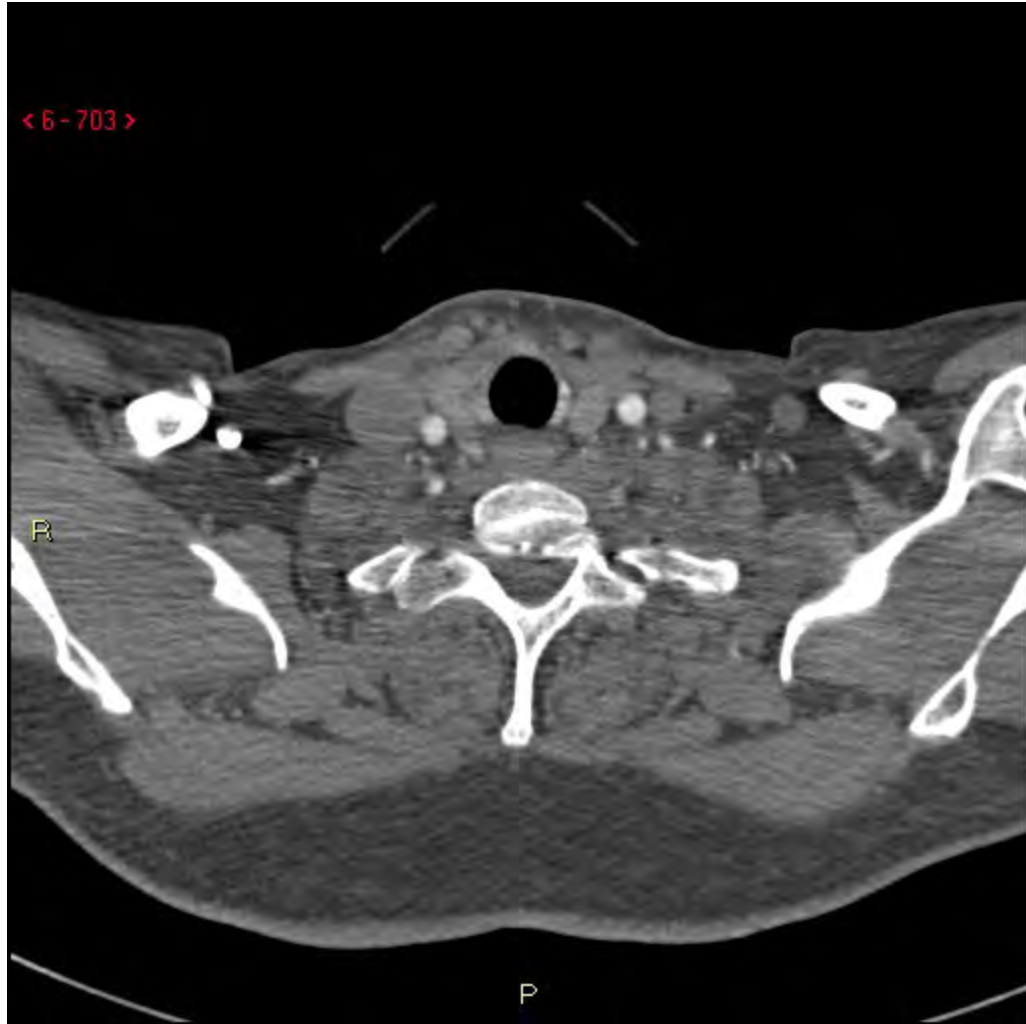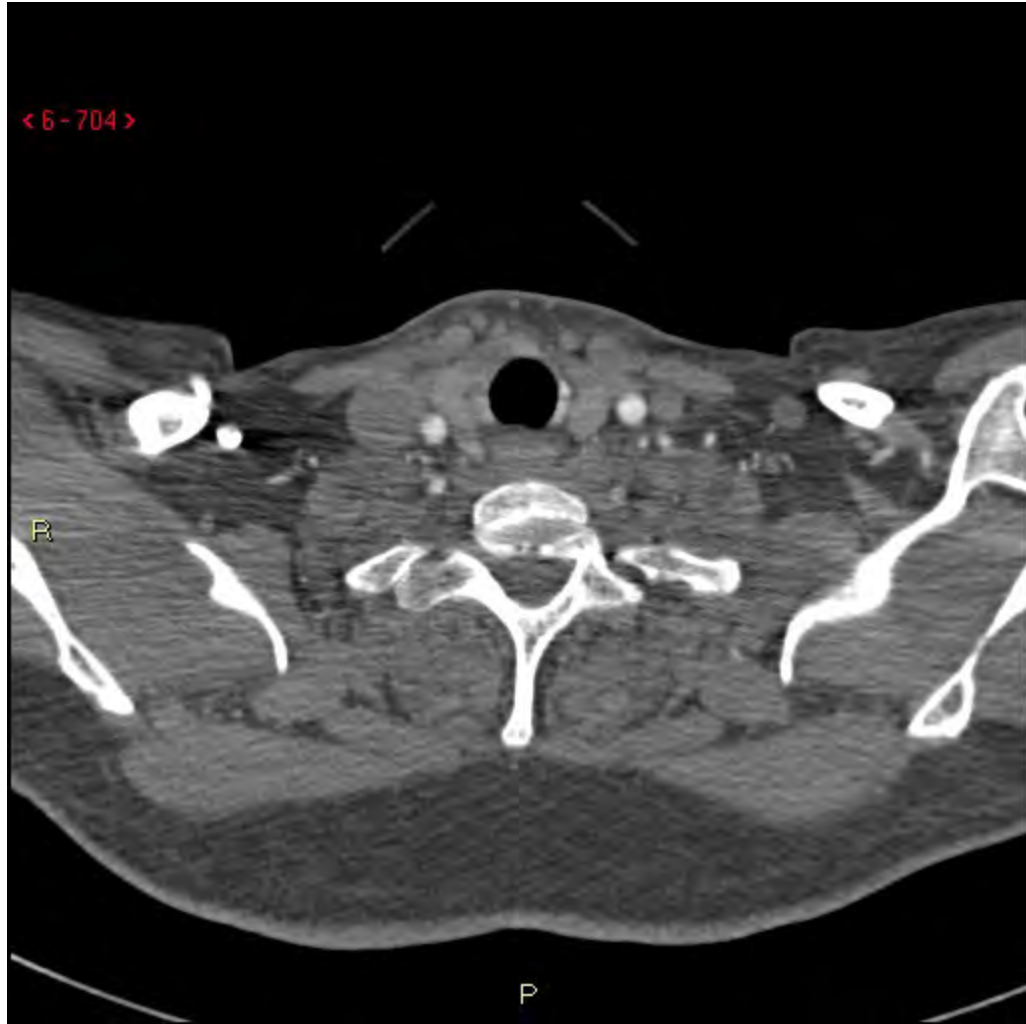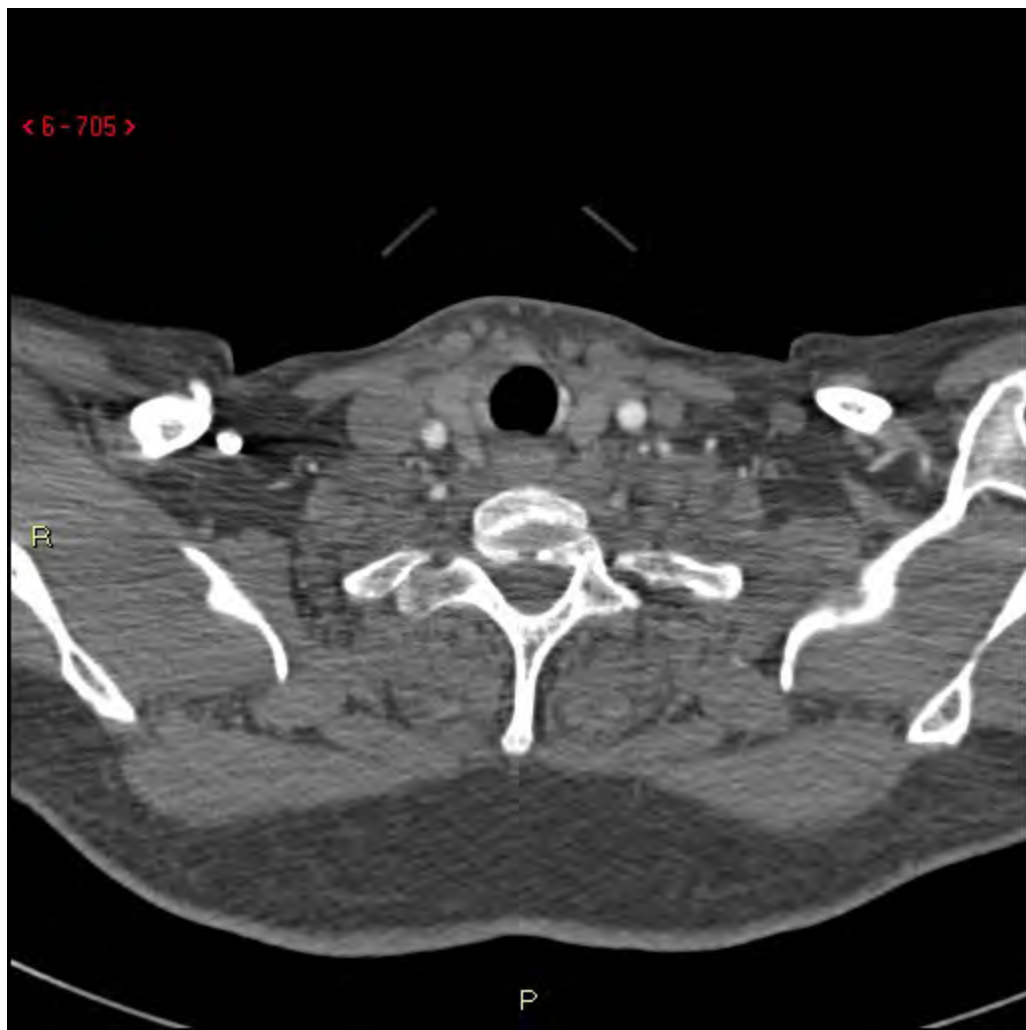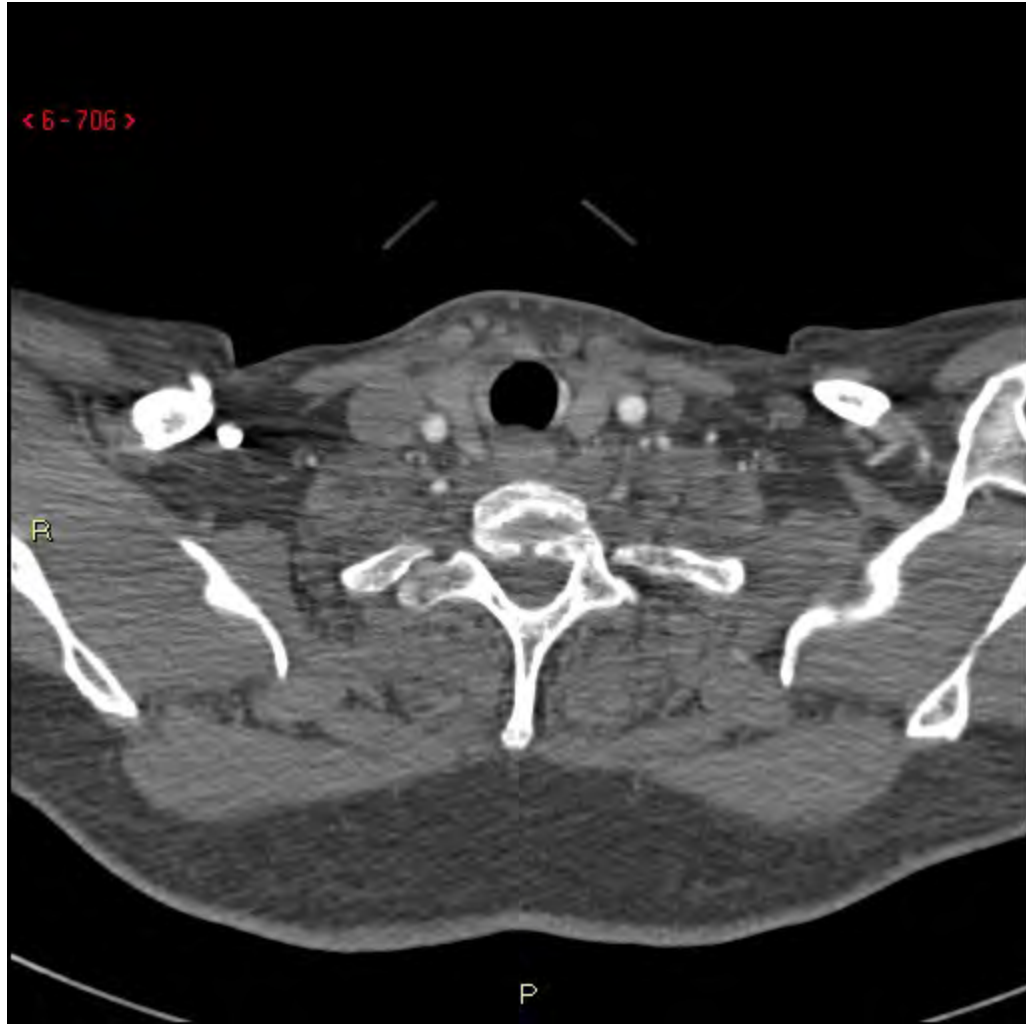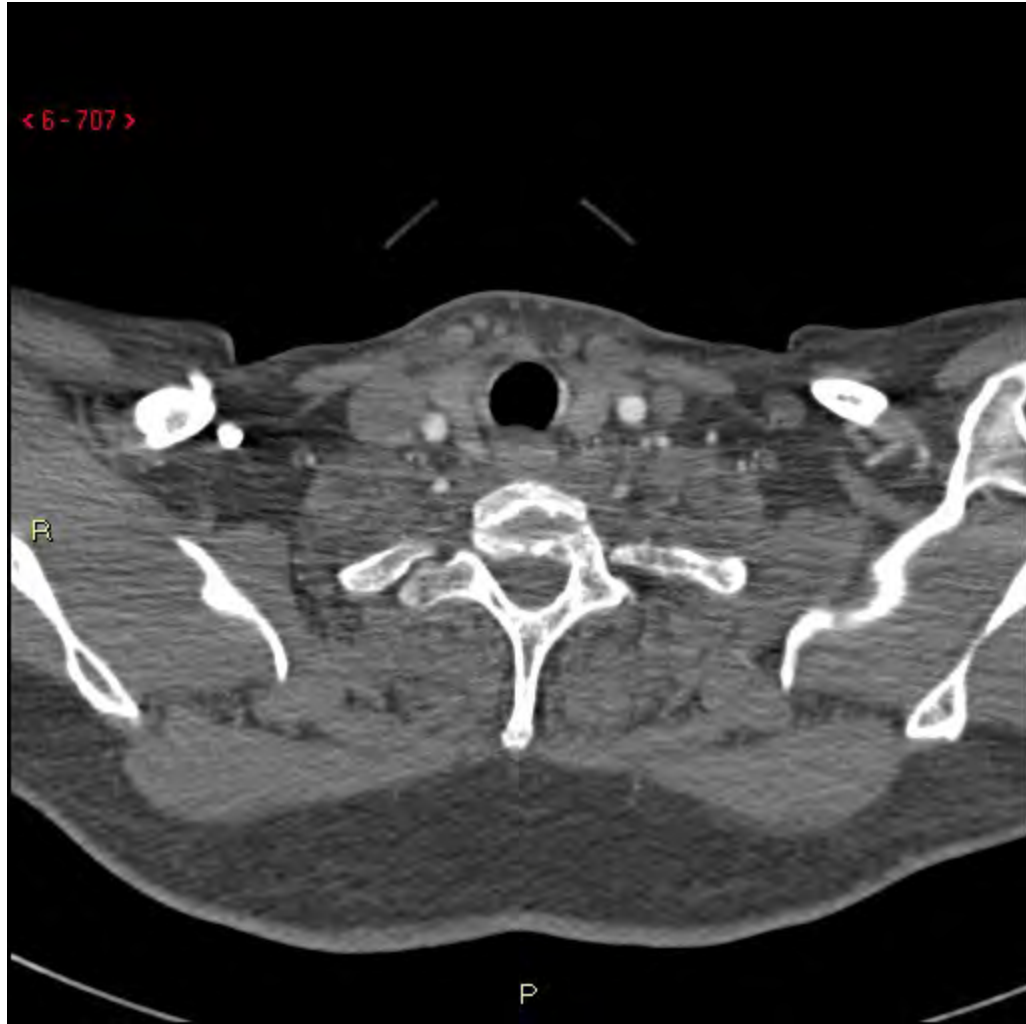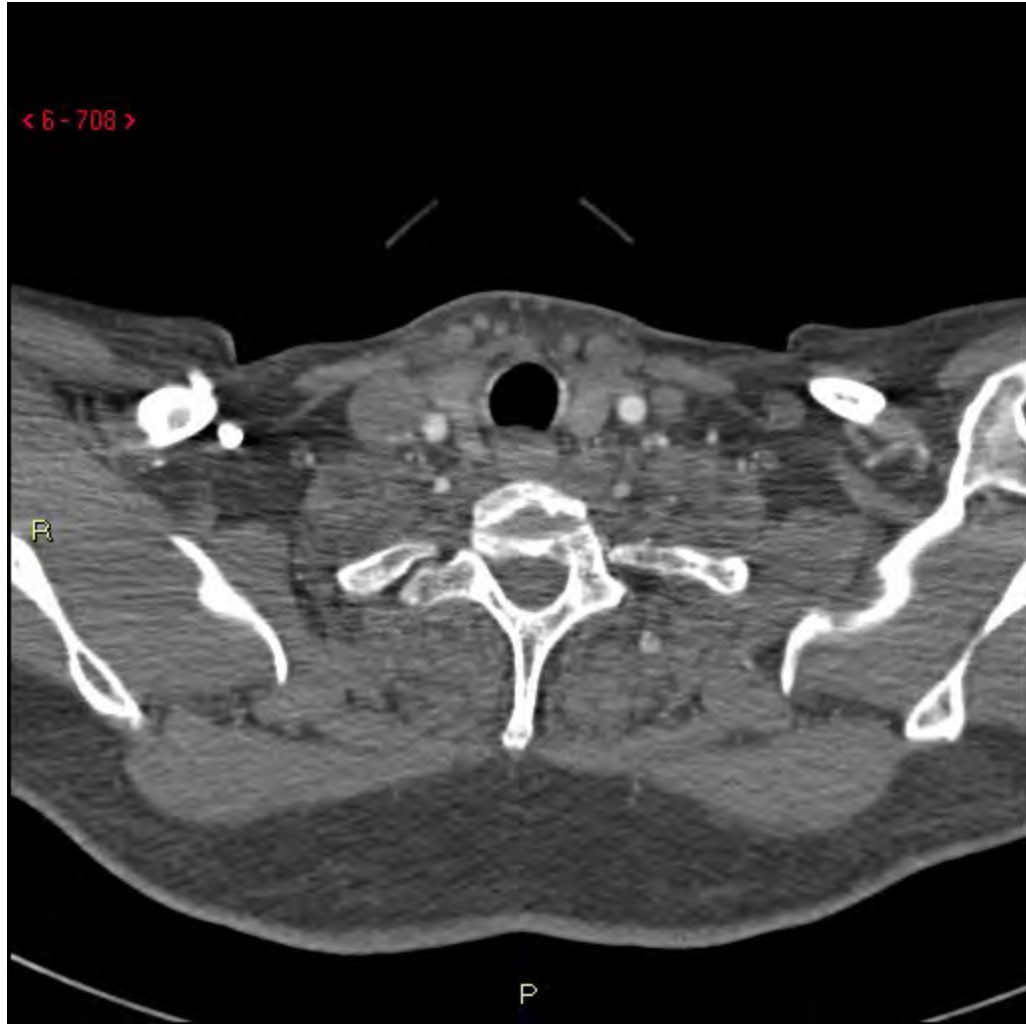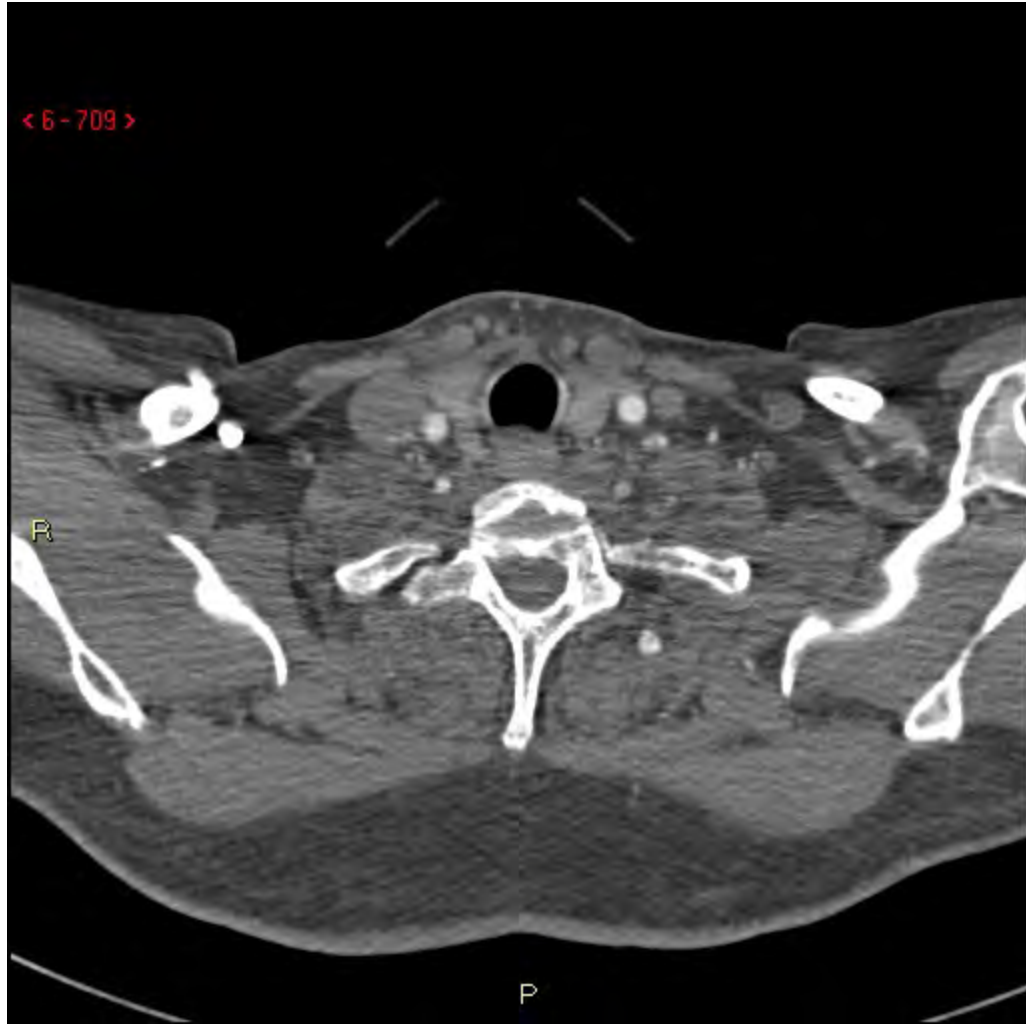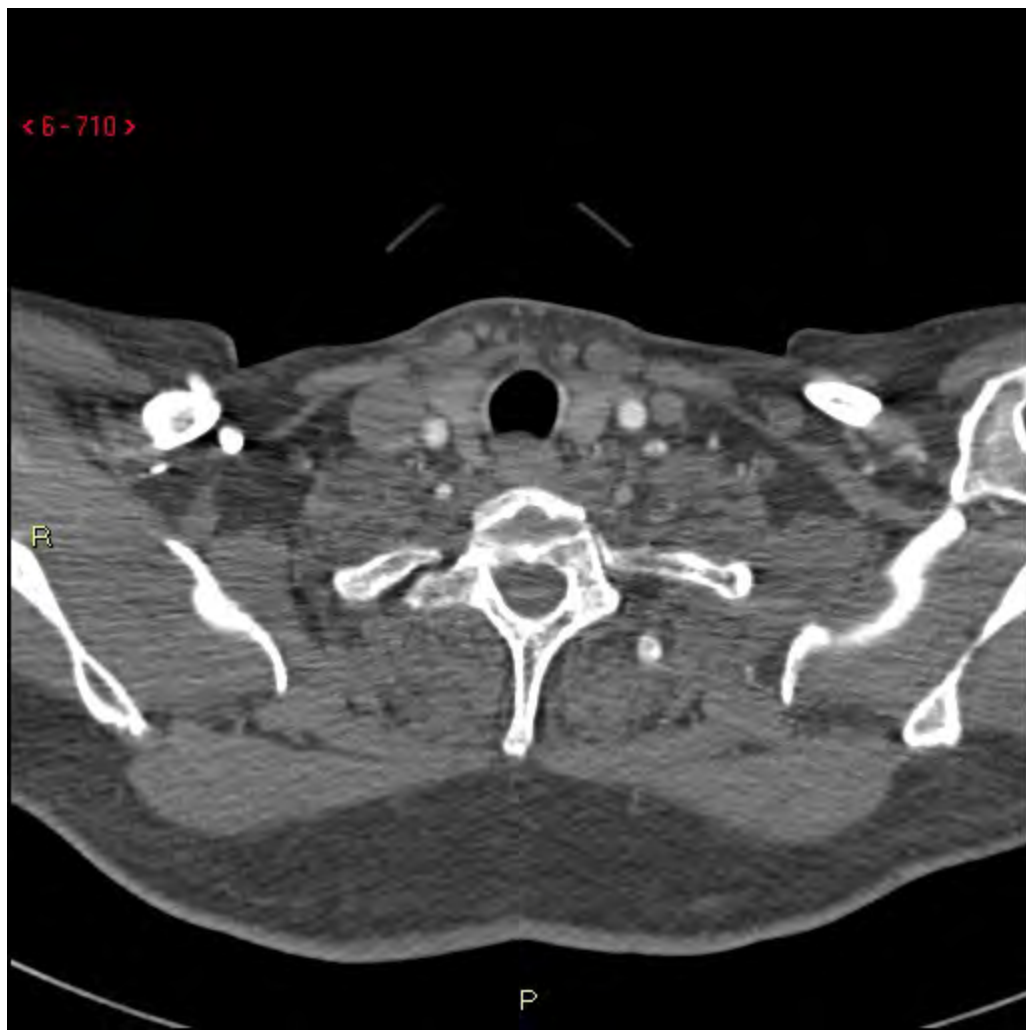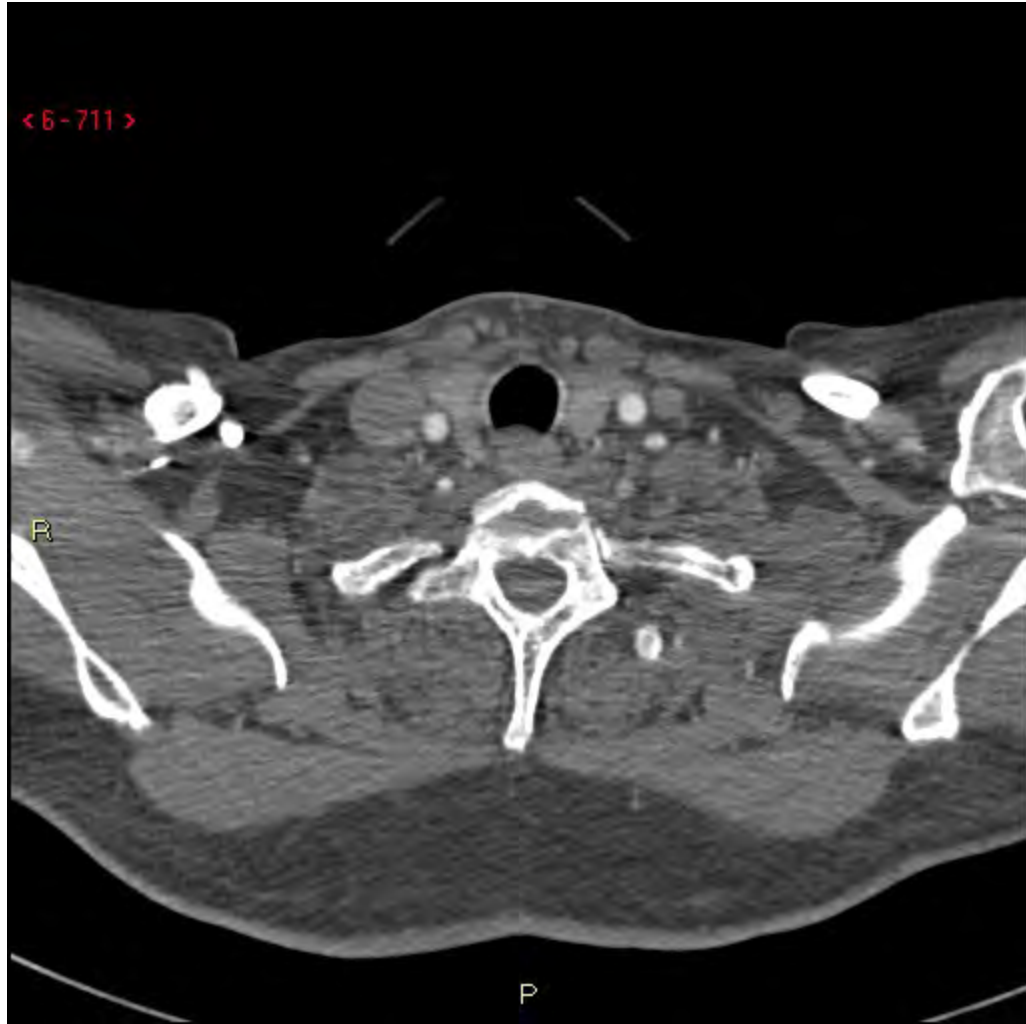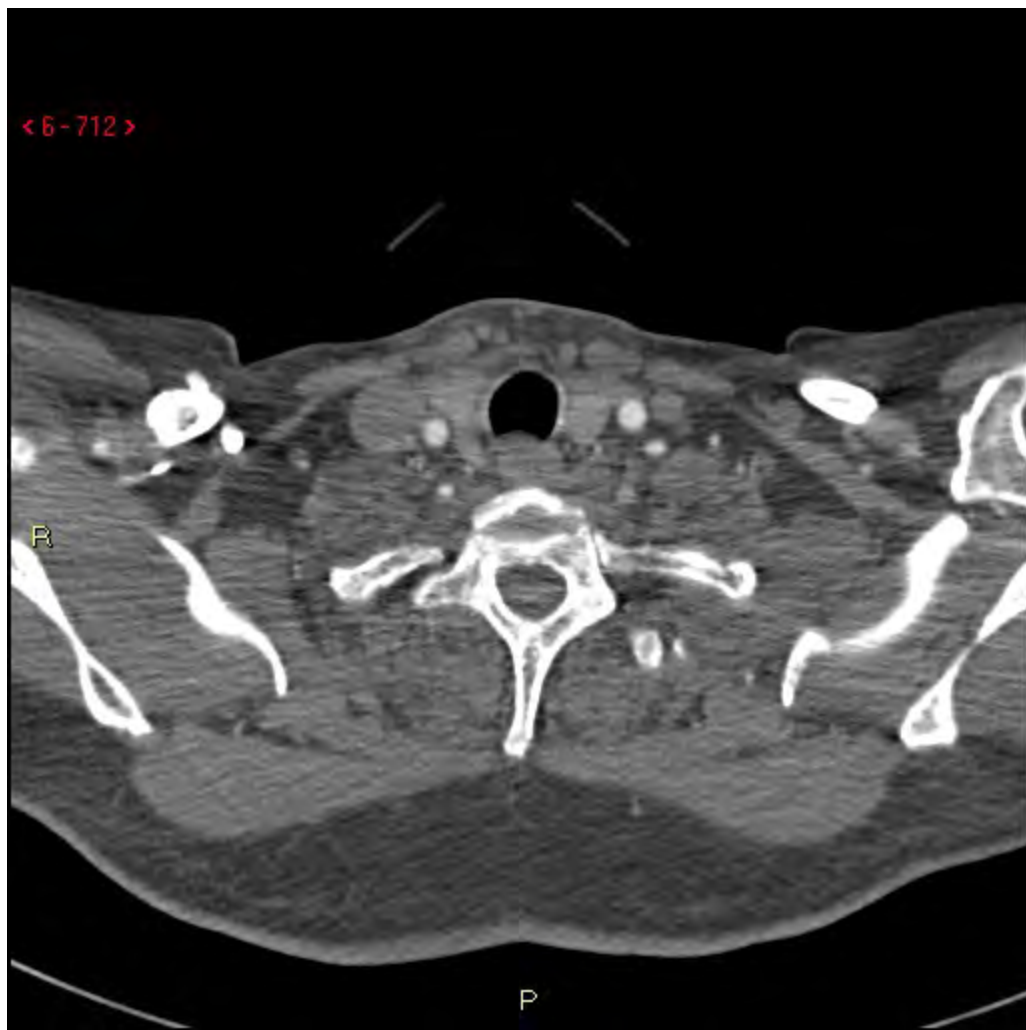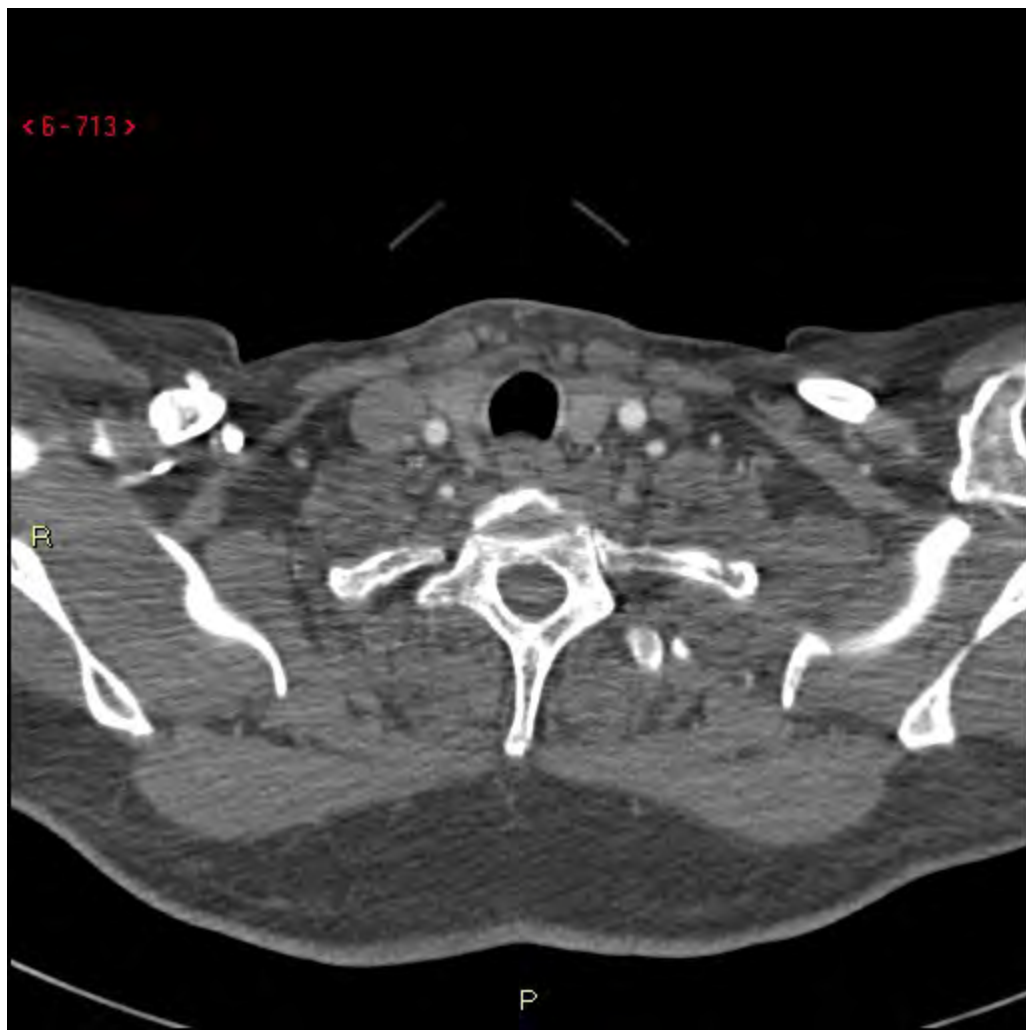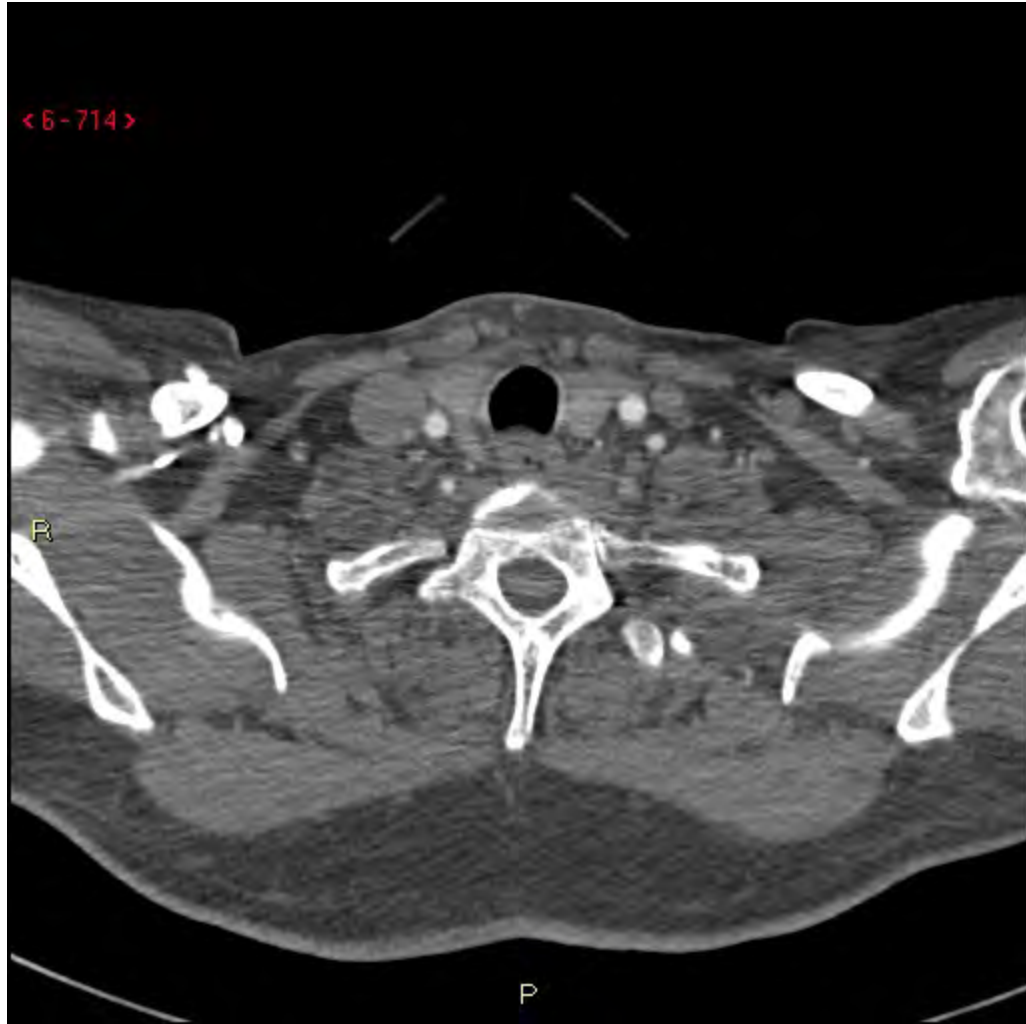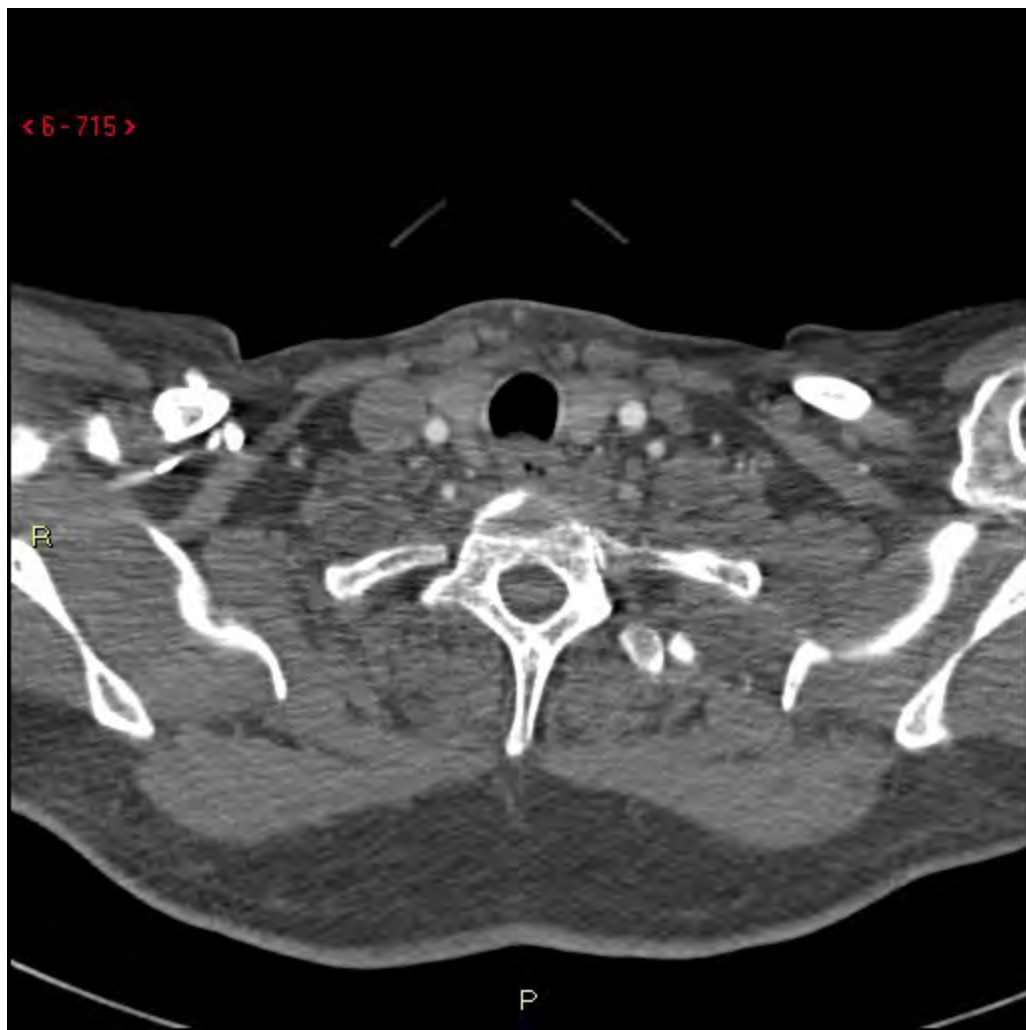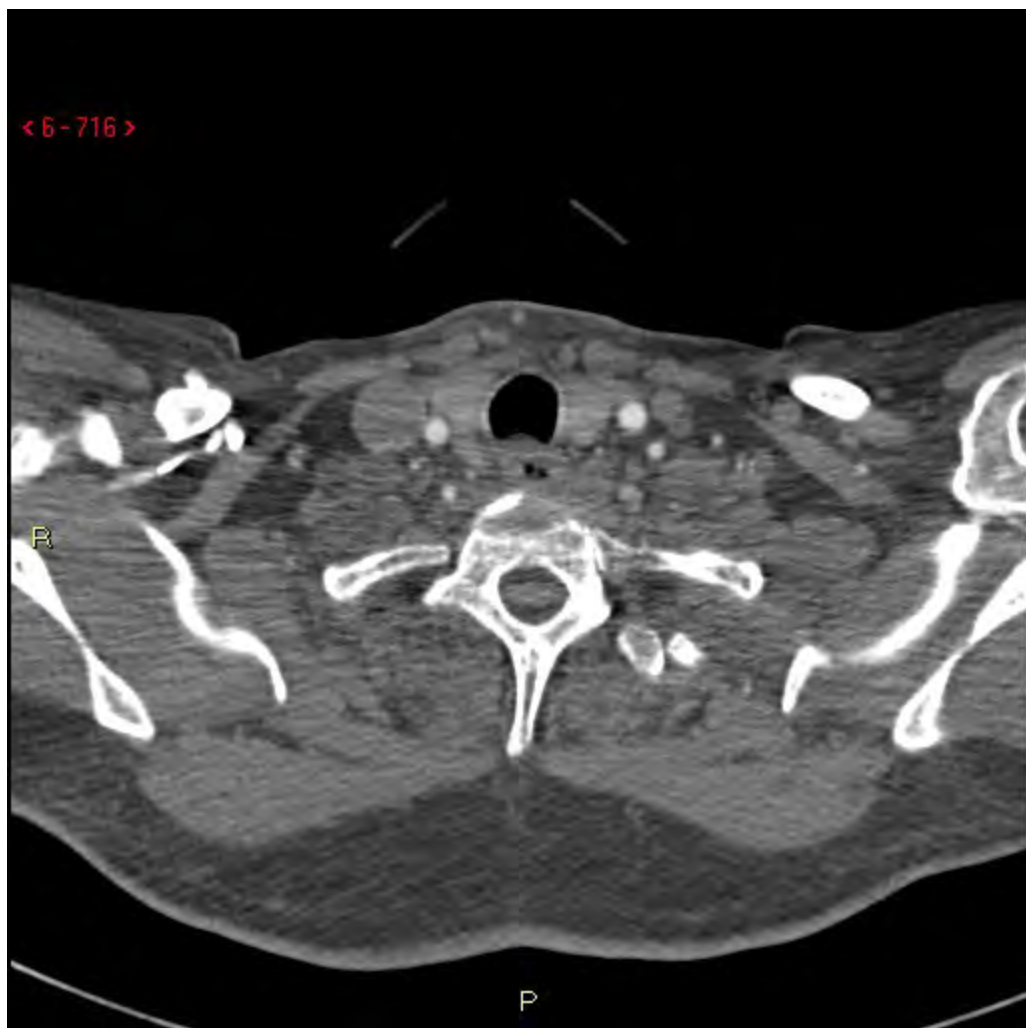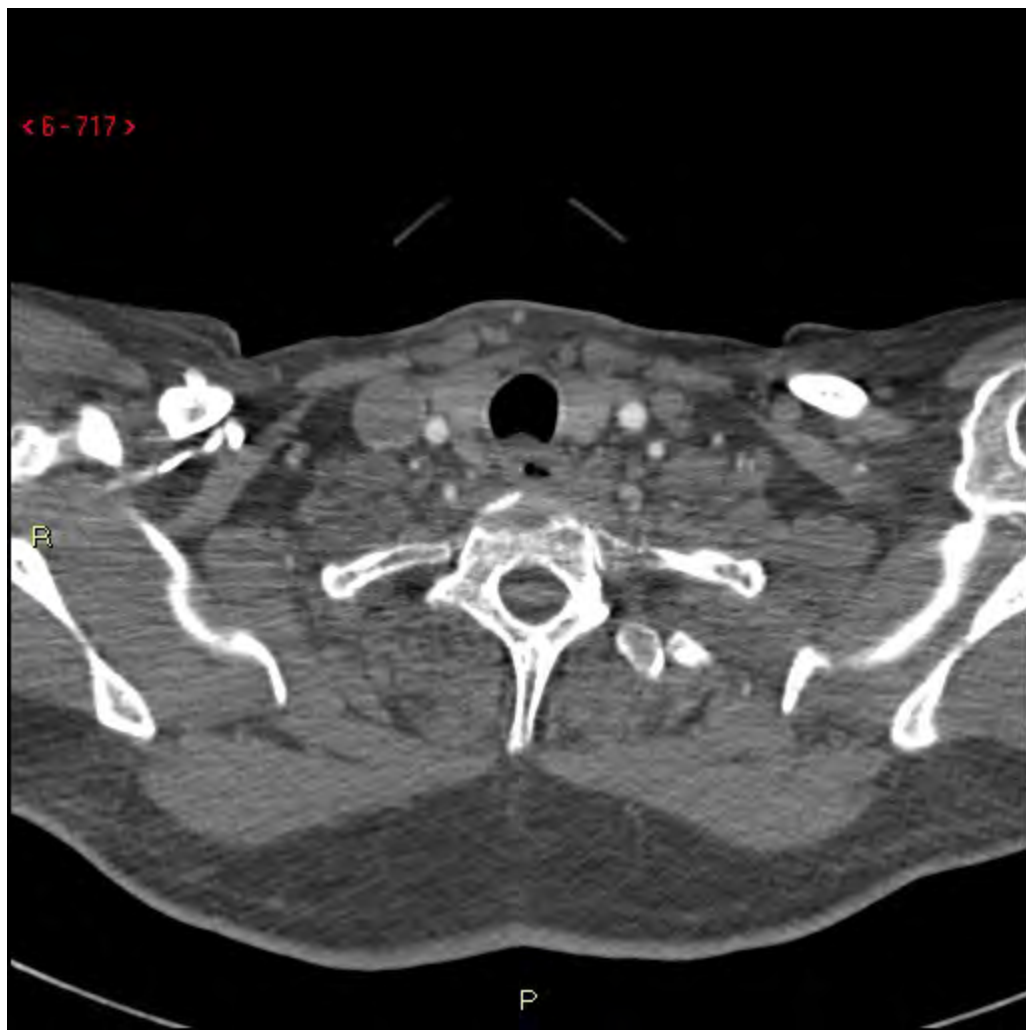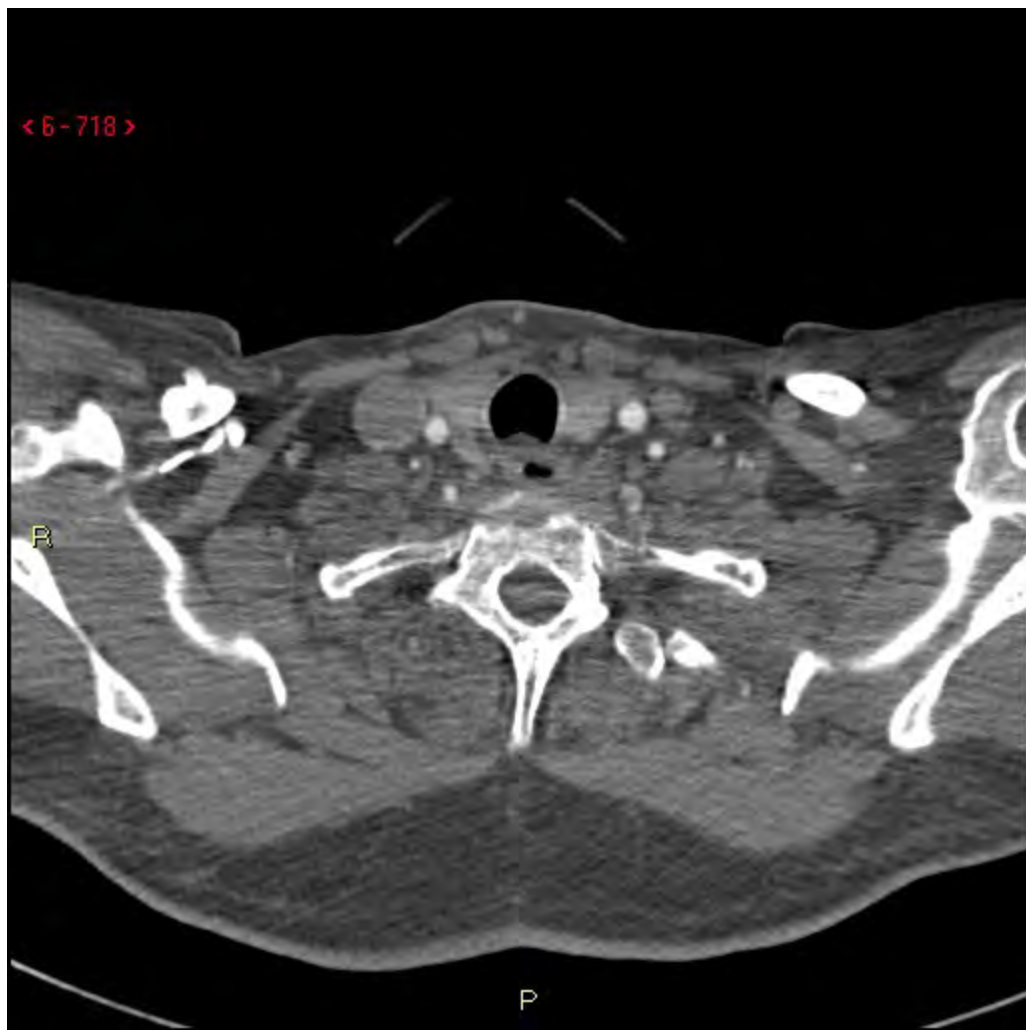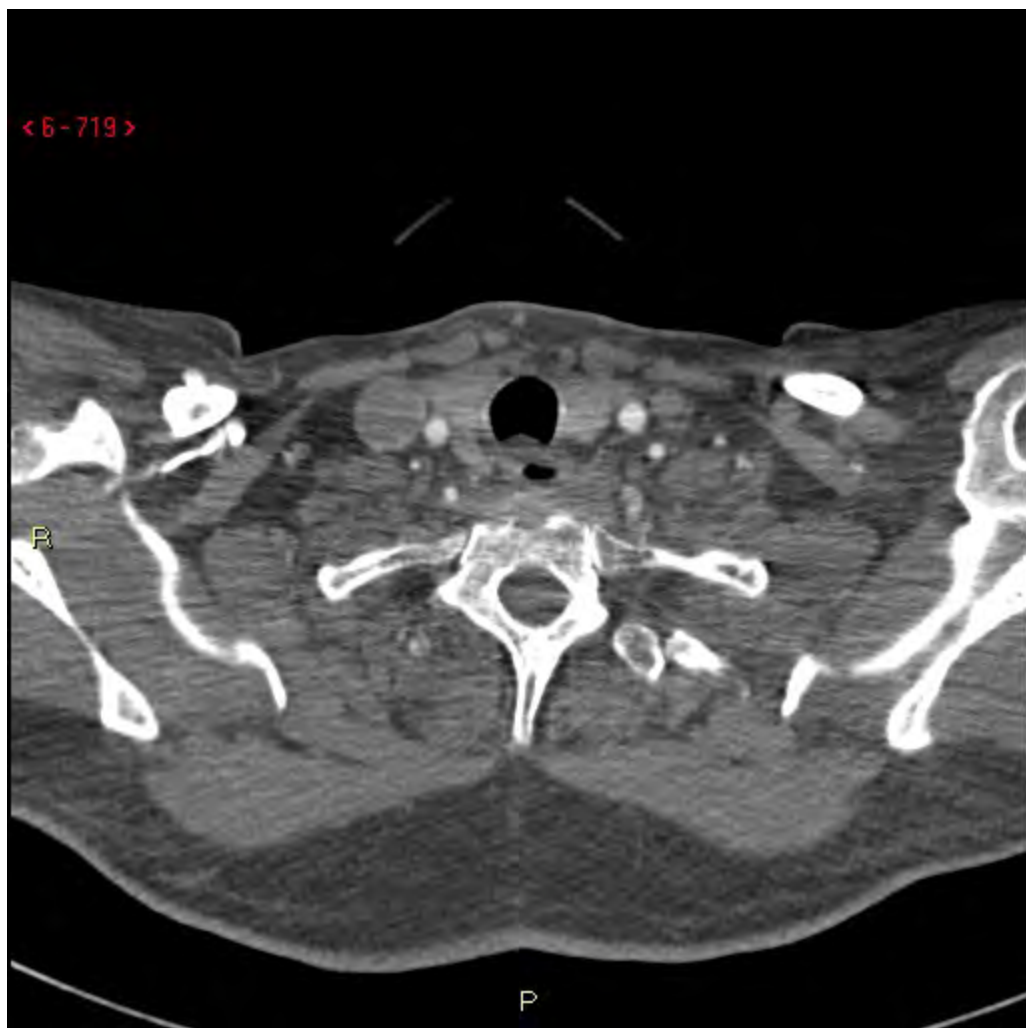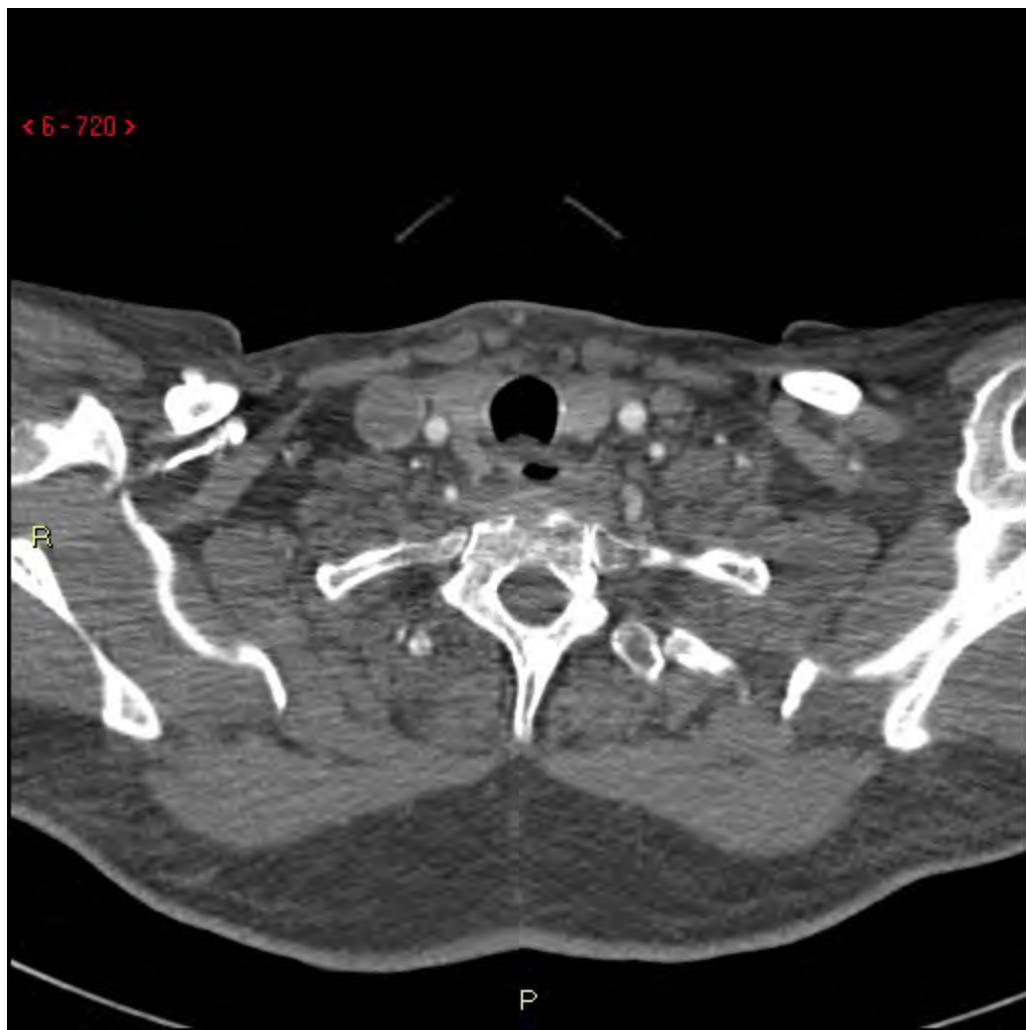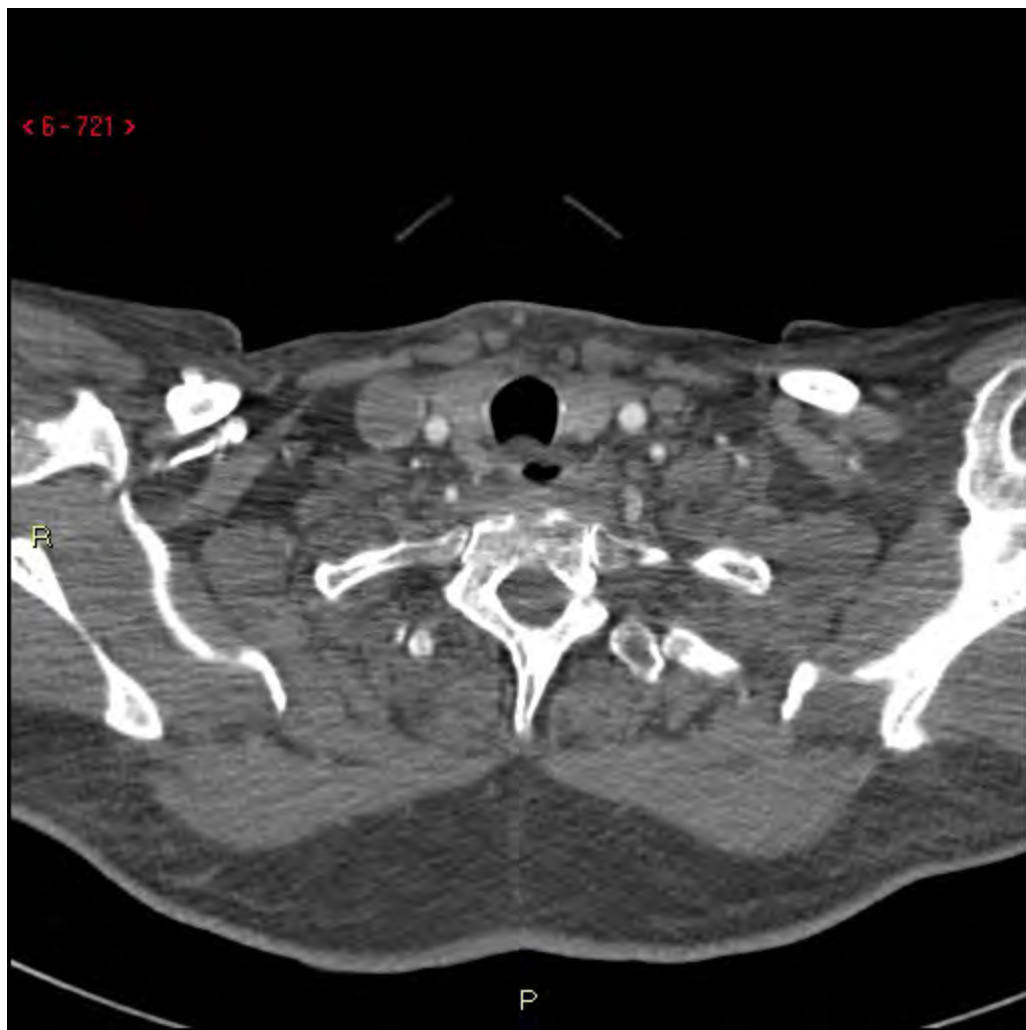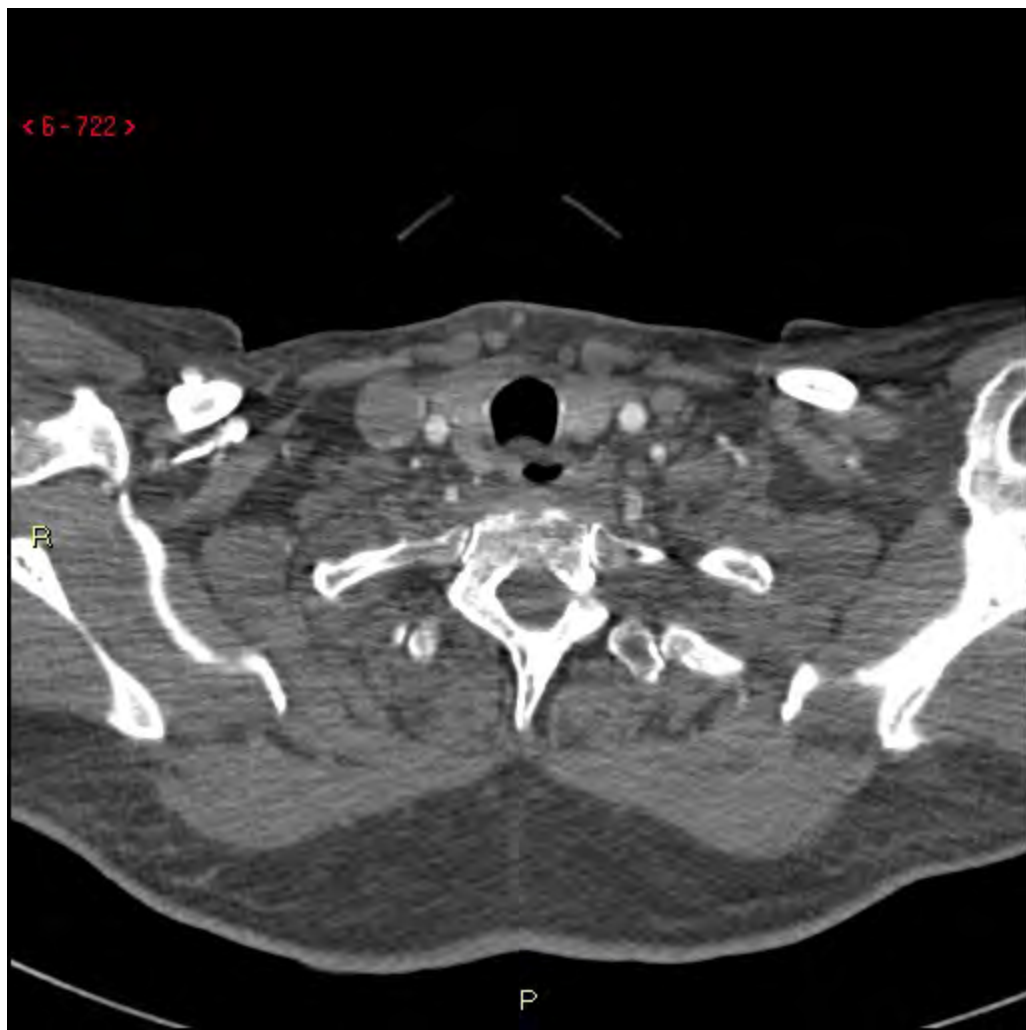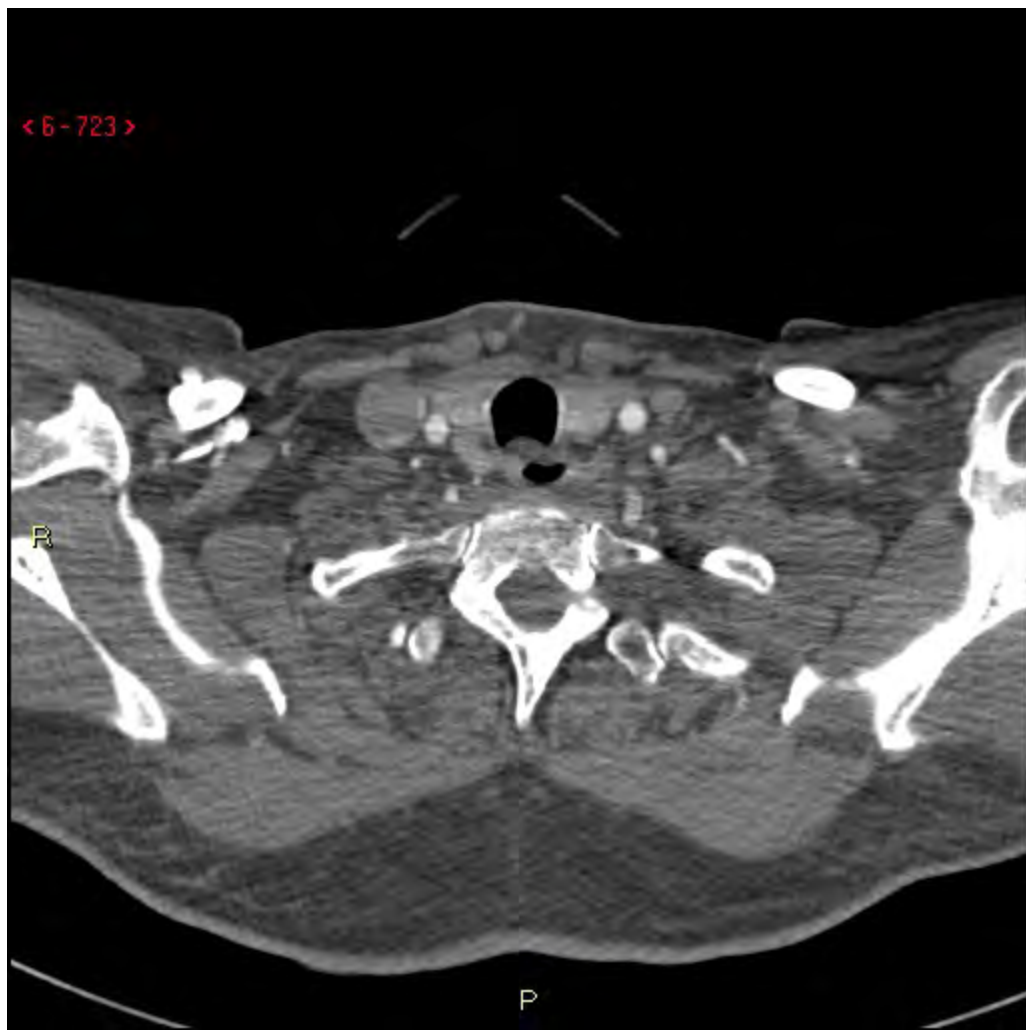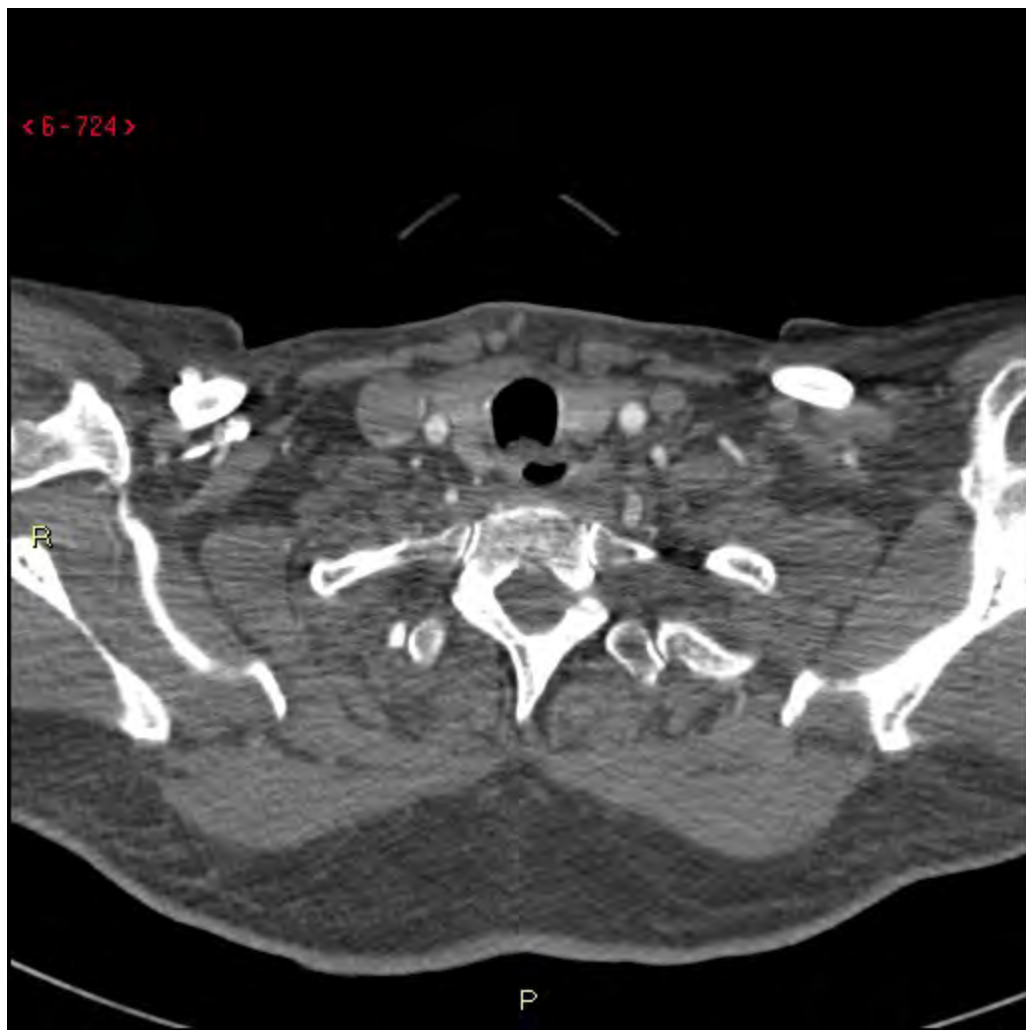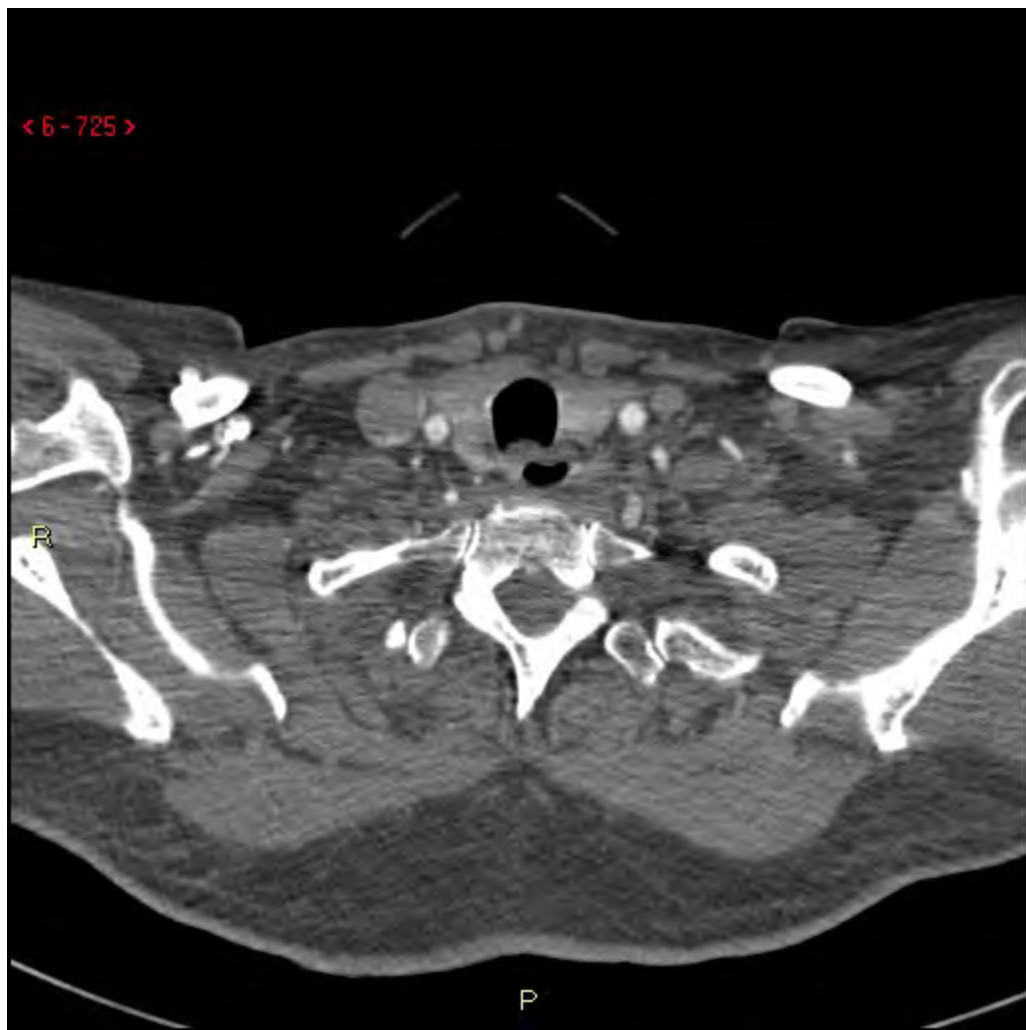






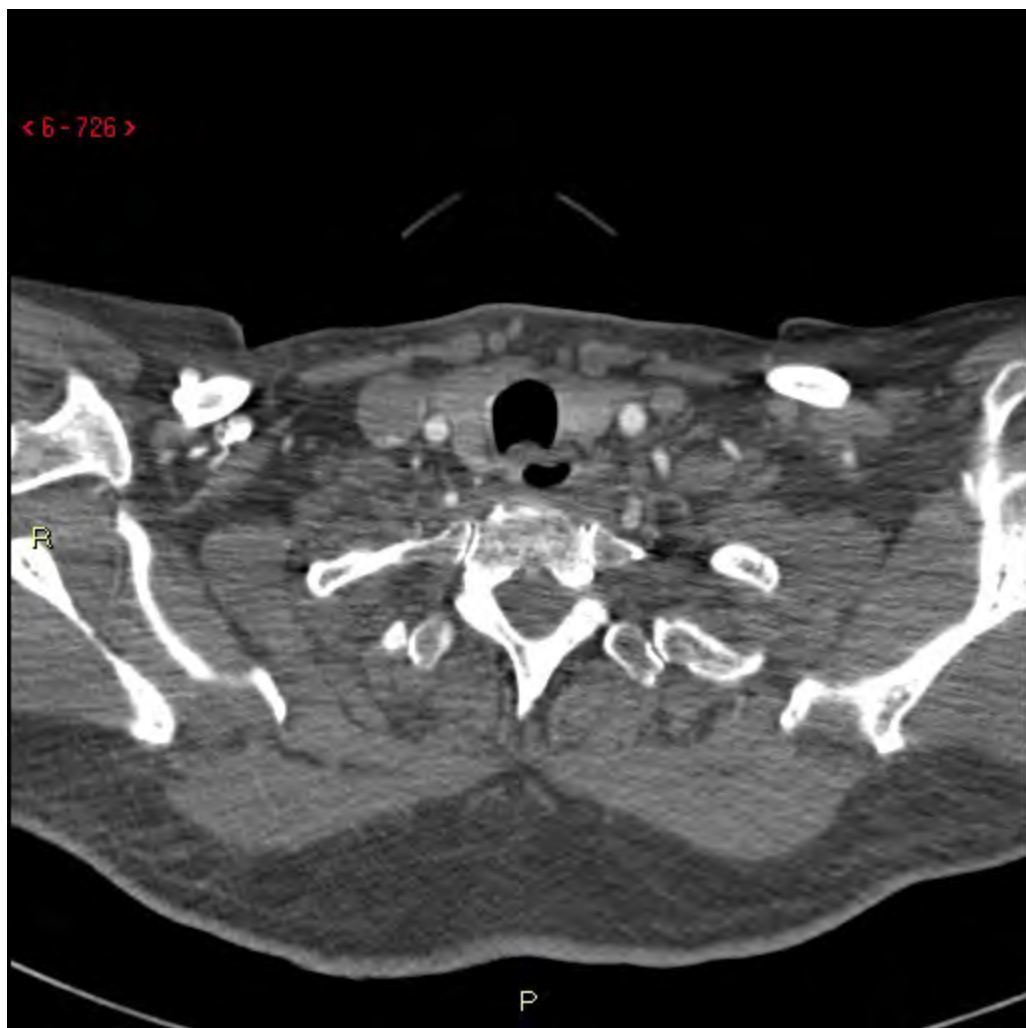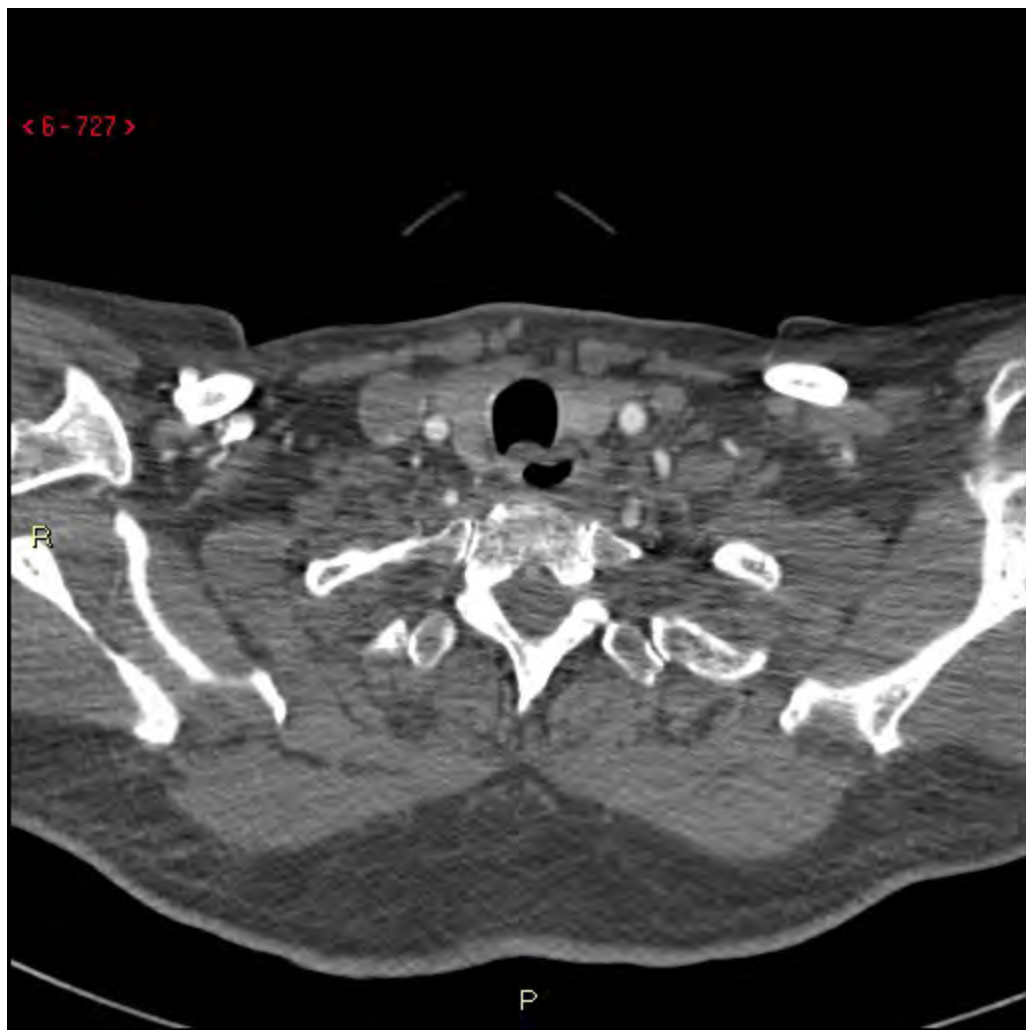




















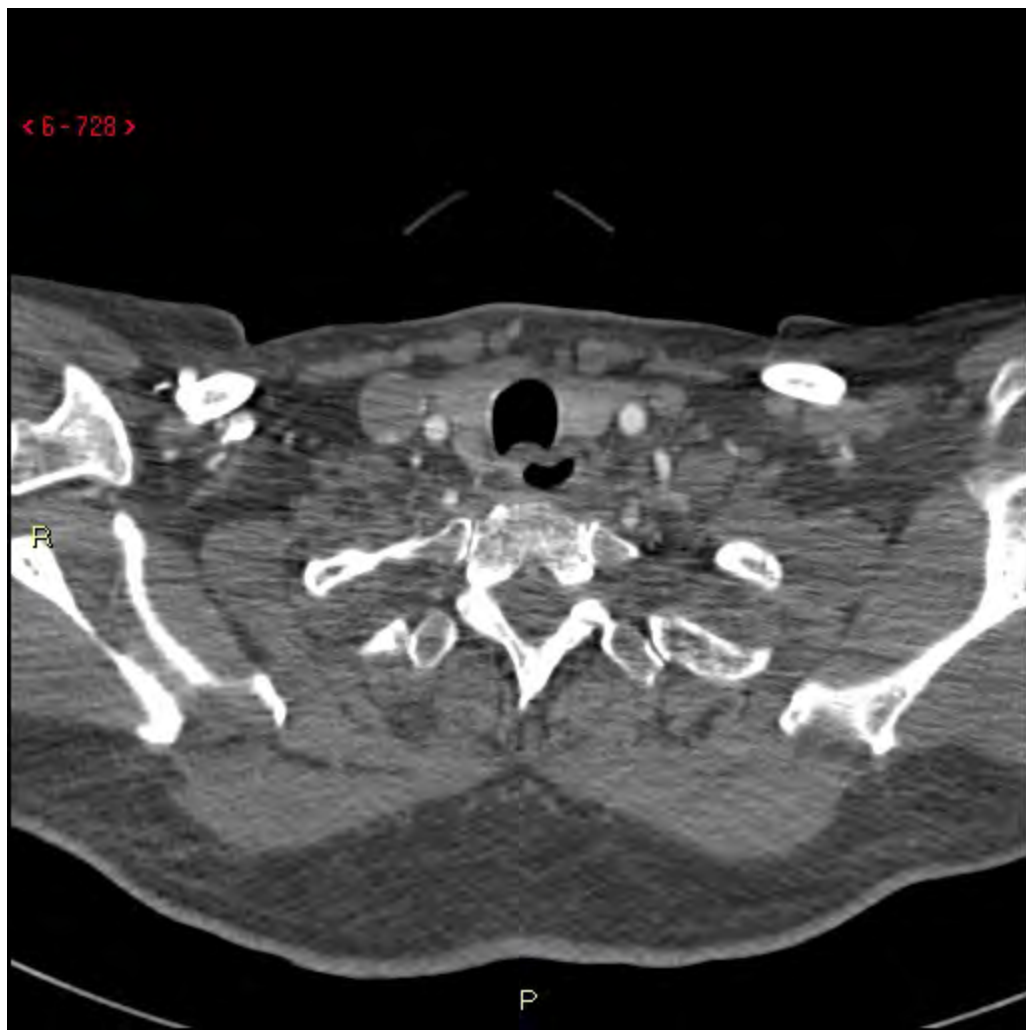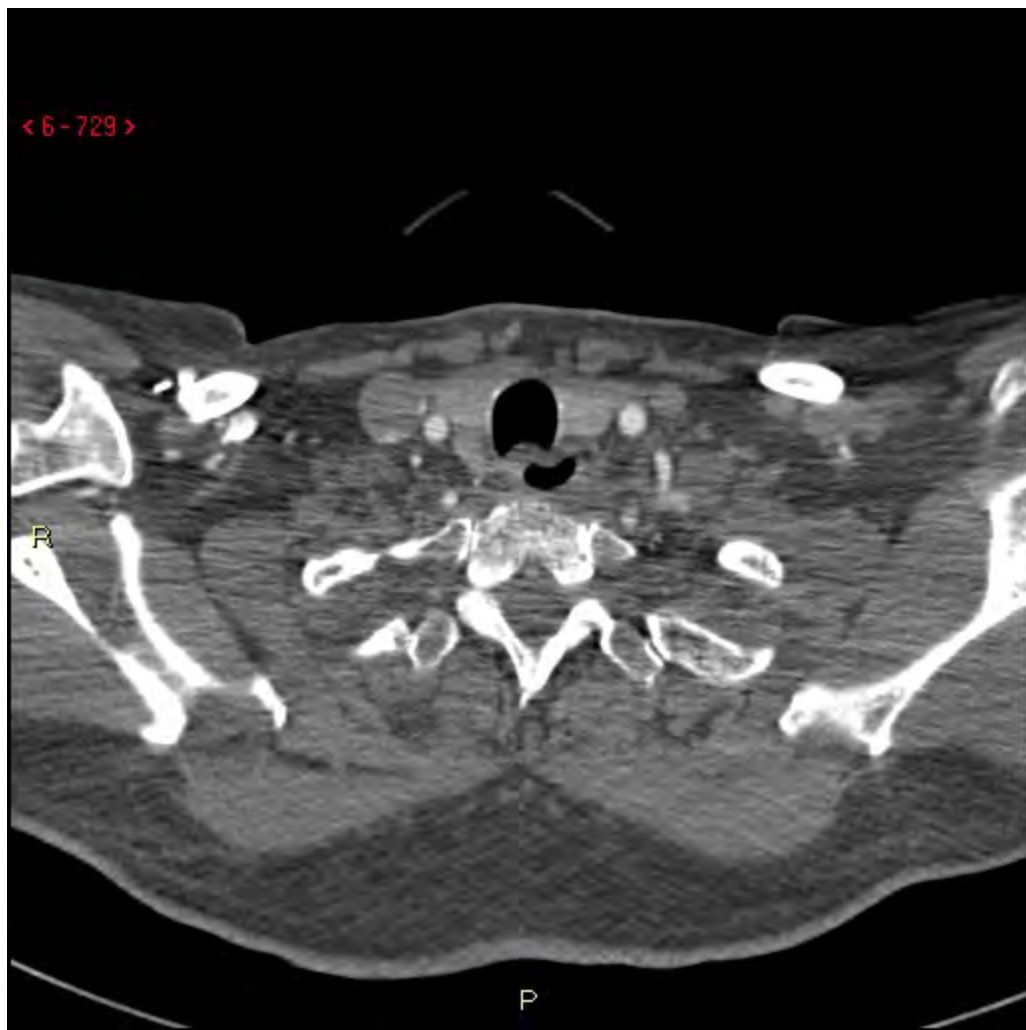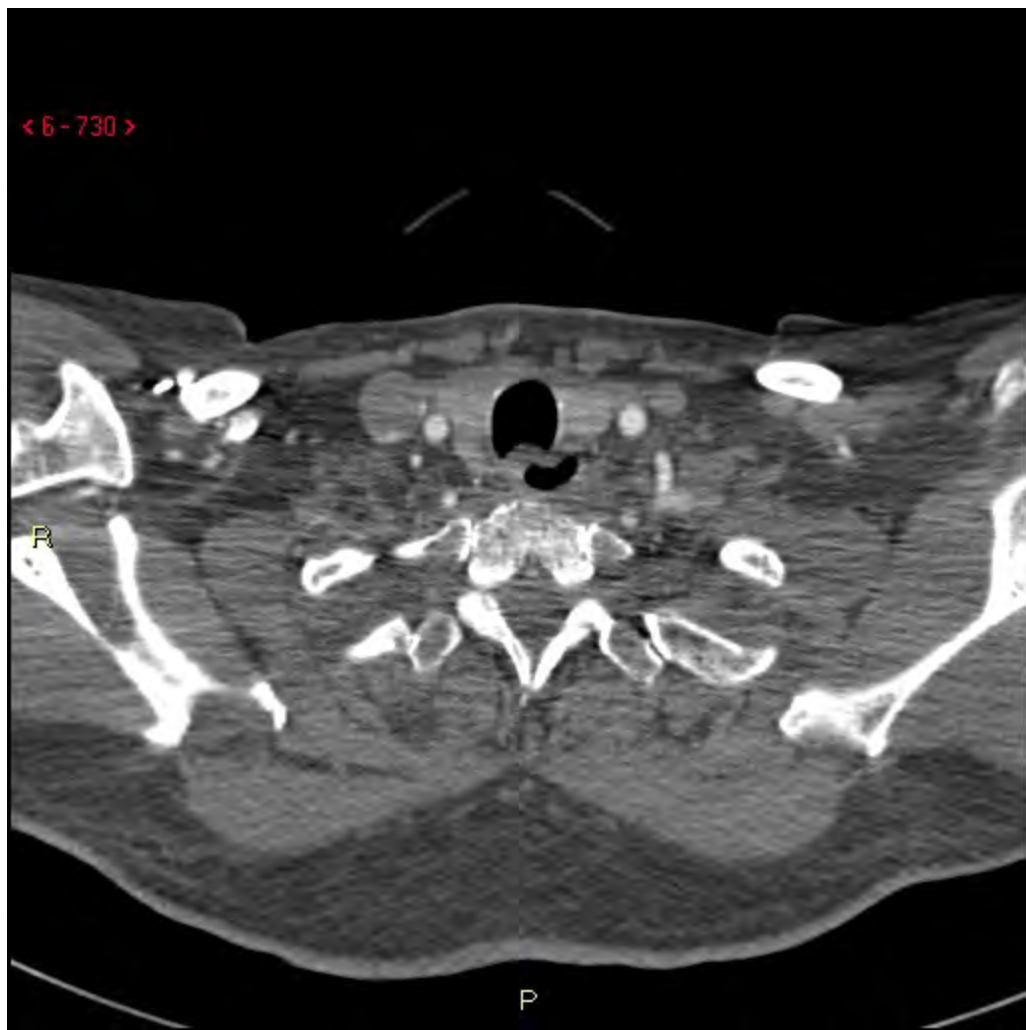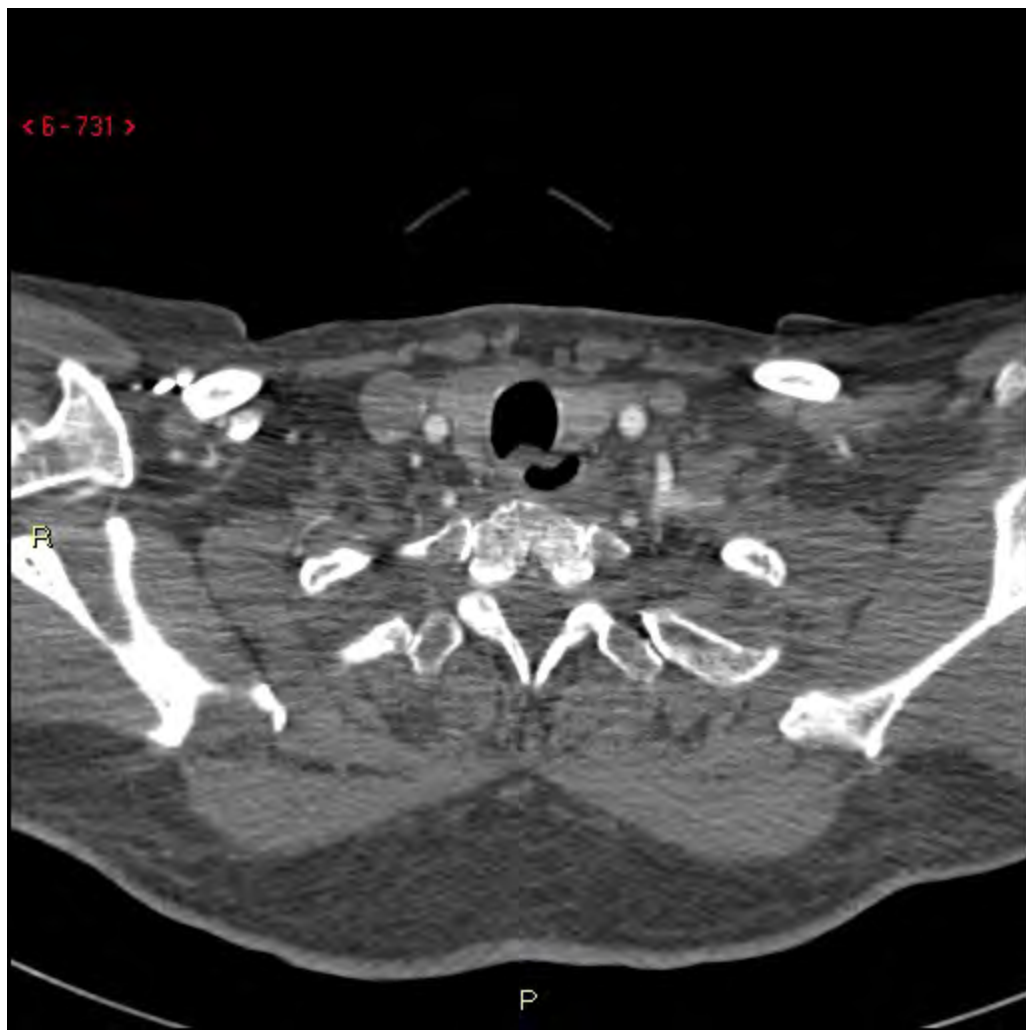Fall 3B

DT-Angio, visade?

# Fall 3B

Fynd: DT hals-/cerebral angiografi, 2013-07-12:

Tecken på dissektion i vänster a. vertebralis.

Endast ett kort proximalt avsnitt vid

avgången från arcus uppvisar svag

kontrastfyllnad. Därefter ses ingen

kontrastfyllnad i artären ända upp till nivå

med C2. Distalt därom trådsml excentrisk

kontrastfyllnad , ända upp till mynningen i

basilaris.

Inga signifikanta stenoser eller ocklusioner i

övriga hals- eller cerebrala artärer.