

Fall 4

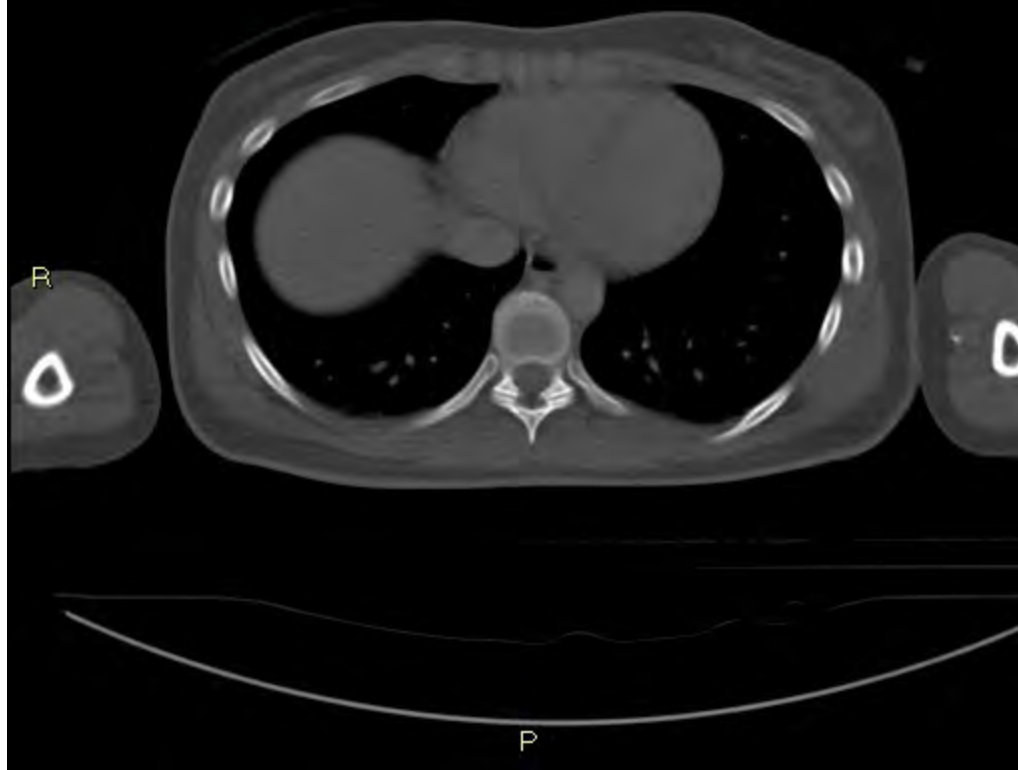Fall 4

25 år, K, Ramlat av Häst. Ont i ryggen.

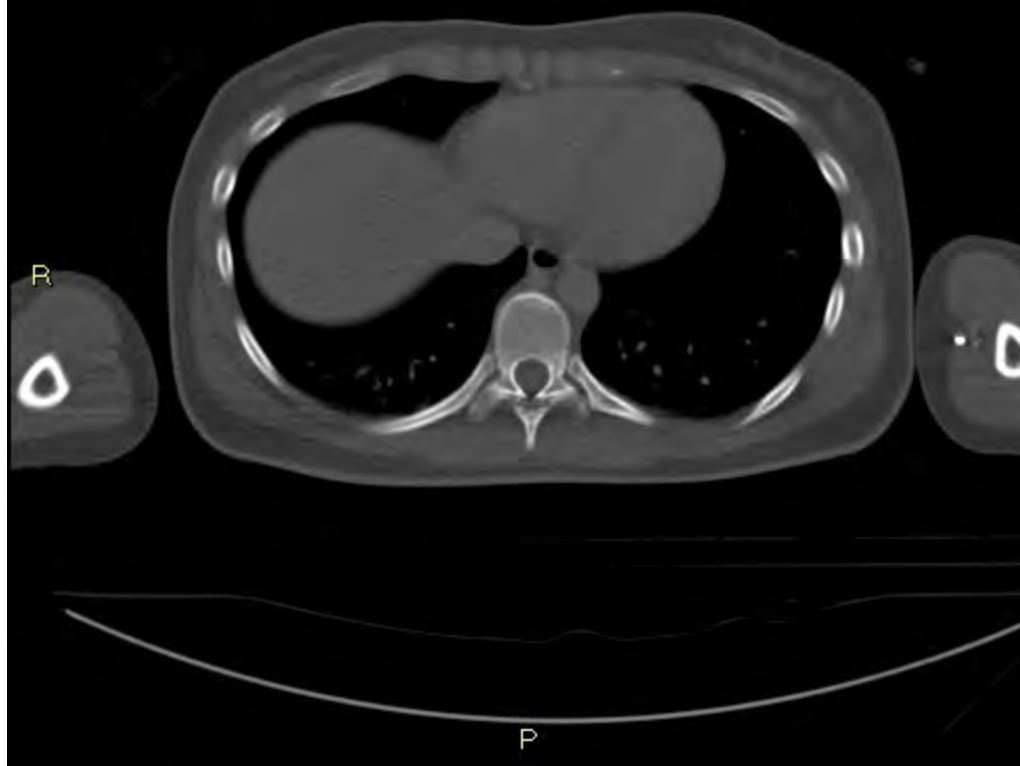Ingen neurologi.

DT från regionen:

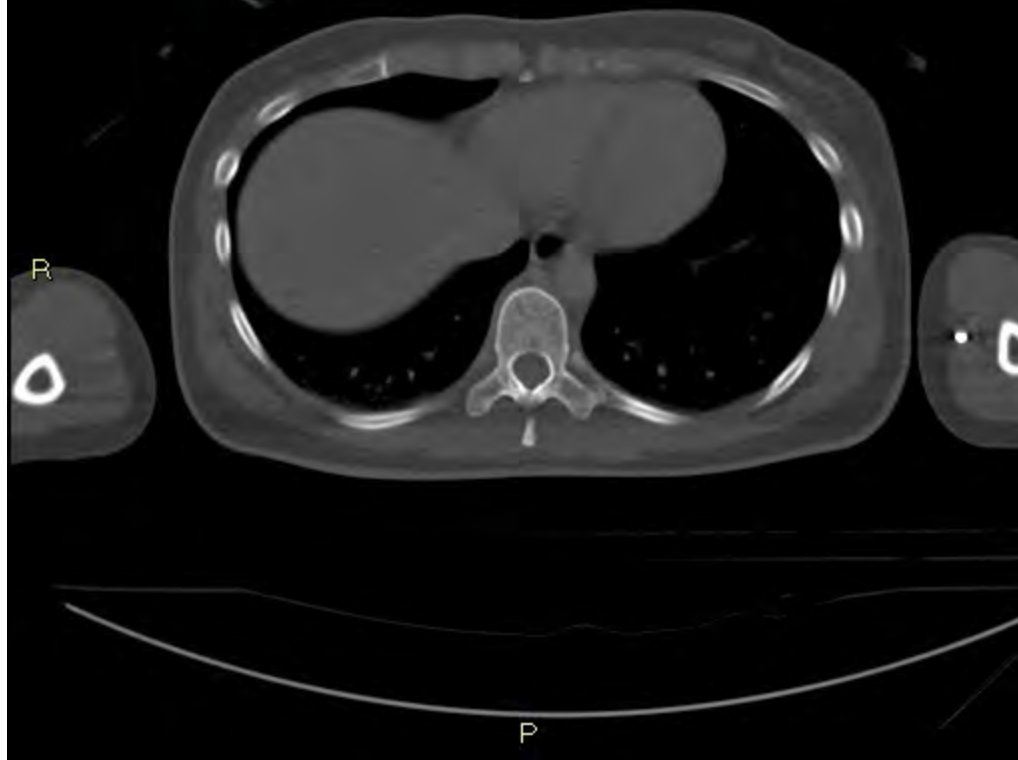< 5 - 15 SKELETT 5/5 >



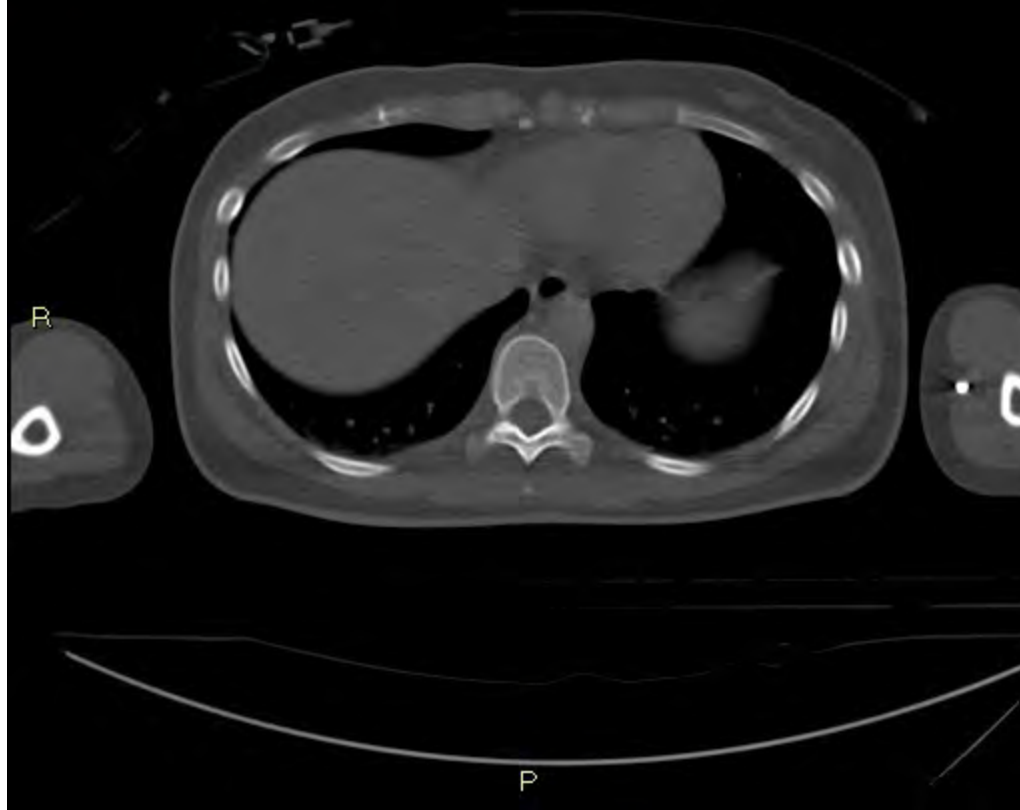< 5 - 16 SKELETT 5/5 >



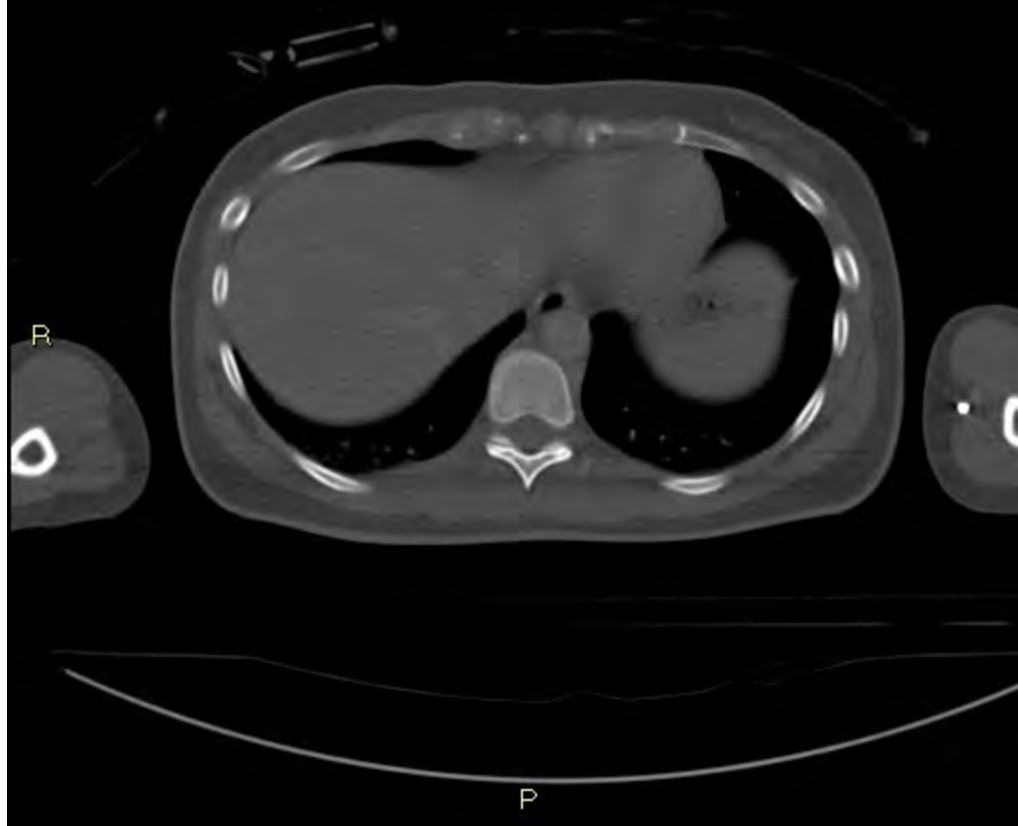
< 5 - 17 SKELETT 5/5 >



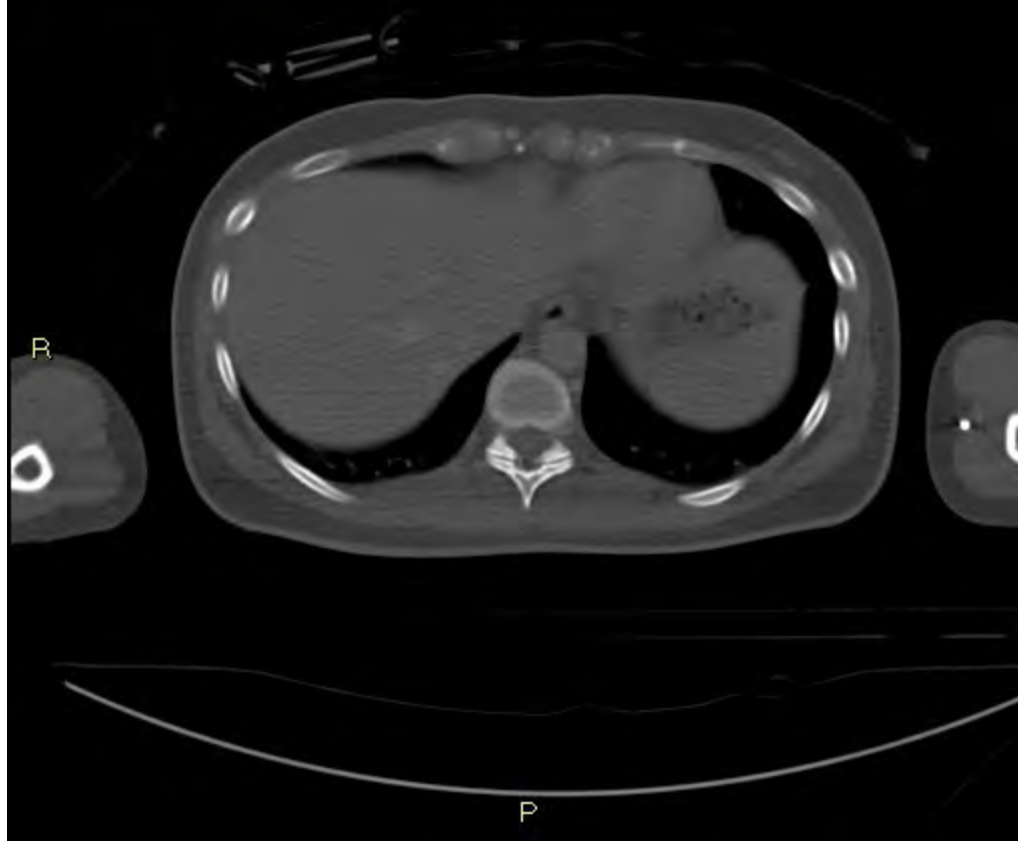< 5 - 18 SKELETT 5/5 >



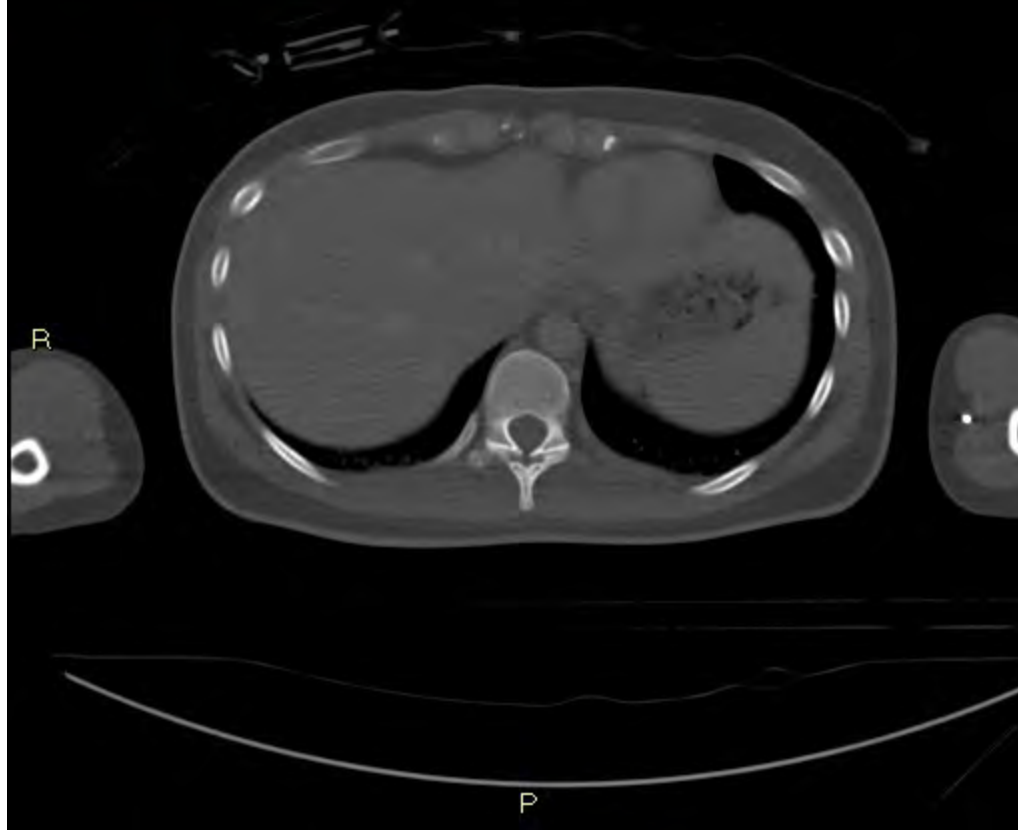
< 5 - 19 SKELETT 5/5 >



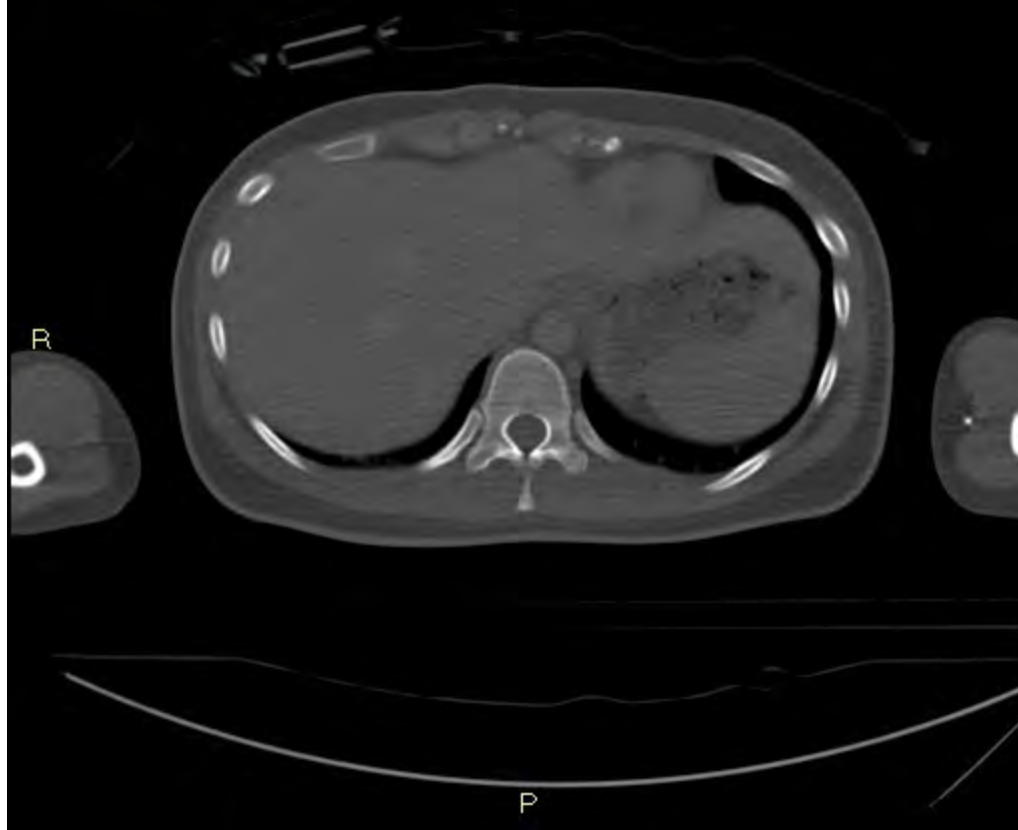
< 5 - 20 SKELETT 5/5 >



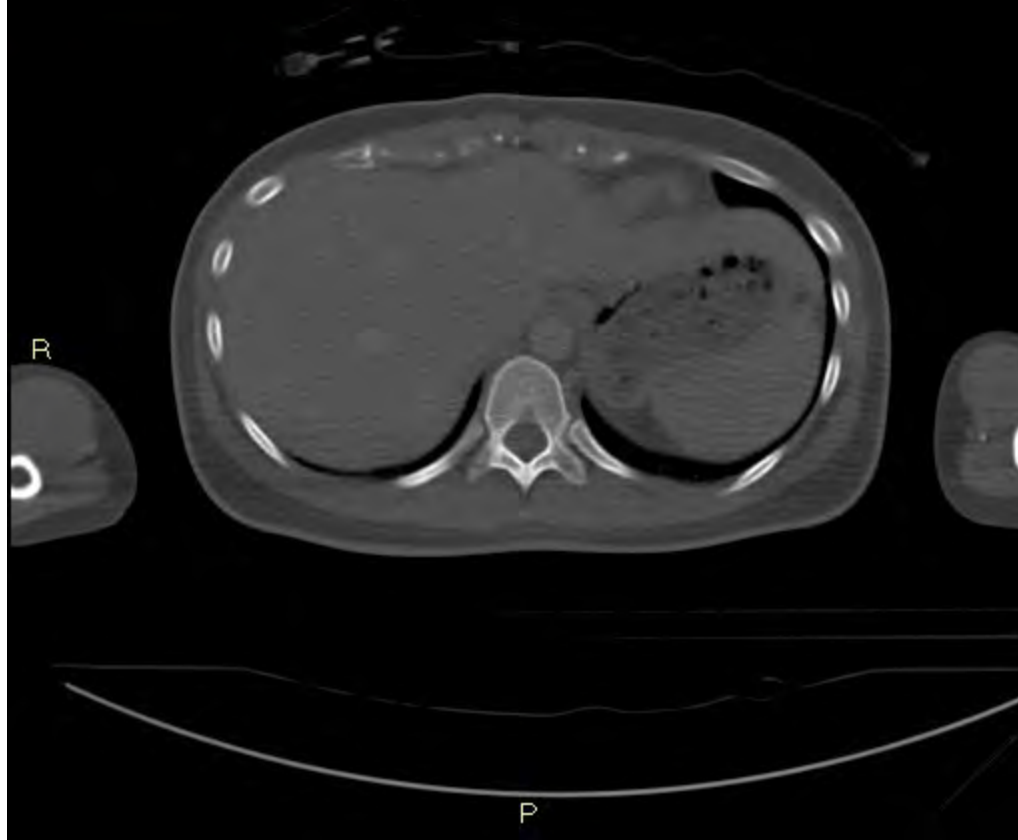
< 5 - 21 SKELETT 5/5 >



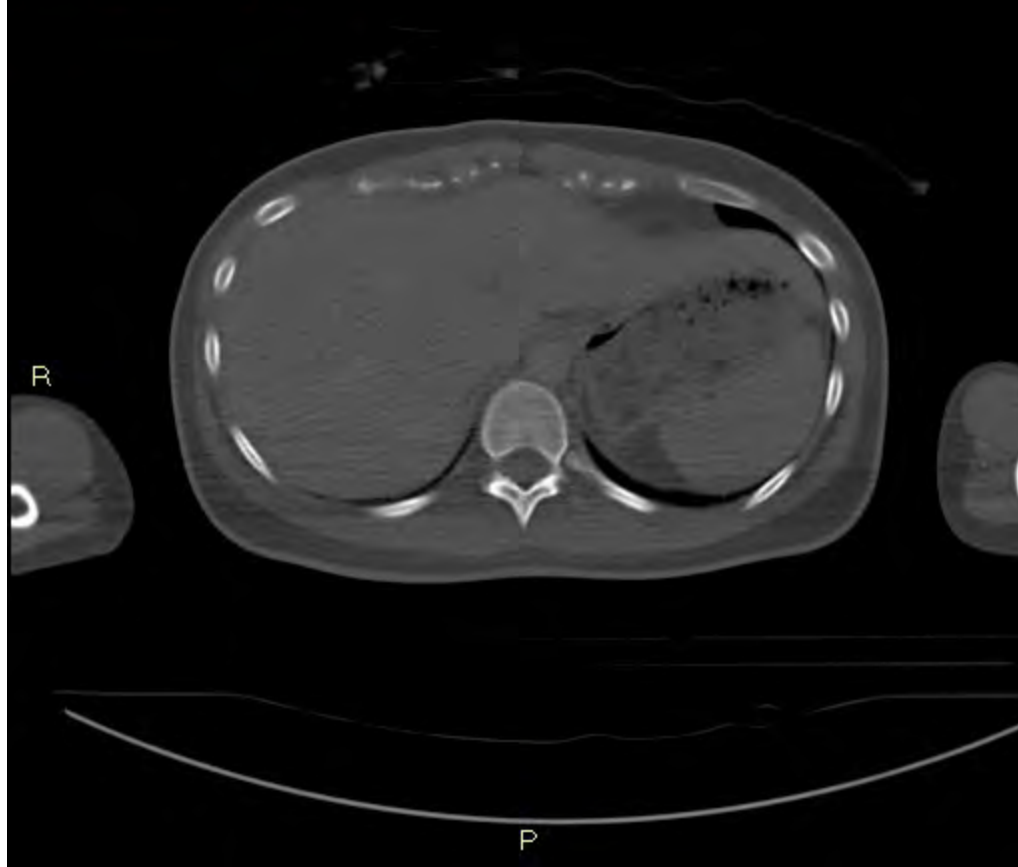
< 5 - 22 SKELETT 5/5 >



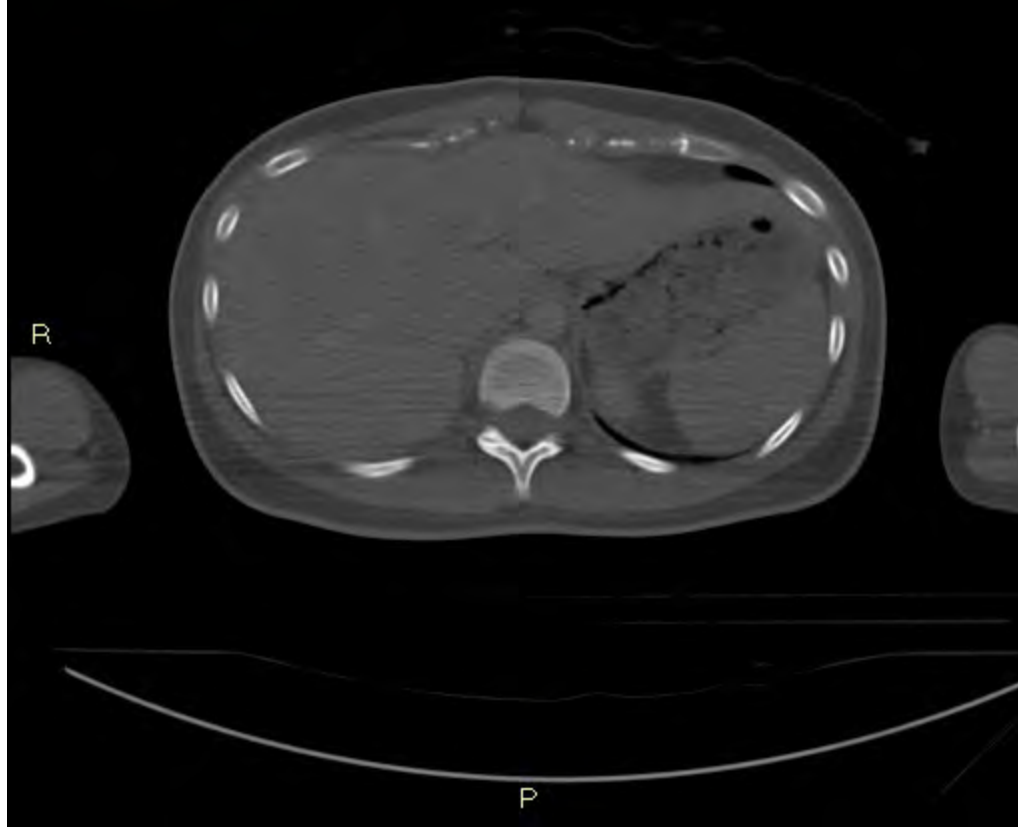
< 5 - 23 SKELETT 5/5 >



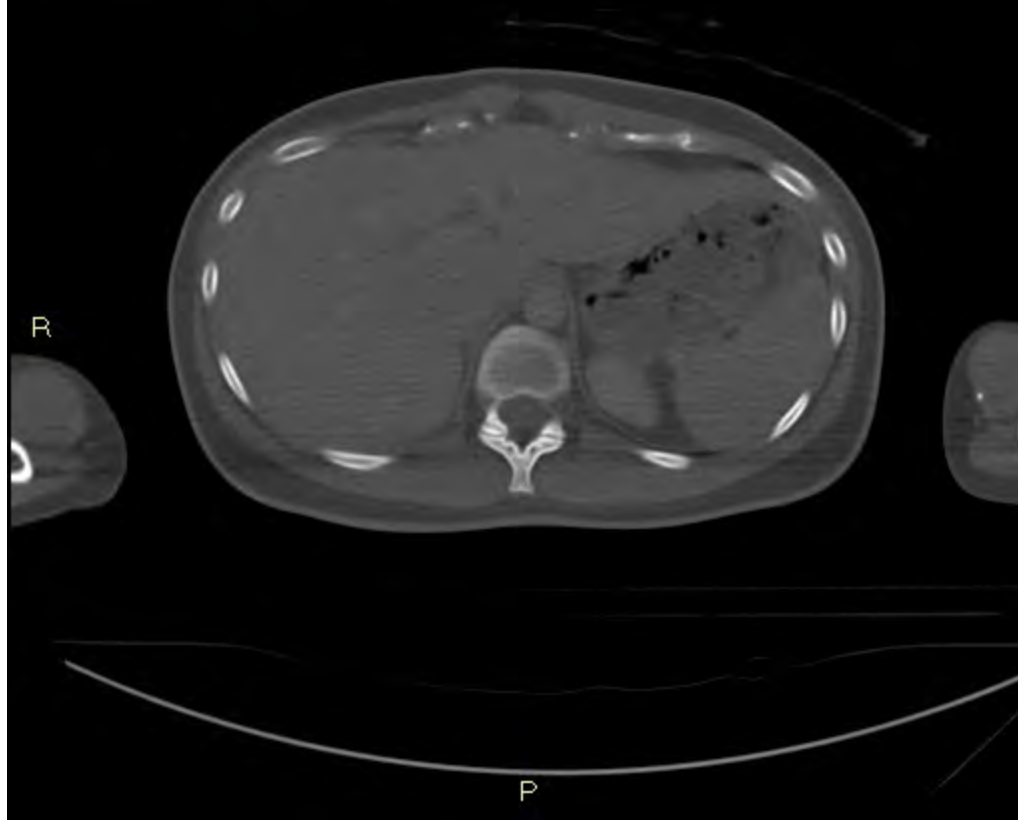
< 5 - 24 SKELETT 5/5 >



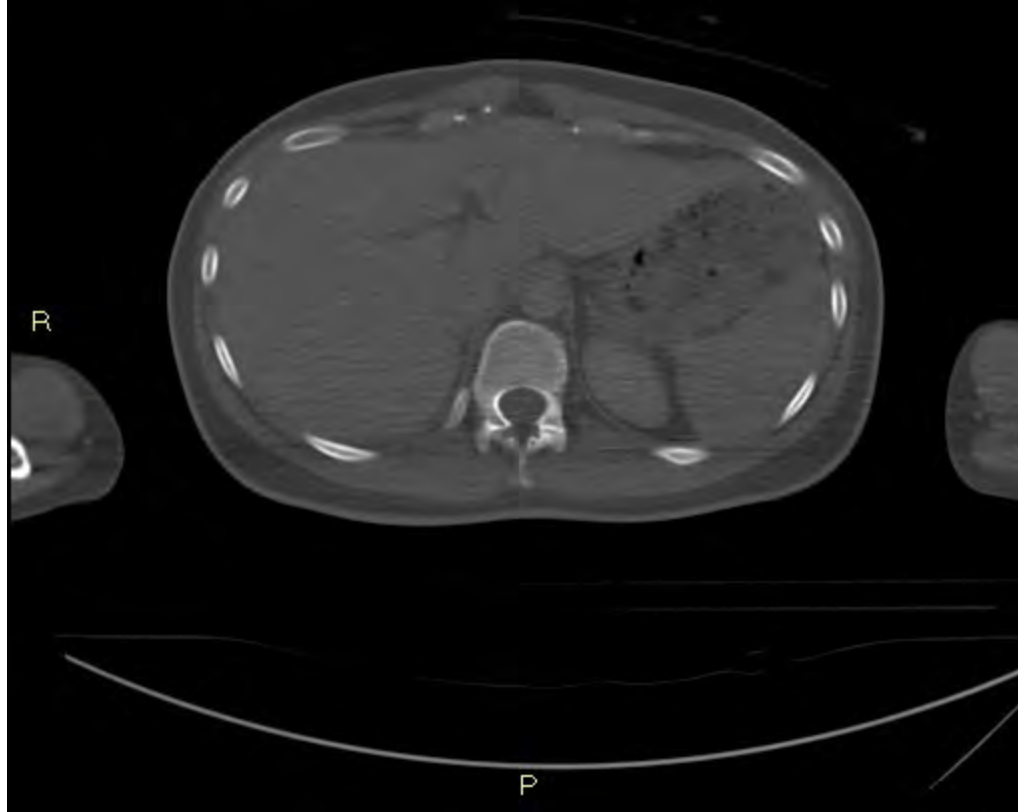
< 5 - 25 SKELETT 5/5 >



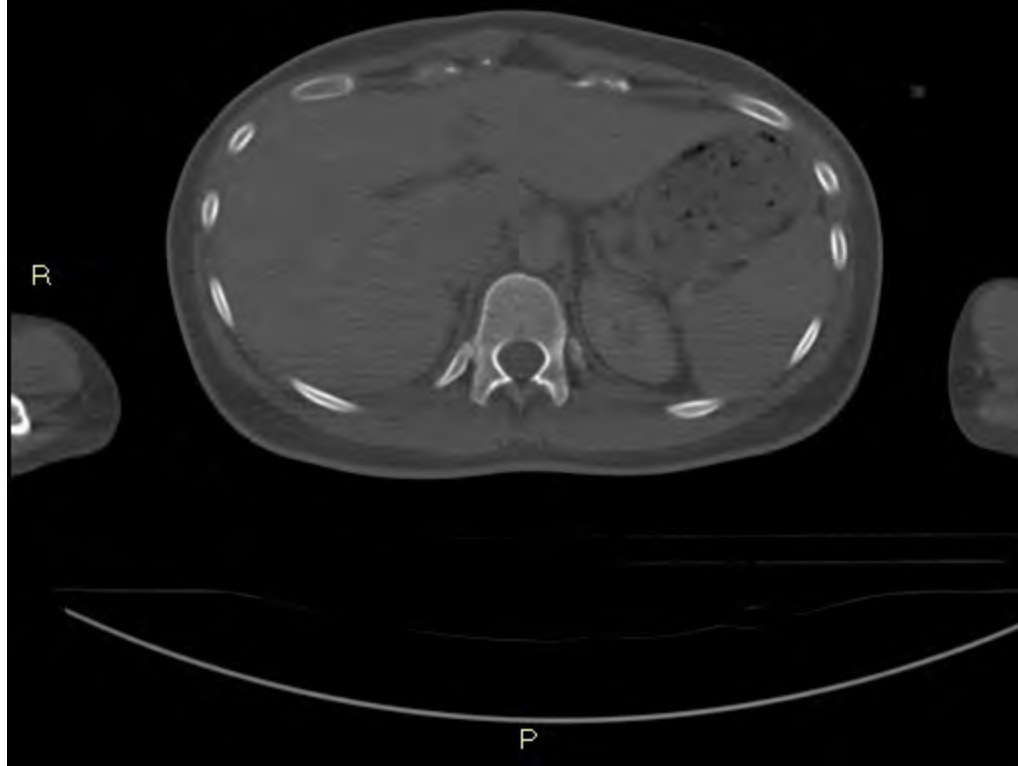< 5 - 26 SKELETT 5/5 >



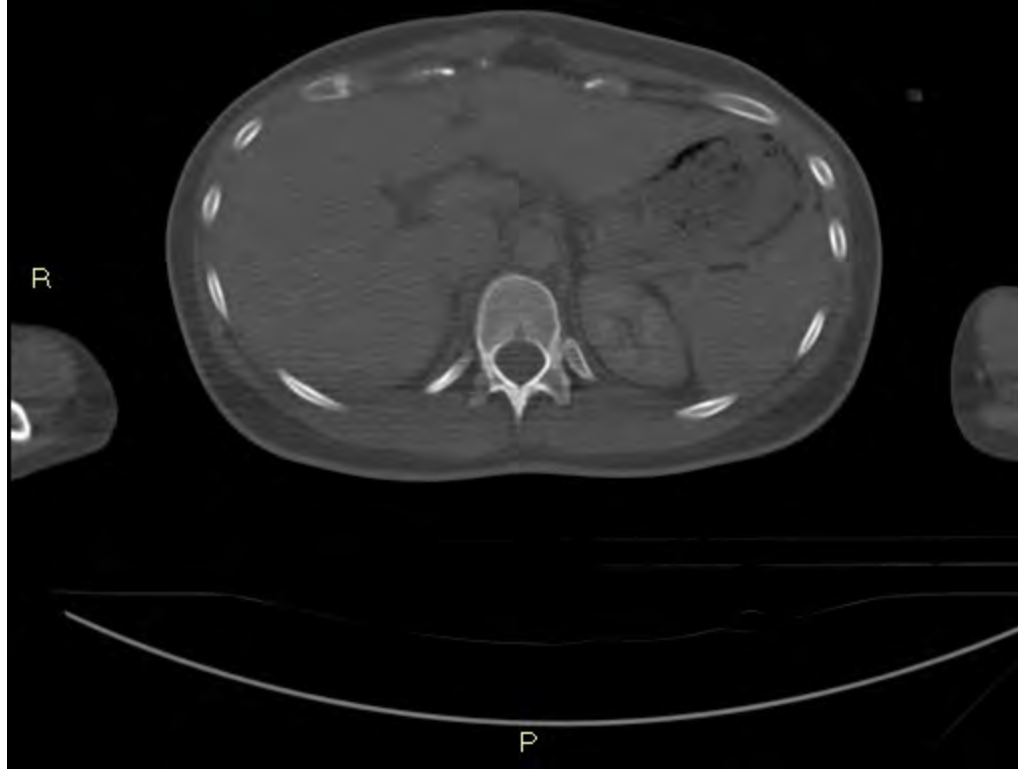< 5 - 27 SKELETT 5/5 >



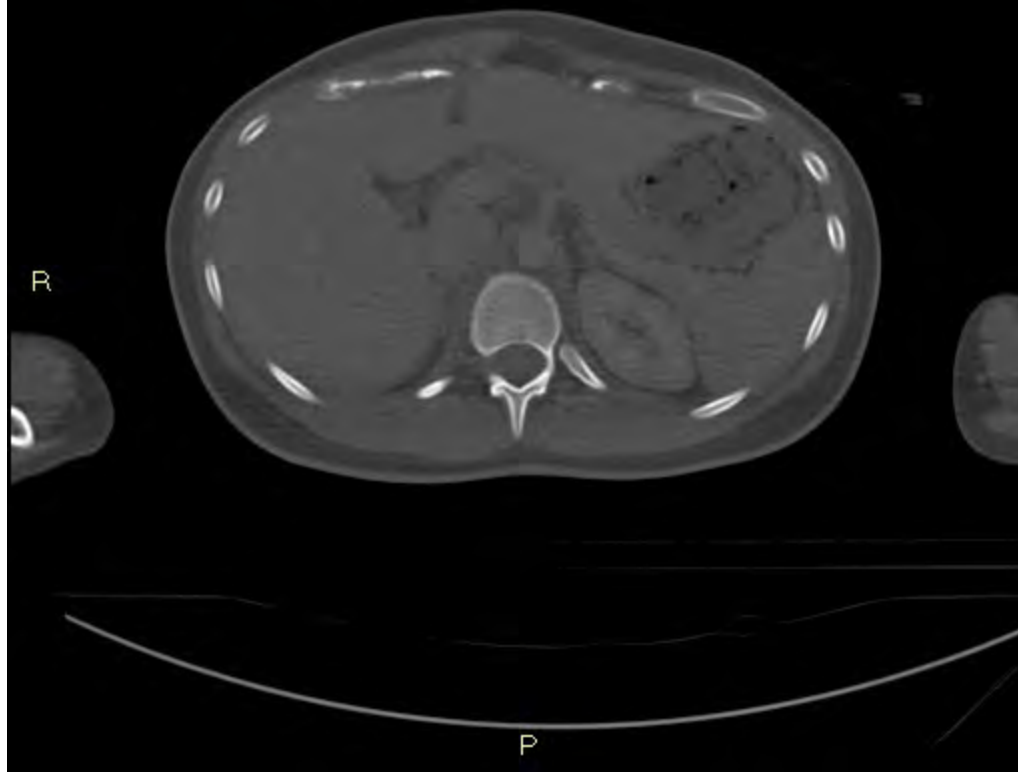
< 5 - 28 SKELETT 5/5 >



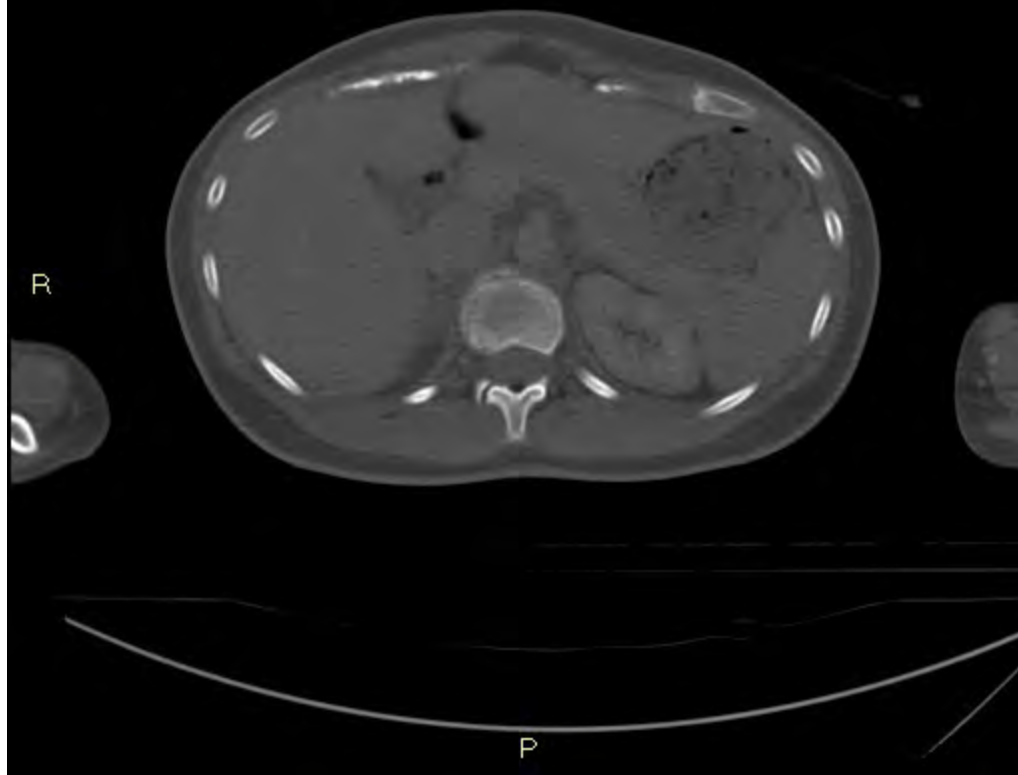
< 5 - 29 SKELETT 5/5 >



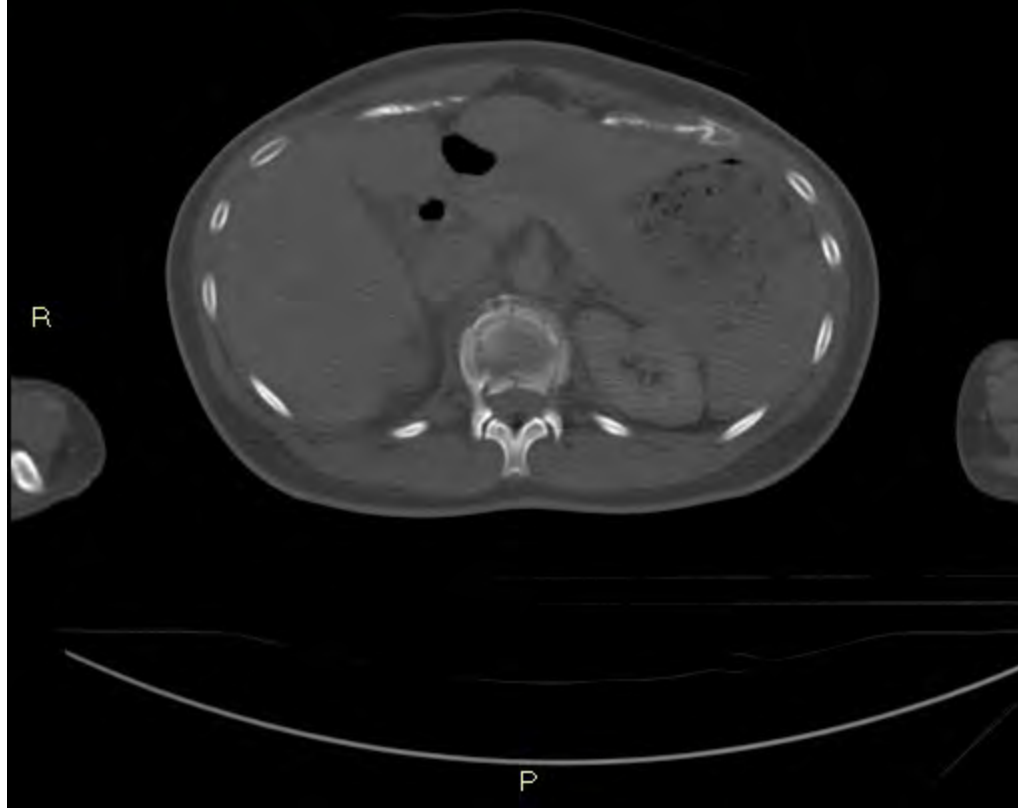
< 5 - 30 SKELETT 5/5 >



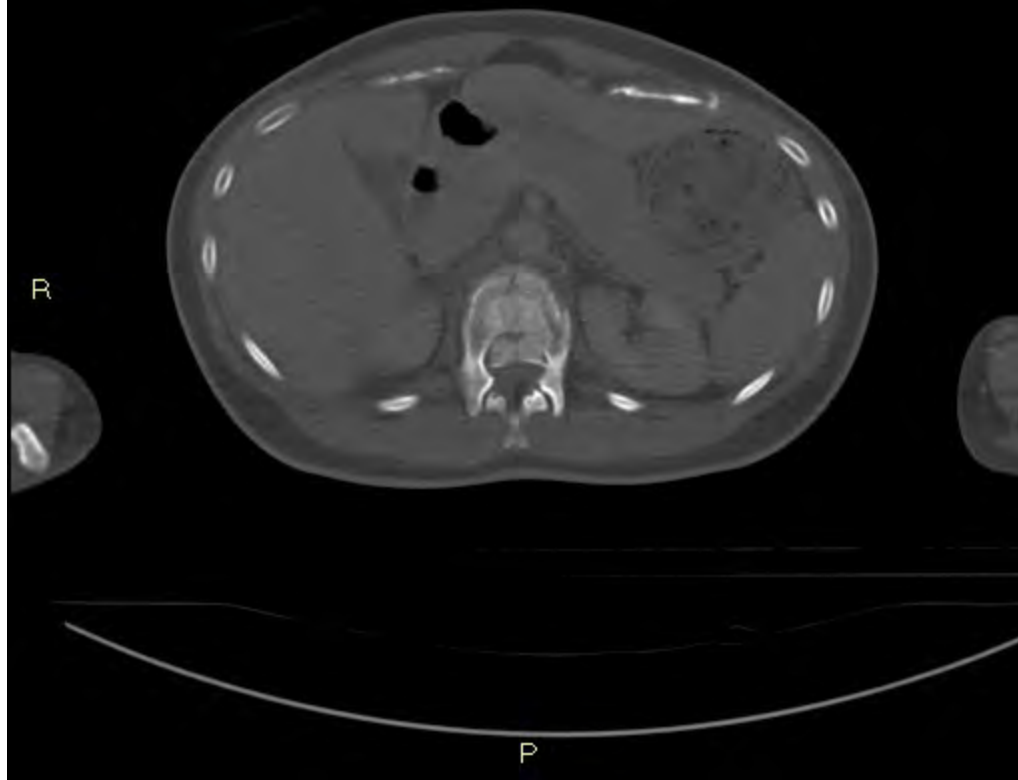
< 5 - 31 SKELETT 5/5 >



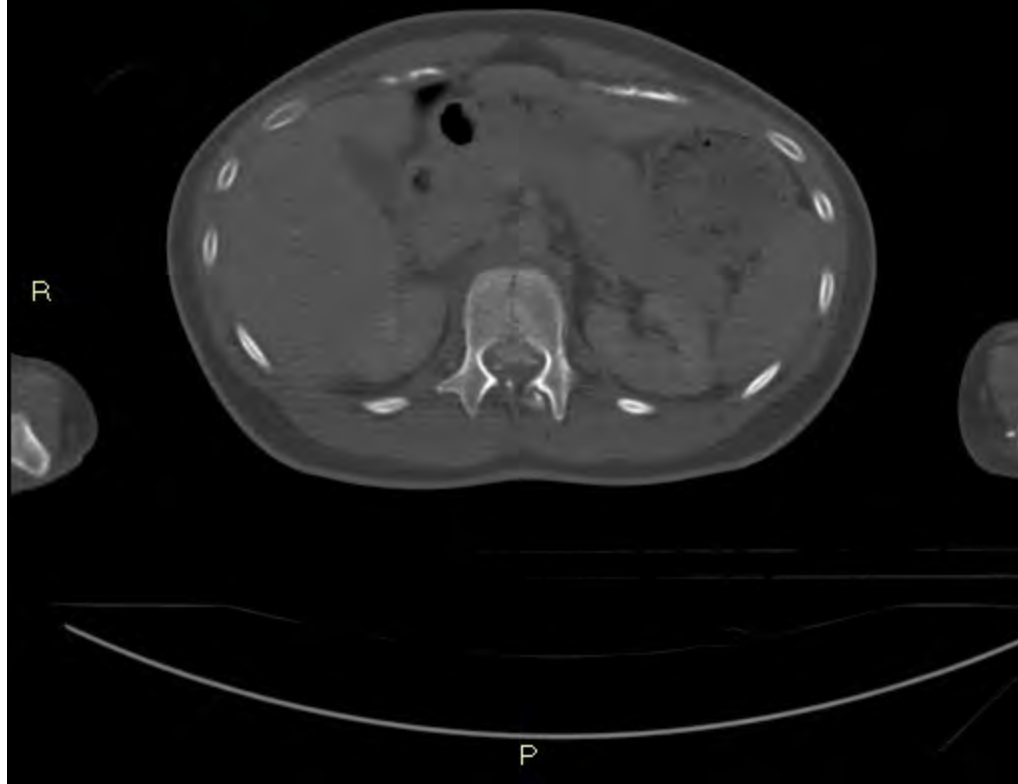
< 5 - 32 SKELETT 5/5 >



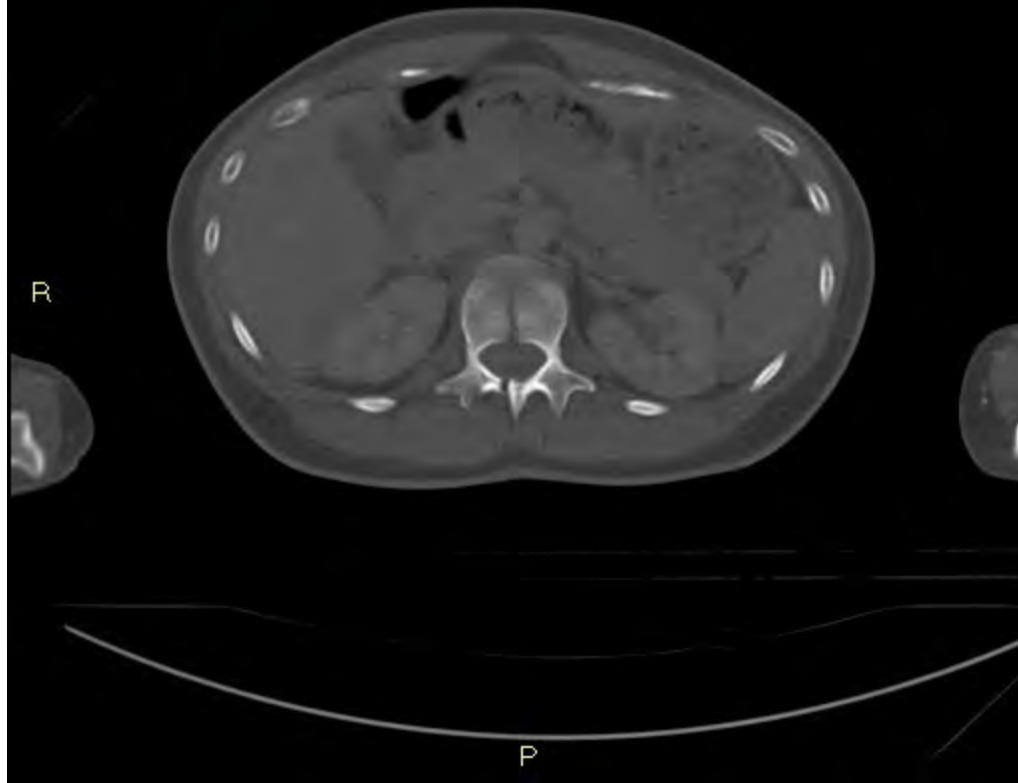
< 5 - 33 SKELETT 5/5 >



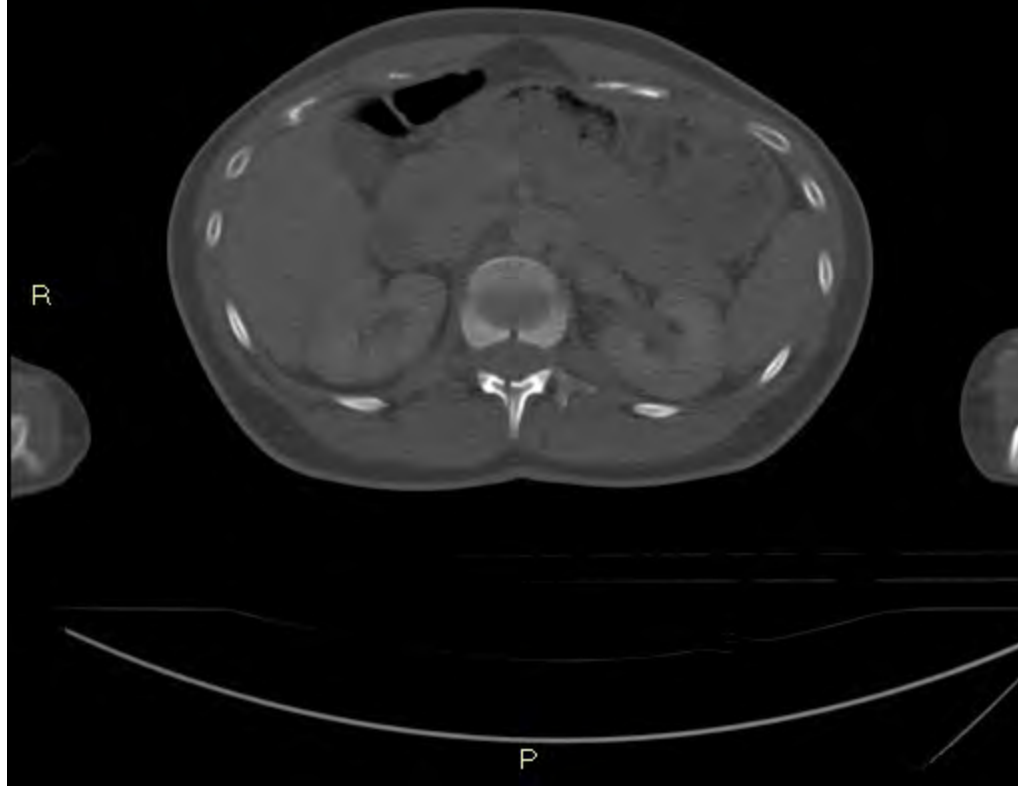
< 5 - 34 SKELETT 5/5 >



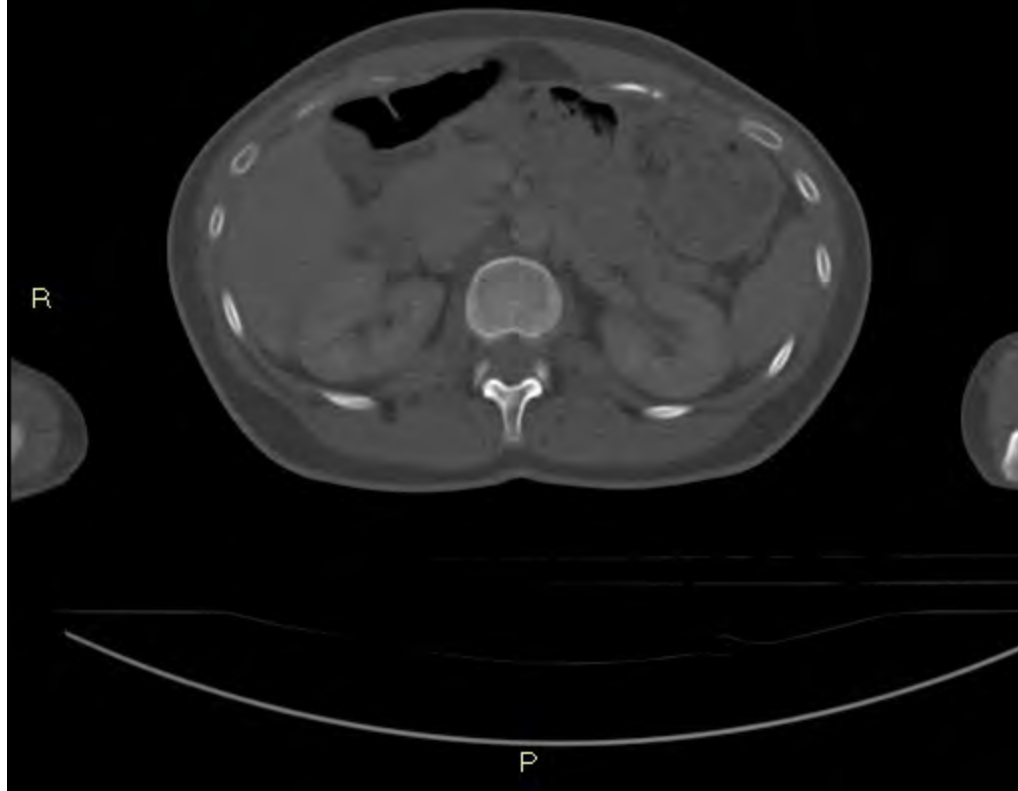
< 5 - 35 SKELETT 5/5 >



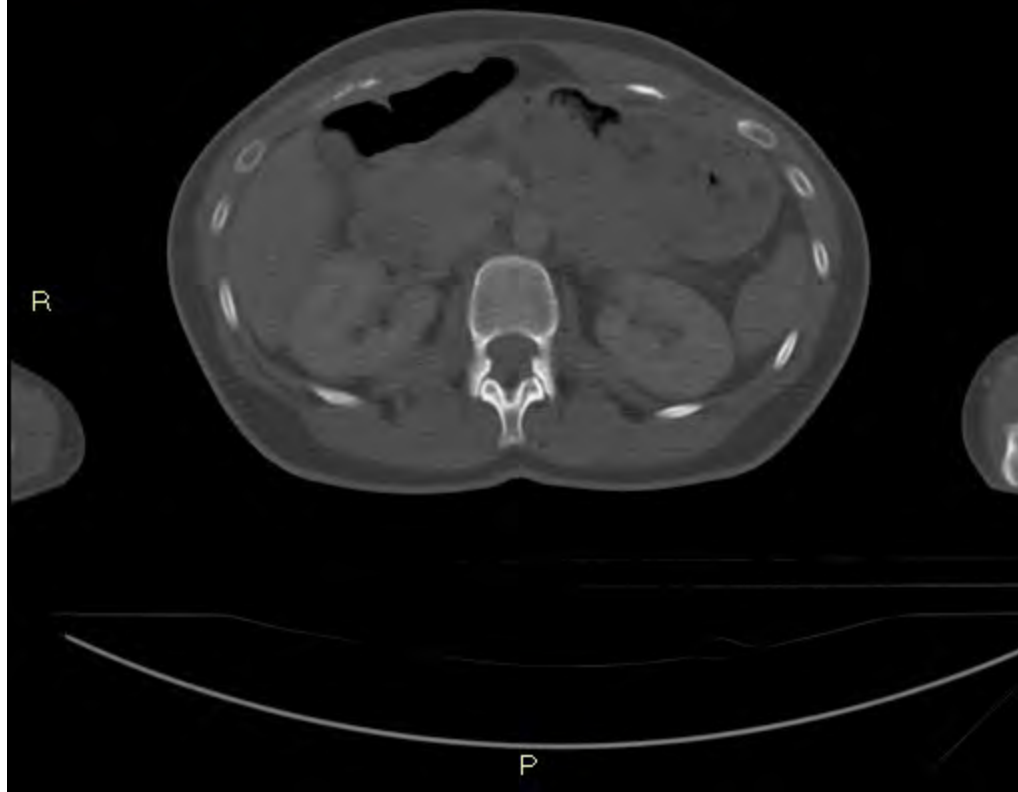
< 5 - 36 SKELETT 5/5 >



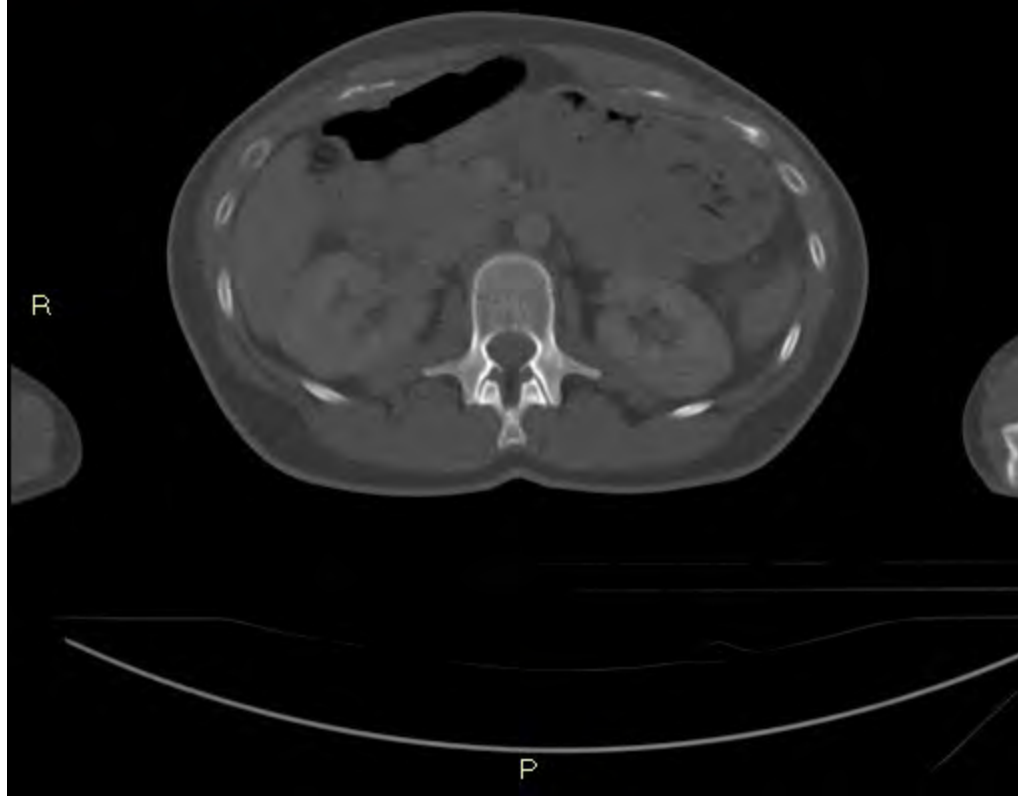
< 5 - 37 SKELETT 5/5 >



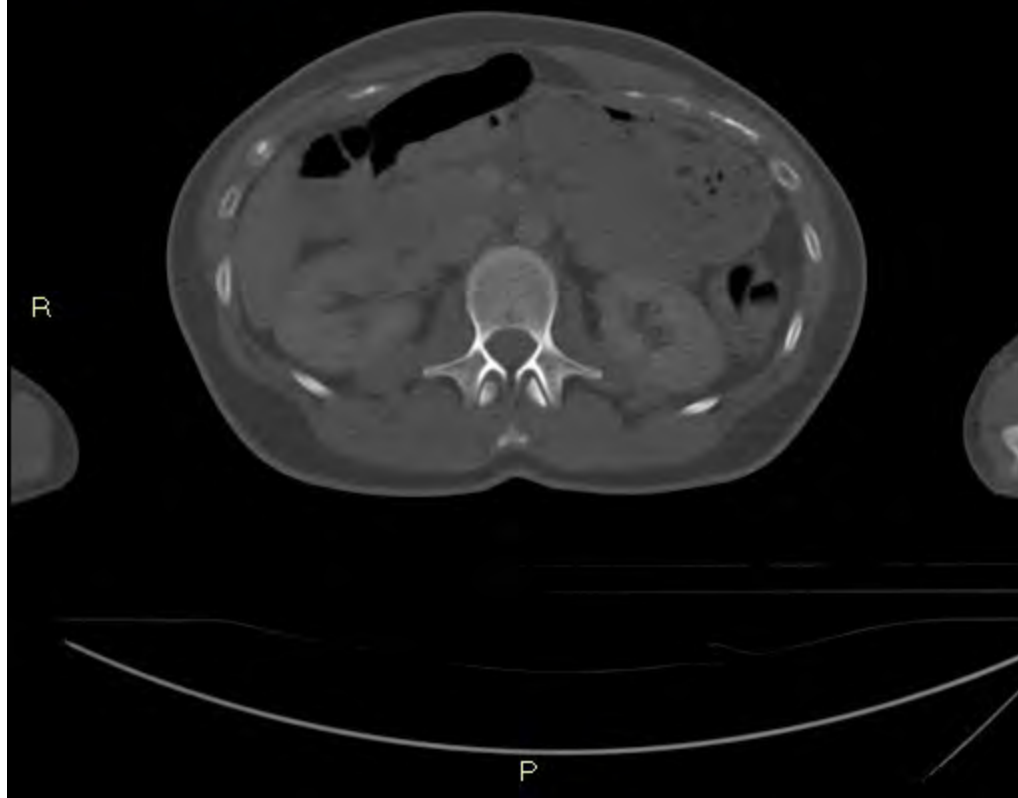
< 5 - 38 SKELETT 5/5 >



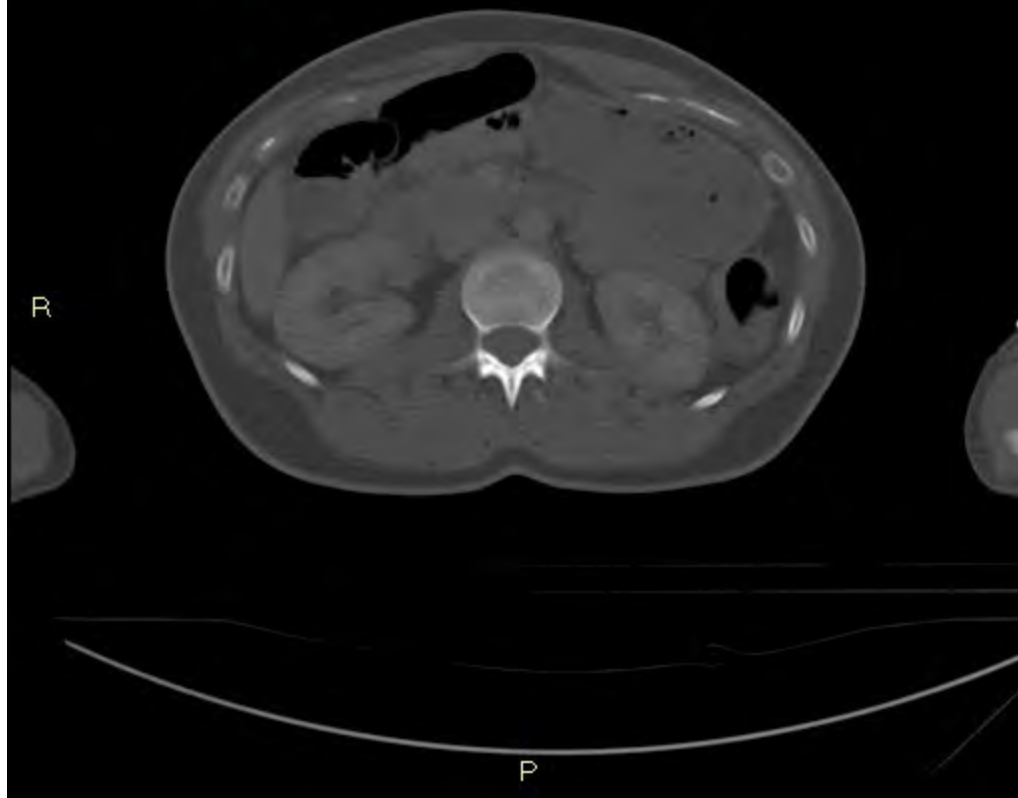
< 5 - 39 SKELETT 5/5 >



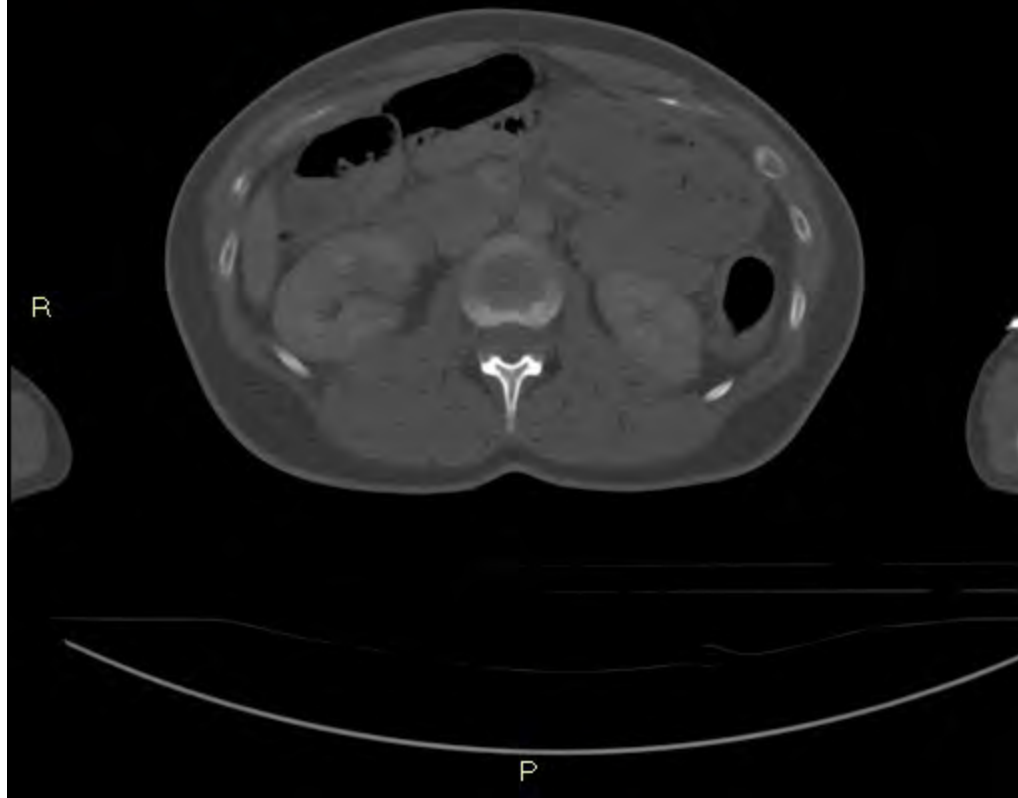
< 5 - 40 SKELETT 5/5 >



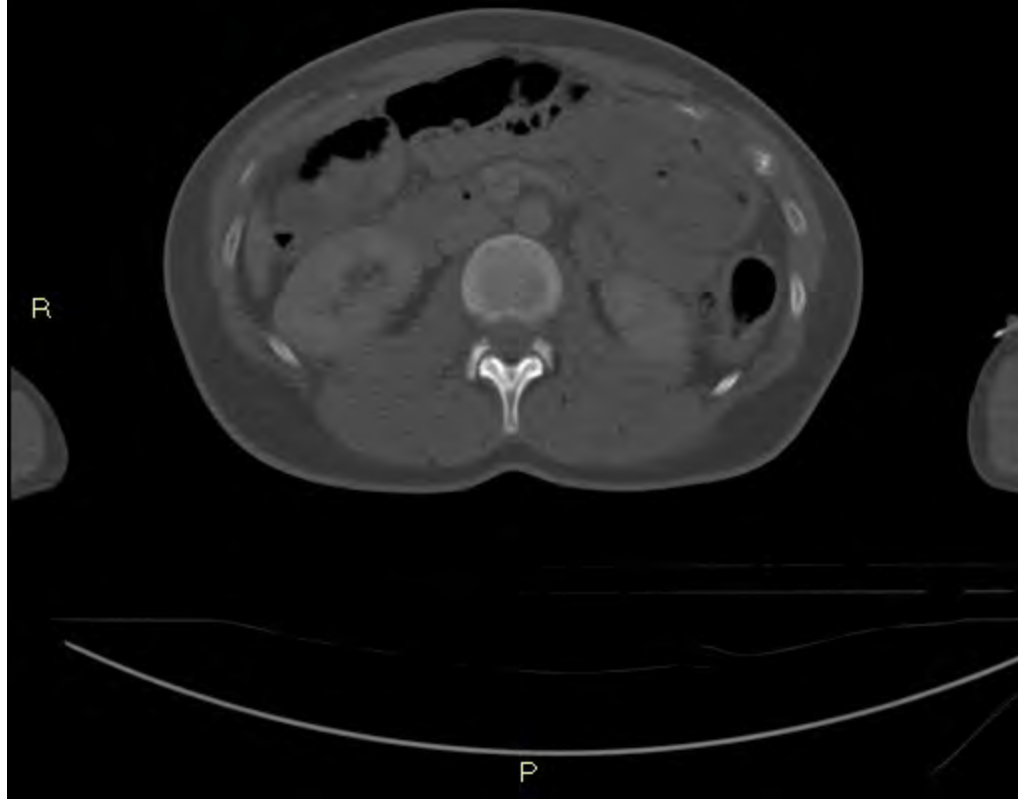
< 5 - 41 SKELETT 5/5 >



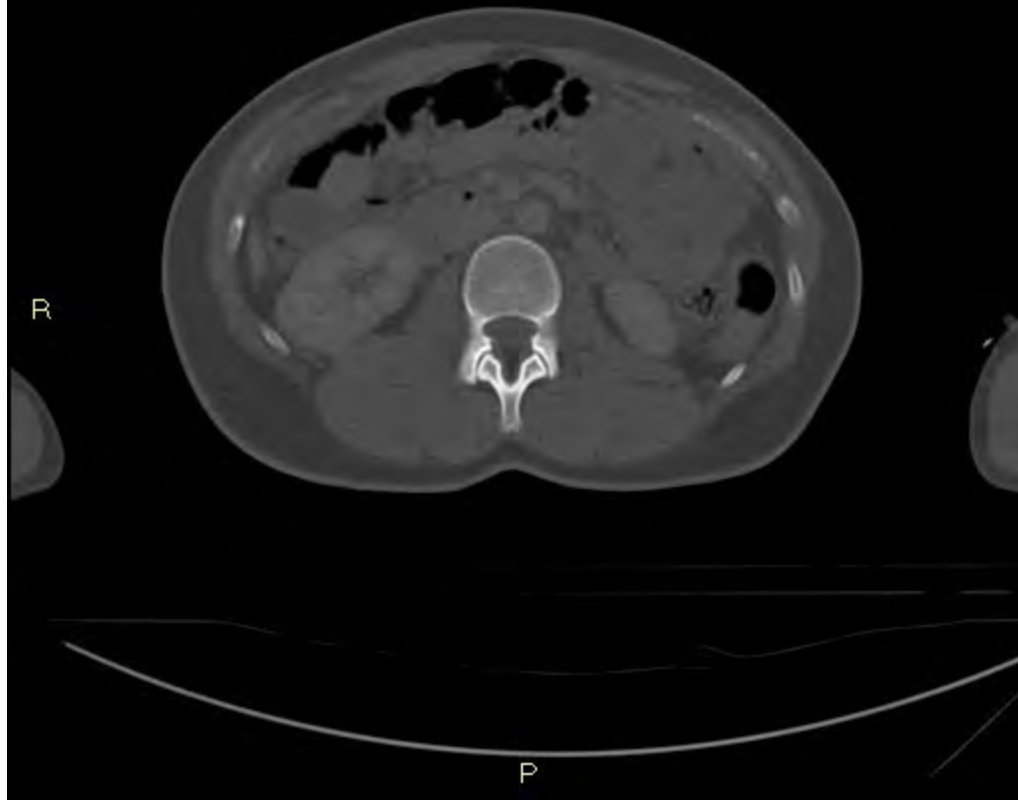< 5 - 42 SKELETT 5/5 >



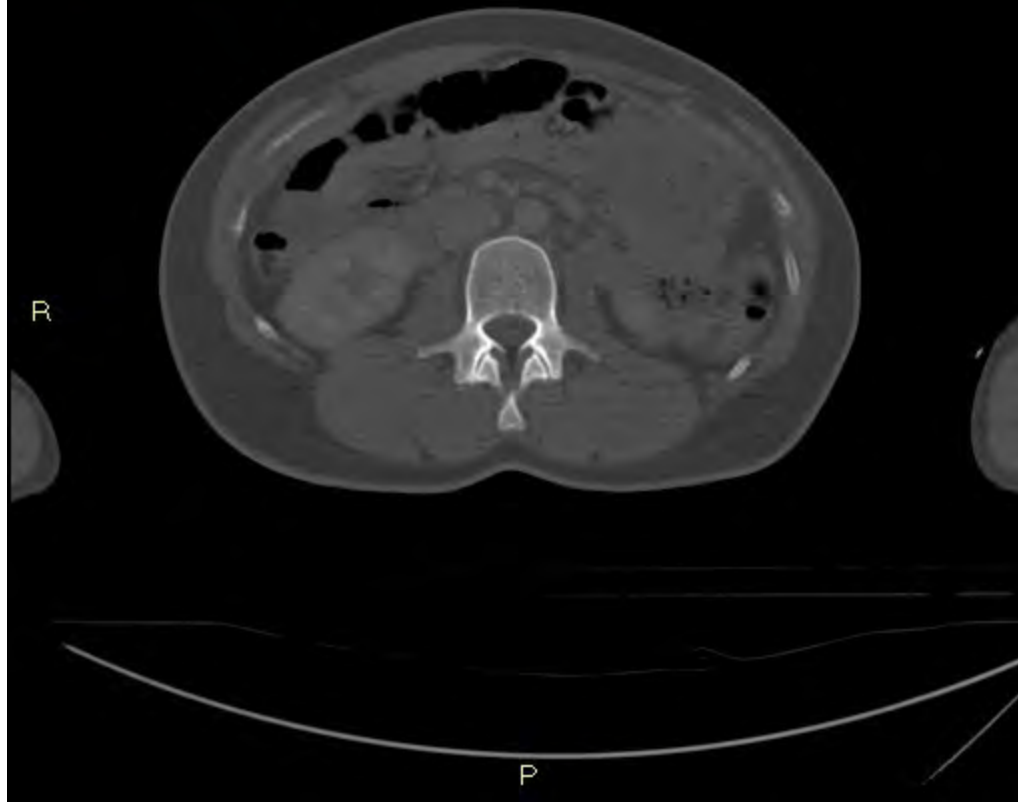< 5 - 43 SKELETT 5/5 >



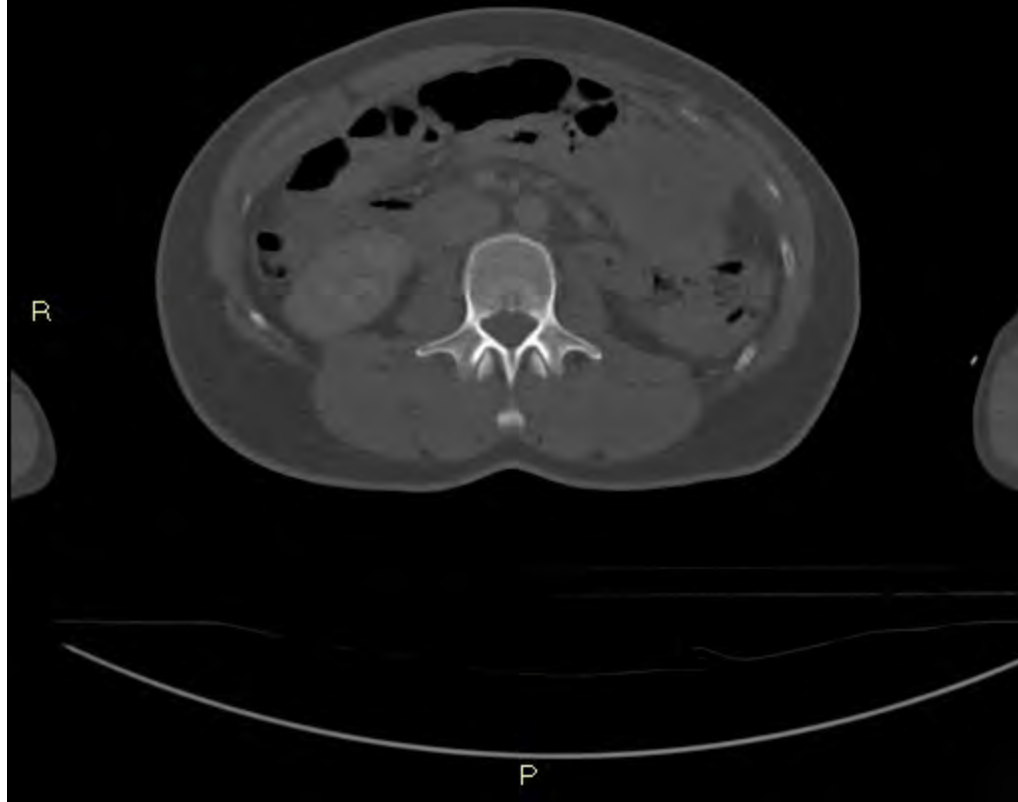< 5 - 44 SKELETT 5/5 >



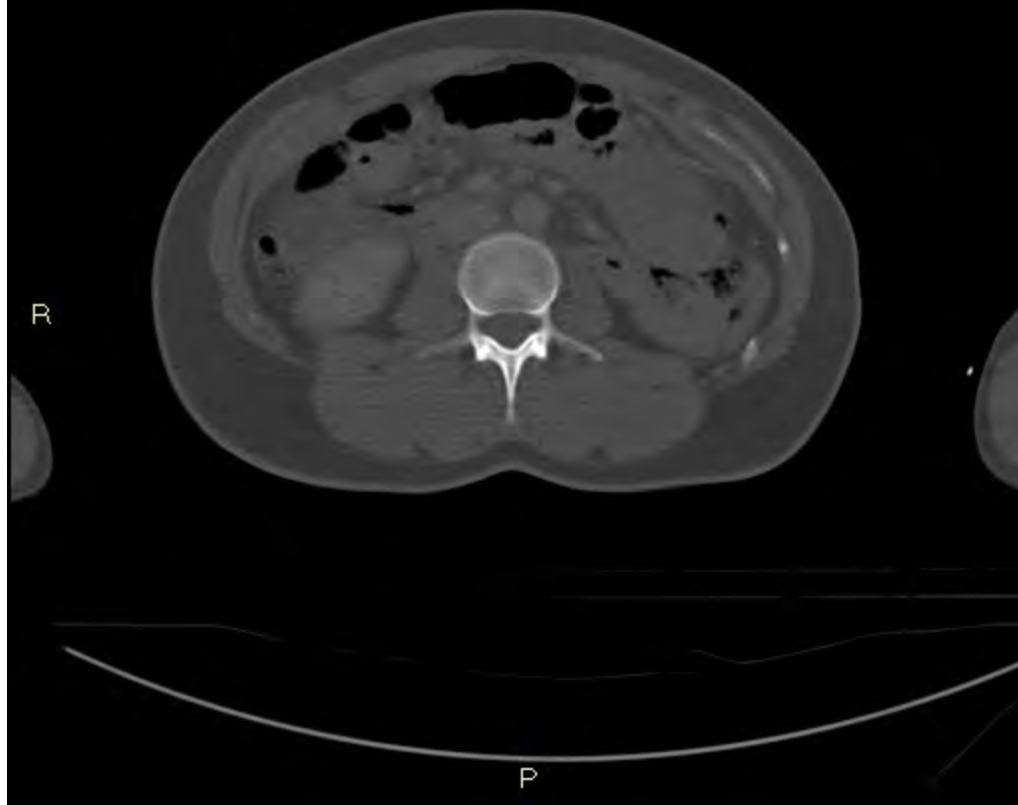< 5 - 45 SKELETT 5/5 >



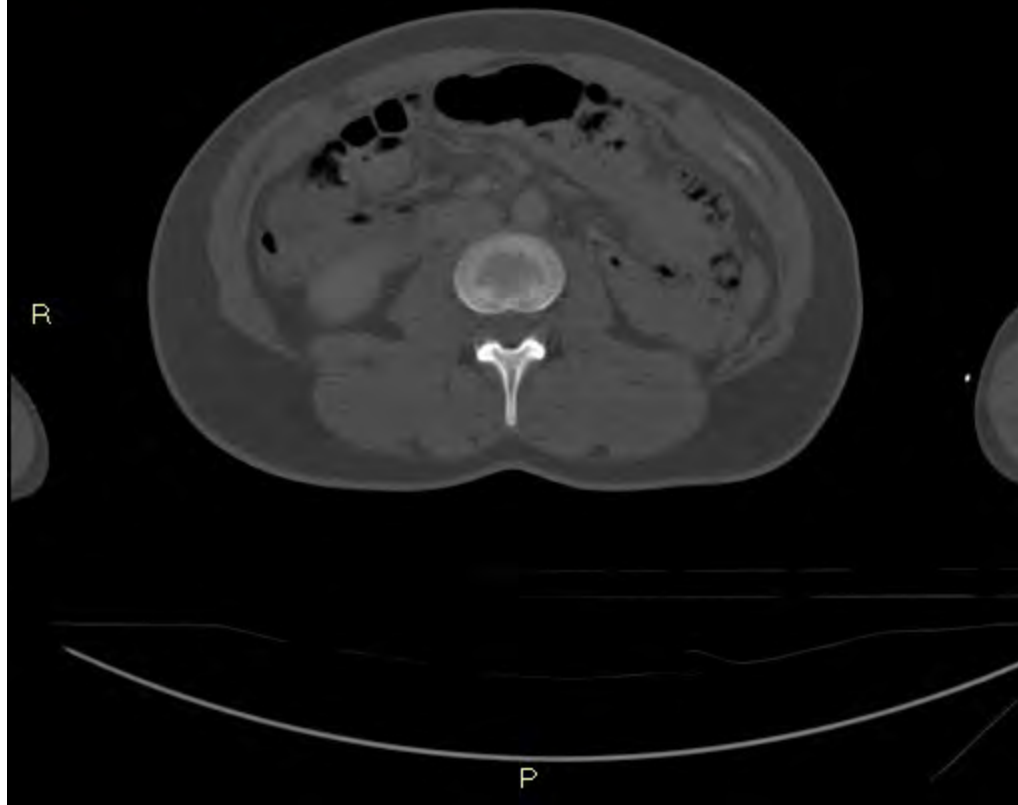< 5 - 46 SKELETT 5/5 >



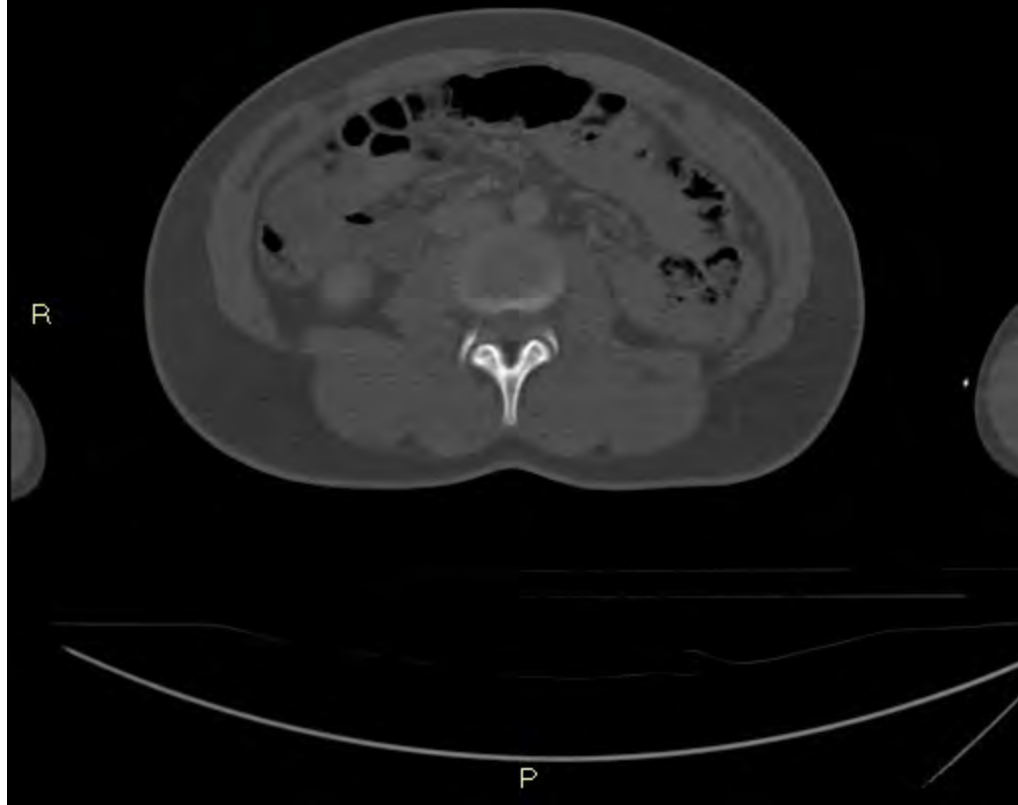
< 5 - 47 SKELETT 5/5 >



< 5 - 48 SKELETT 5/5 >



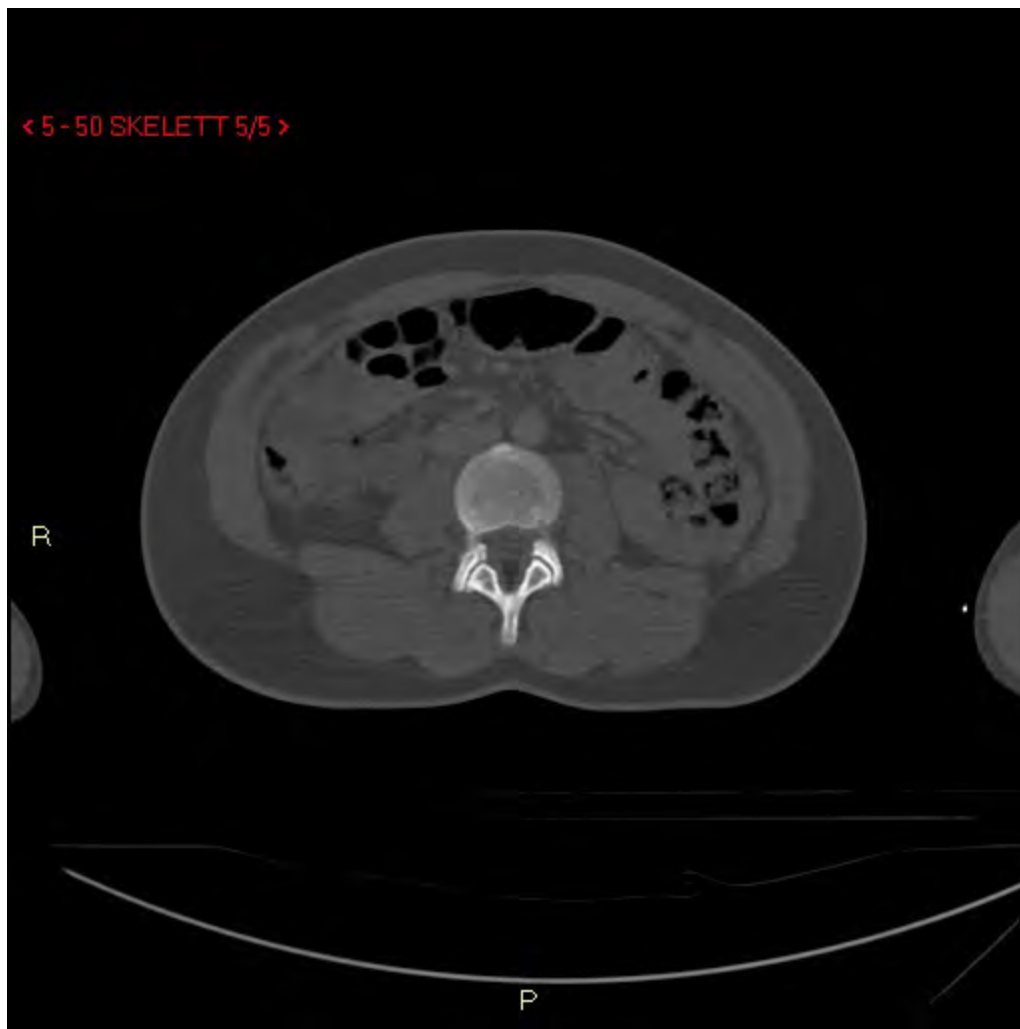
< 5 - 49 SKELETT 5/5 >



< 5 - 50 SKELETT 5/5 >

R

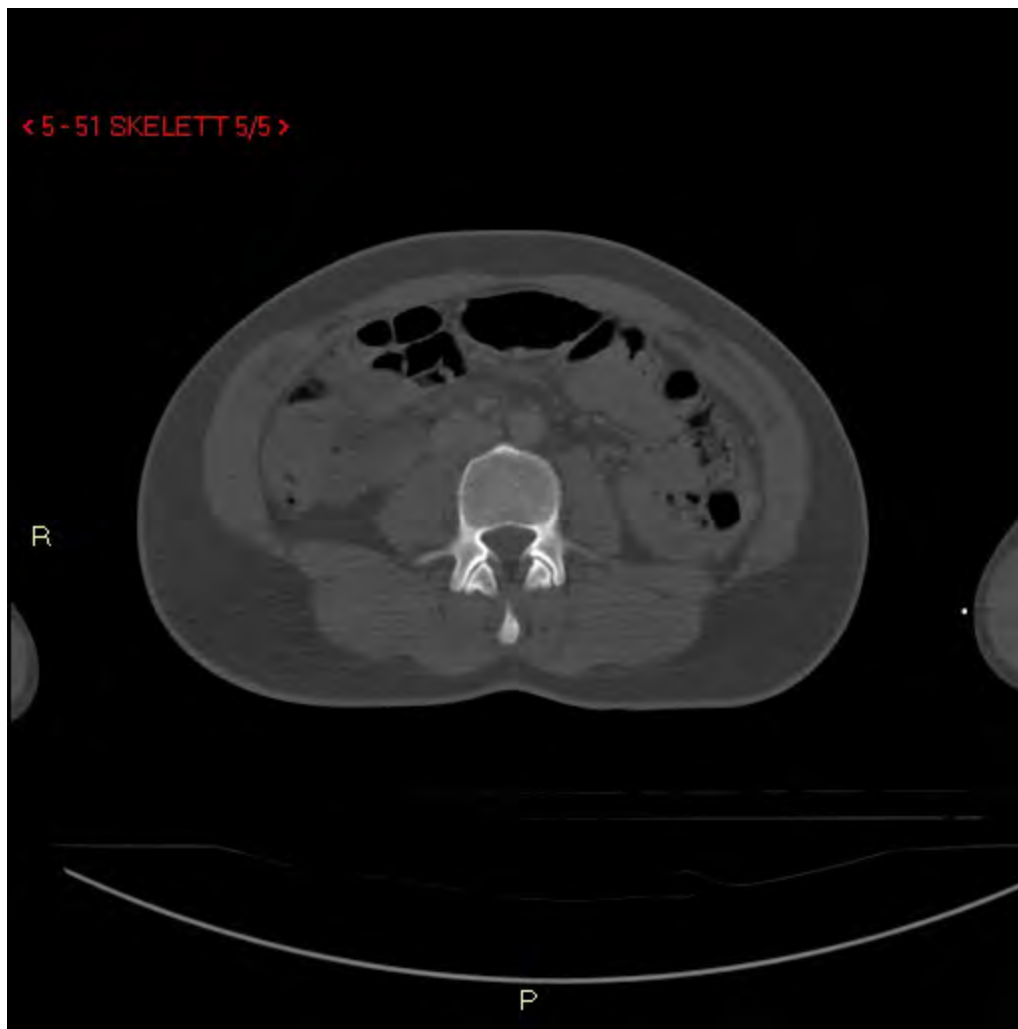
P



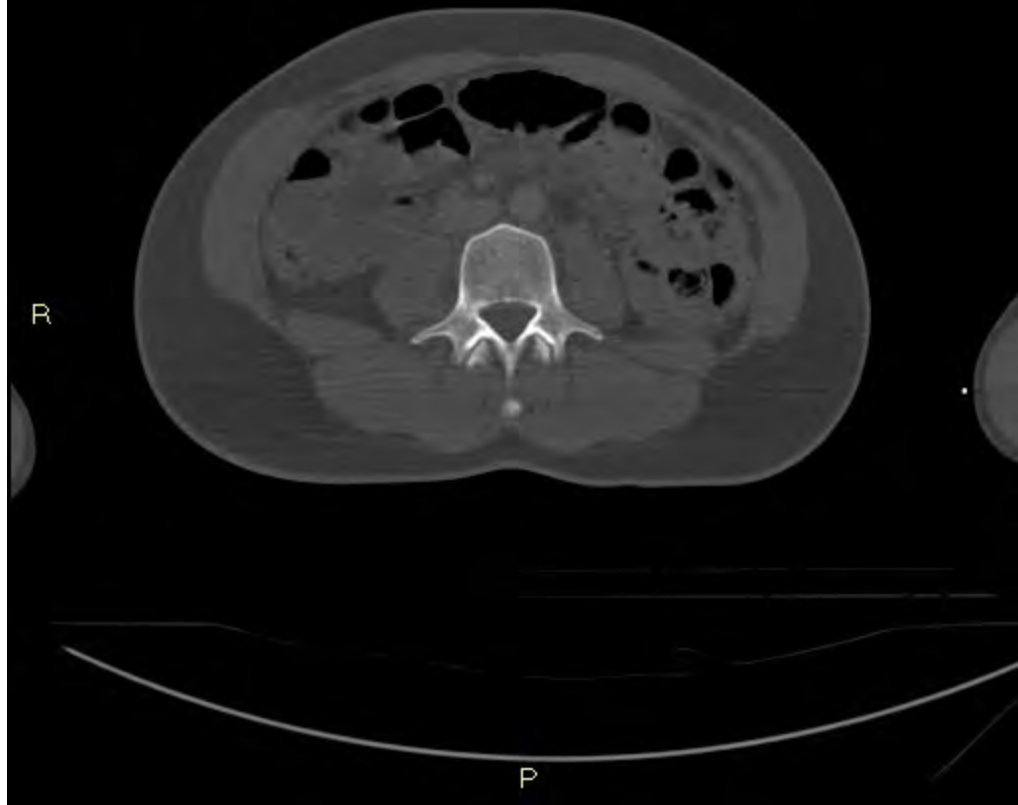< 5 - 51 SKELETT 5/5 >

R

P



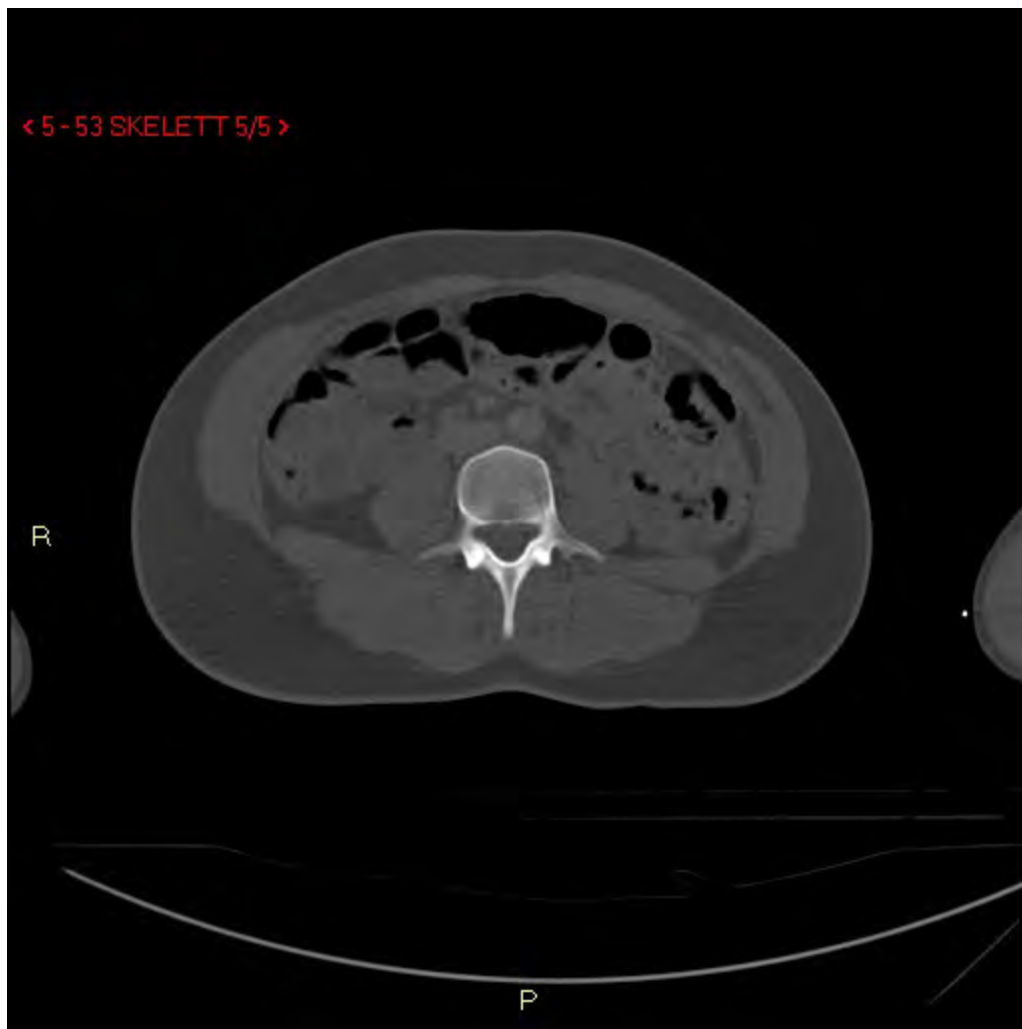
< 5 - 52 SKELETT 5/5 >



< 5 - 53 SKELETT 5/5 >

R

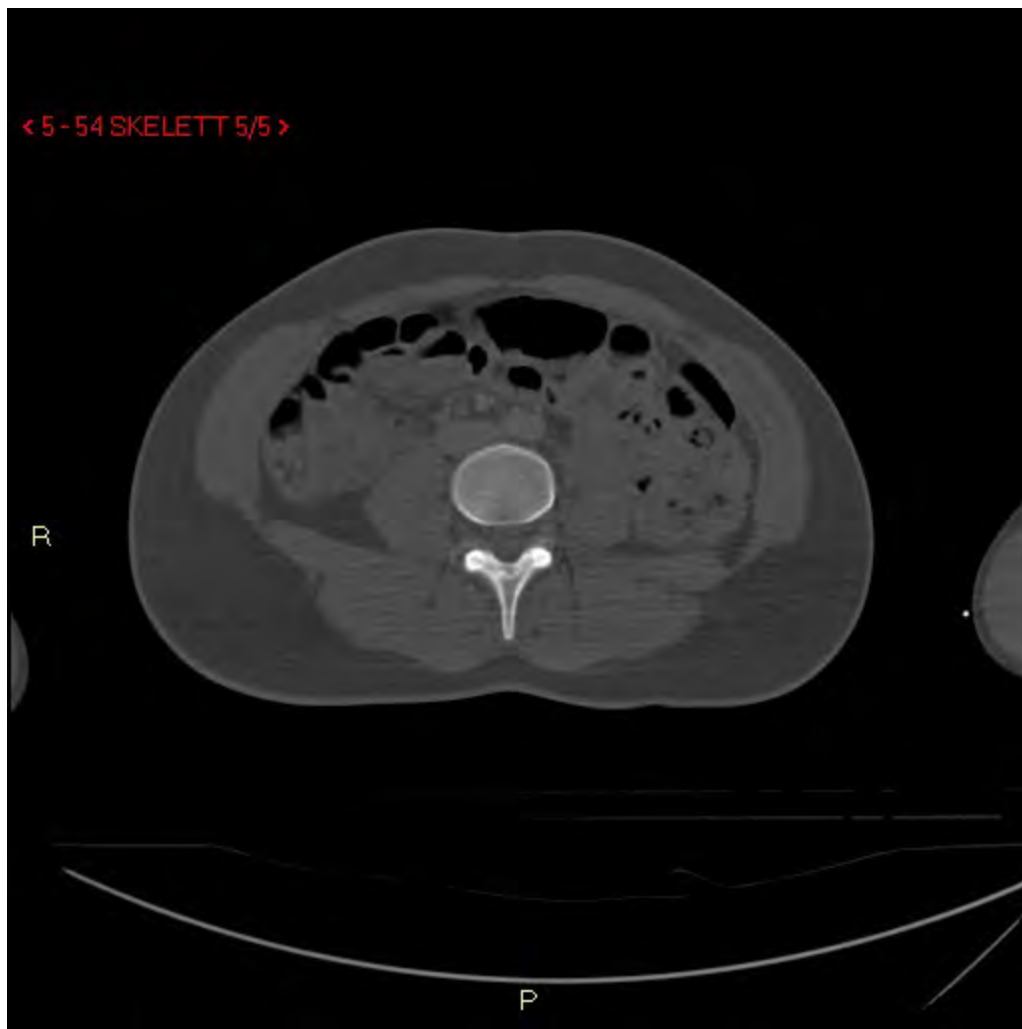
P



< 5 - 54 SKELETT 5/5 >

R

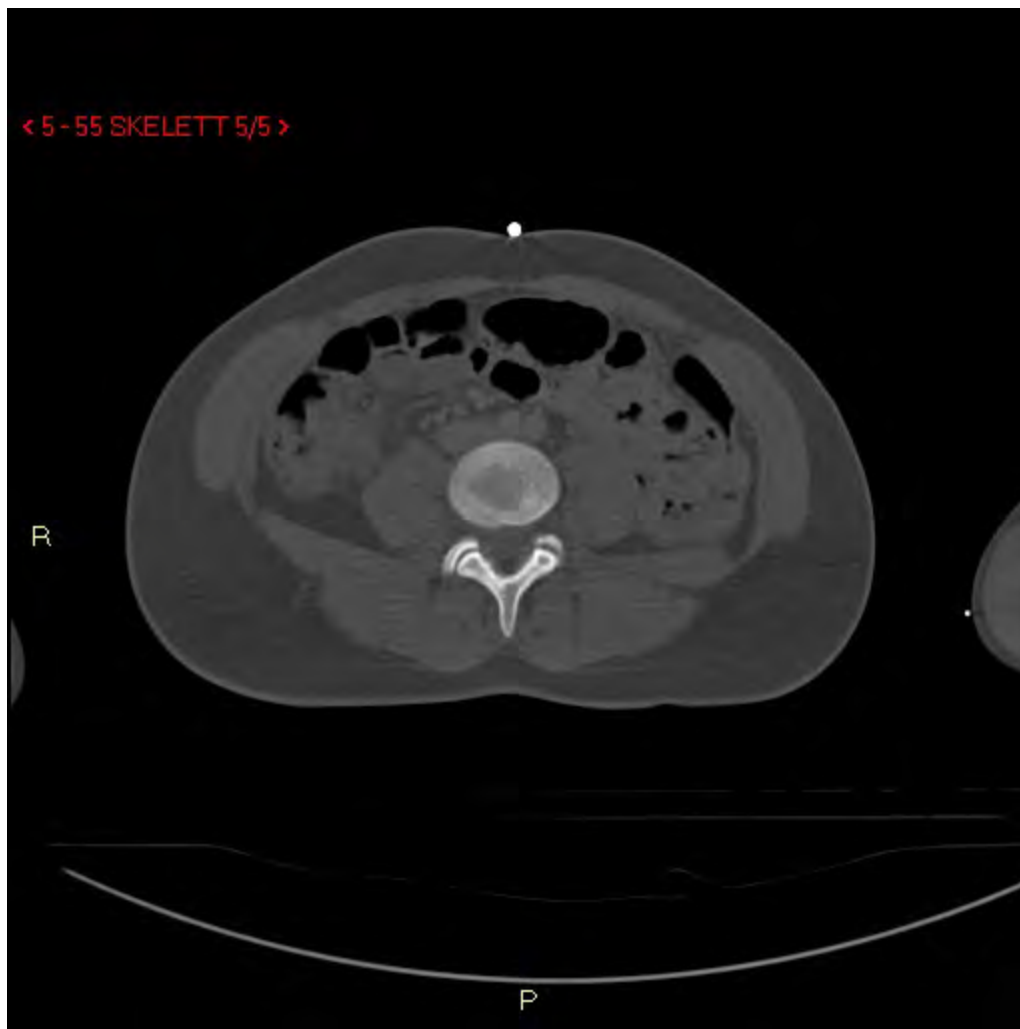
P



< 5 - 55 SKELETT 5/5 >

R

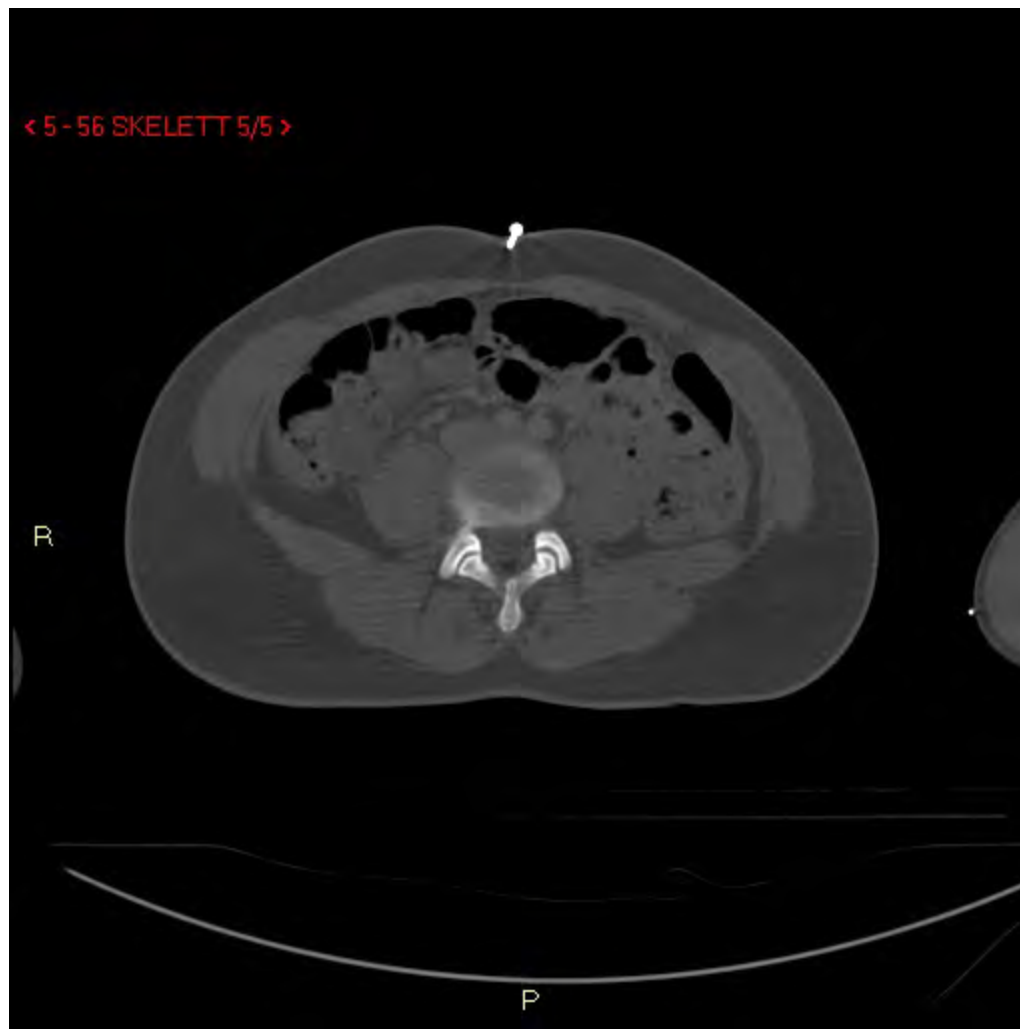
P



< 5 - 56 SKELETT 5/5 >

R

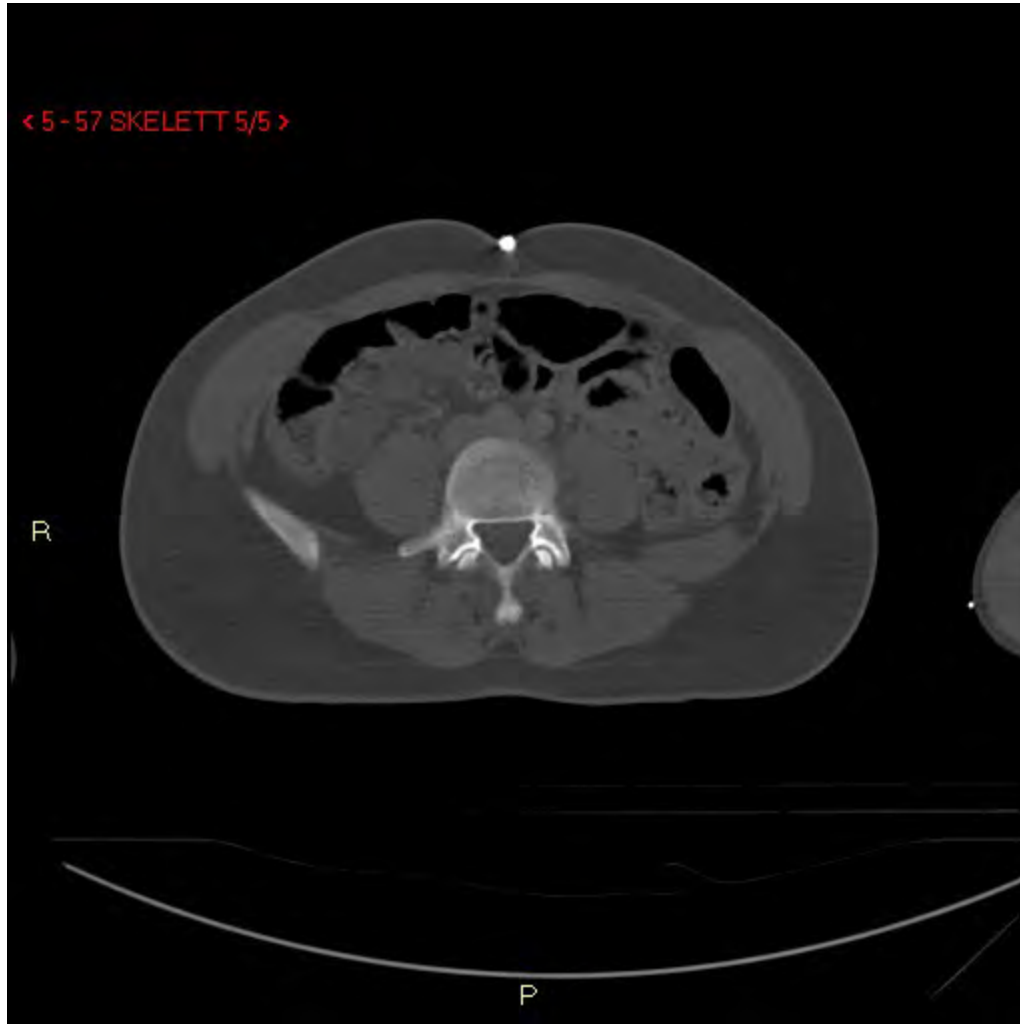
P



< 5 - 57 SKELETT 5/5 >

R

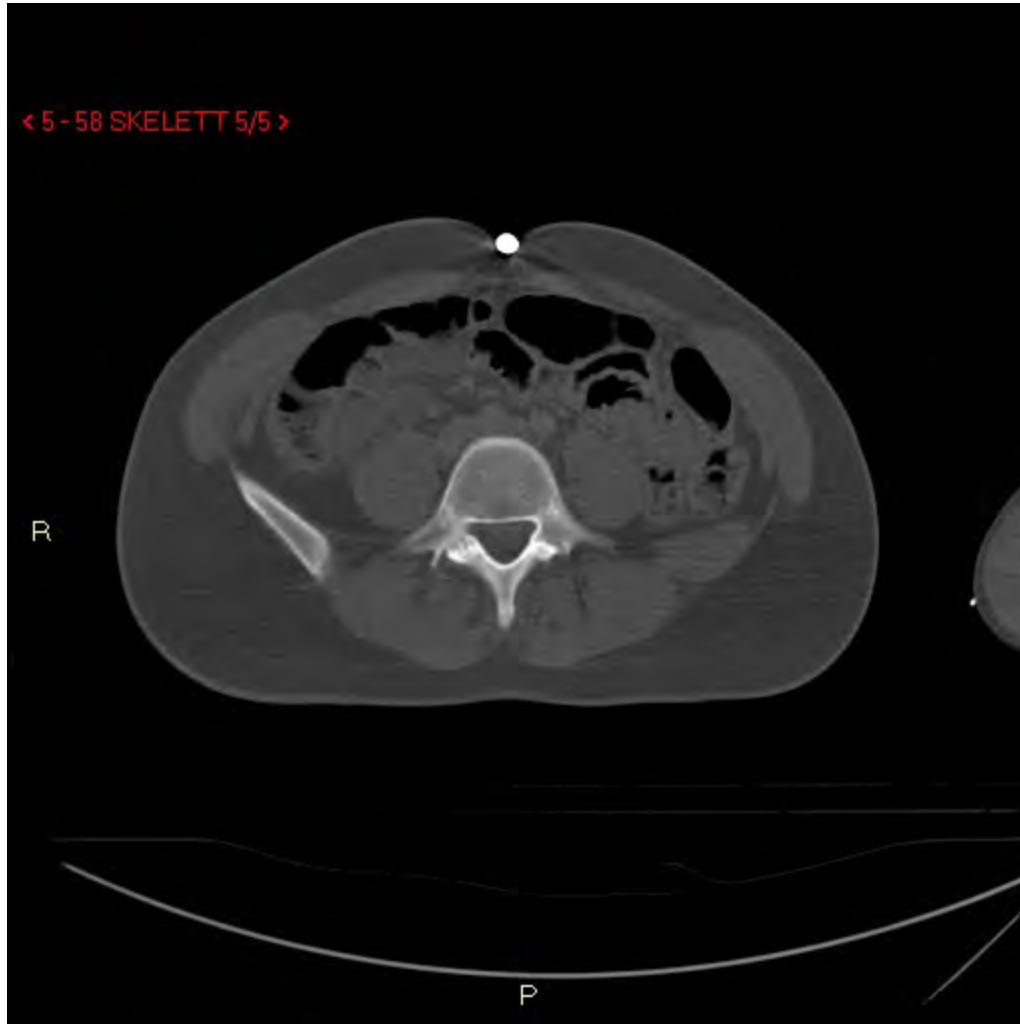
P



< 5 - 58 SKELETT 5/5 >

R

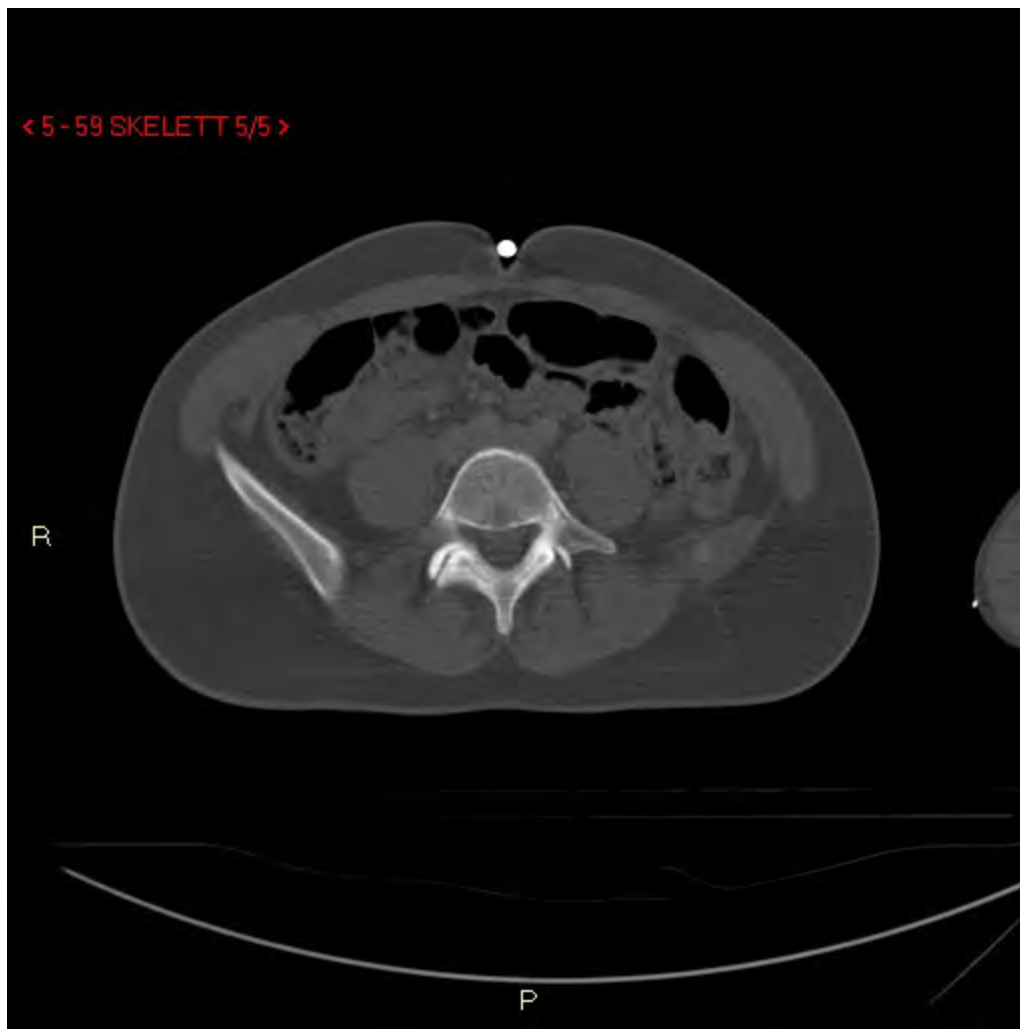
P



< 5 - 59 SKELETT 5/5 >

R

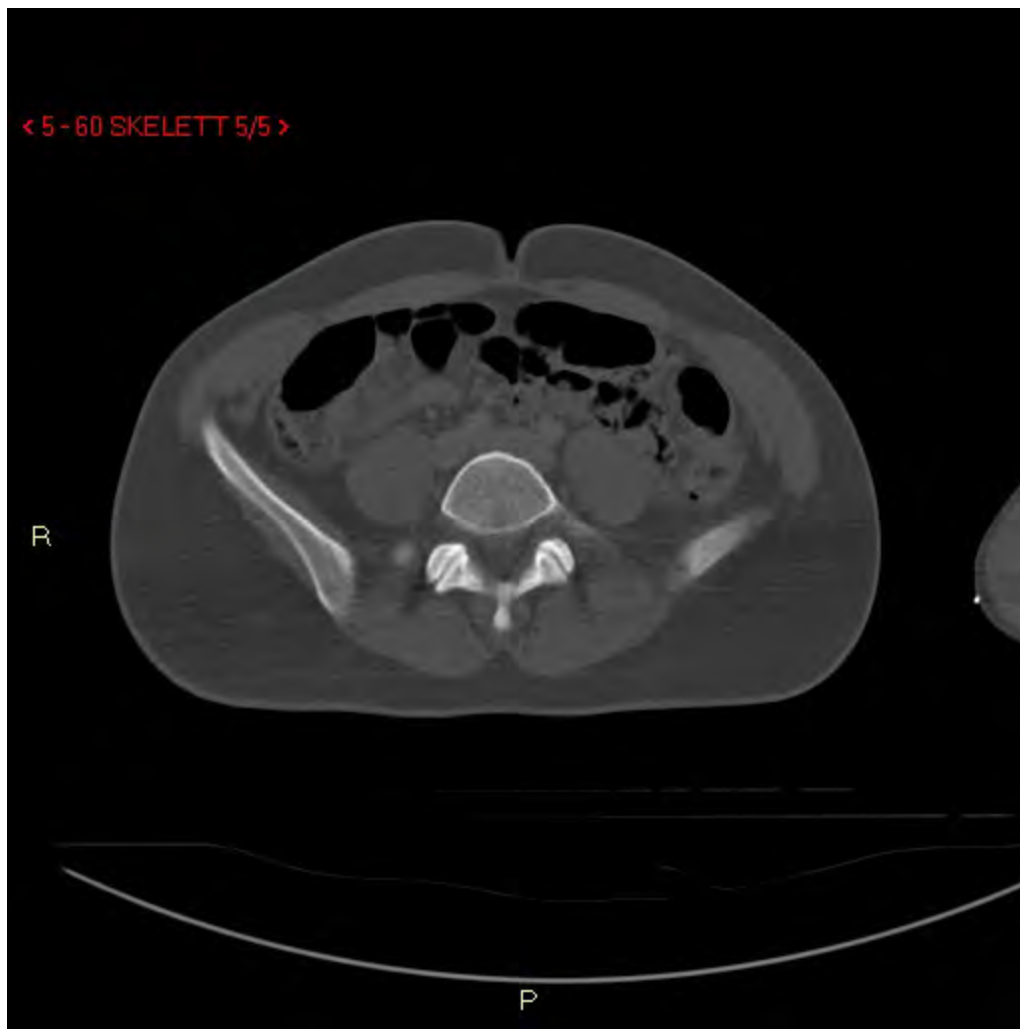
P



< 5 - 60 SKELETT 5/5 >

R

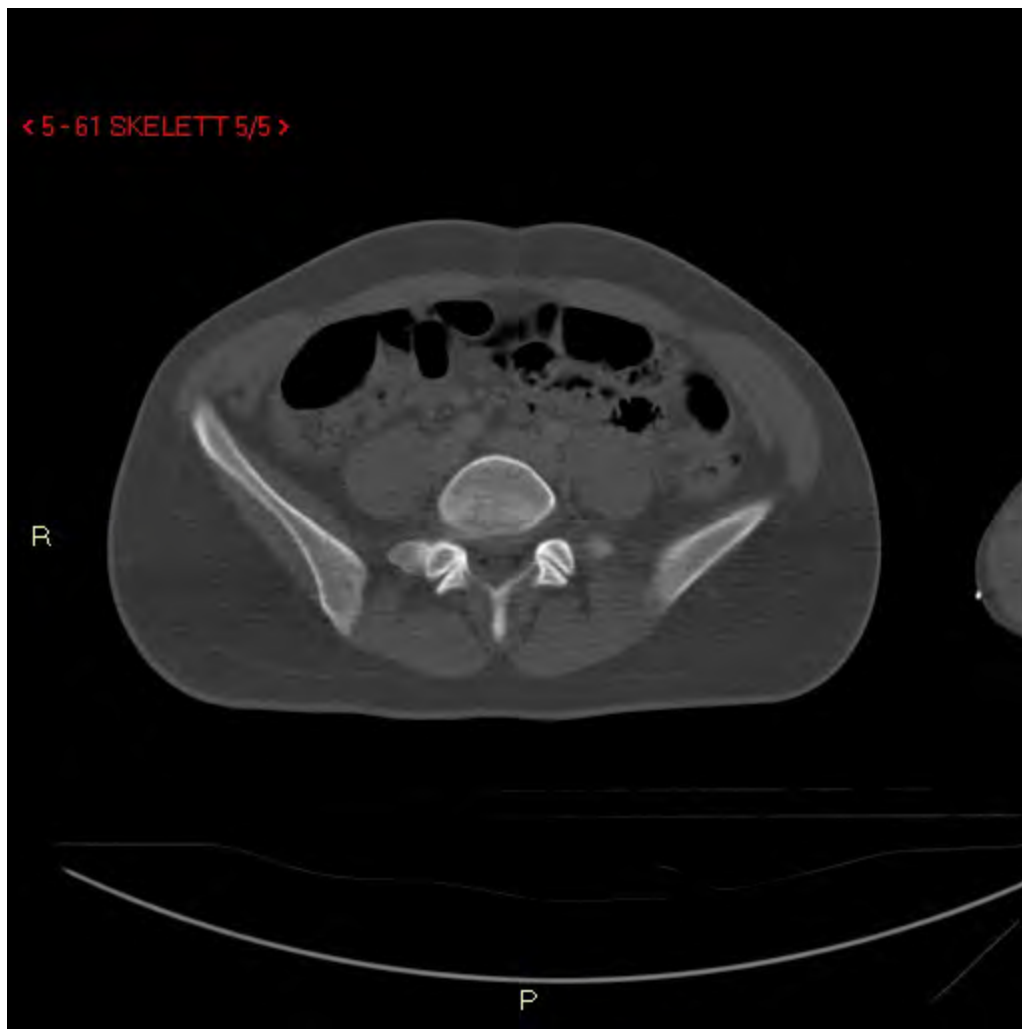
P



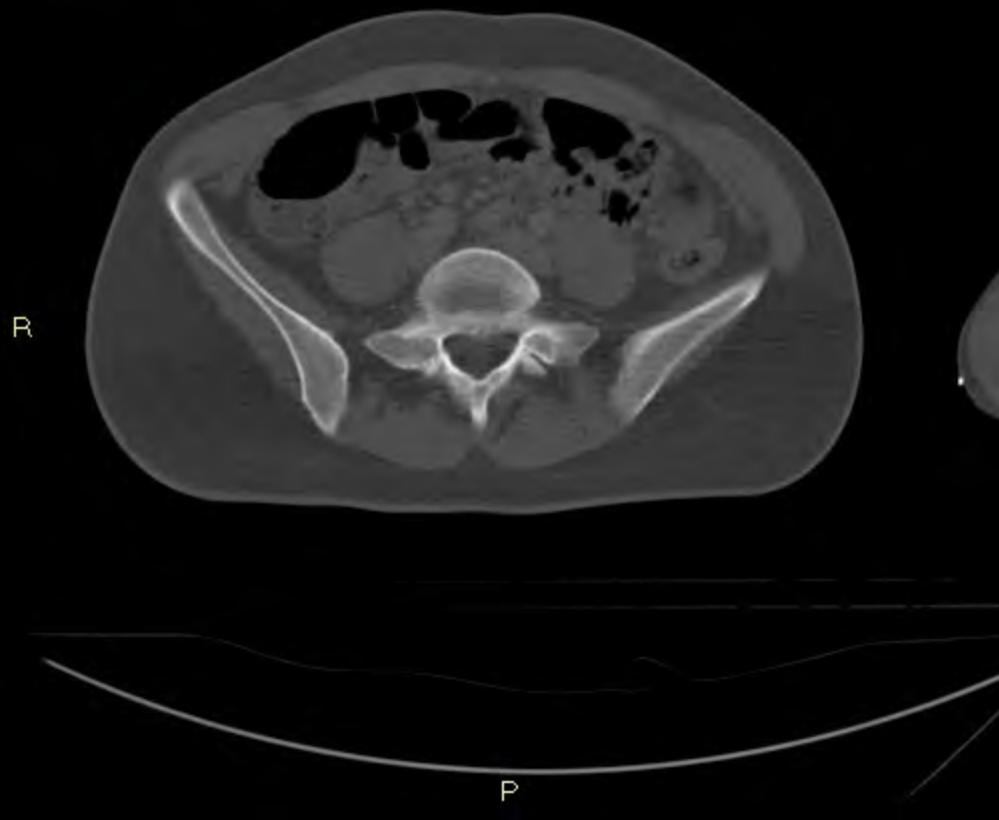< 5 - 61 SKELETT 5/5 >

R

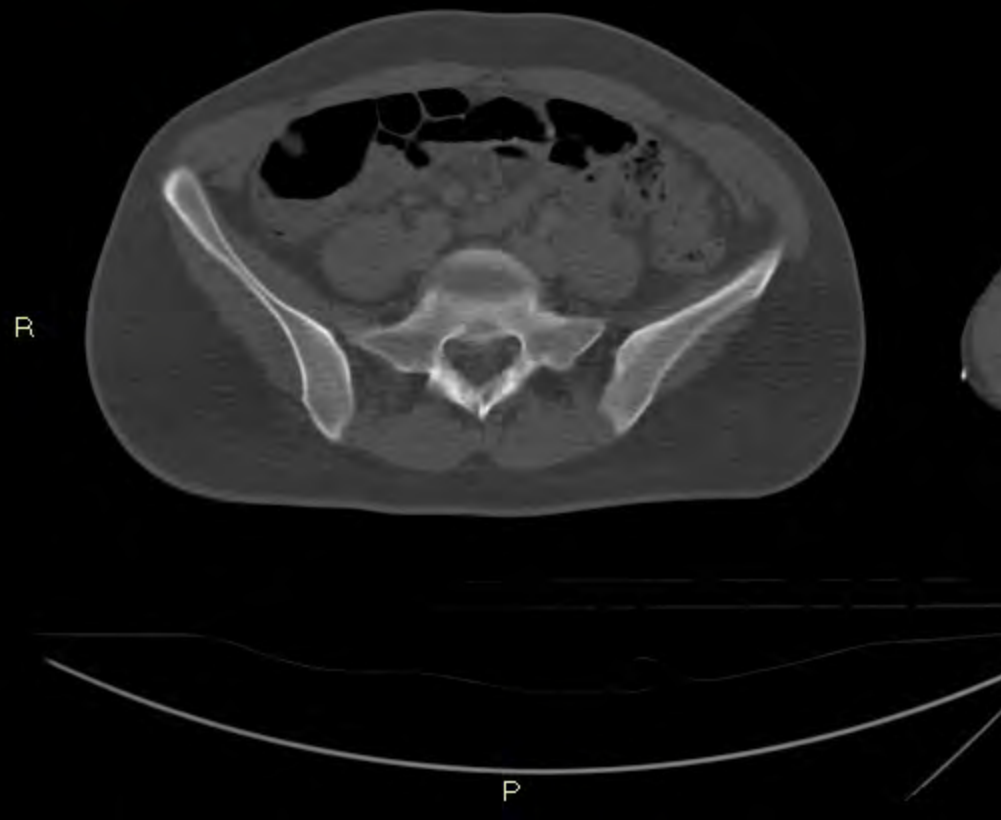P



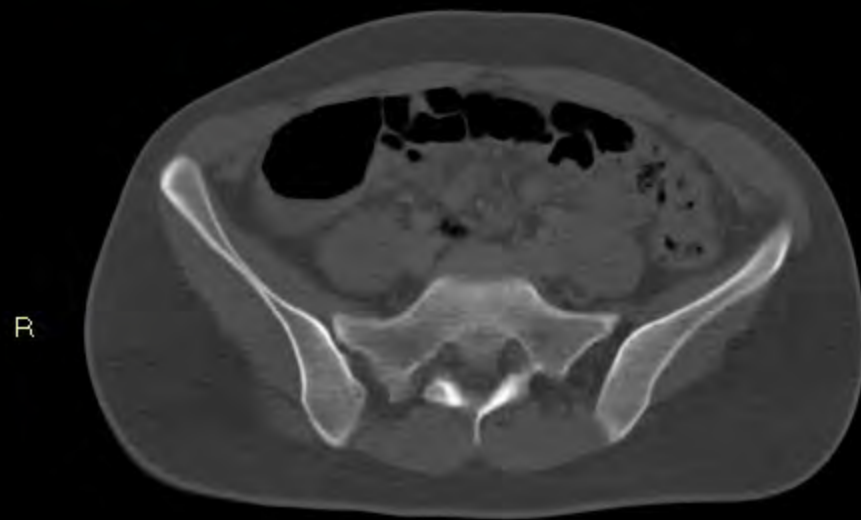
< 5 - 62 SKELETT 5/5 >



< 5 - 63 SKELETT 5/5 >



< 5 - 64 SKELETT 5/5 >



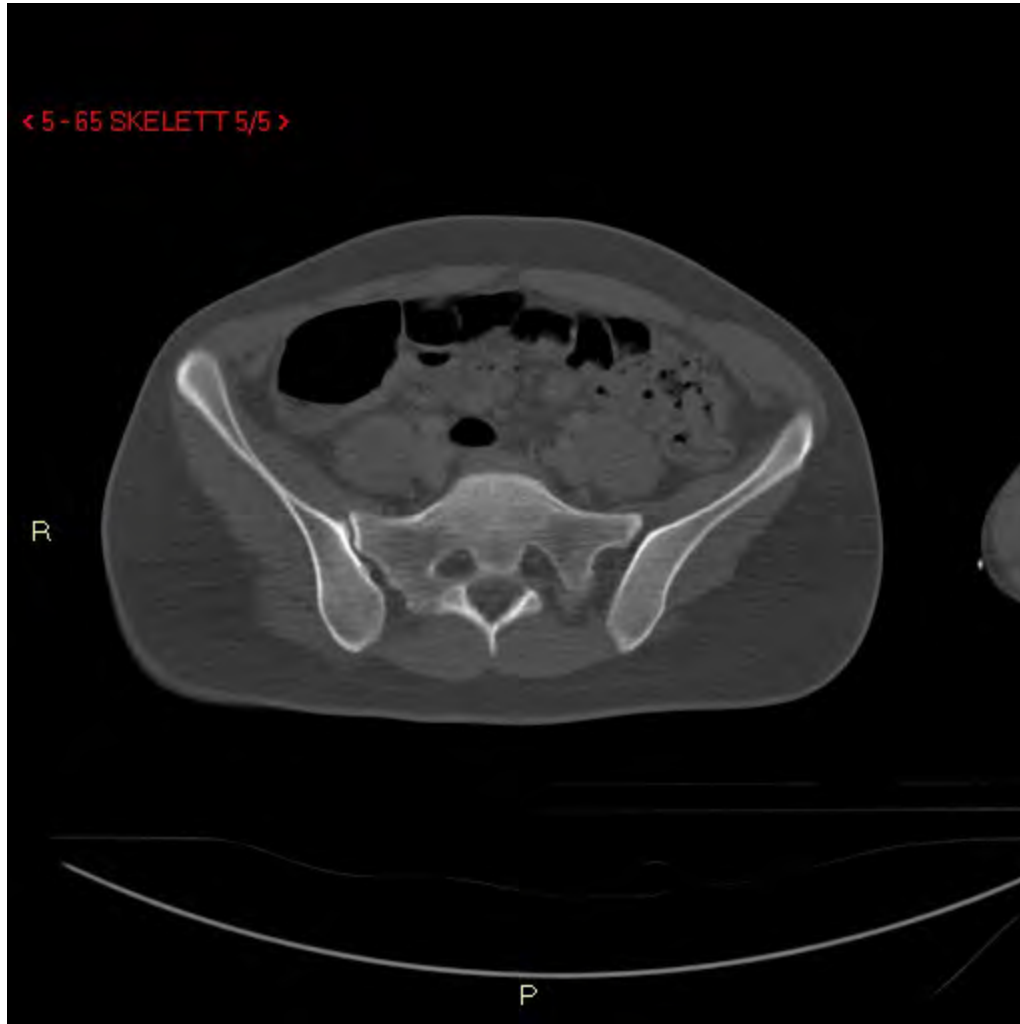
R

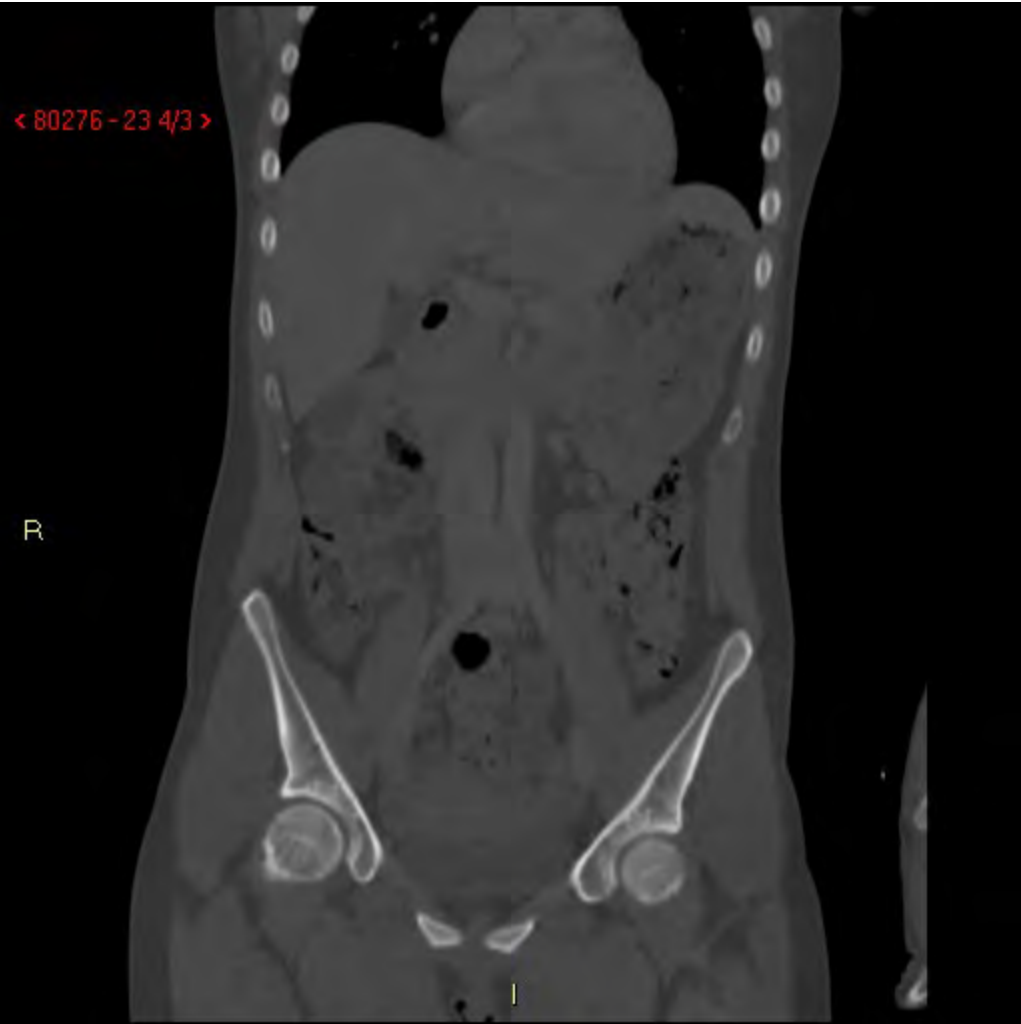P

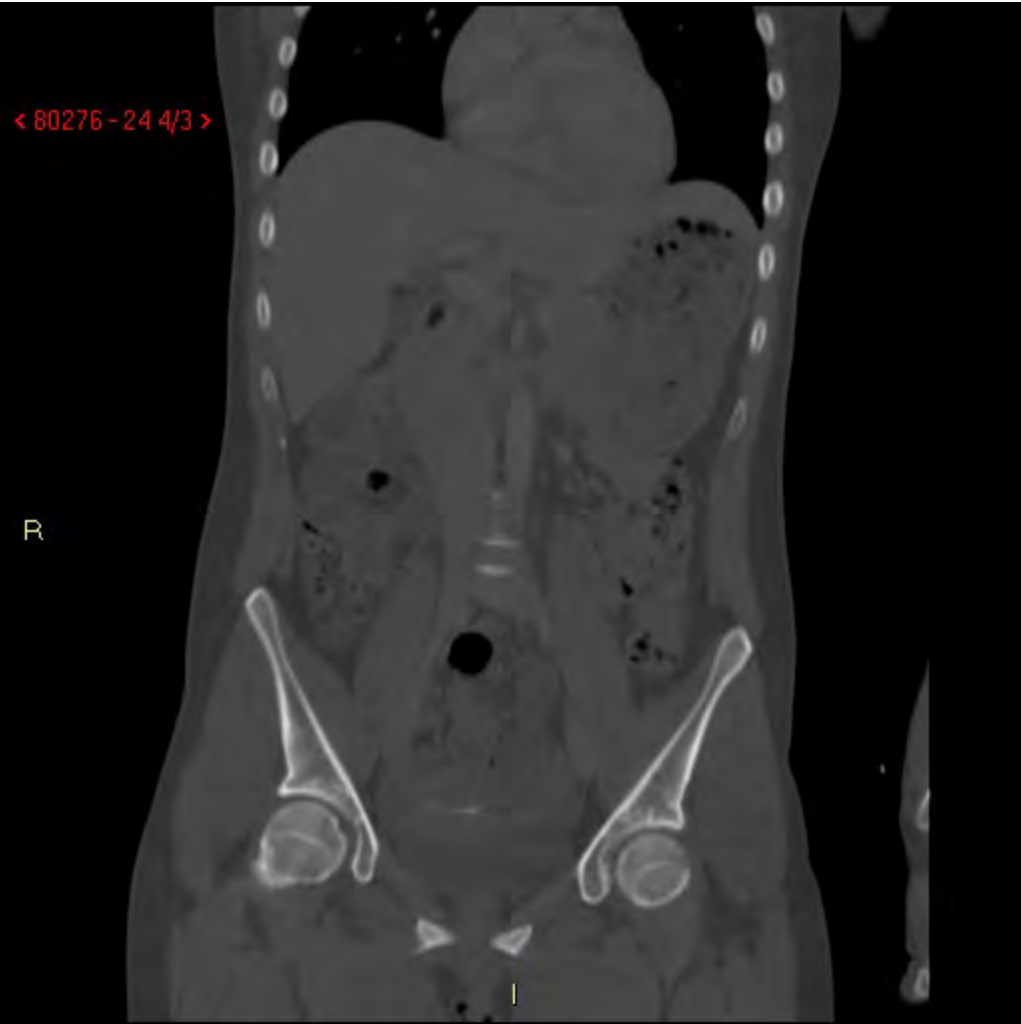
< 5 - 65 SKELETT 5/5 >

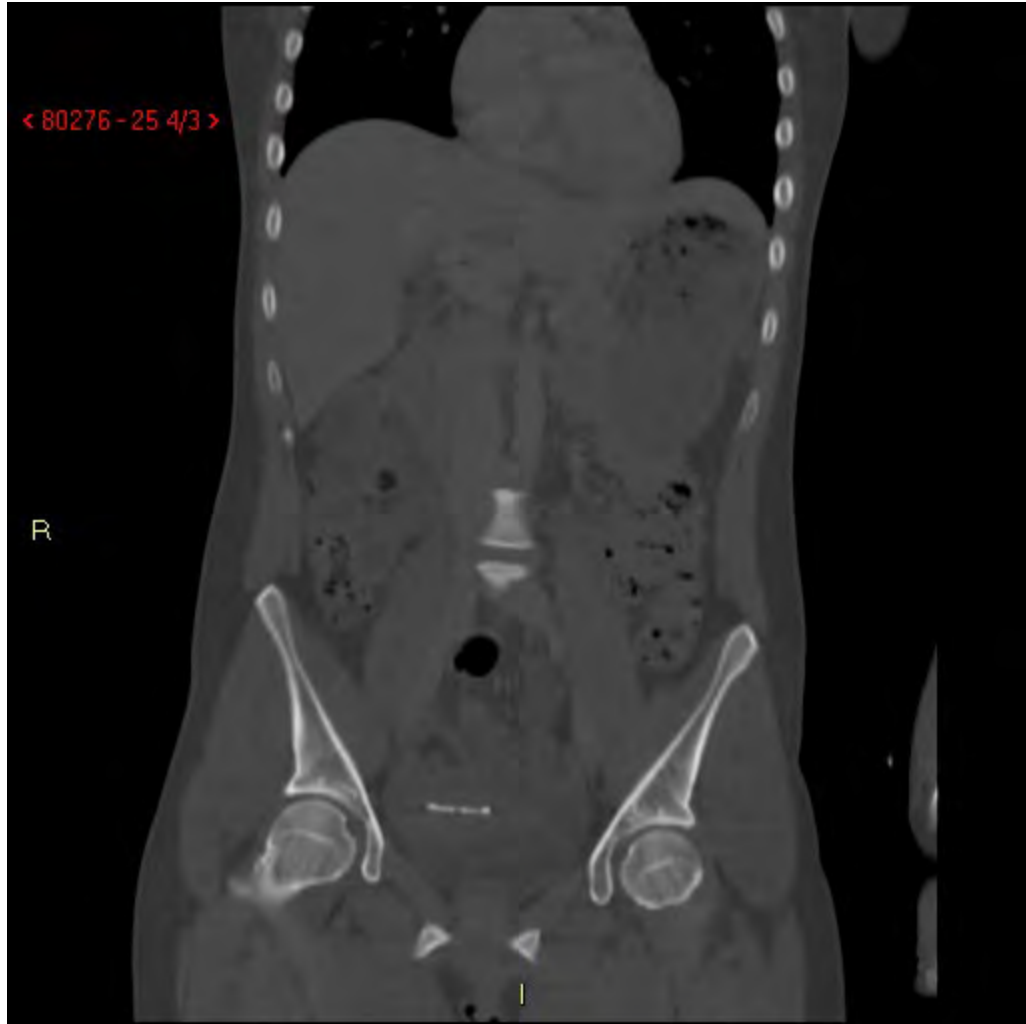R

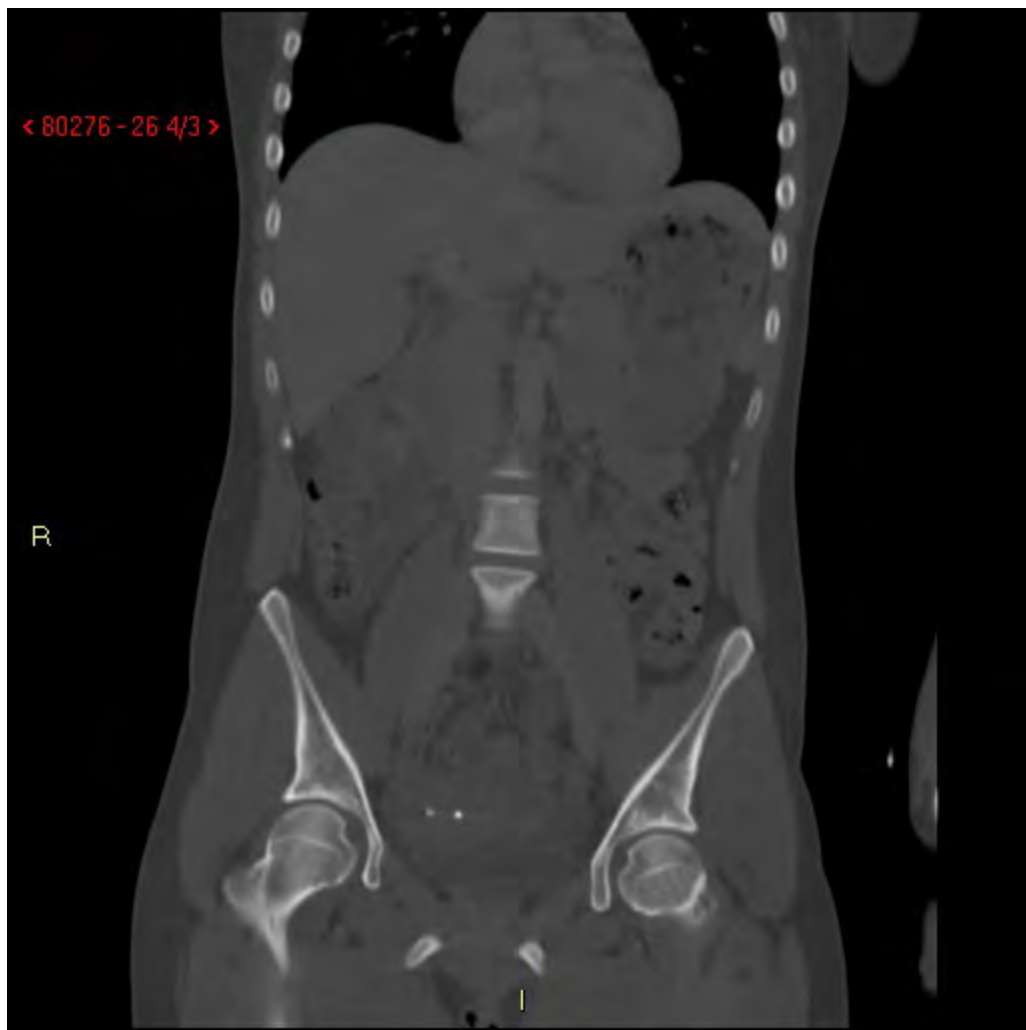P

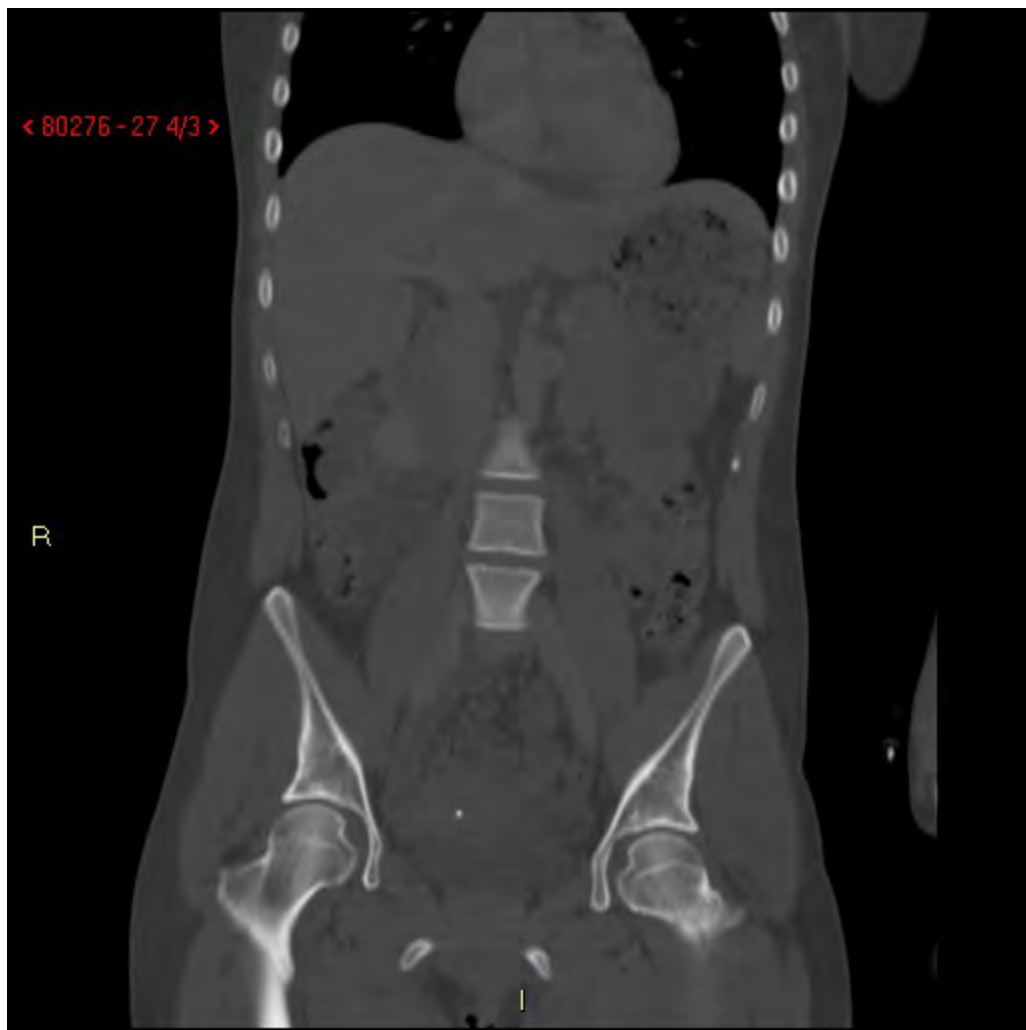


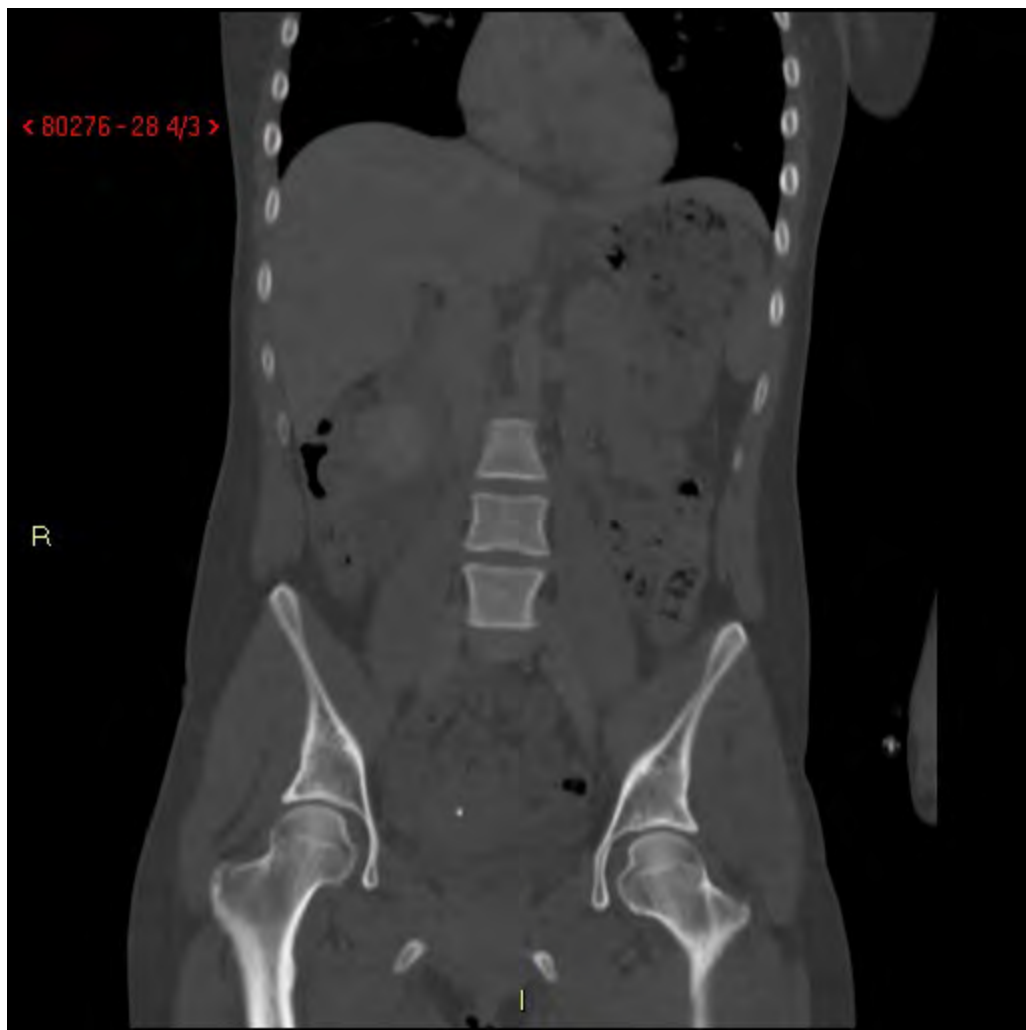


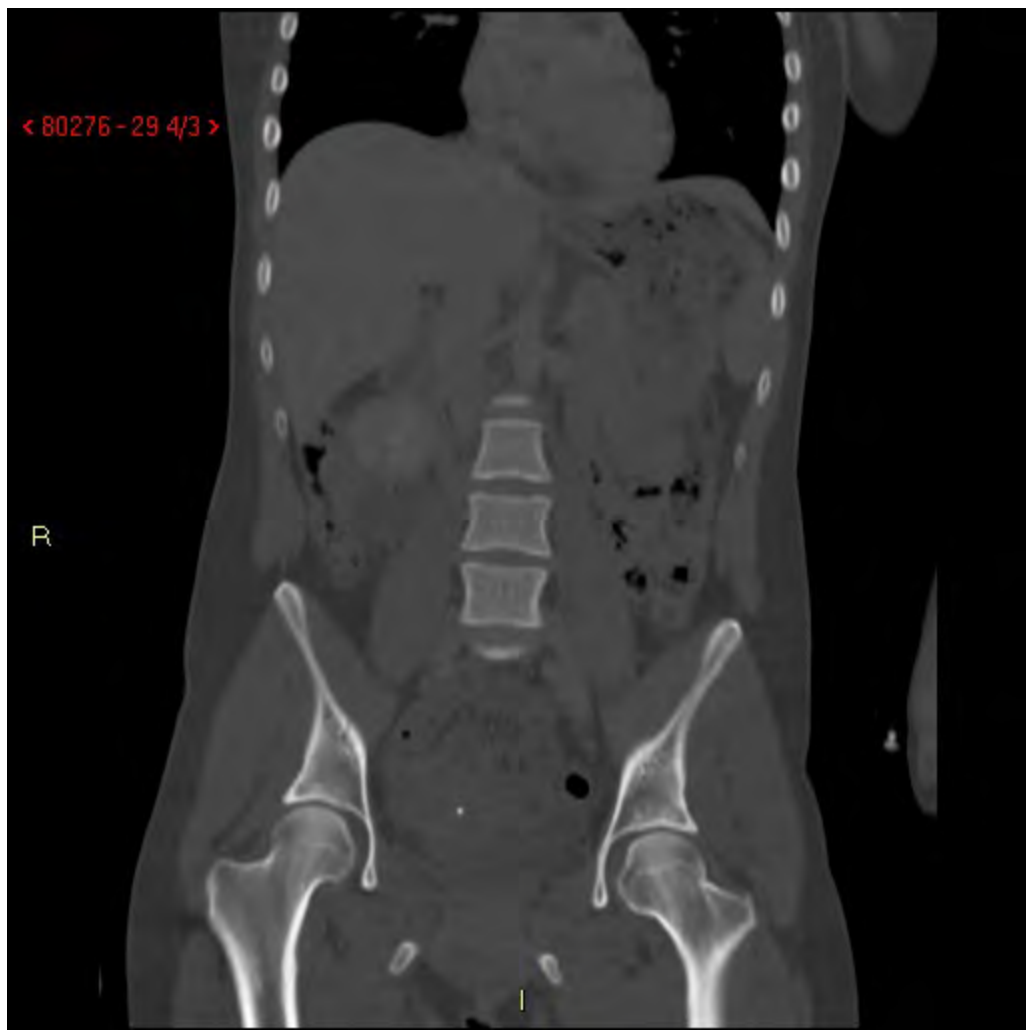


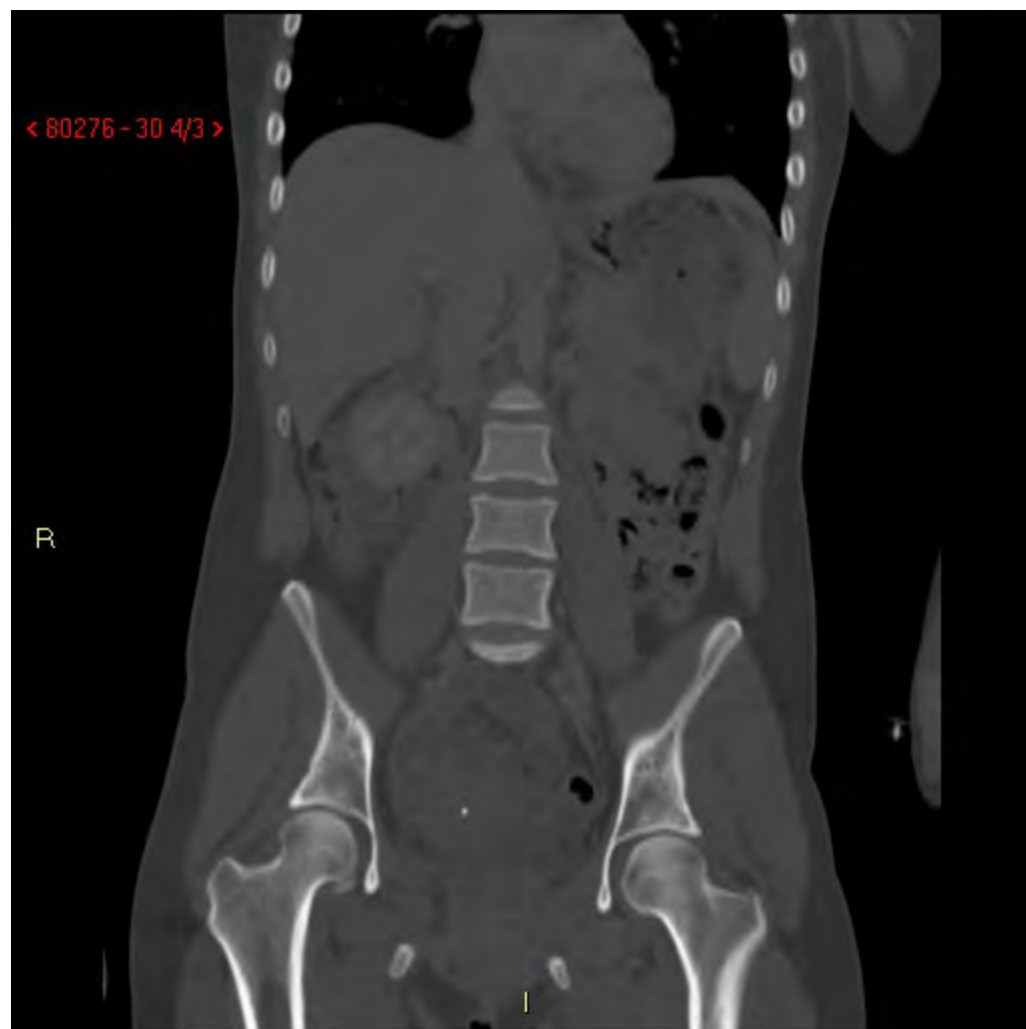


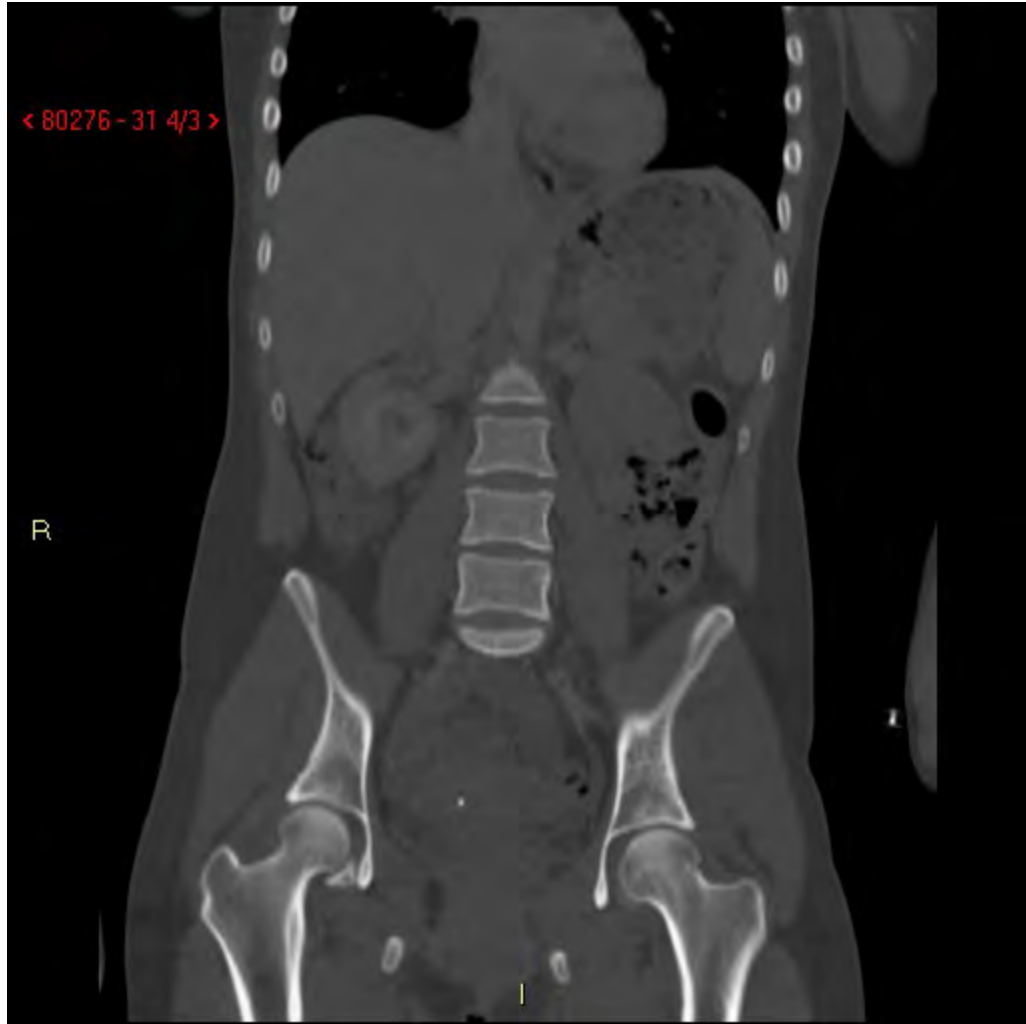


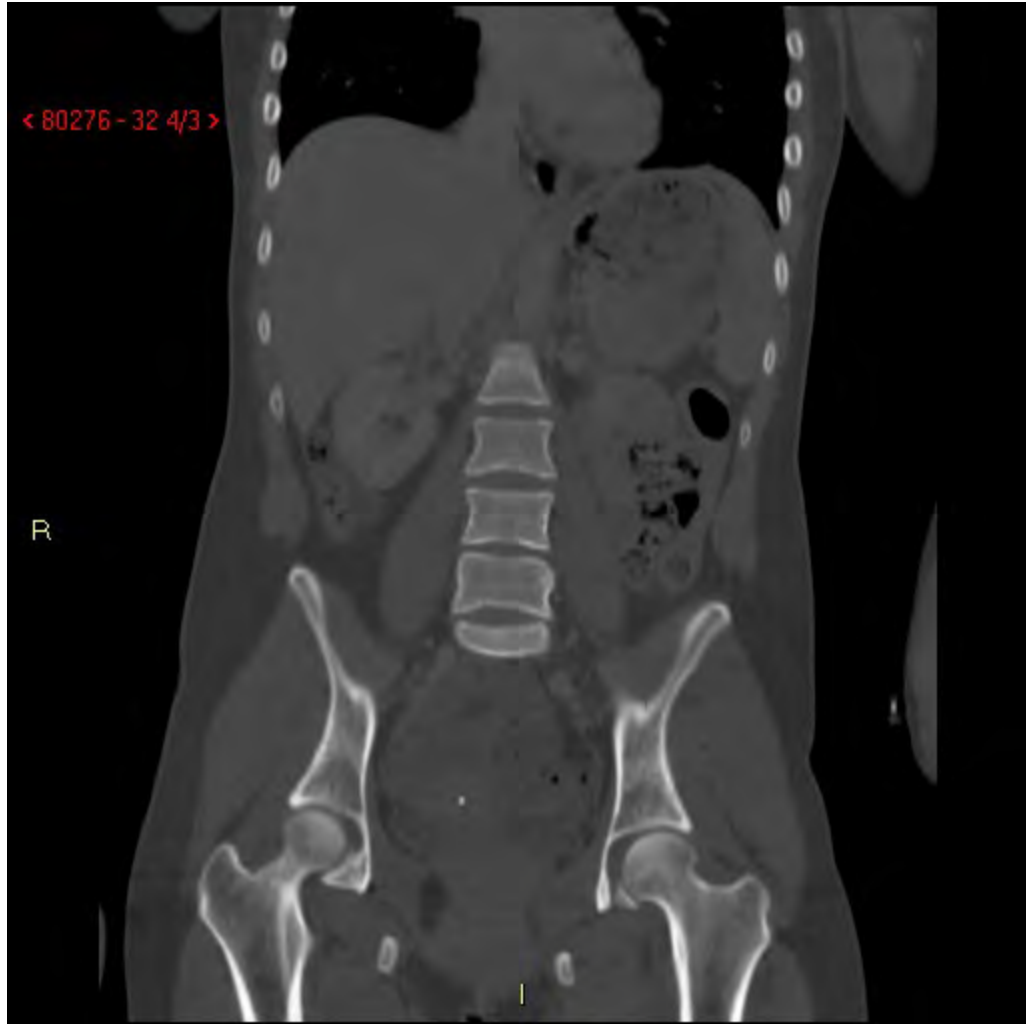


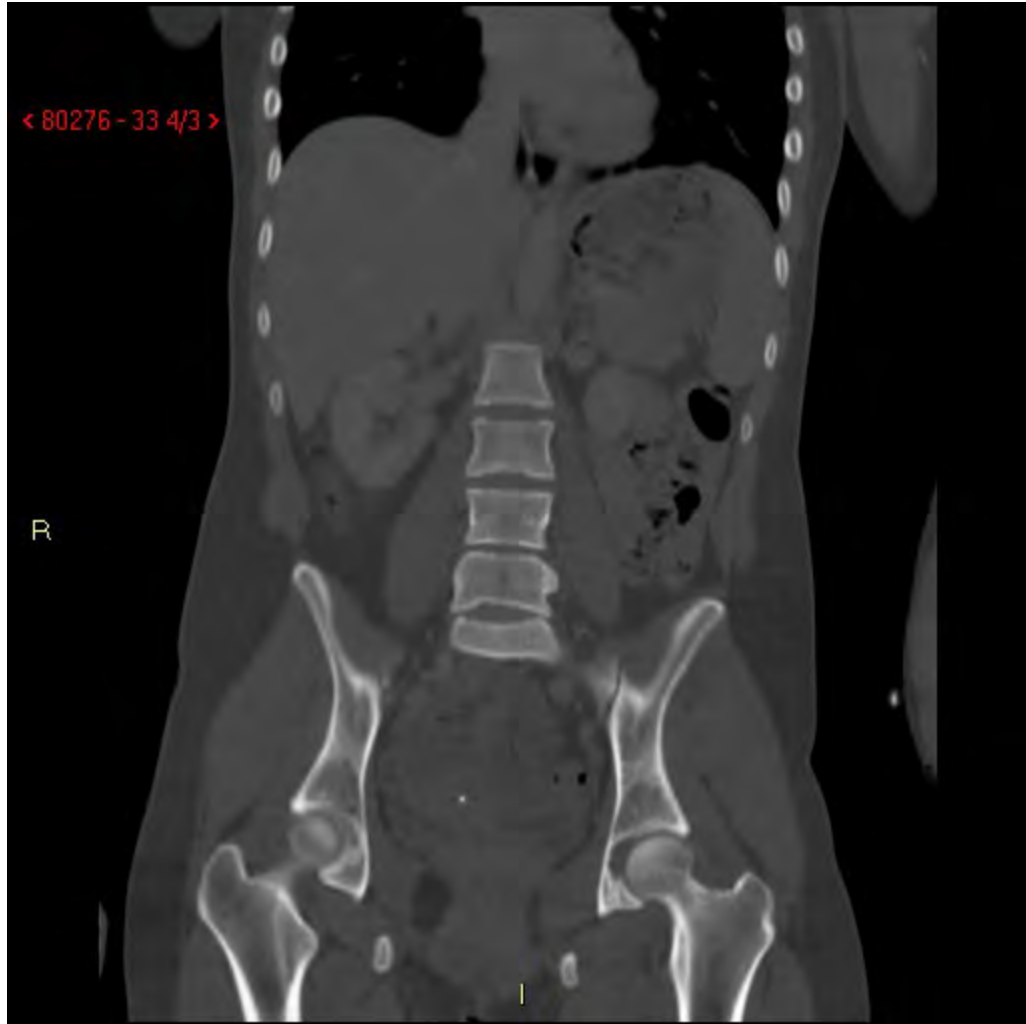


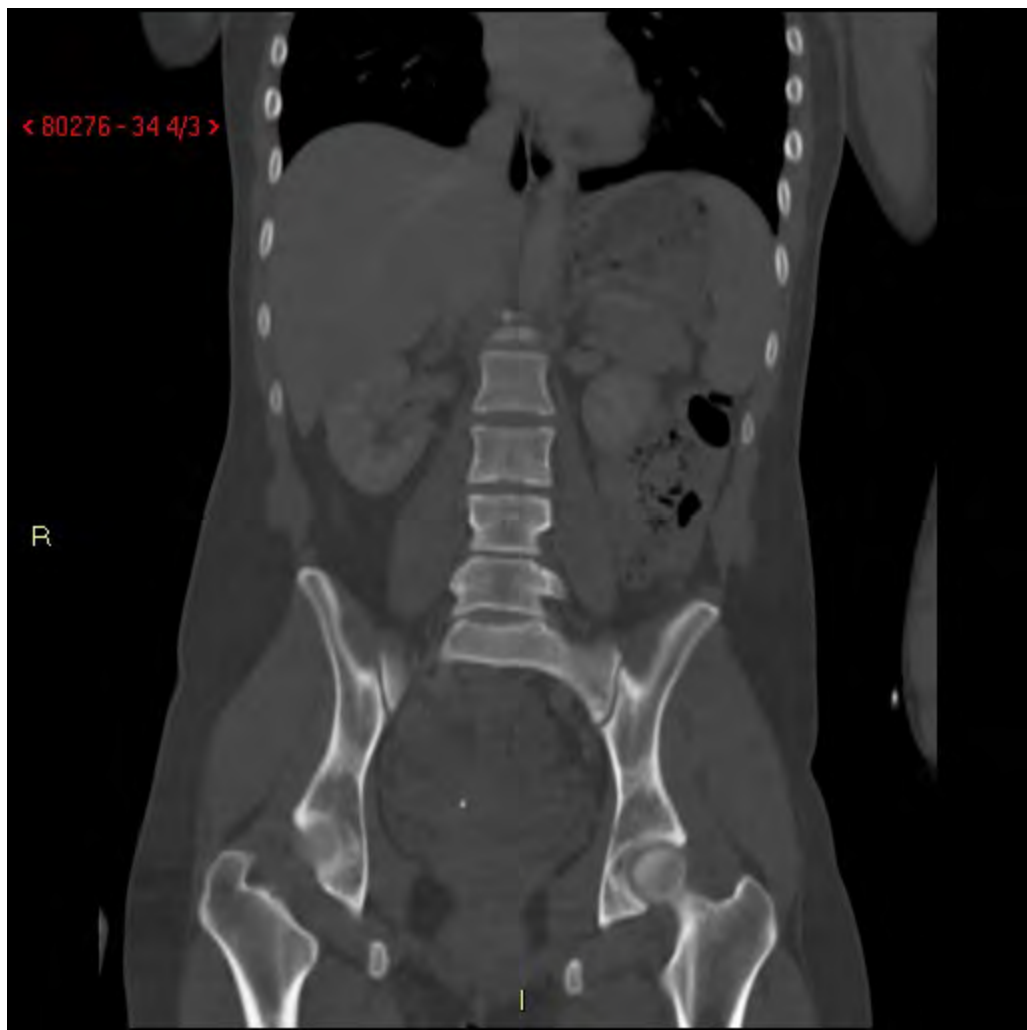


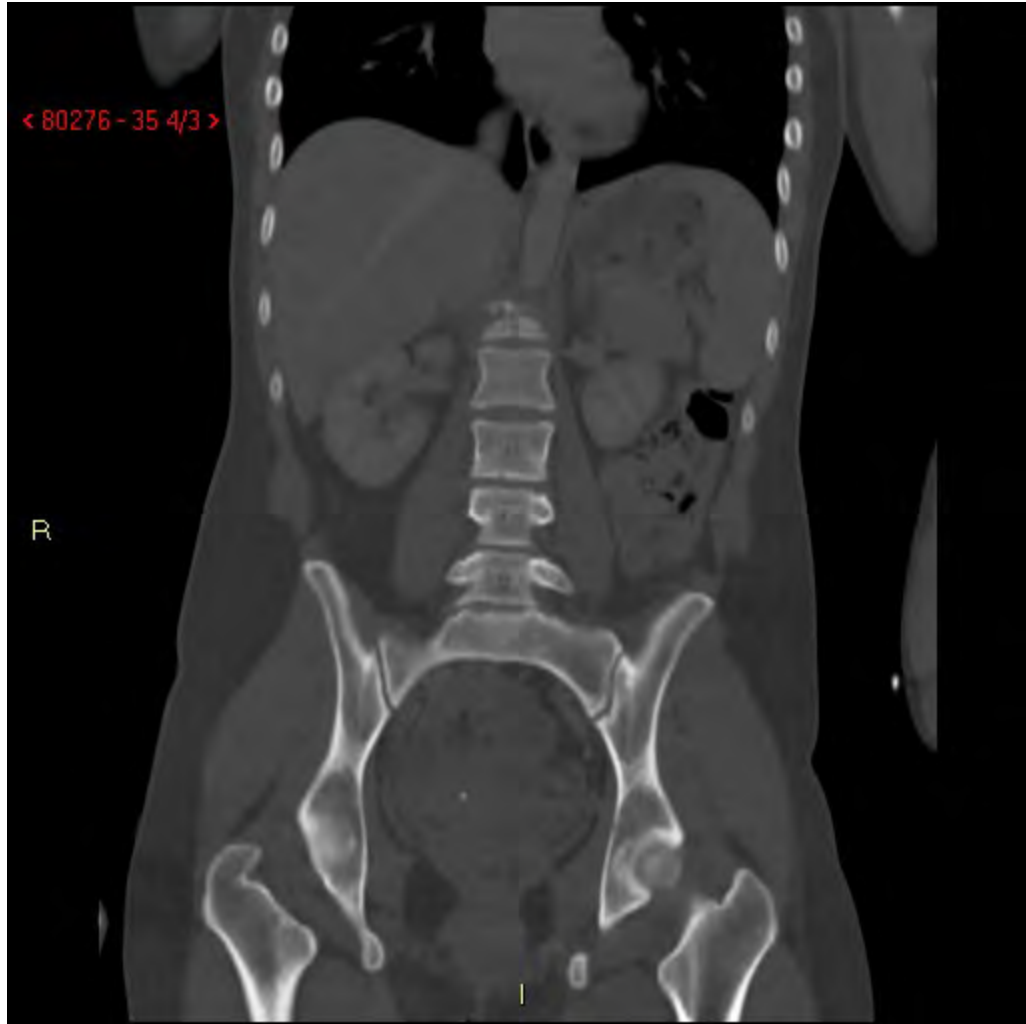


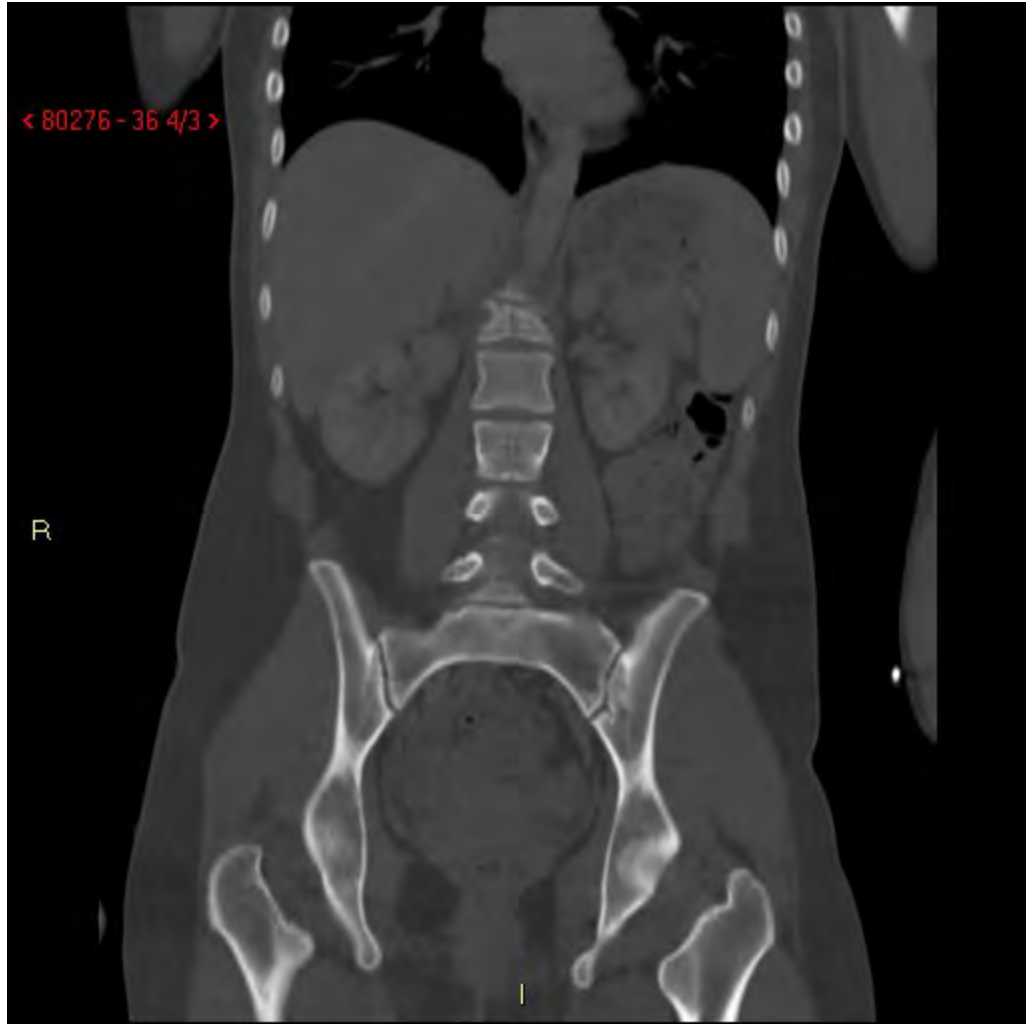


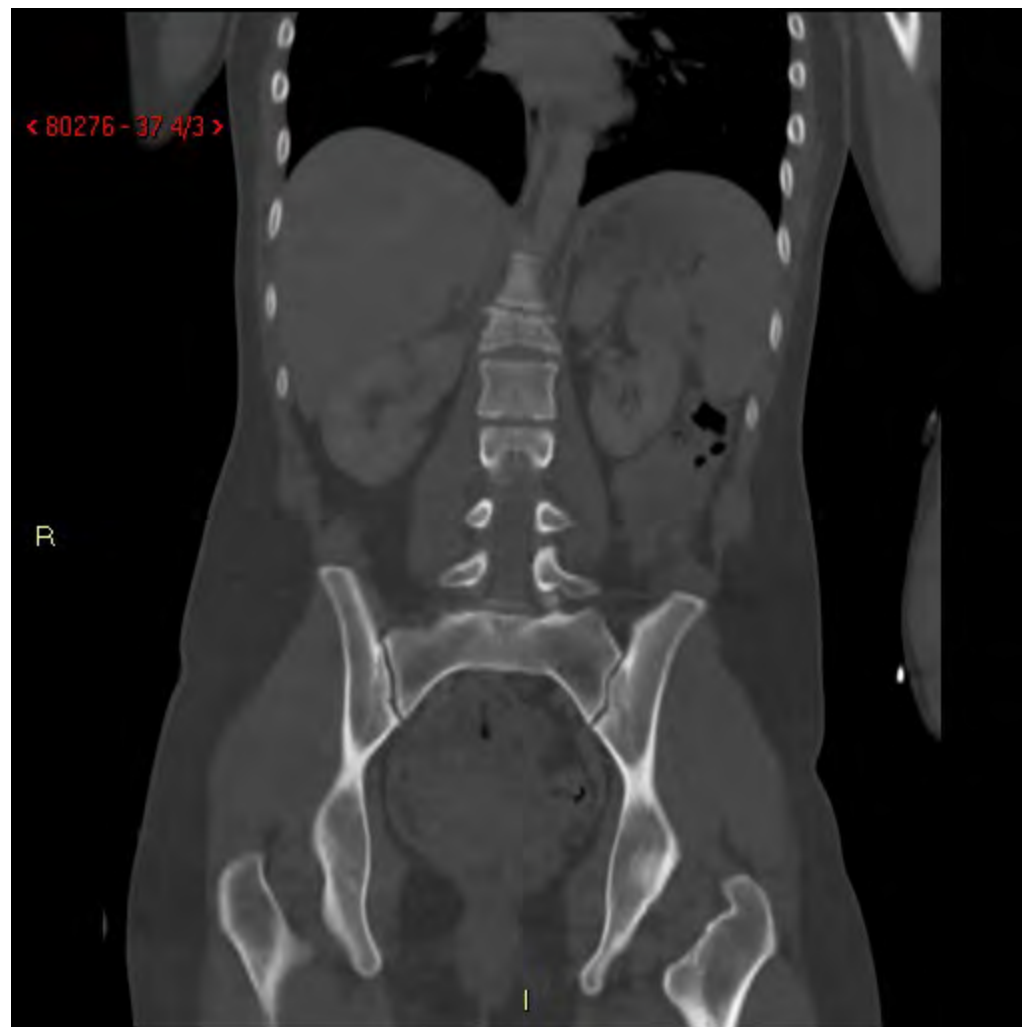


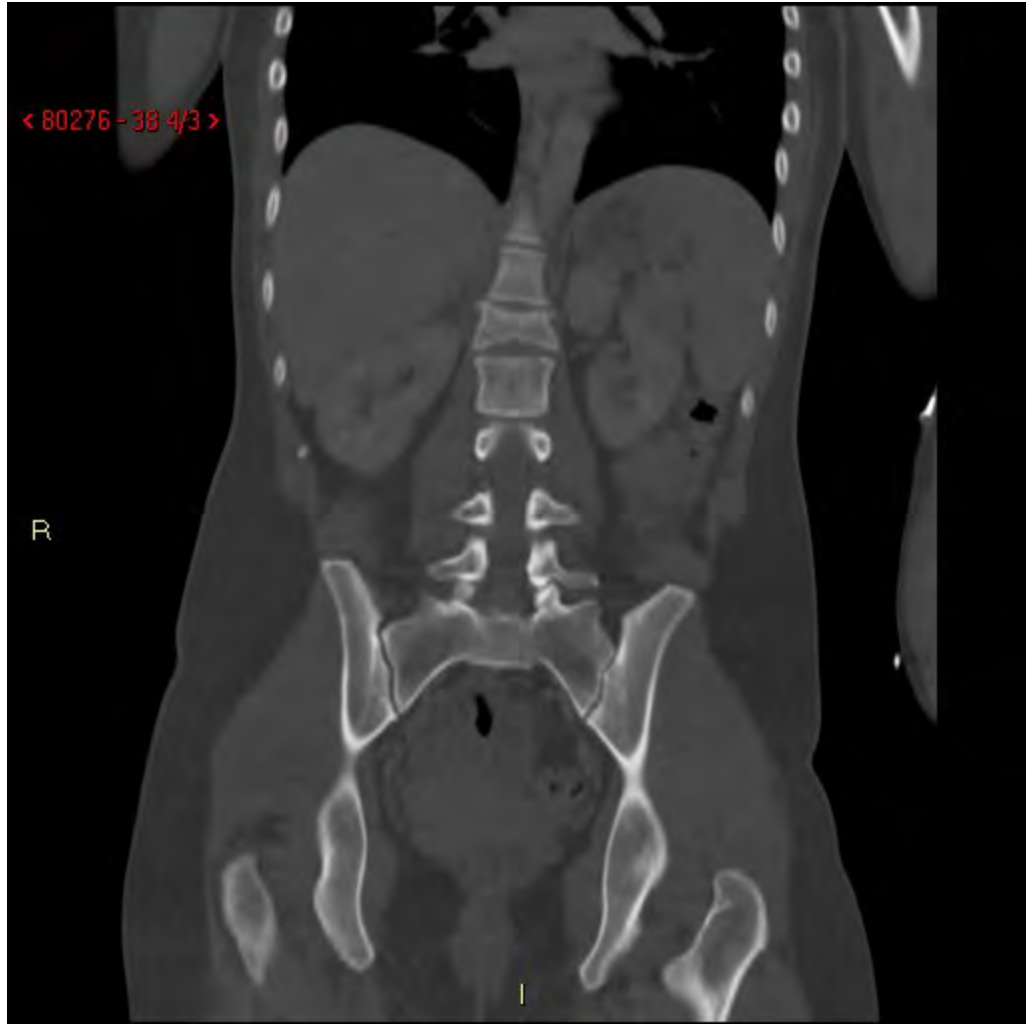


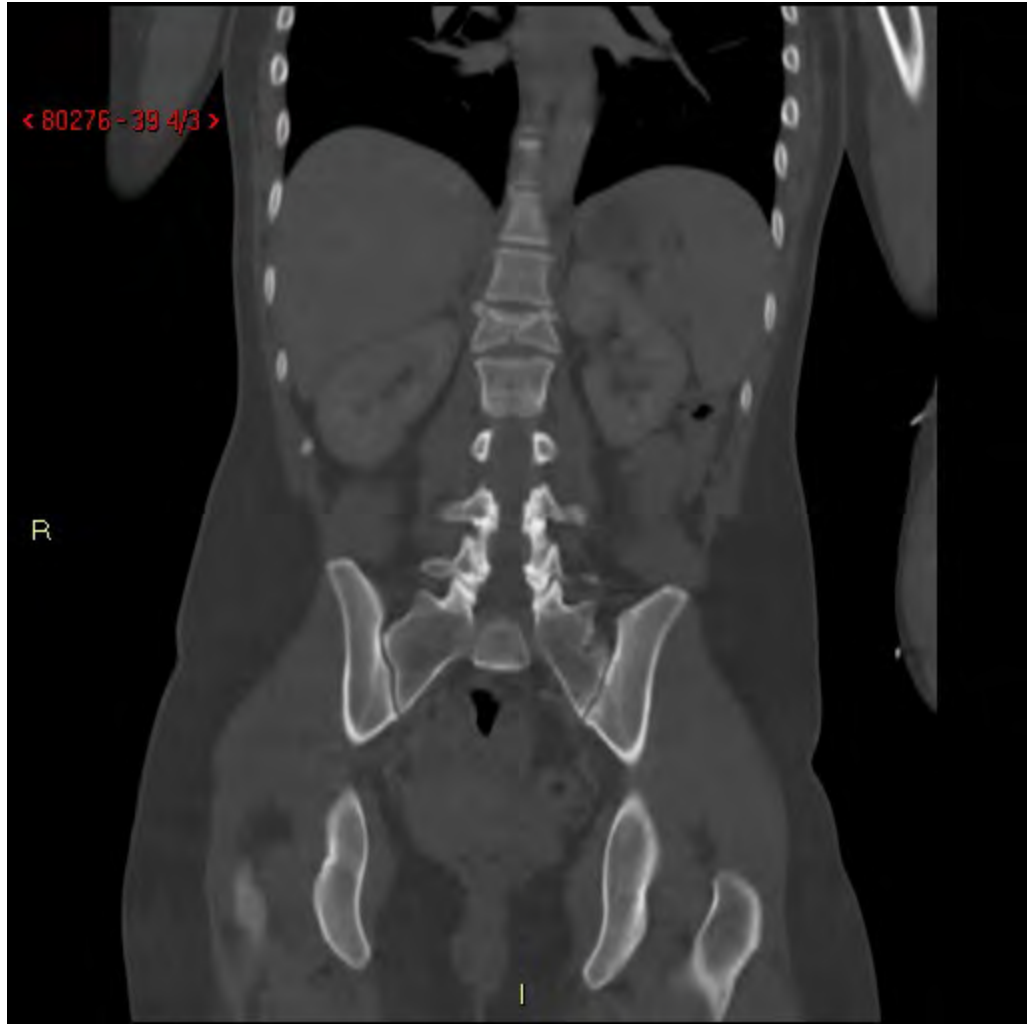


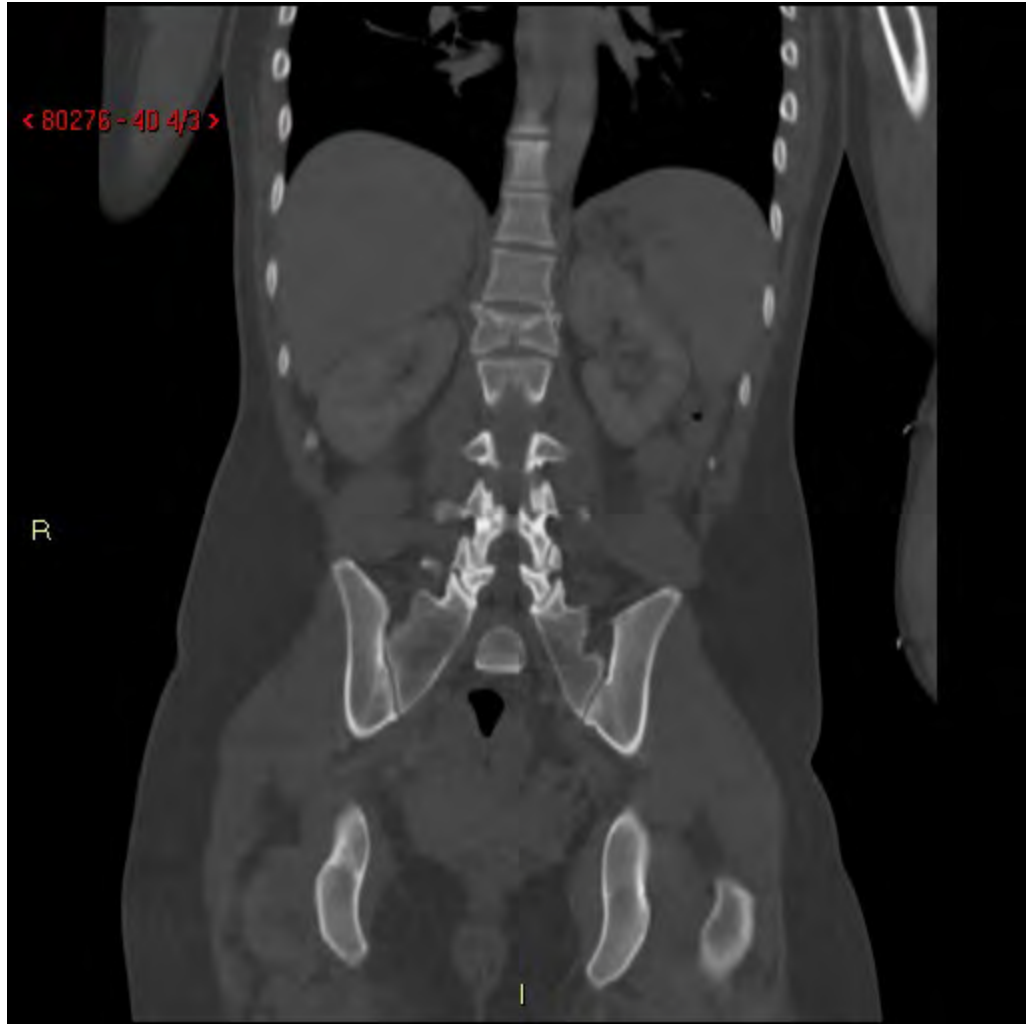


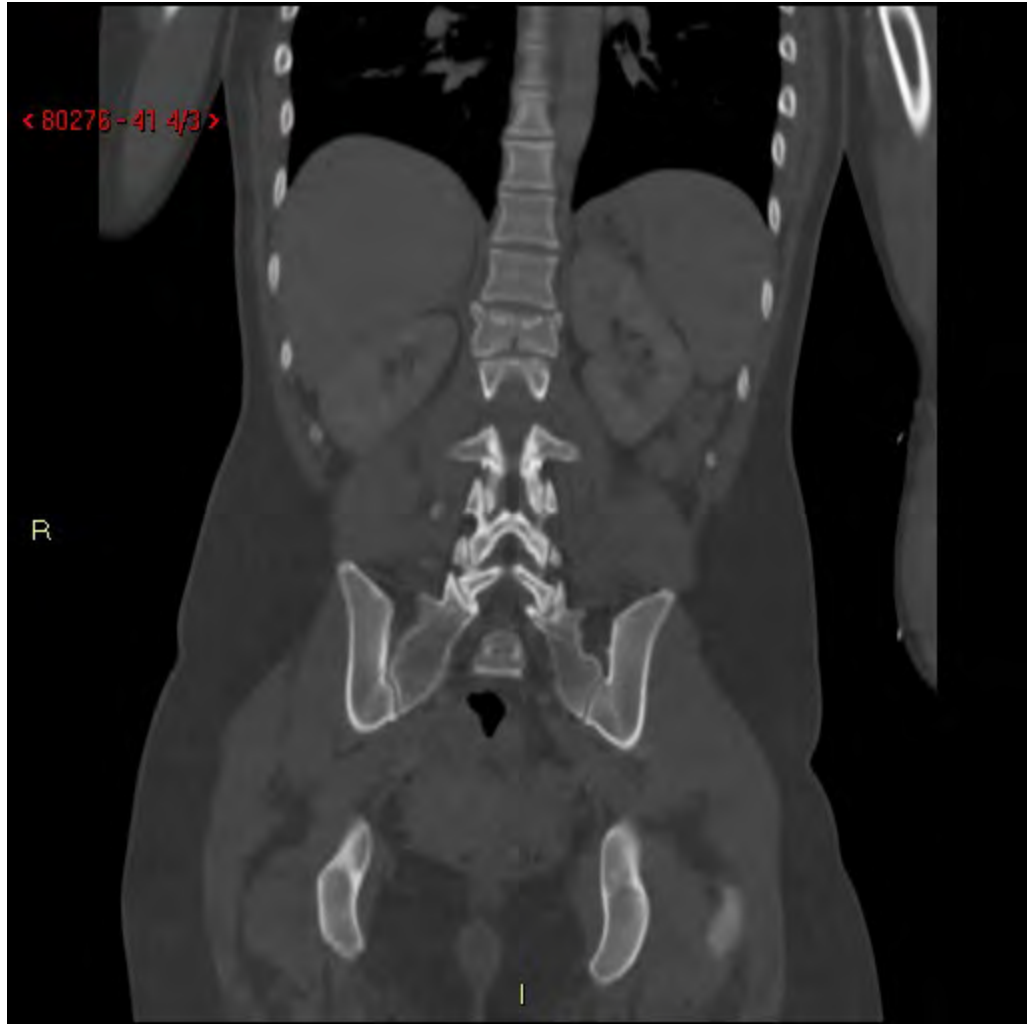


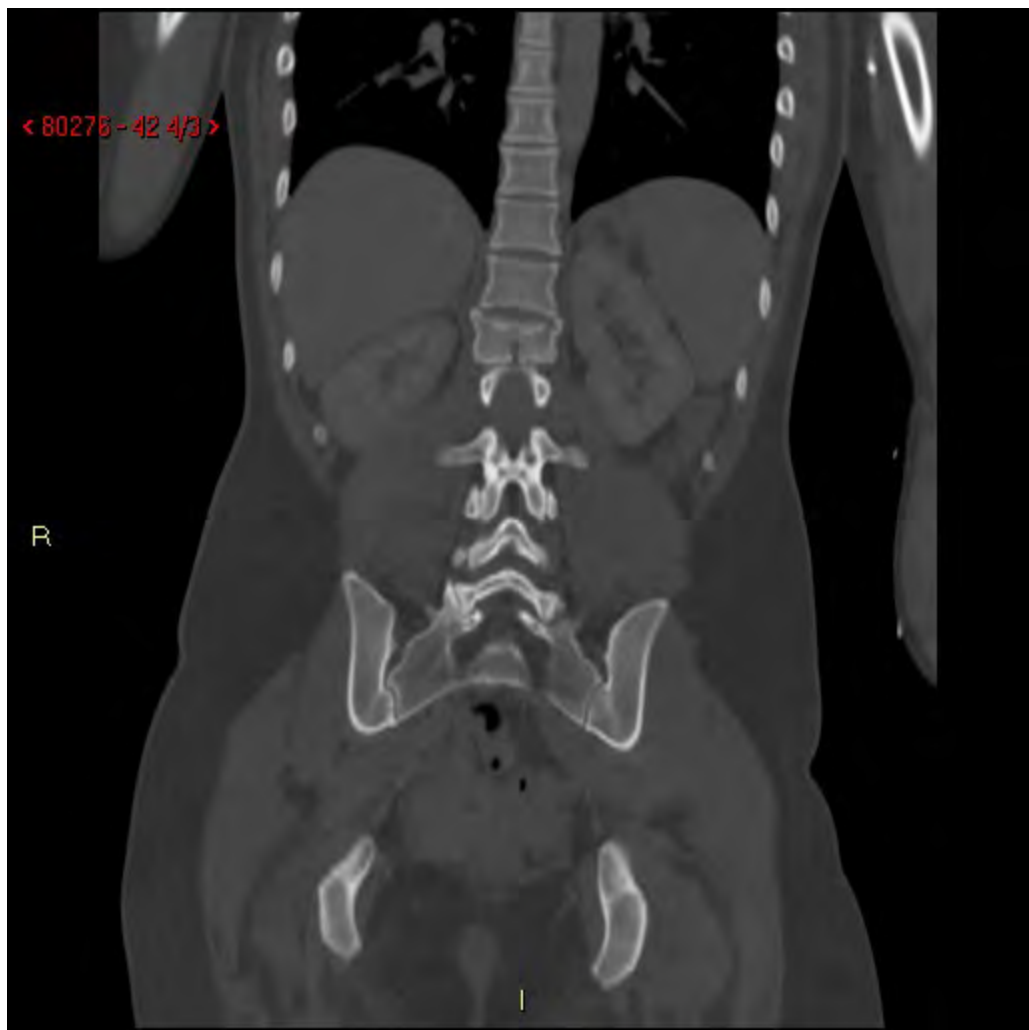


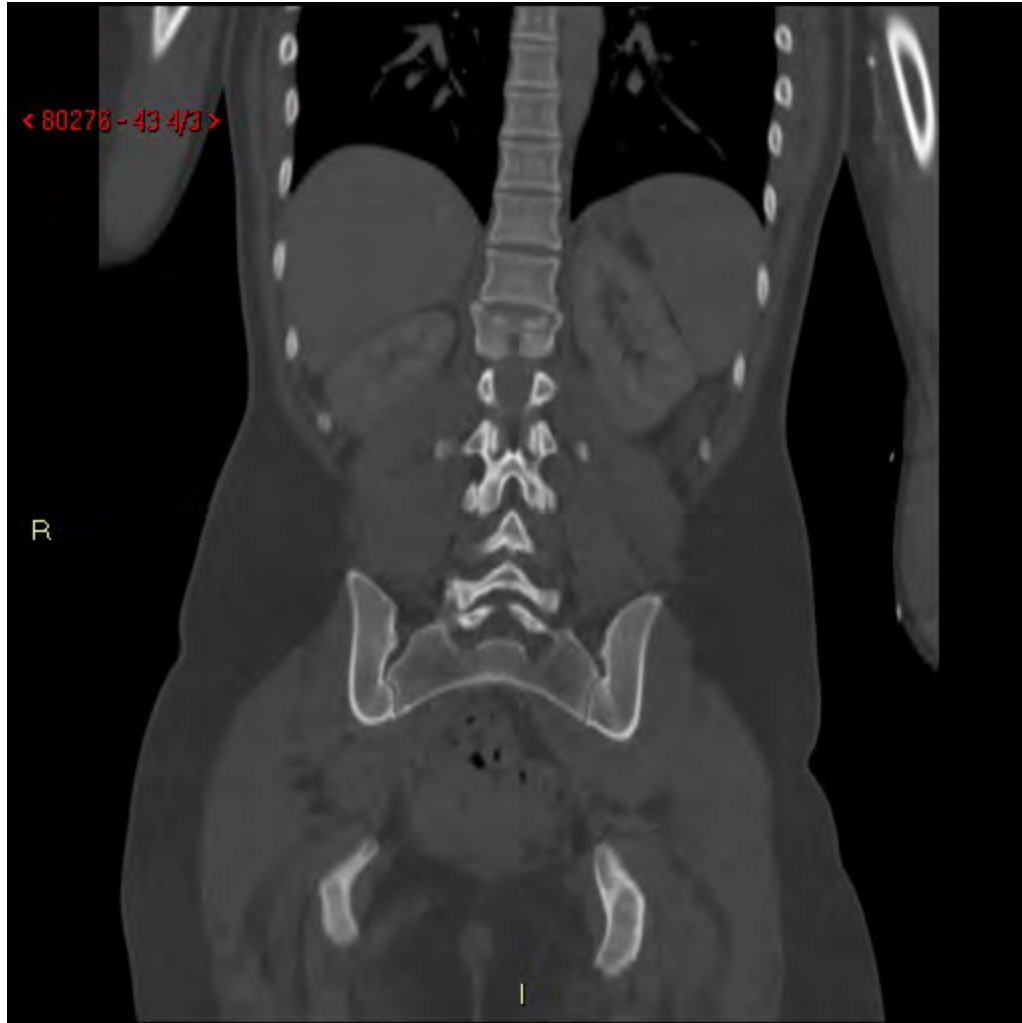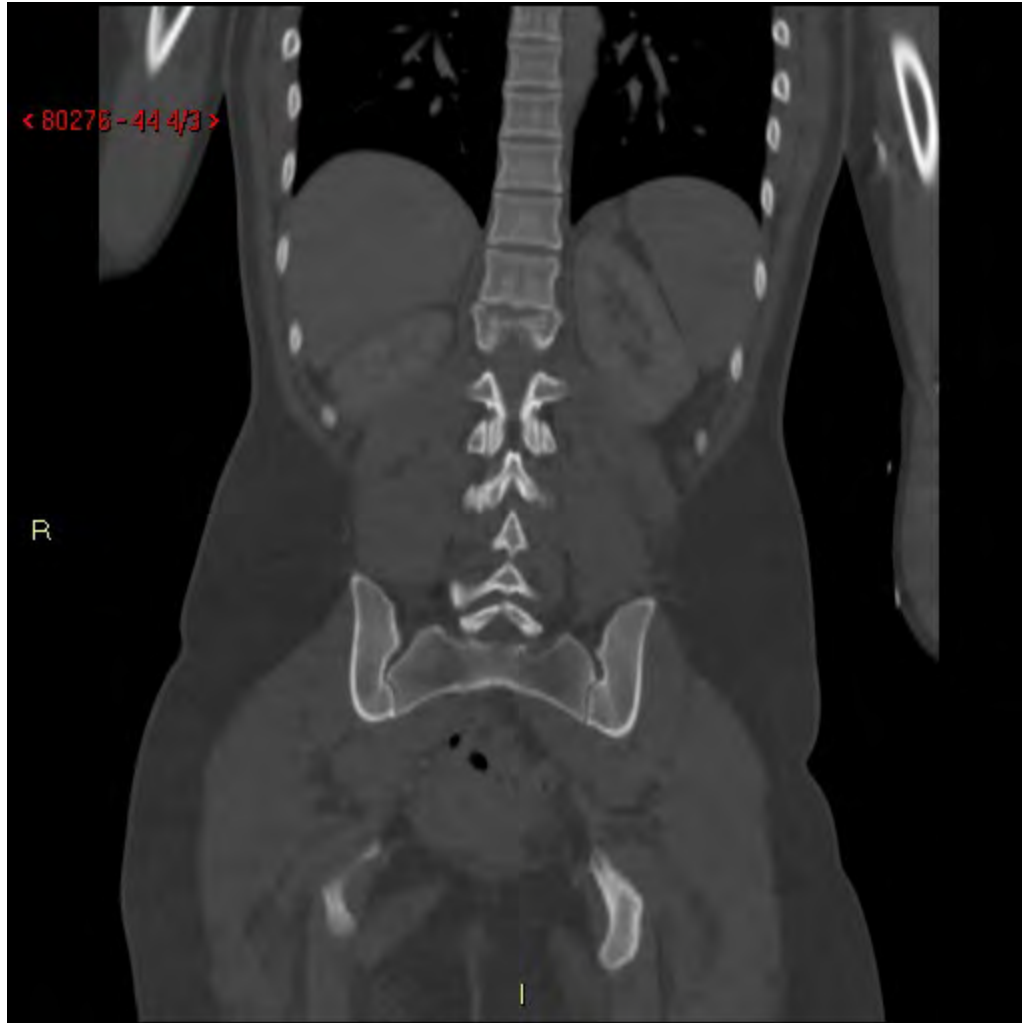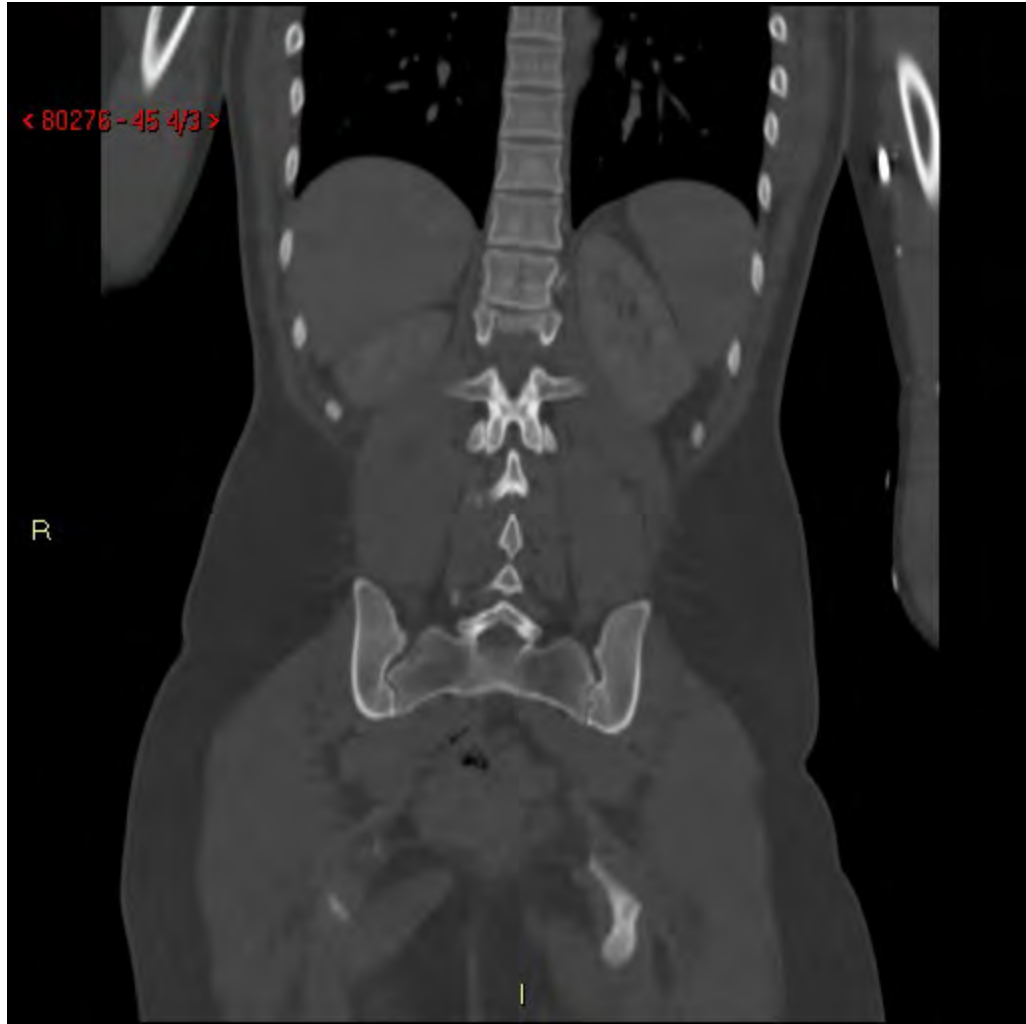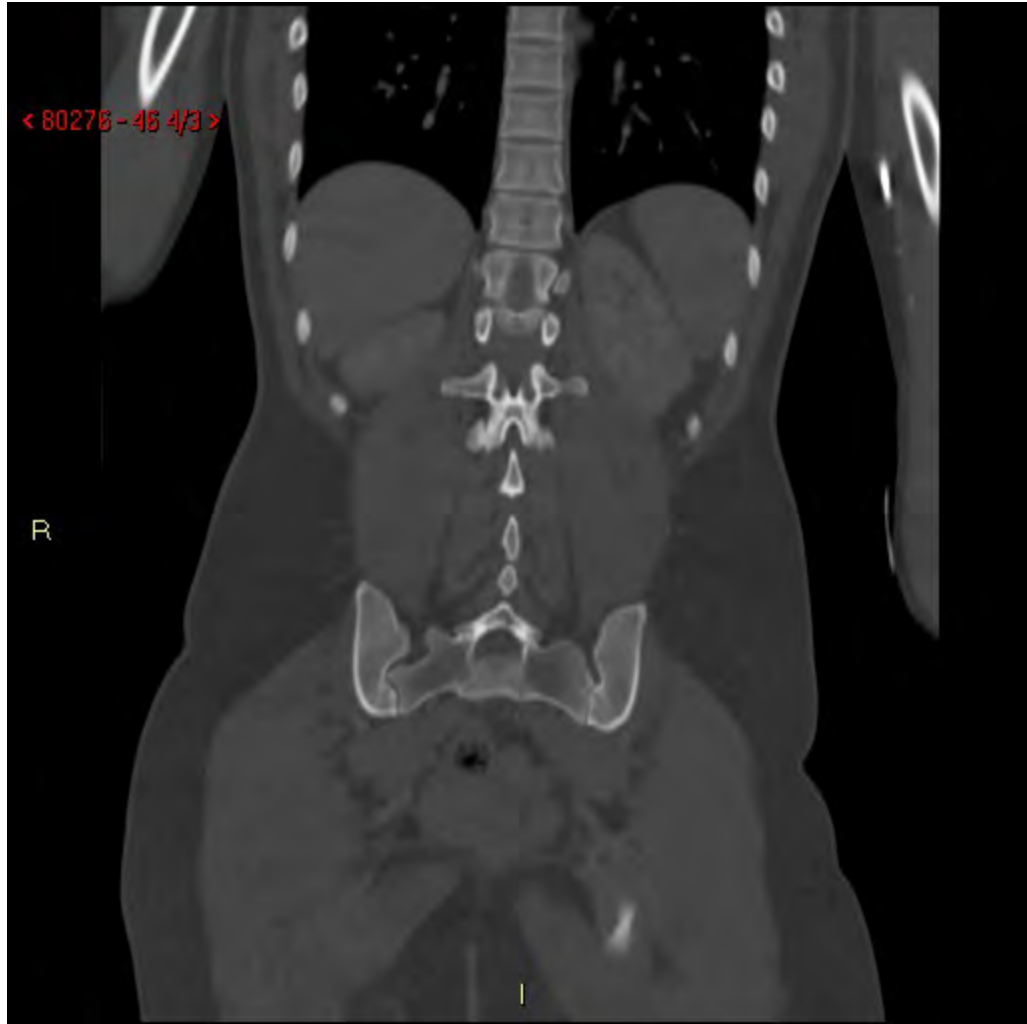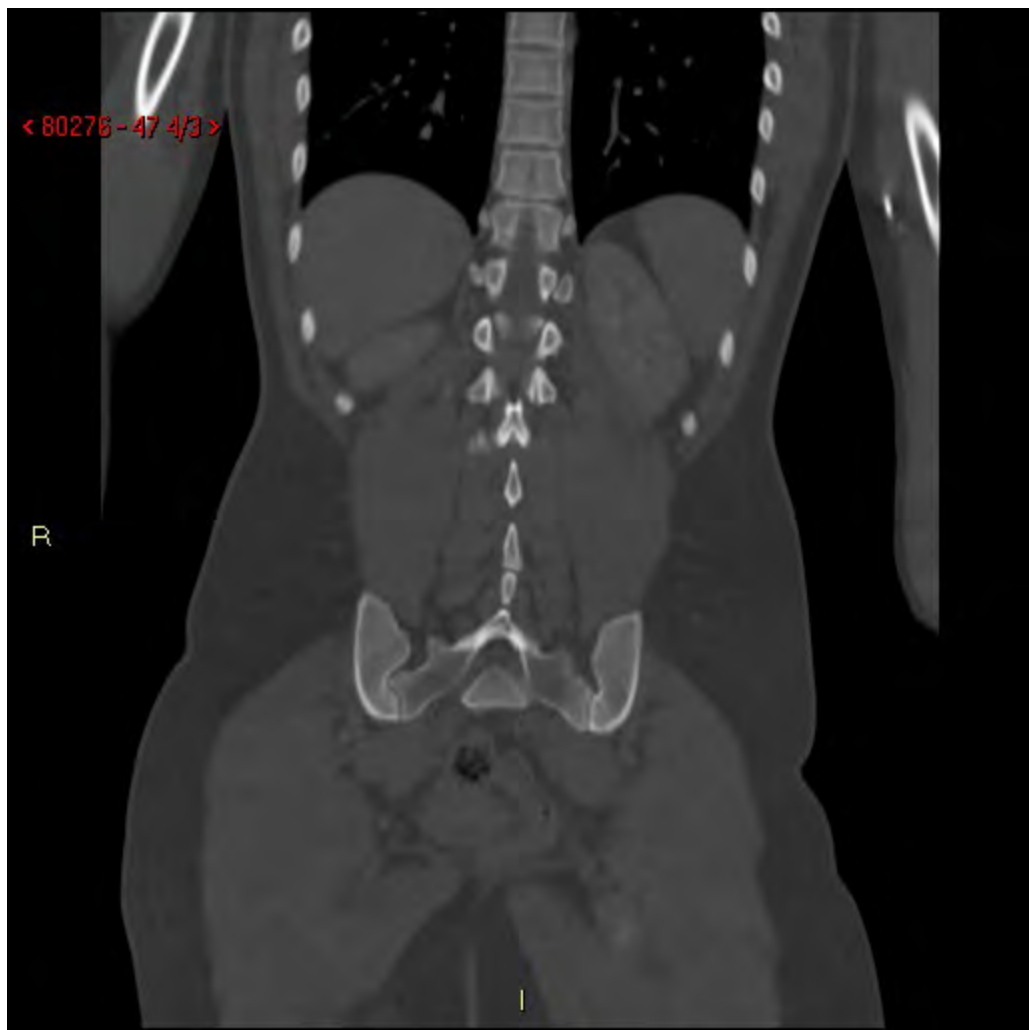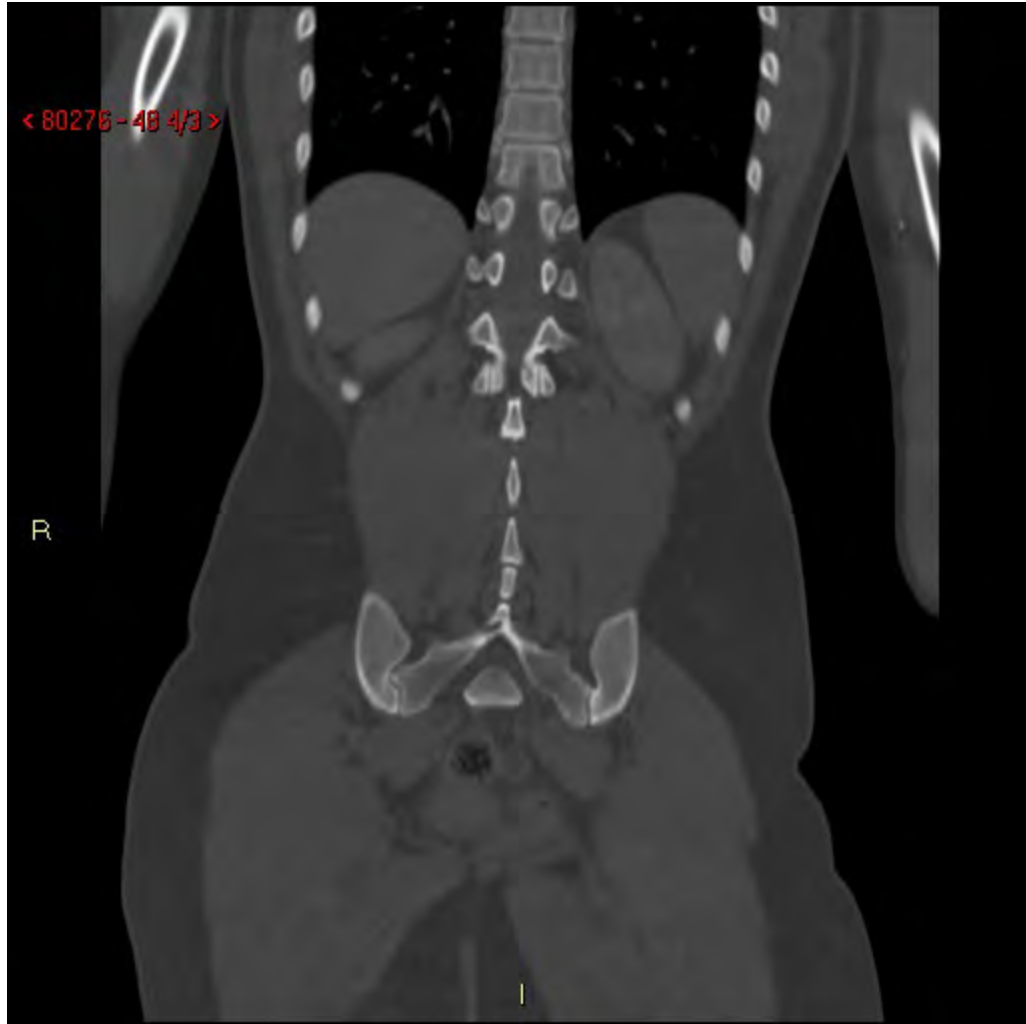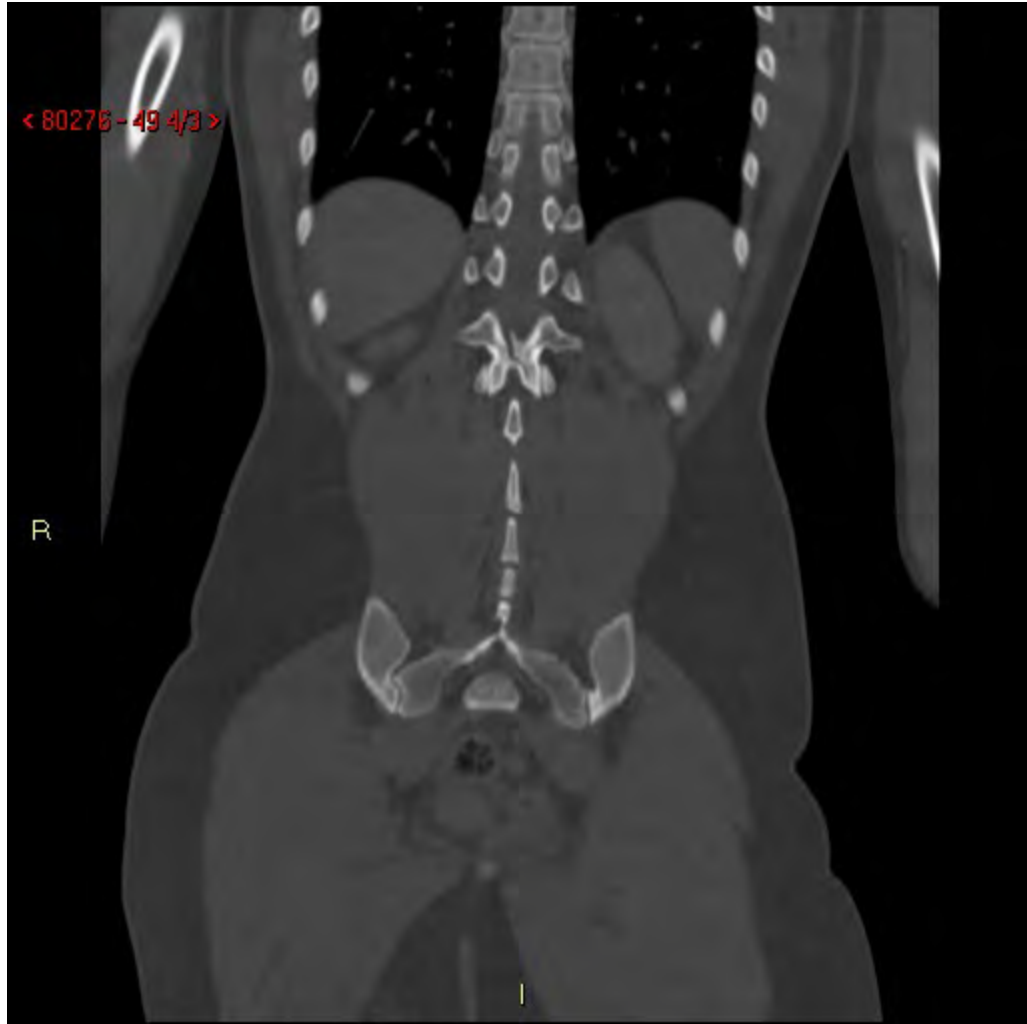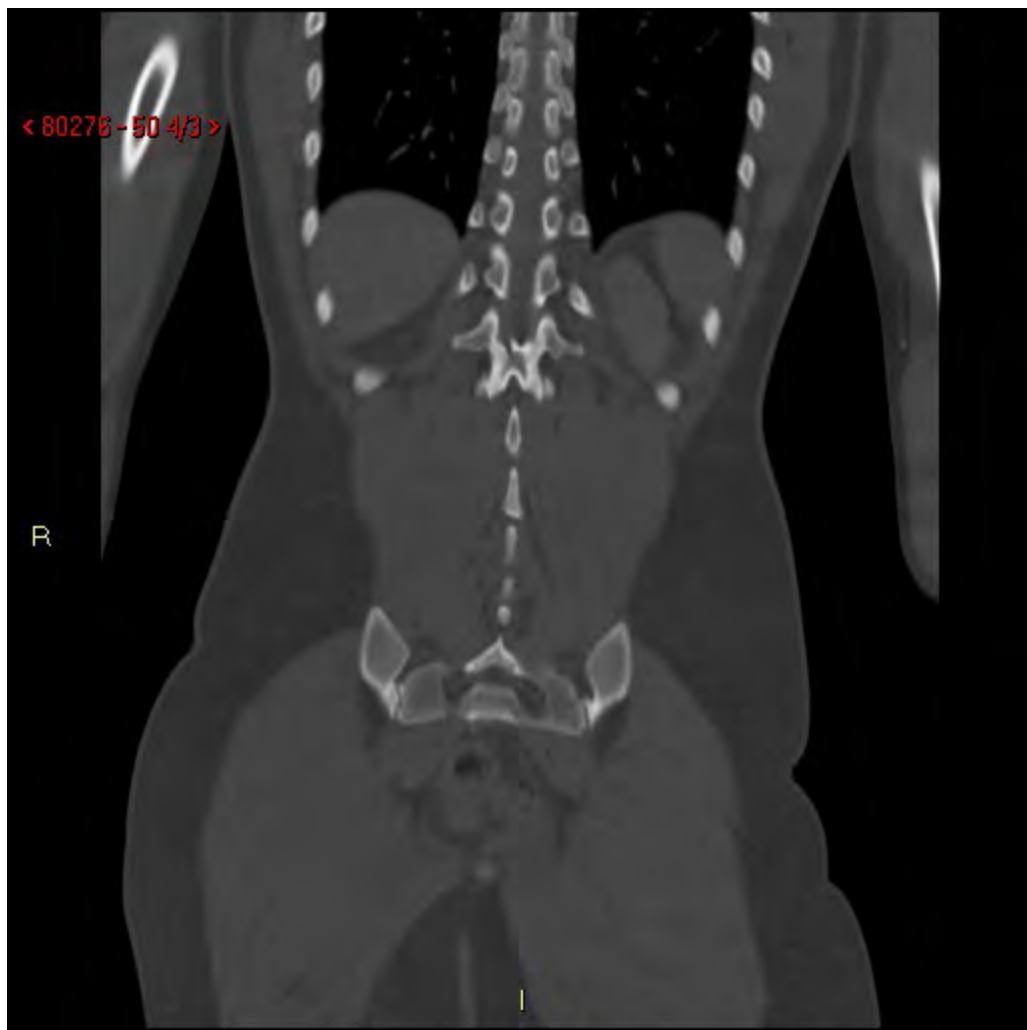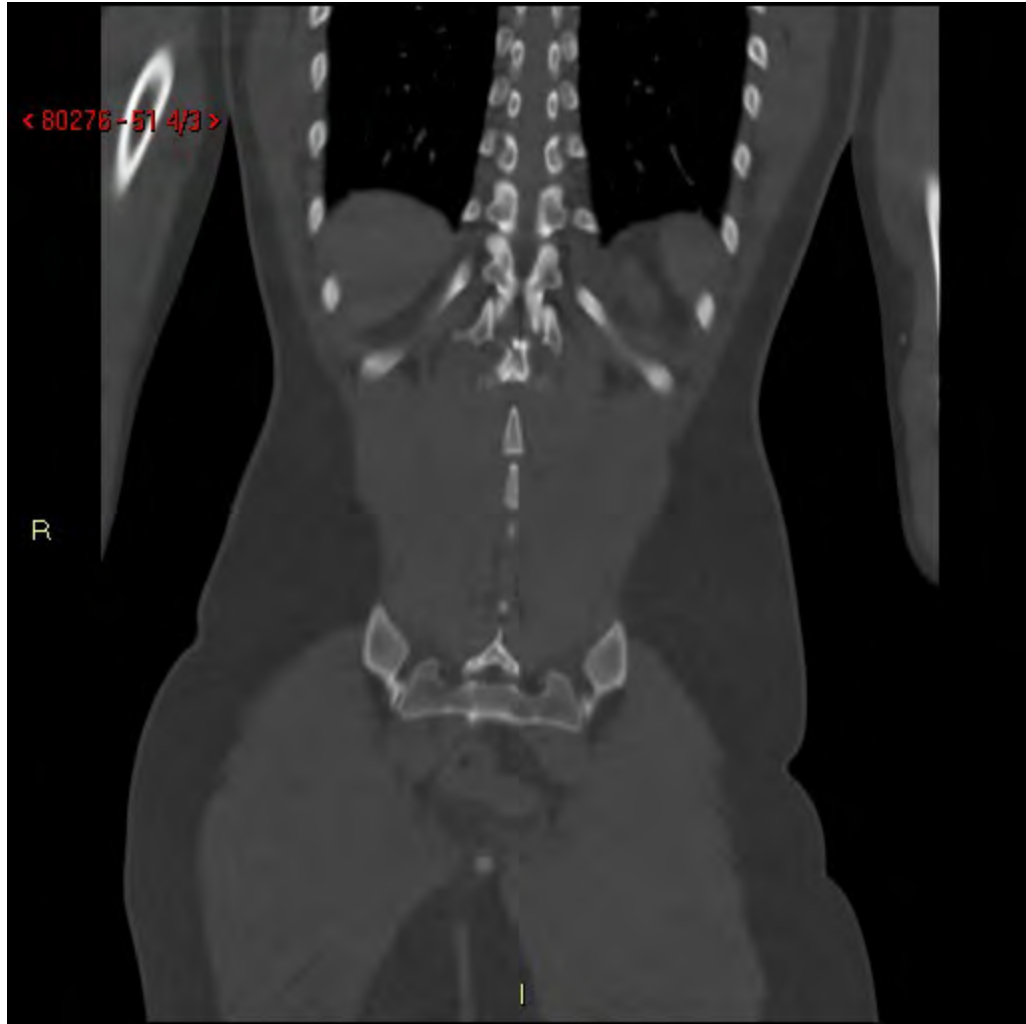
















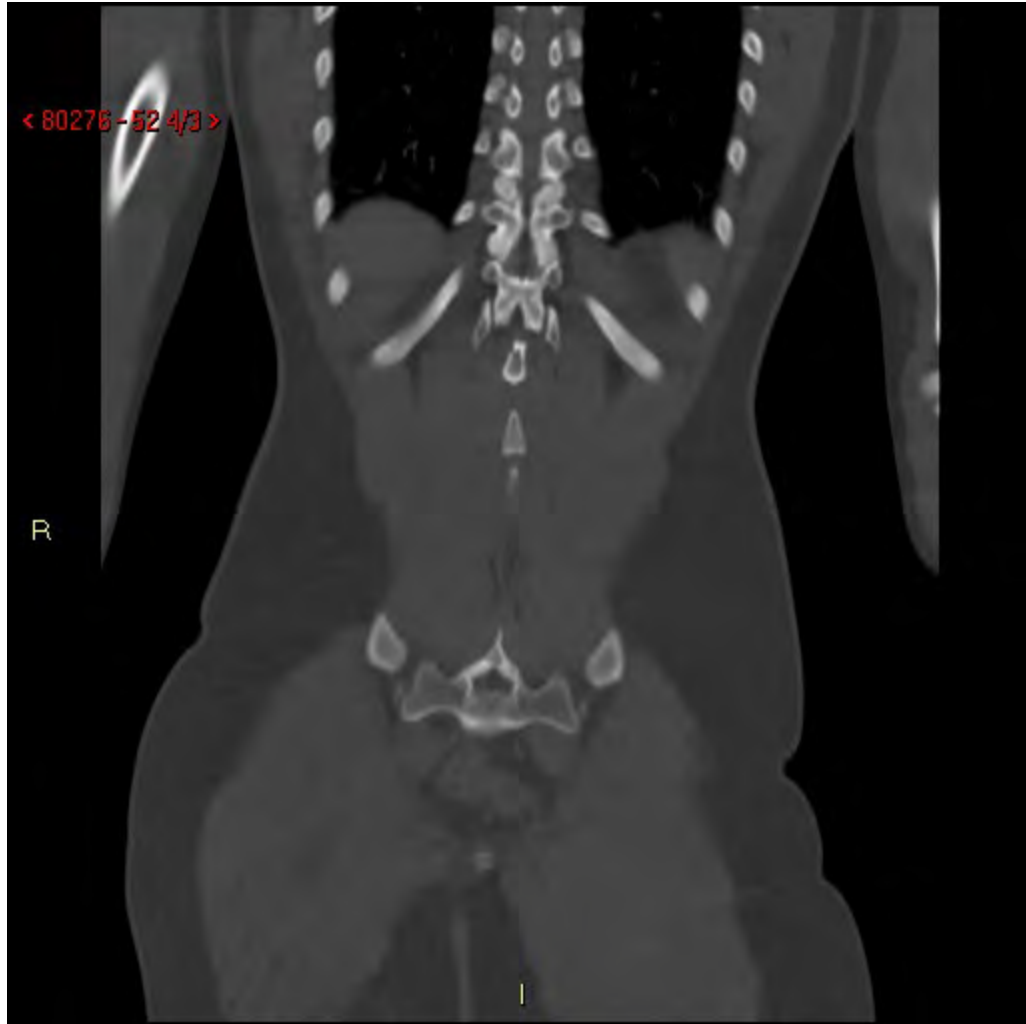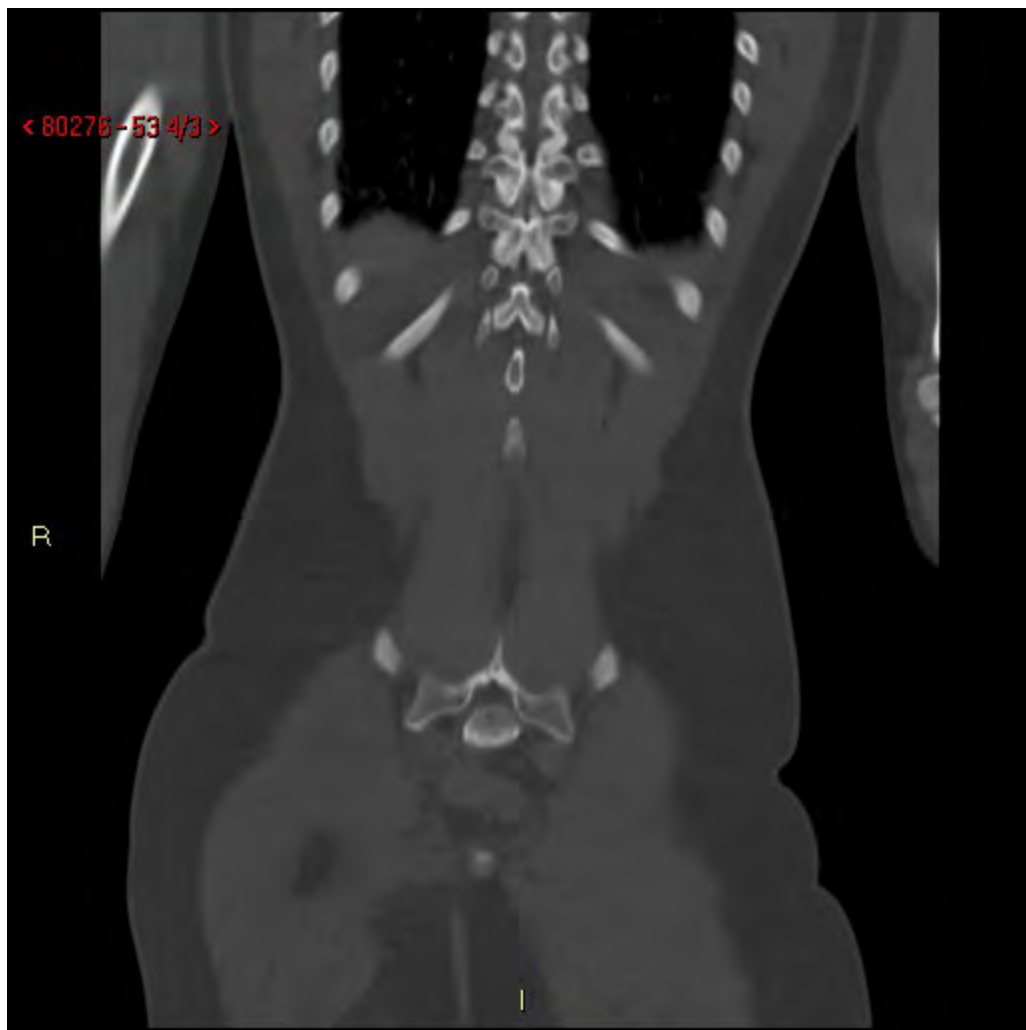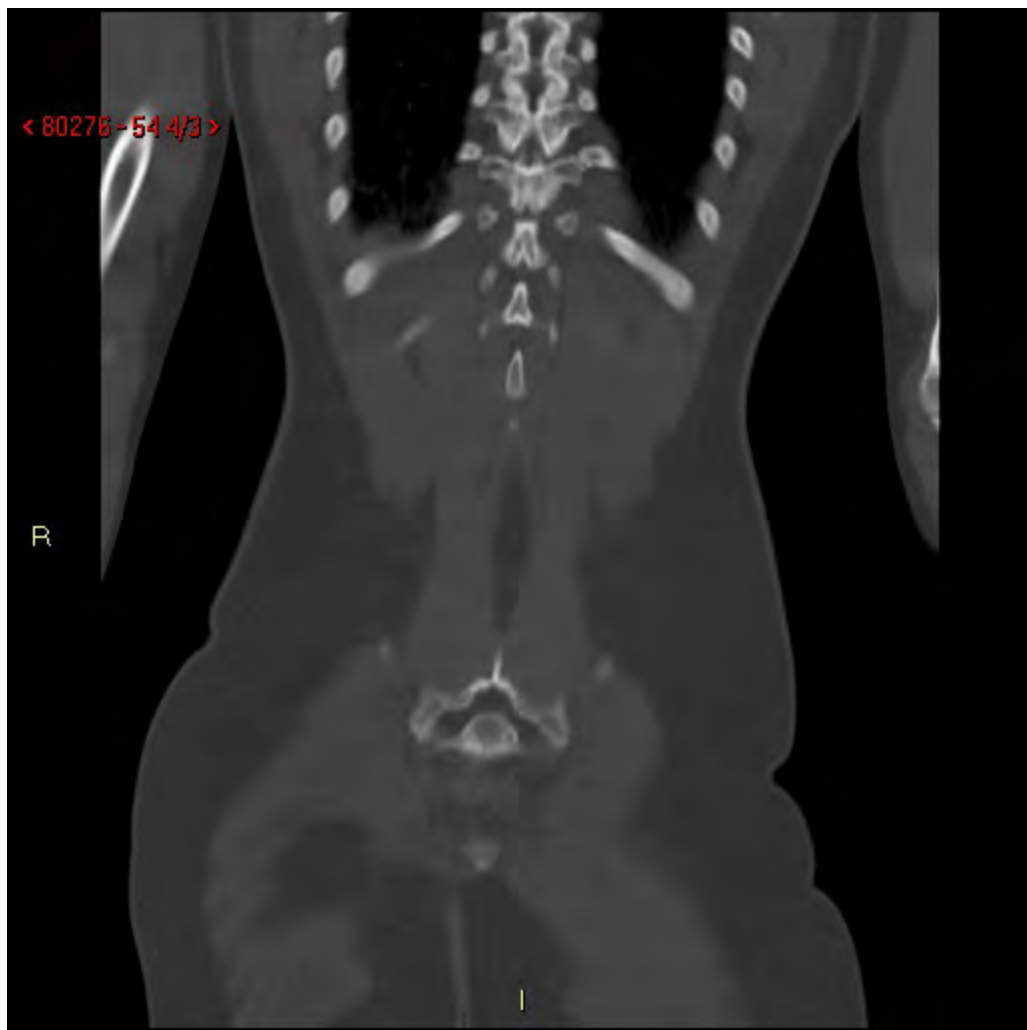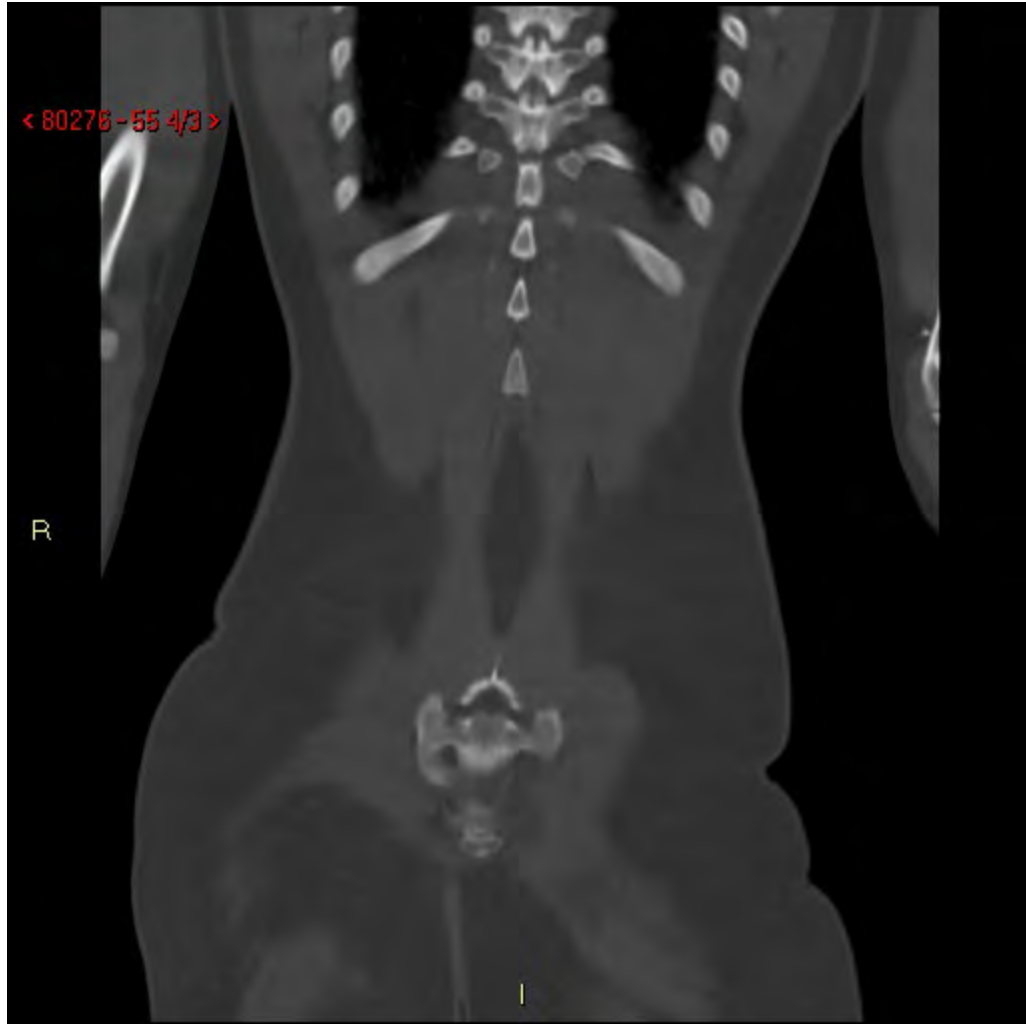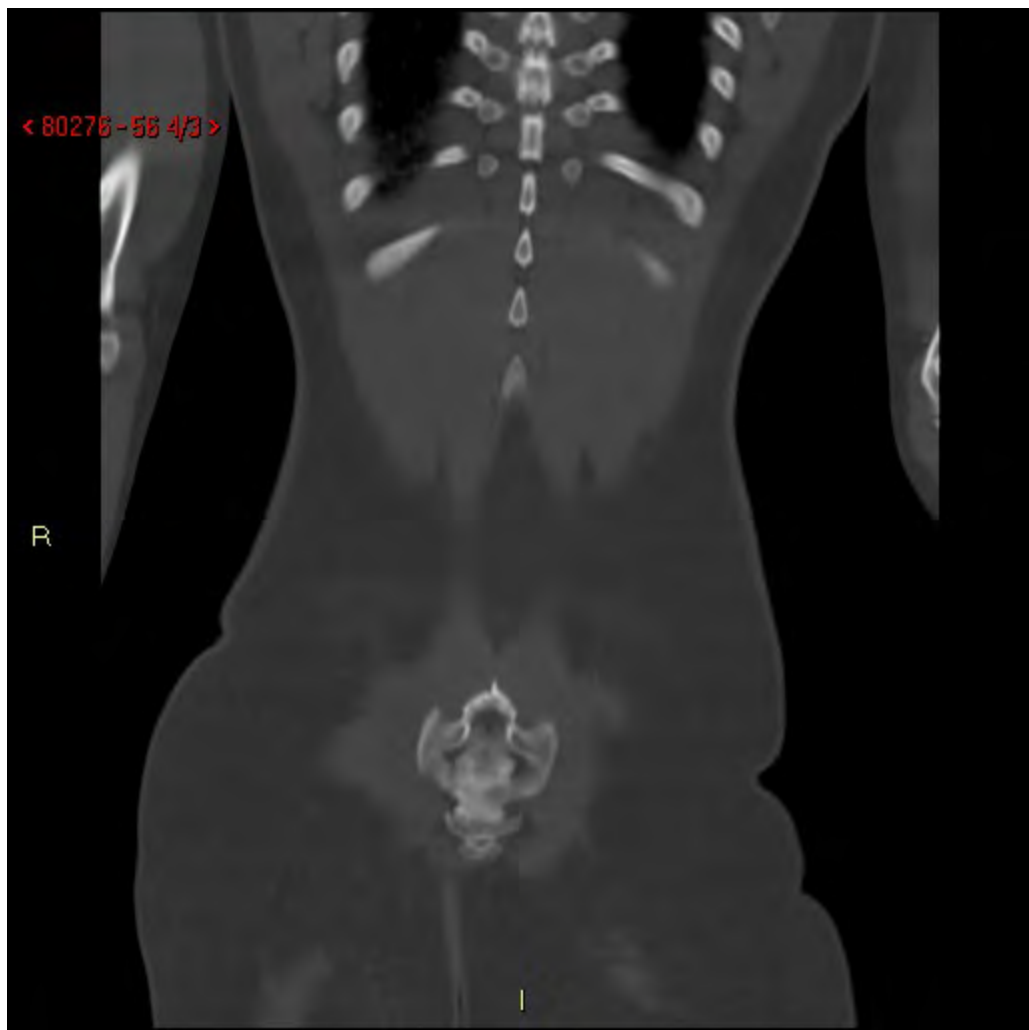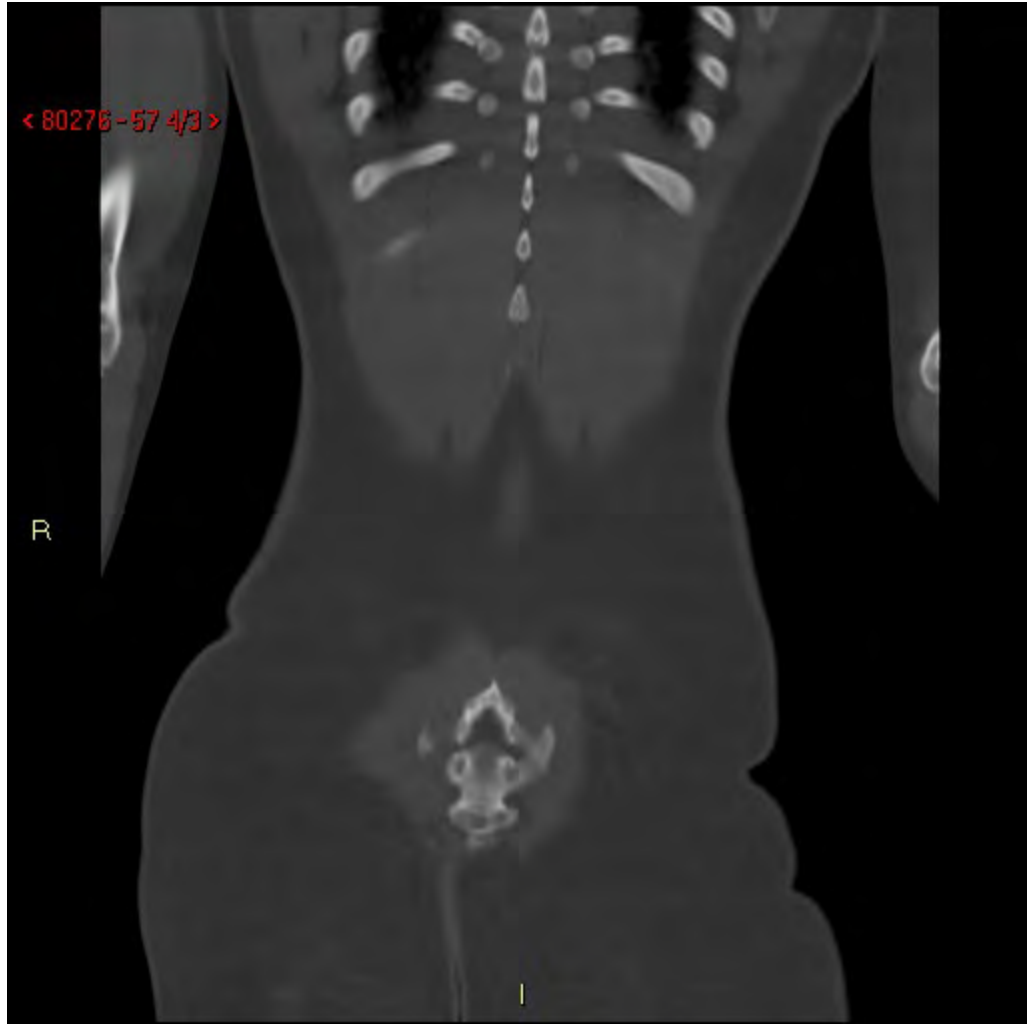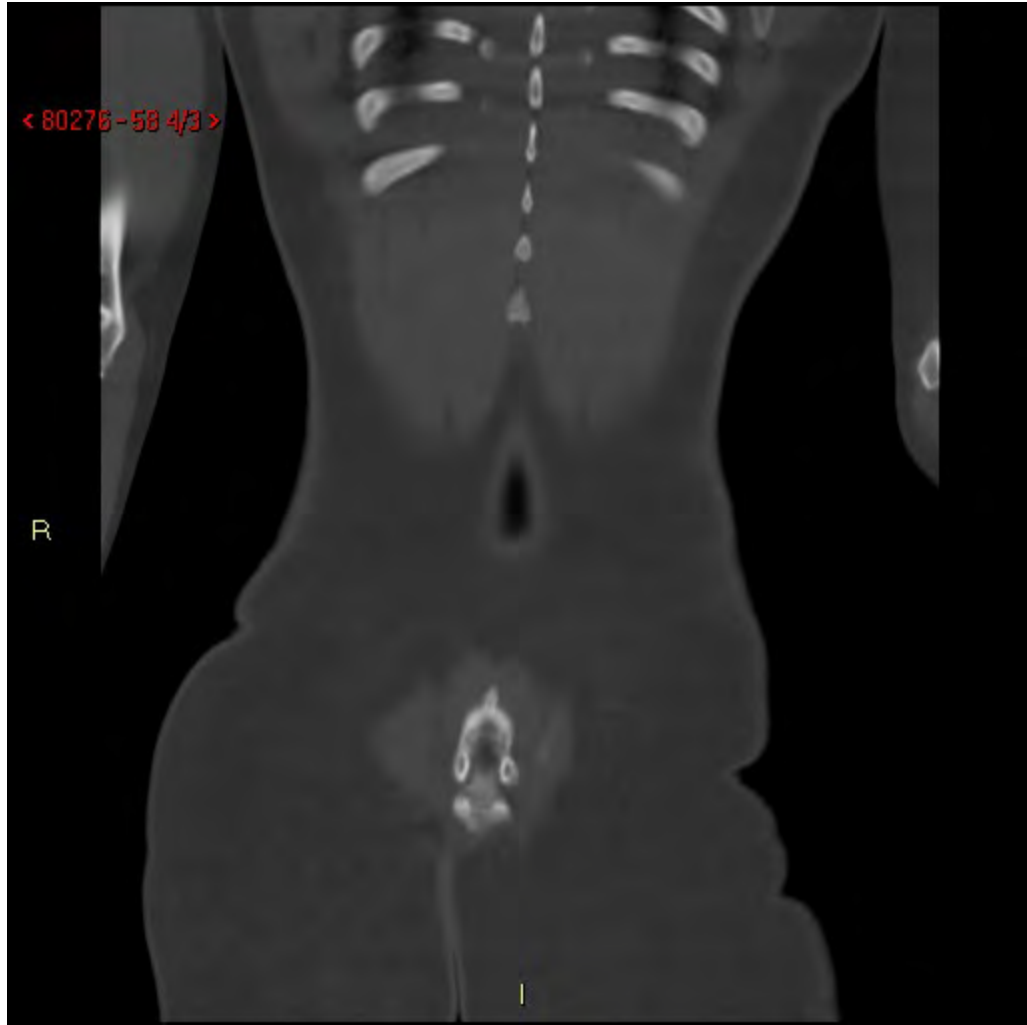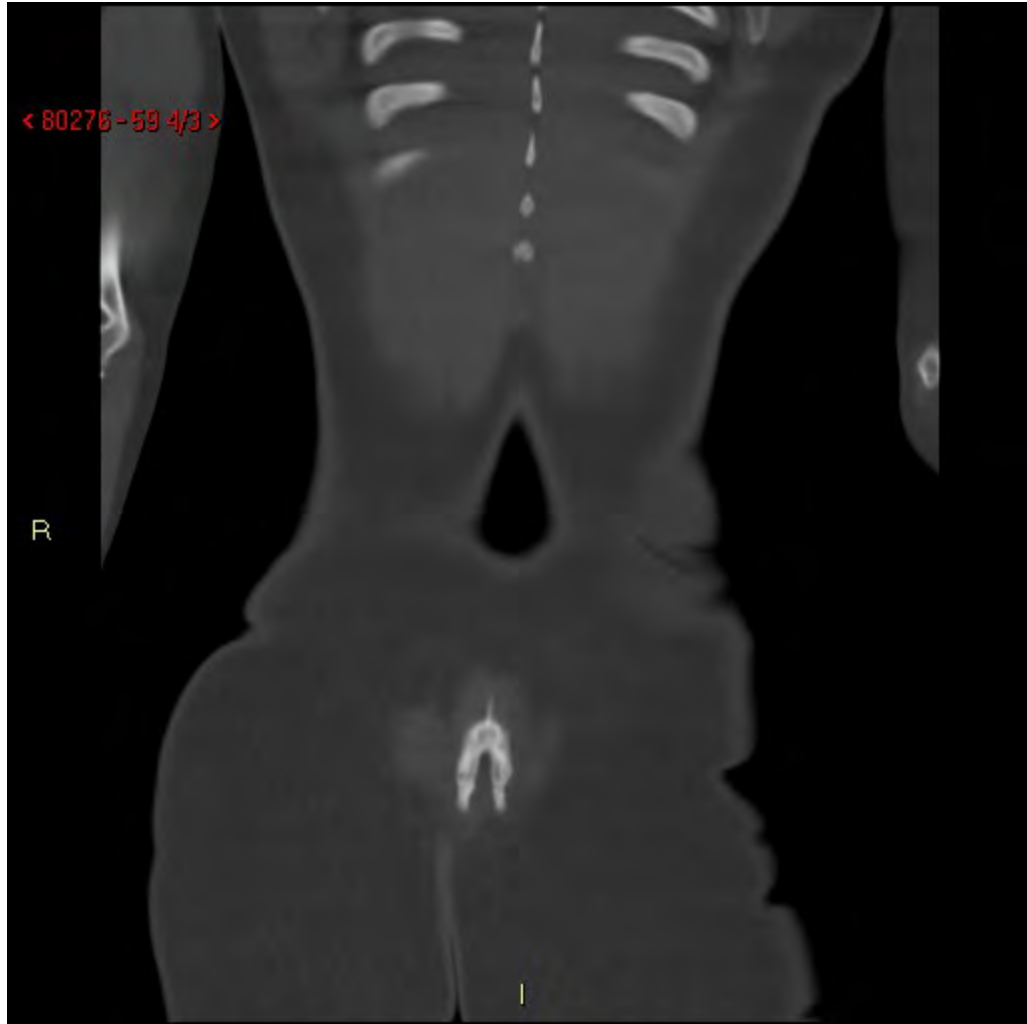


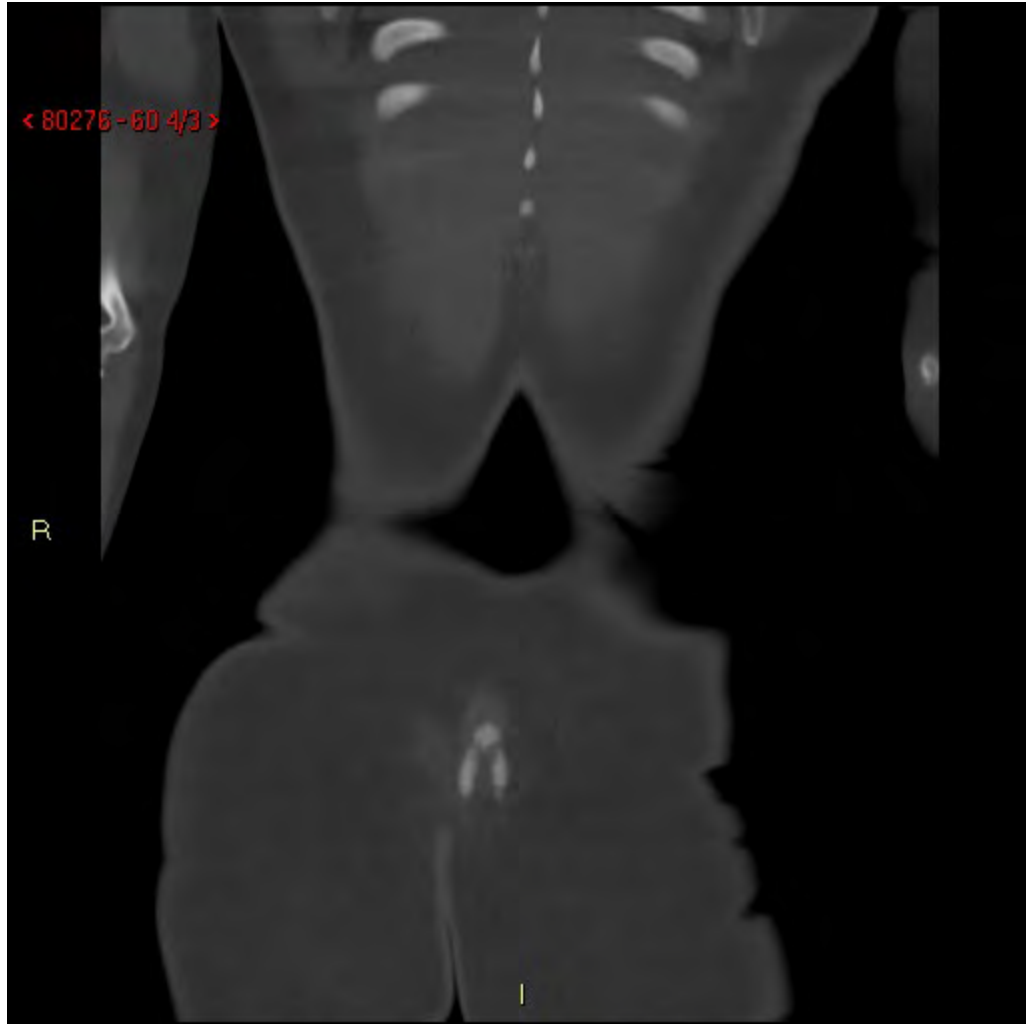


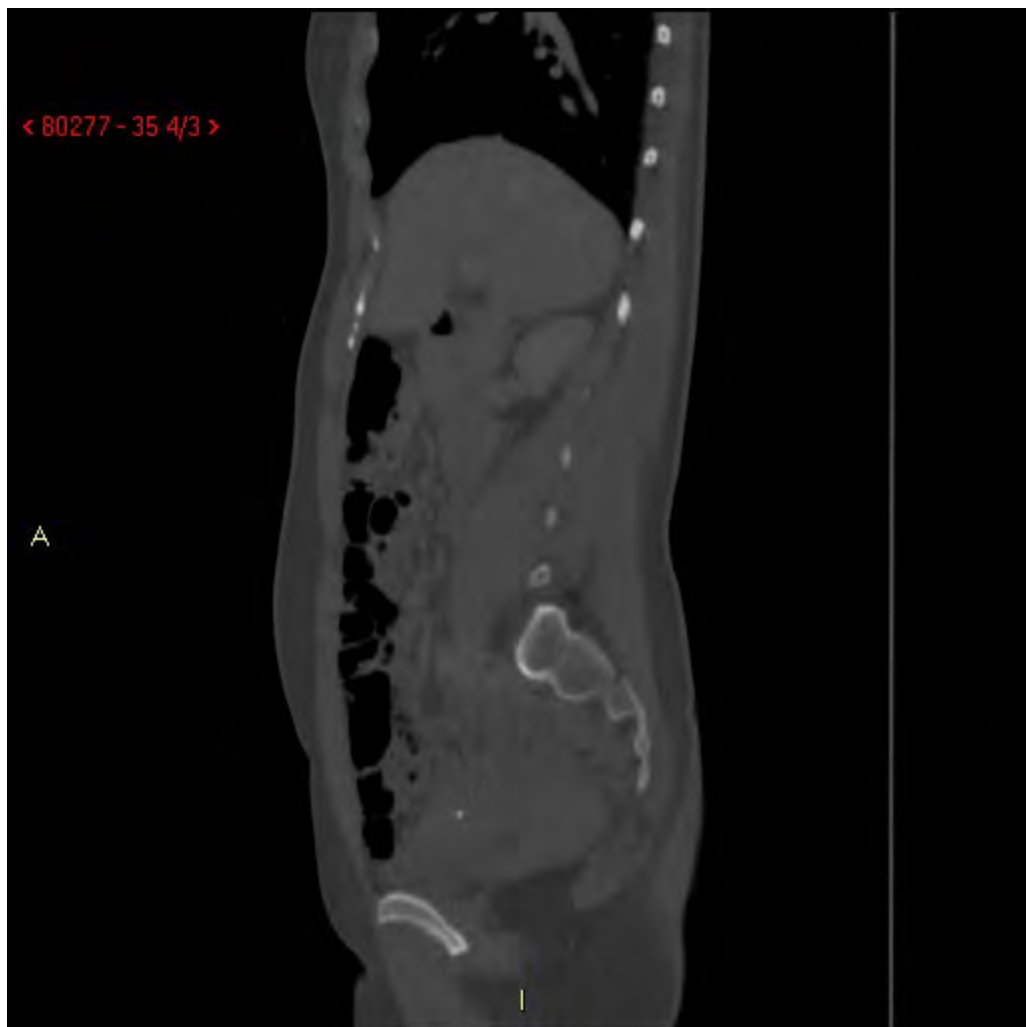


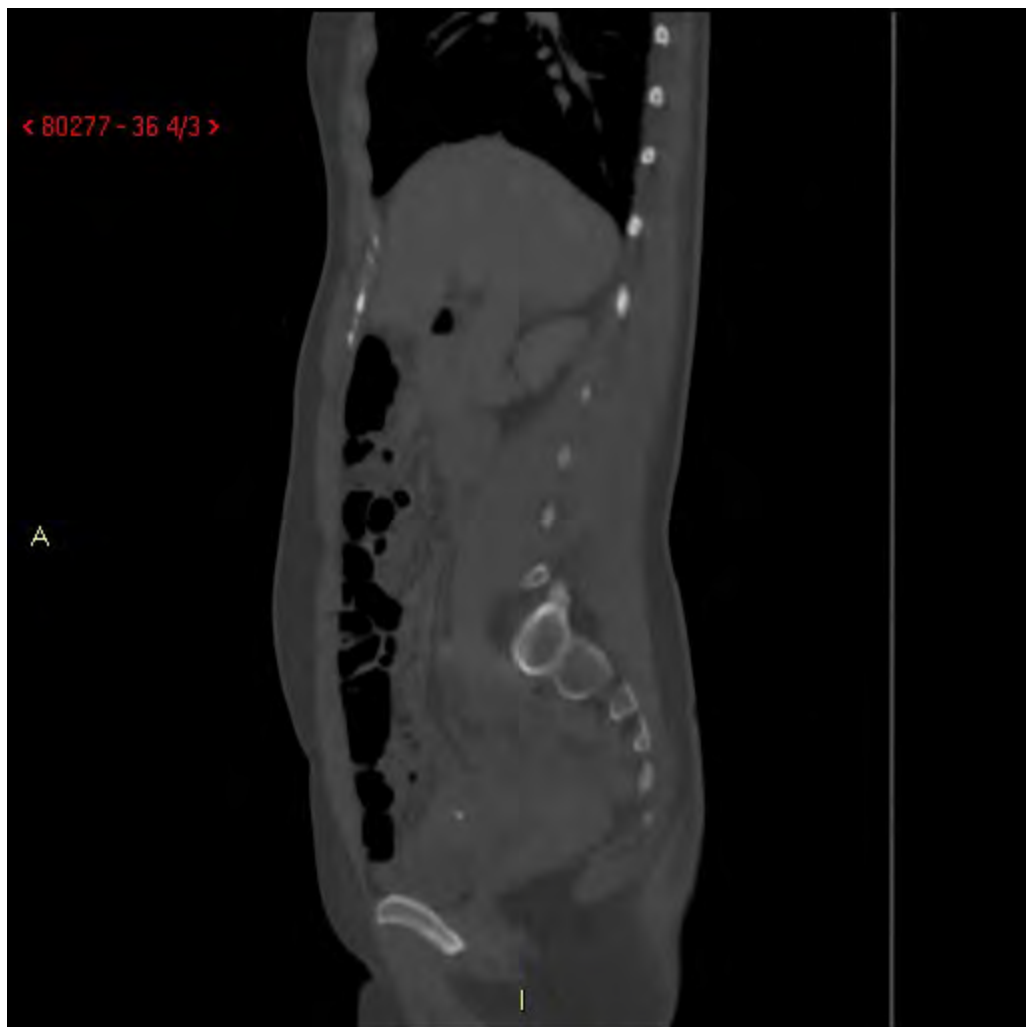


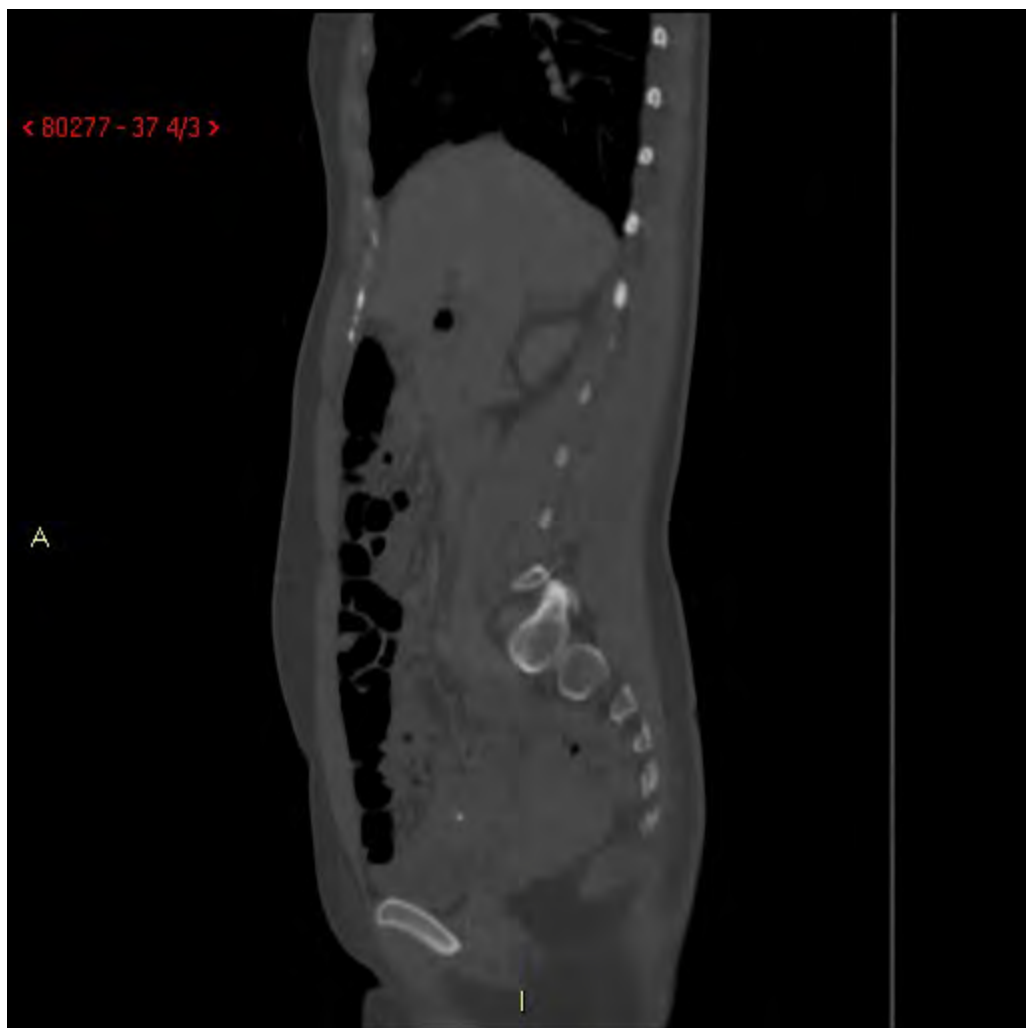


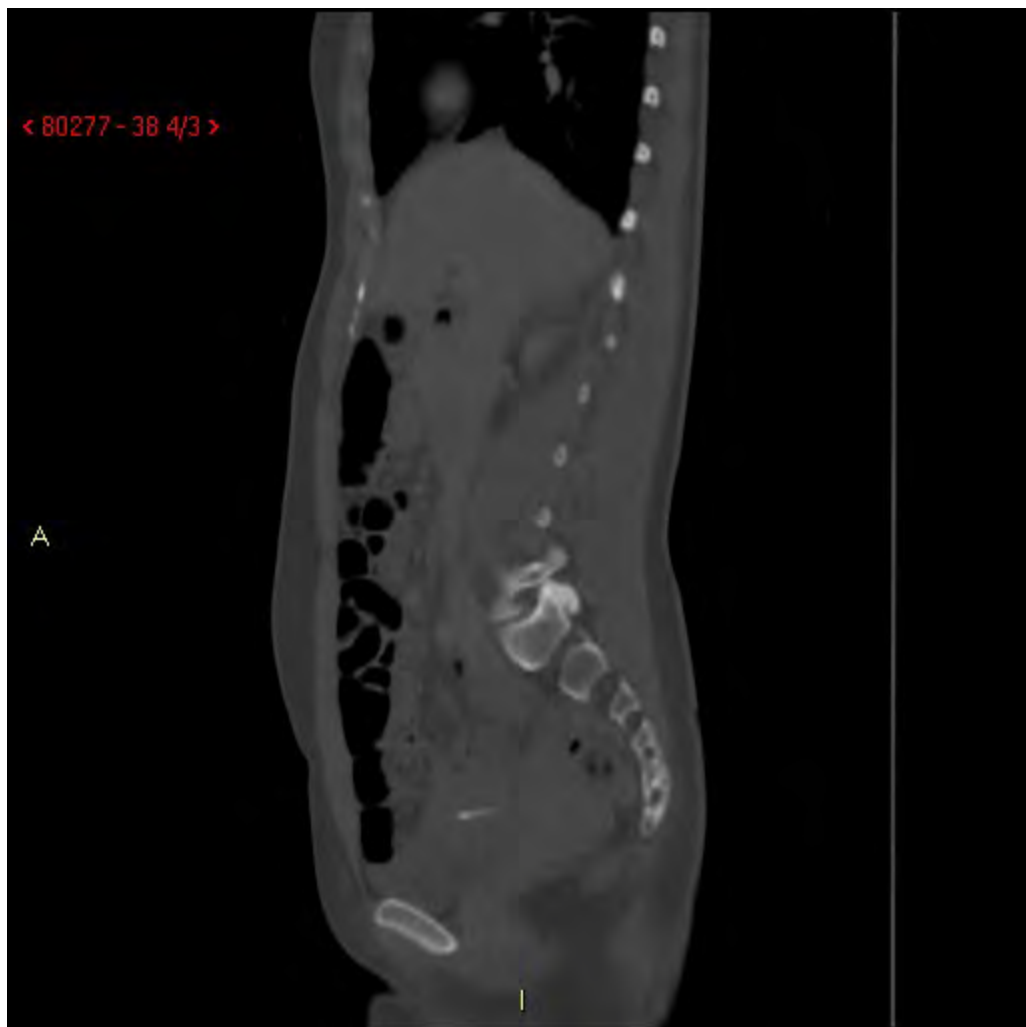


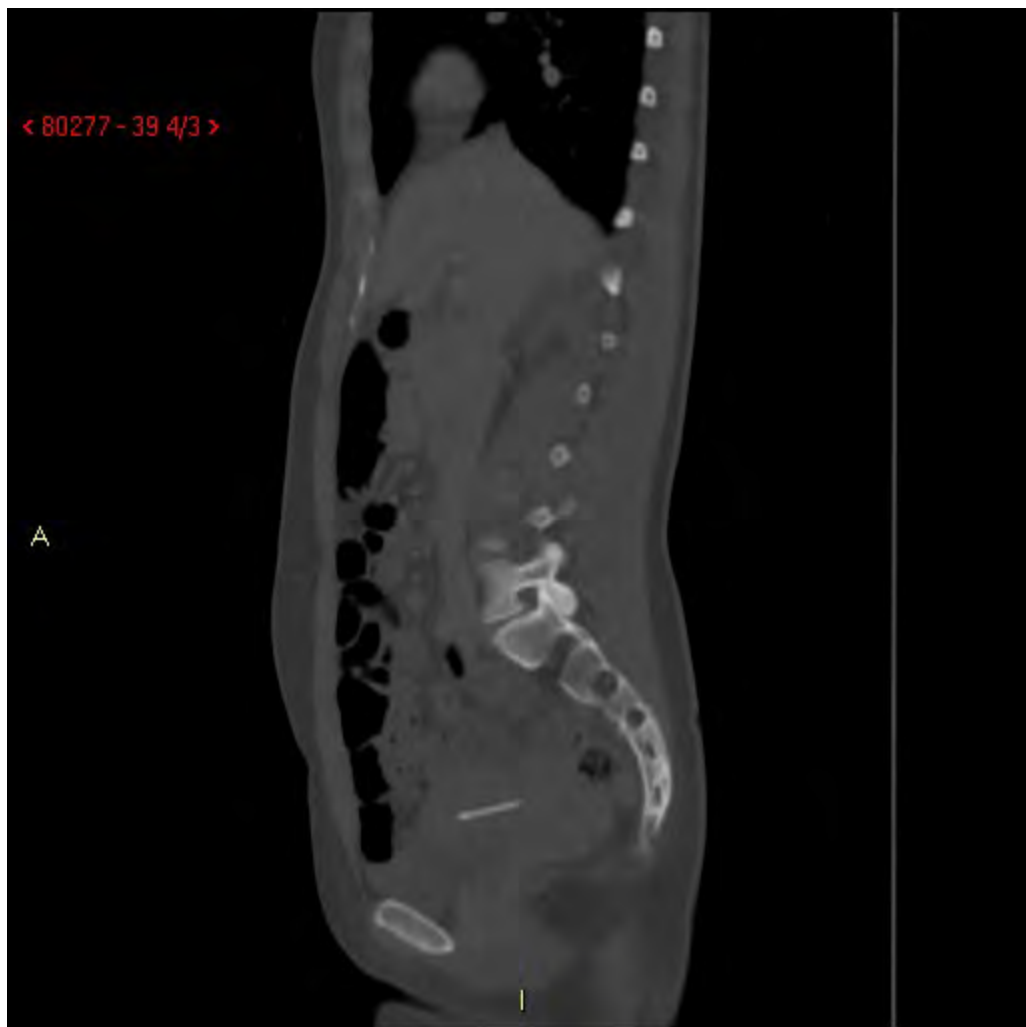


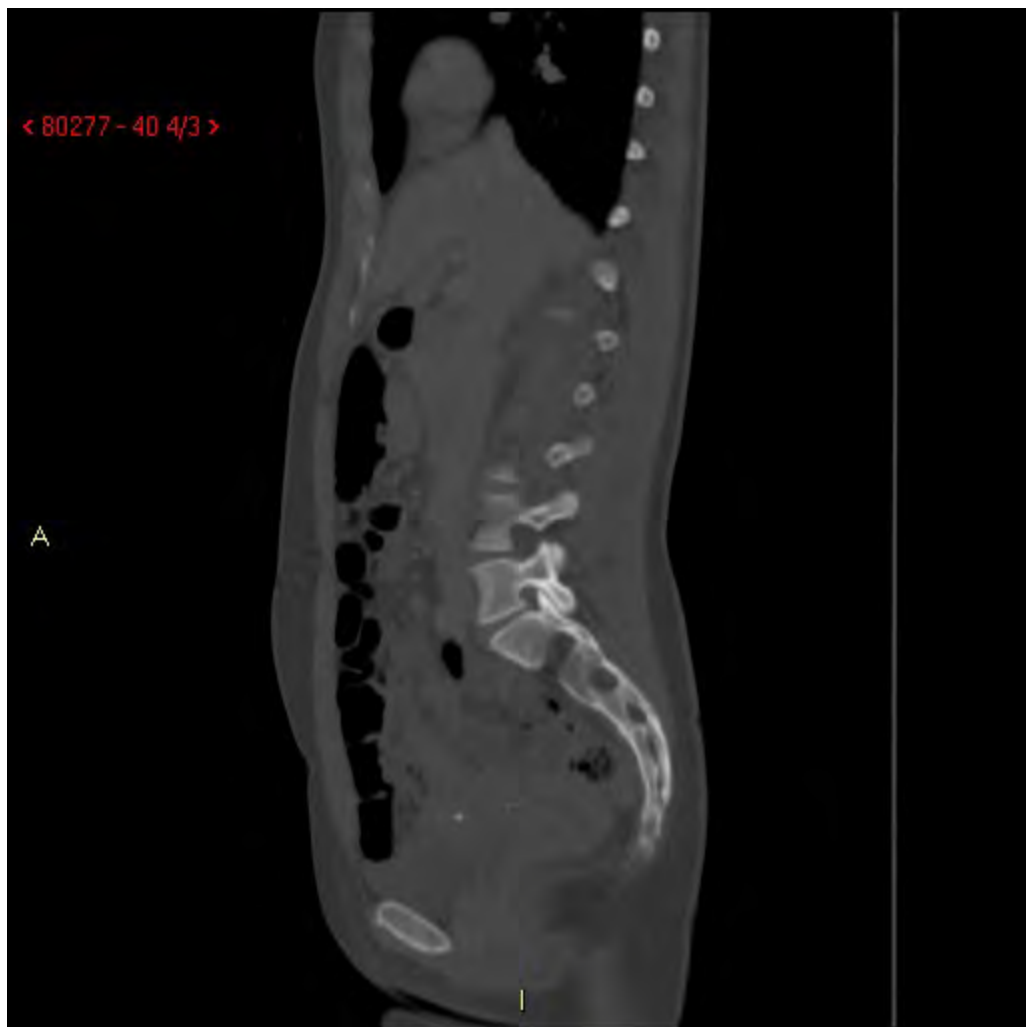


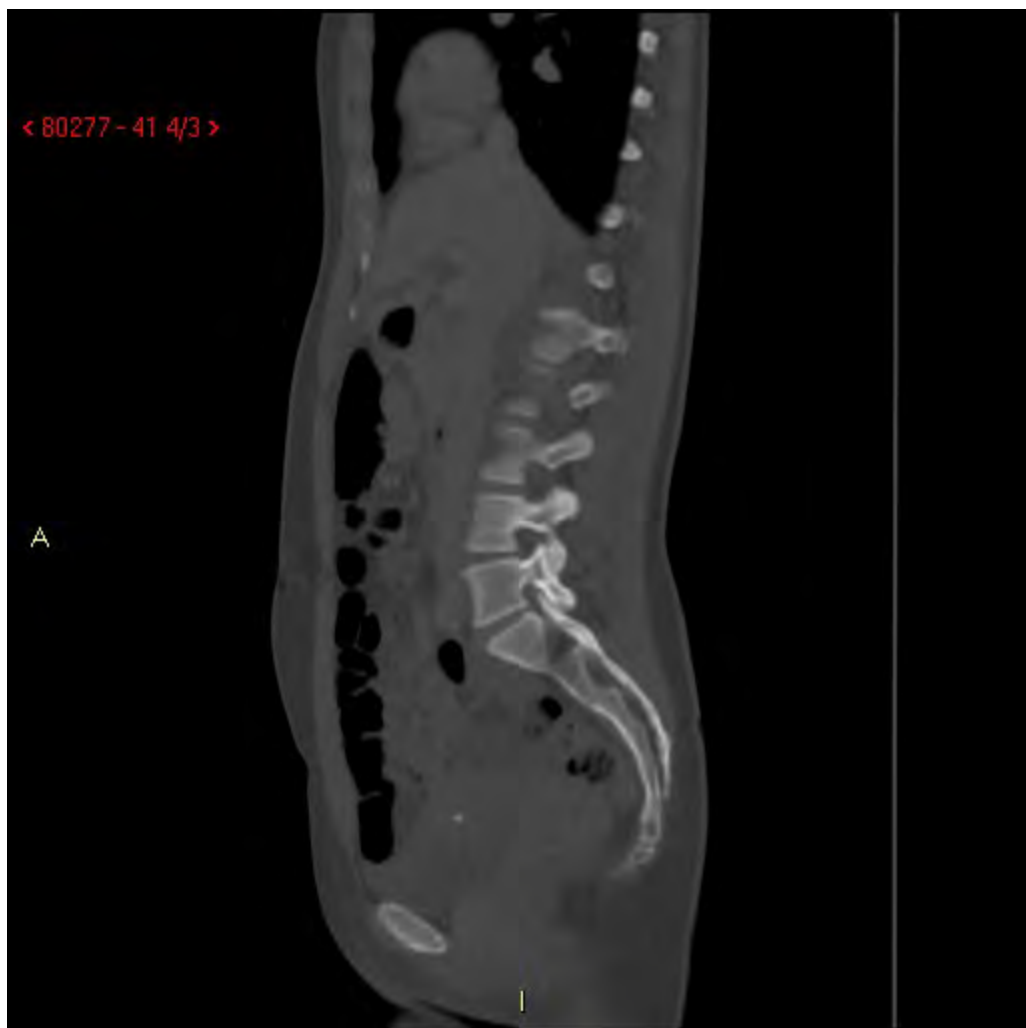


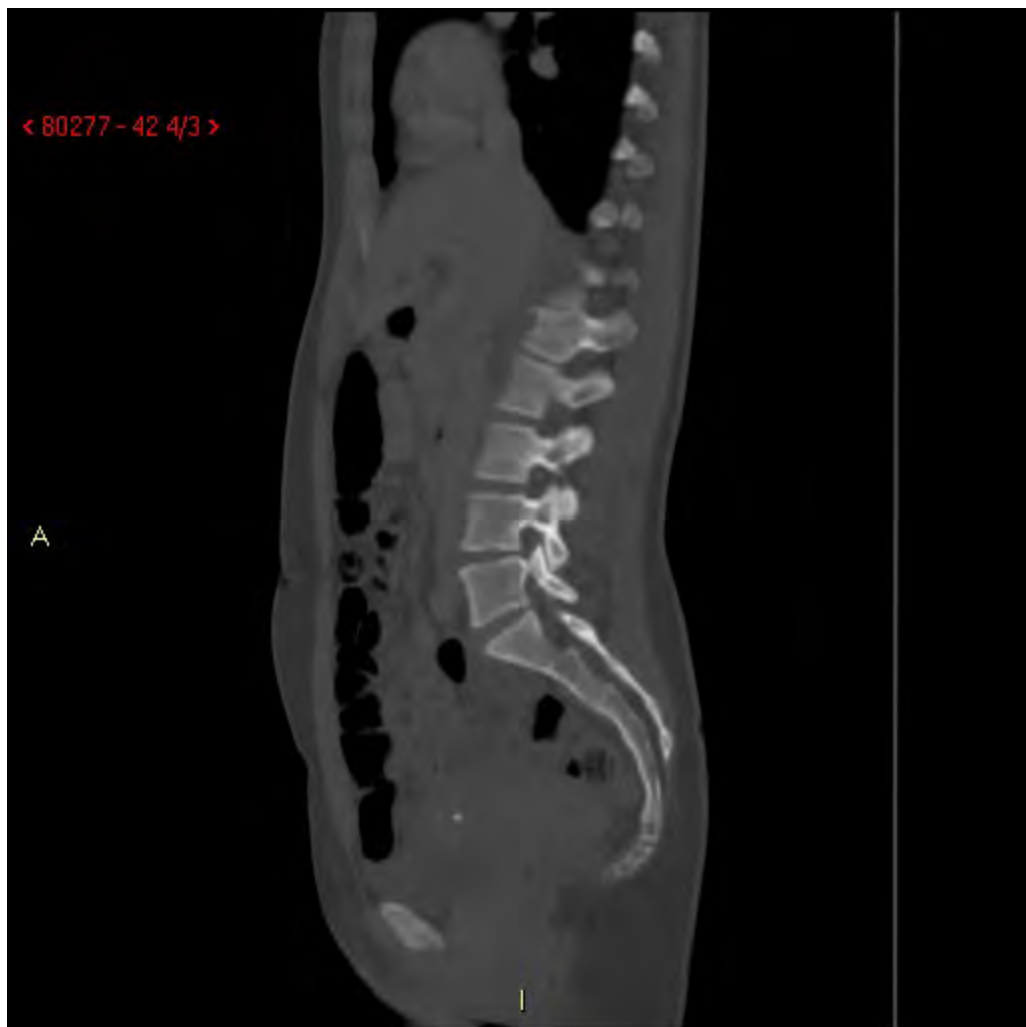






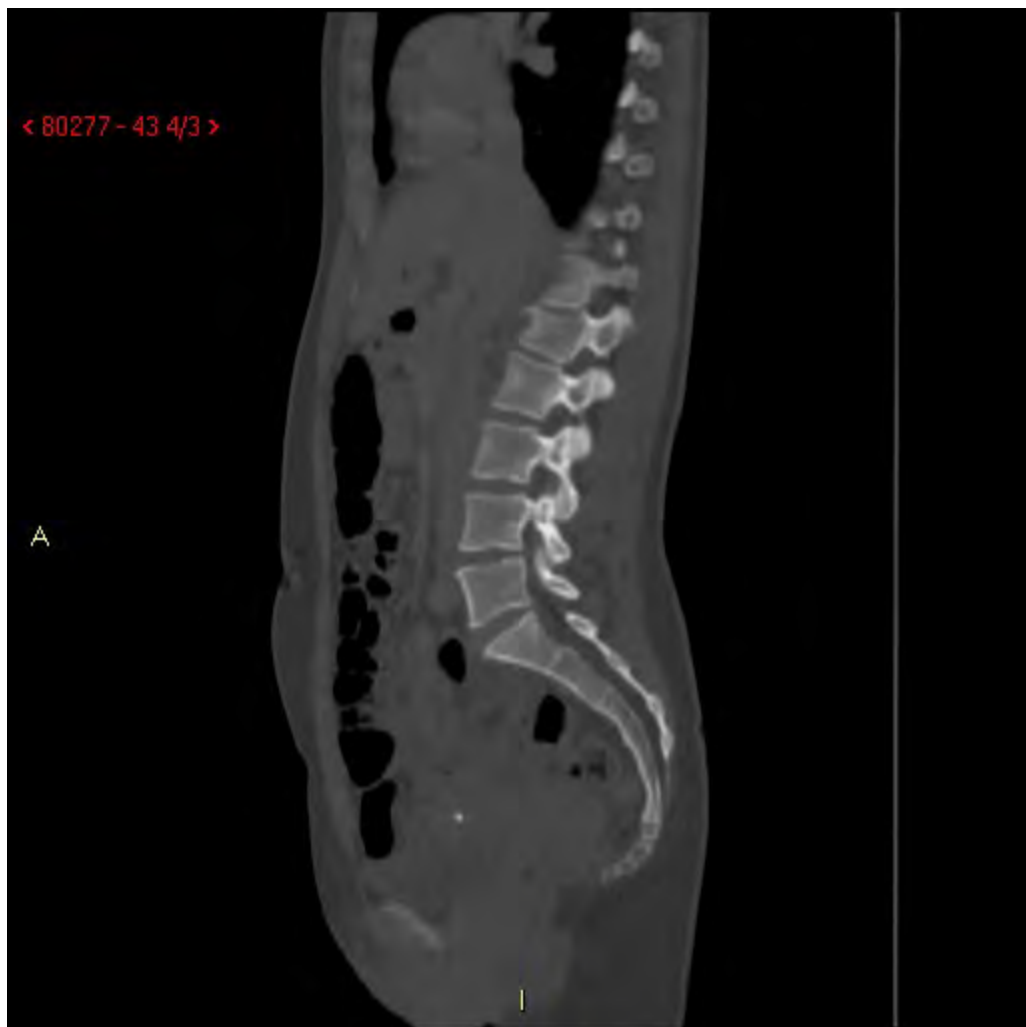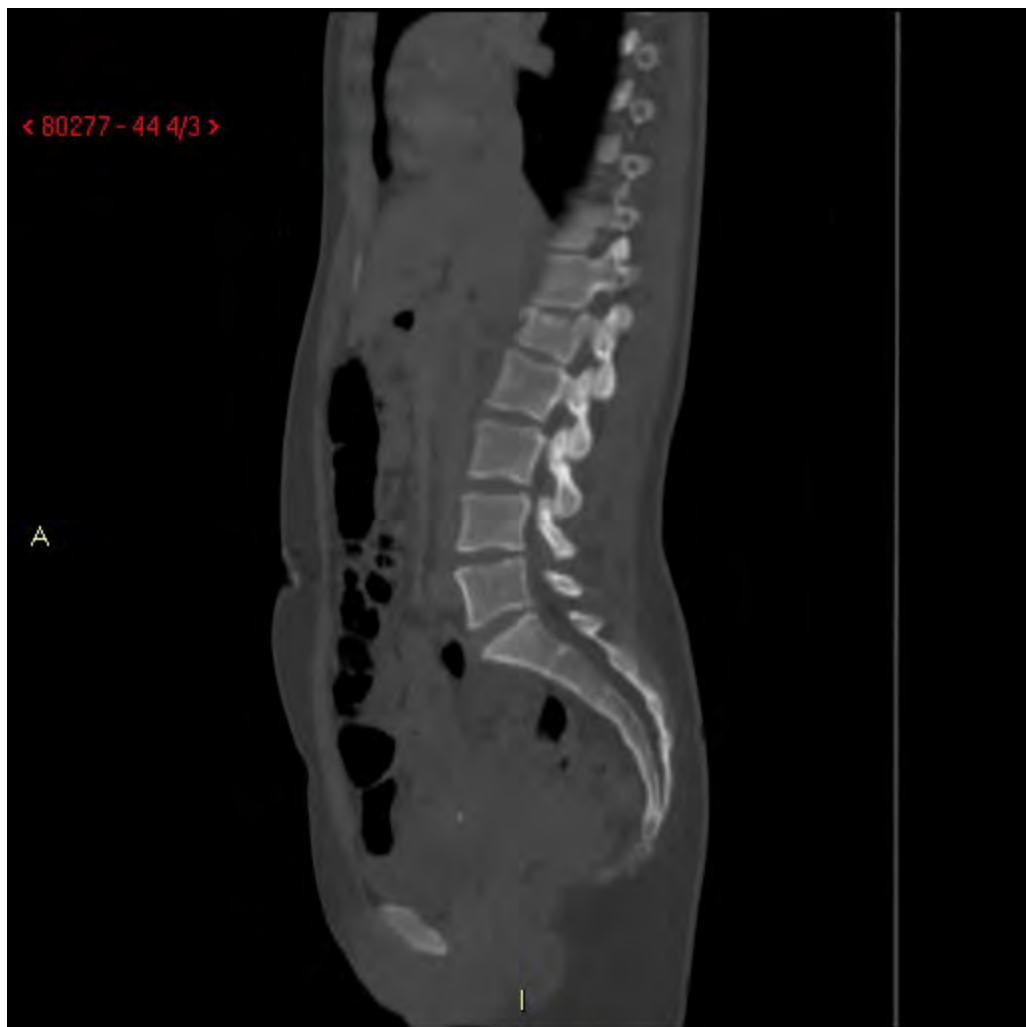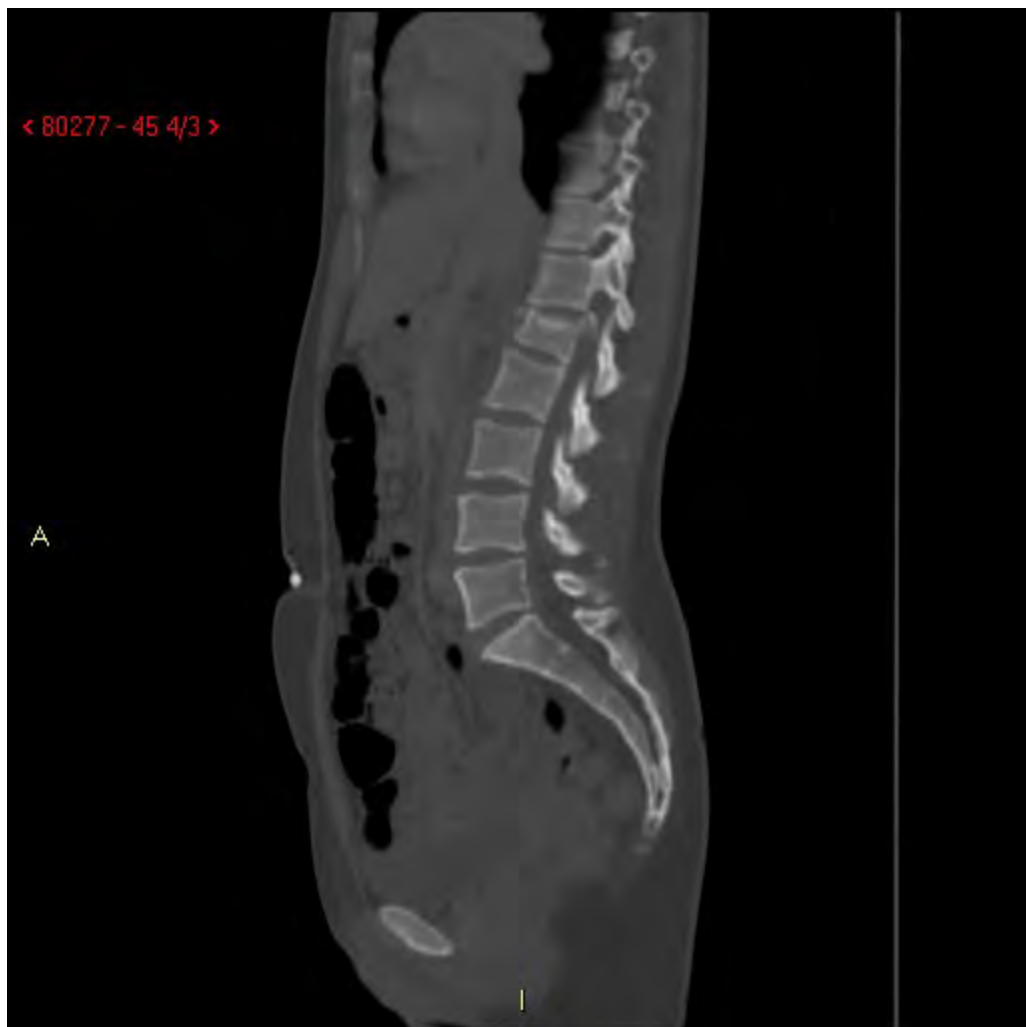










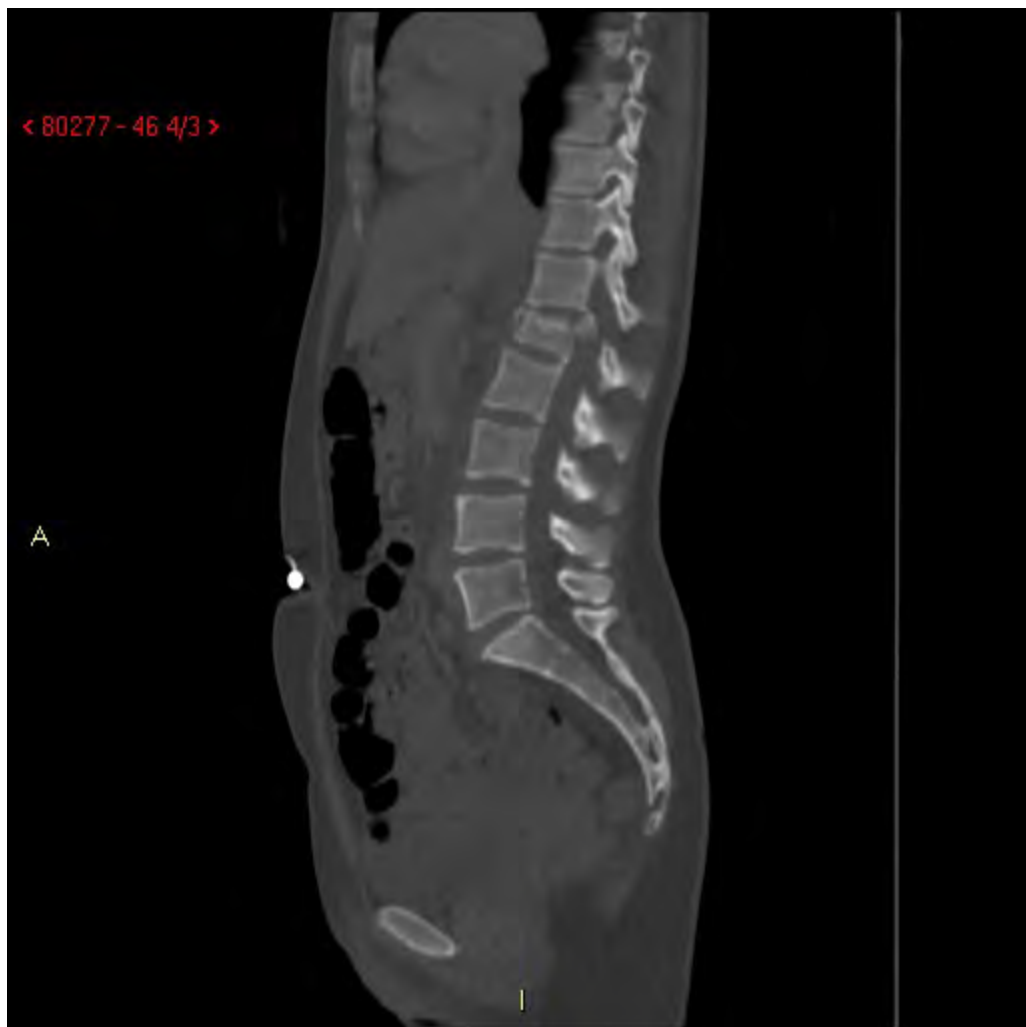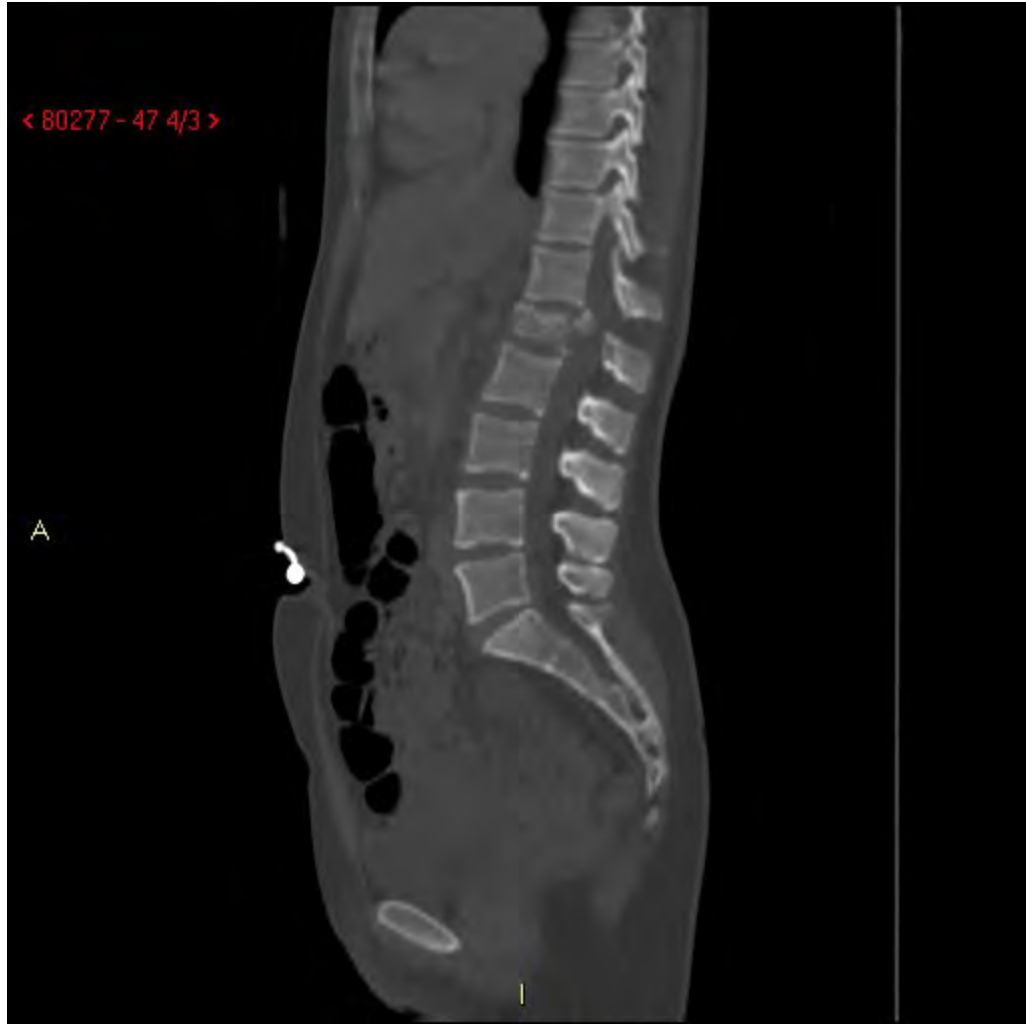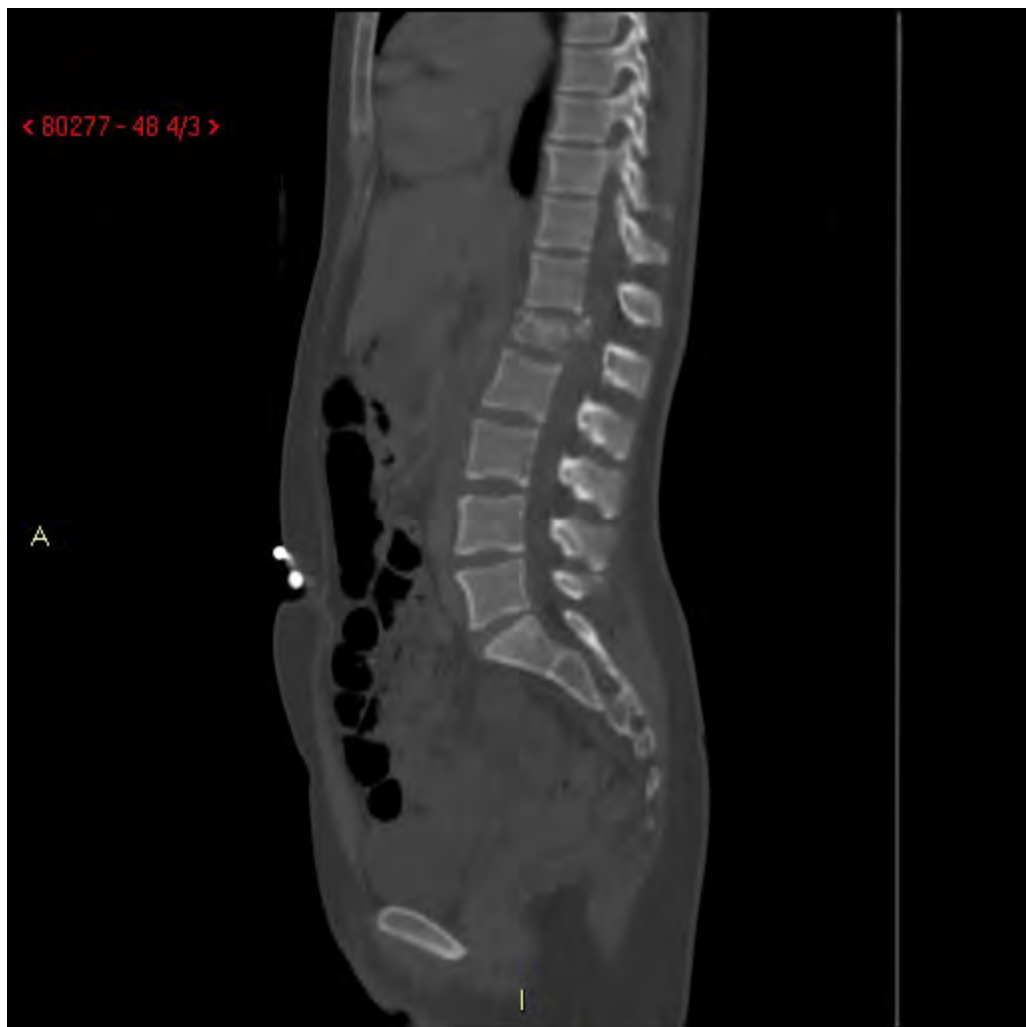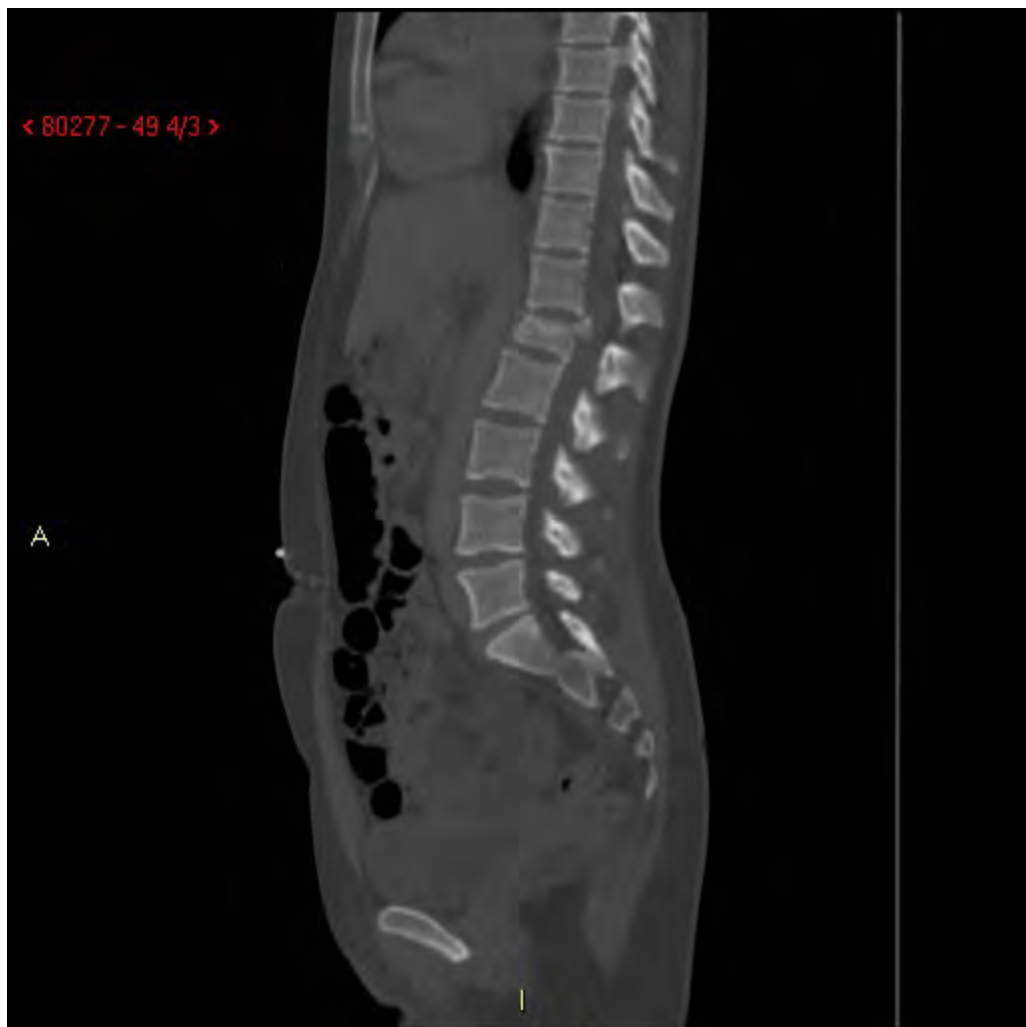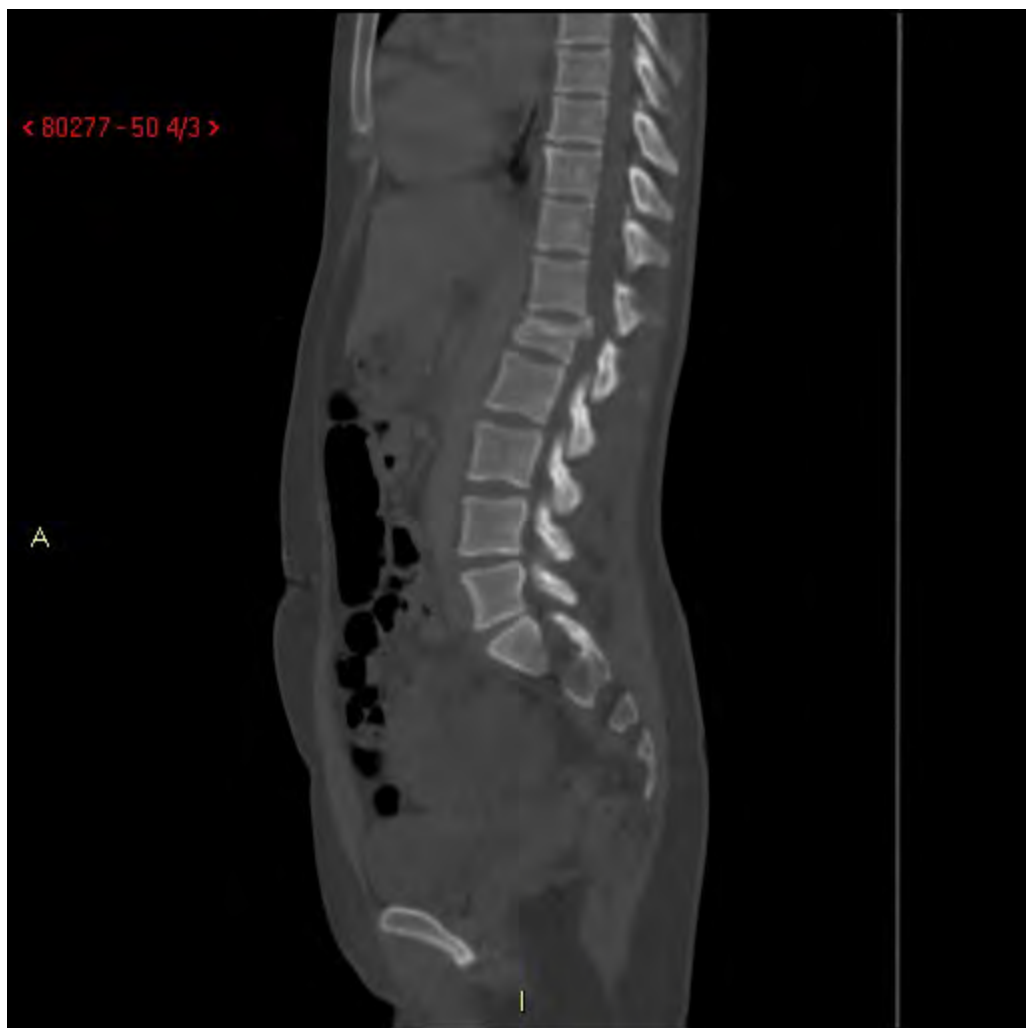












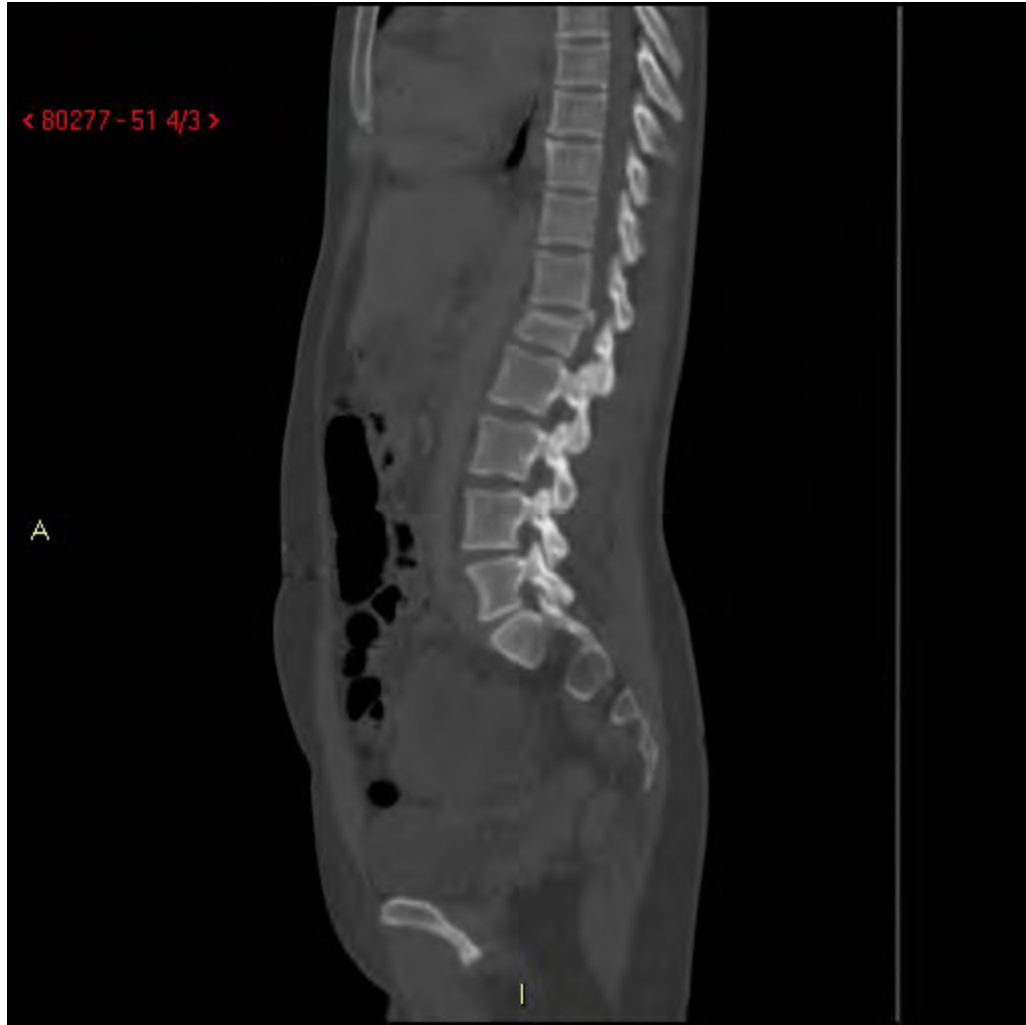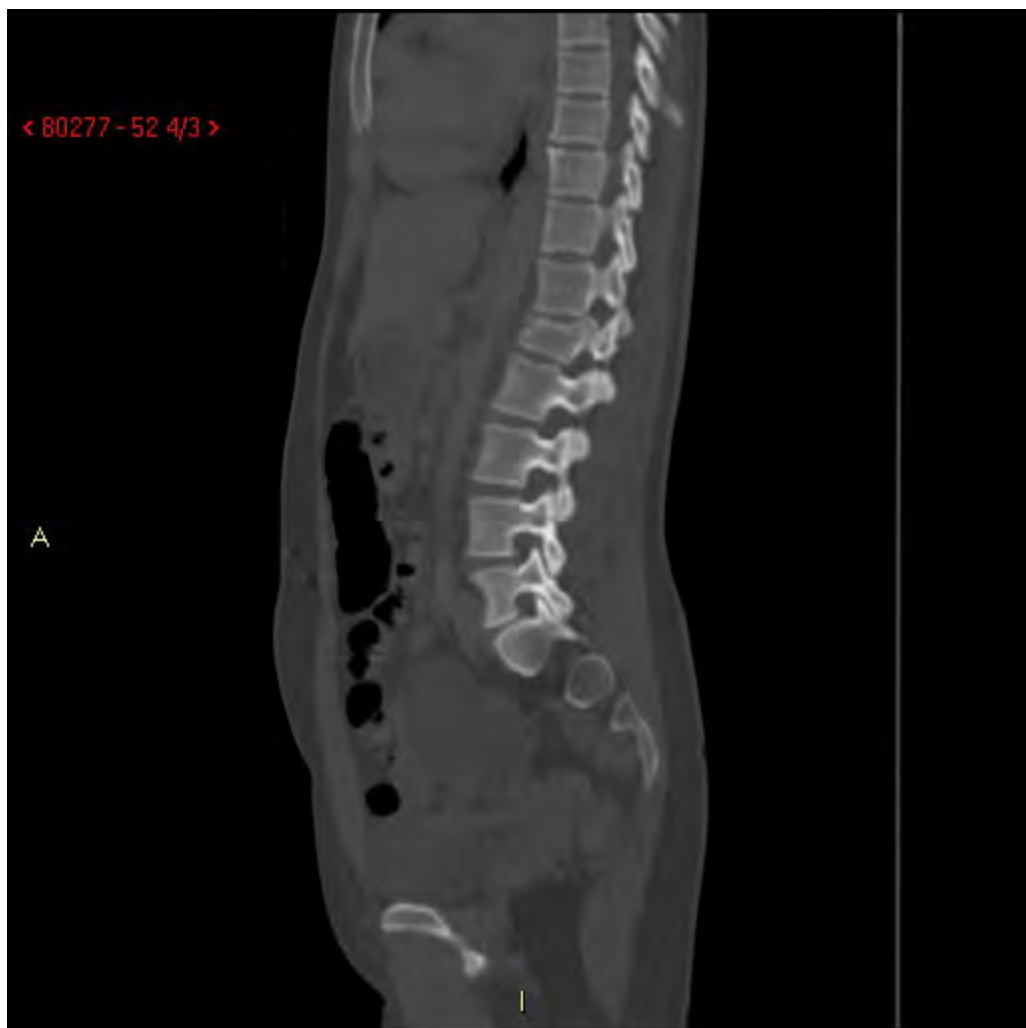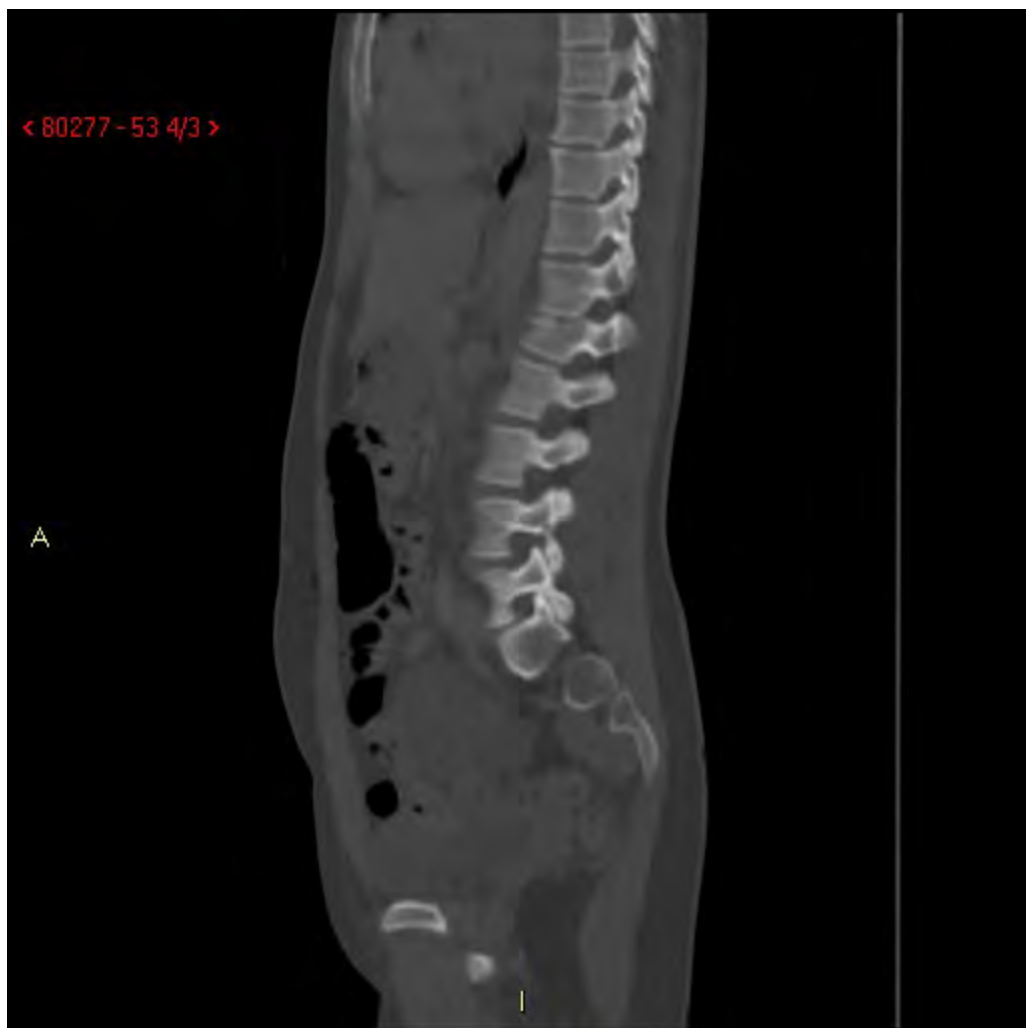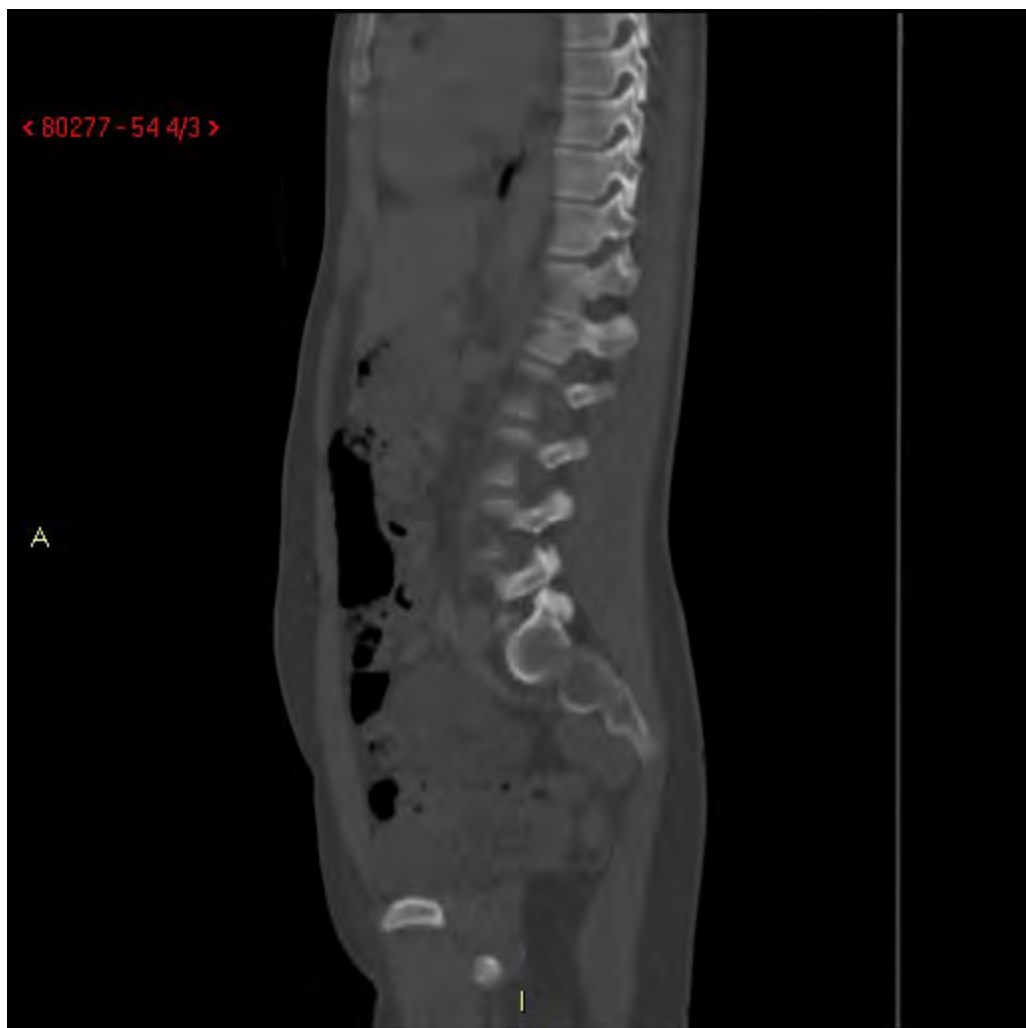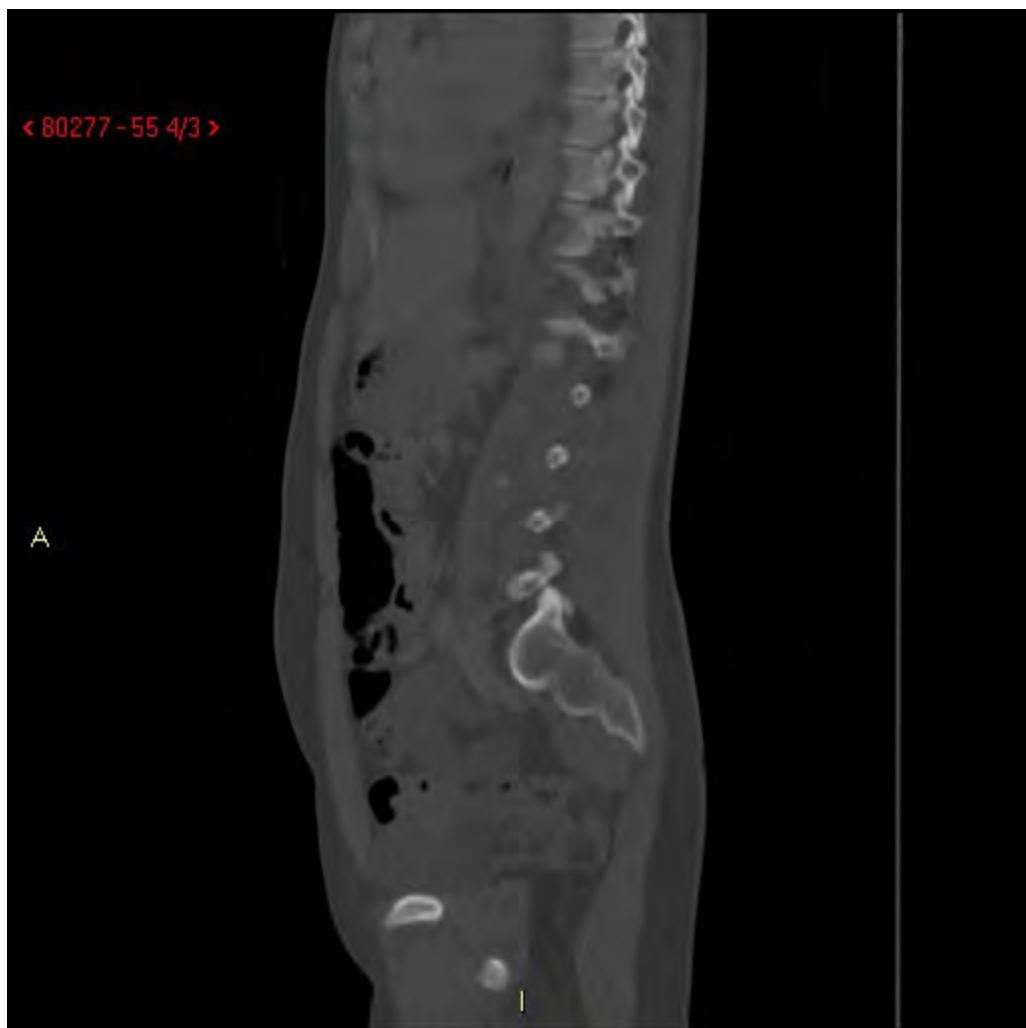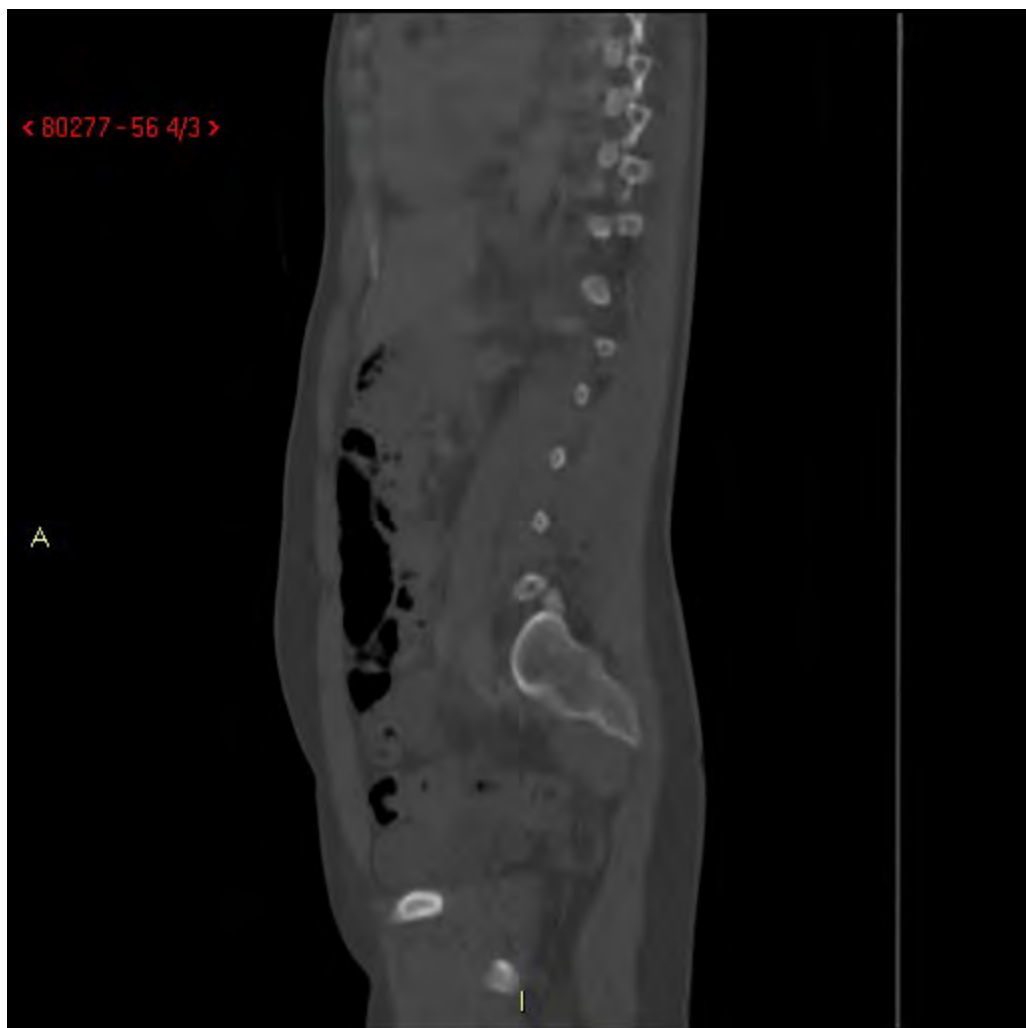


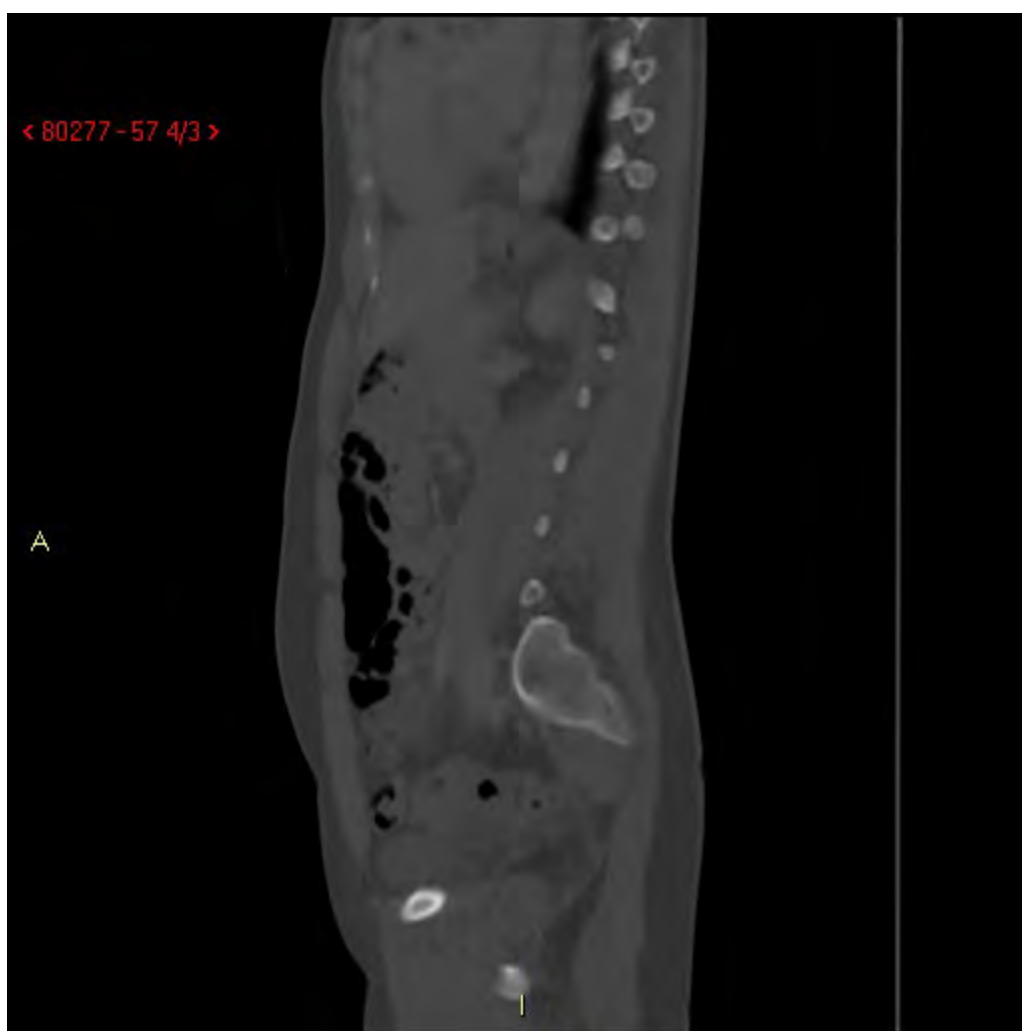


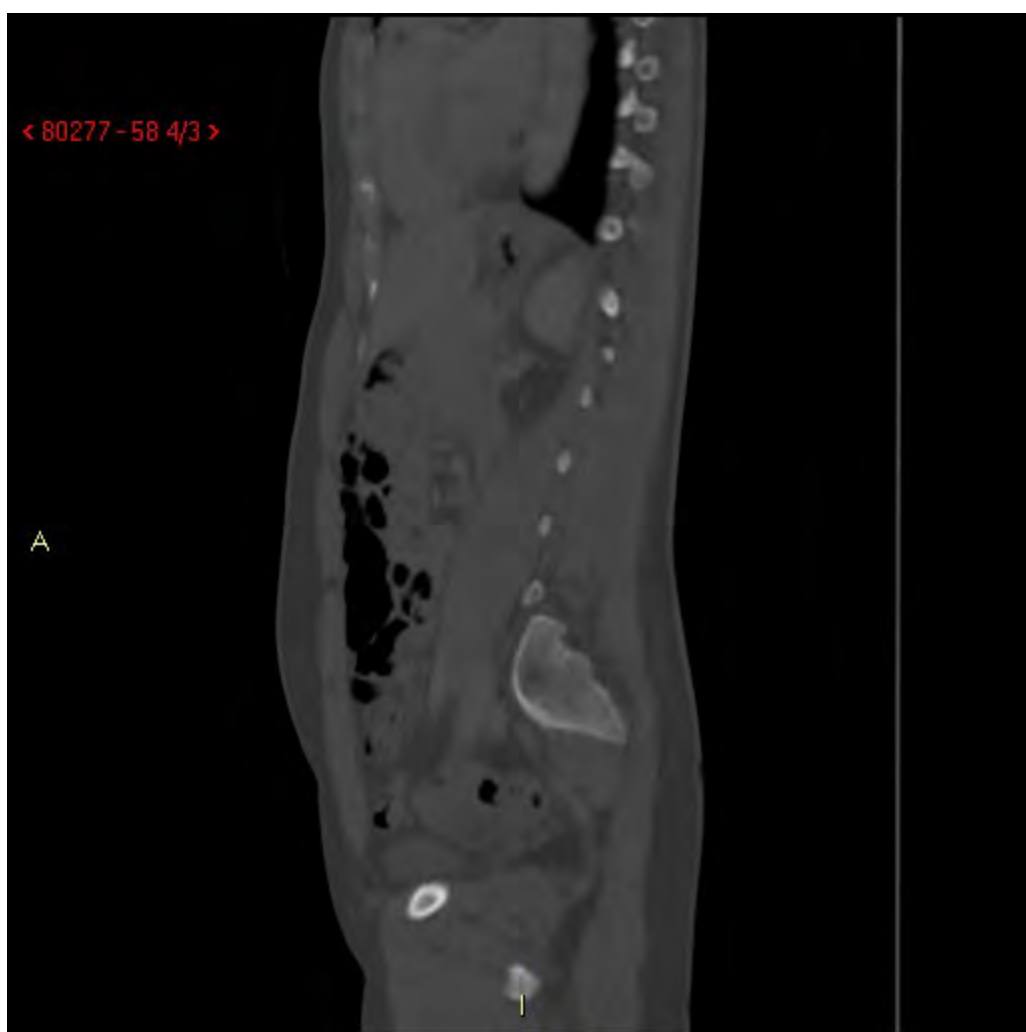


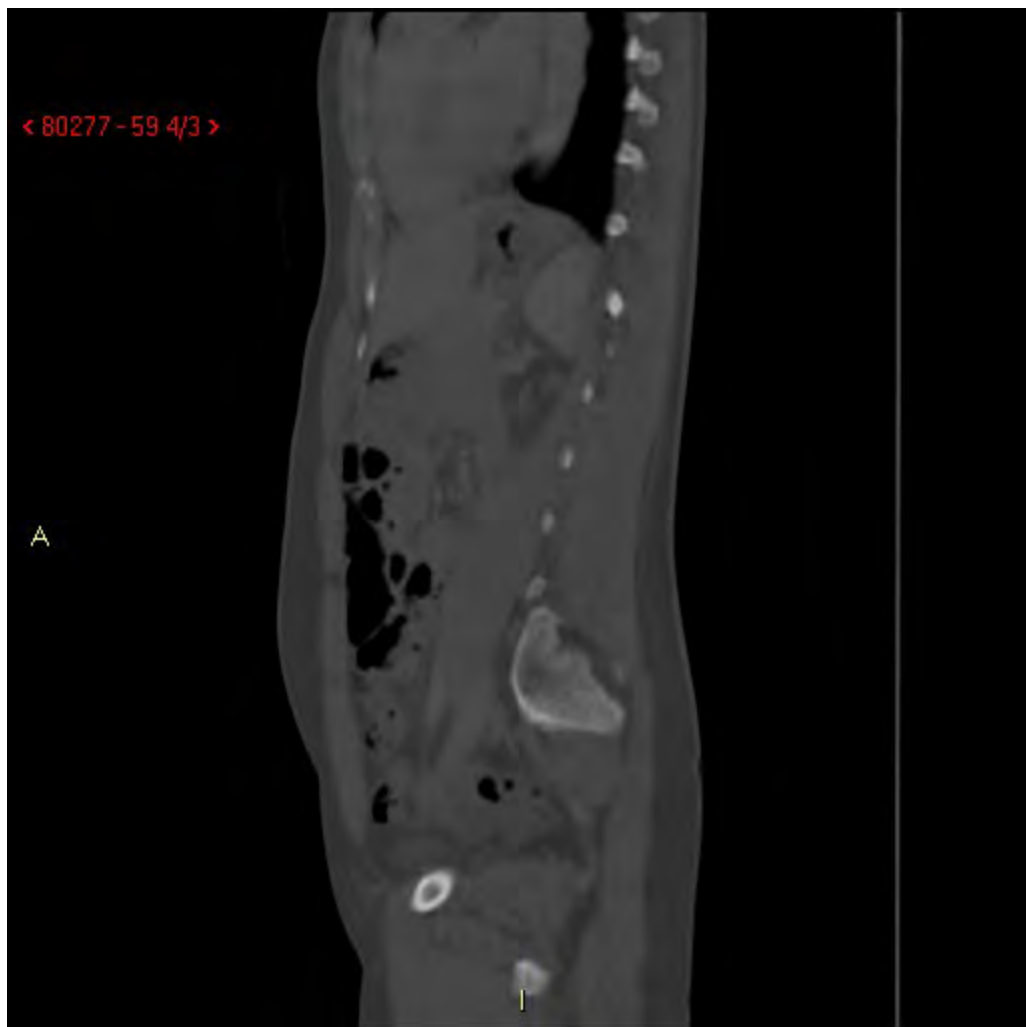


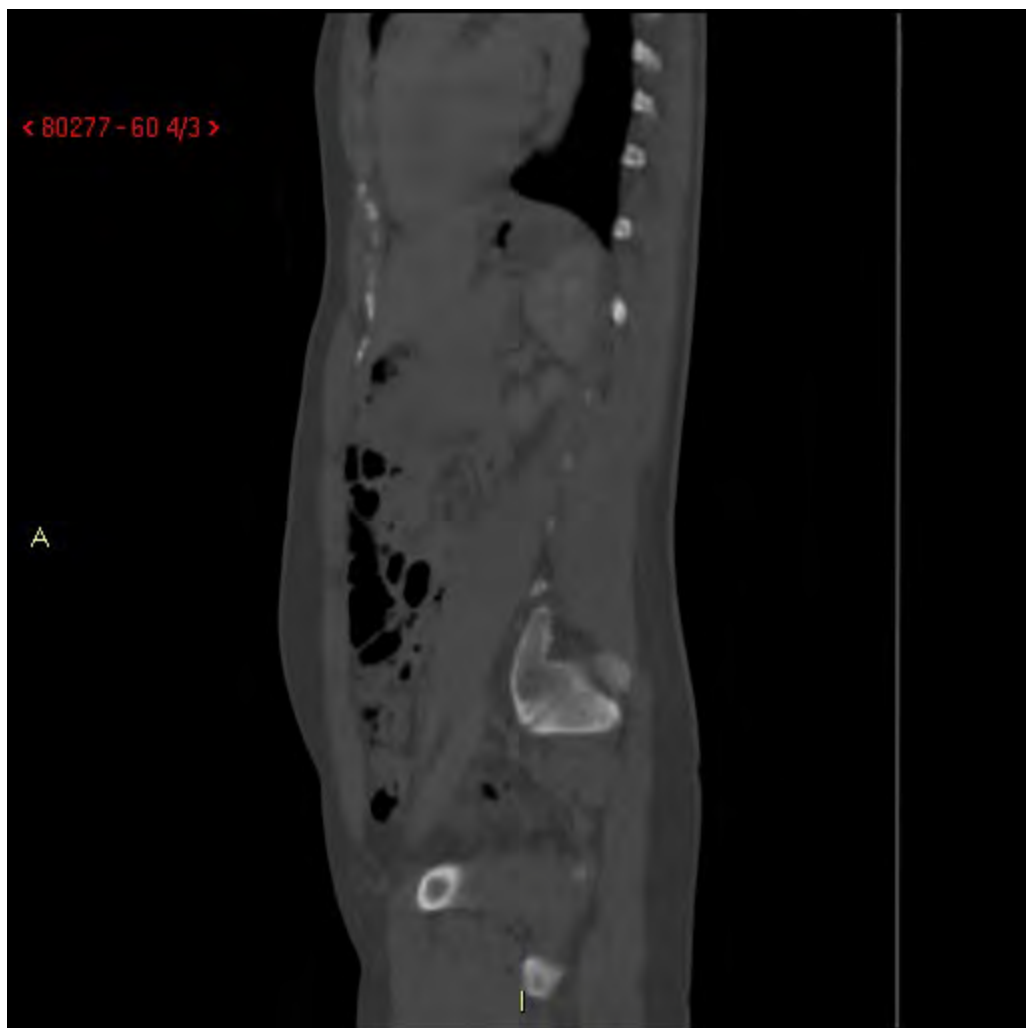


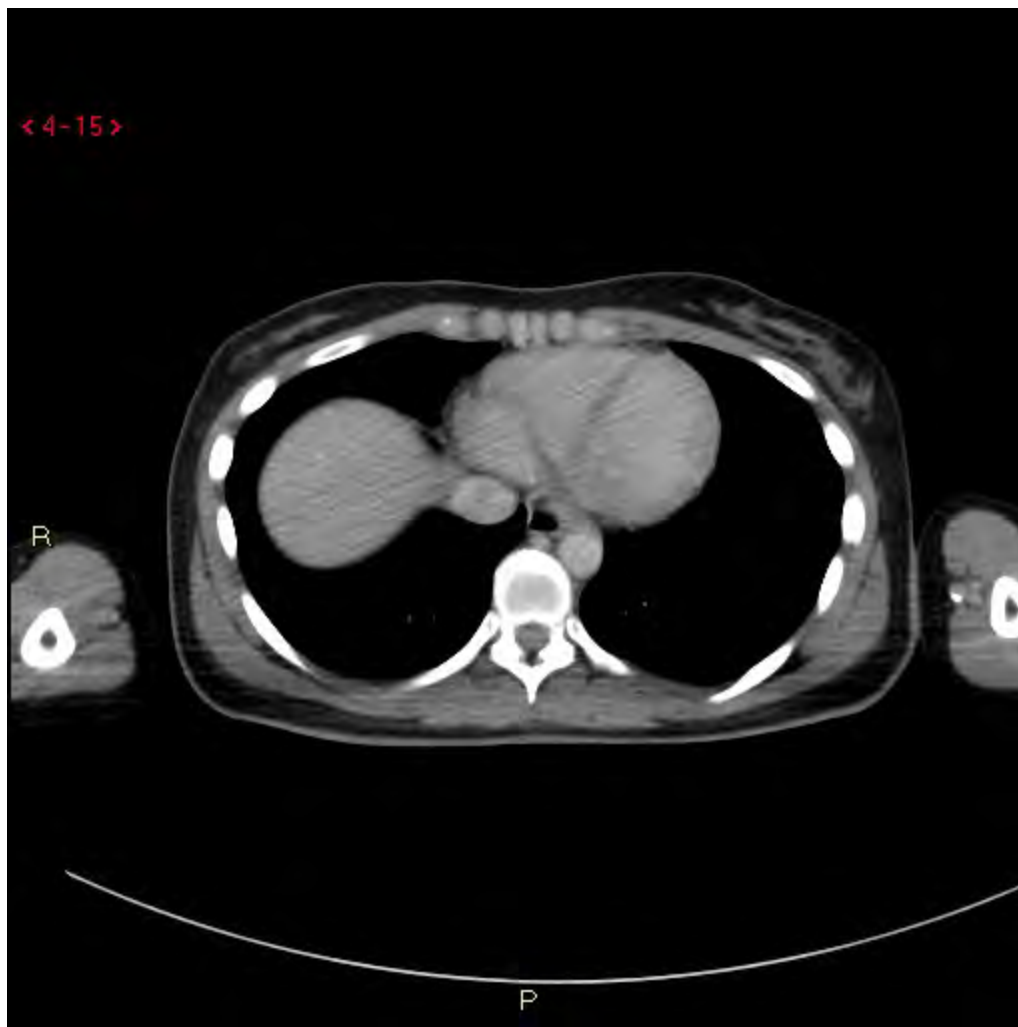


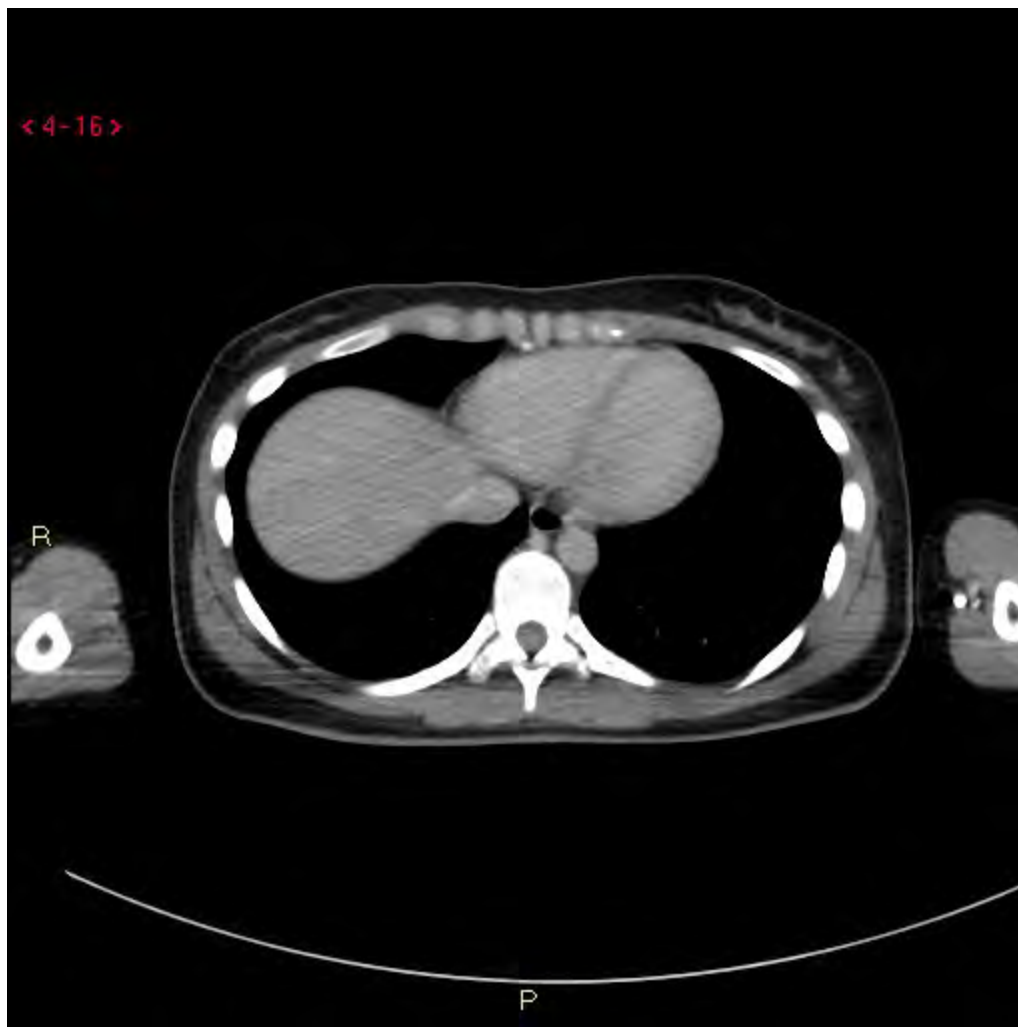










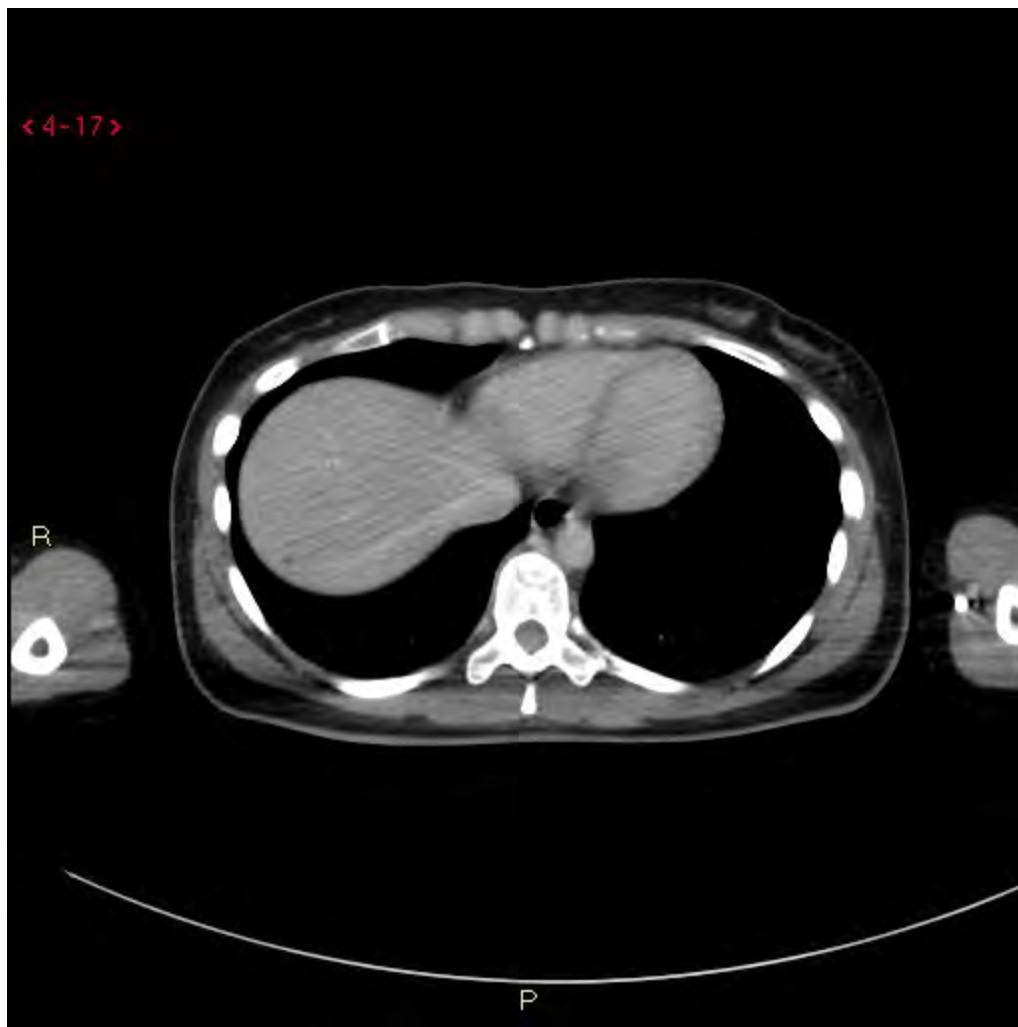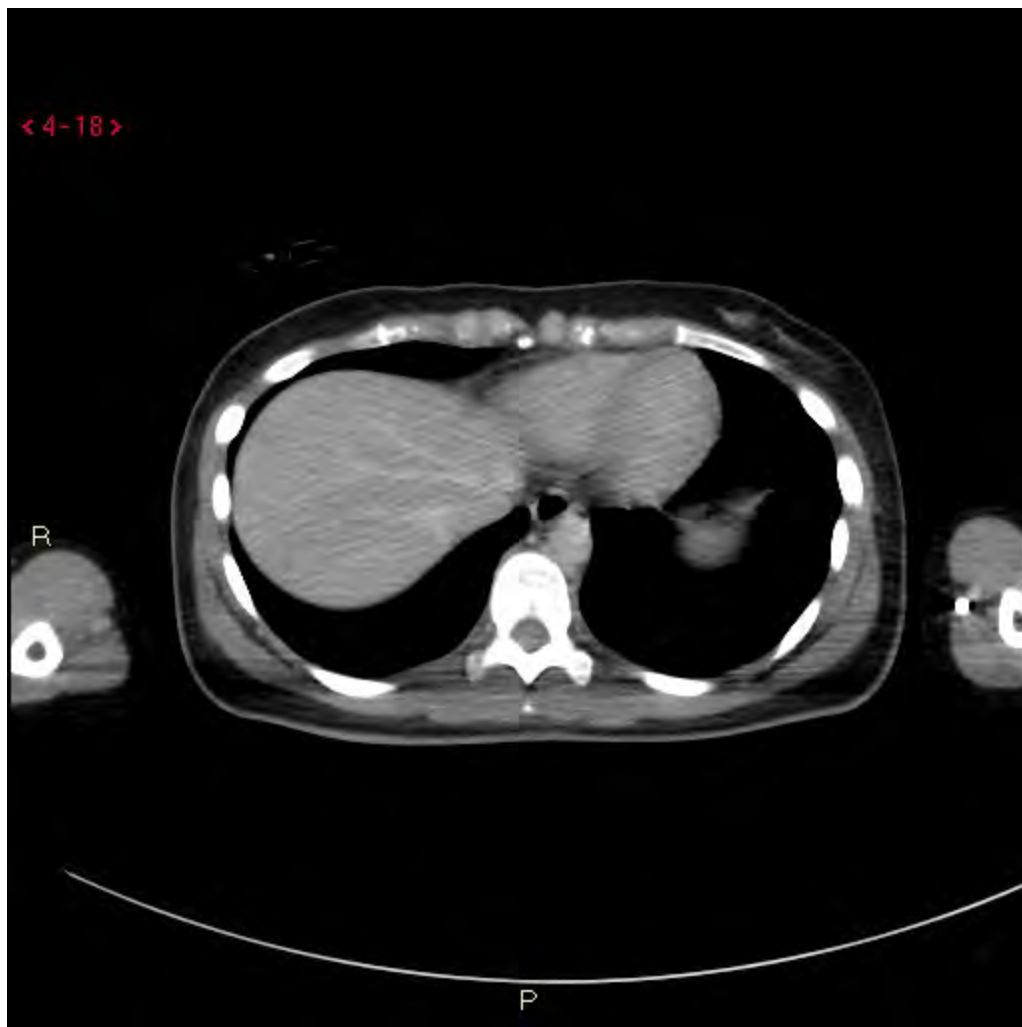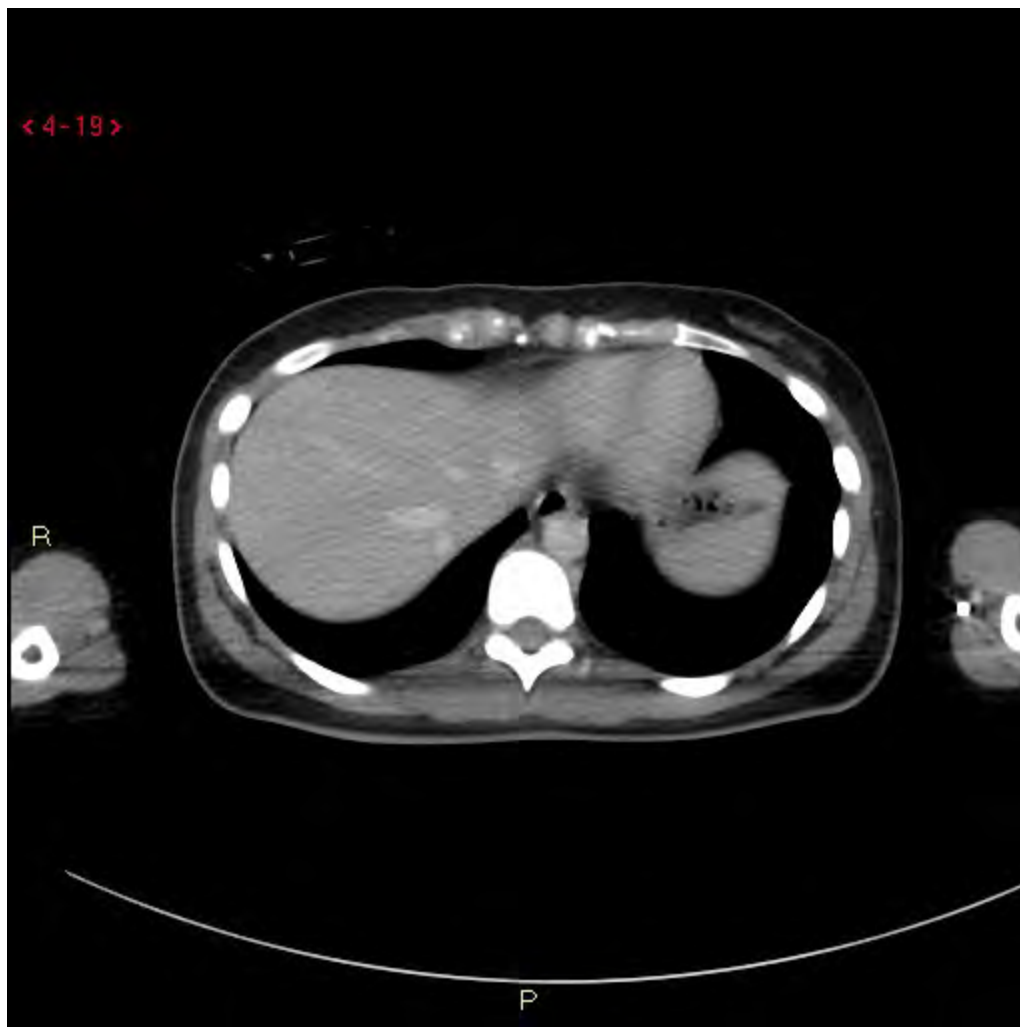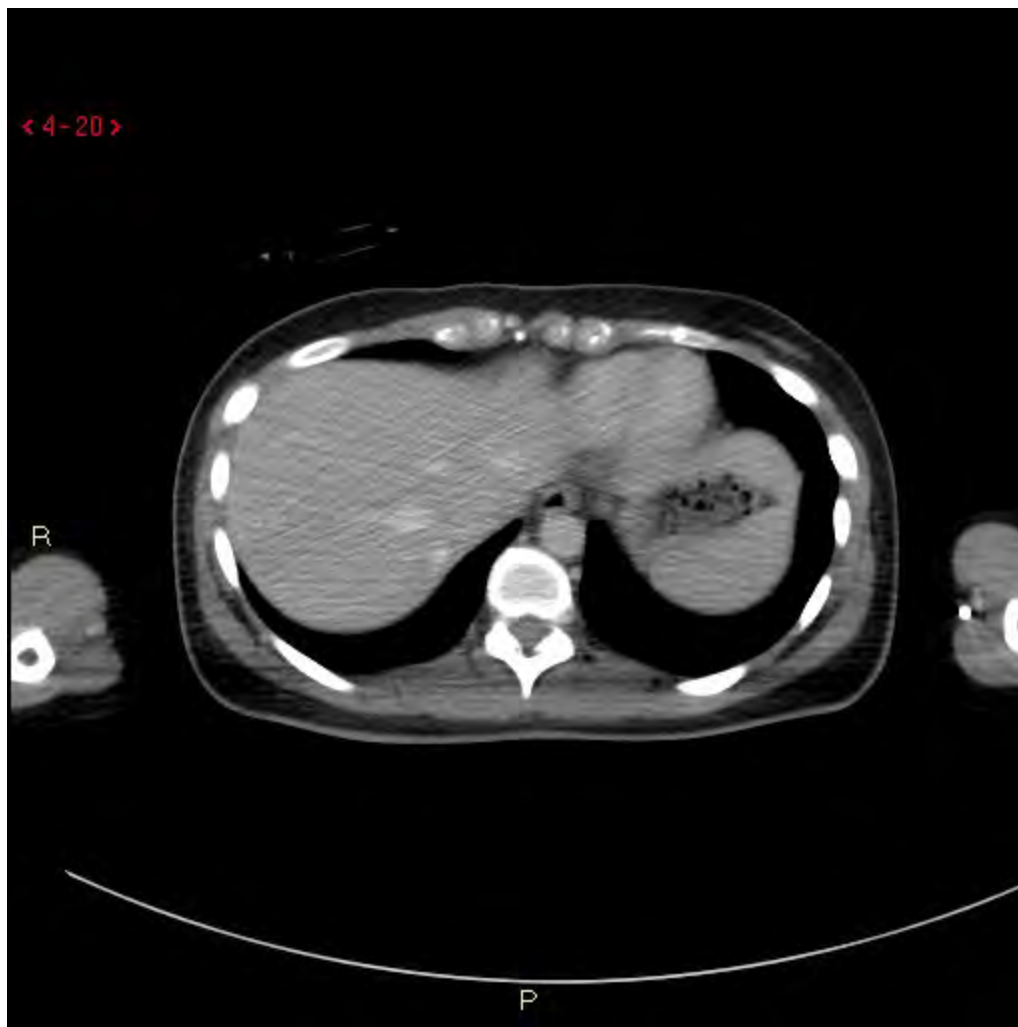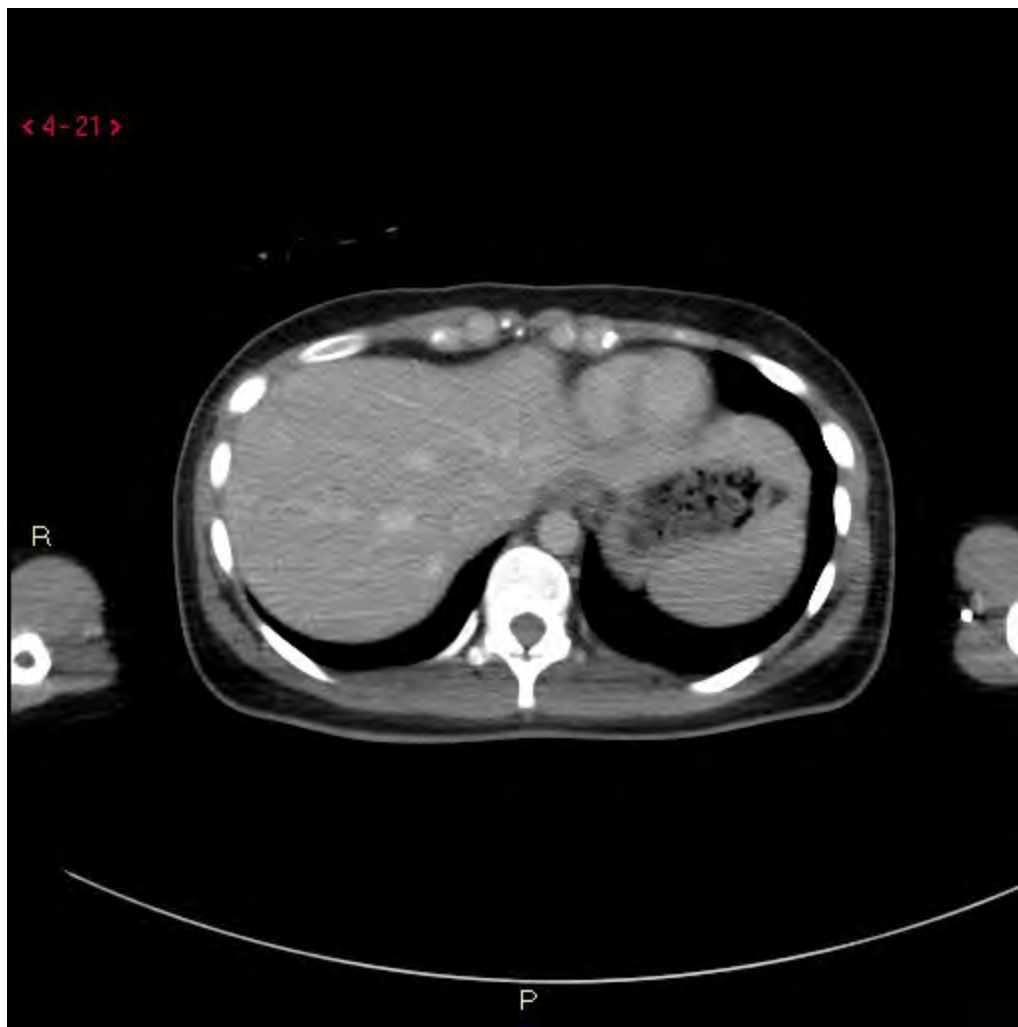




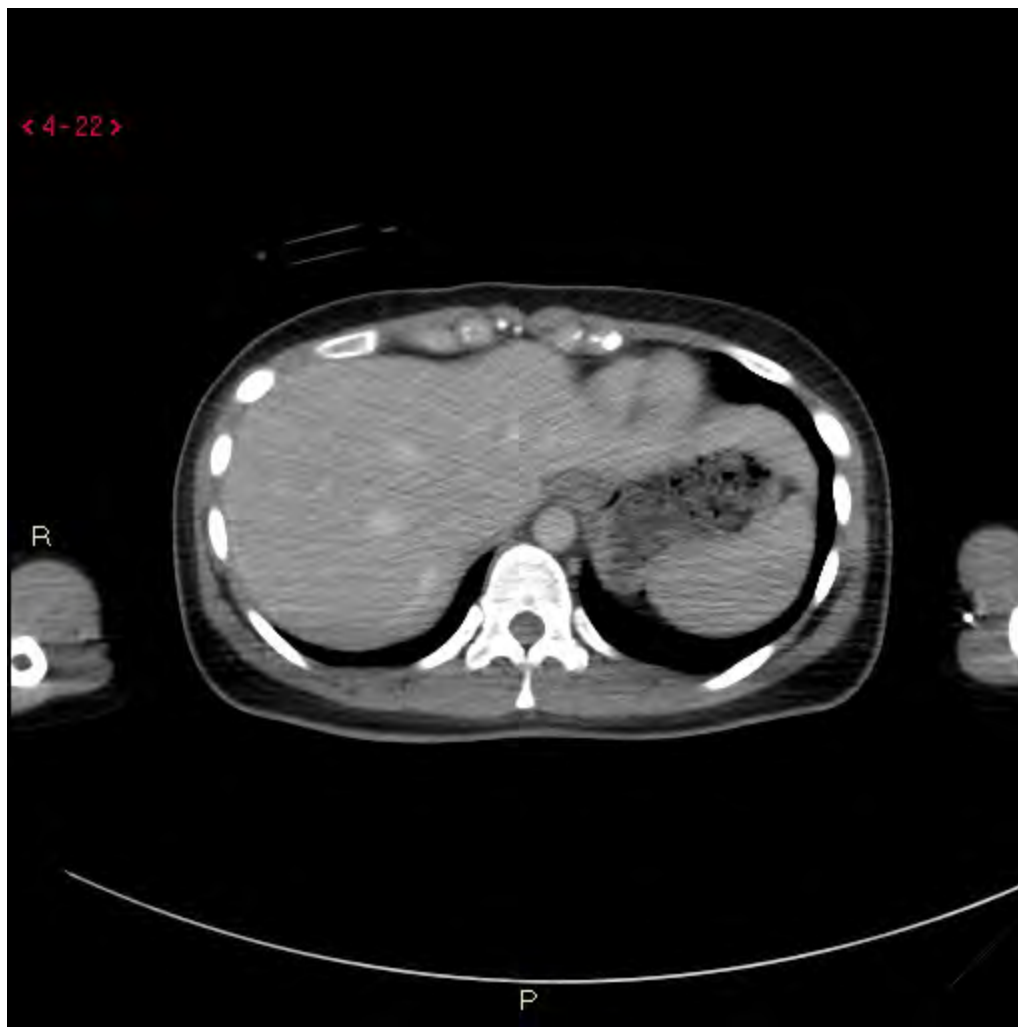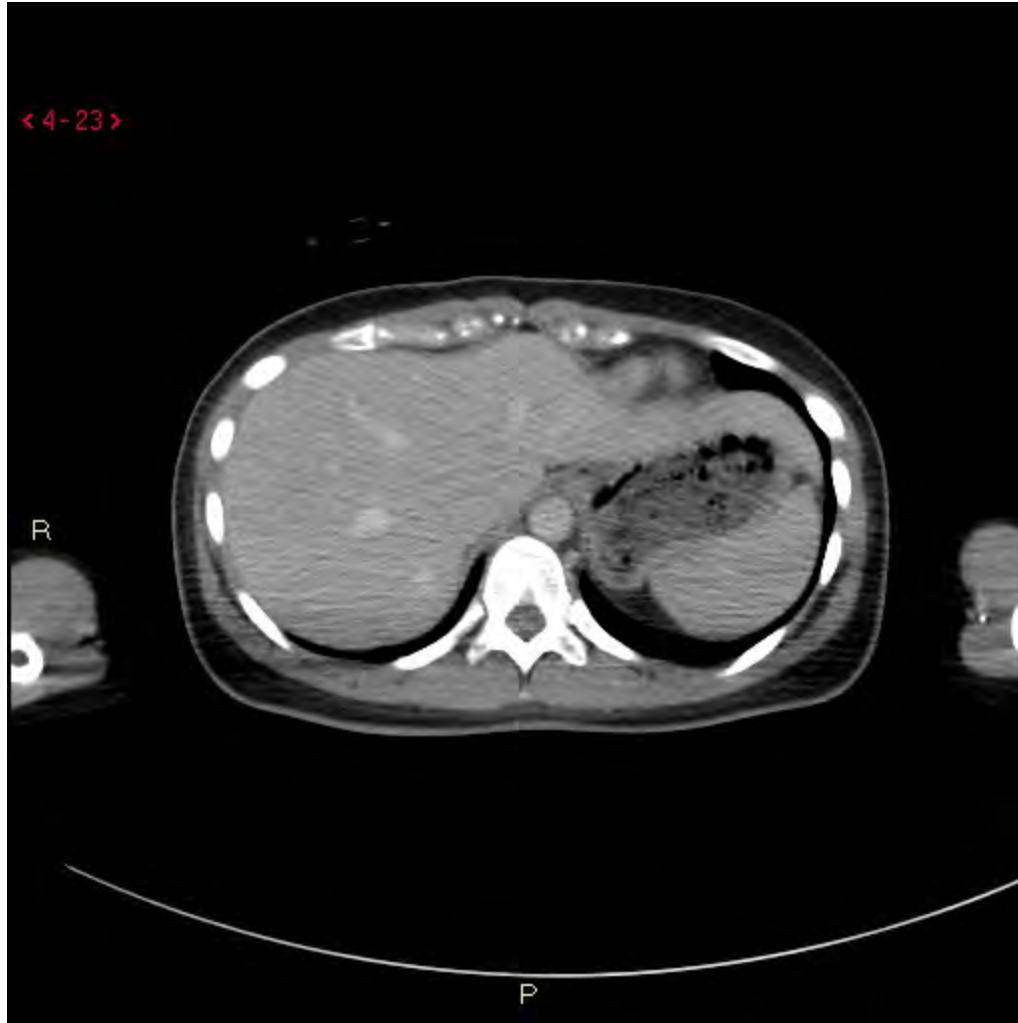






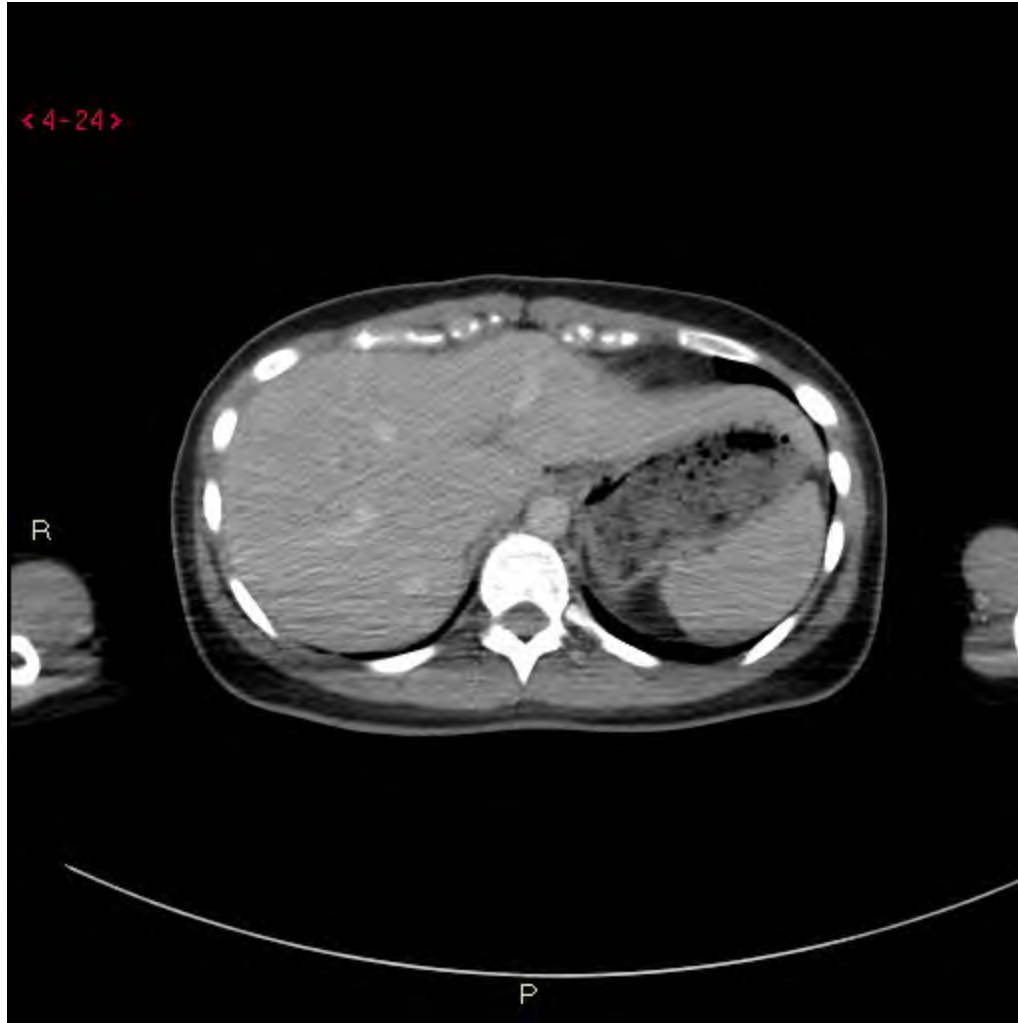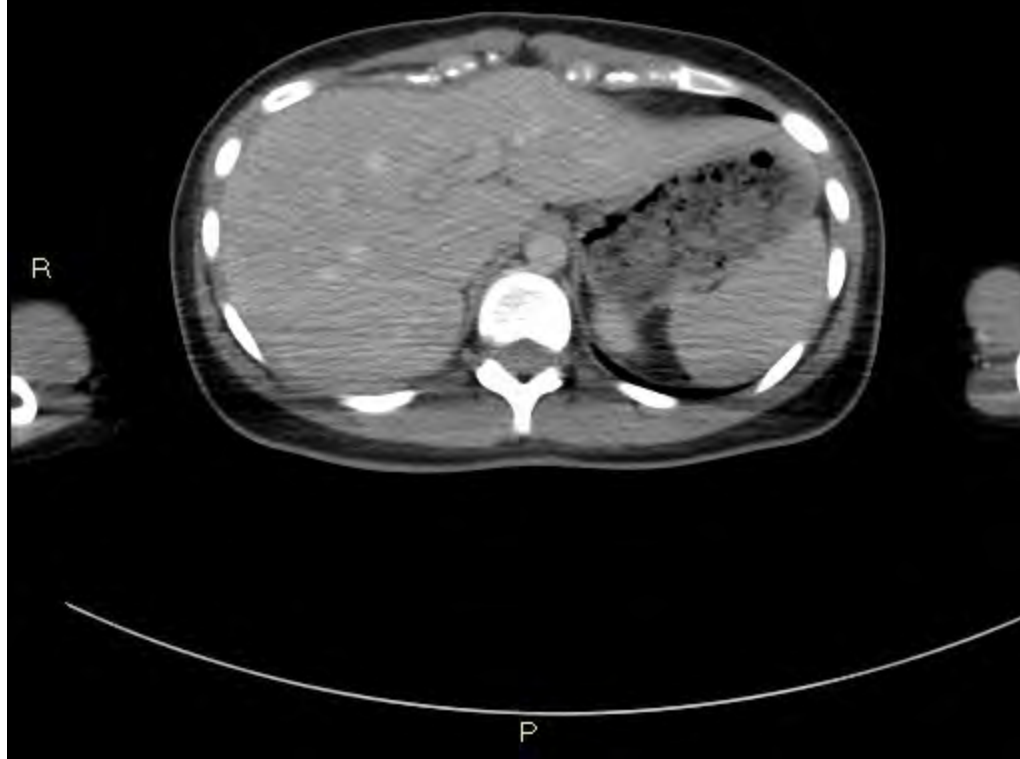




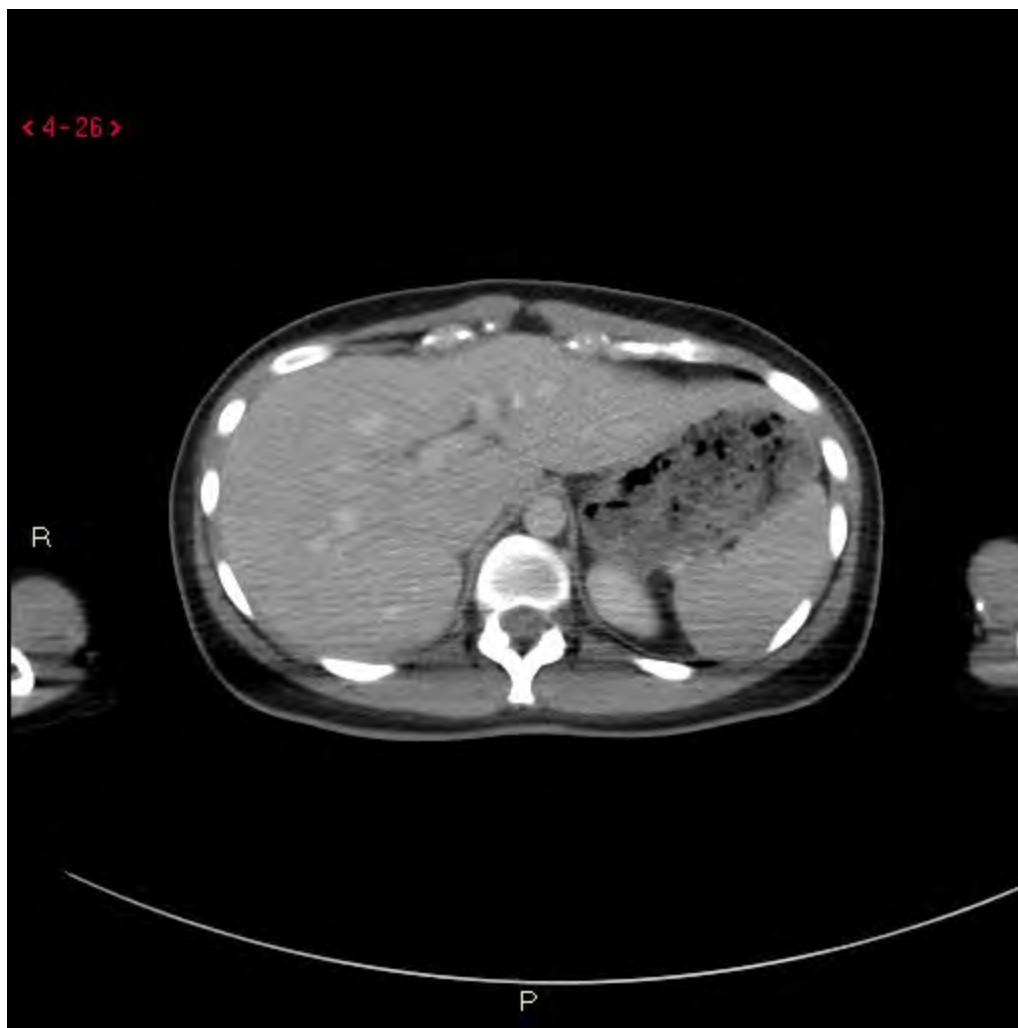




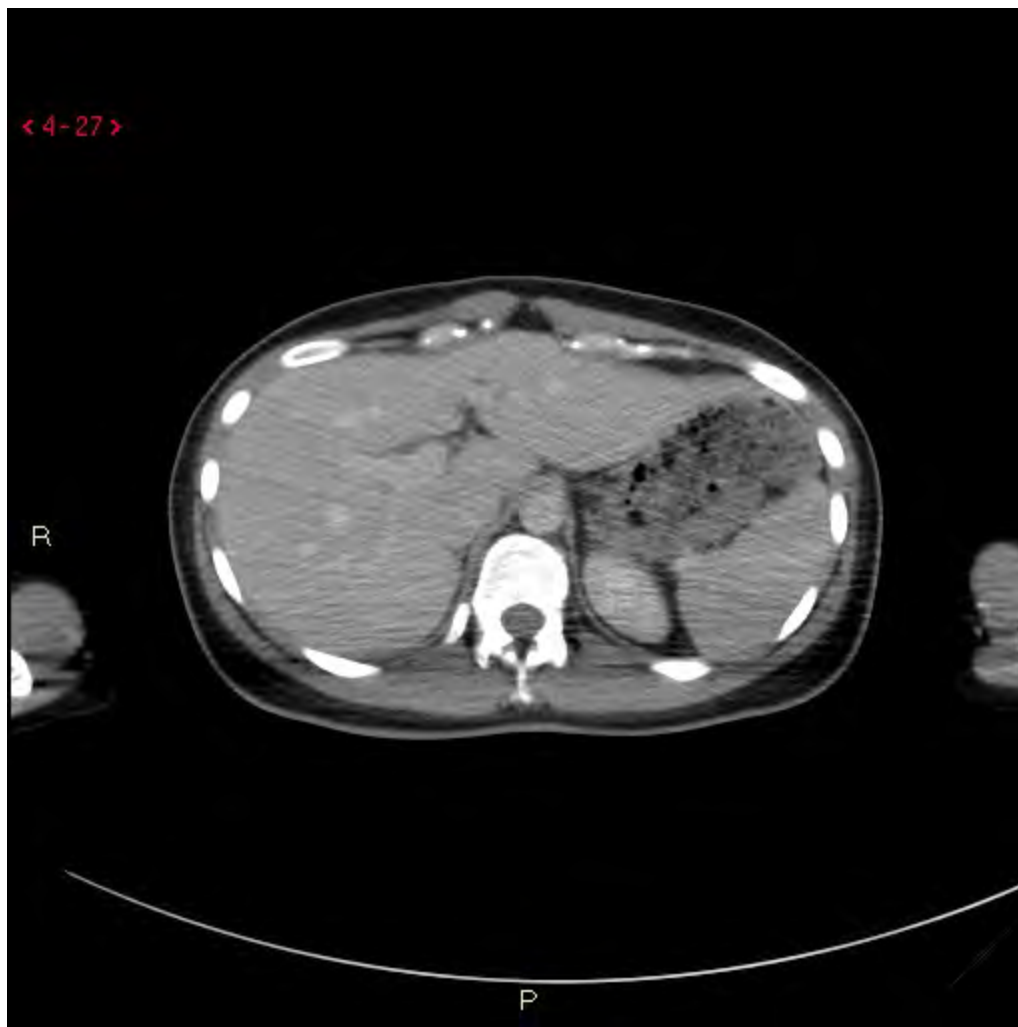
< 4-25 >



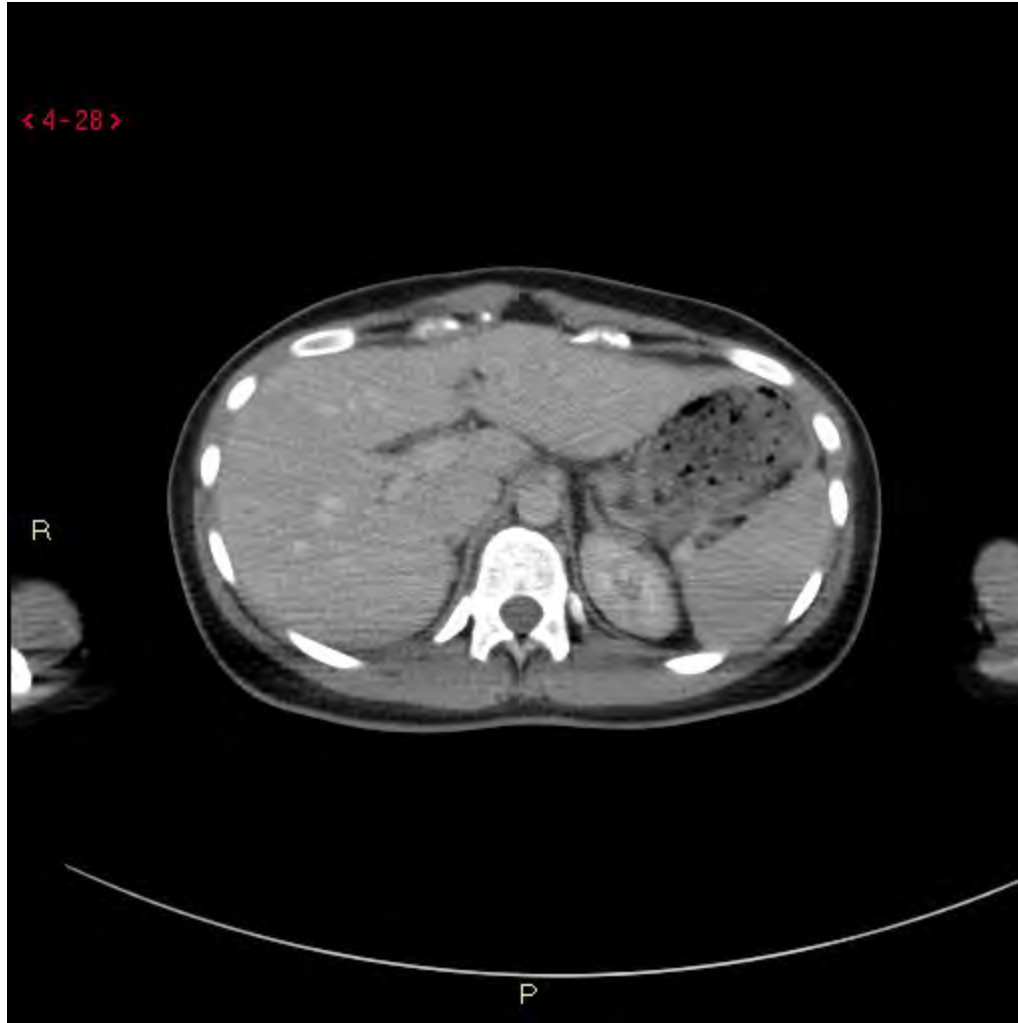
< 4-26 >



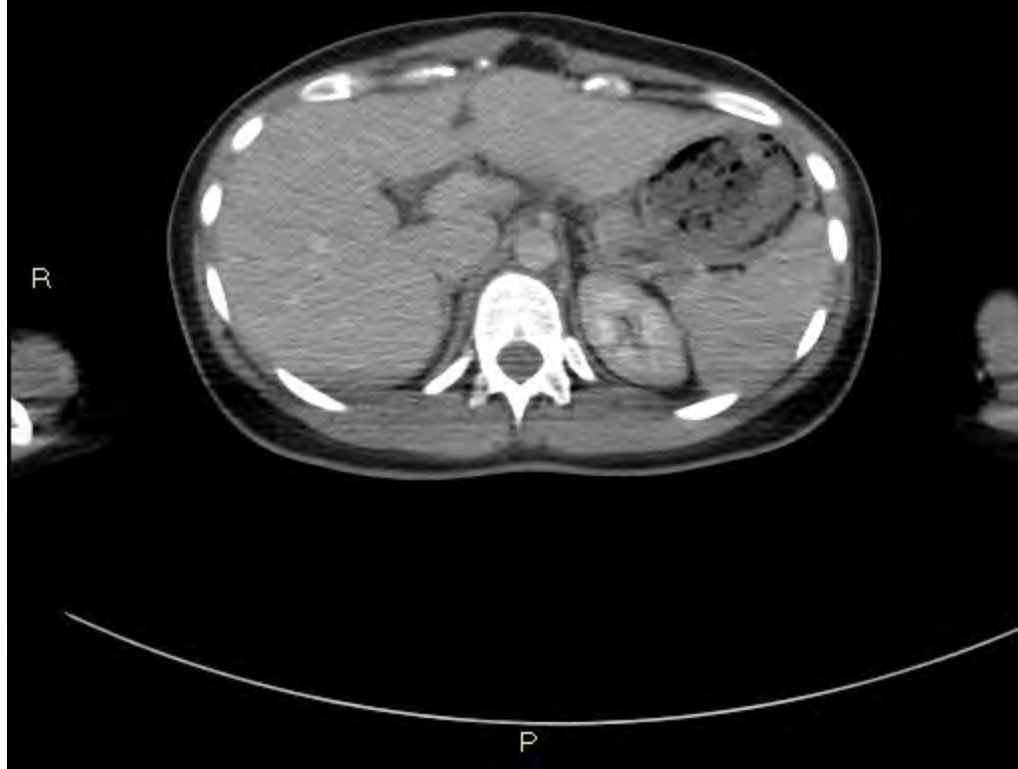< 4-27 >

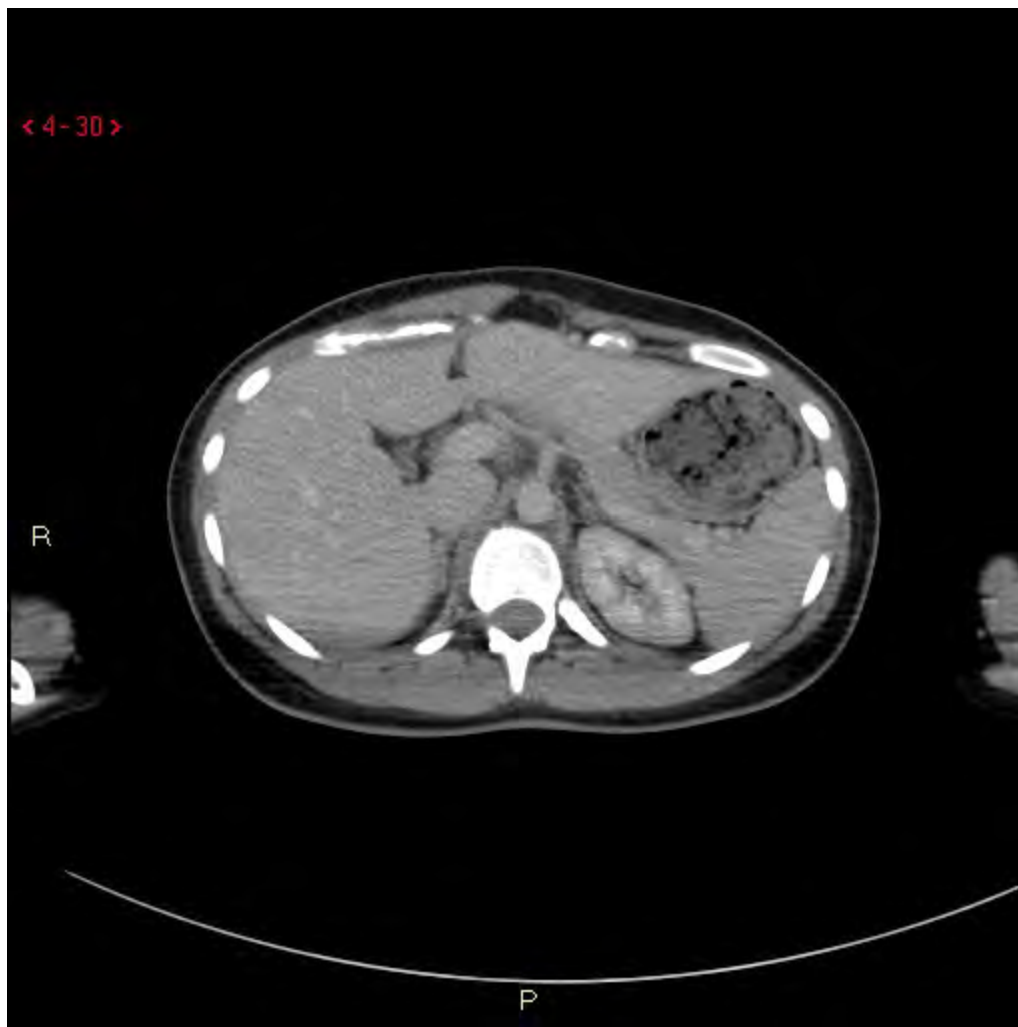


< 4-28 >

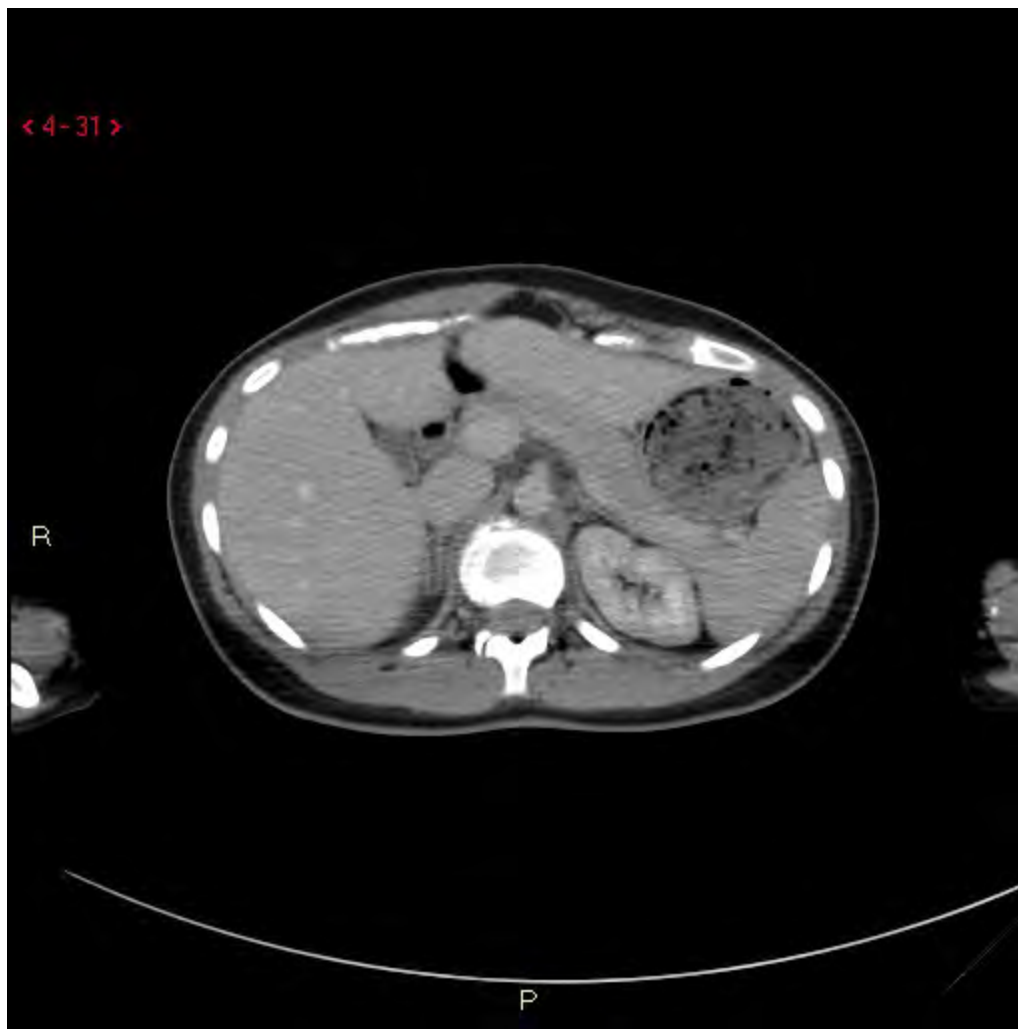


< 4-29 >

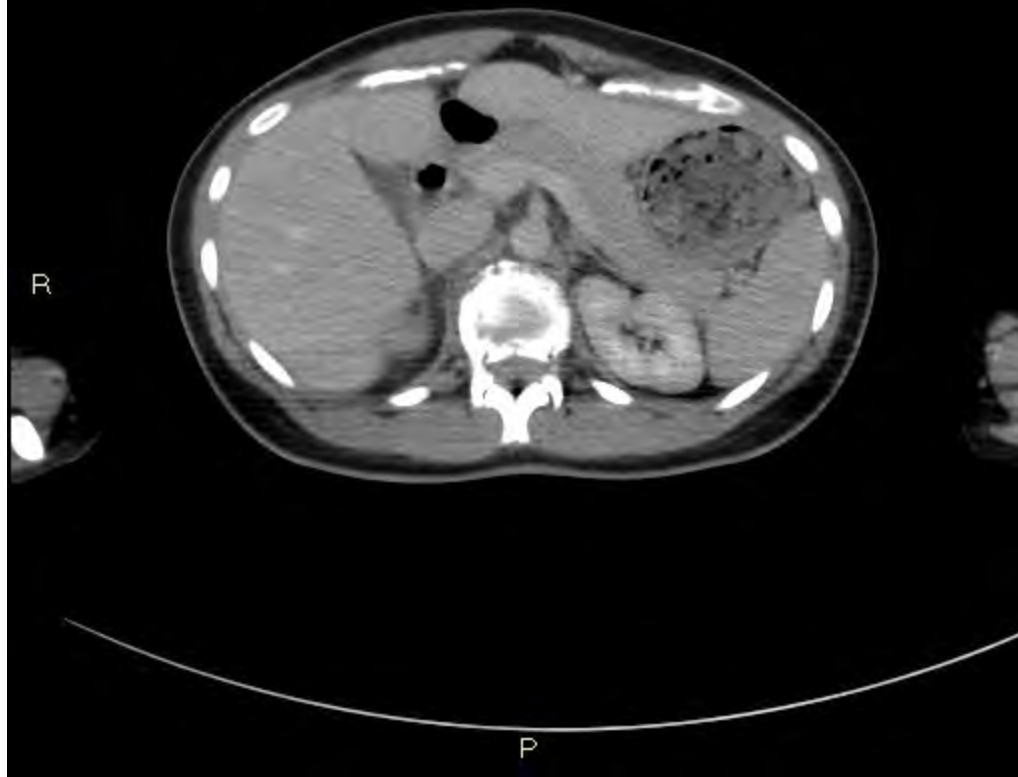




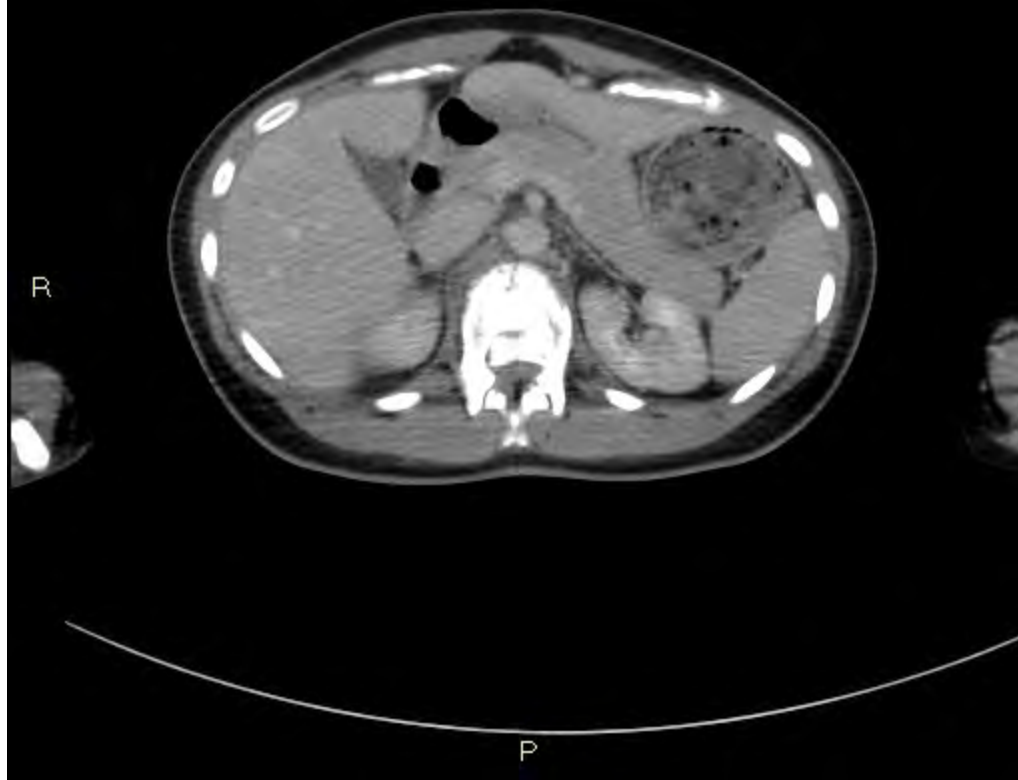
< 4-31 >



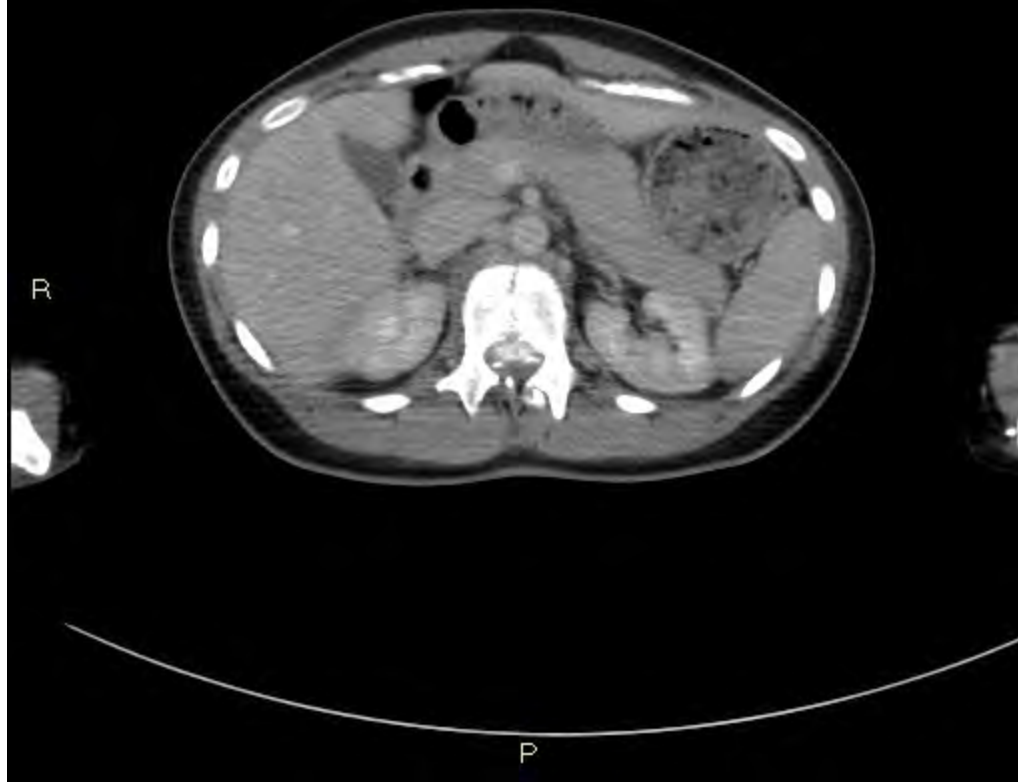< 4-32 >



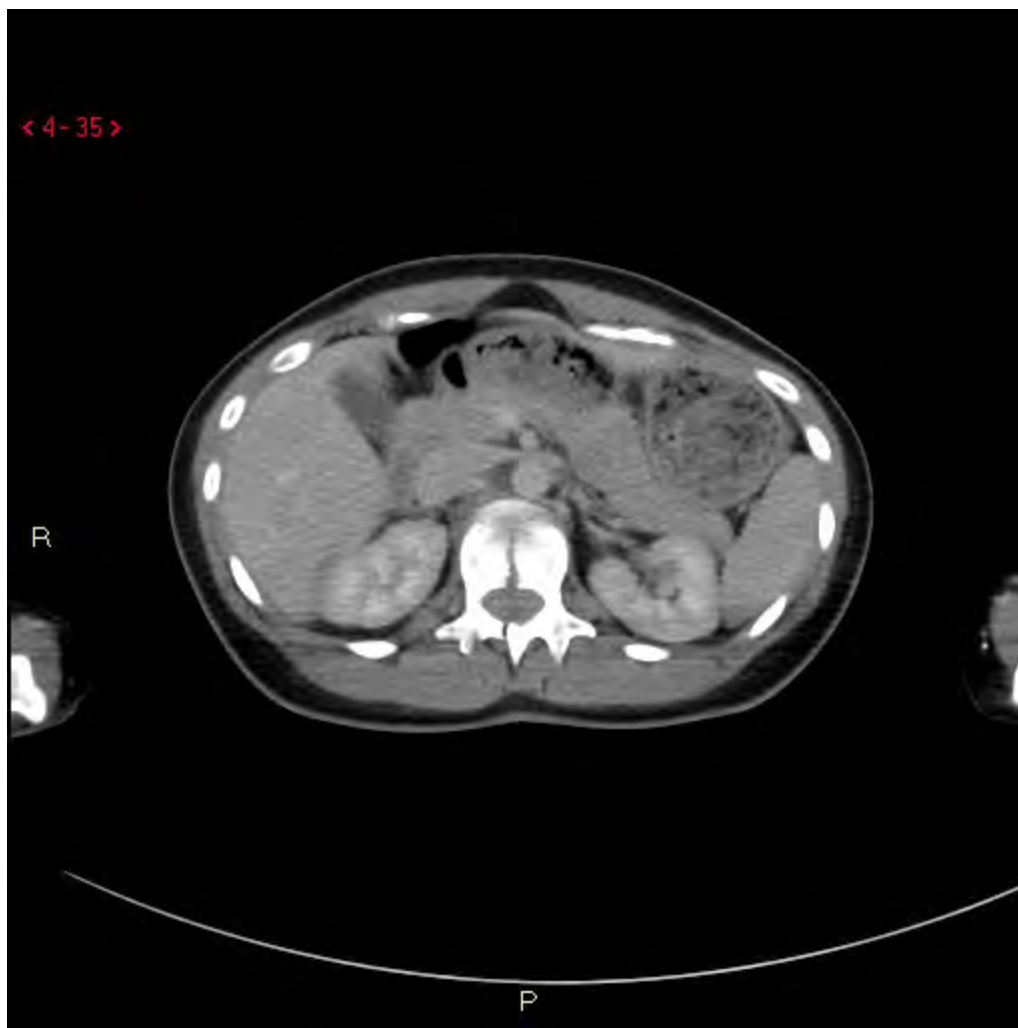
< 4-33 >



< 4-34 >



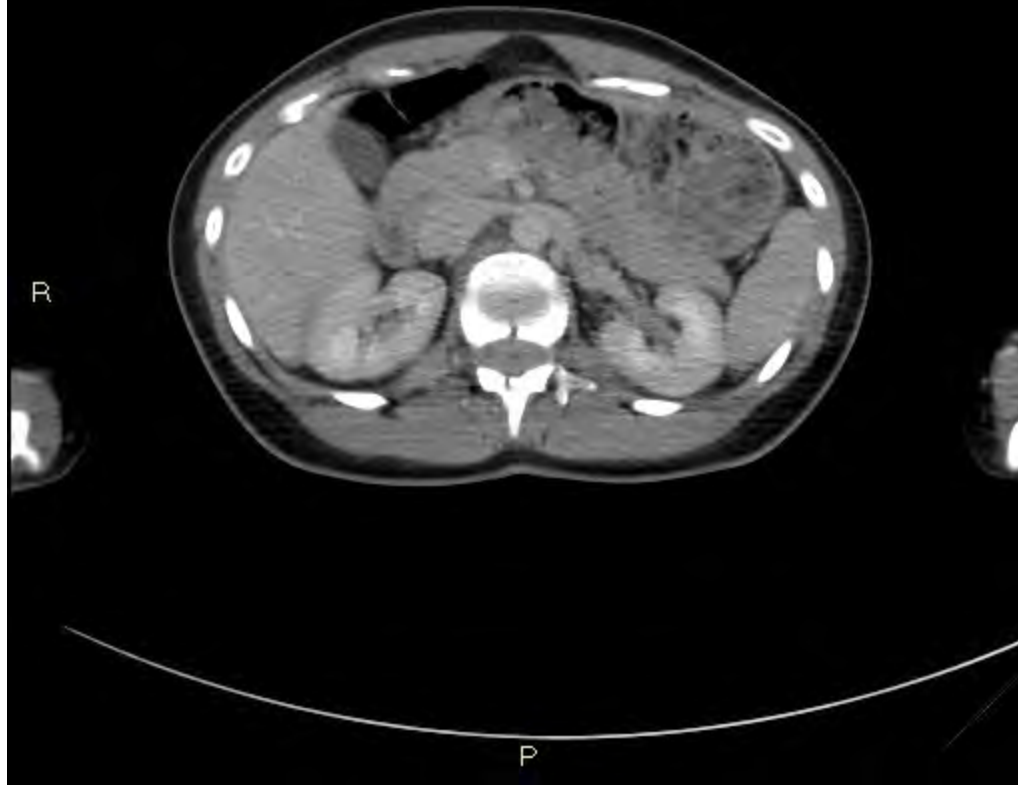
< 4-35 >



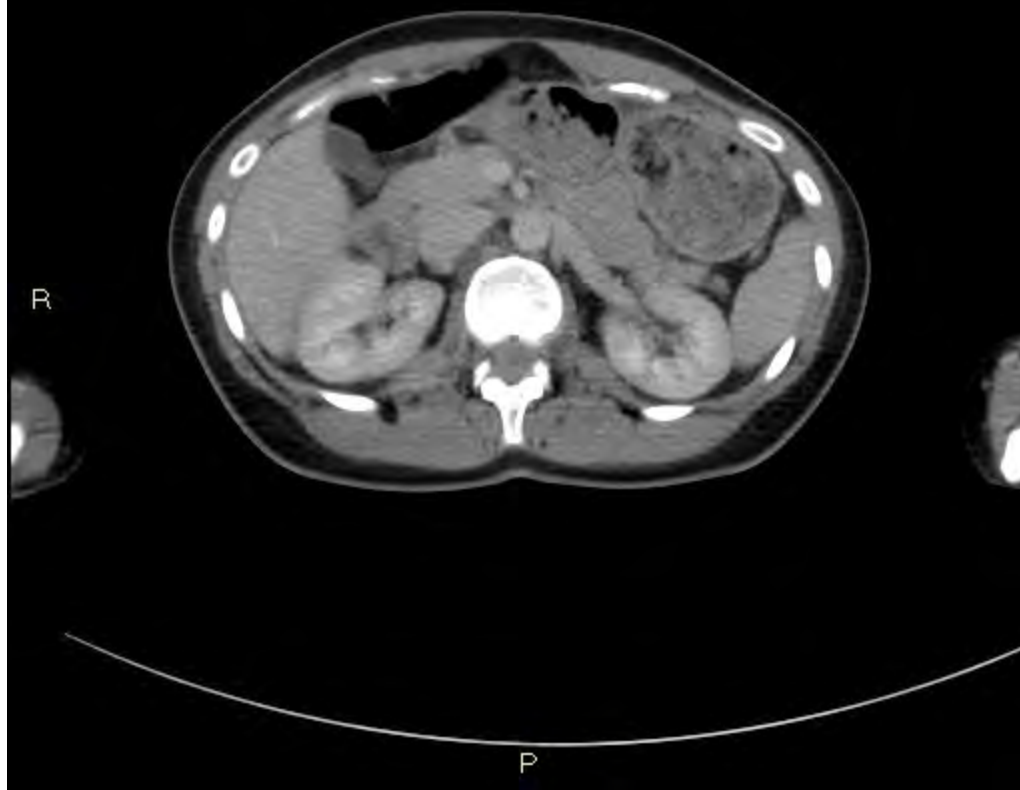R

P

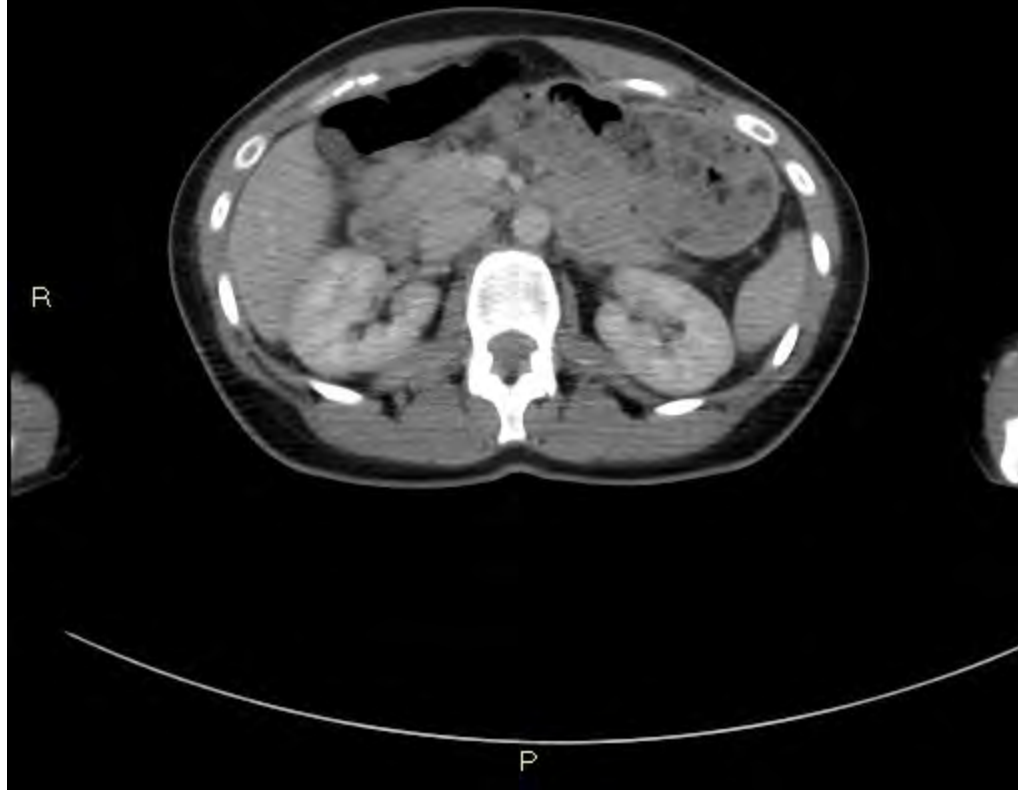
< 4-36 >



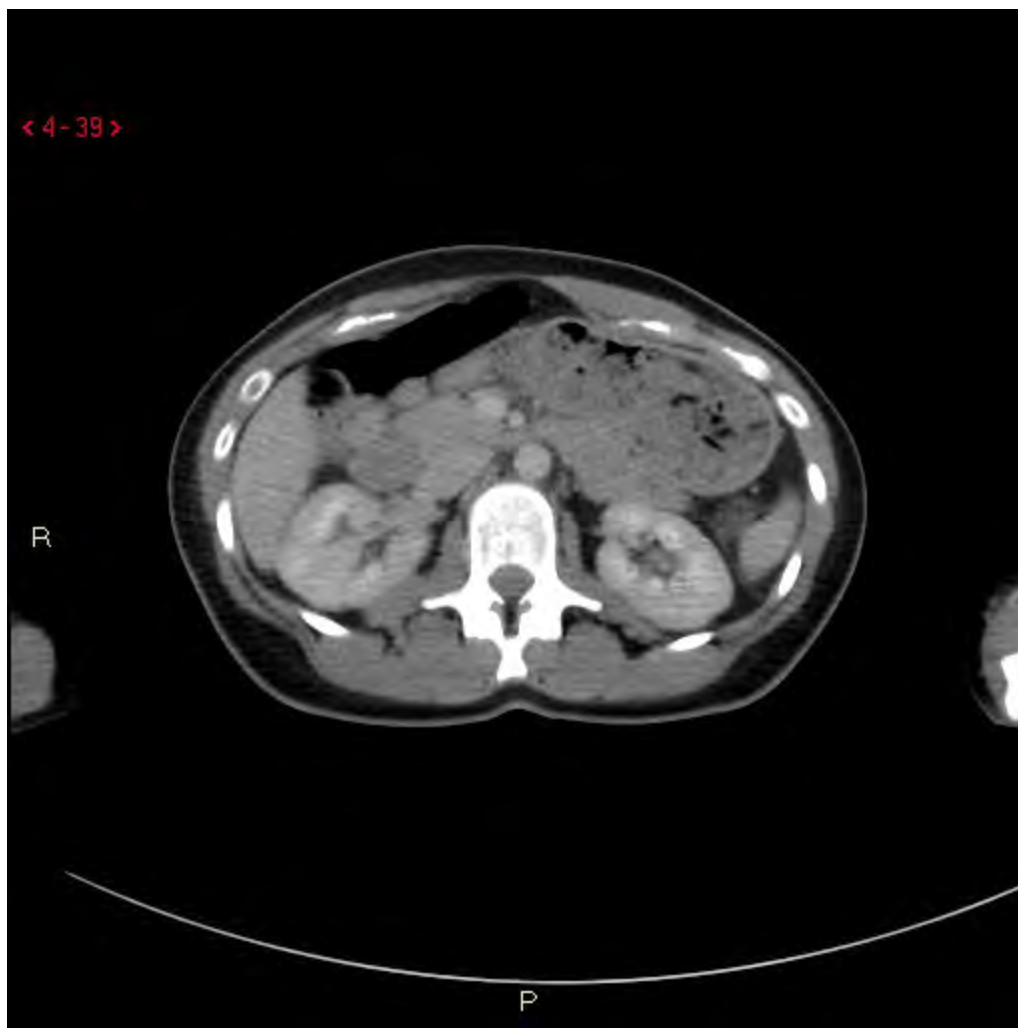
< 4-37 >

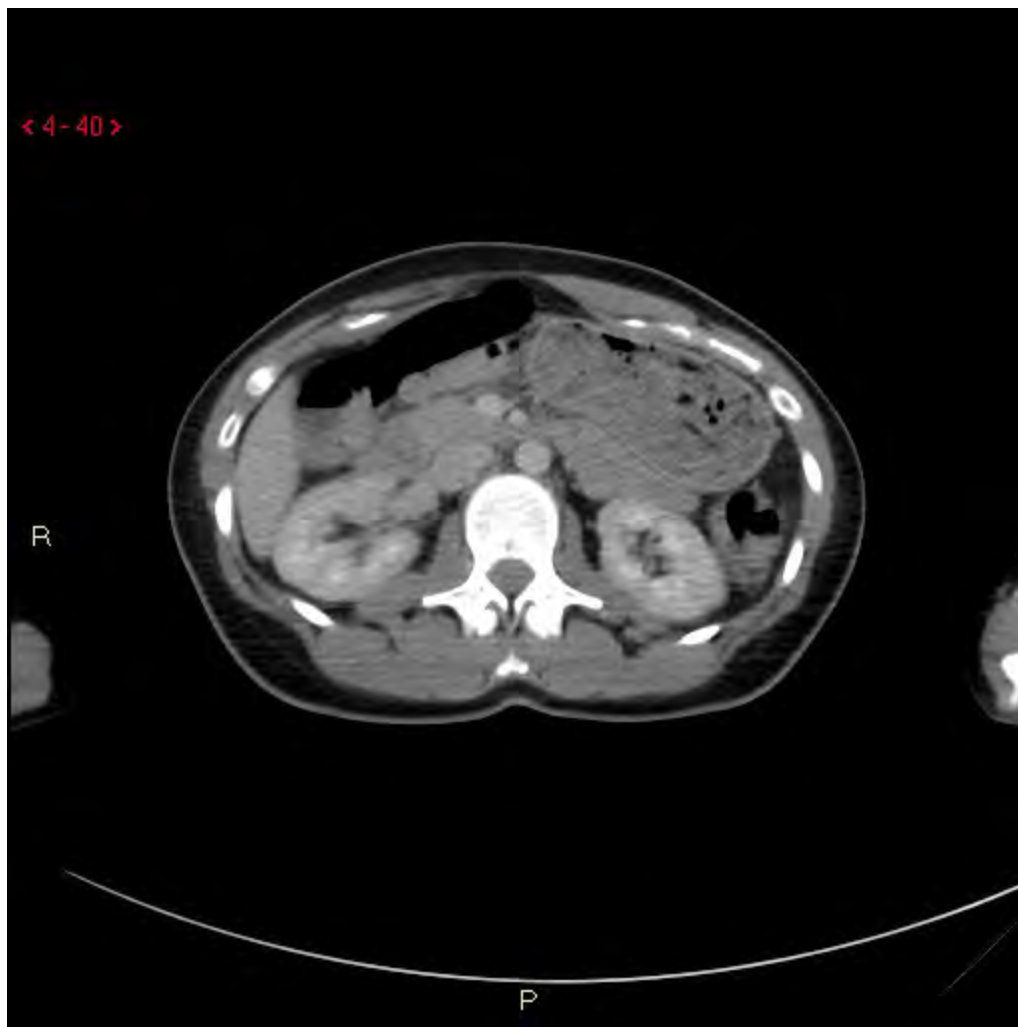


< 4-38 >



< 4 - 39 >

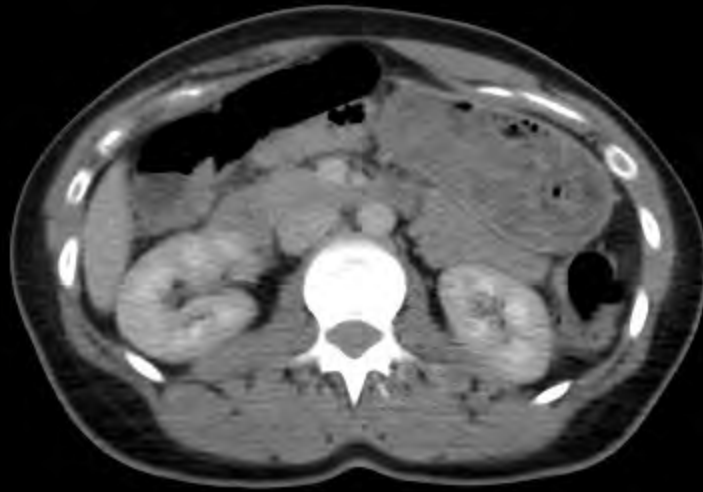




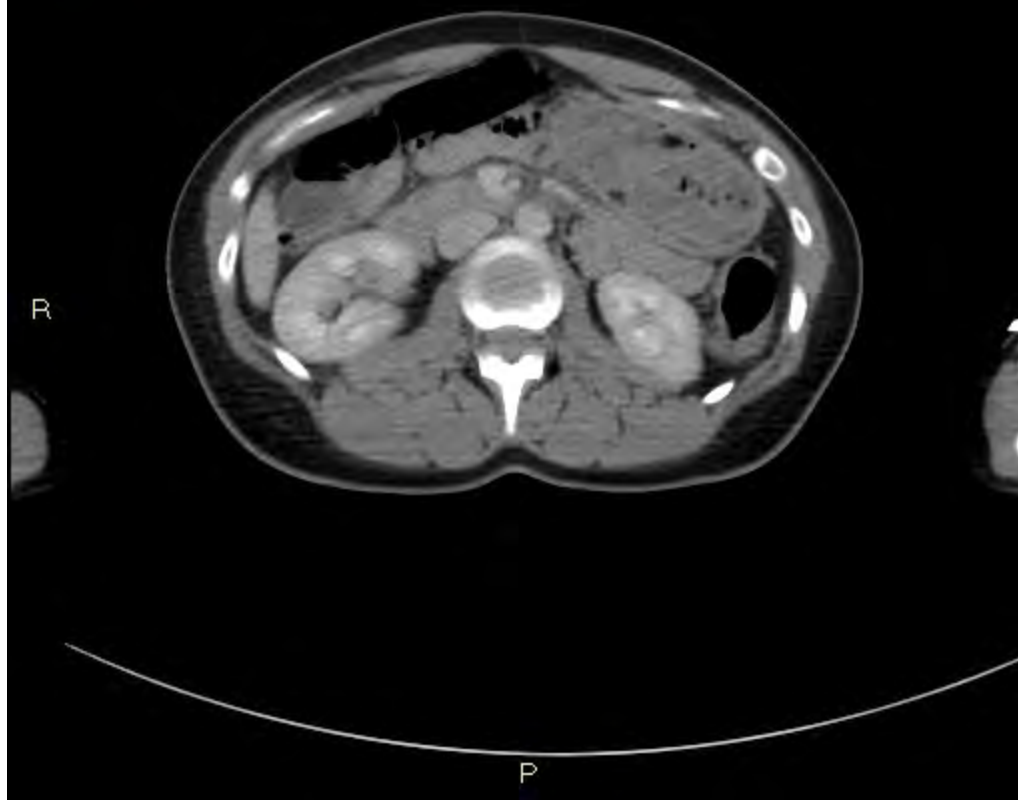
< 4 - 41 >

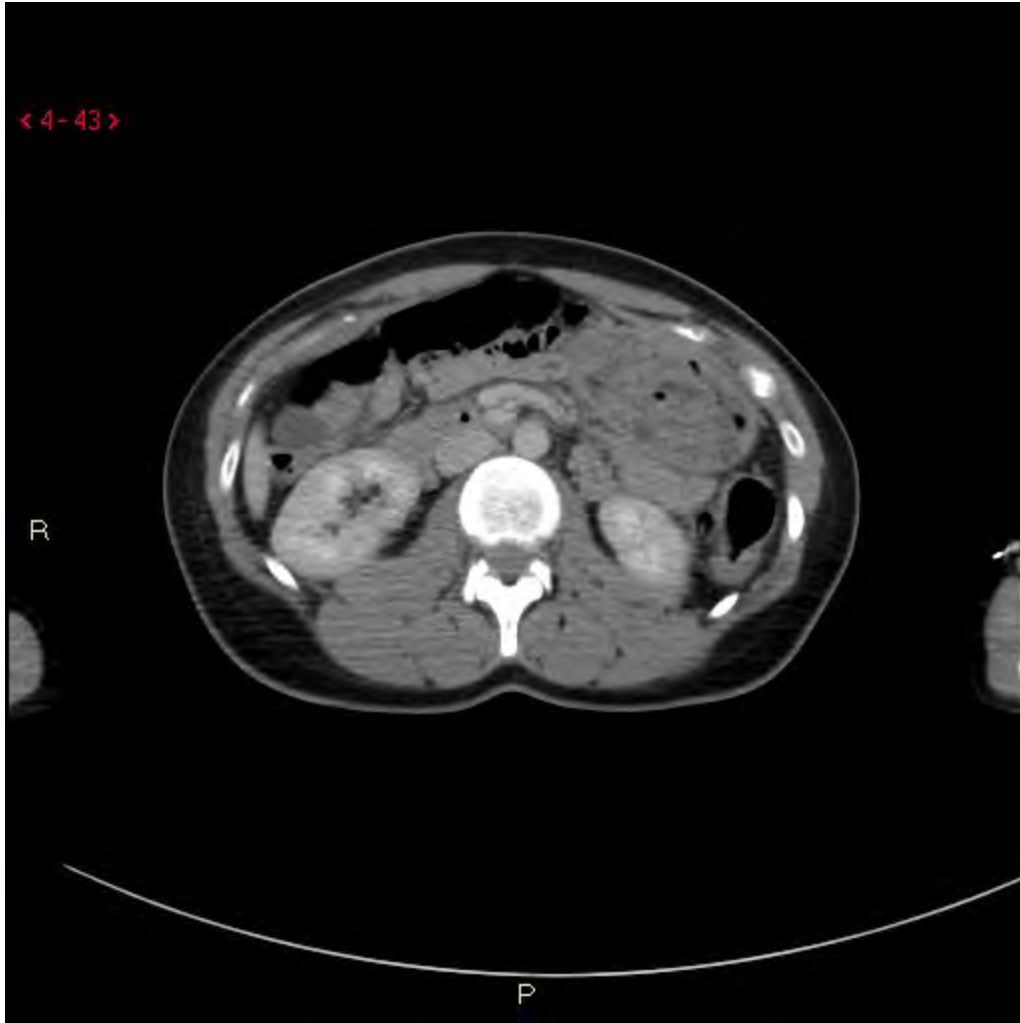
R

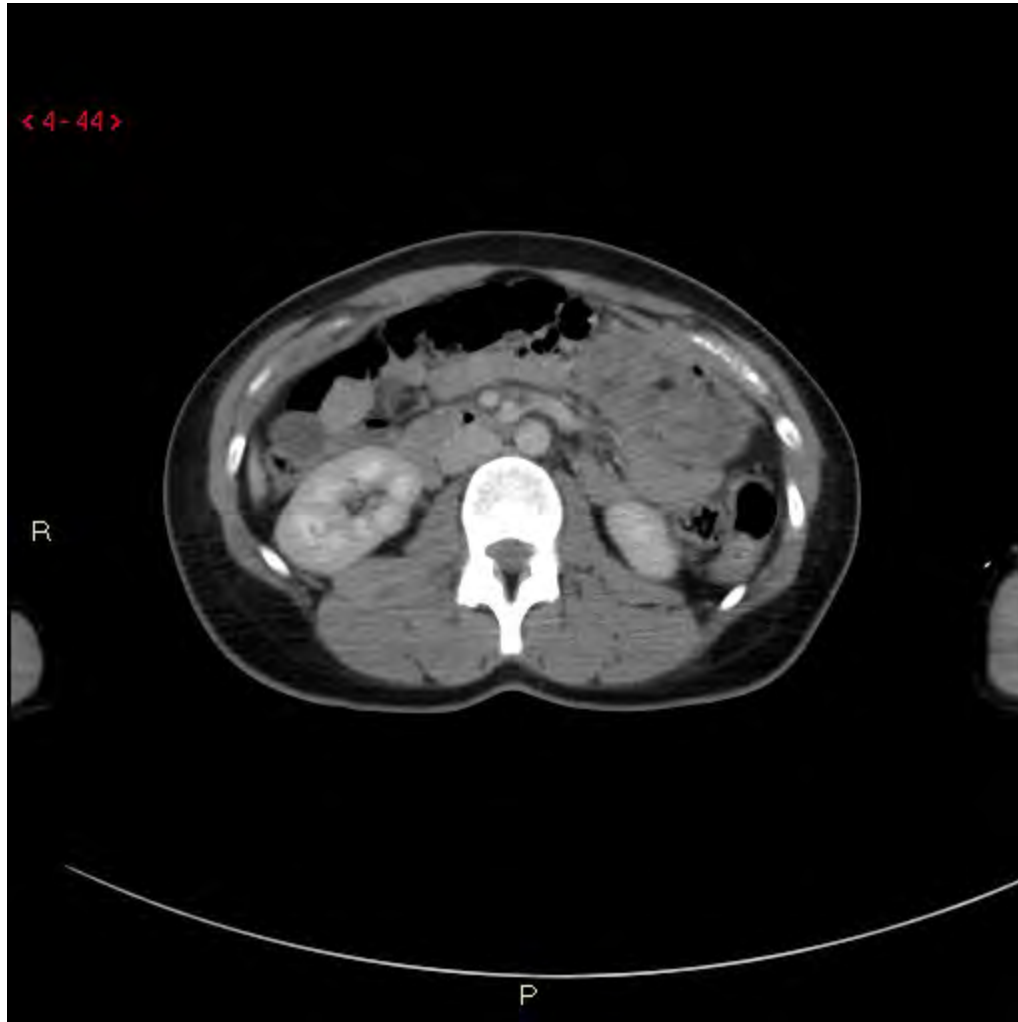
P

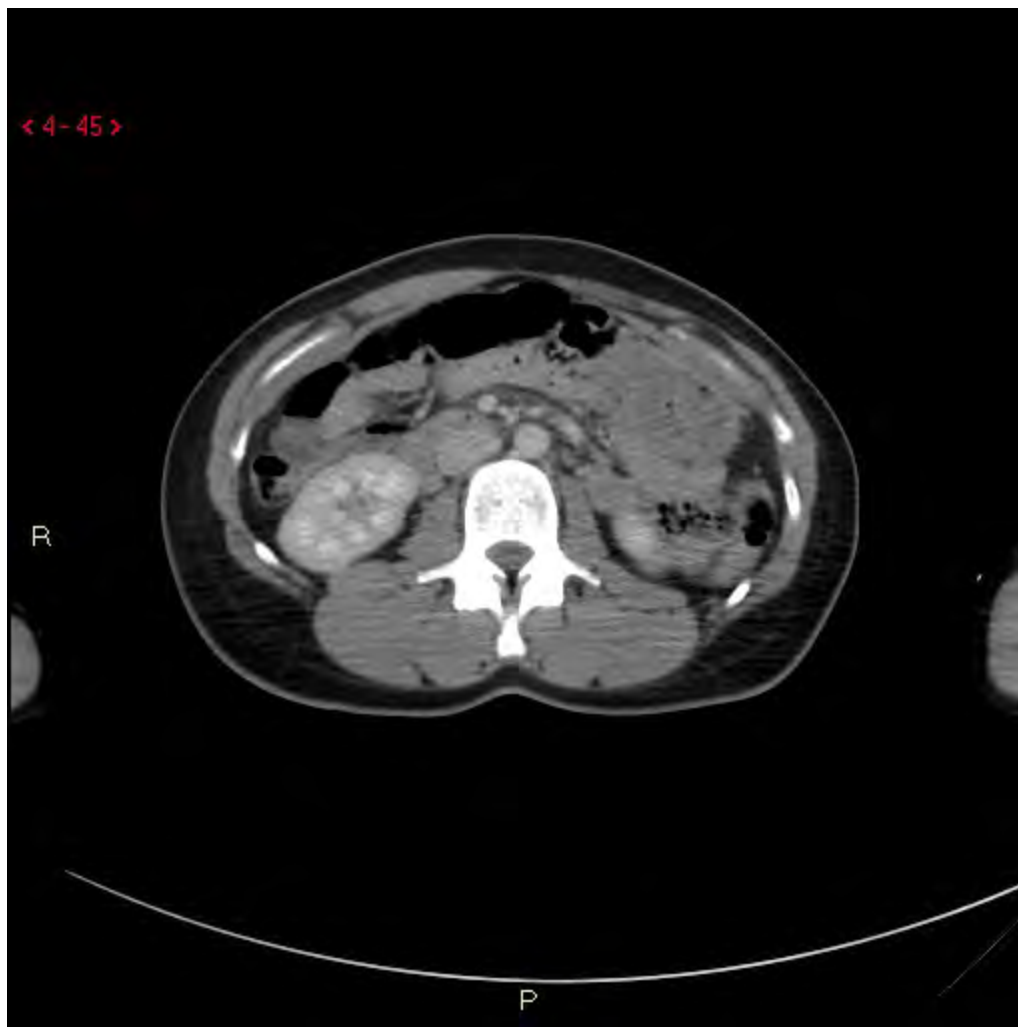


< 4-42 >





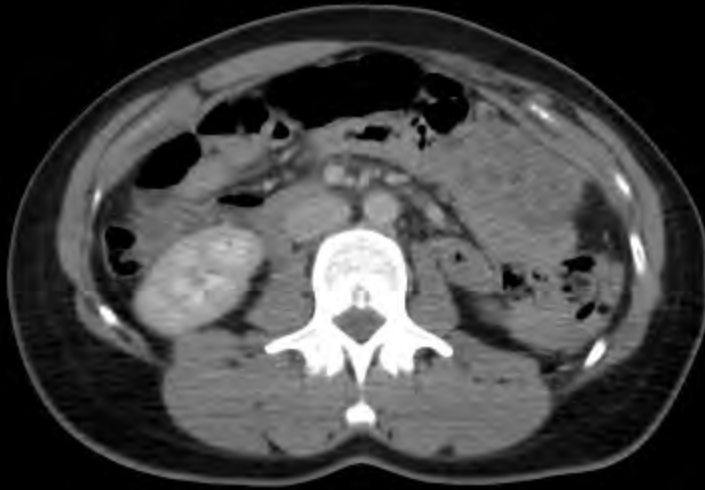

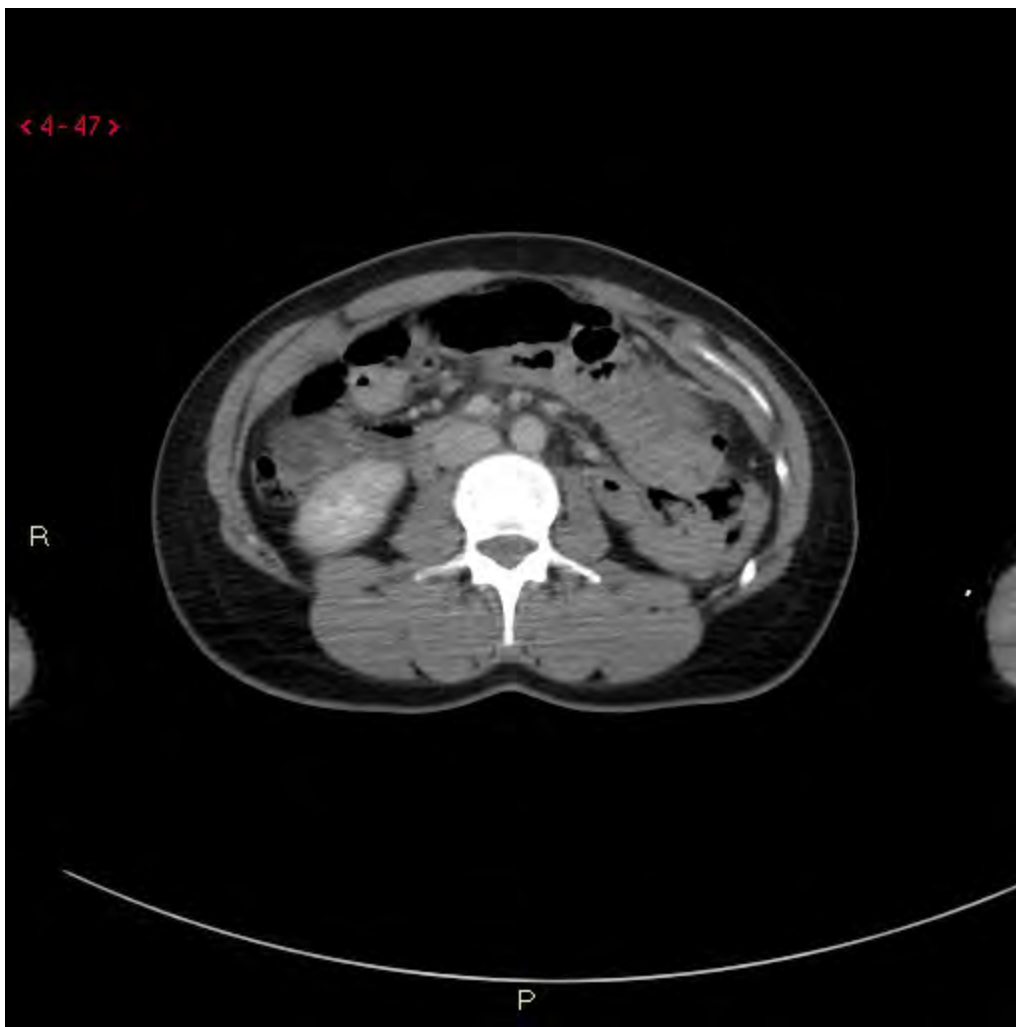


< 4 - 46 >

R

P

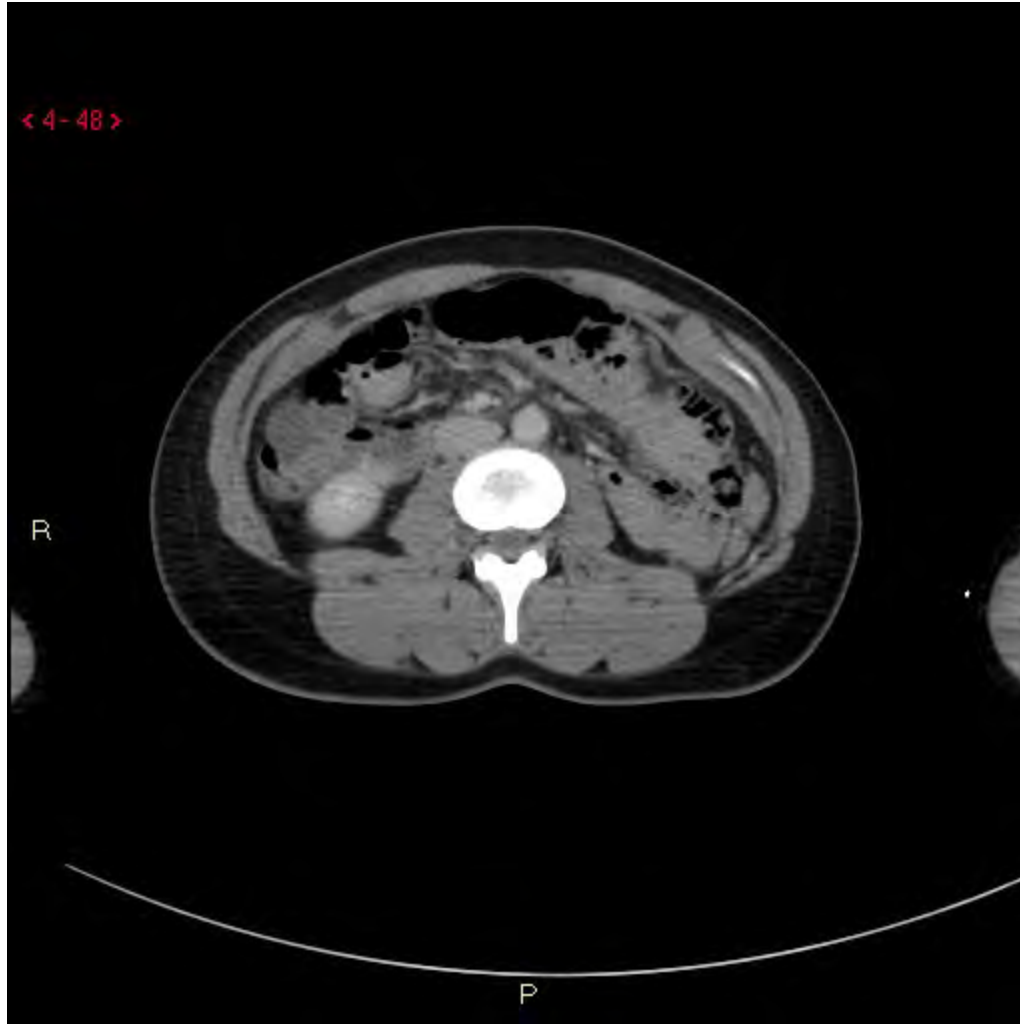




< 4-48 >

R

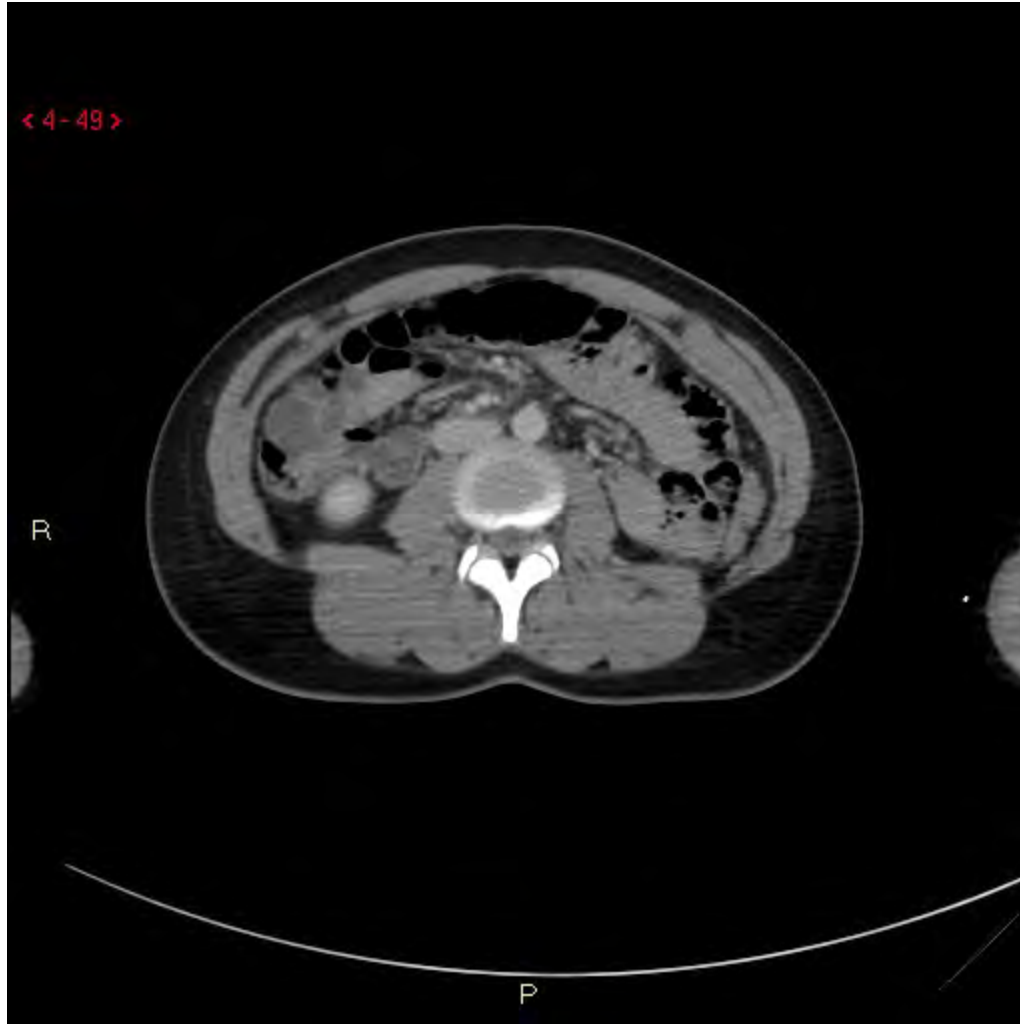
P



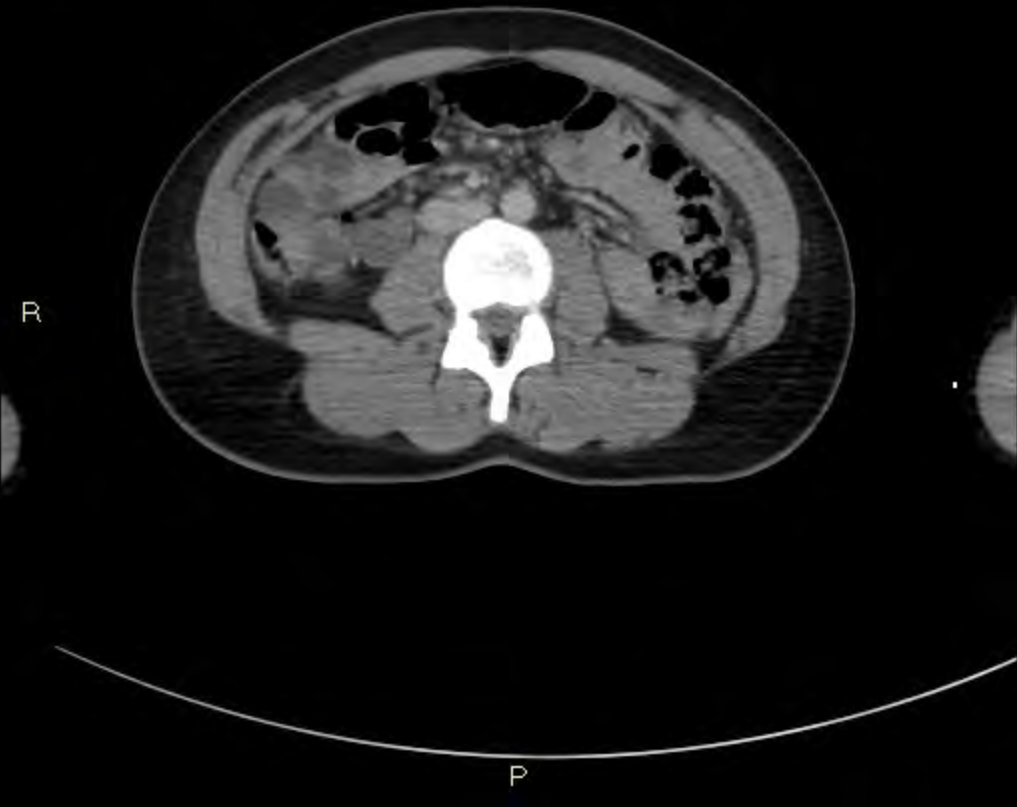< 4 - 49 >

R

P

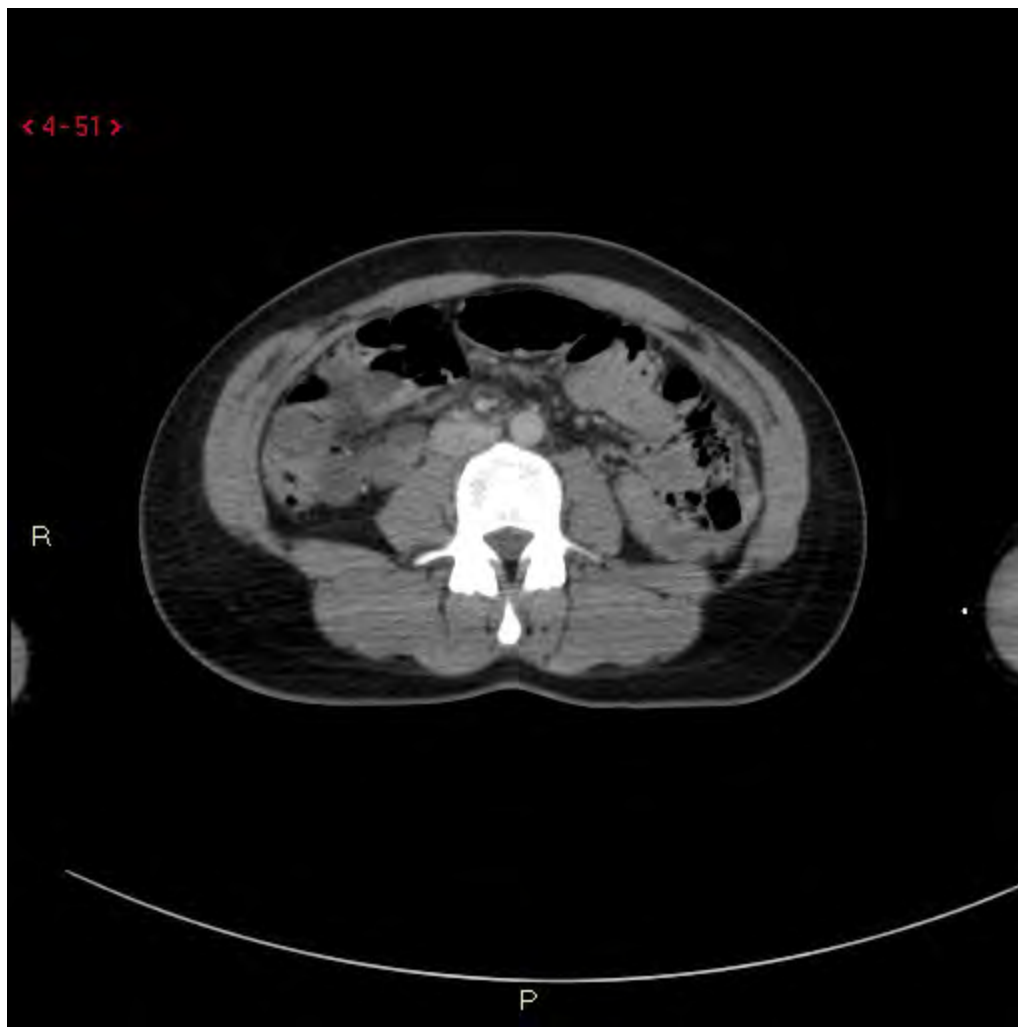


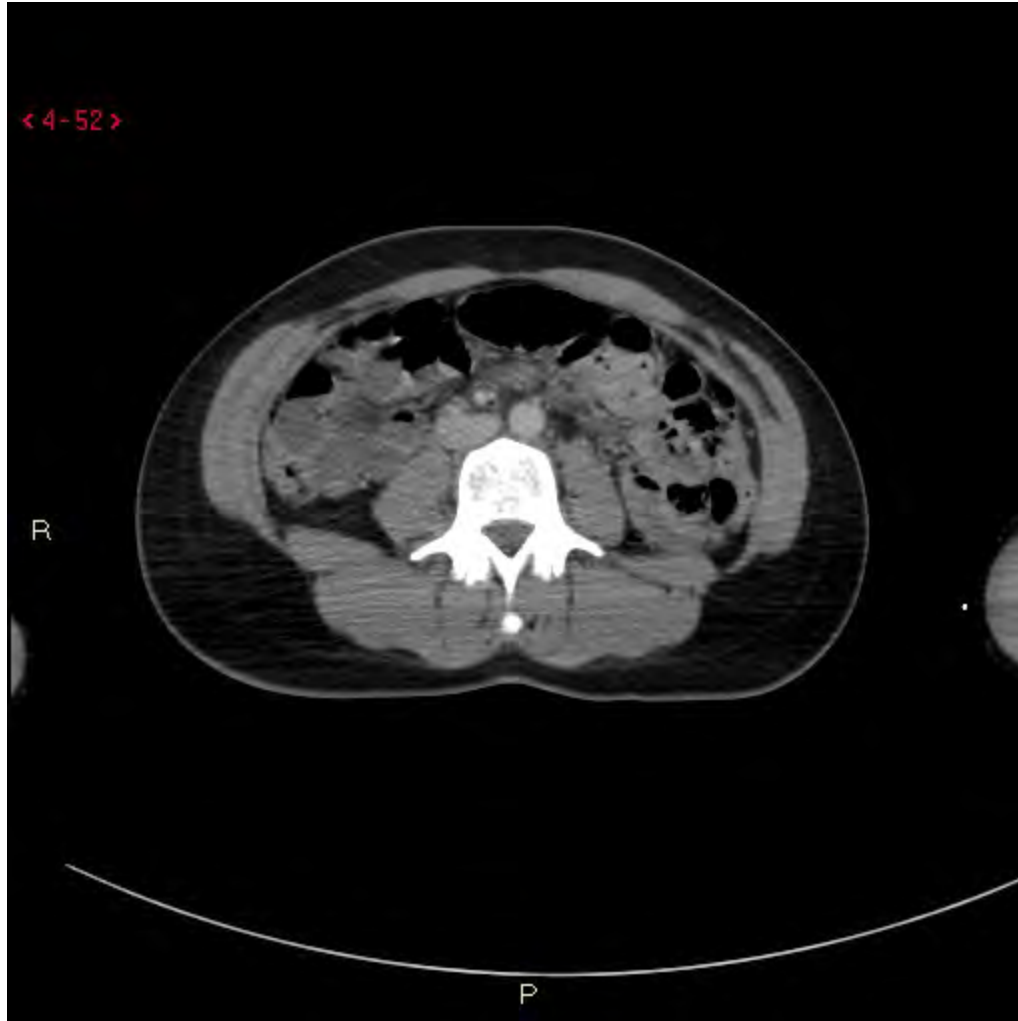
< 4-50 >



R

P

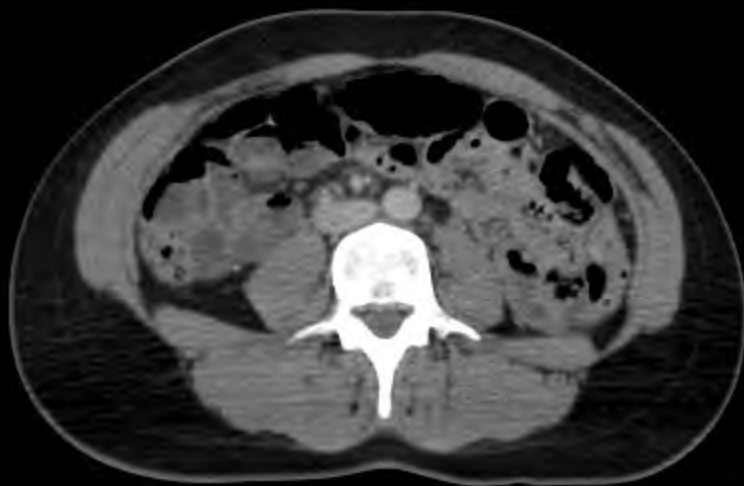


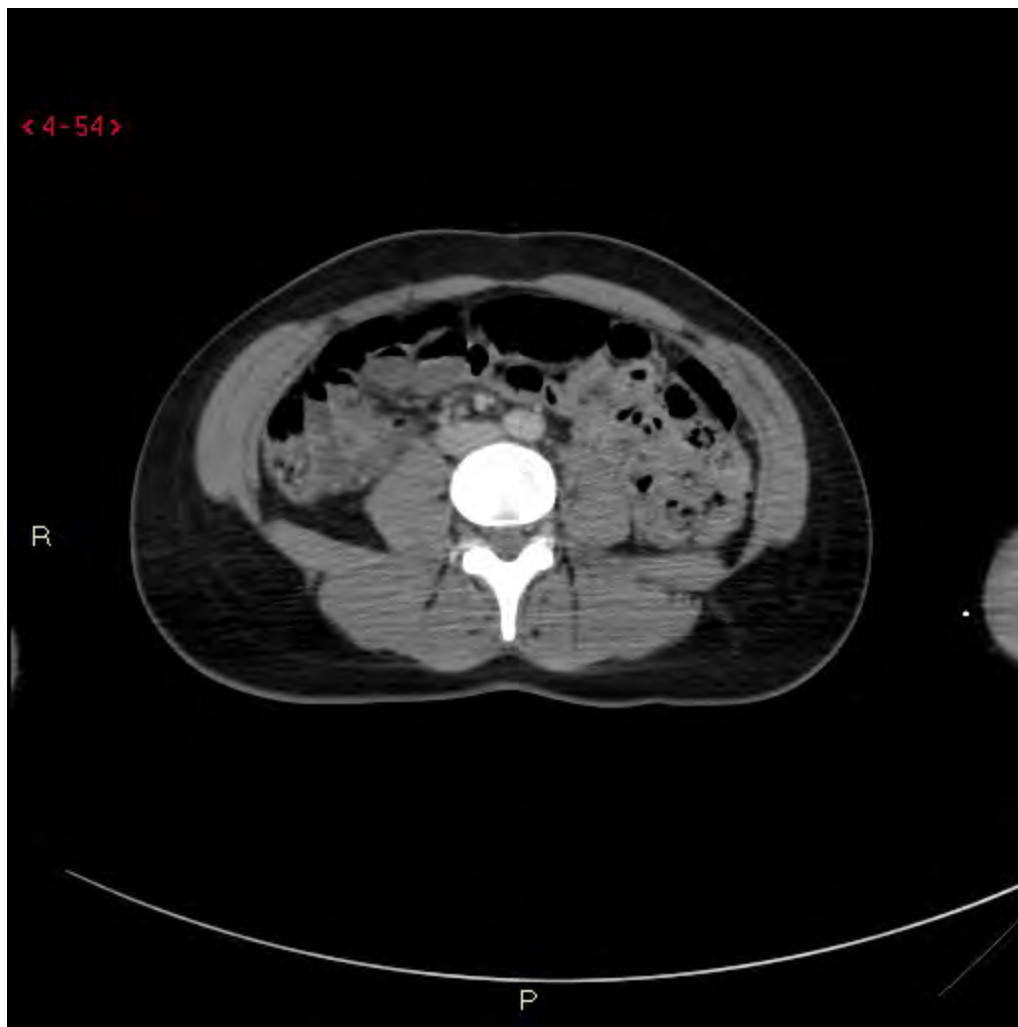


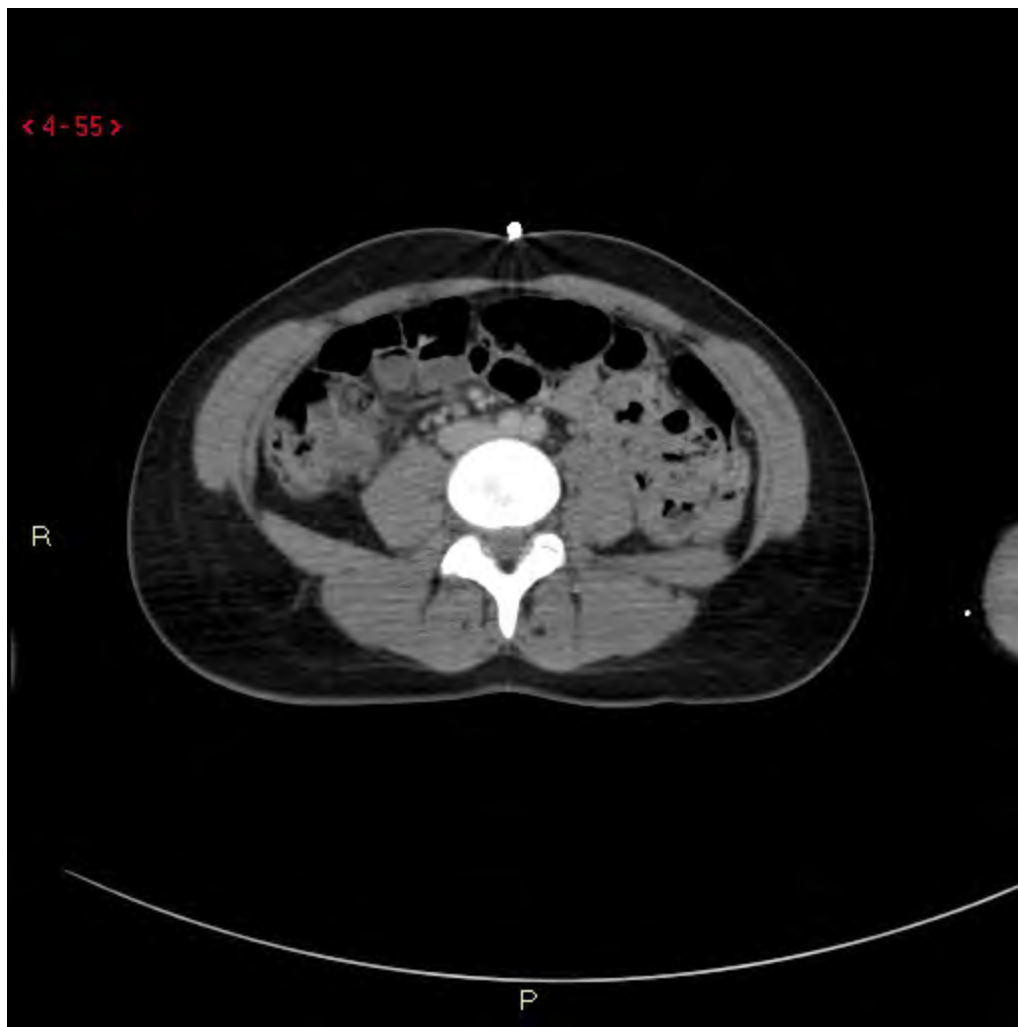
< 4-53 >

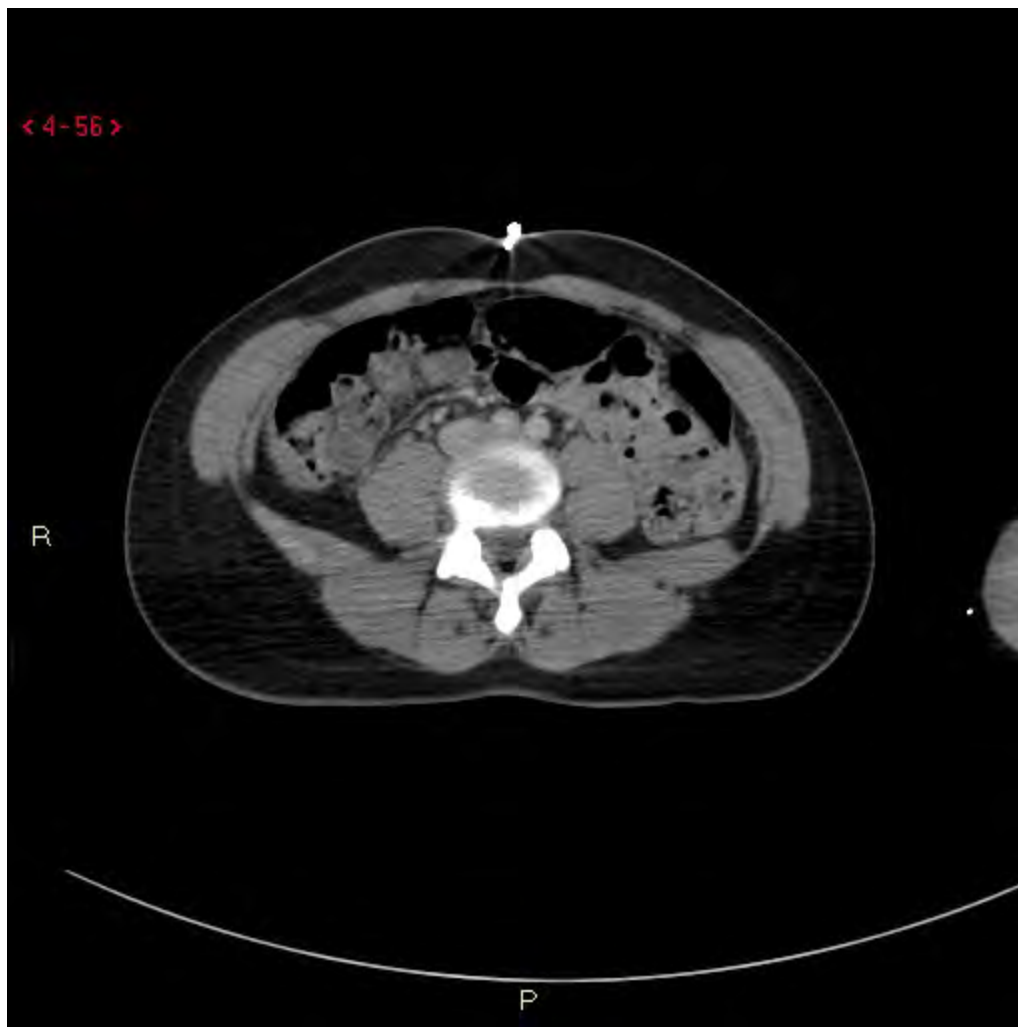
R

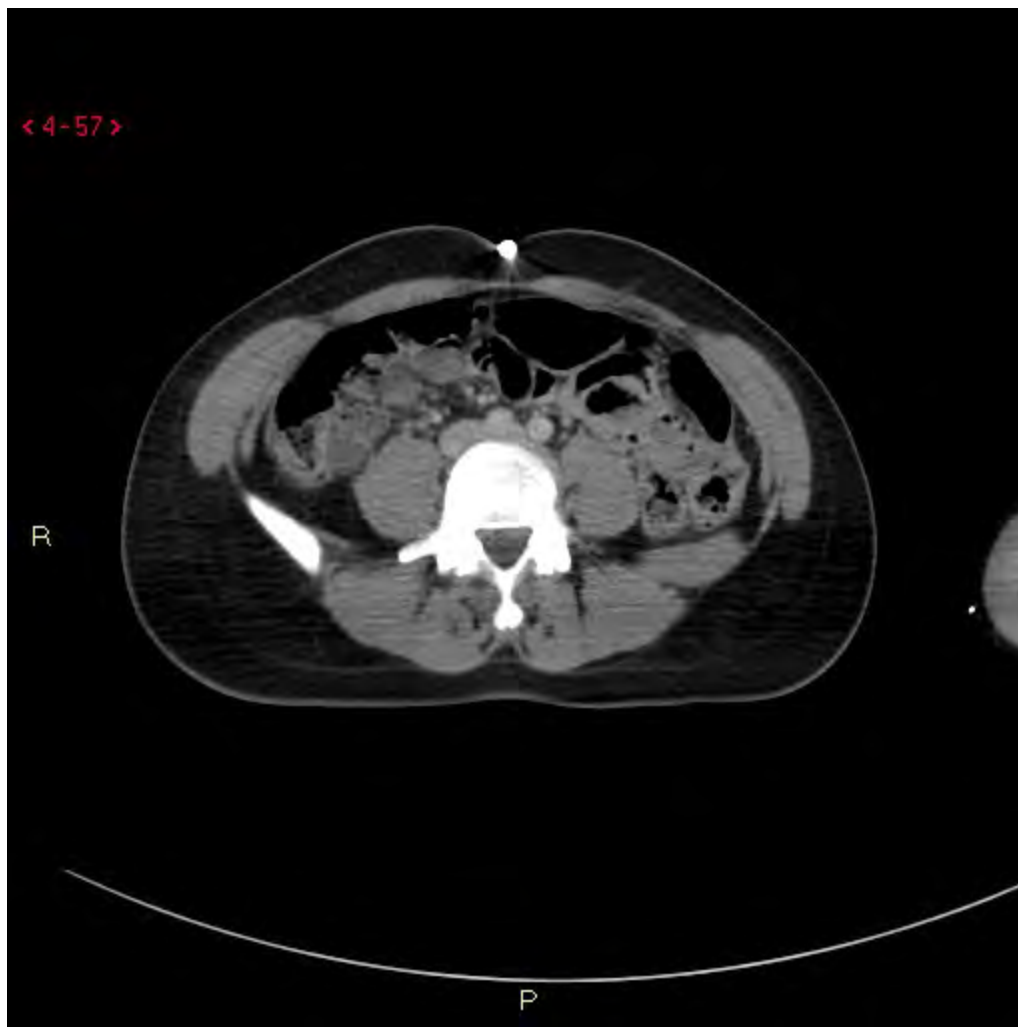
P

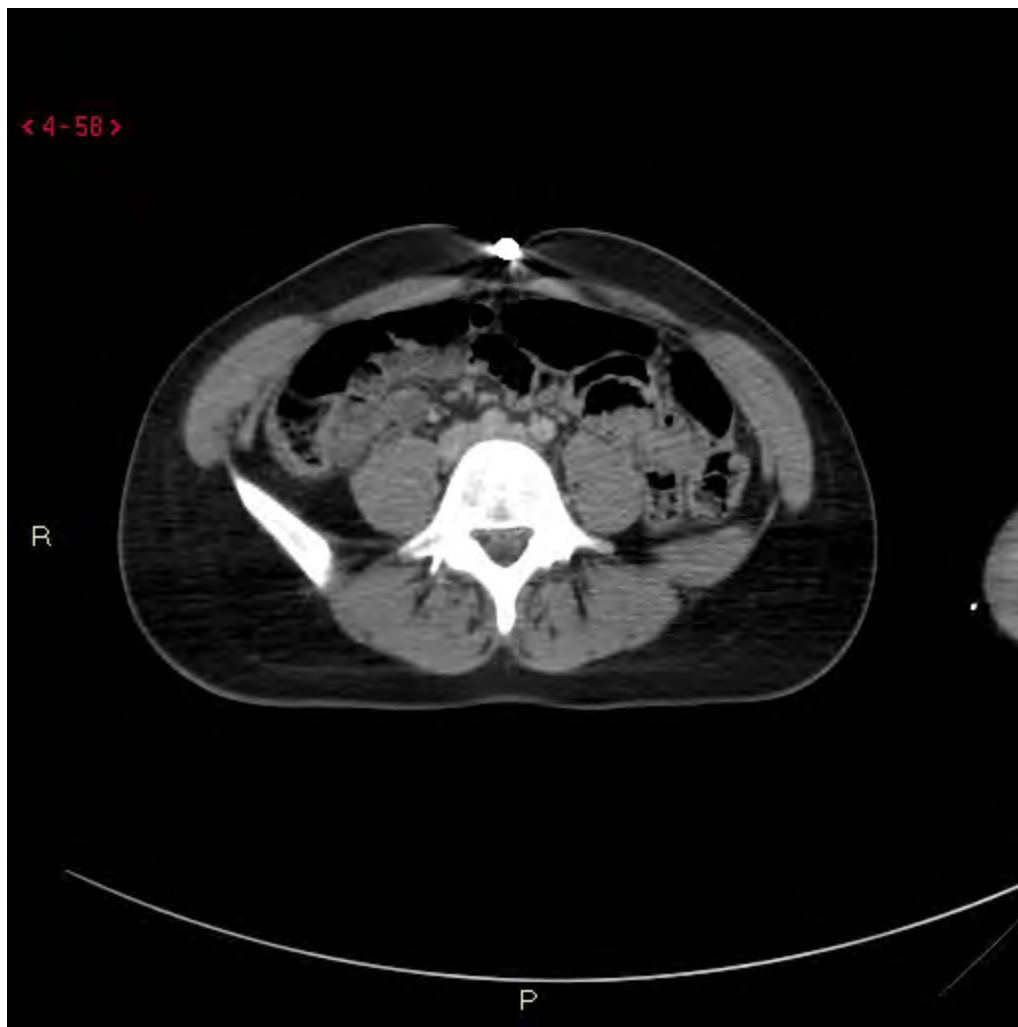







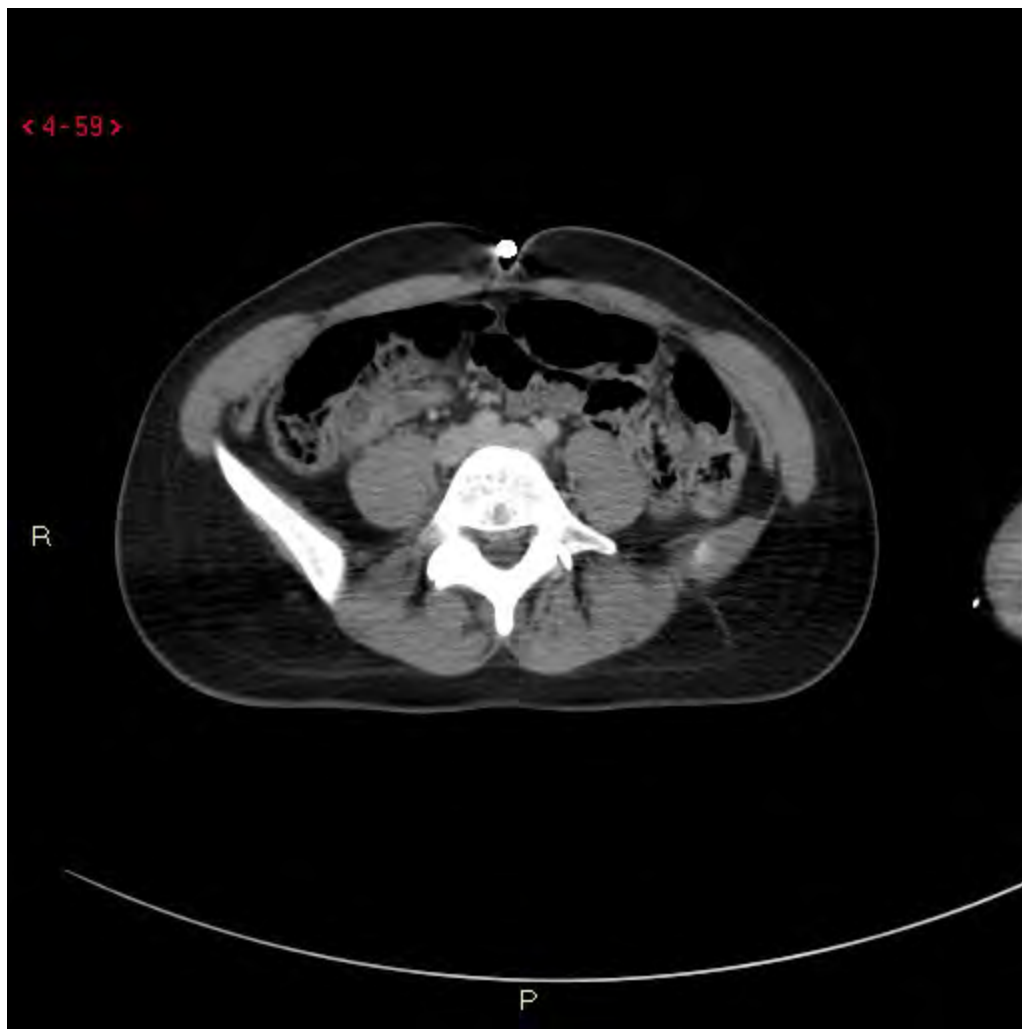



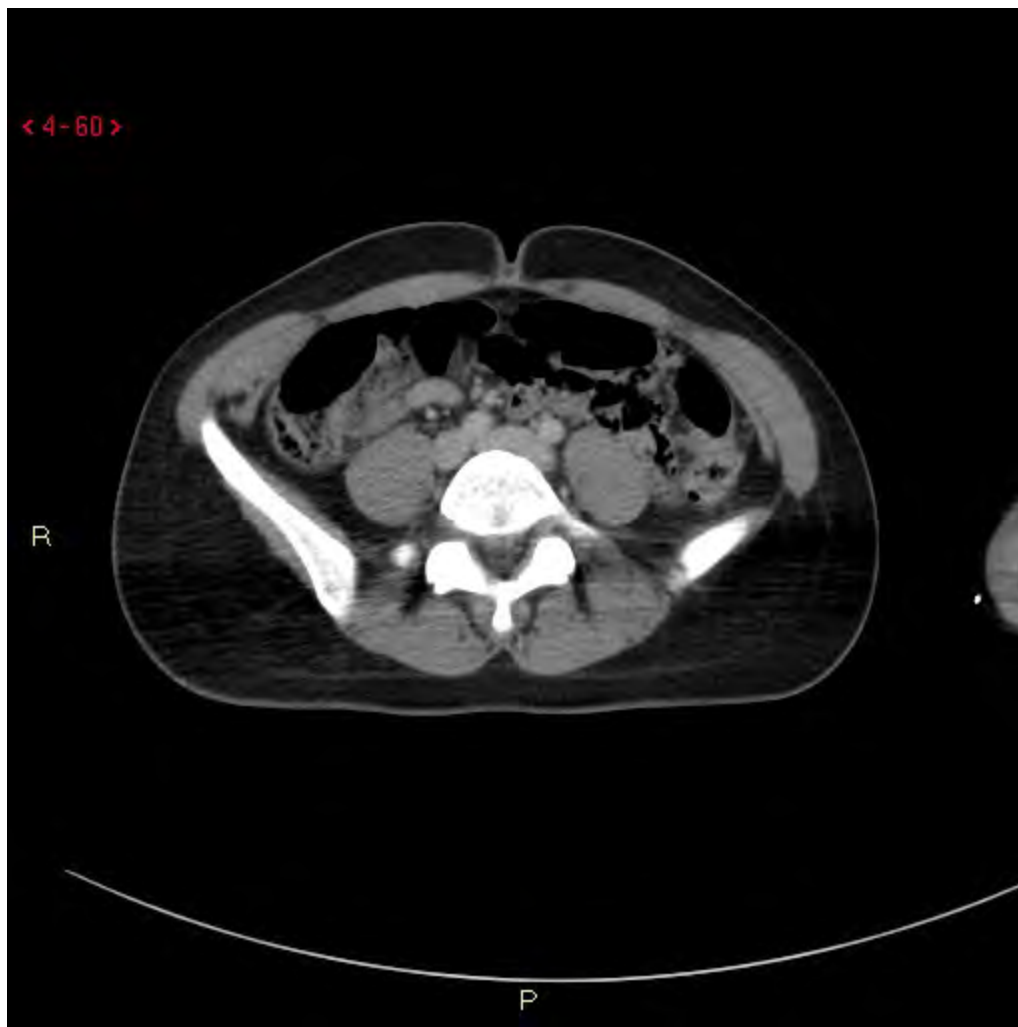
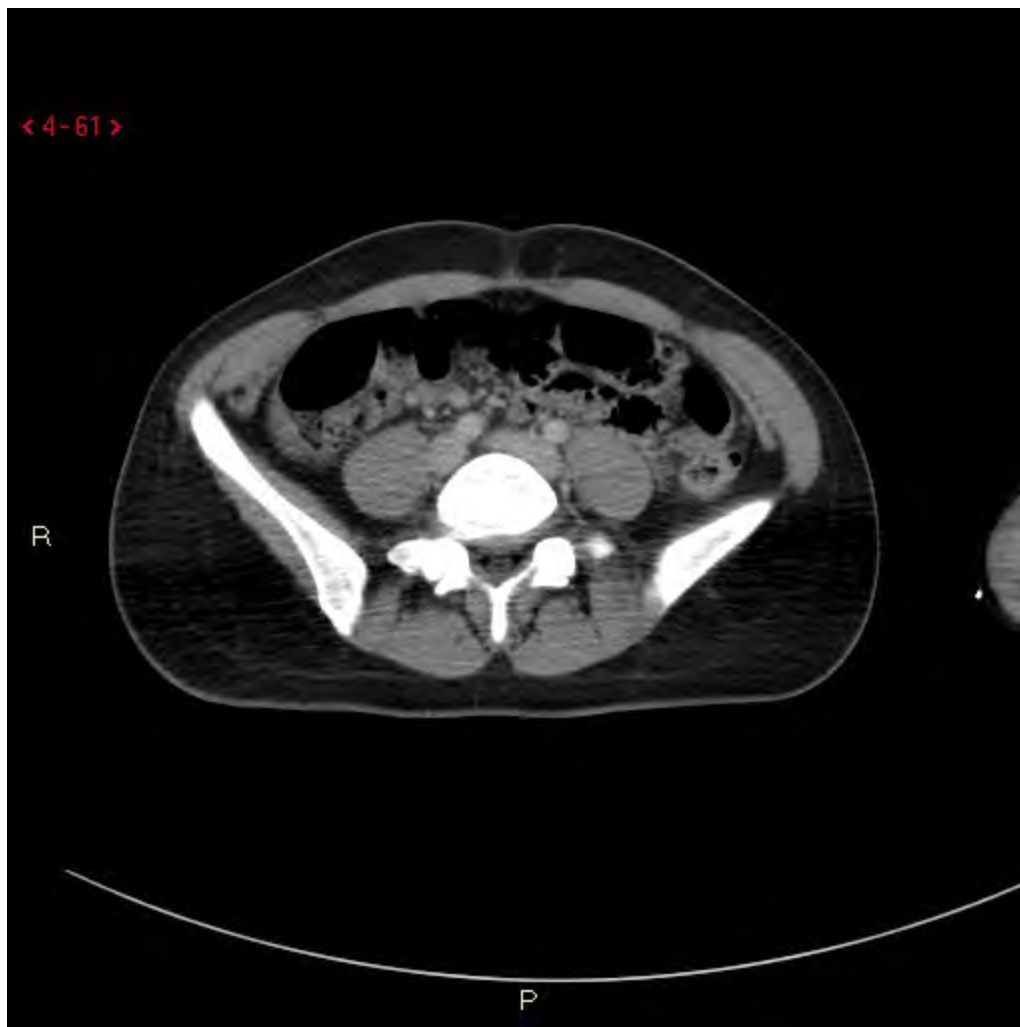< 4-59 >

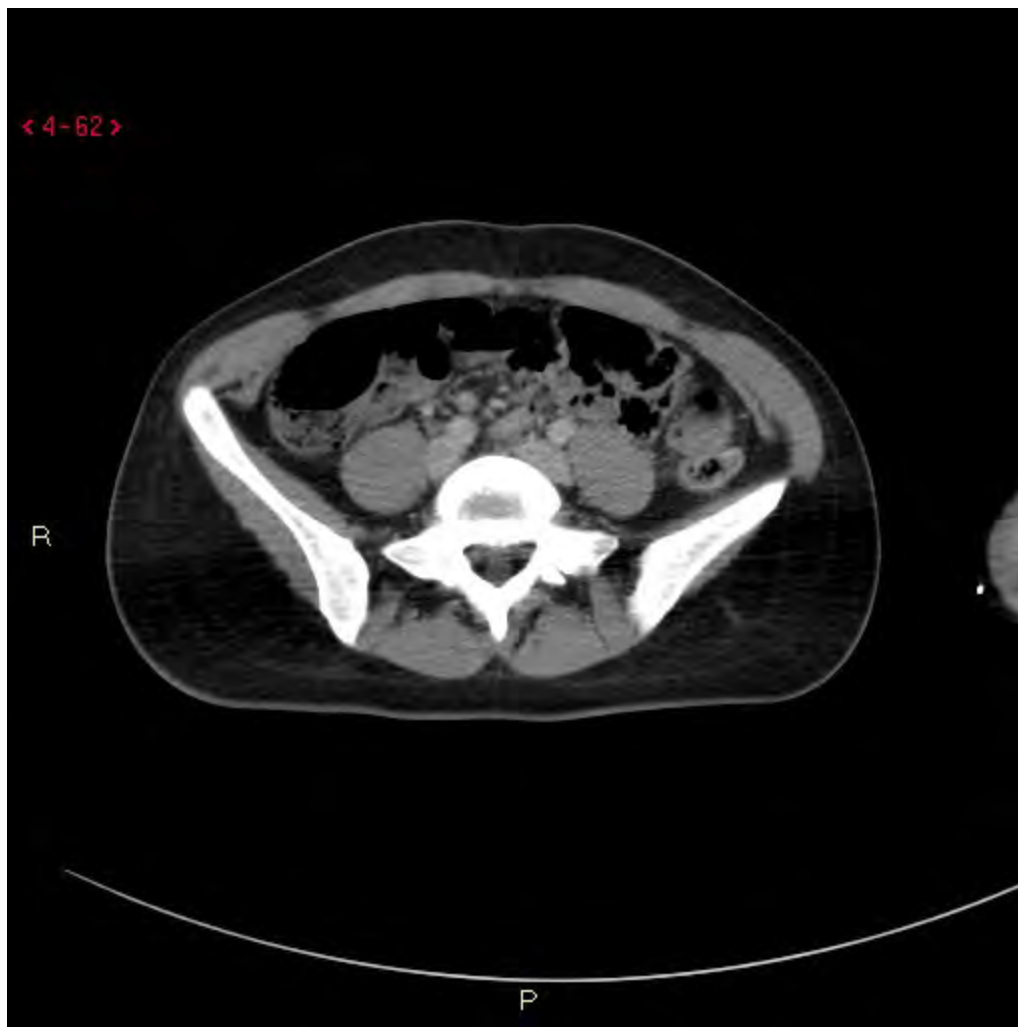
R

P





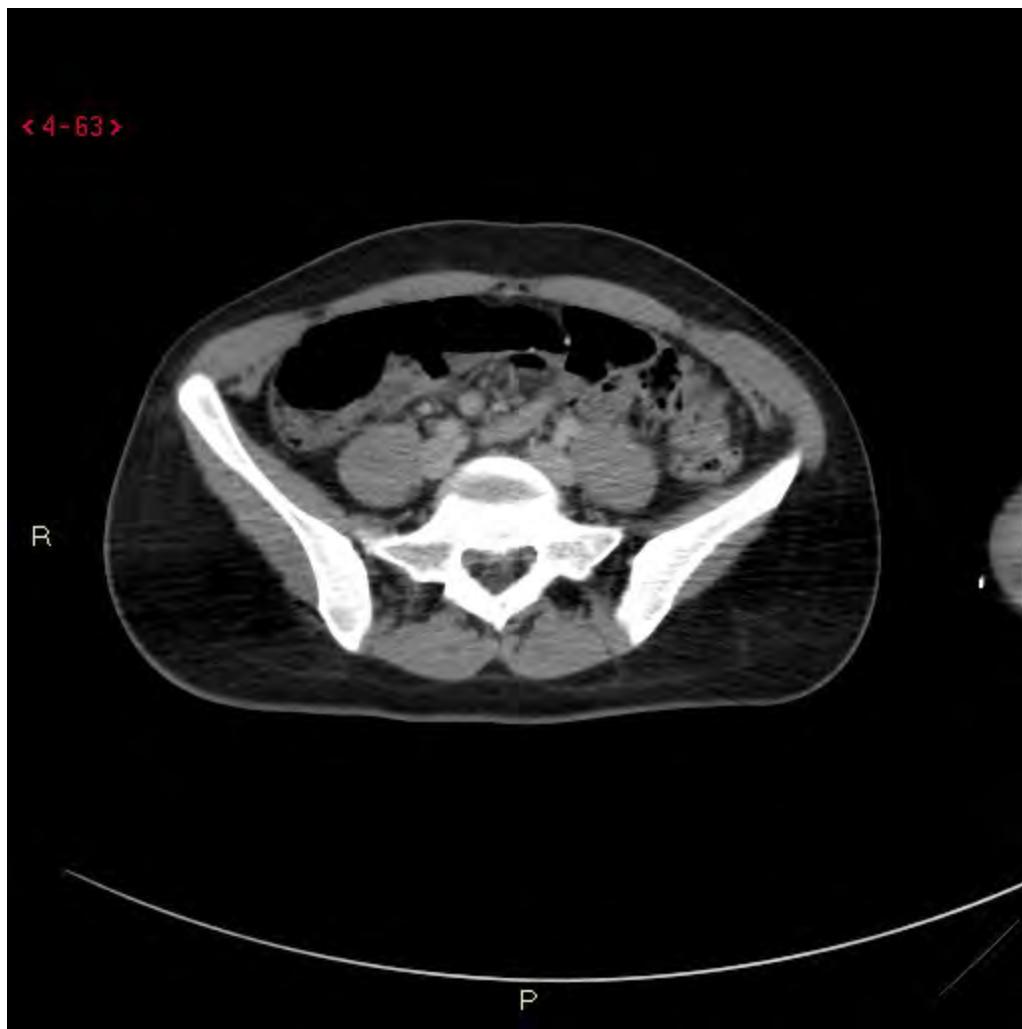


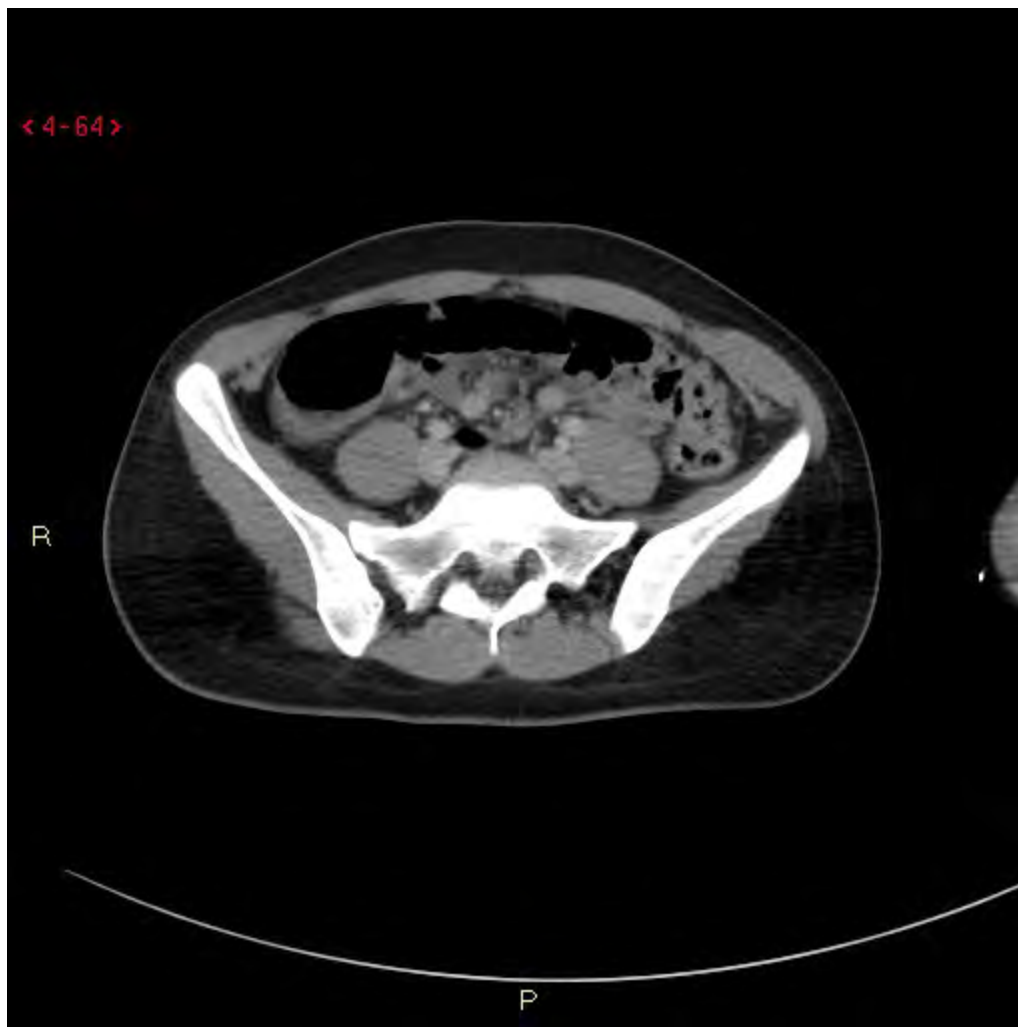

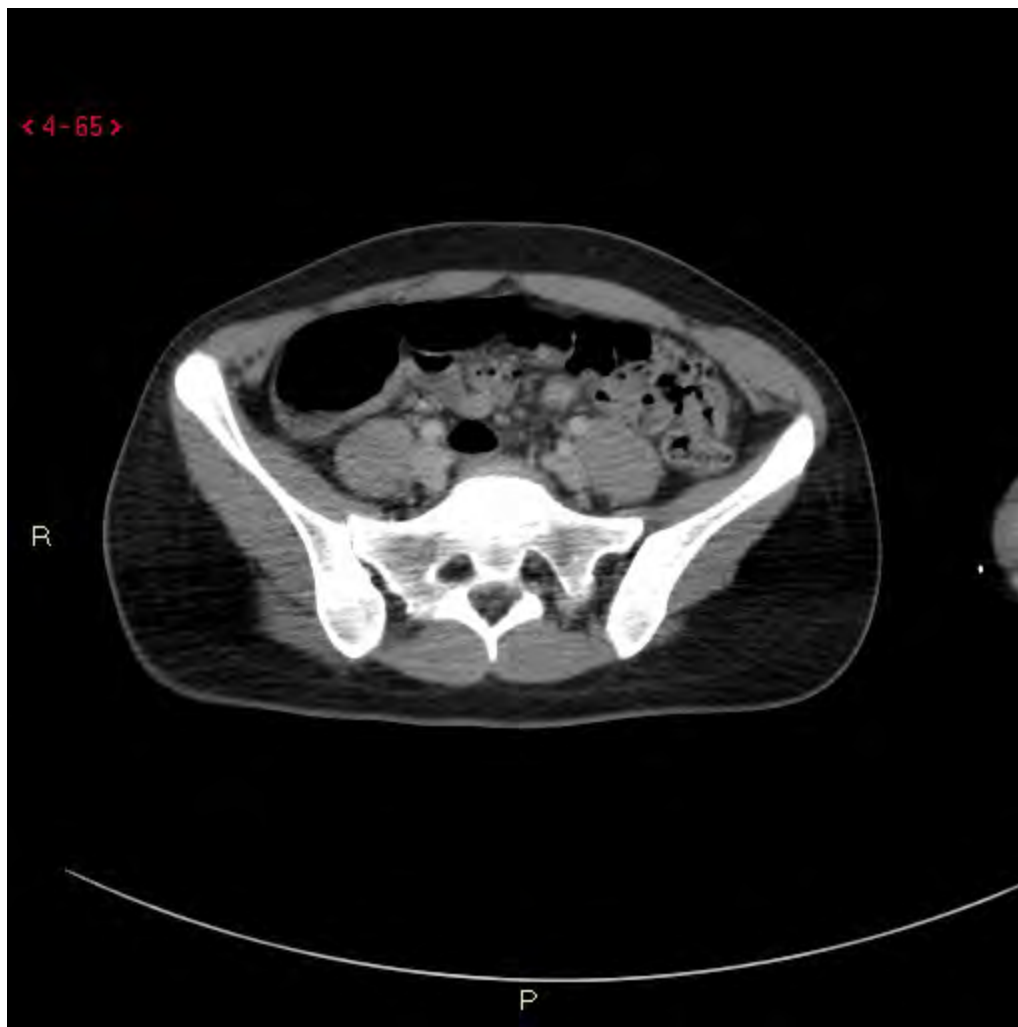
< 4-63 >

R

P

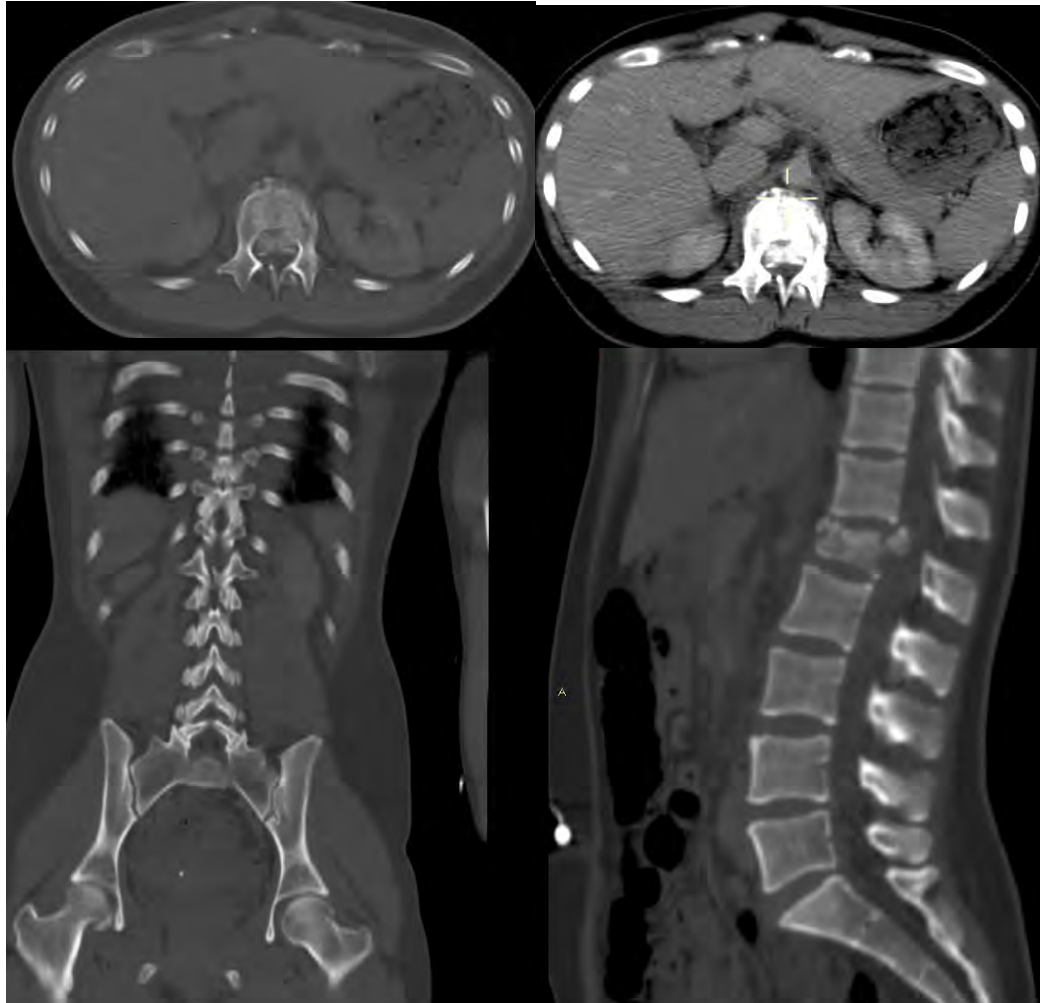






Fall 4

Fynd?



Fall 4

Morfologi:

Kompression fx: 1 p

Kompression fx + burst: **2 p**

Translation/rotation: 3 p

Distraktion: 4 p

Neurologiskt status

Intakt: 0 p

Nerv rot påverkan: 2 p

Ryggmärg, conus medullaris

Komplett: 2 p

Inkomplett: 3 p

Cauda equina: 3 p

Skada i bakre ligament
complex

Intakt: 0 p

Misstänkt: 2 p

Skada: 3 p







Poängsumma =

3 eller mindre konservativ
behandling

5 eller mer, kirurgi
övägs,

4 konservativt eller
kirurgiskt.

Fall 4

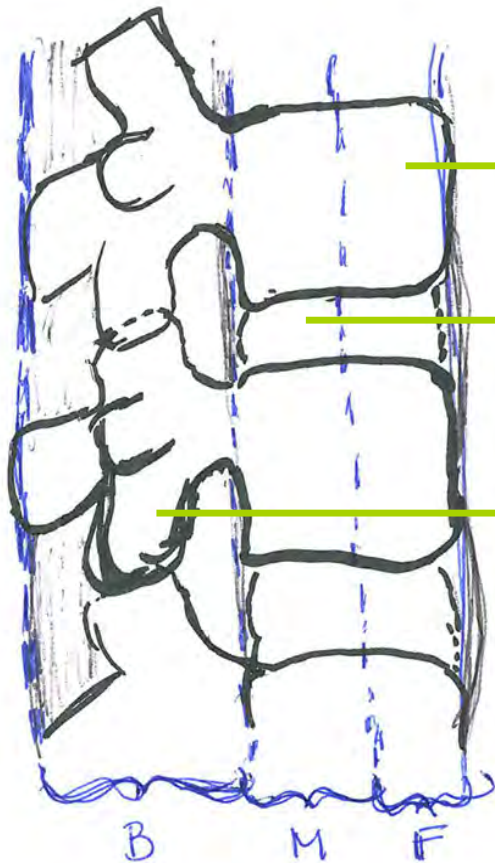
INJURY MECHANISM	TYPE	INJURY PATTERN	SUB-TYPE	STABILITY	APPROACH
	A			A1	STABLE Conservative (Log-Roll)
				A2	STABLE Conservative (Log-Roll) consider secondary anterior surgery in A2.3 (pincer) fractures
				A3	UNSTABLE Damage control spine surgery using perc. post. Instrument. in A3.2/.3 Consider conservative in some A3.1
	B			B1	UNSTABLE Damage control spine surgery using perc. post. Instrument. if sufficient closed reduction is feasible
				B2	UNSTABLE Otherwise and for decompression use open approach.
				B3	UNSTABLE Consider secondary anterior fusion
	C			C1	UNSTABLE Damage control spine surgery using open approach in the first place since closed reduction is insufficient and decompression is needed often.
				C2	UNSTABLE Only in rare cases perc. post. Instrument. feasible.
				C3	UNSTABLE Consider secondary anterior fusion

M
A
G
E
R
L
/
A
O



Fall 4

Bröst- och Ländrygg



Främre pelare: ALL
ventrala $\frac{1}{2}$ av kotkroppen-disken

Mellersta pelare: PLL
dorsala $\frac{1}{2}$ av kotkroppen-disken

Bakre pelare: Pediklar
Ledutskott, facettleder,
spinalutskott

Fall 4

Stabil?

Fall 4

Stabil?

