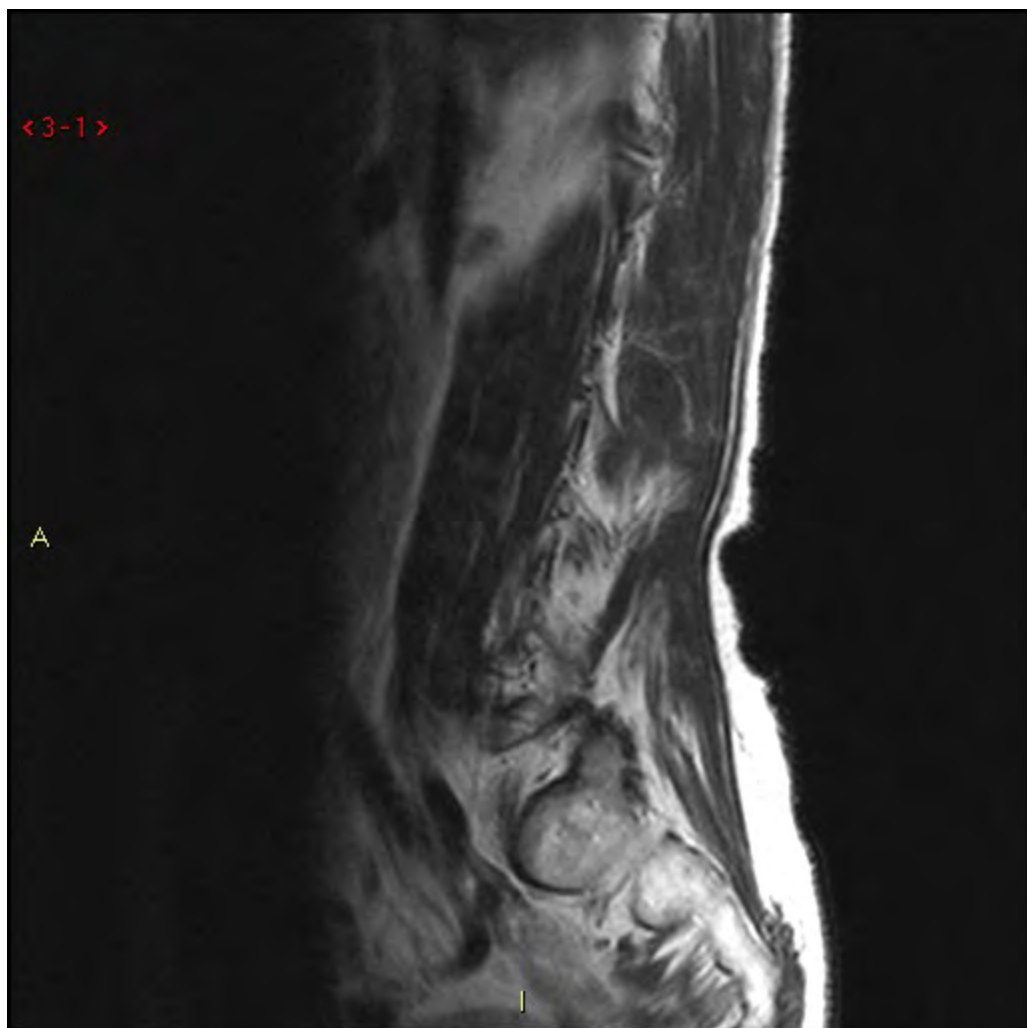
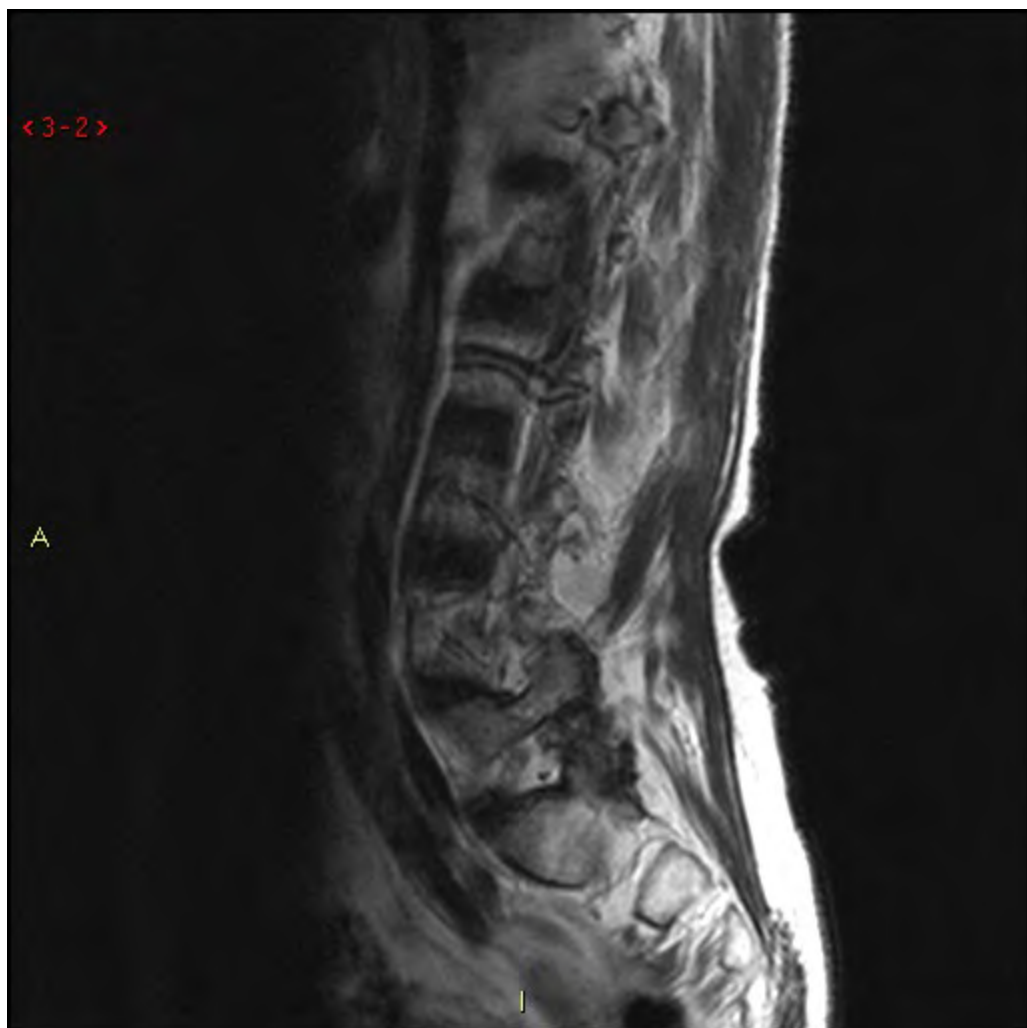
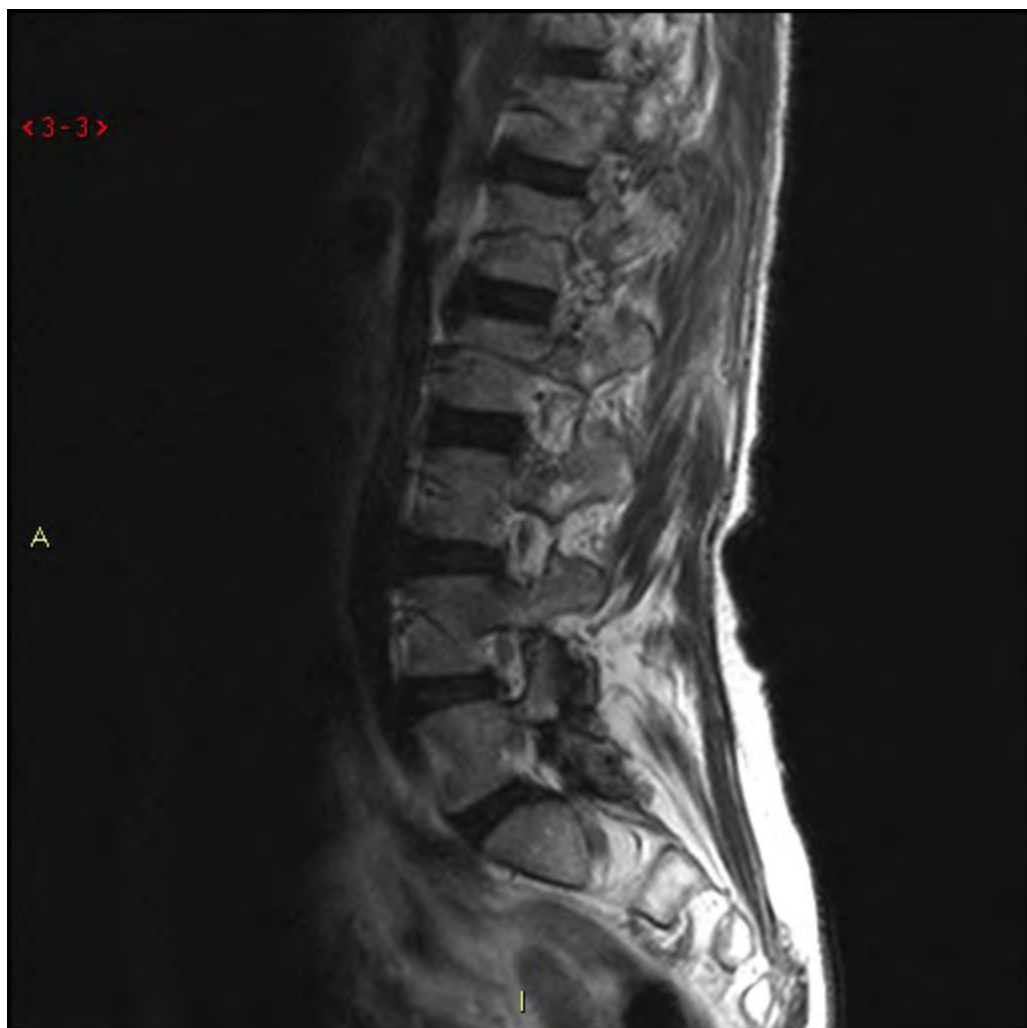Fall 7

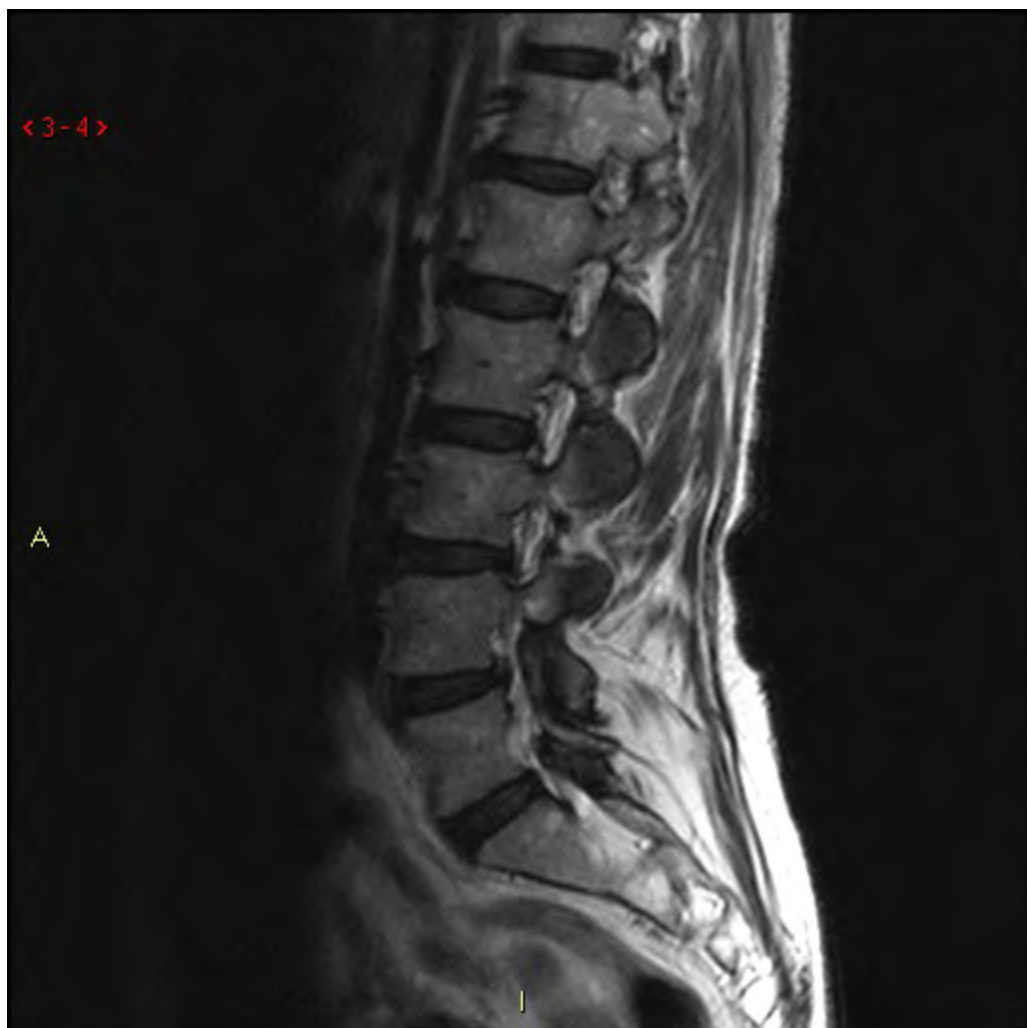Fall 7

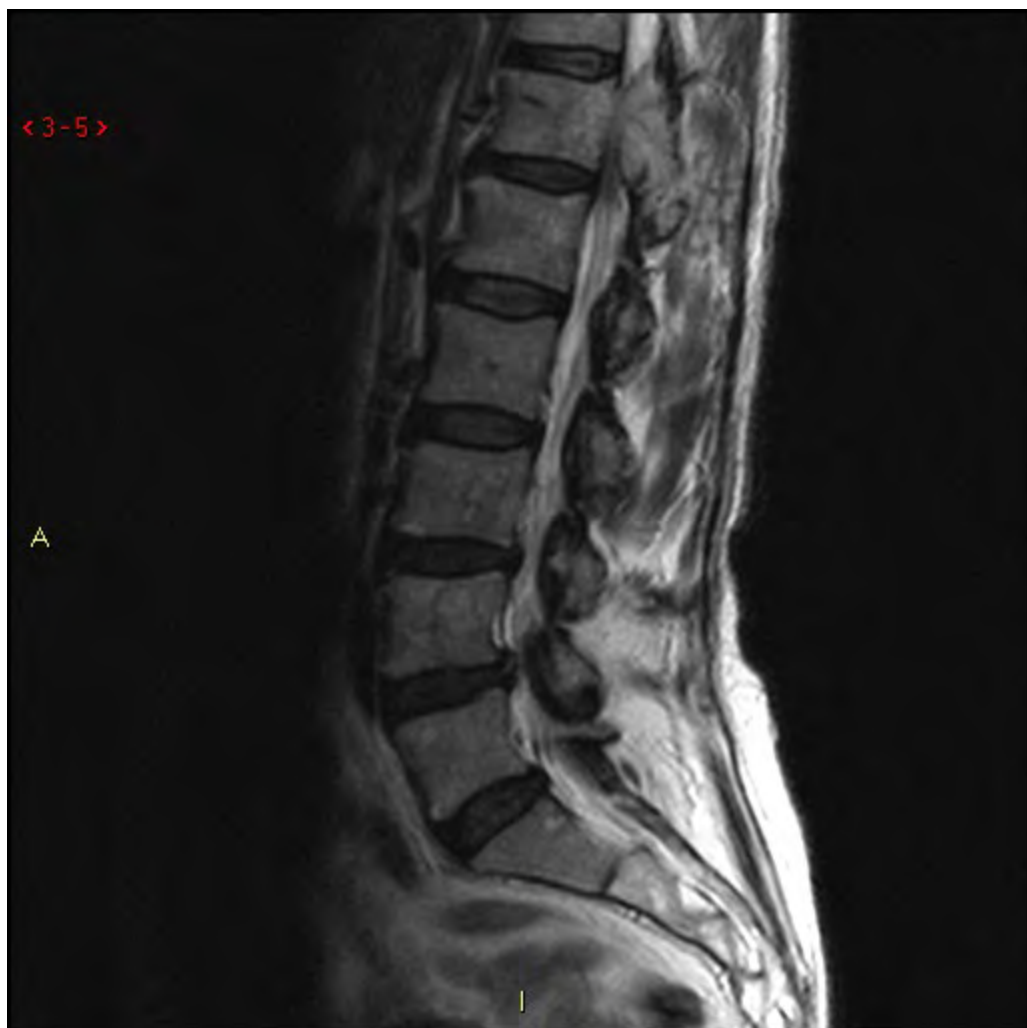73 år, K. sedan 2 månader ländryggssmärta
och sedan två veckor tillbaka
bensvaghet som verkar progrediera.
Svårt med kontroll av rörelser i benen.
MRT från regionen.

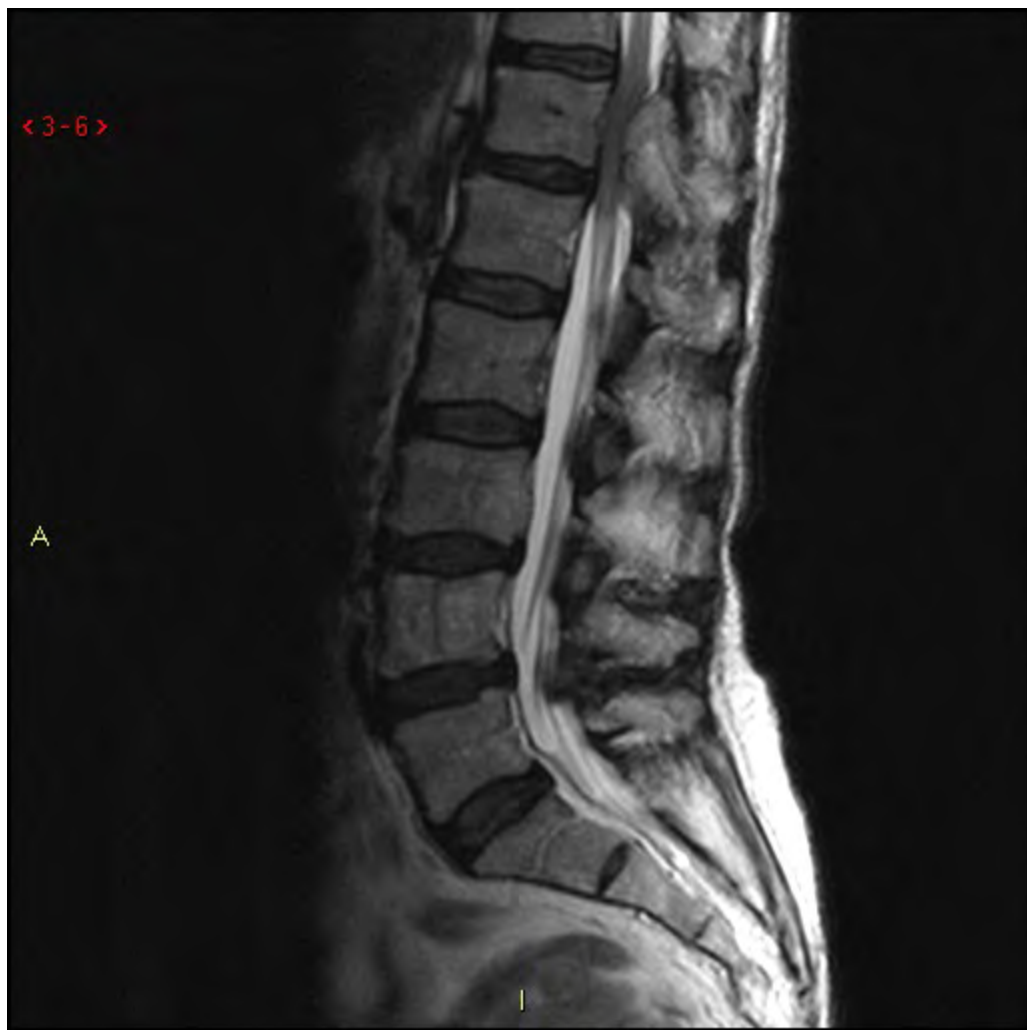


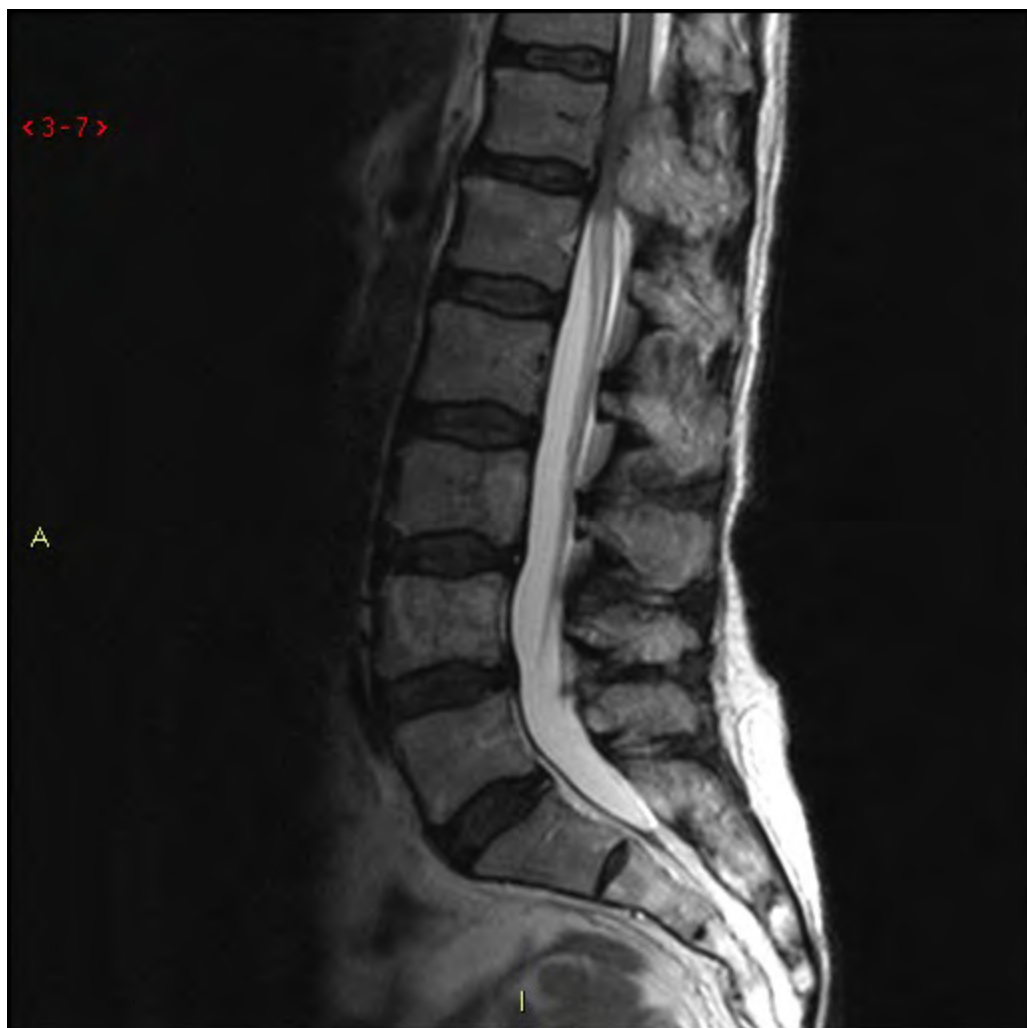


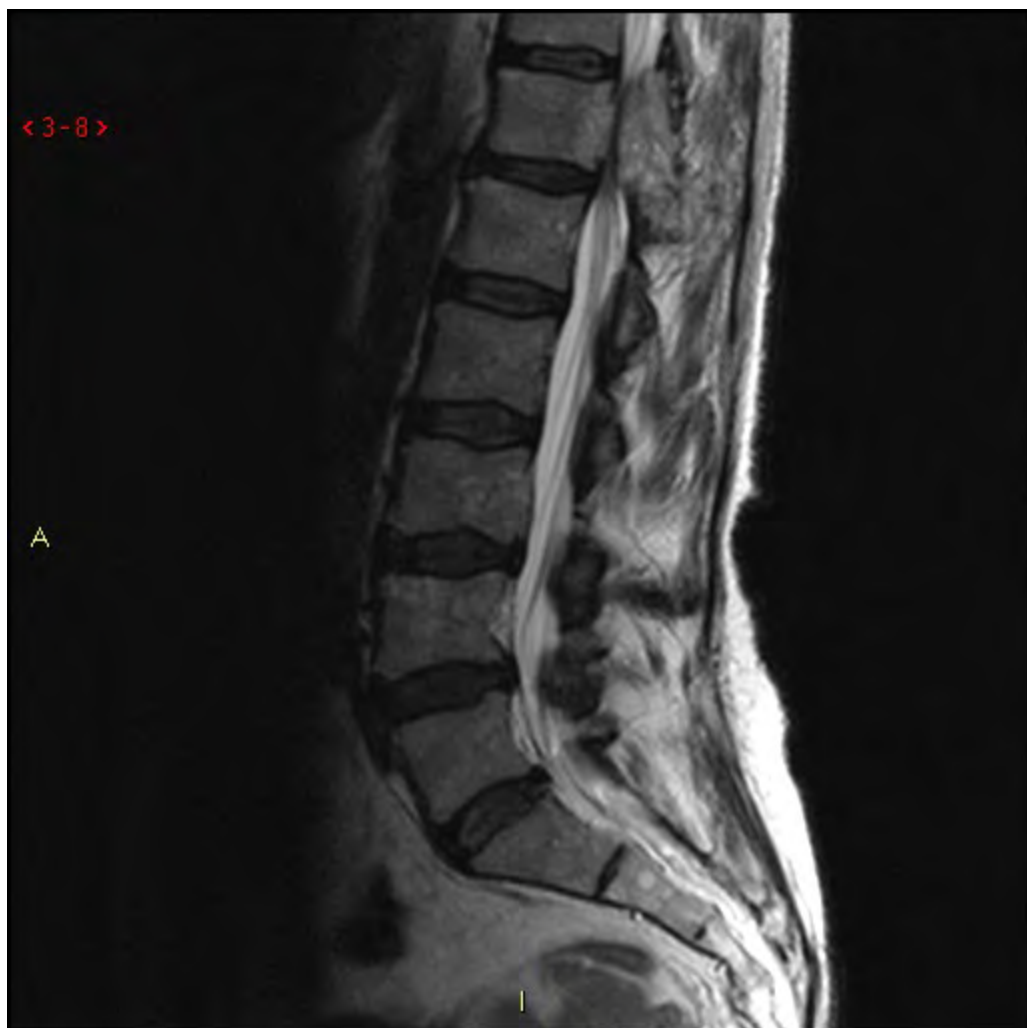


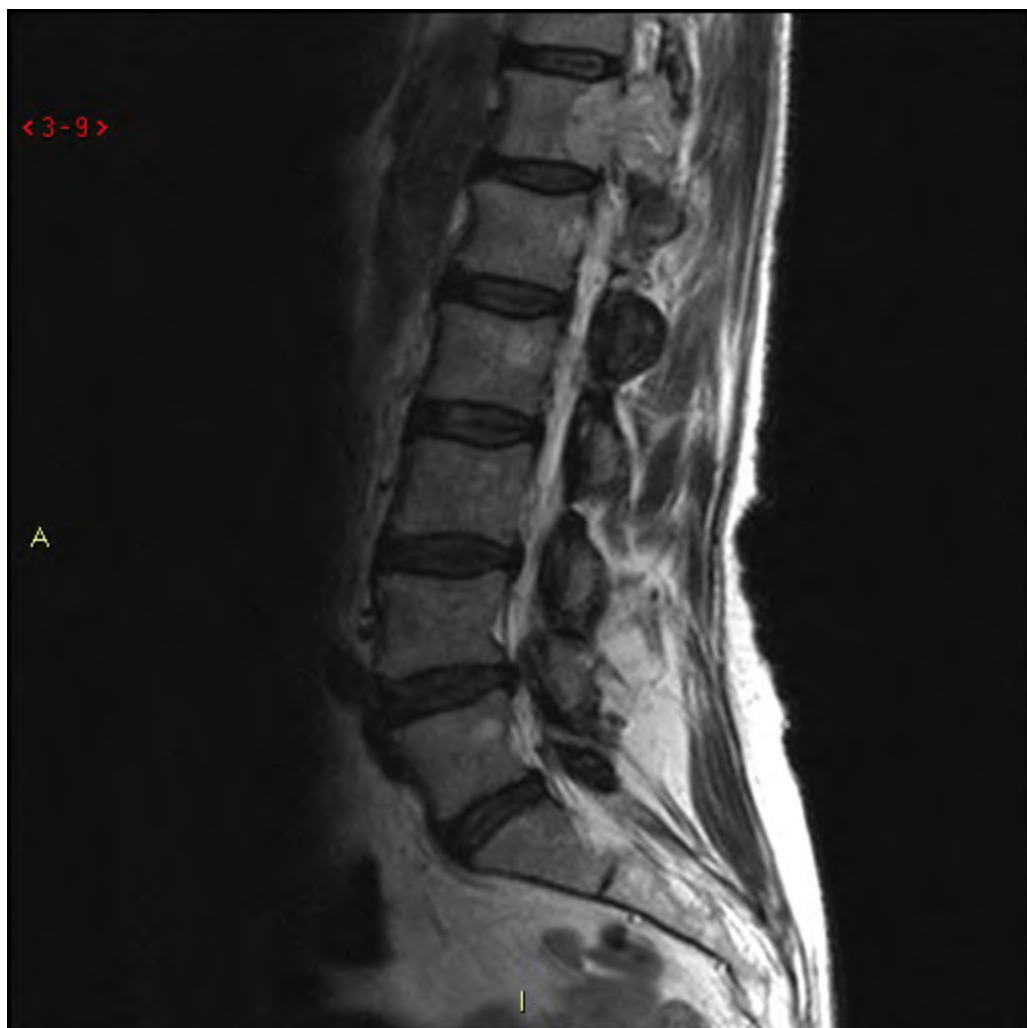


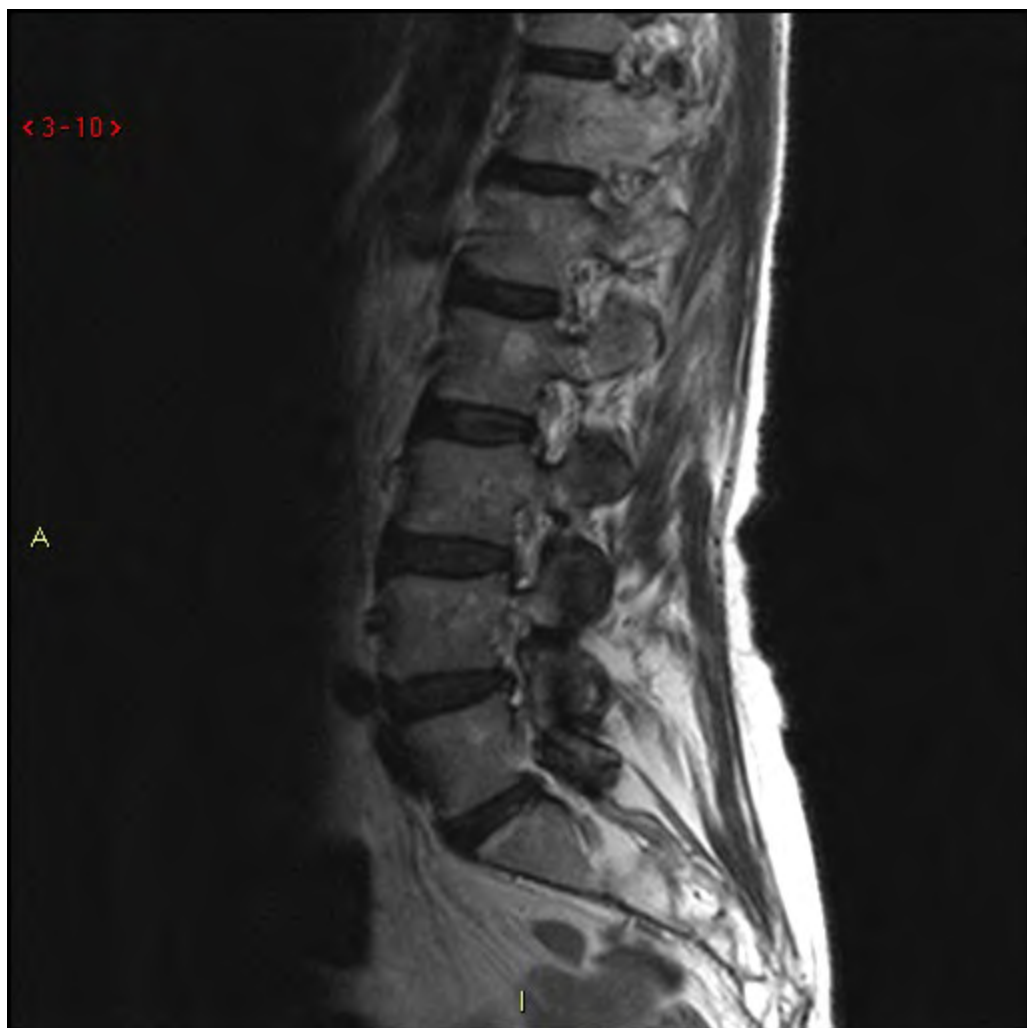

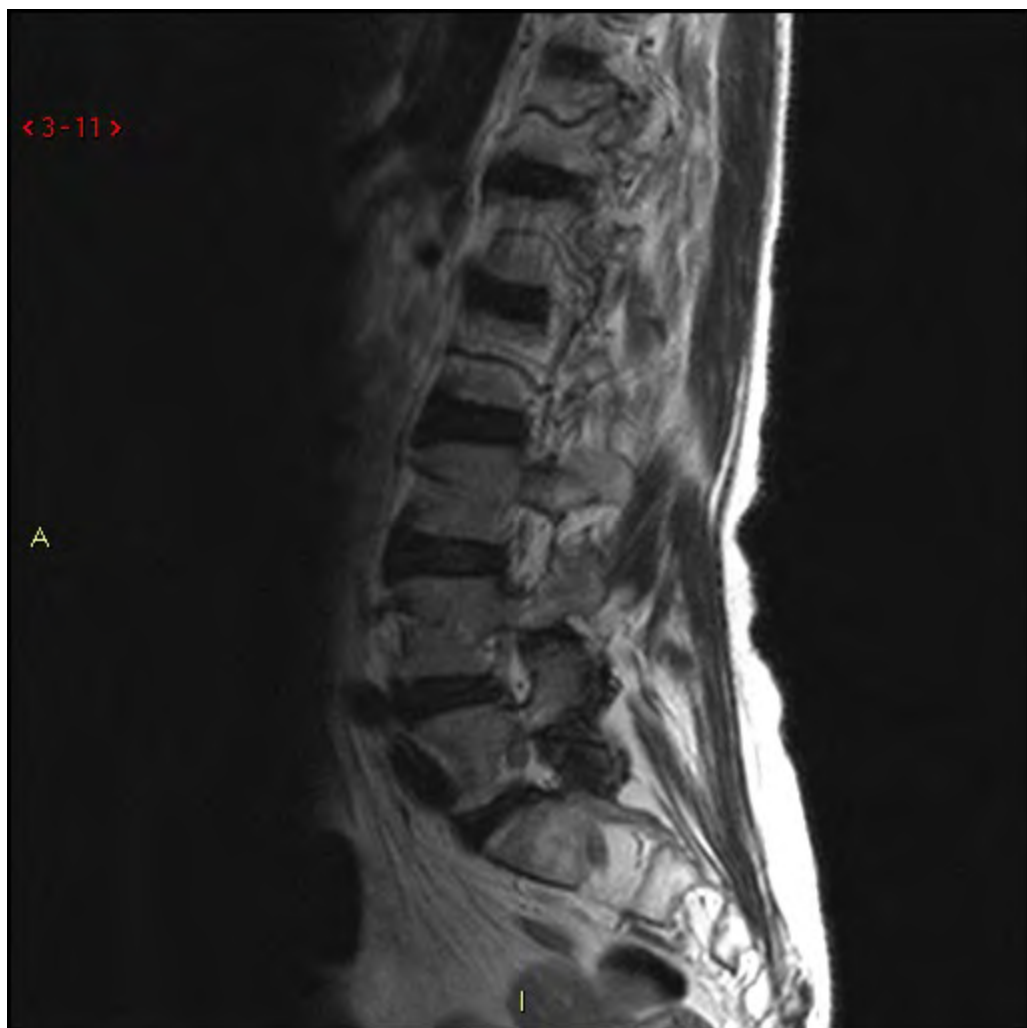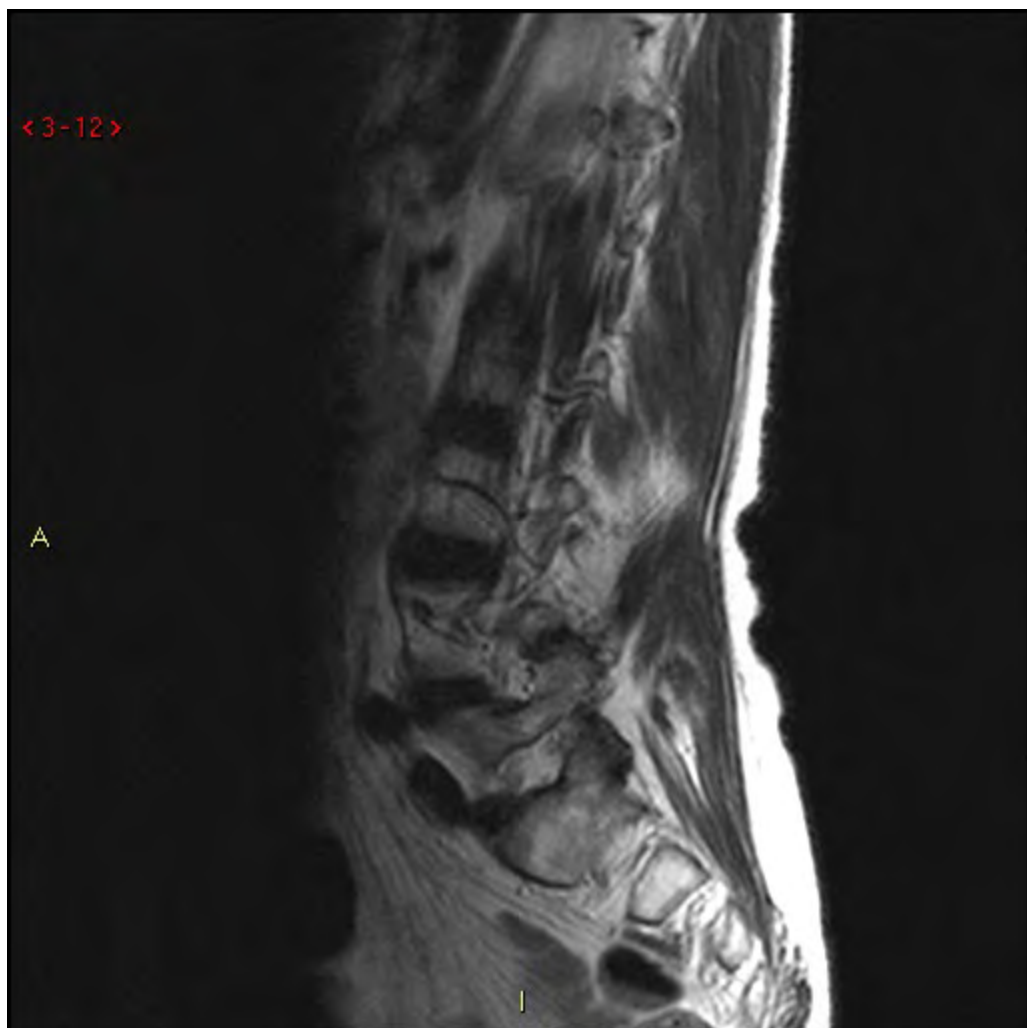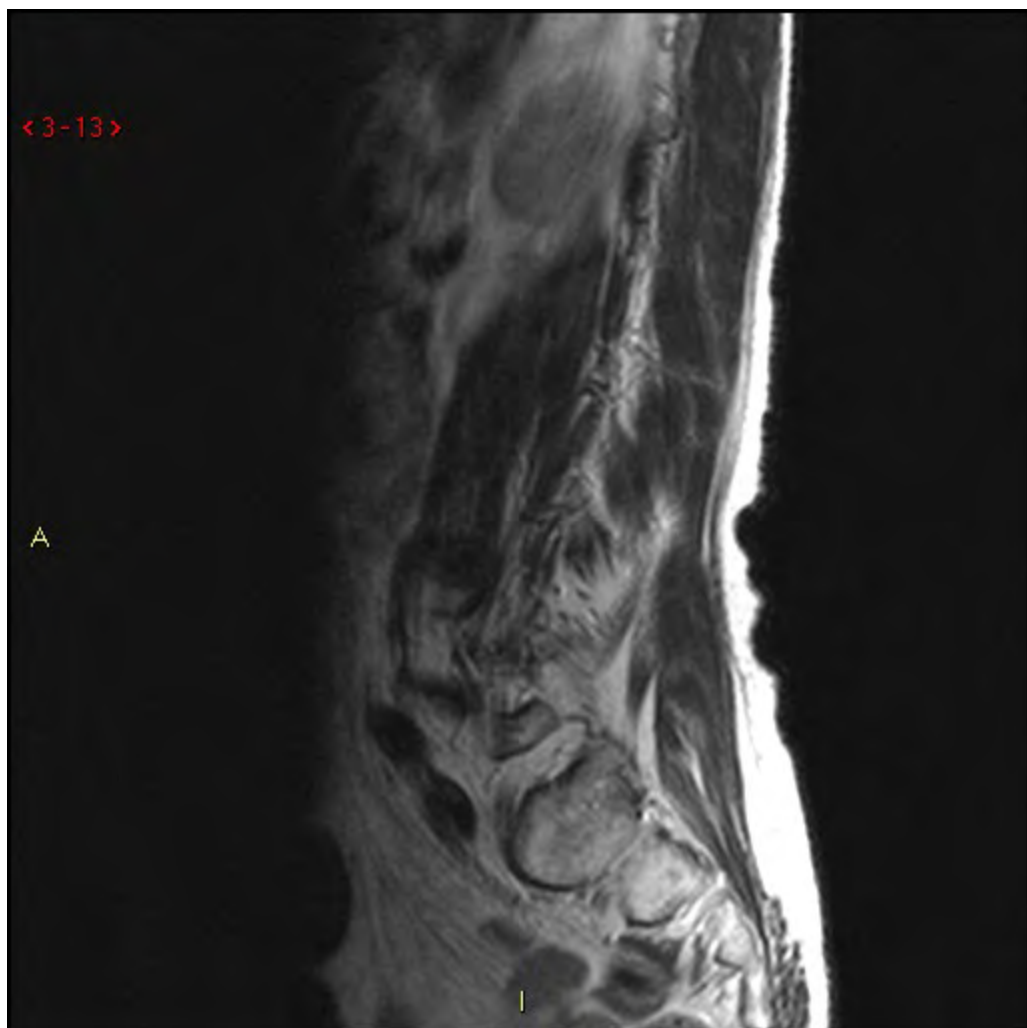









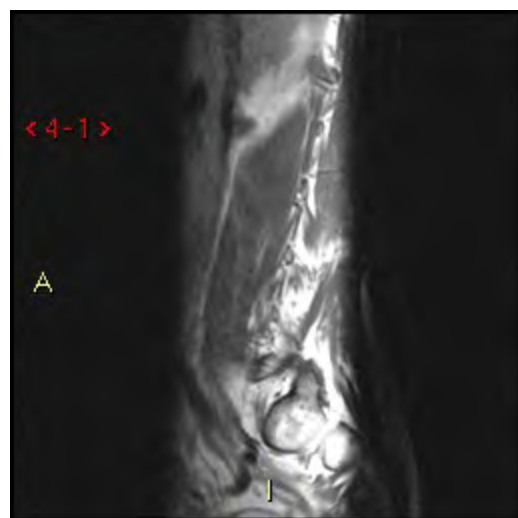


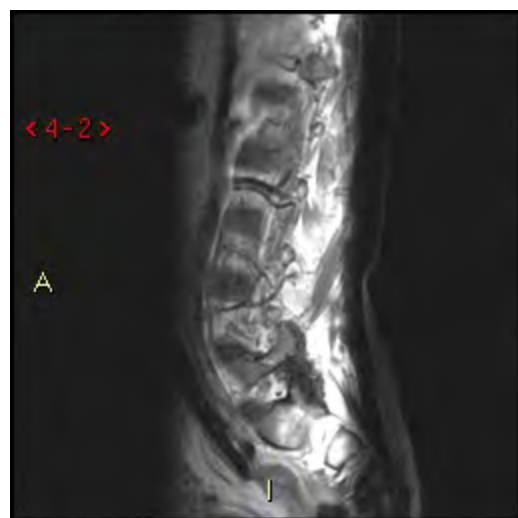


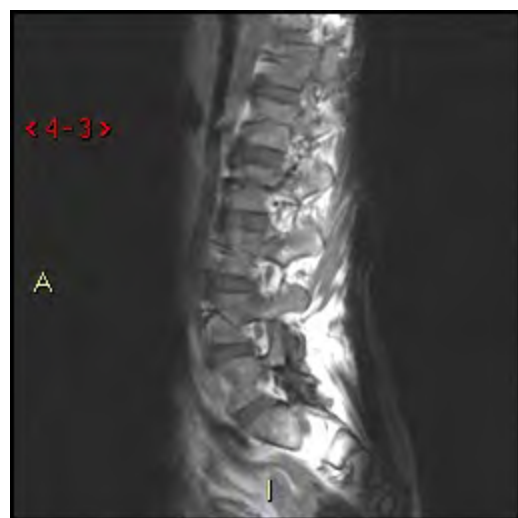


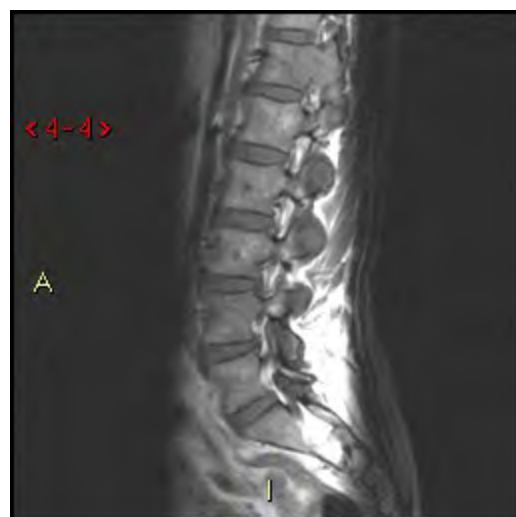


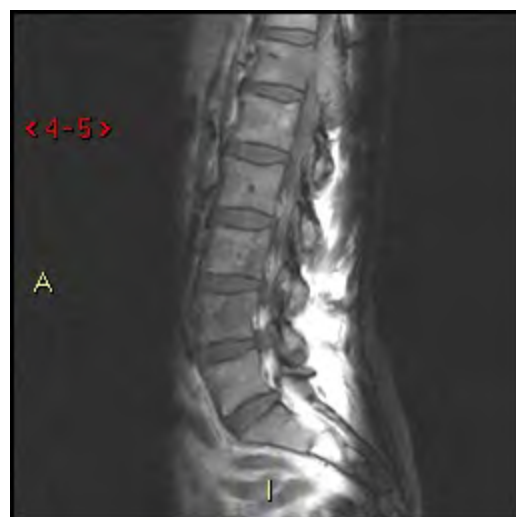


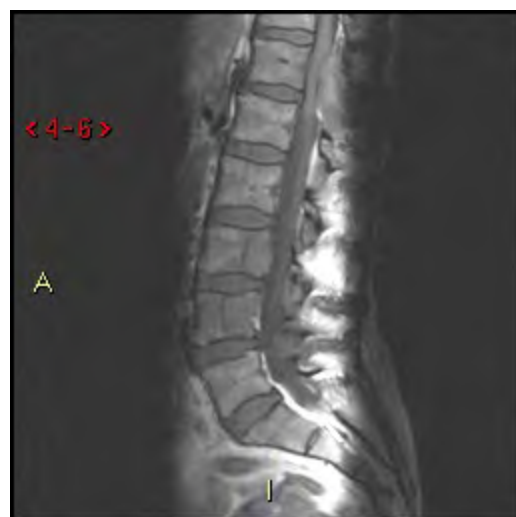

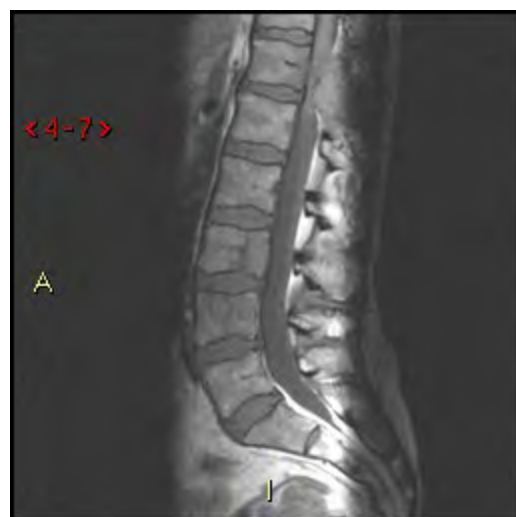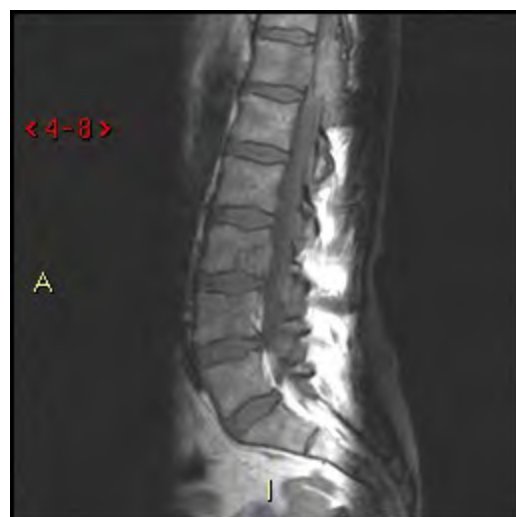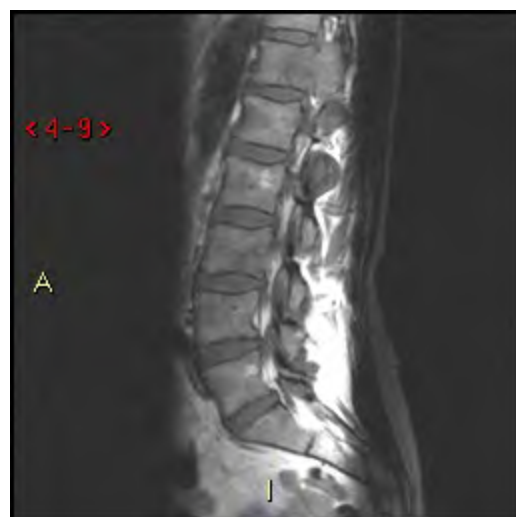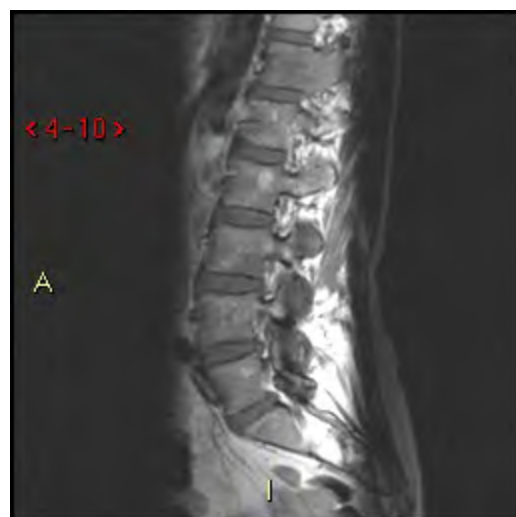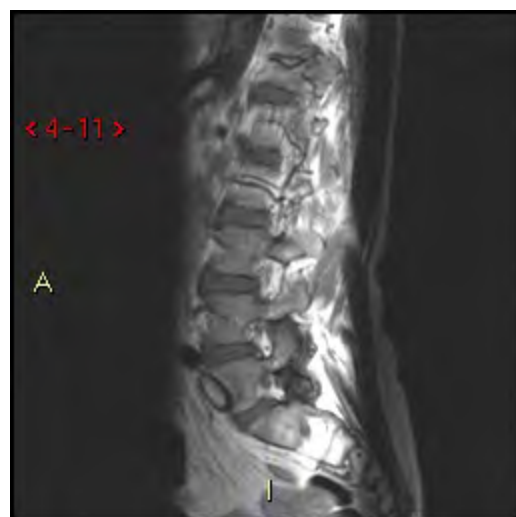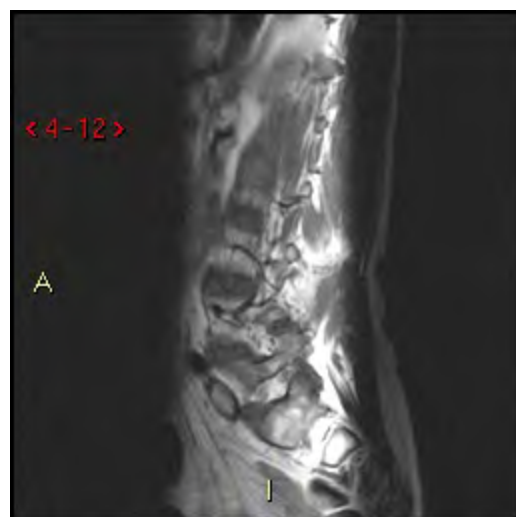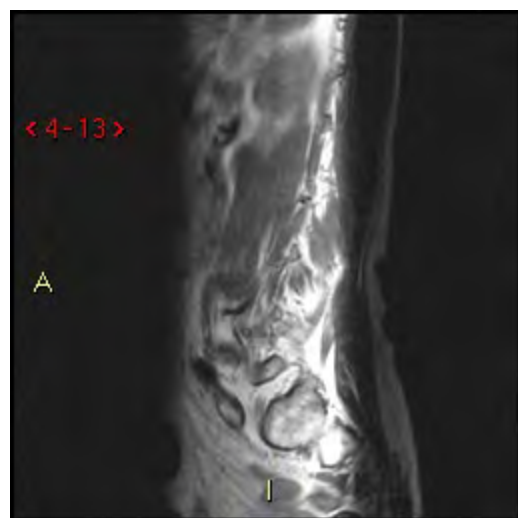





















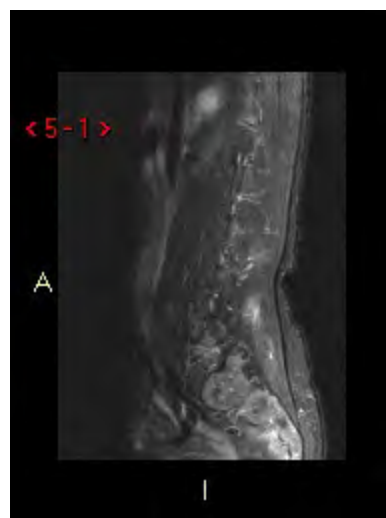


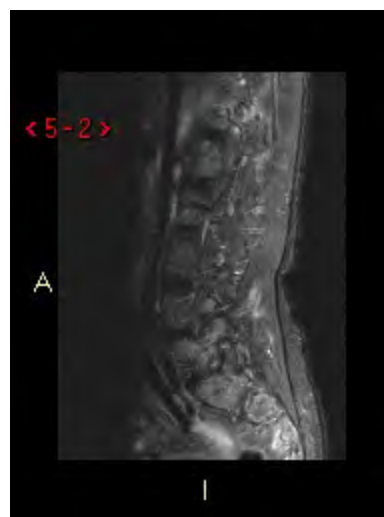


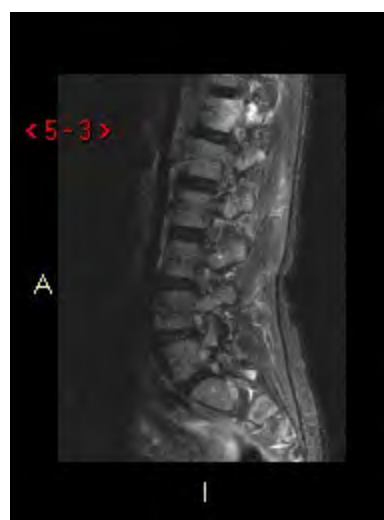

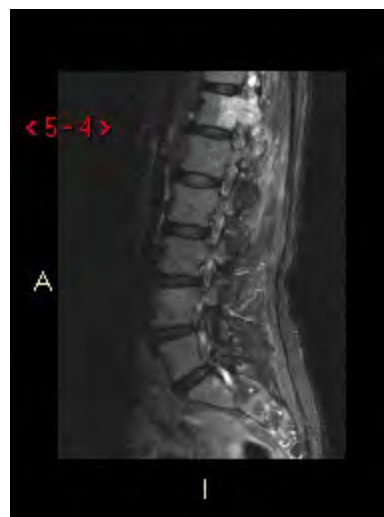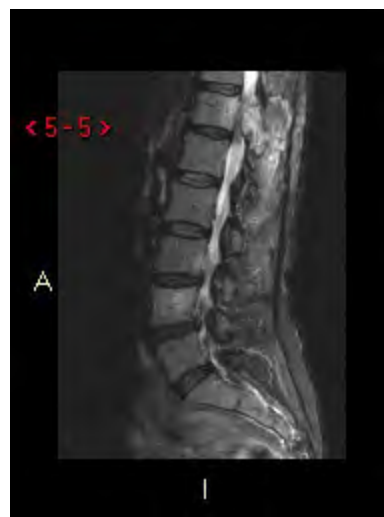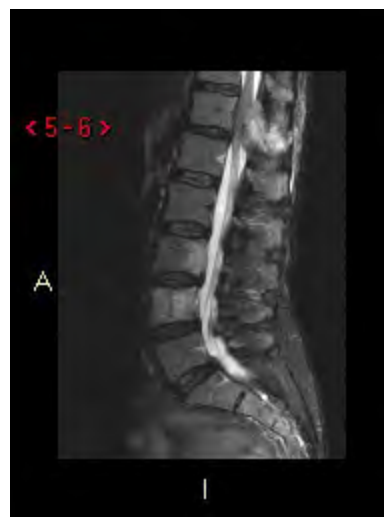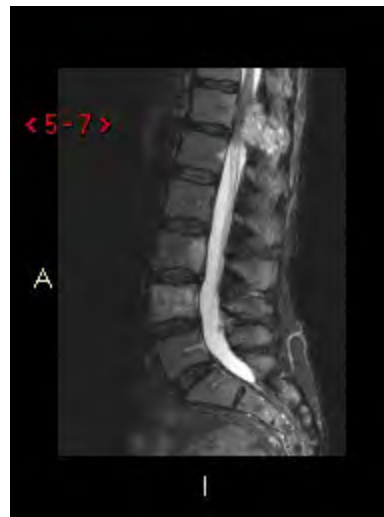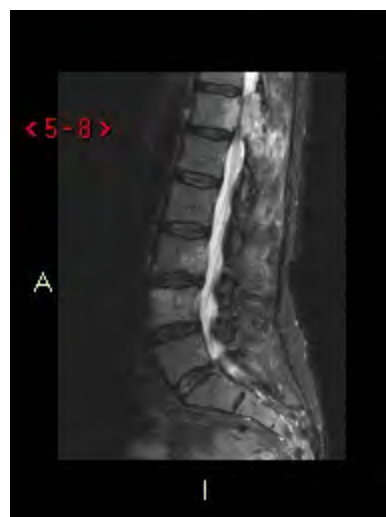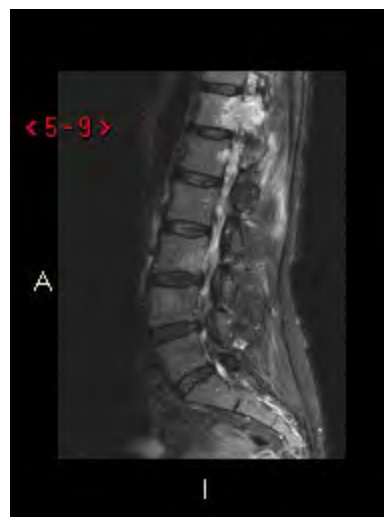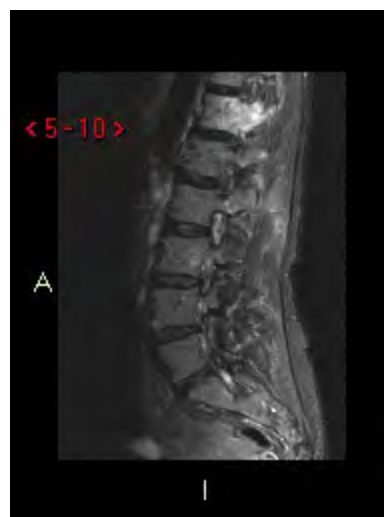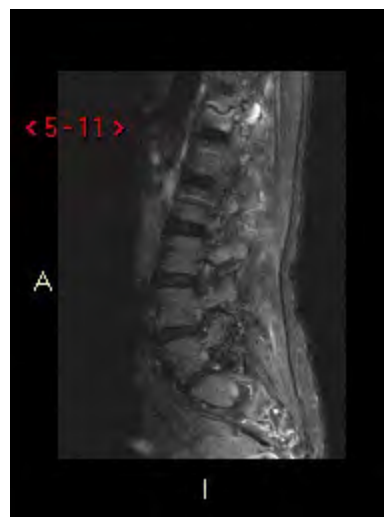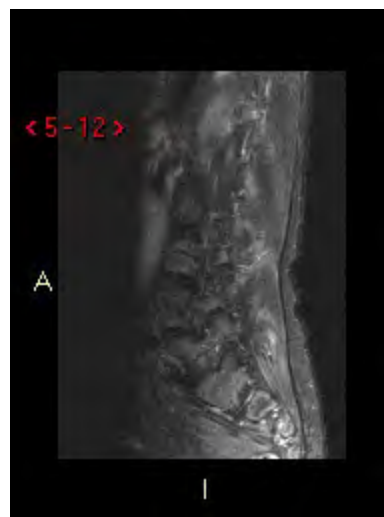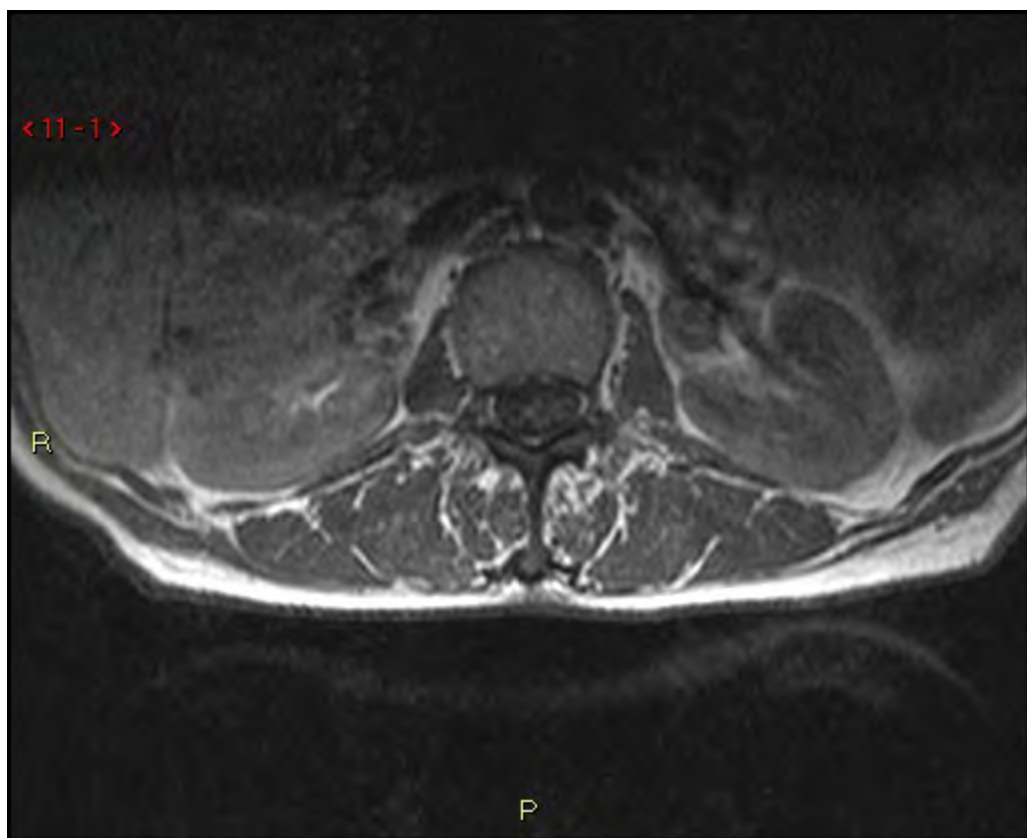


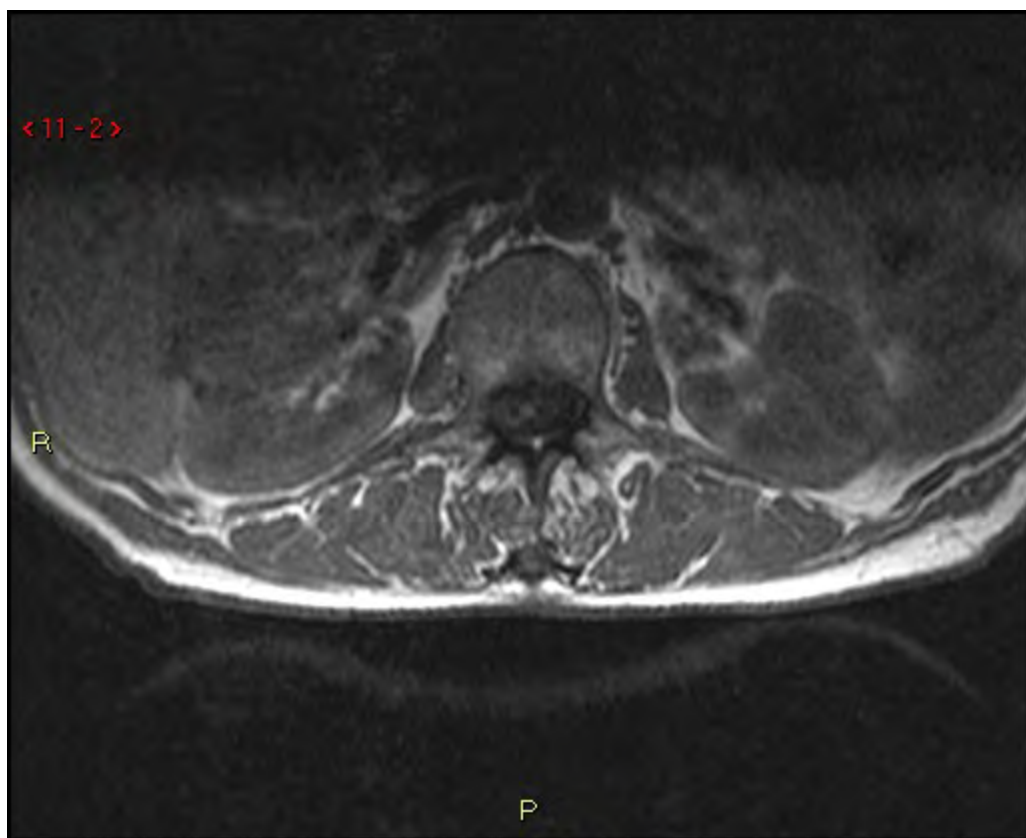


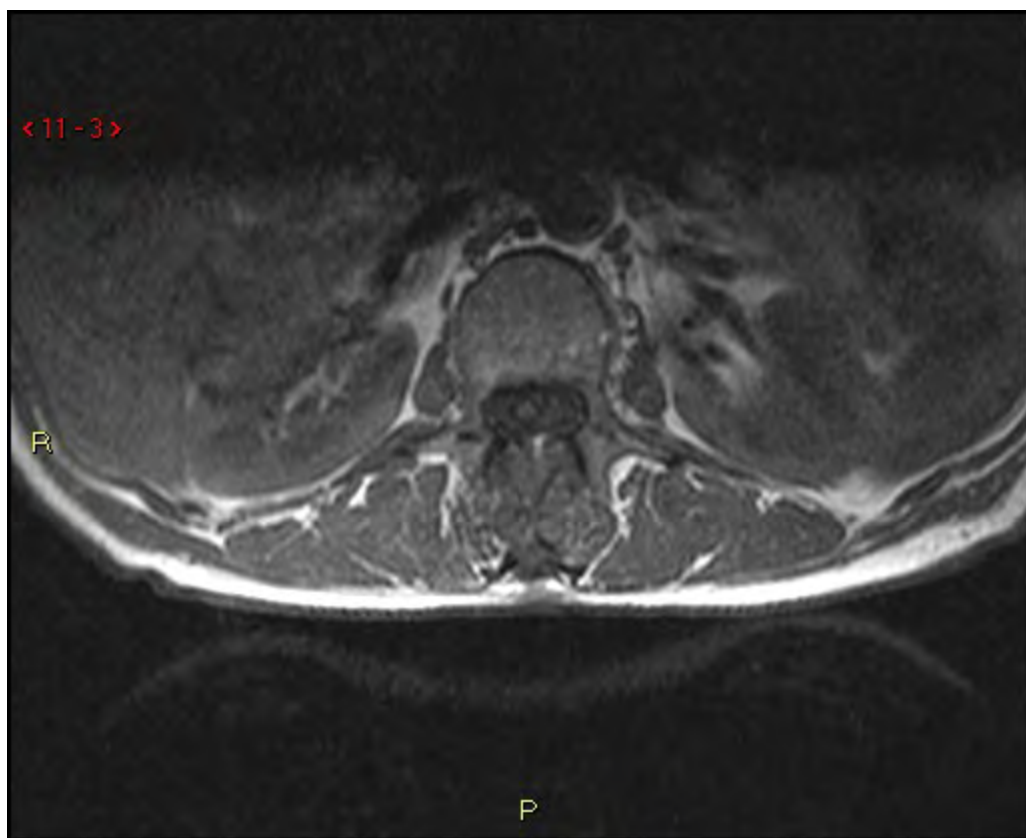


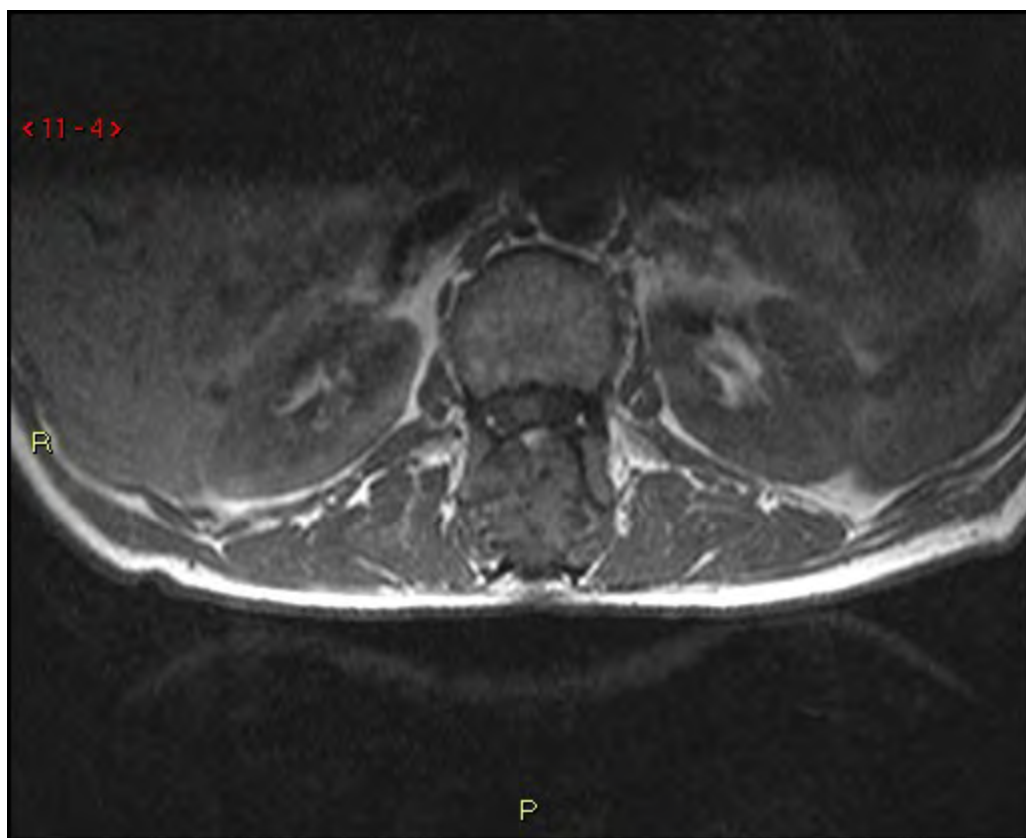


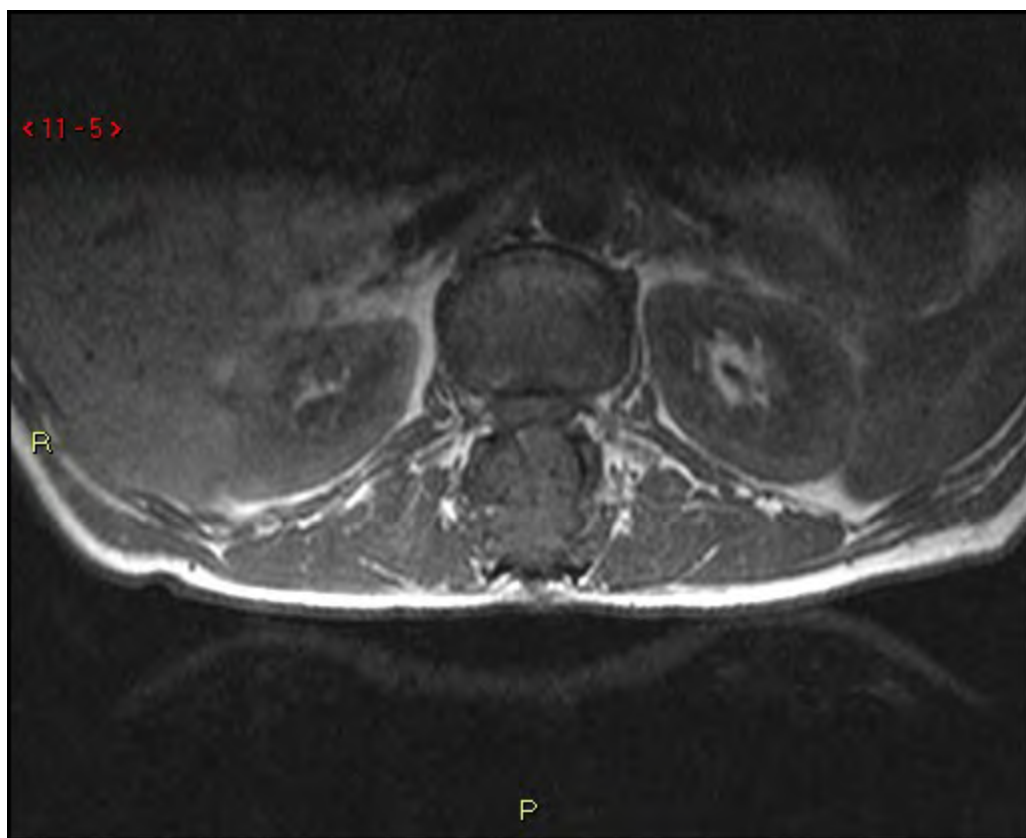


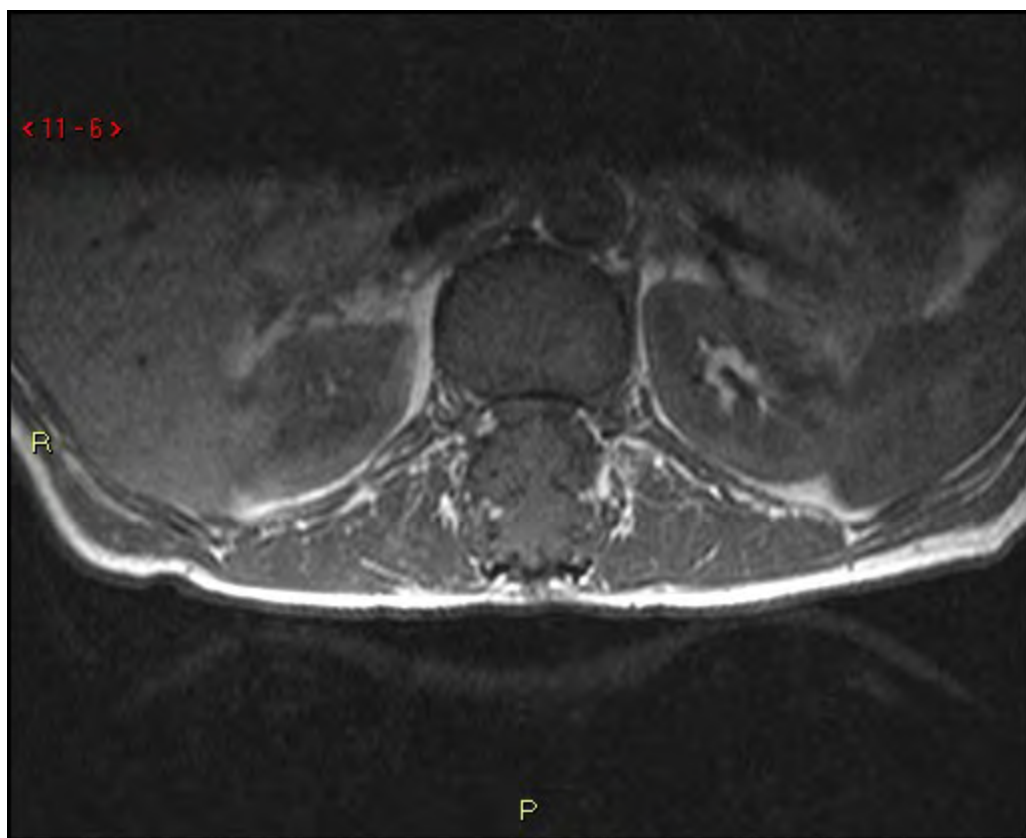


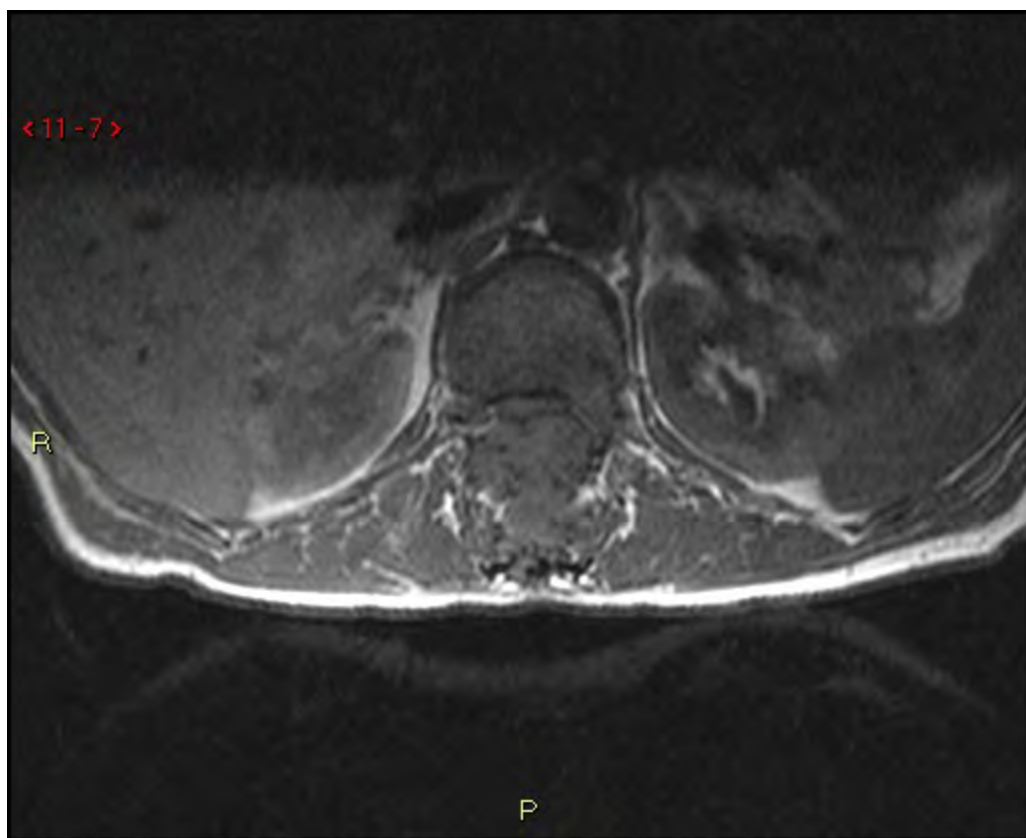


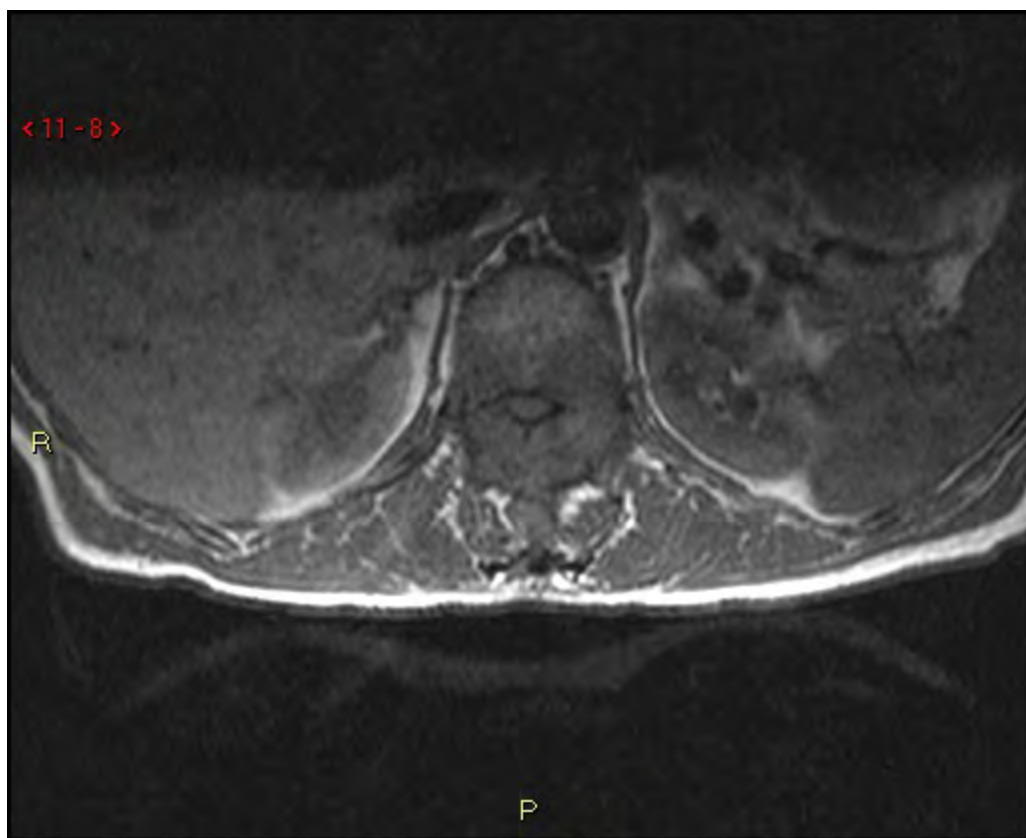


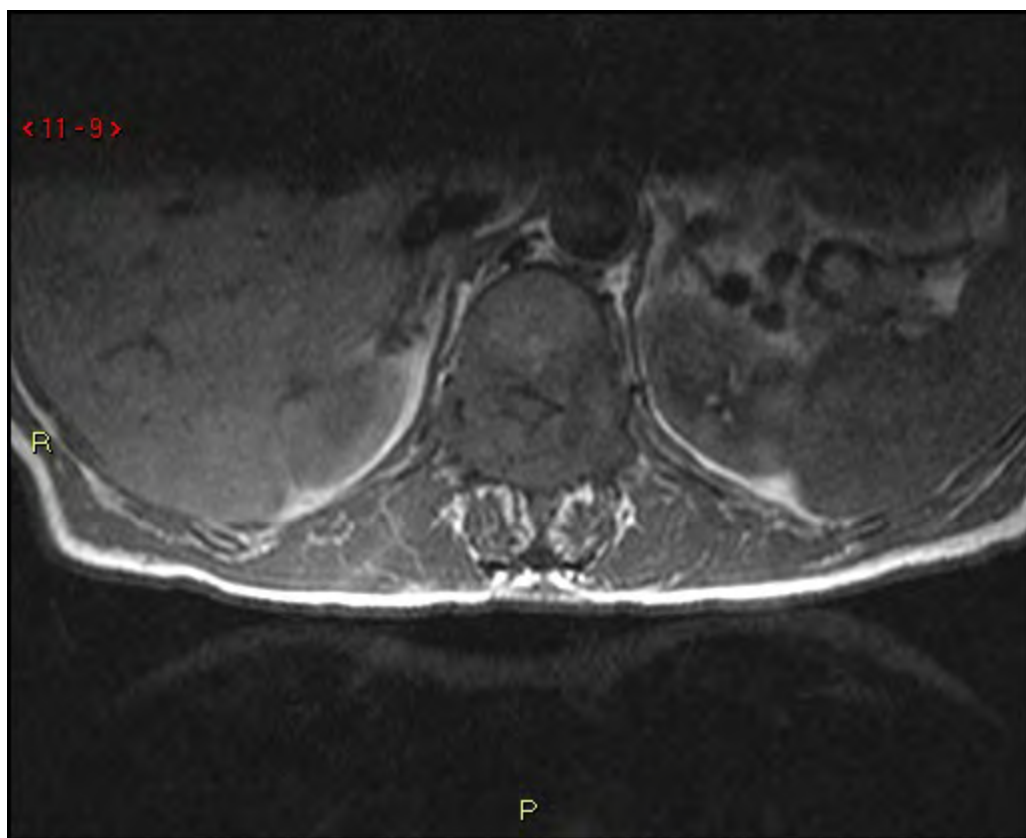


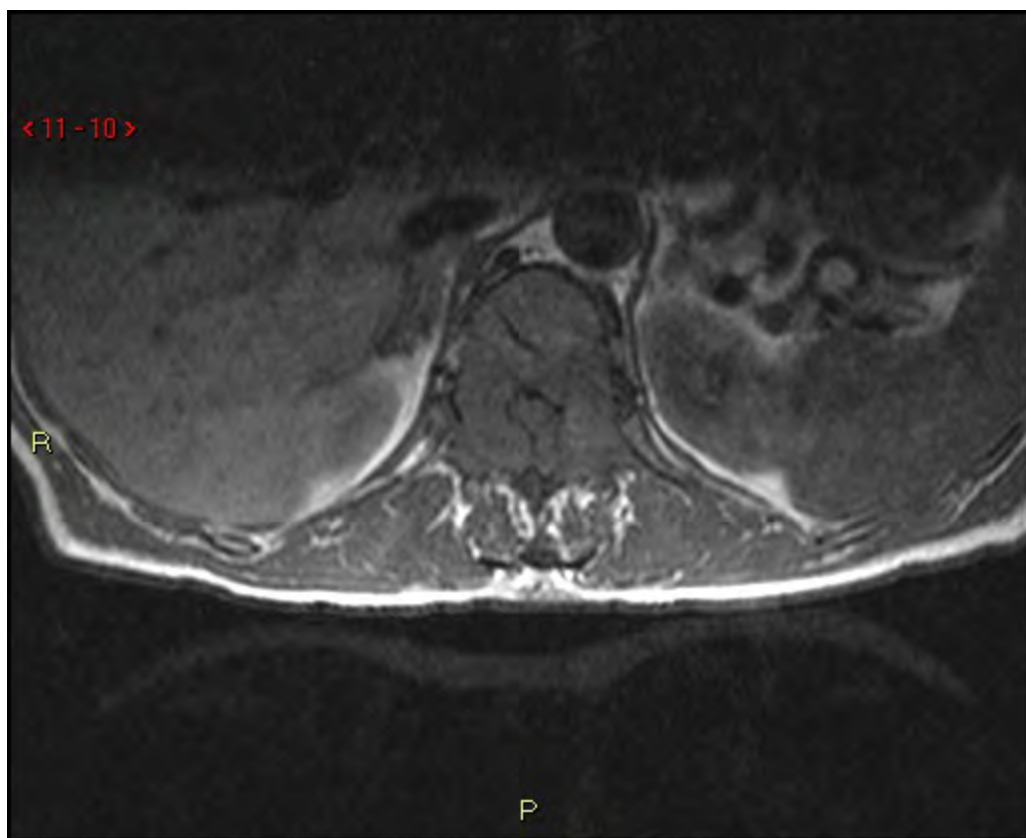


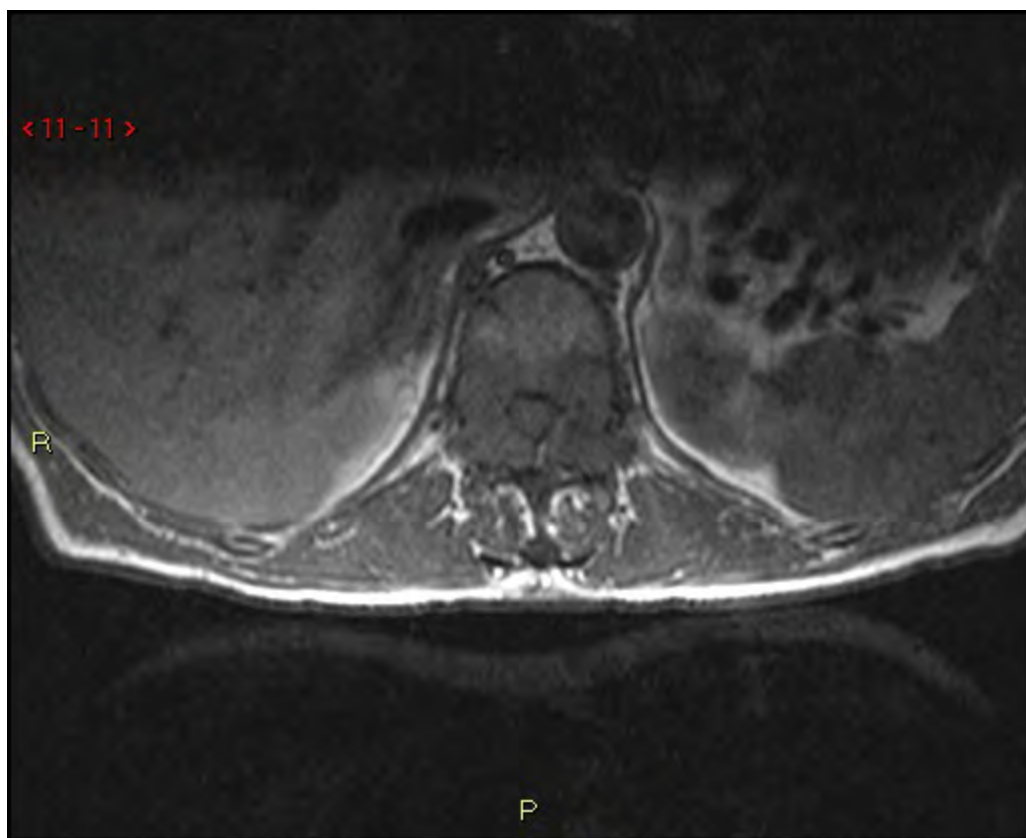


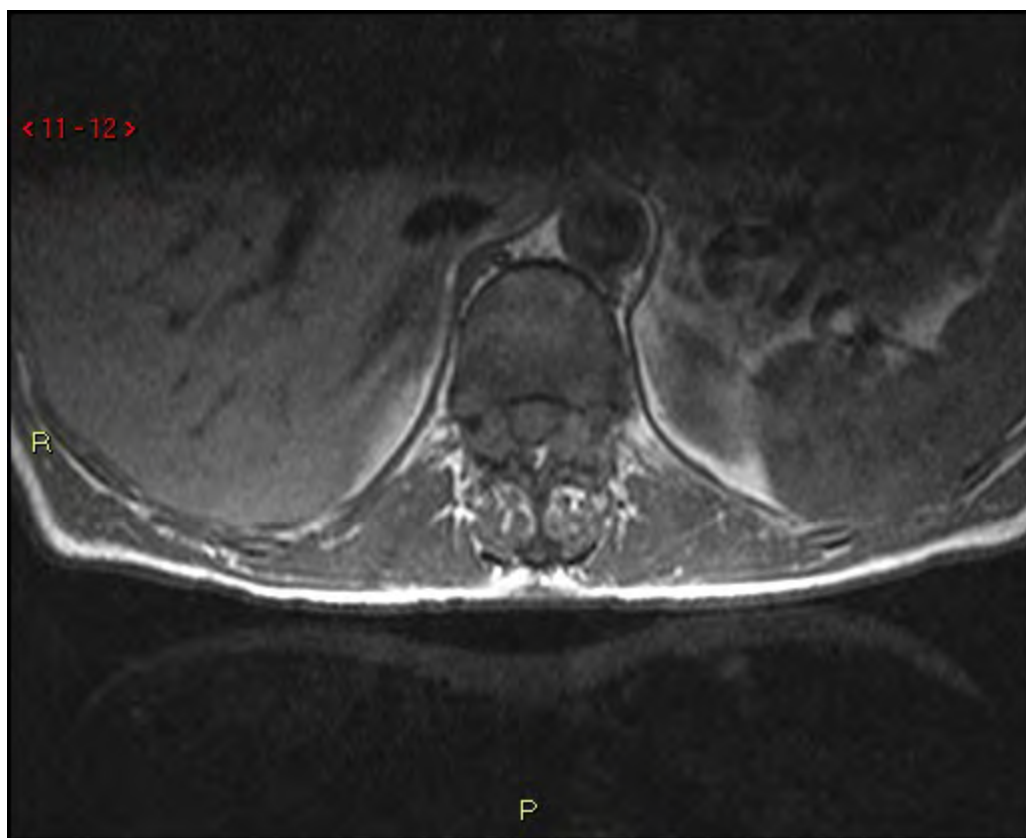


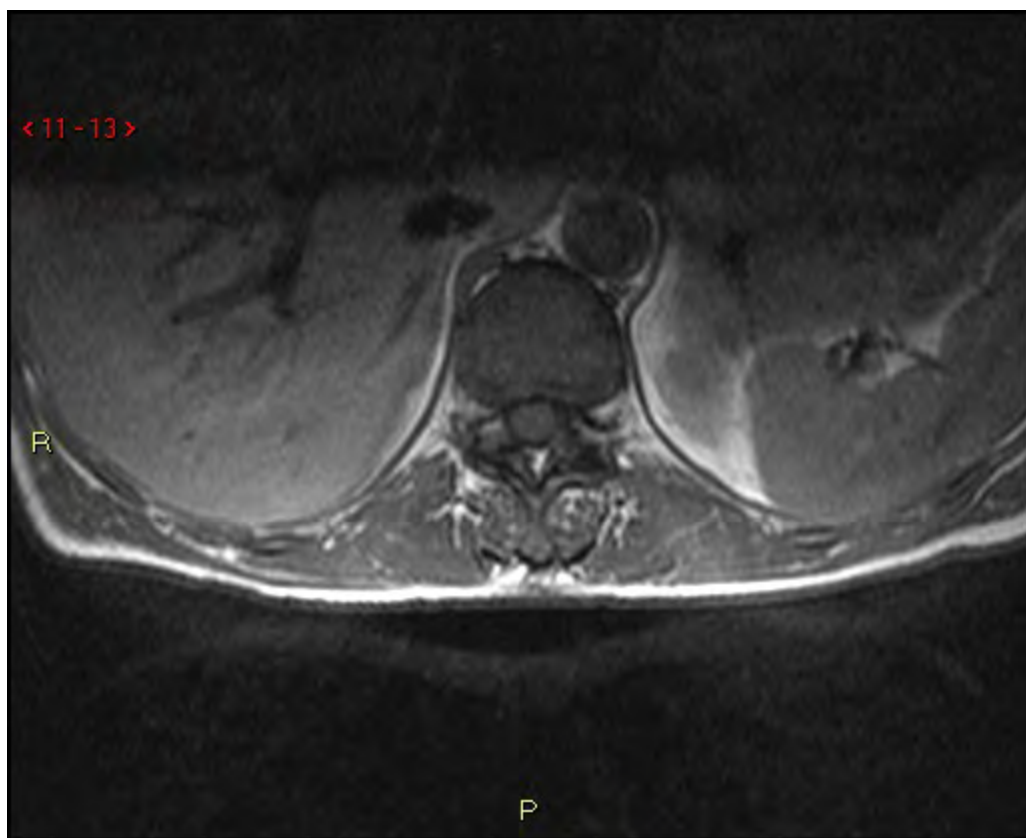


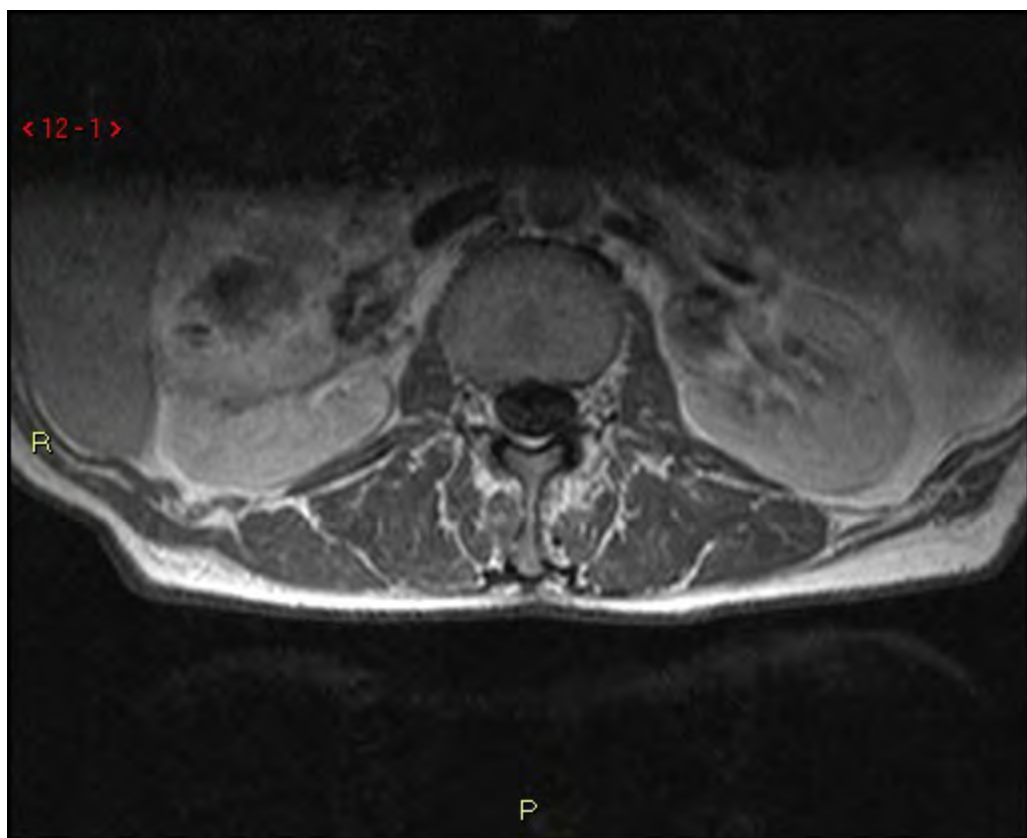


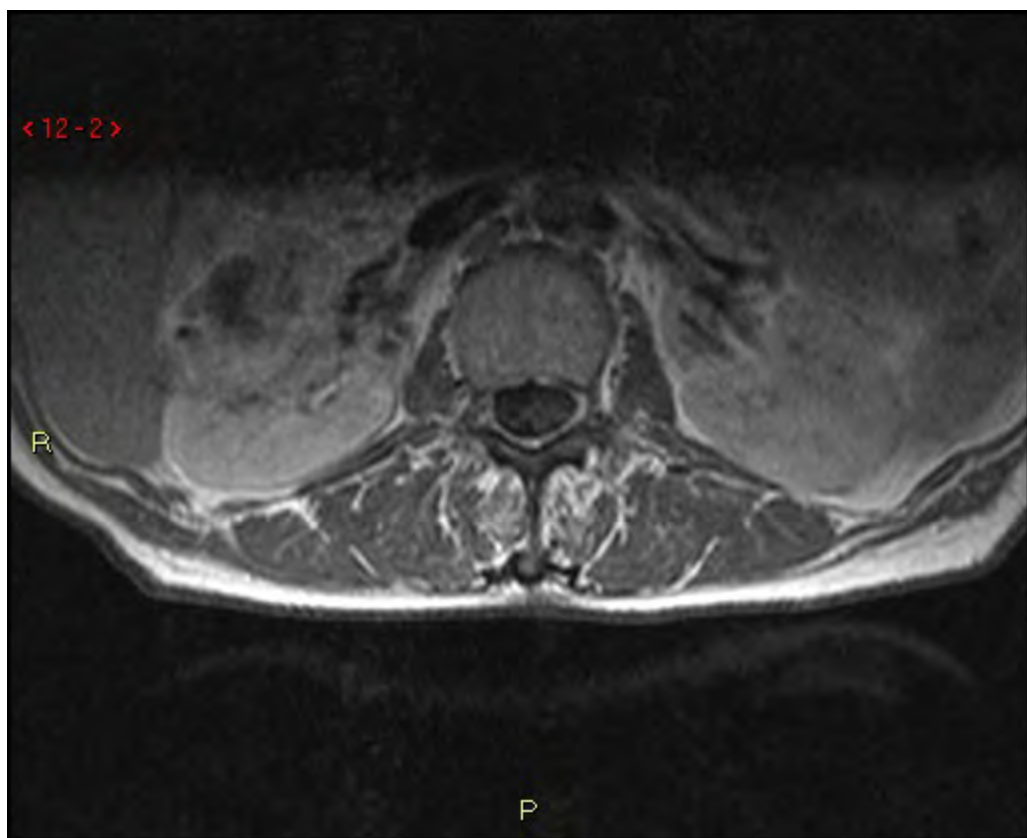


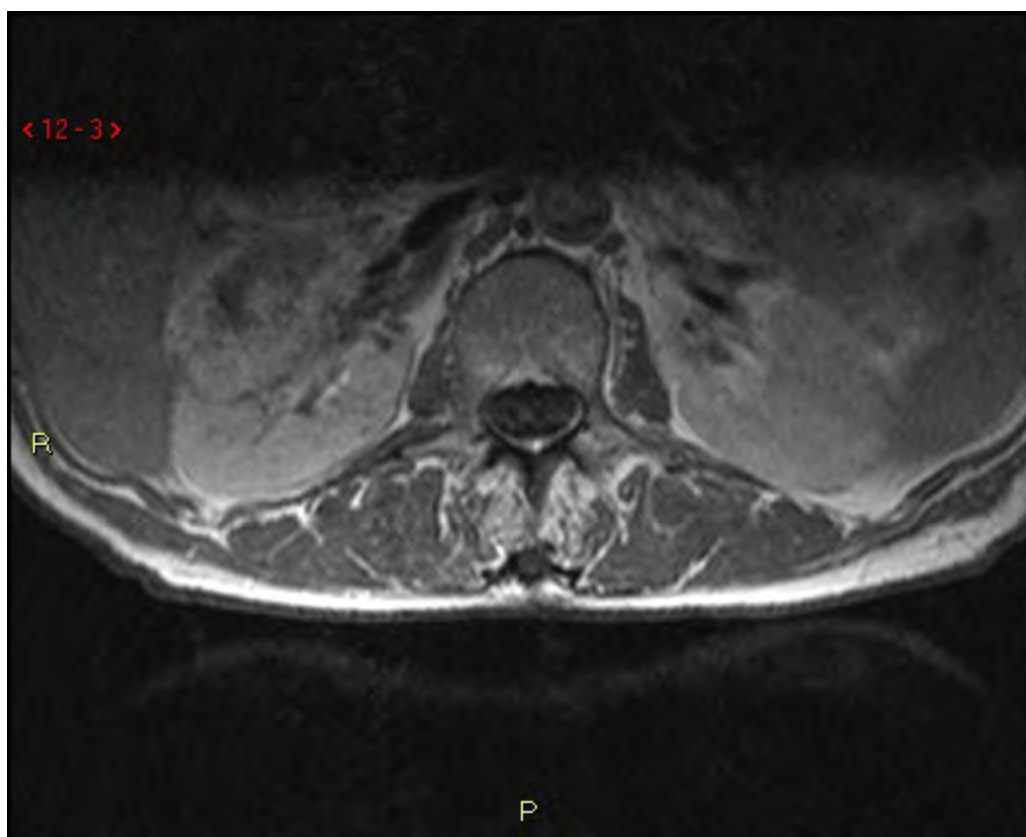


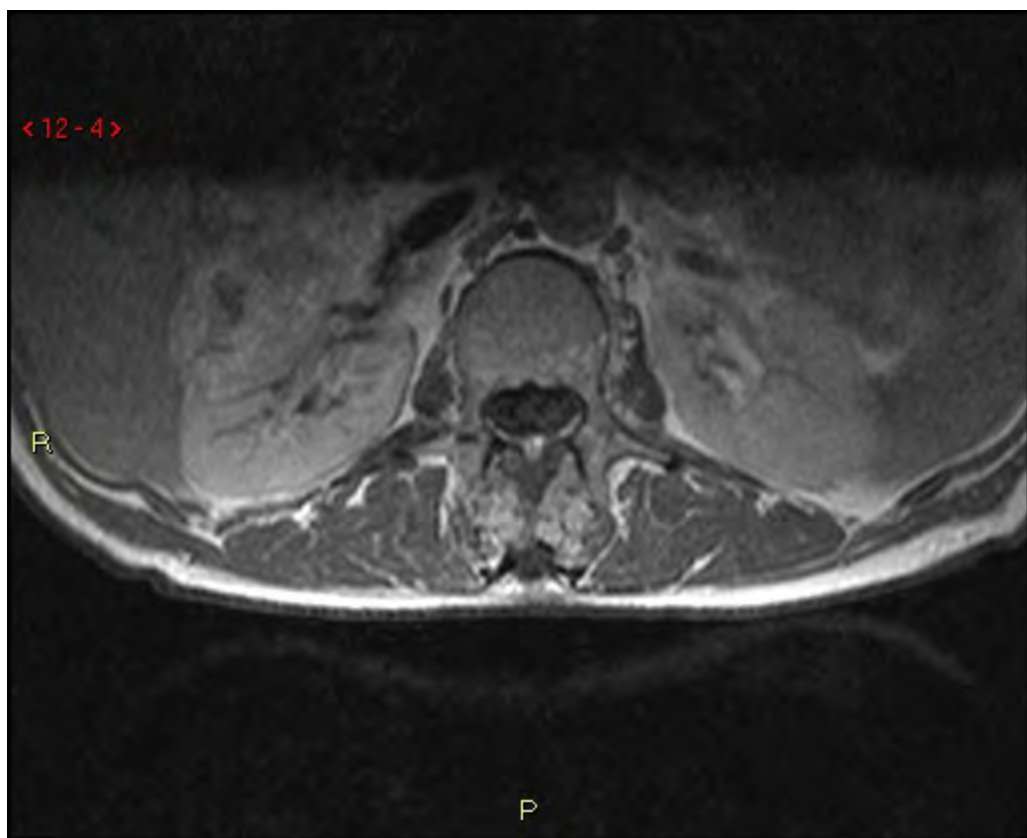


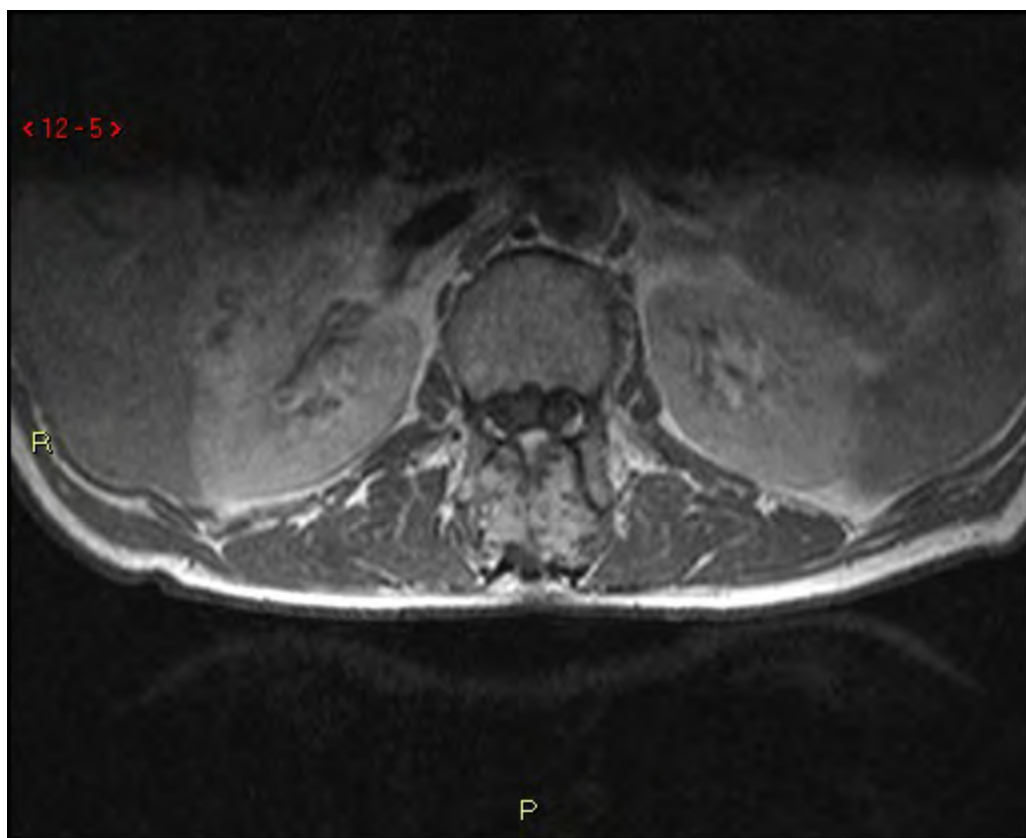


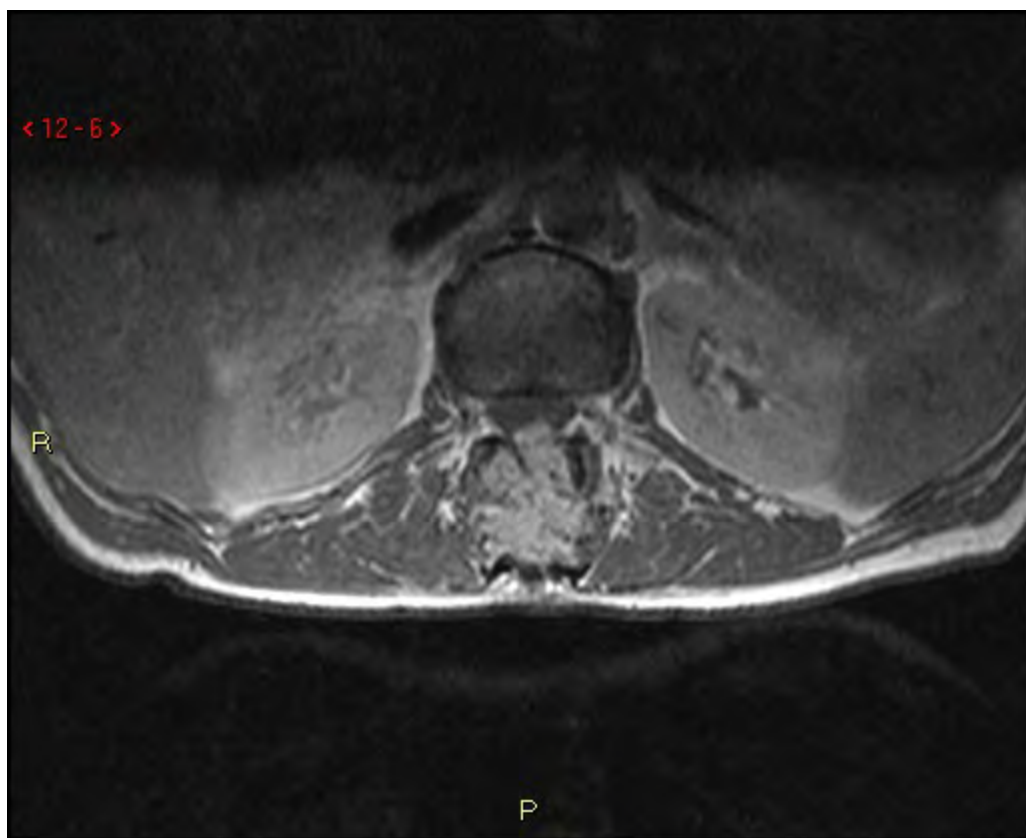


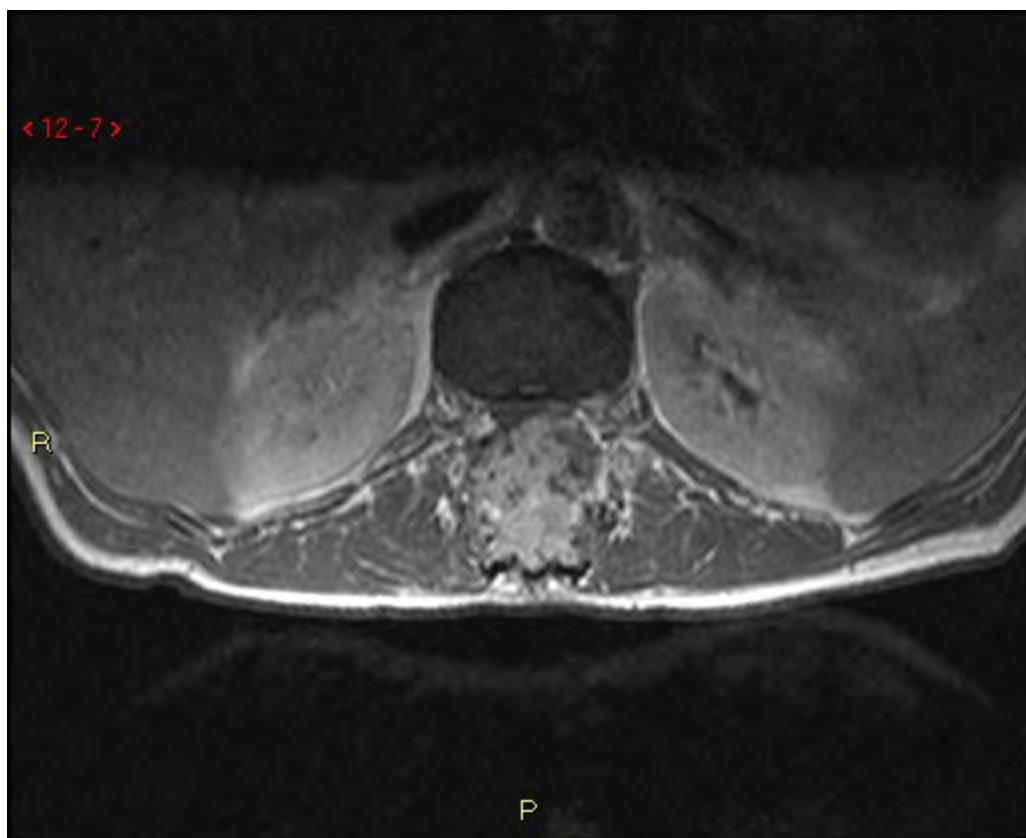


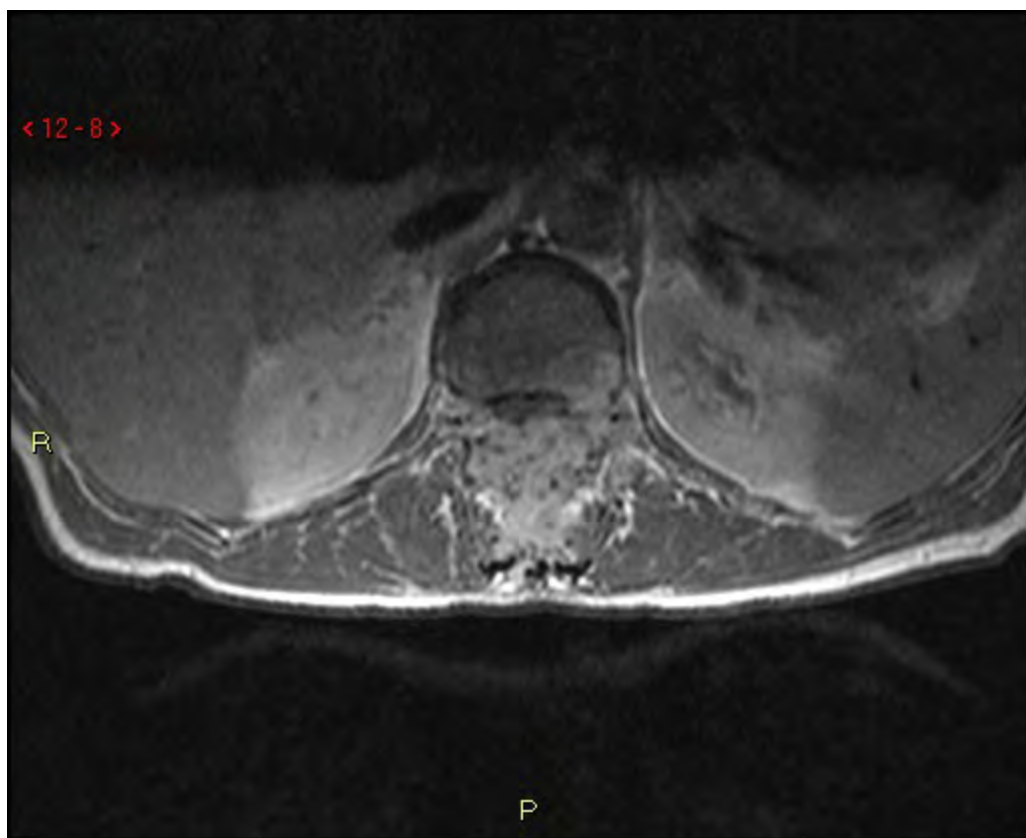


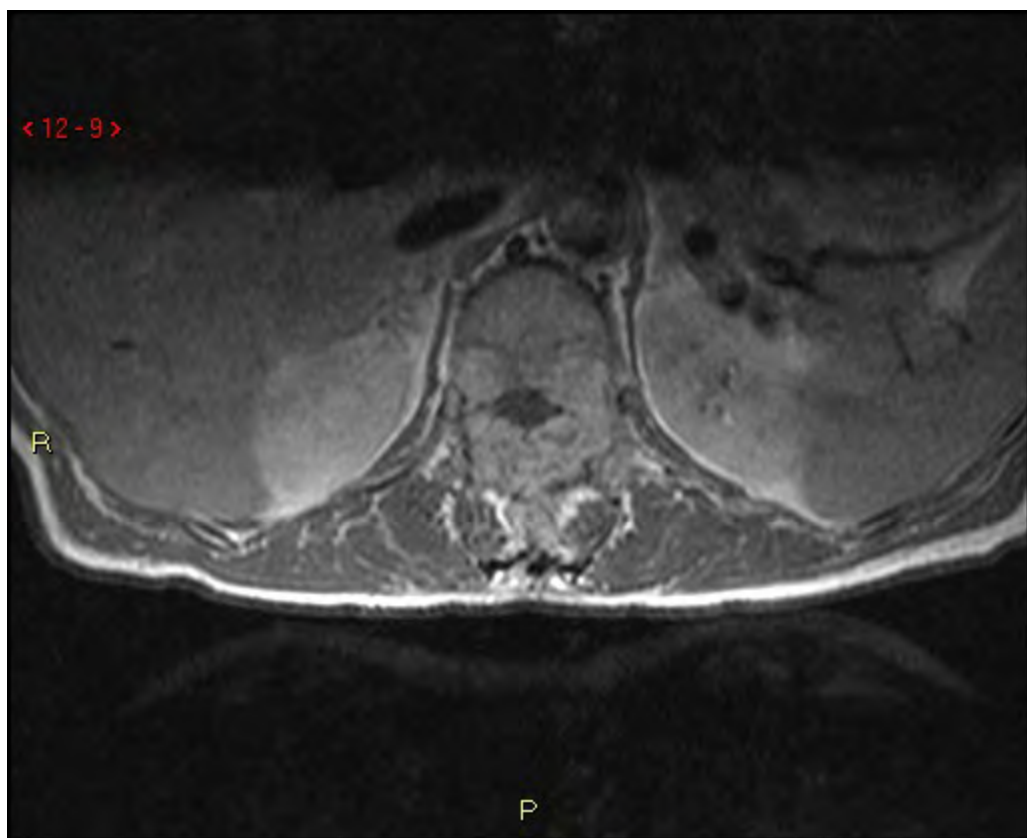


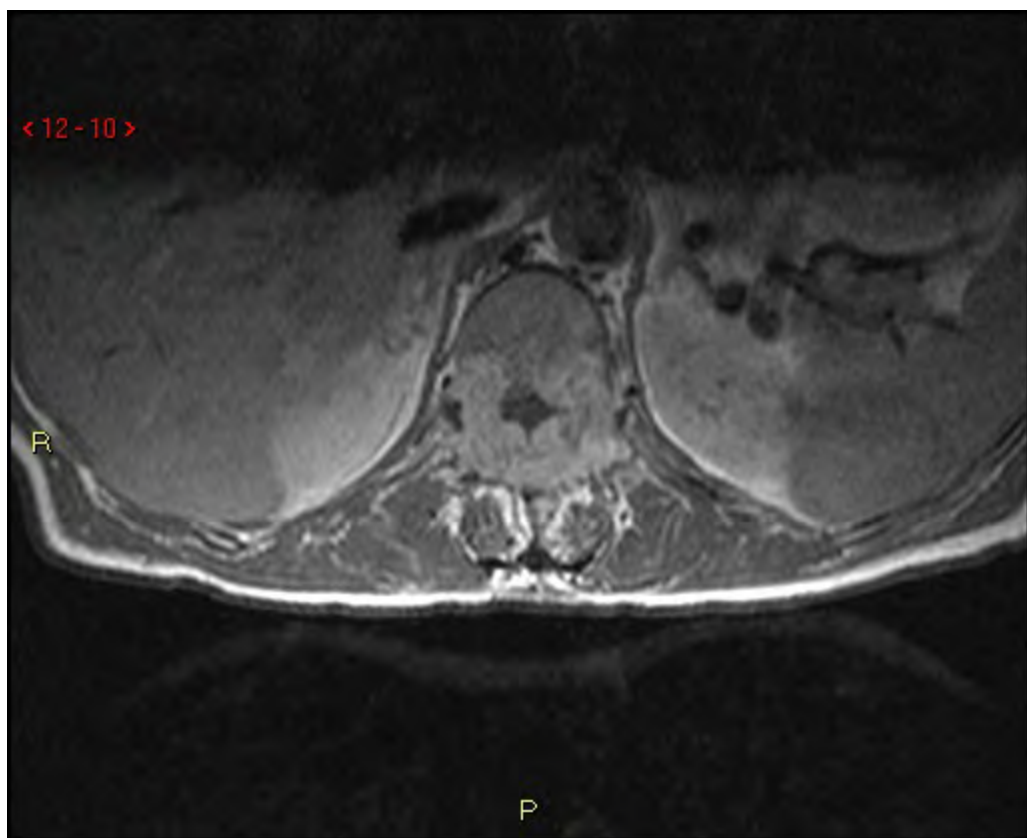


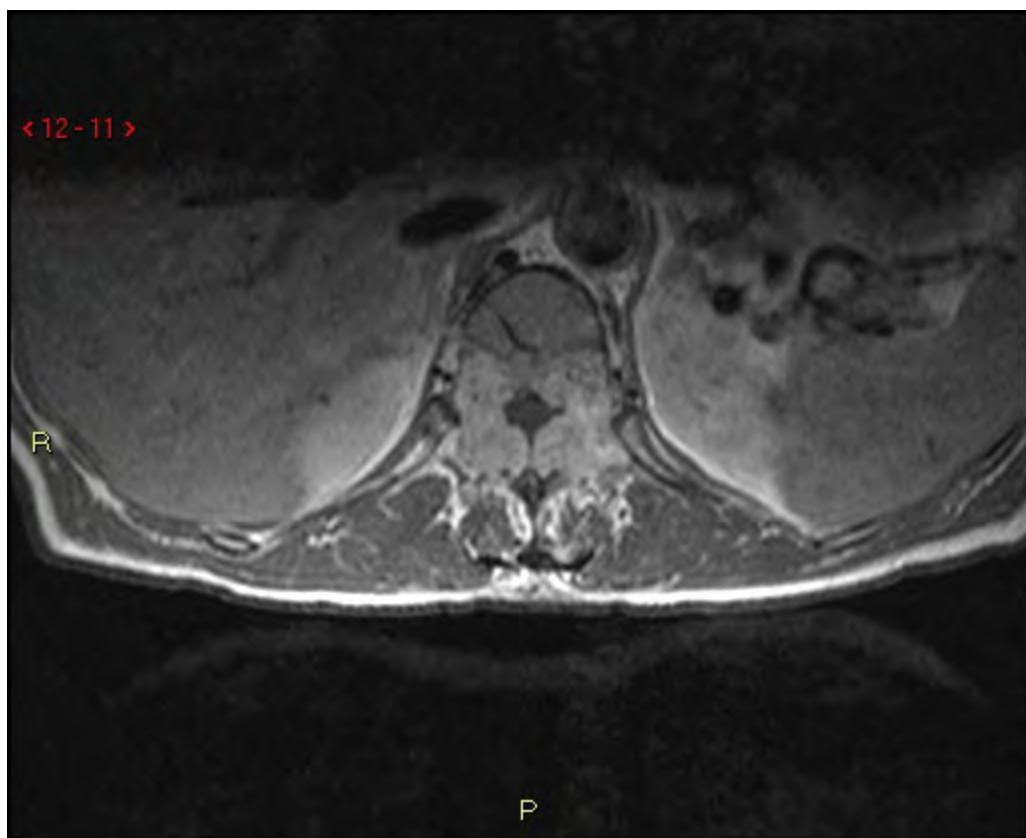


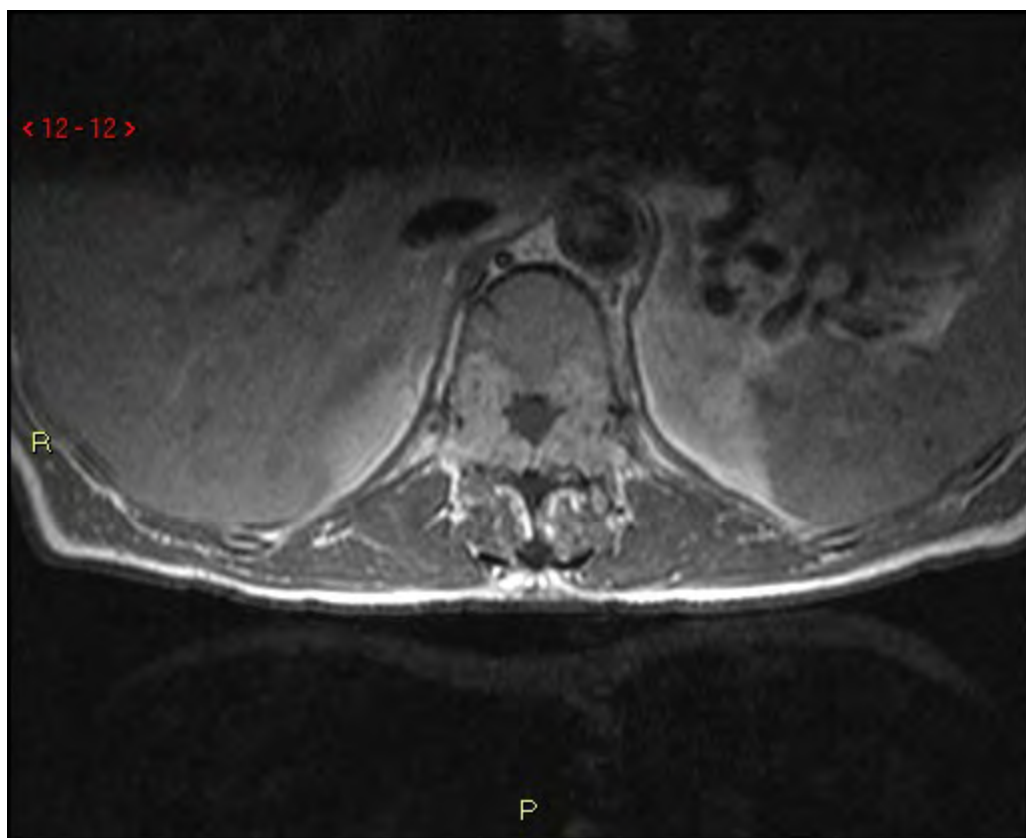


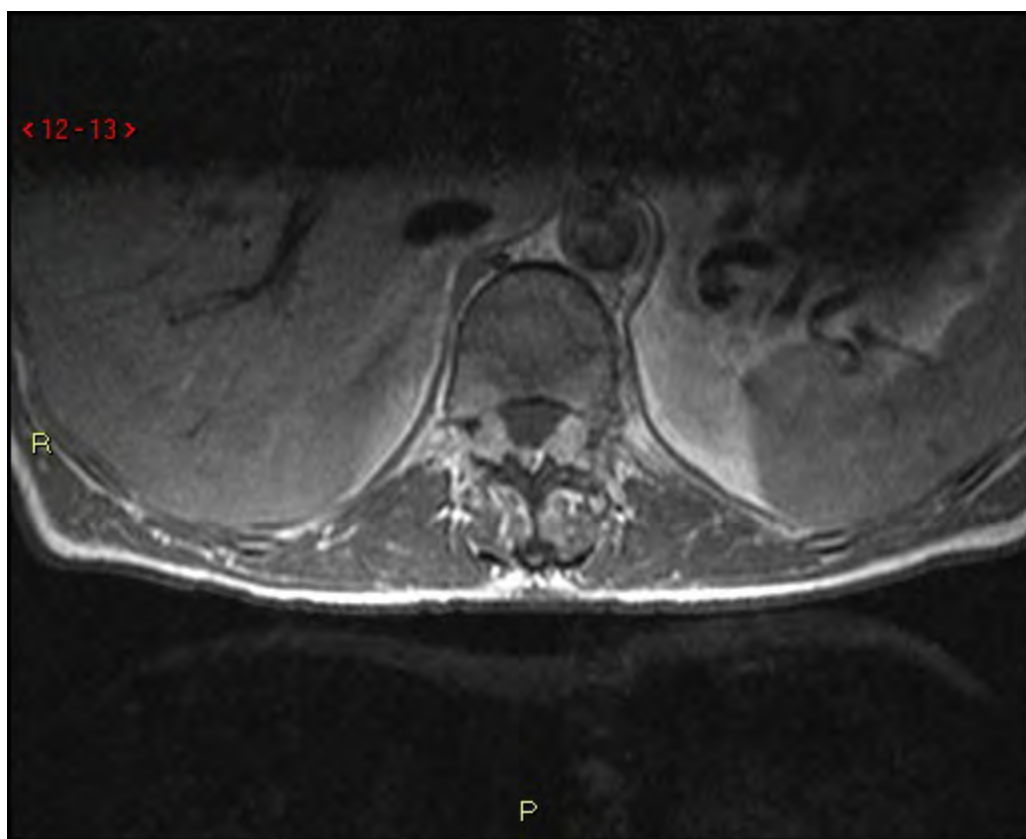


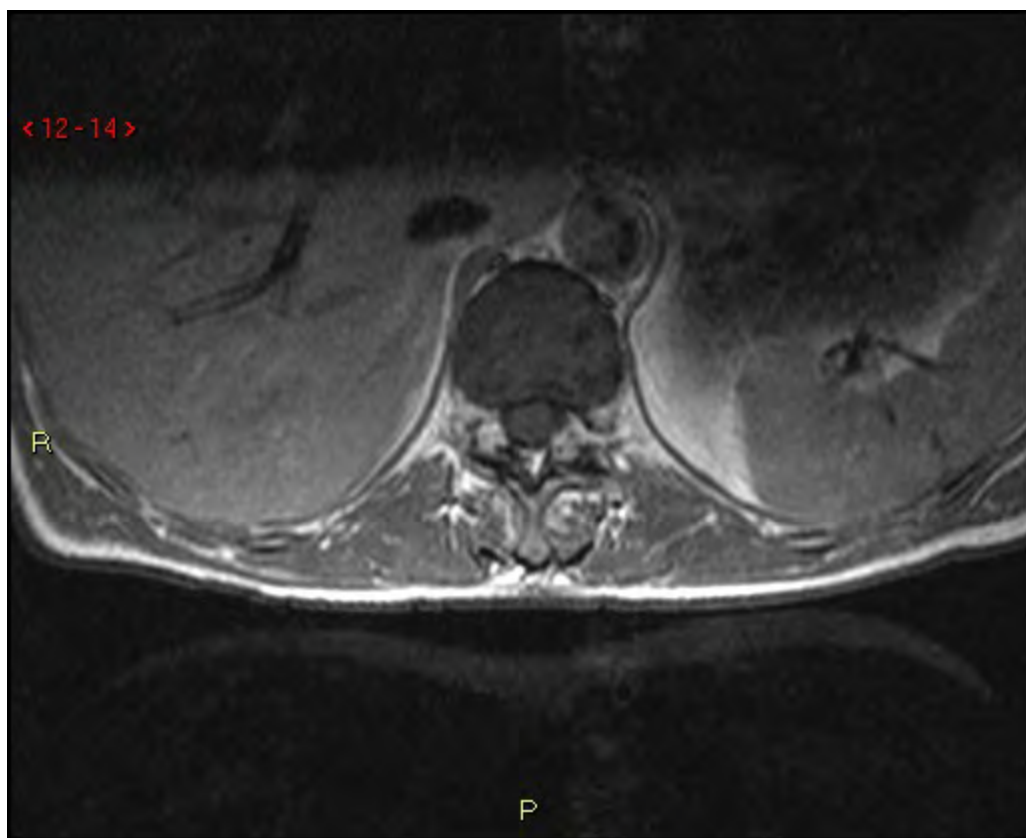


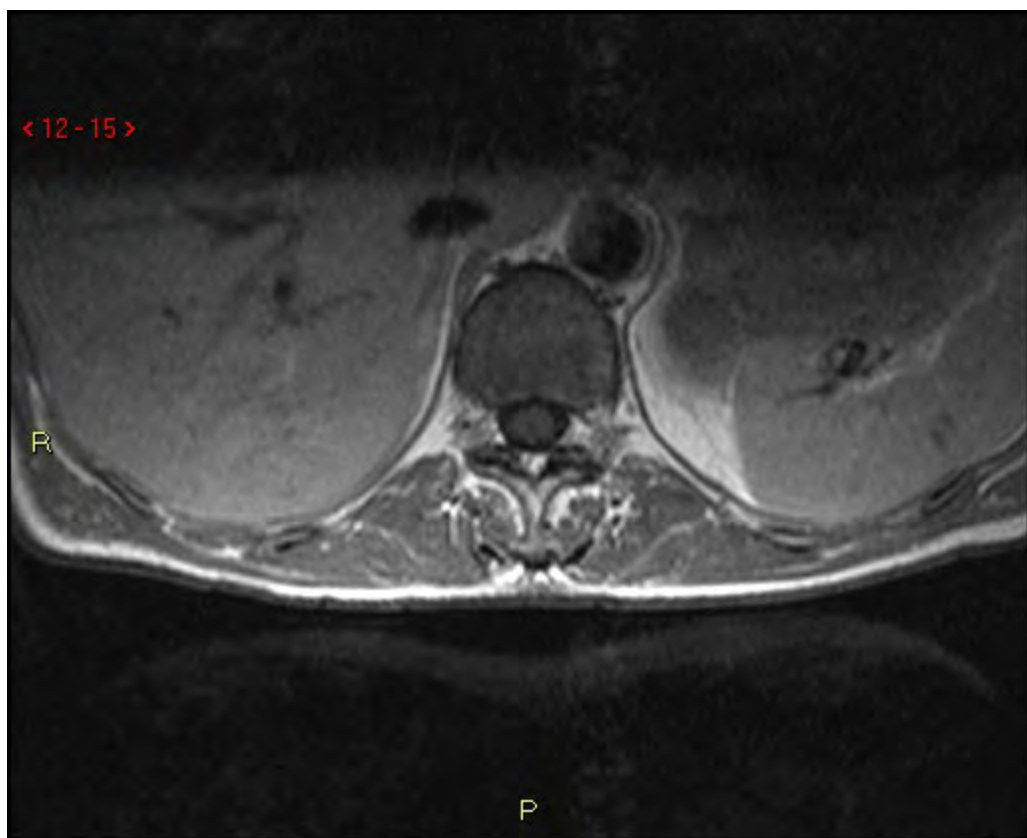








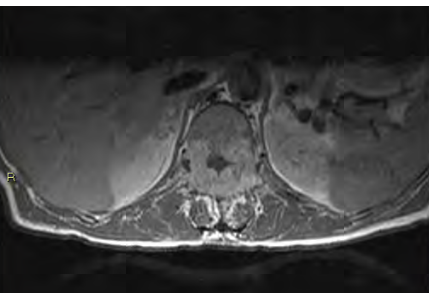
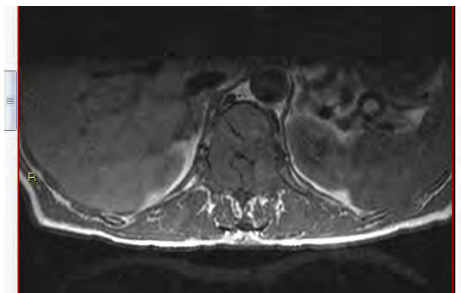




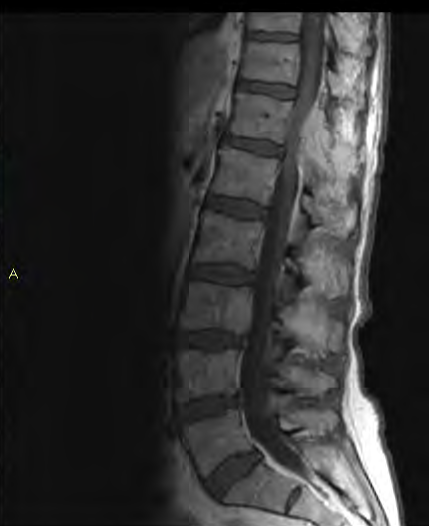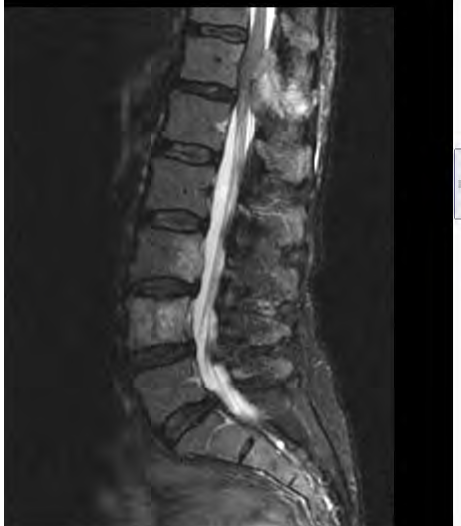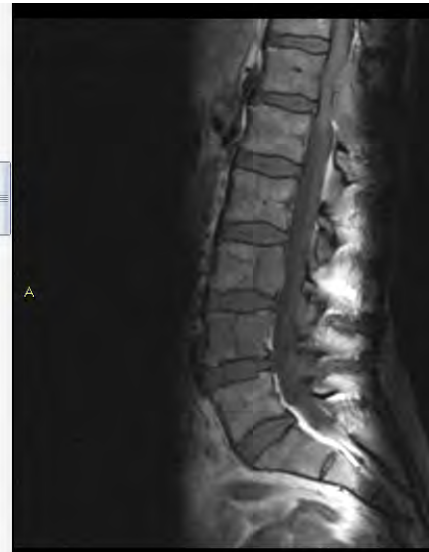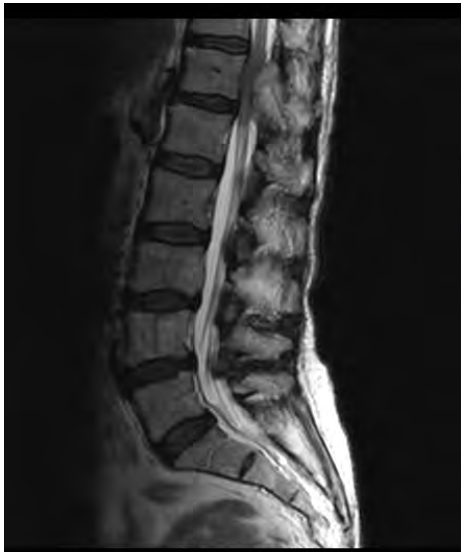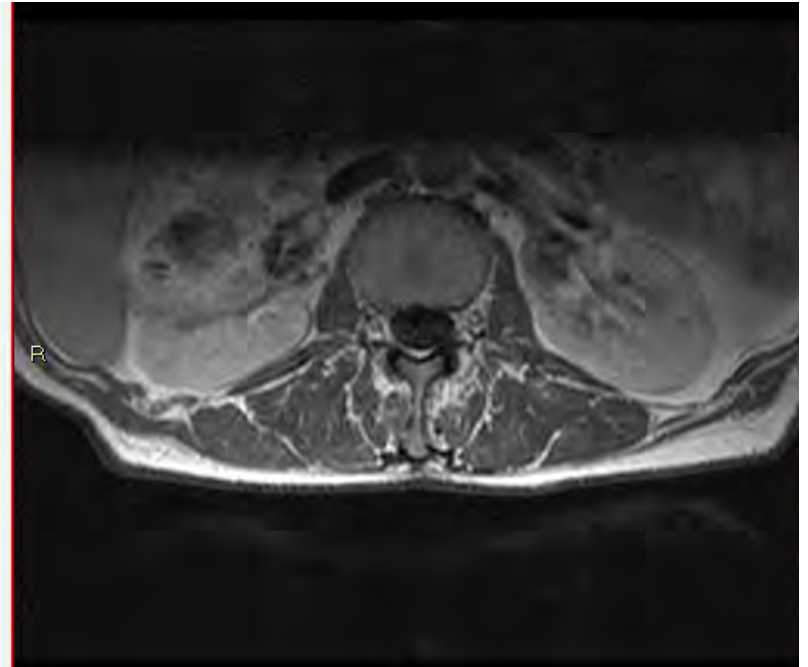
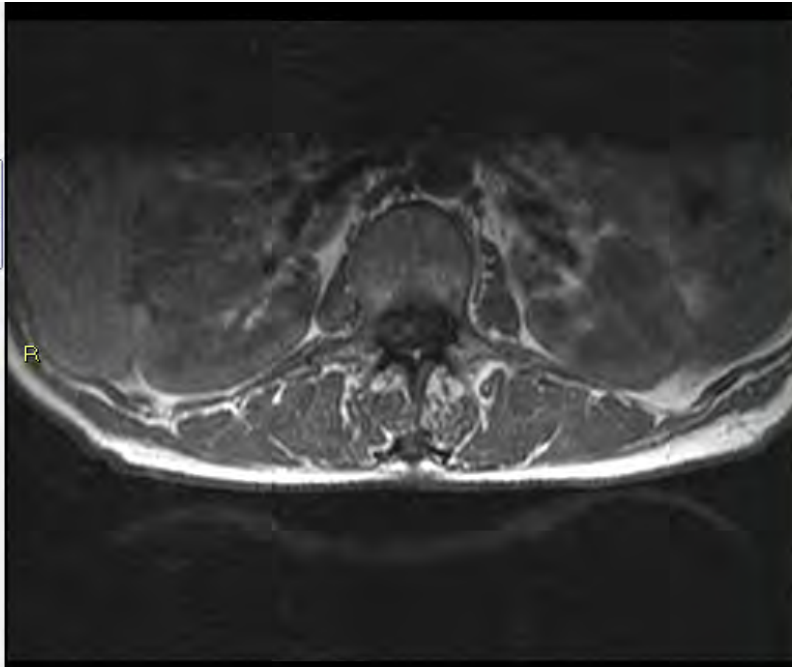
Fall 7

Fynd?

Fall 7

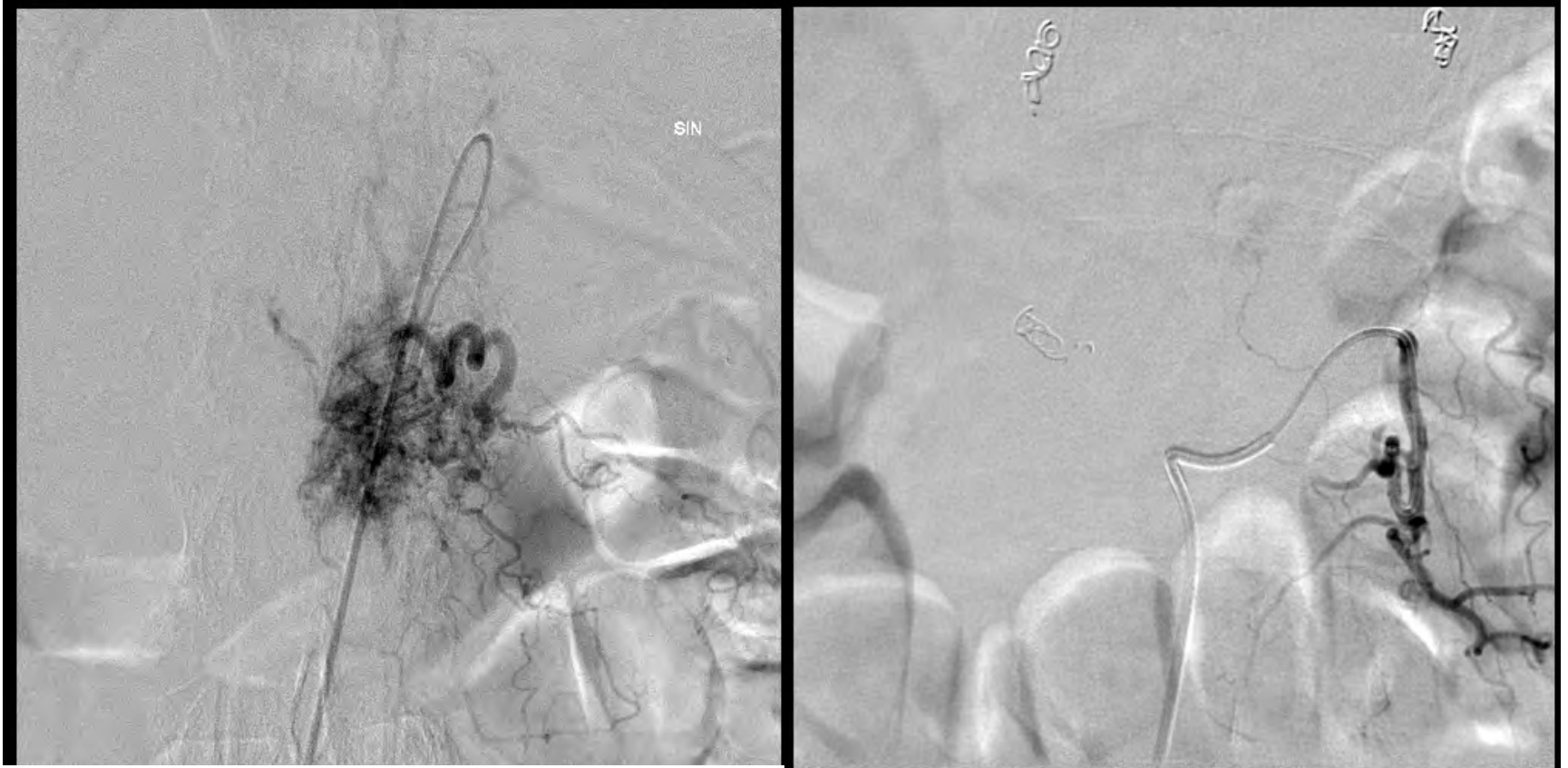


Fall 7

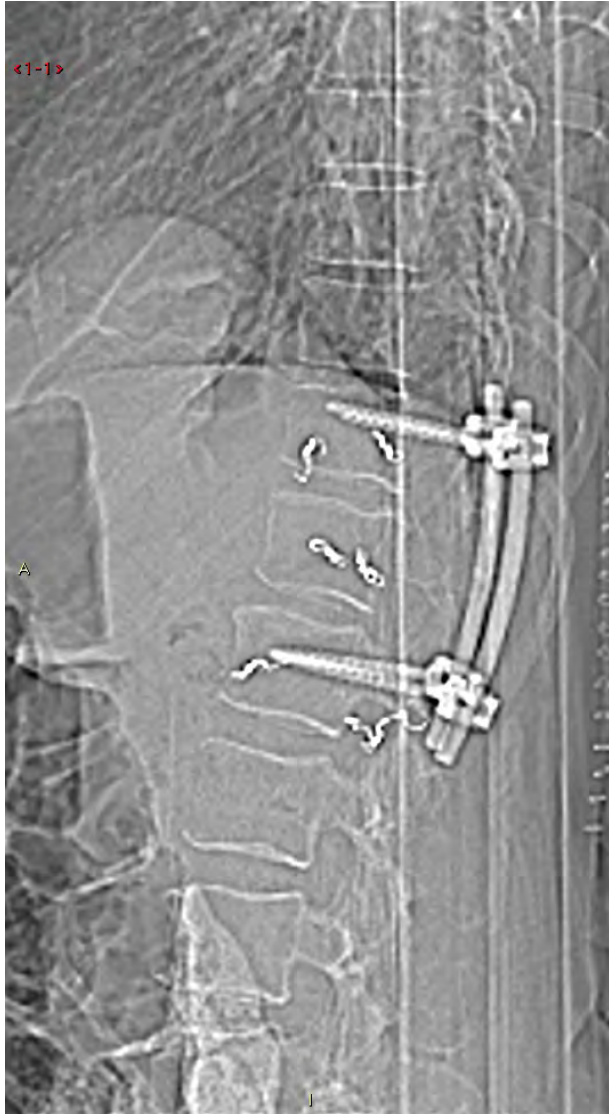

Nästa us?

Fall 7



Fall 7



Vilka diagnoser är viktiga för kirurgen att veta om pre-op?

Fall 7

Metastaser: bröst, lung, prostata, lymfom, njurcancer.

Sclerotiska : Prostata, sarkom, medullär thyreoidea cancer. MR: T1 och T2↓

Sclerotiska och Lytiska: Bröst, Lymfom, urotelialCancer. MR: T1↓ och T2↓↑

Lytiska: Lungcancer, G-I cancer, renalcellsCa, malignant melanom, myelom. MR: T1 blandad, T2 blandad