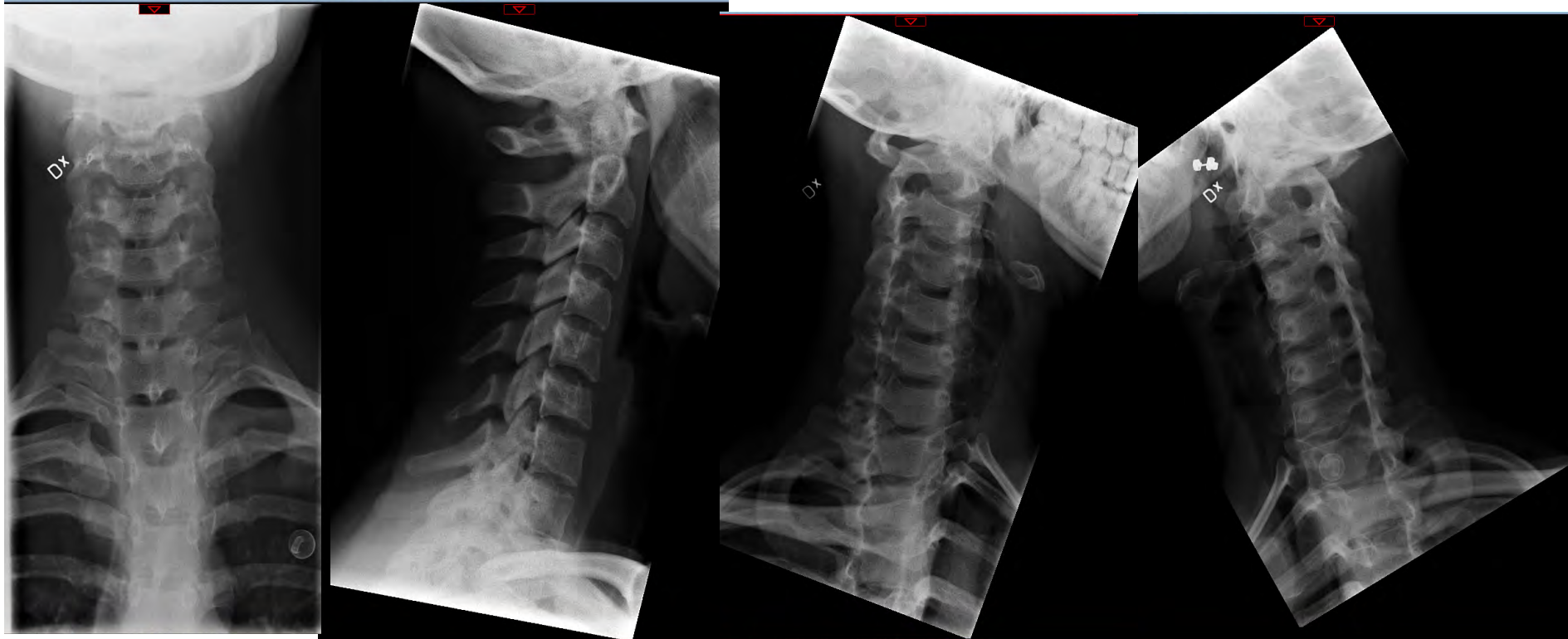

Fall 10

# Fall 10

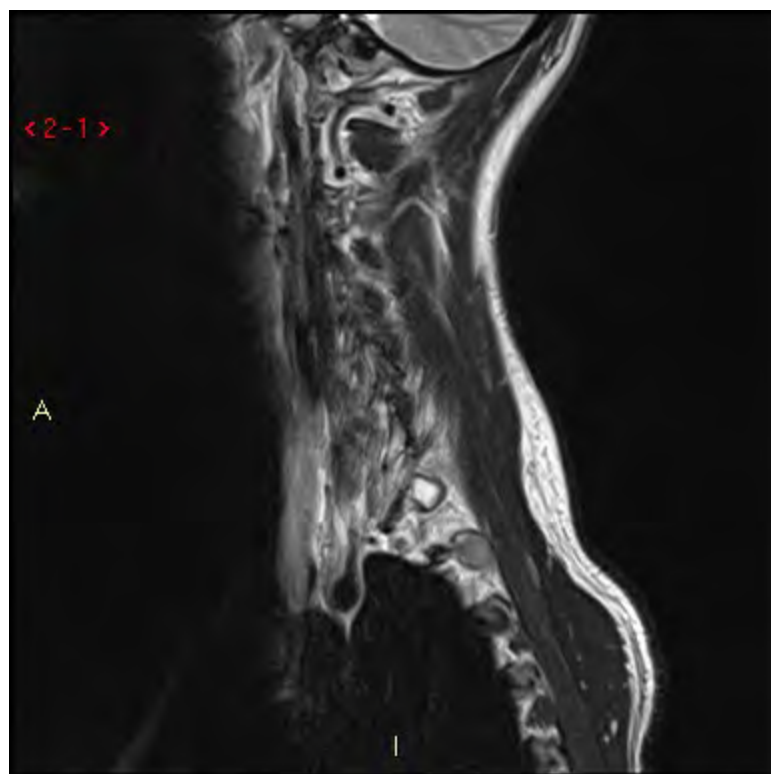
18 år K, Sedan 3-4 år ont i nacken av och till. Varit hos kiropraktiker. Känsla av låsning. Smärtutstrålning ibland till ffa höger arm. Sjukgymnastik utan effekt. Nu Röntgen.

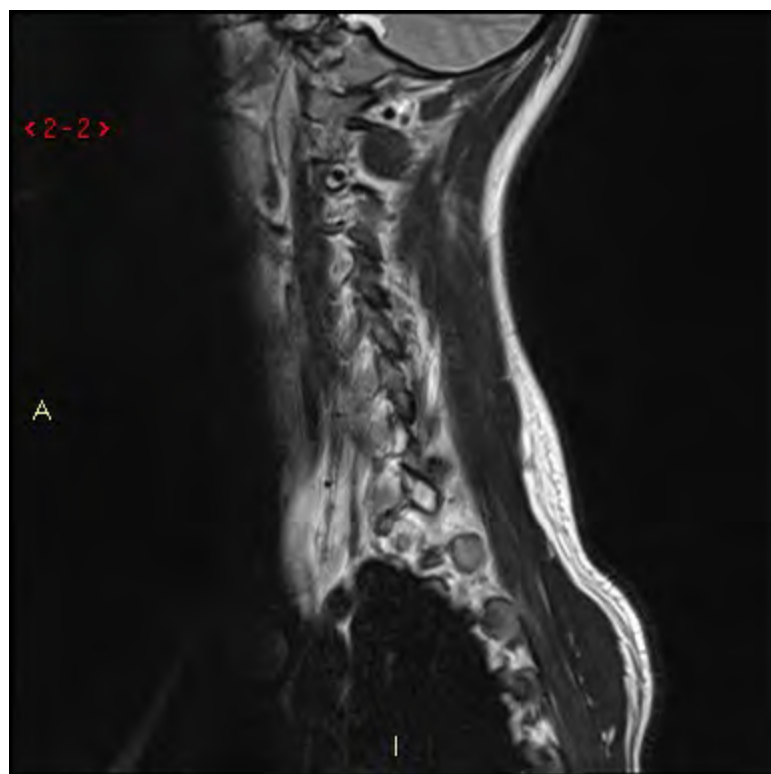
# Fall 10

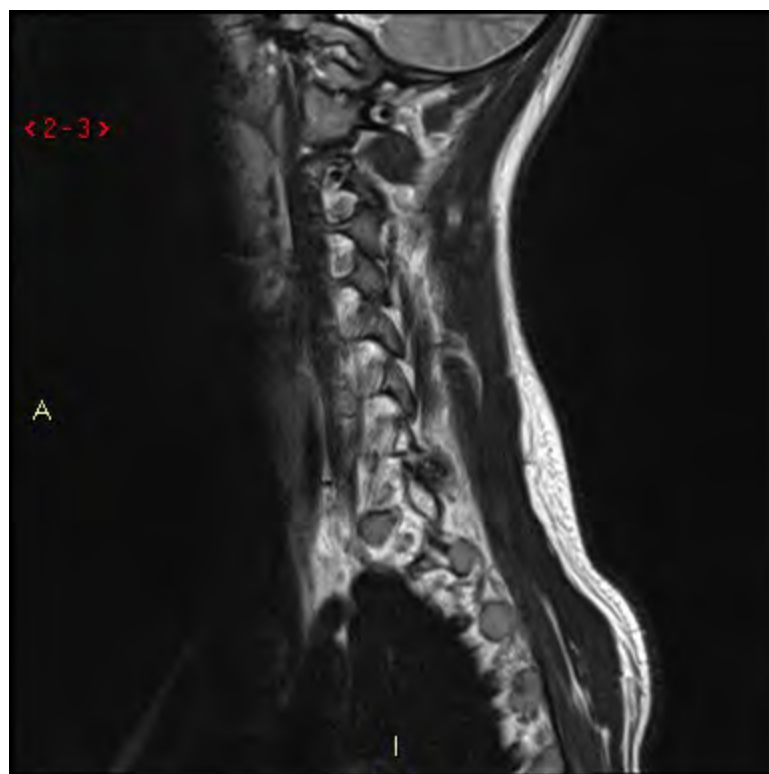

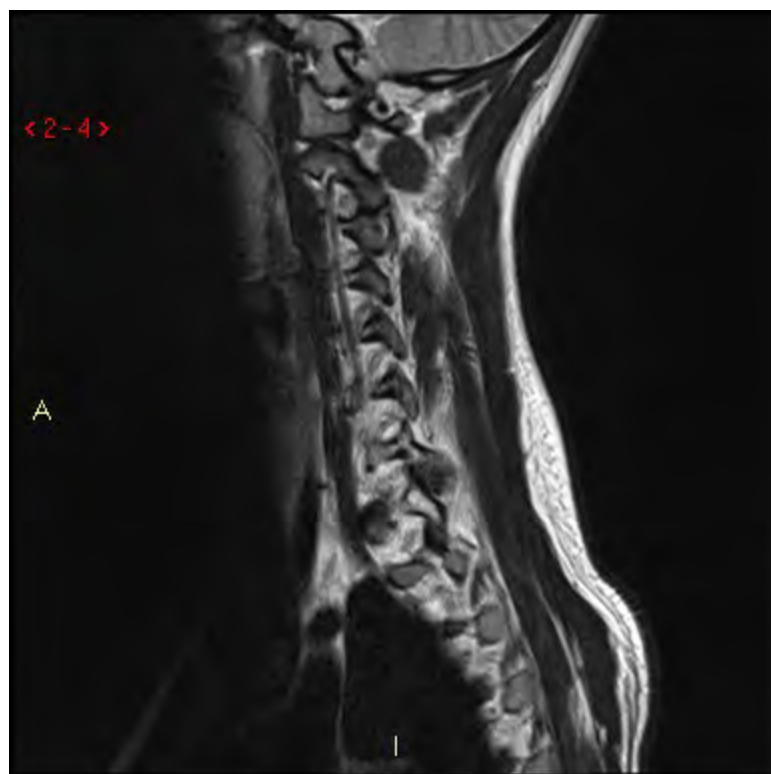# Fall 10

Inga fynd på rtg. Ingen åtgärd.  
Åter Efter 3 månader, nu med MRT  
remiss!

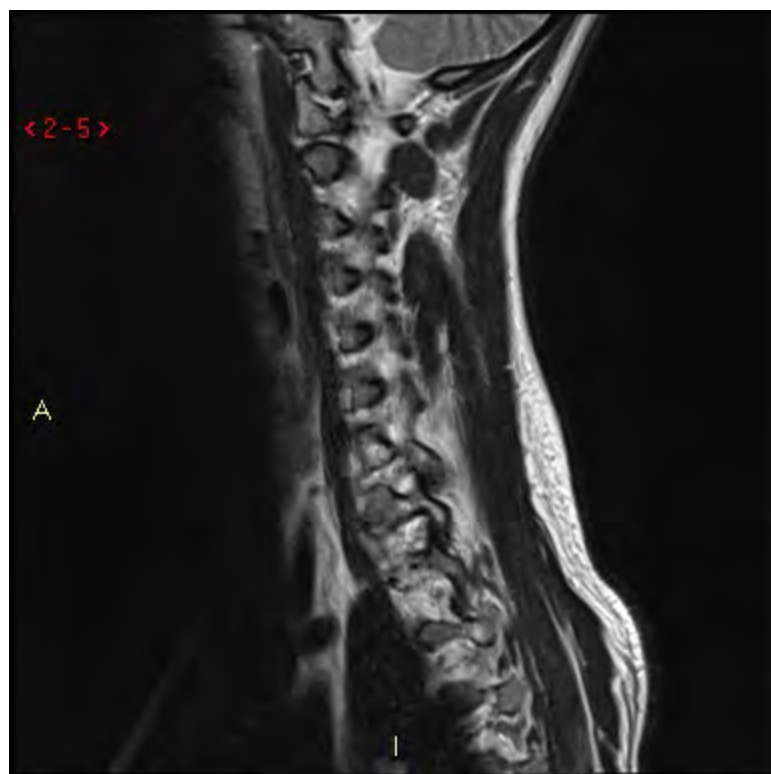


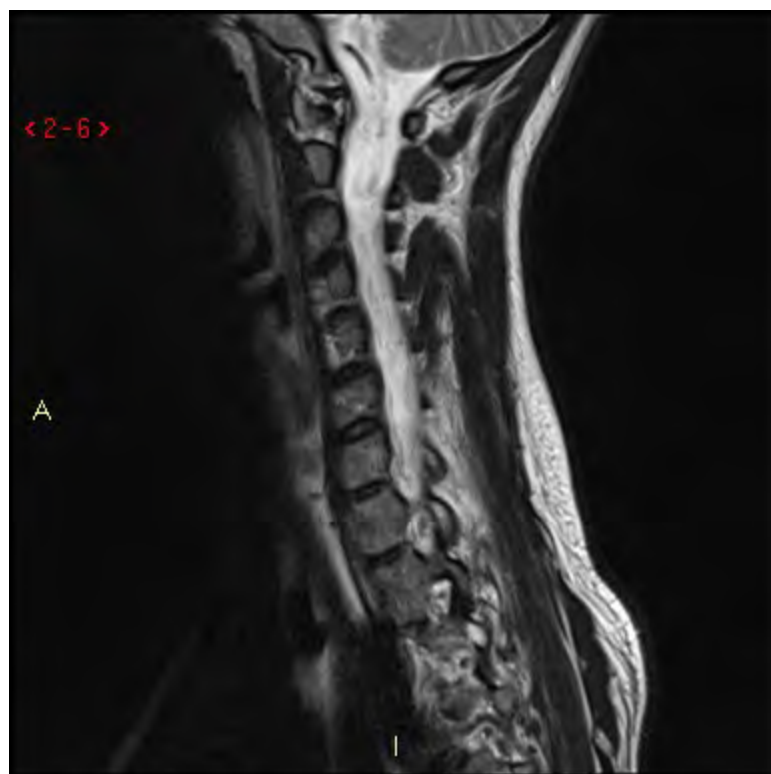


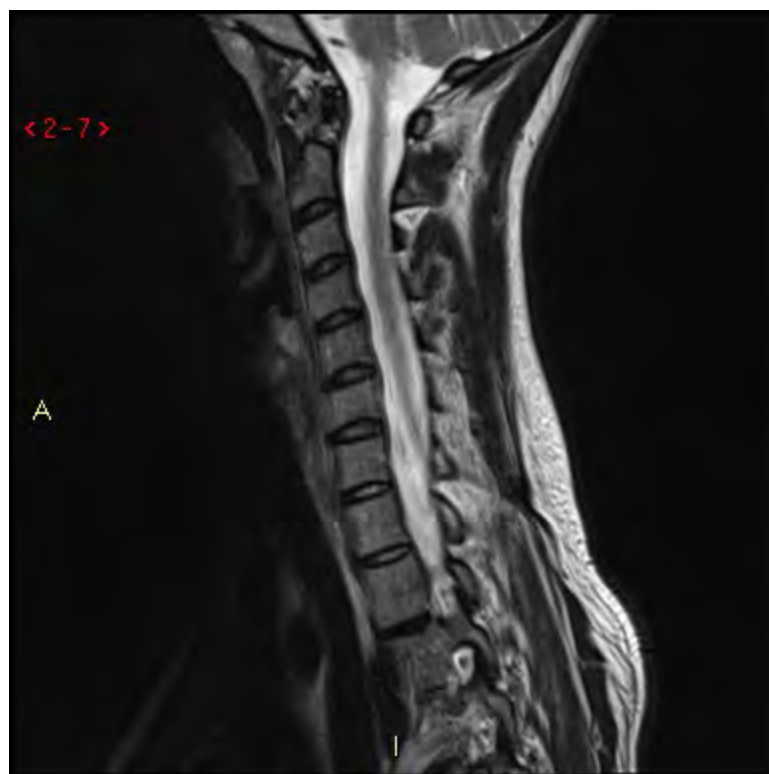


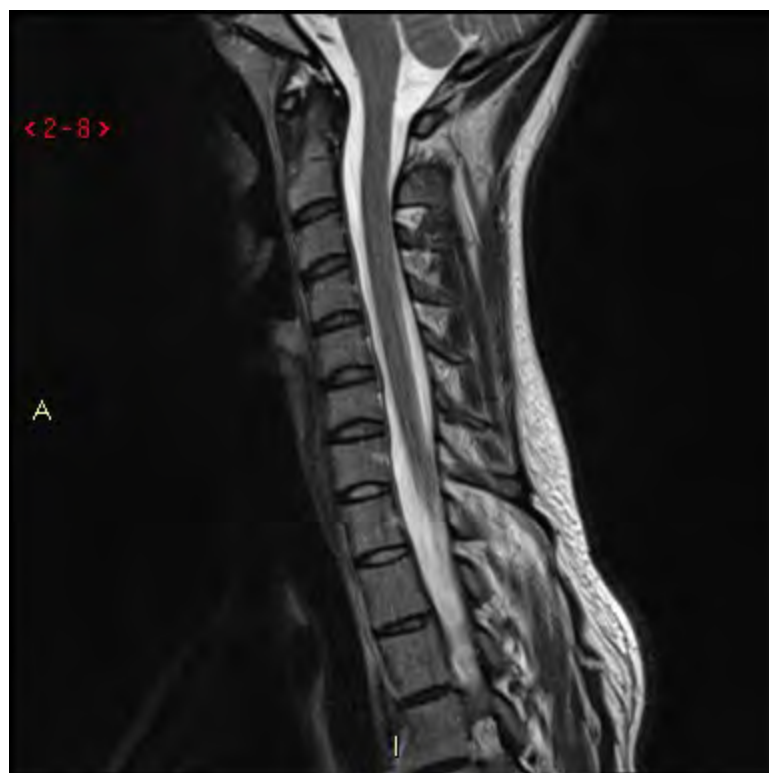


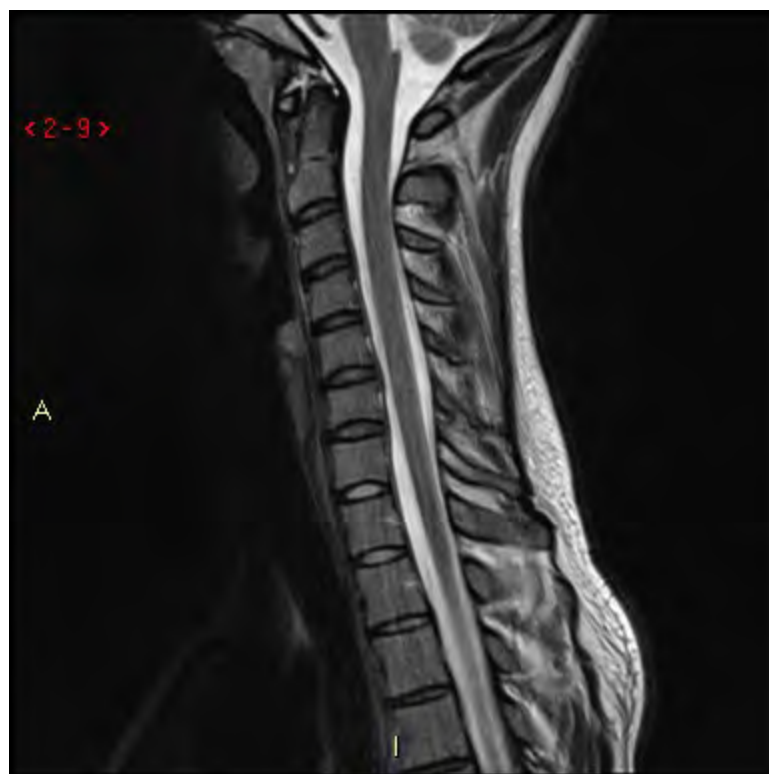


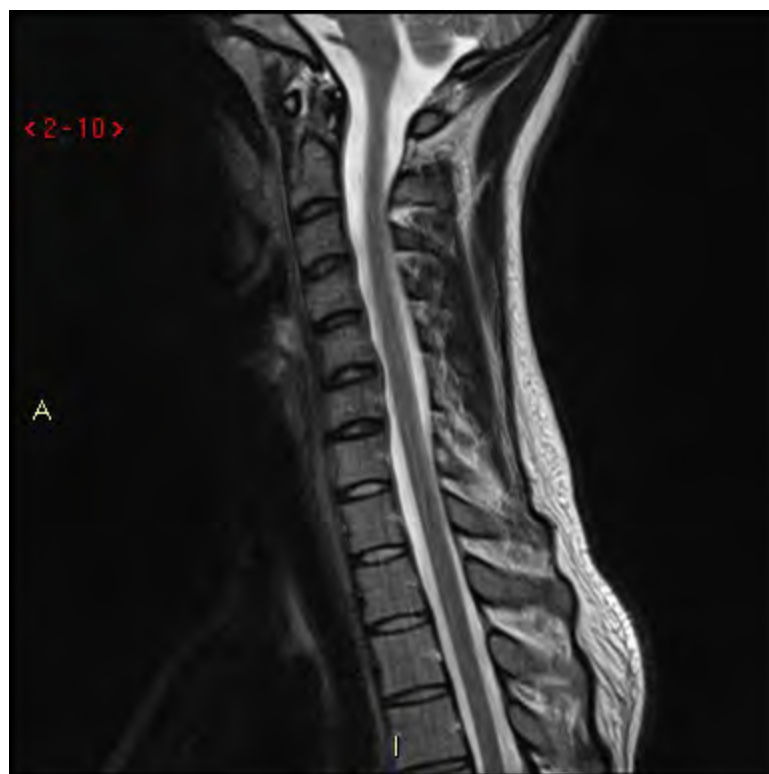


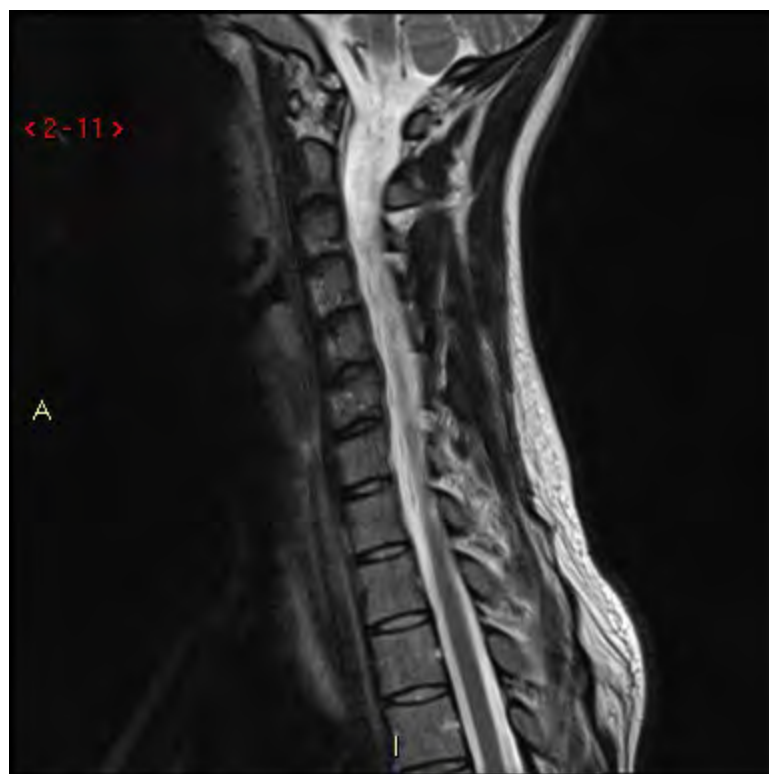


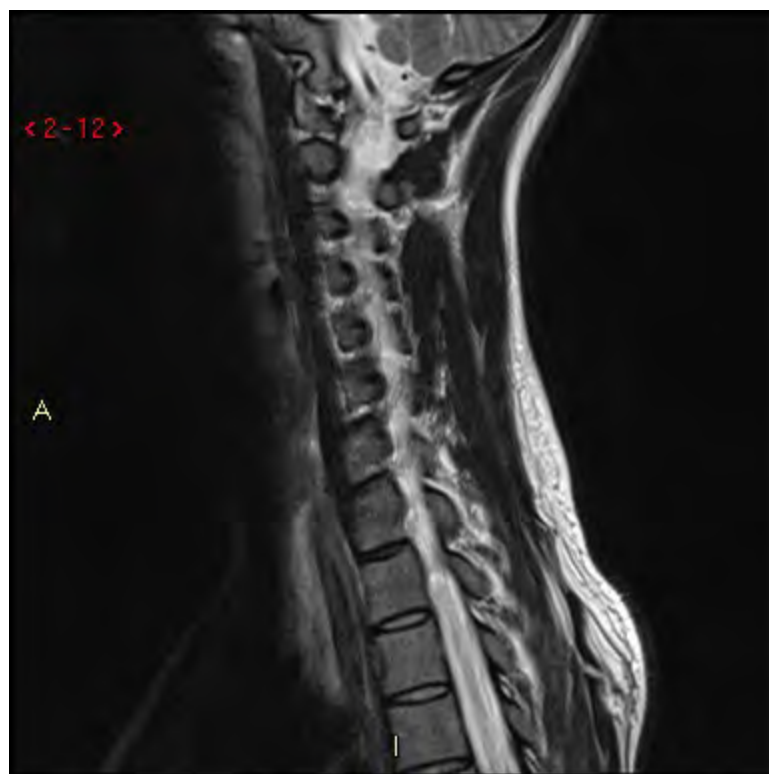




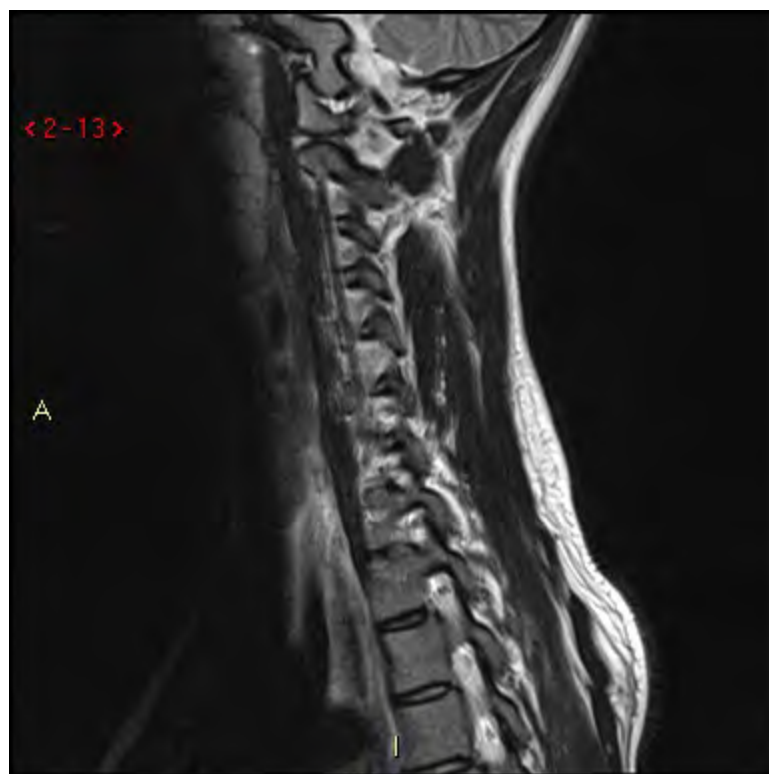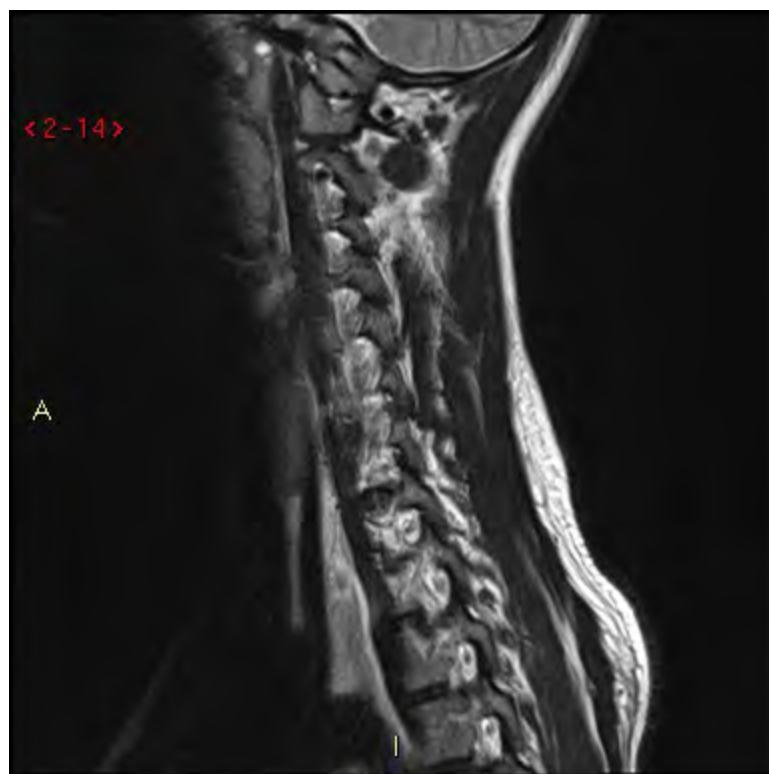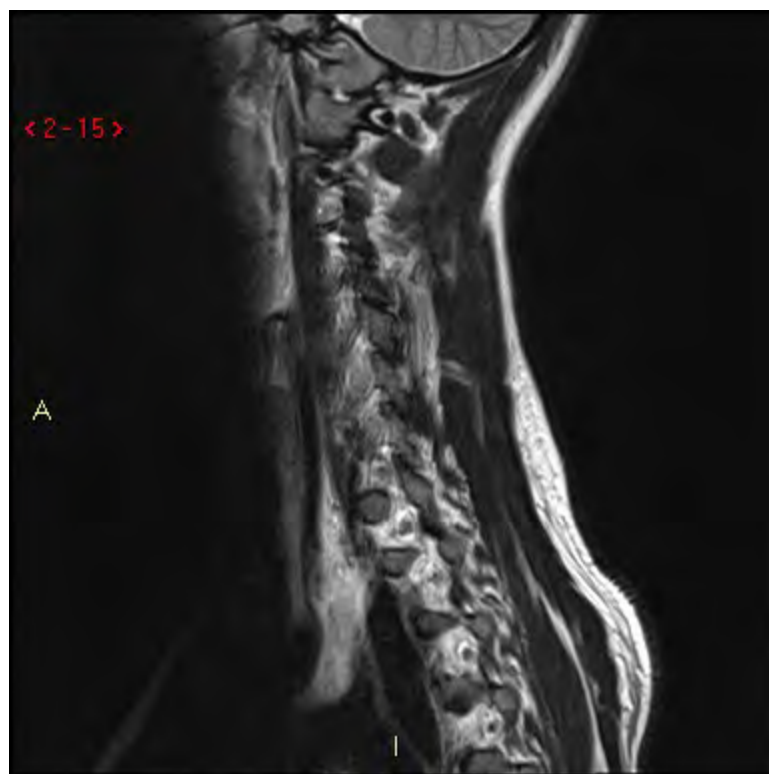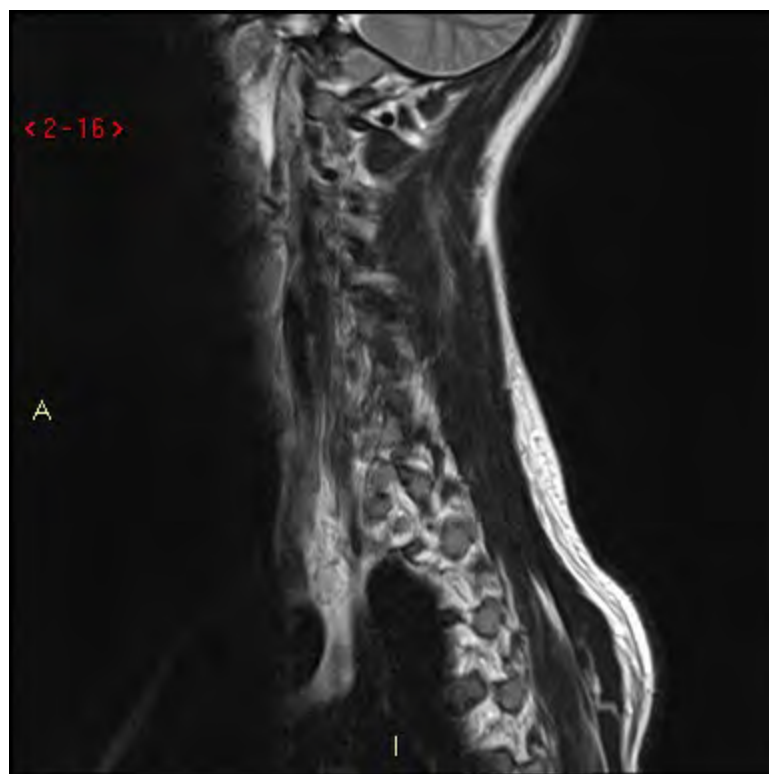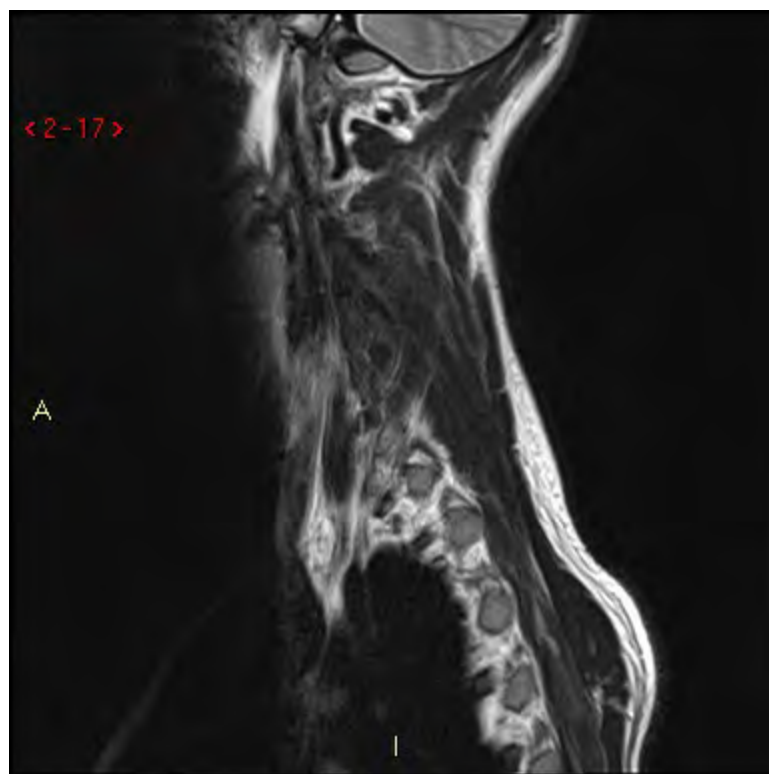


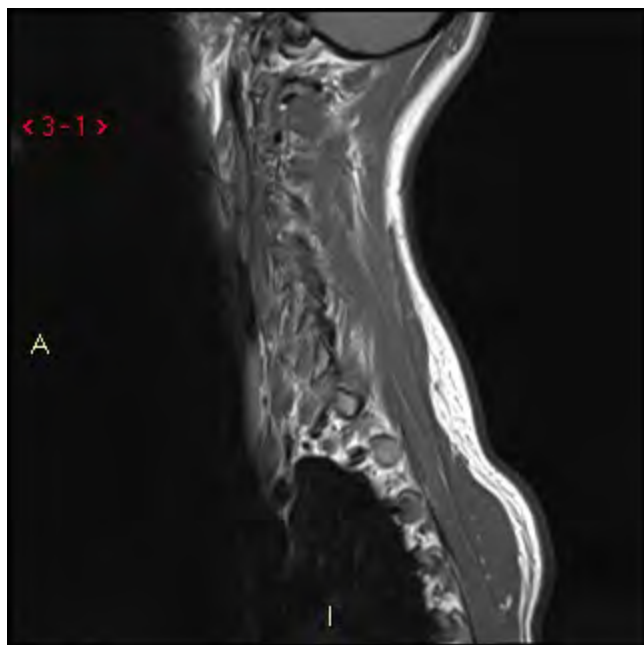


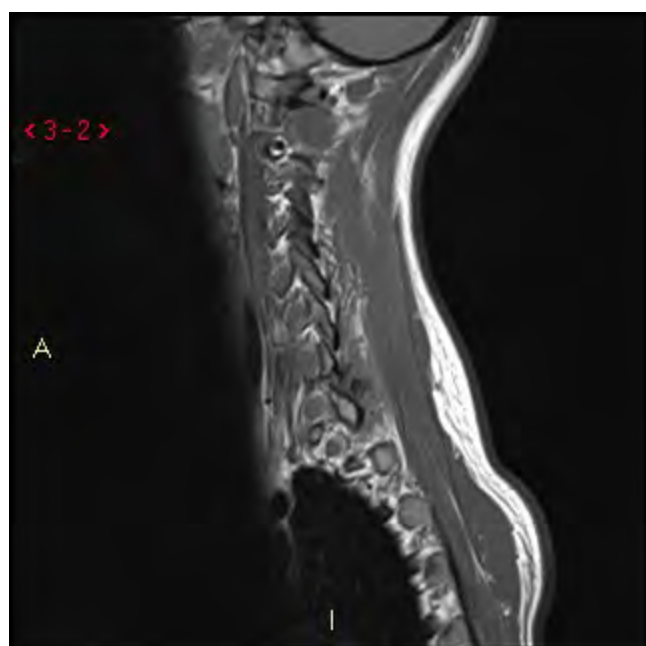


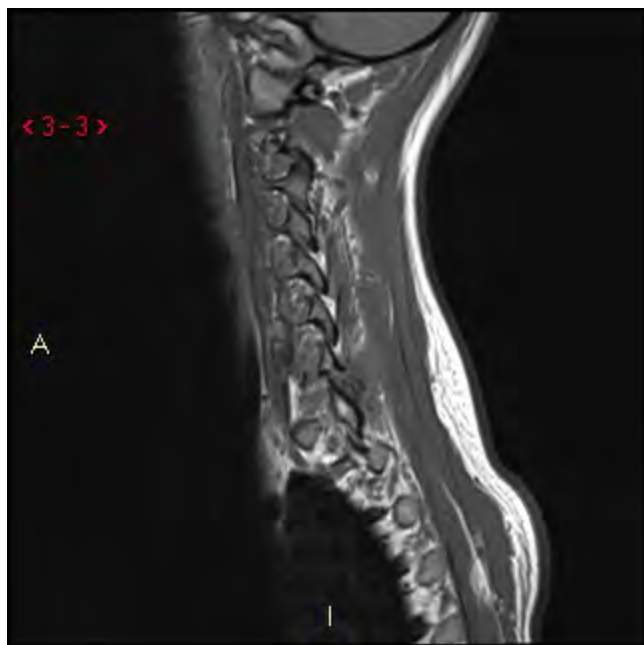




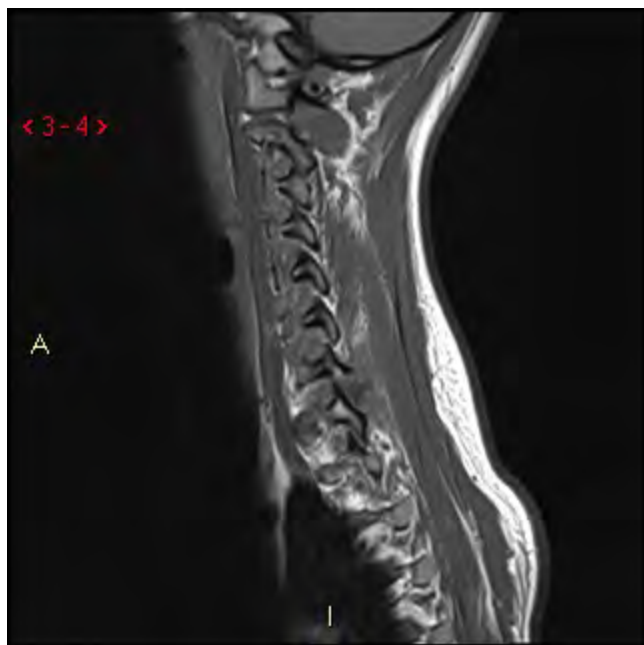


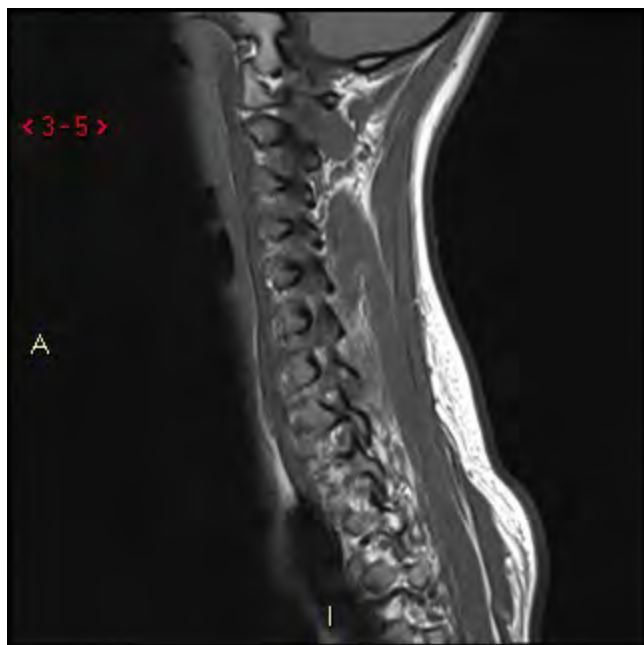














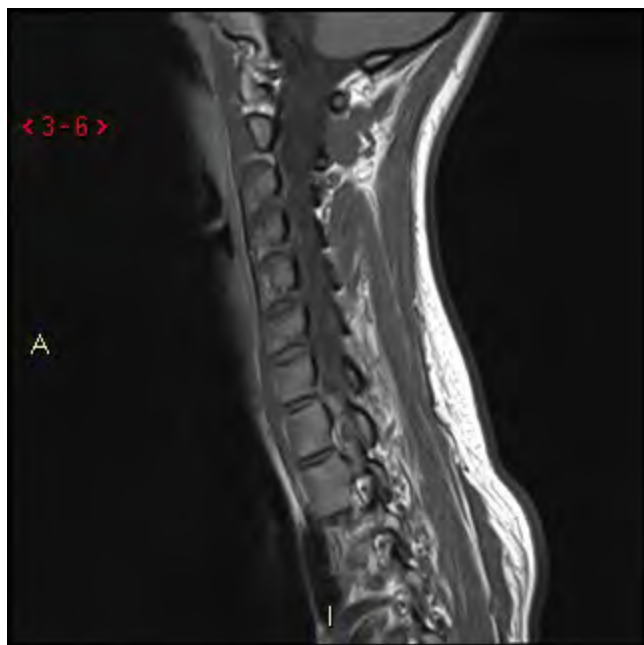


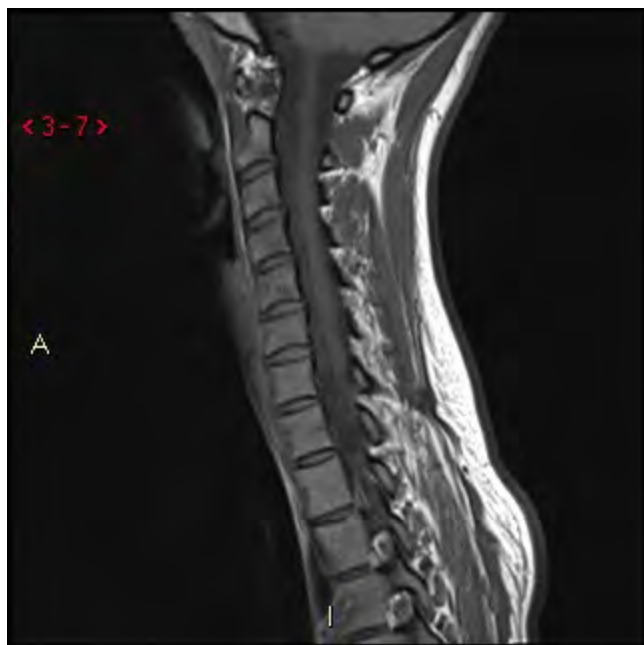


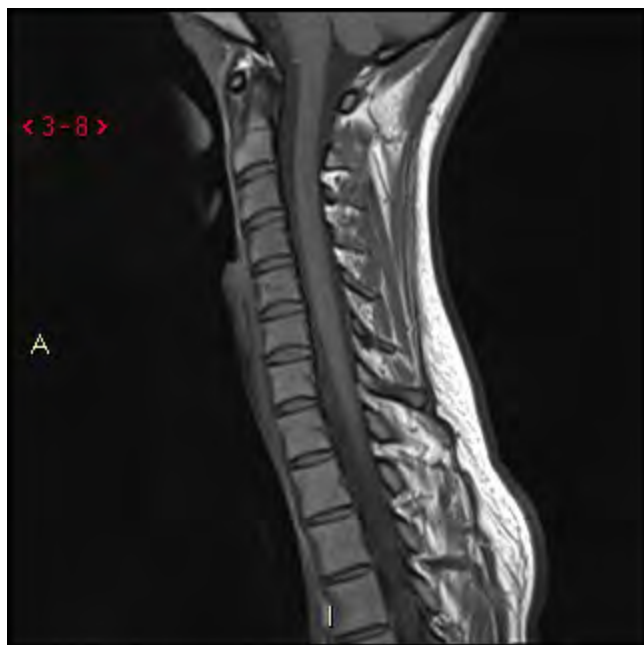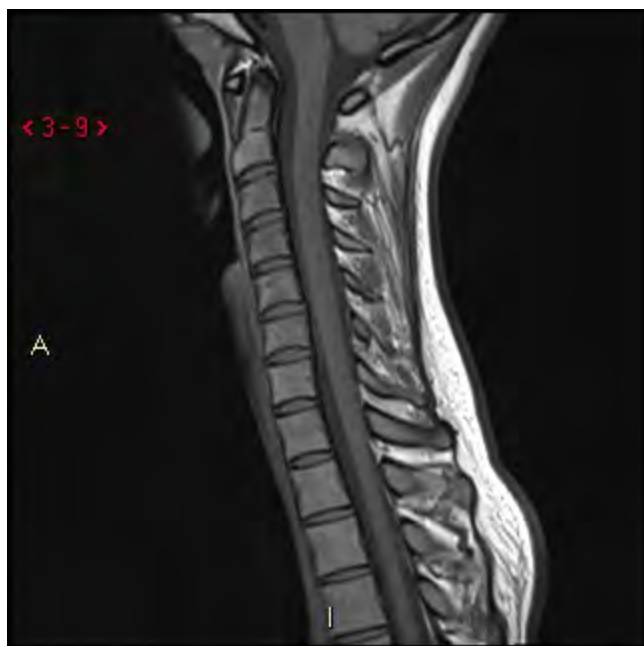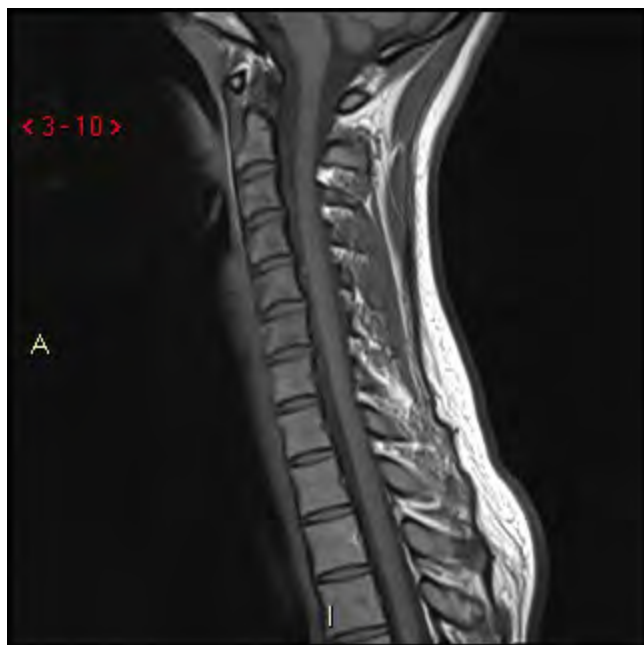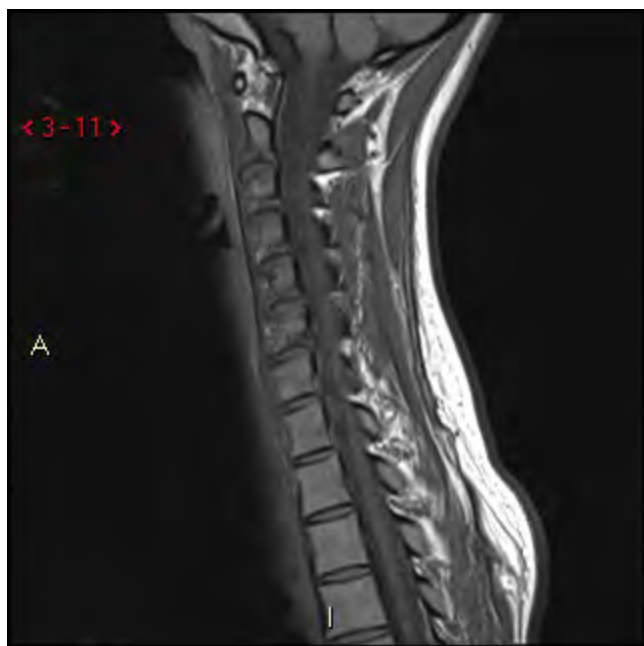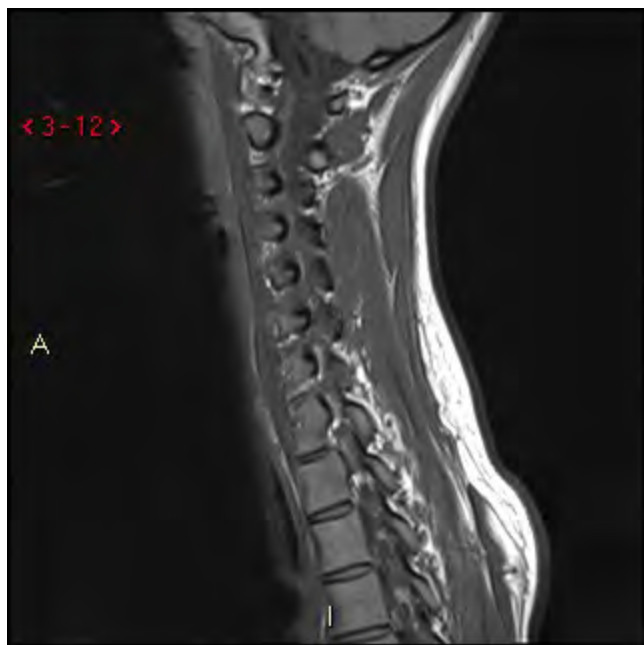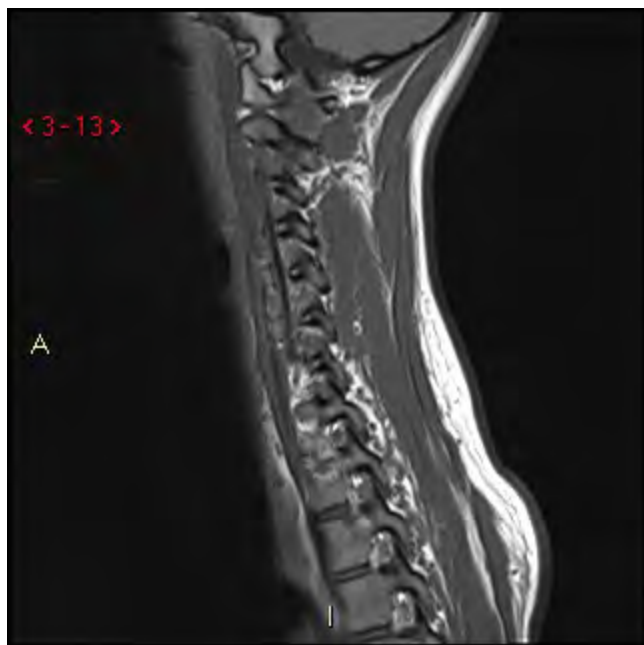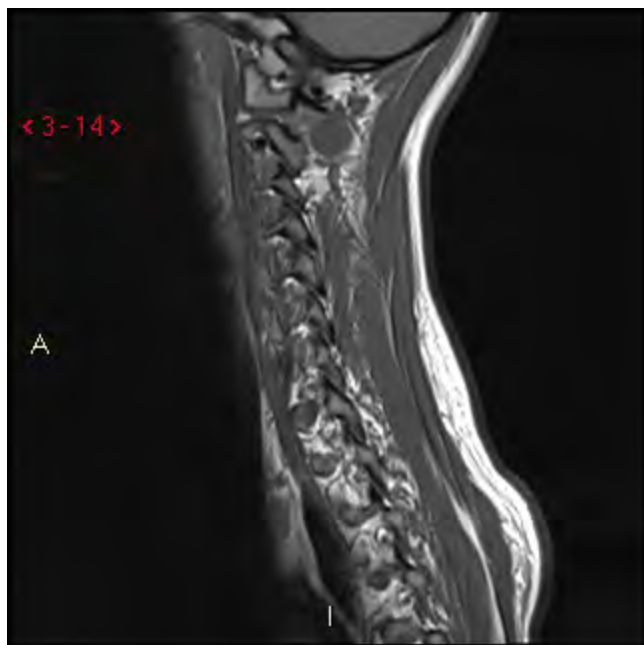


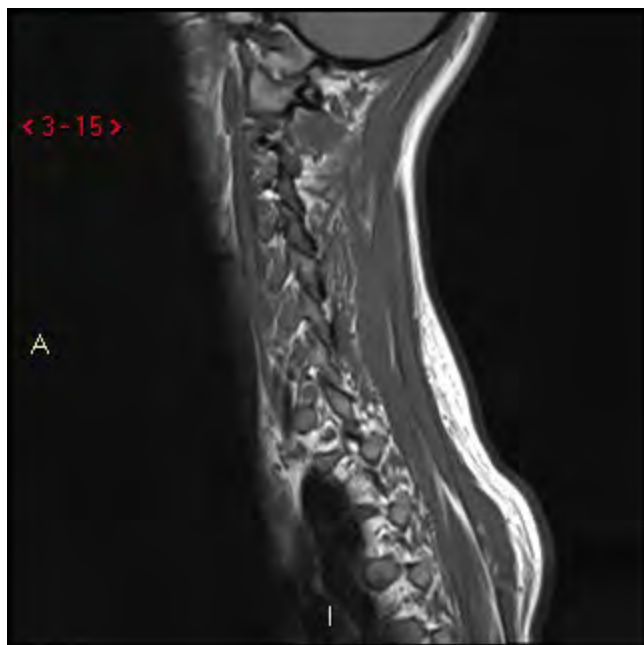


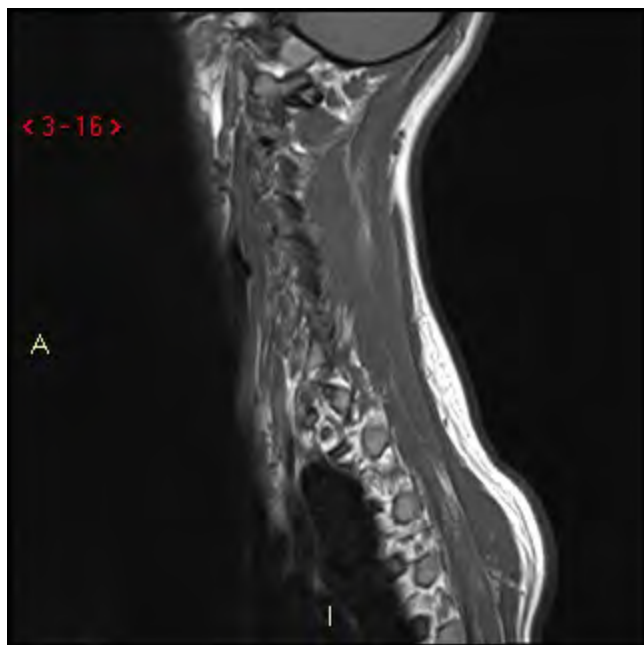


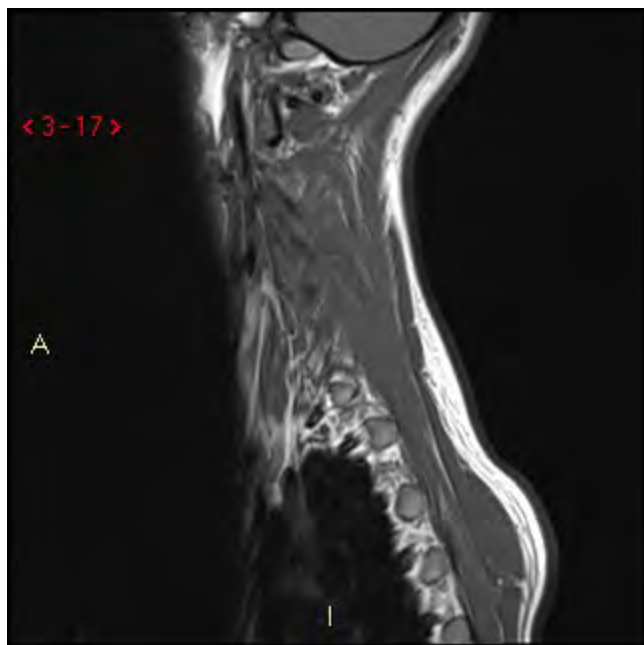


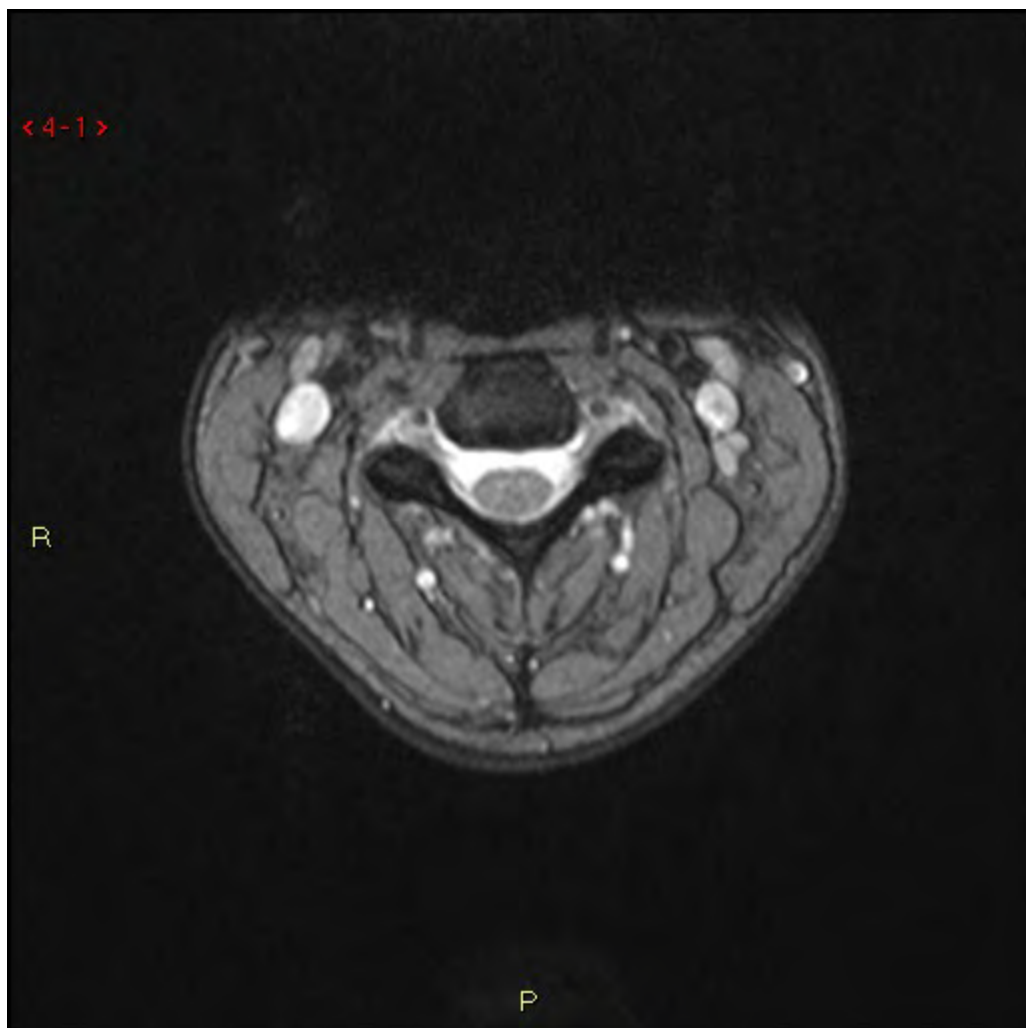


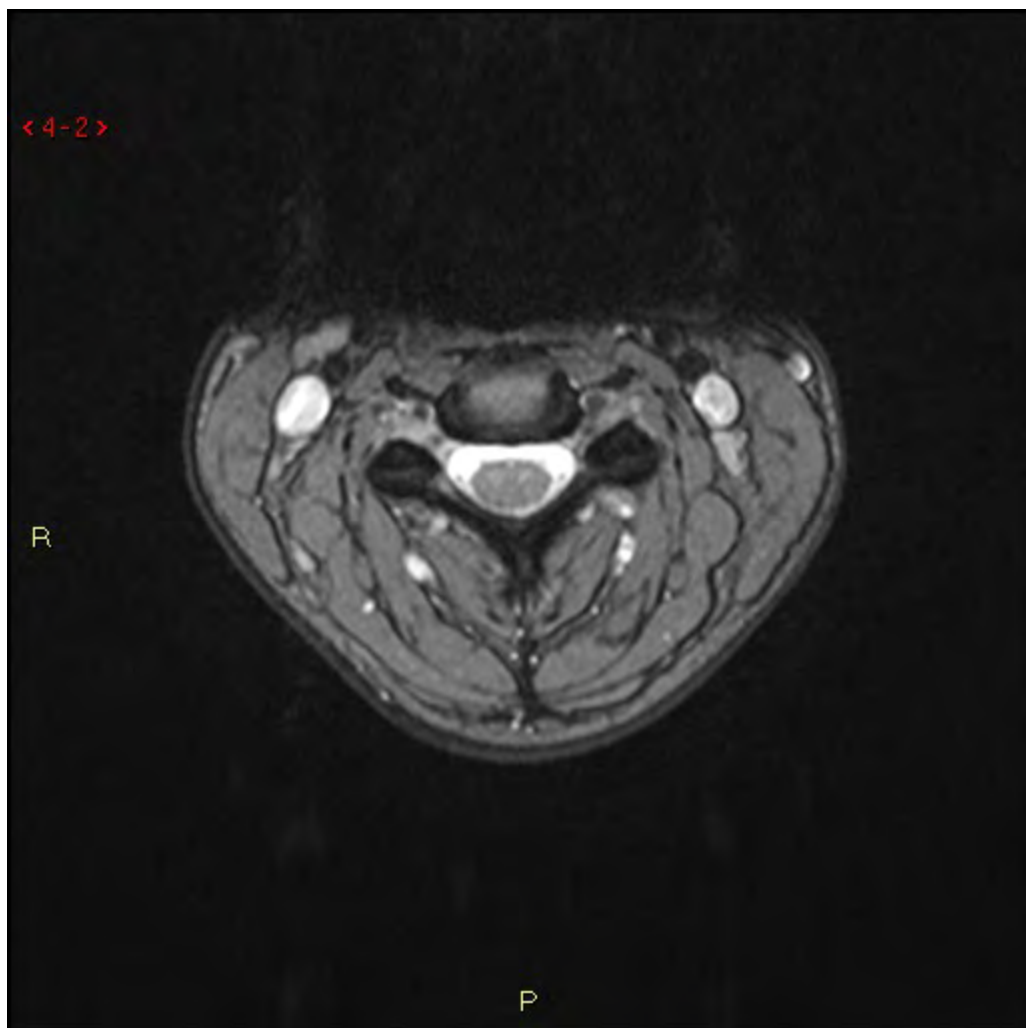




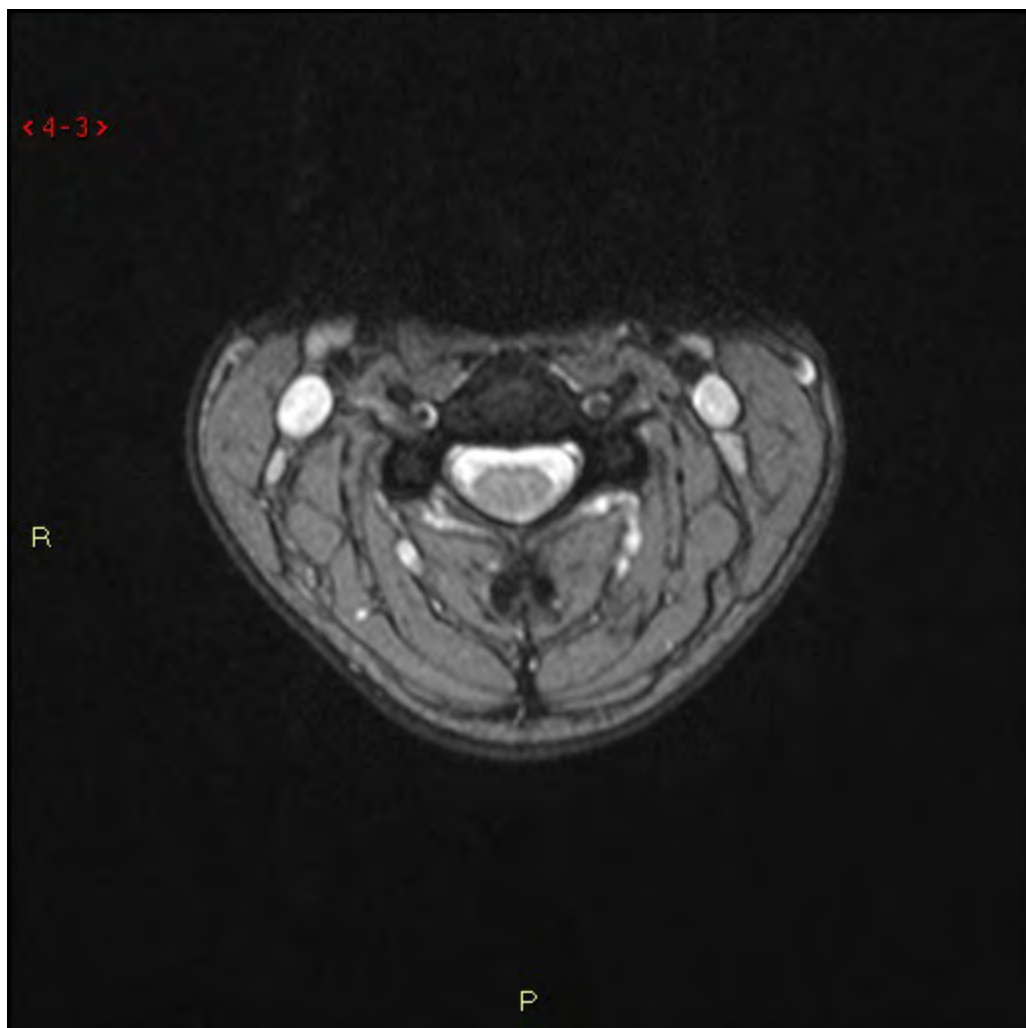


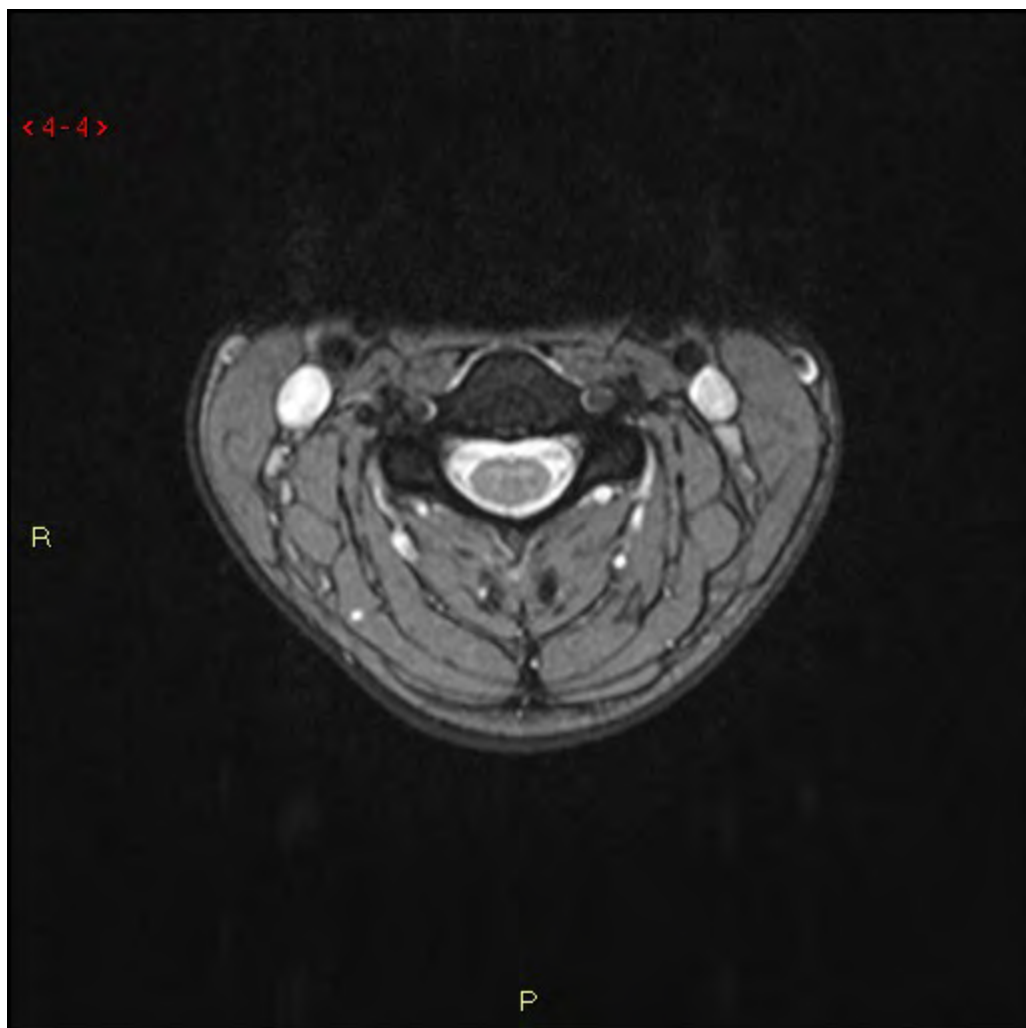


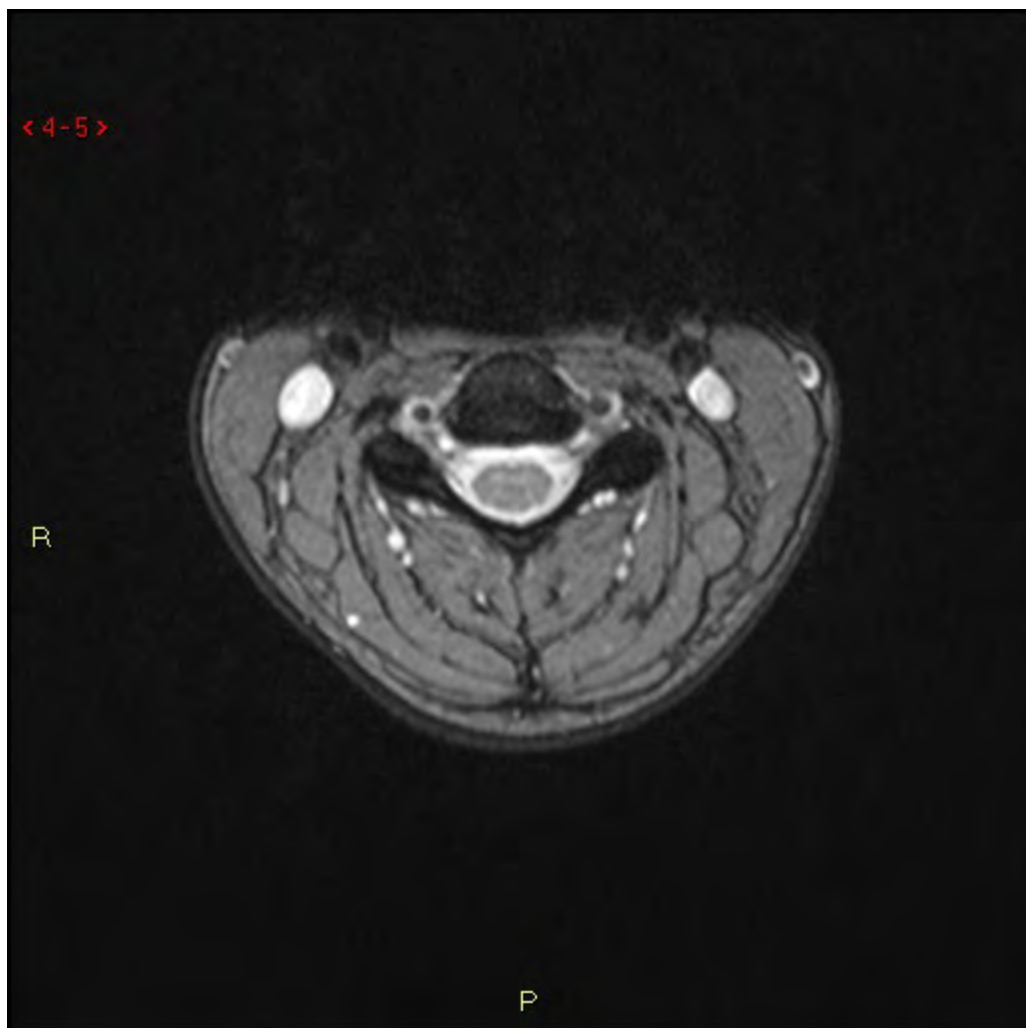


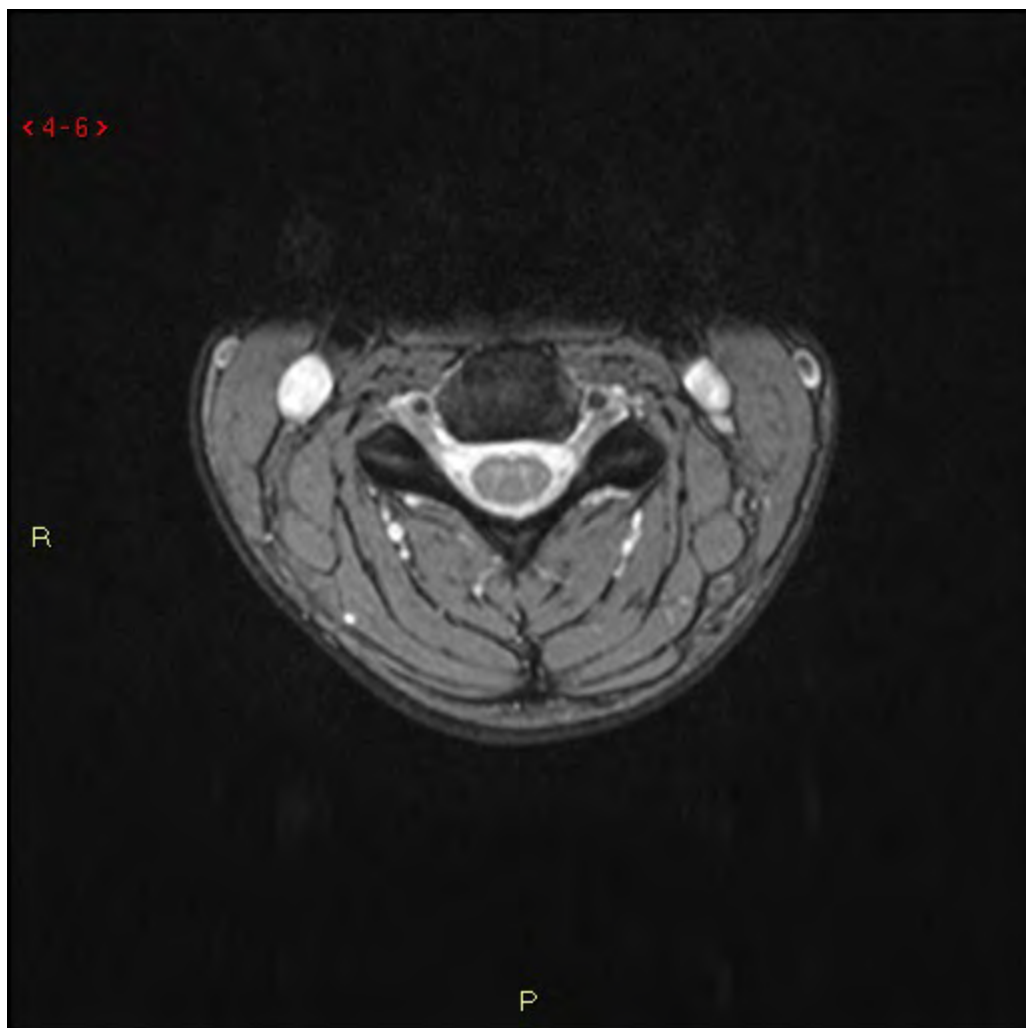


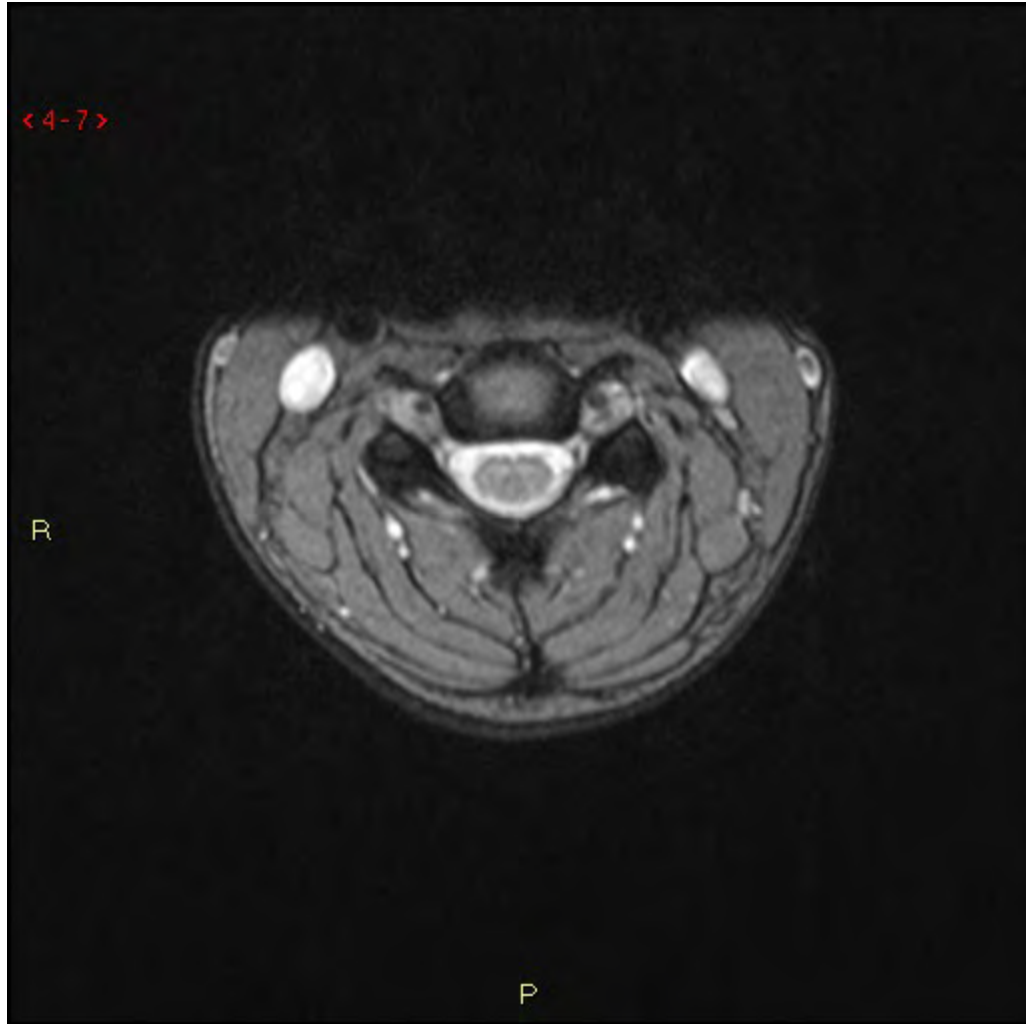


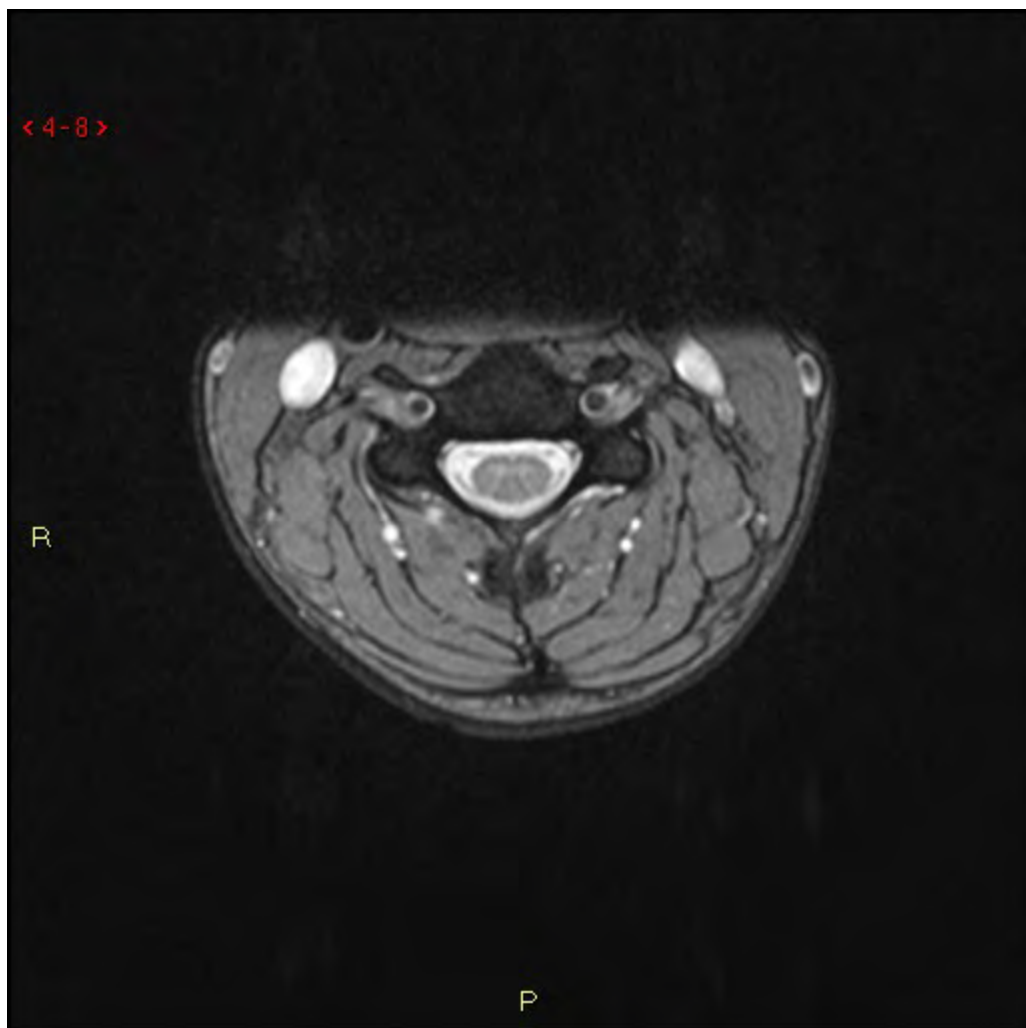


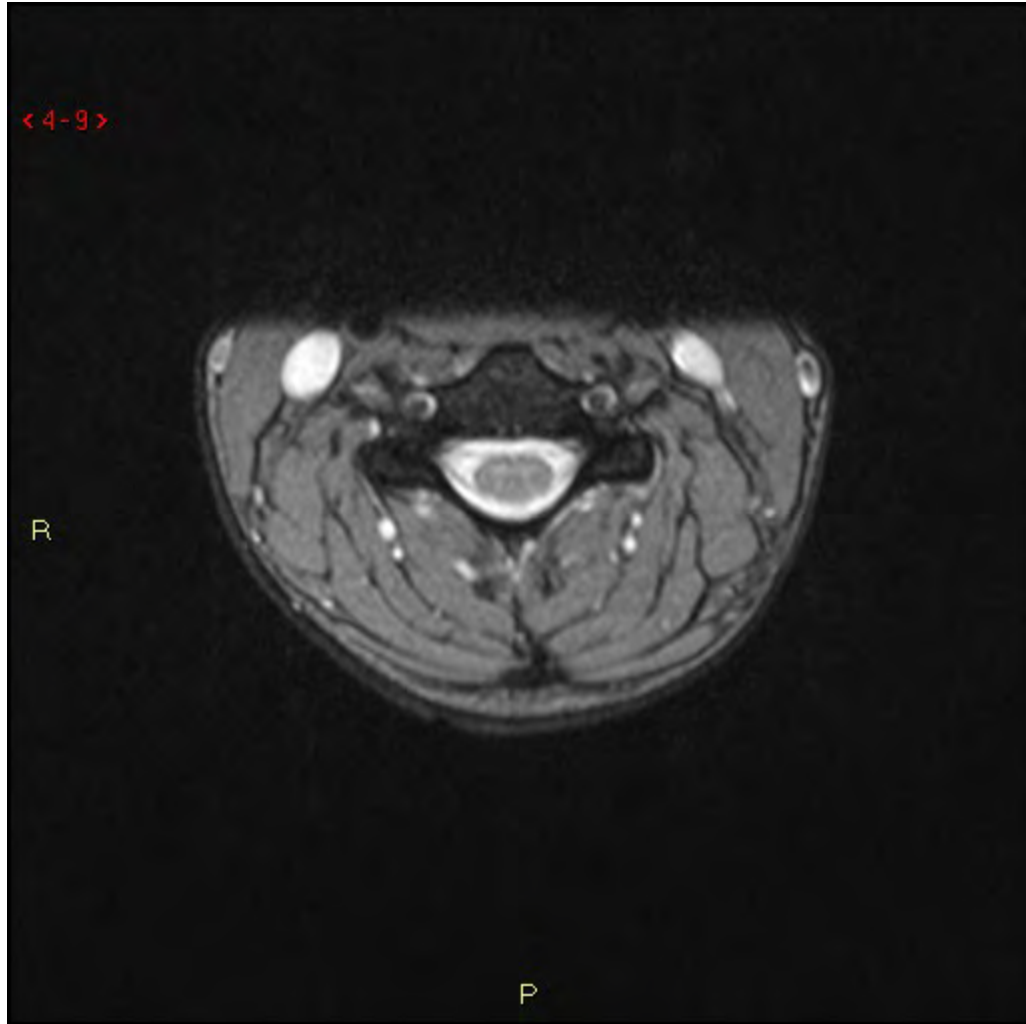








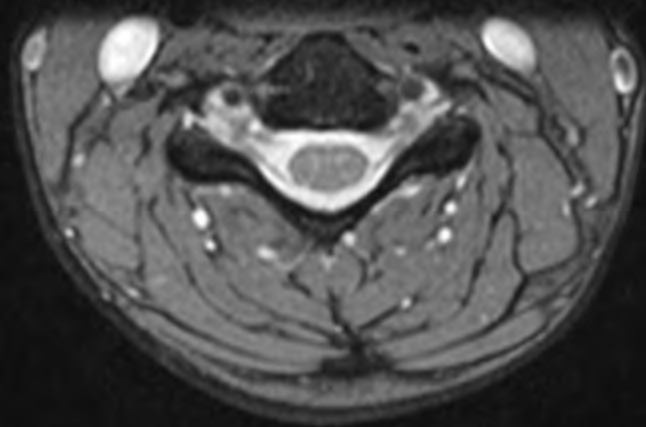




< 4-10 >

R

P

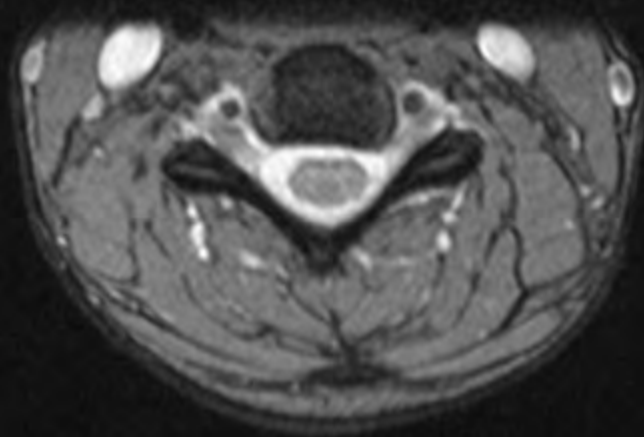



< 4-11 >

R

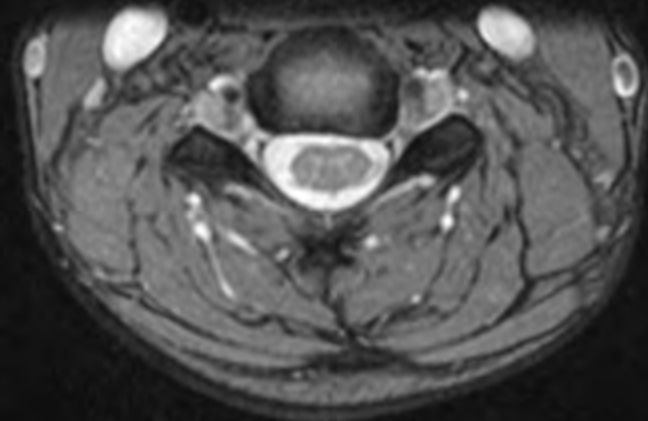
P



< 4-12 >

R

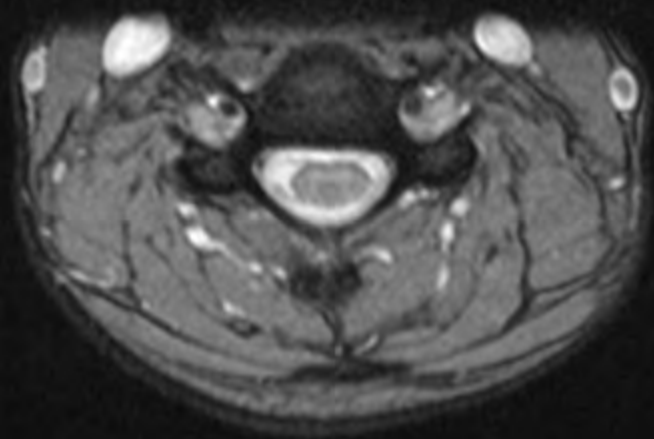P

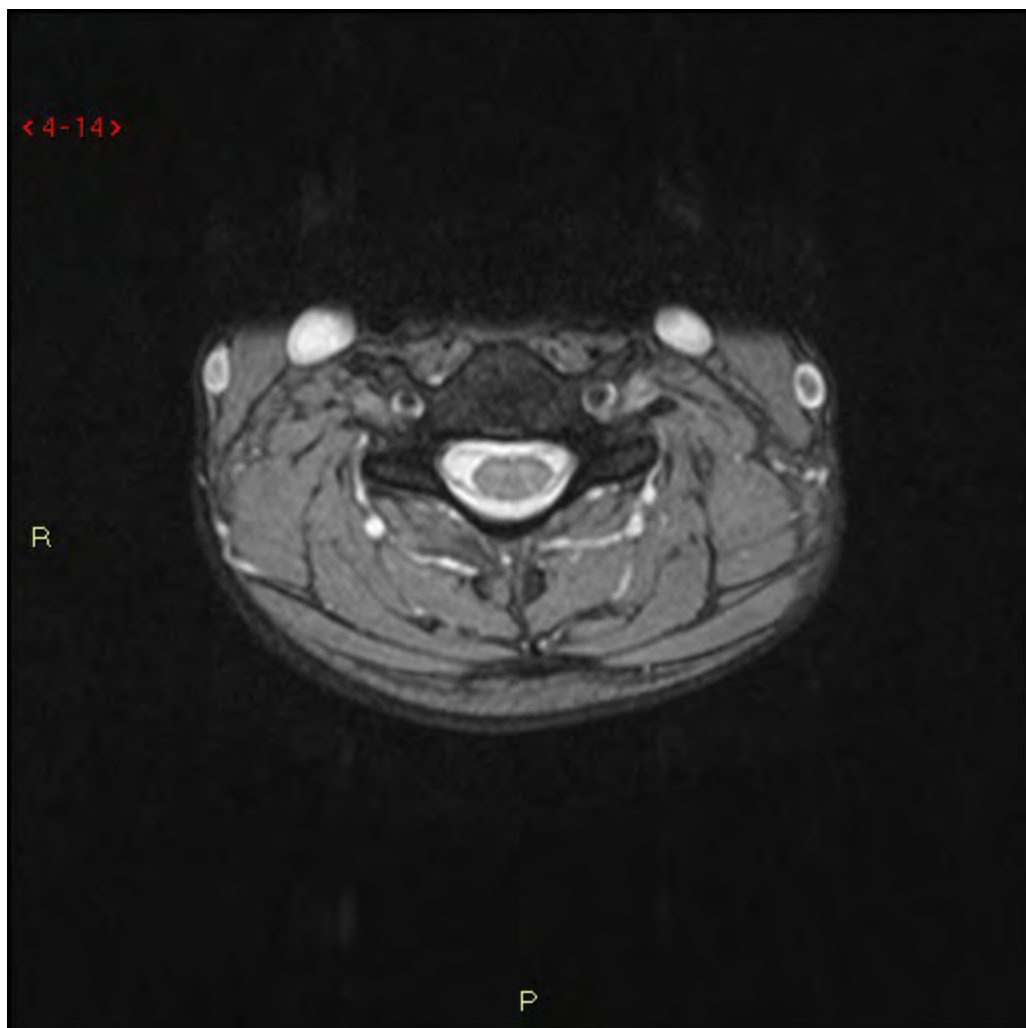


< 4-13 >

R

P

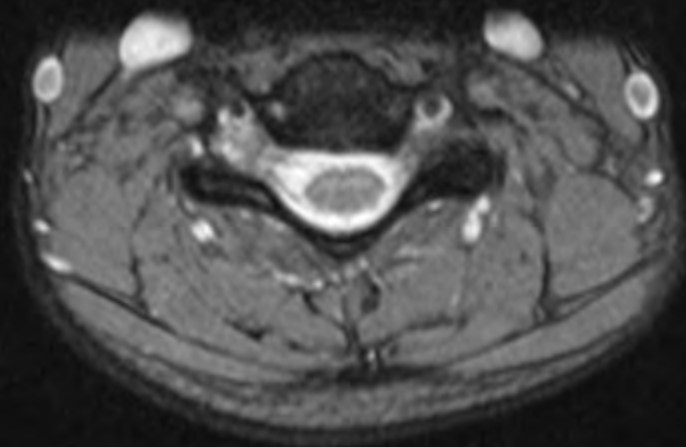




< 4-15 >

R

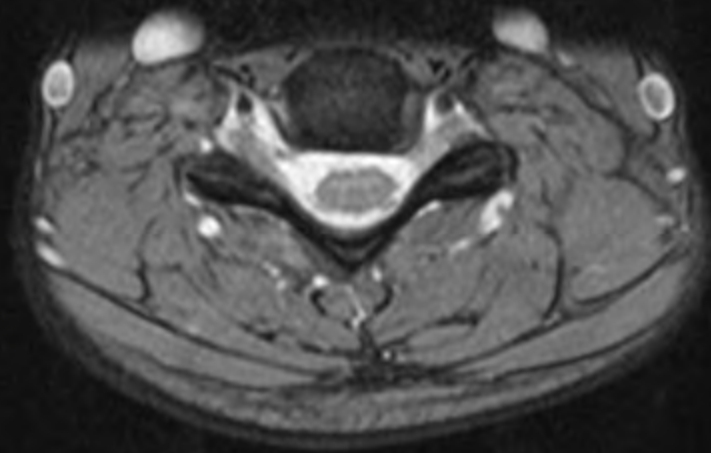
P



< 4-16 >

R

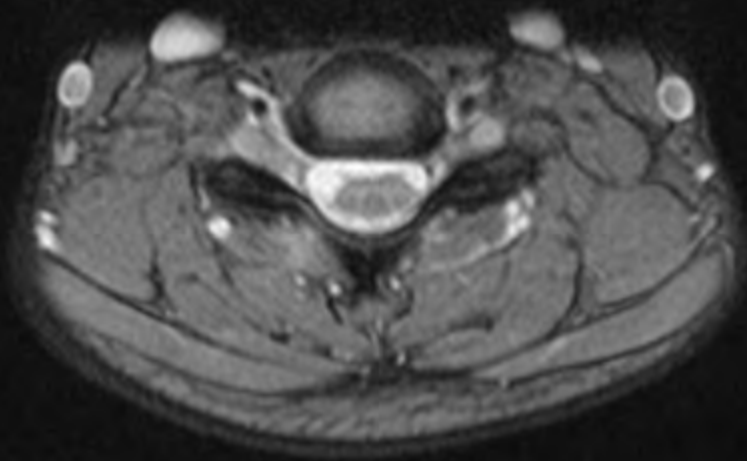
P



< 4-17 >

R

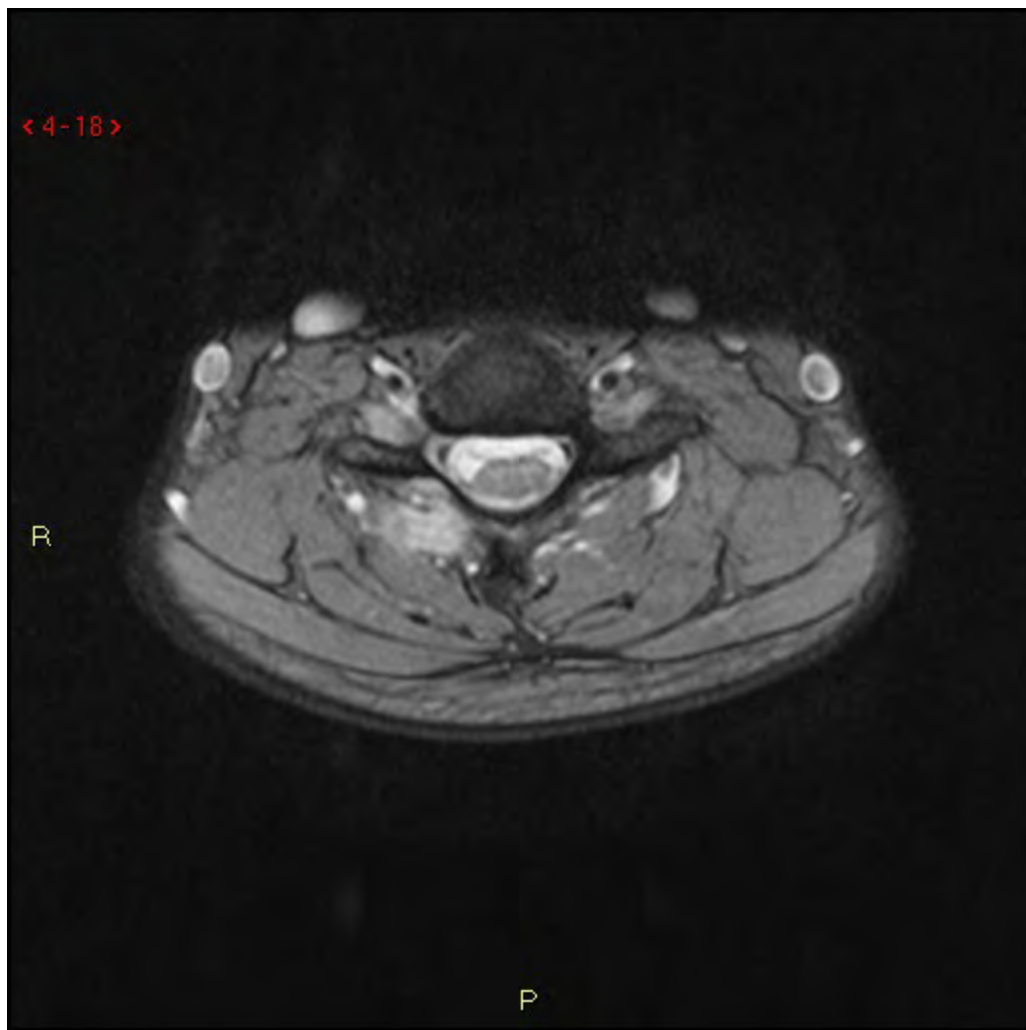
P



< 4-18 >

R

P

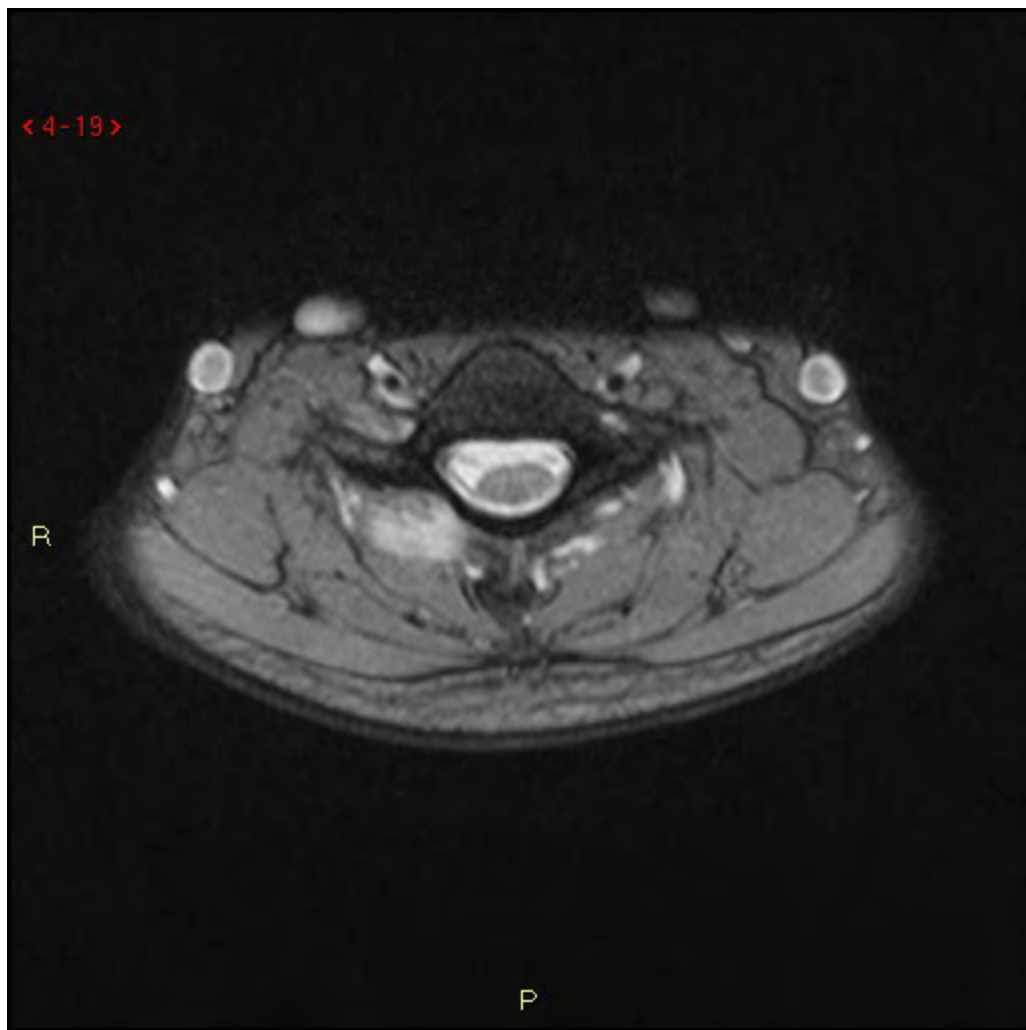


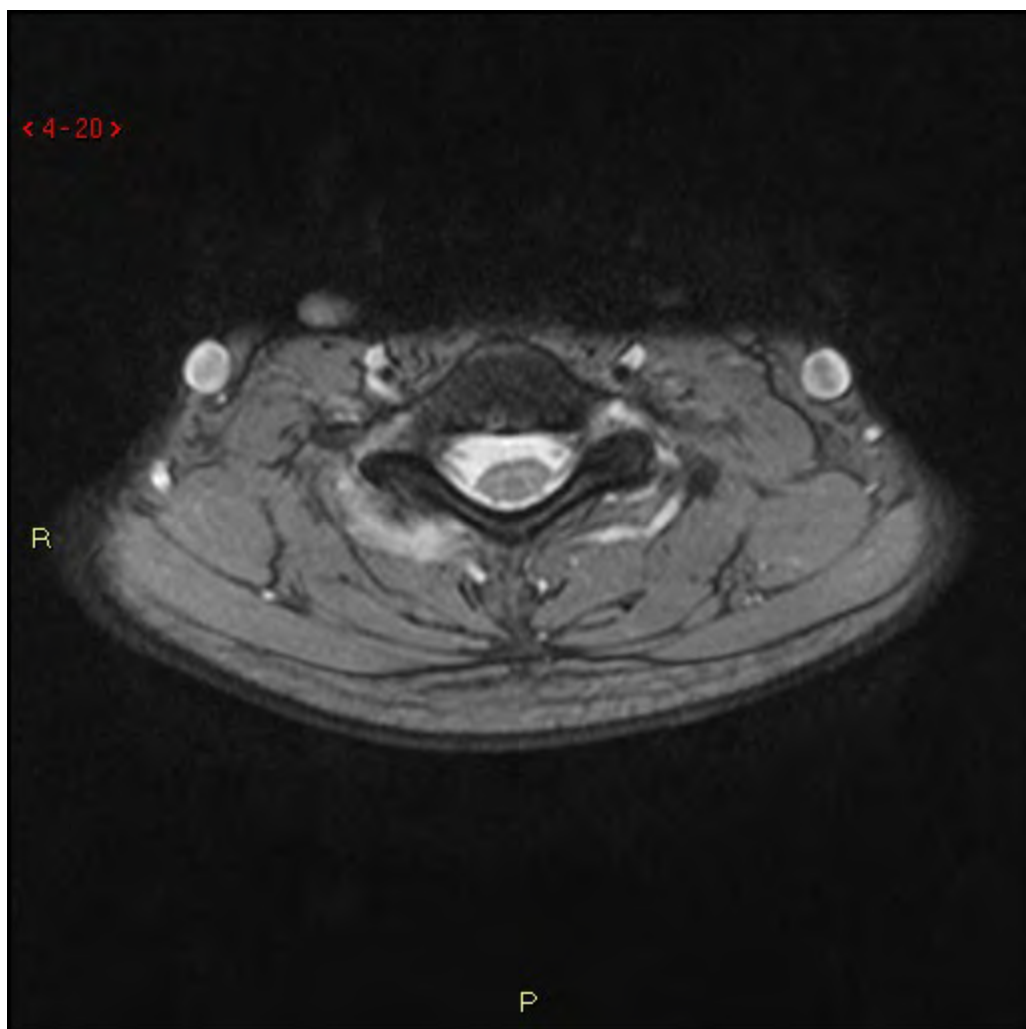


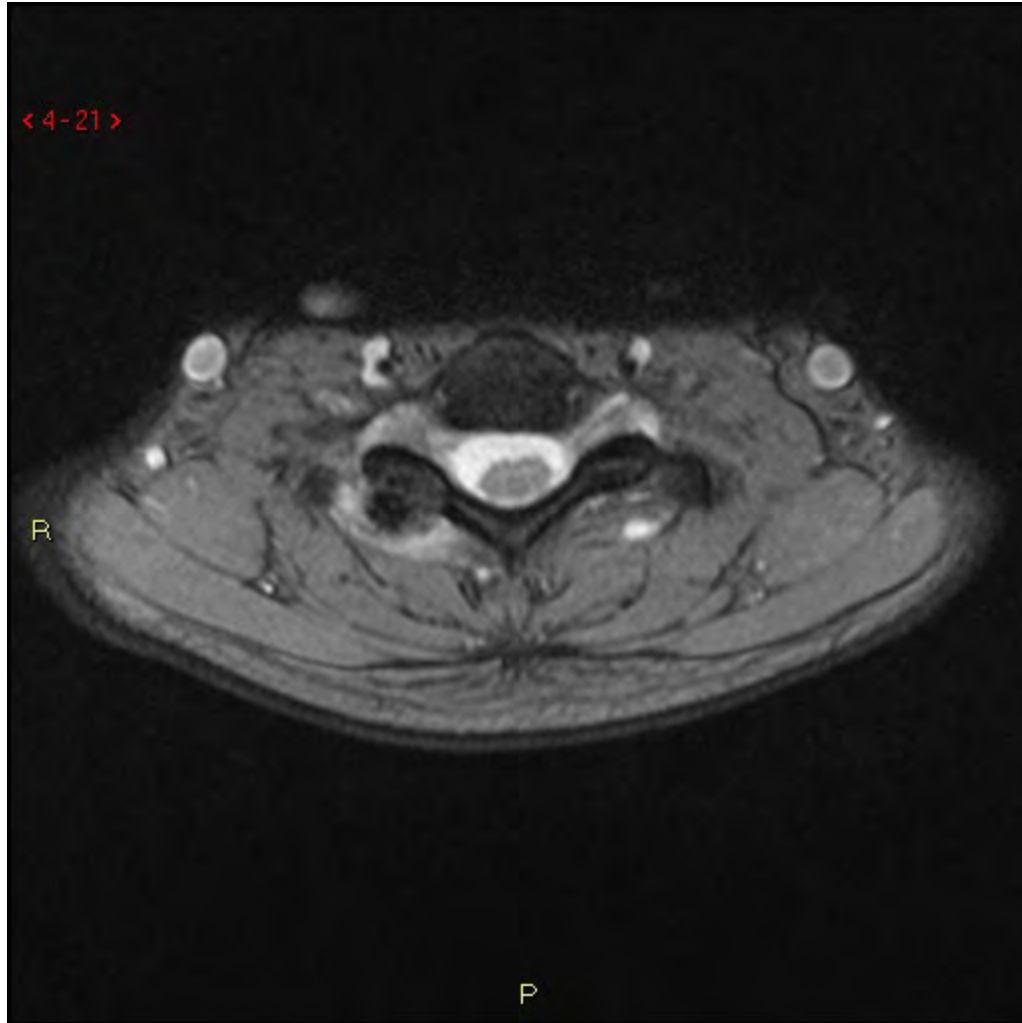
< 4-19 >

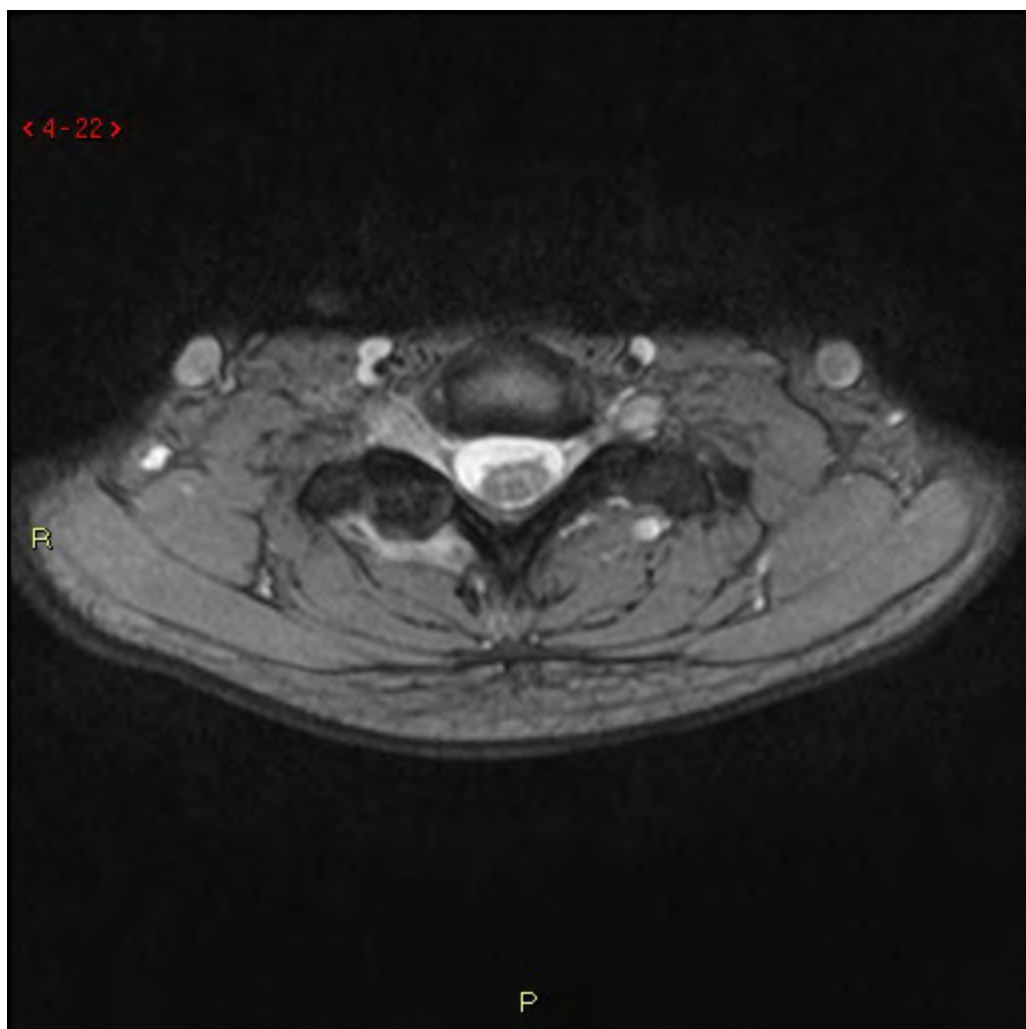
R

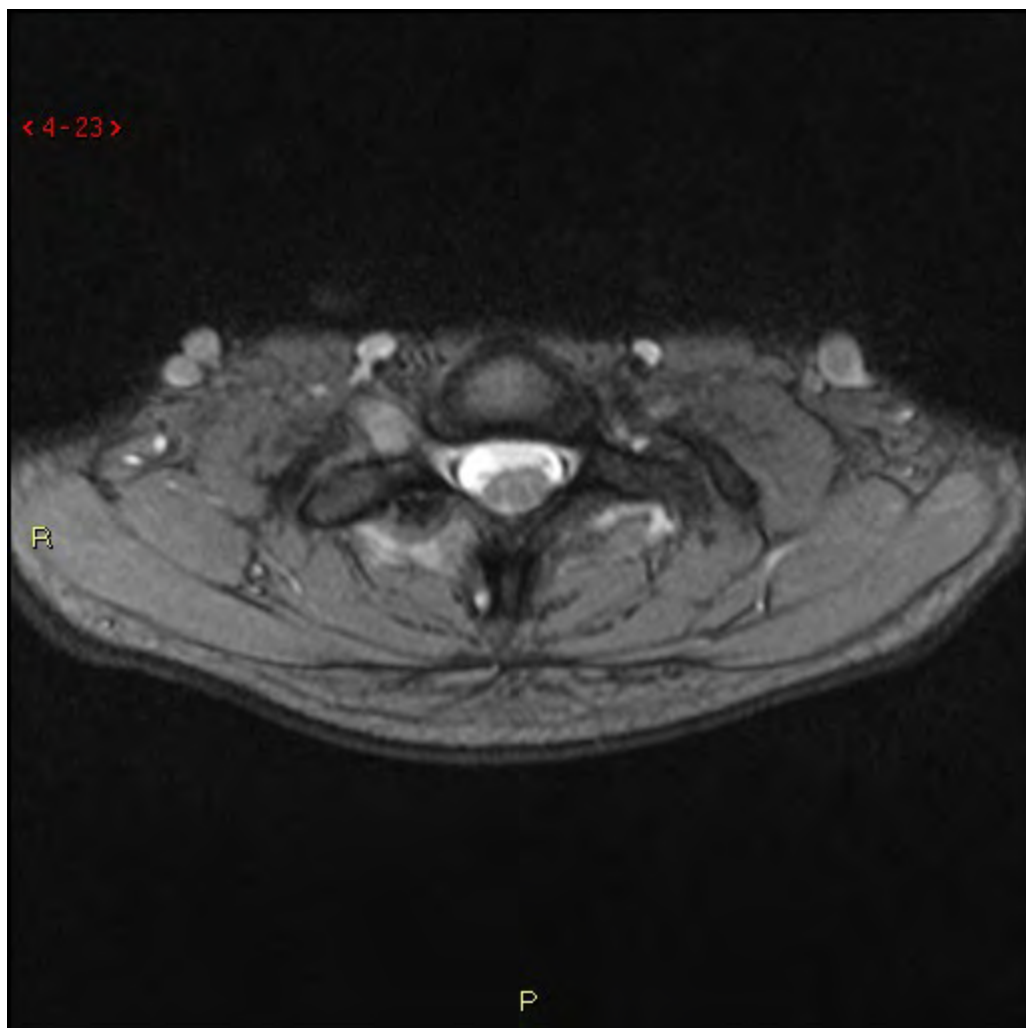
P

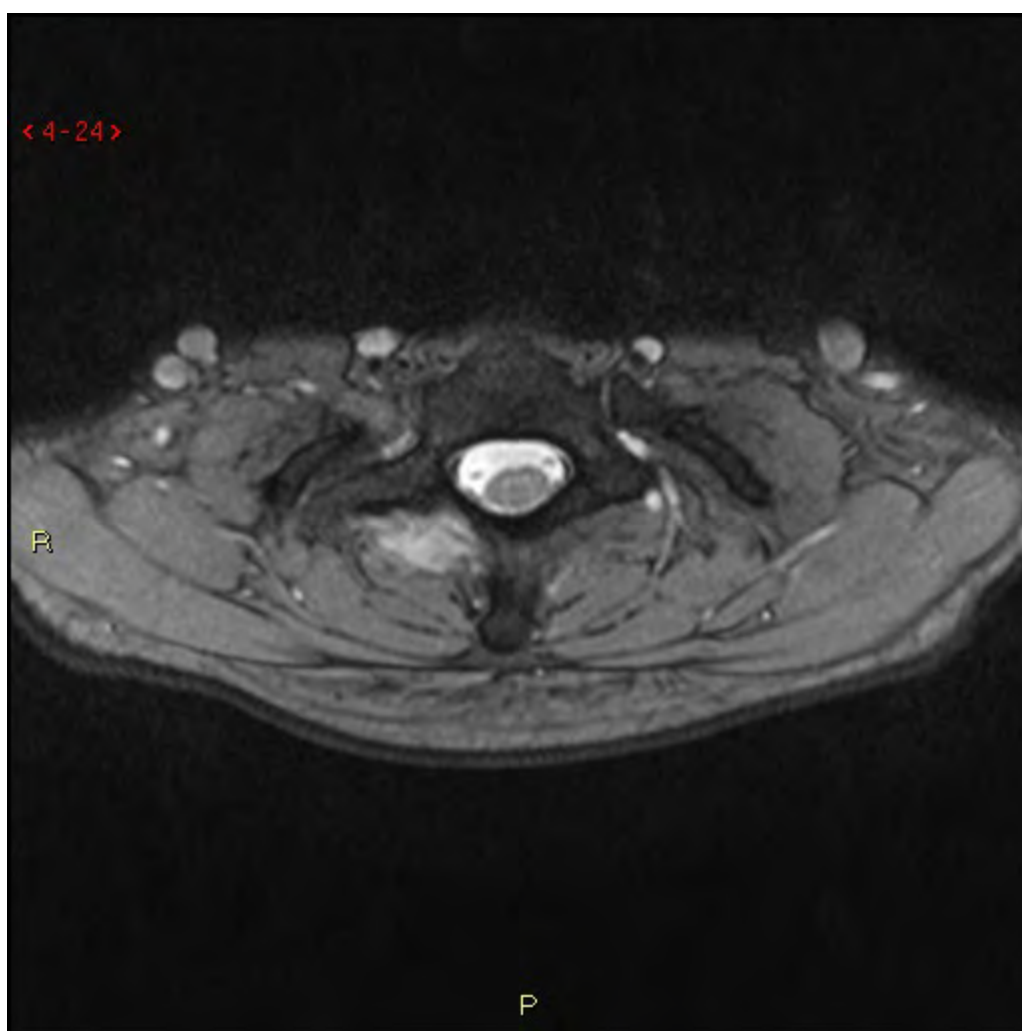








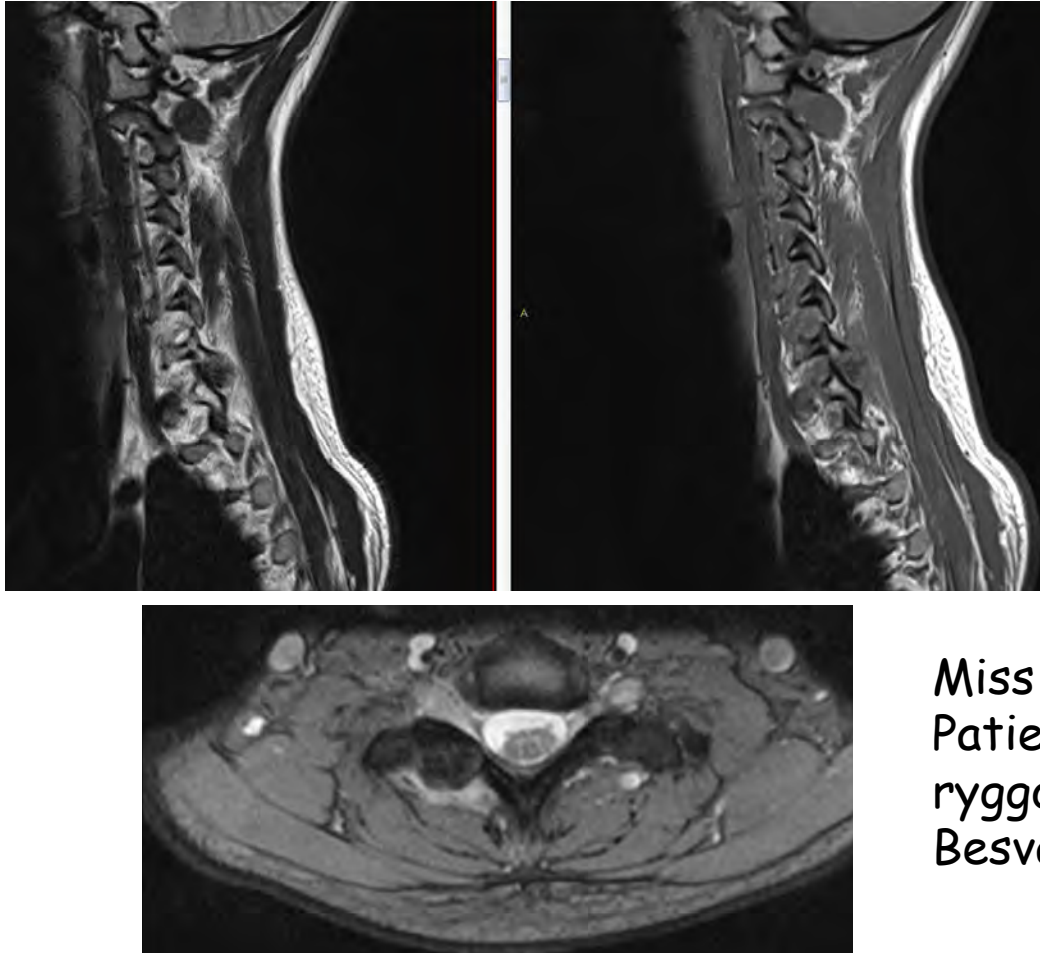




# Fall 10

Fynd?

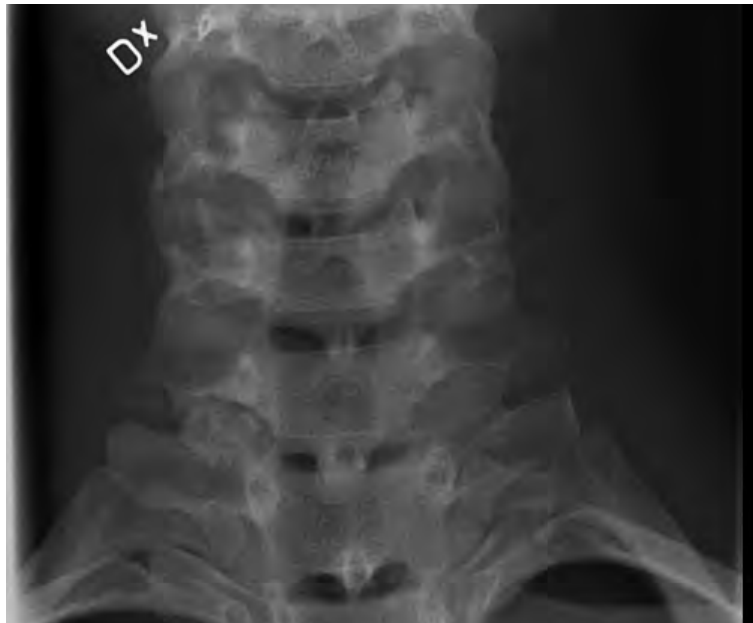# Fall 10



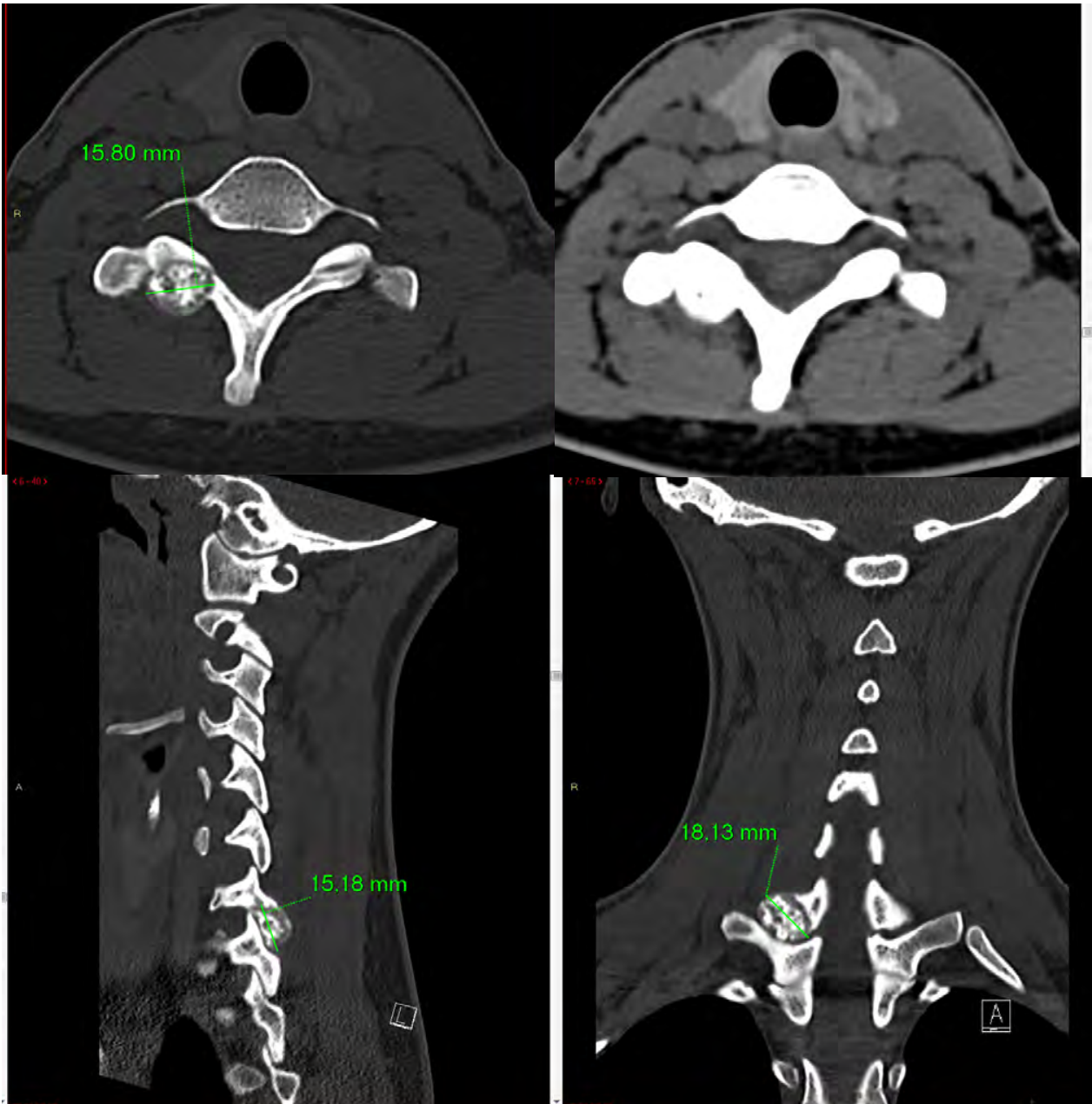
Miss av RTG!  
Patient remitteras till  
ryggortoped pga ihållande  
Besvär, som hittar förändringen!



# Fall 10



# Fall 10



# Fall 10

- Osteoid osteom: 10-20 år. 2-3:1= M:F, <1.5cm i diameter om större osteoblastom. Bakre kotdelar (75%) nidus omgivet av reaktiv cortikalt ben, radiolucent zon, sällan i kotkropp, epiduralt eller paraspinalt. Ländrygg, Halsrygg, Bröstrygg och mest sällan Sacrum.
- Osteoblastom: 20-30 år, 2-3:1=M:F, ofta >2cm i diameter bakre kotdelar, ofta in i kotkroppen. Inget nidus, ofta lytiskt. Hals- Bröst och Ländrygg.
- Osteochondrom: 30-40 år, 2:1= M:F. Bakre kotkroppsdelar, ssk spinalutskott i halsrygg, A-A.
- Hemangiom: topp 30-40 år. Kotkroppens vaskulära delar, vertikala parallella stråk med högre densitet än omgivningen. Bröst-Ländryggsövergång. Prickigt på axial DT.
- Aneurysmal bencysta: 5-20 år. Bakre kotkroppsdelar, cystisk och cystorna innehåller blod produkter, lytic expansiva lesioner med vätskenivåer