

Fall 11

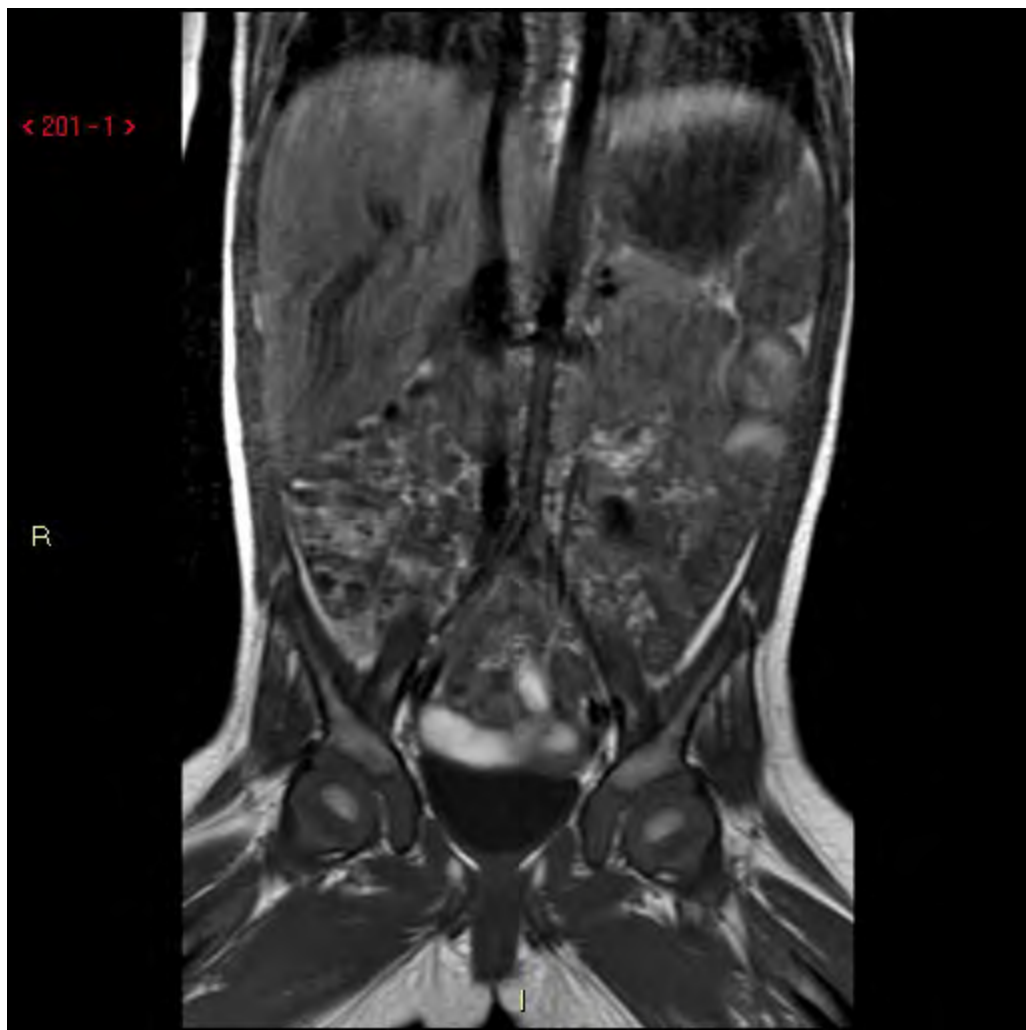# Fall 11

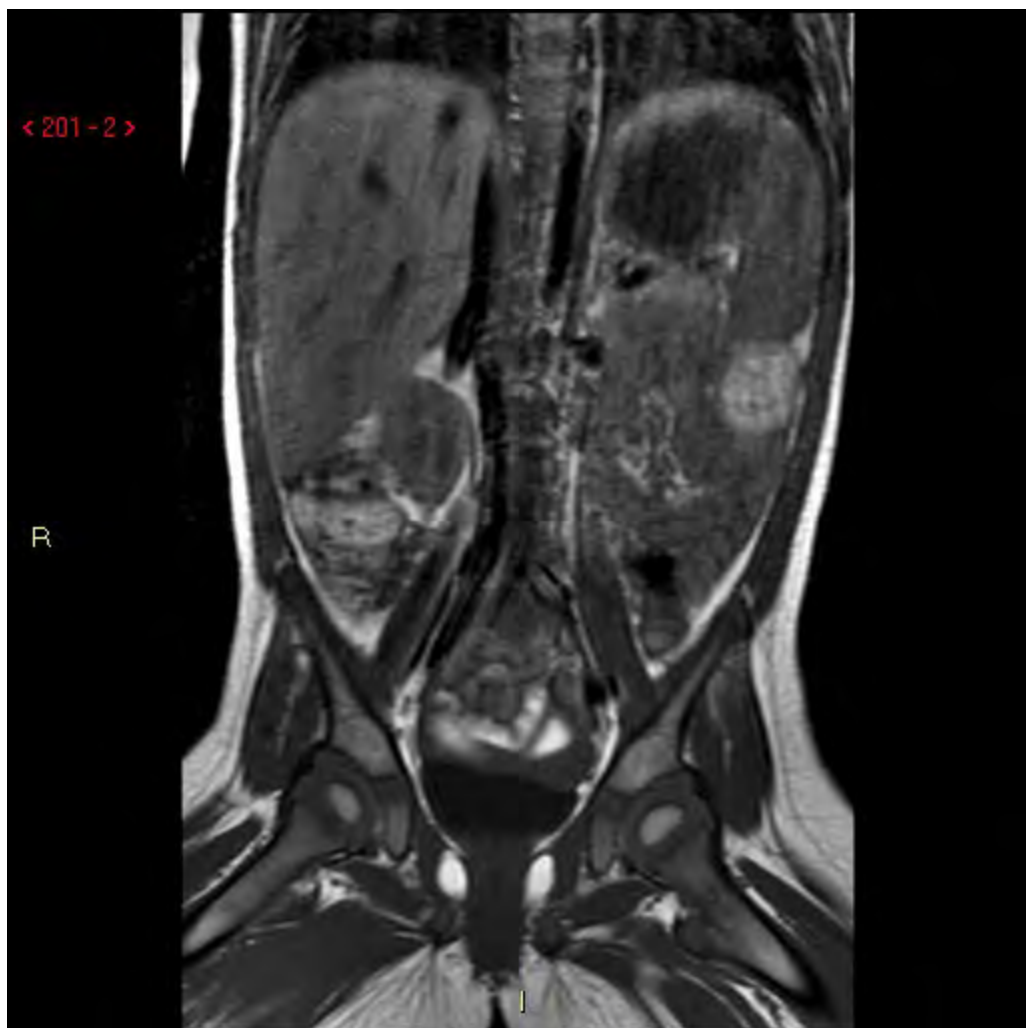1år och 1mån Flicka.

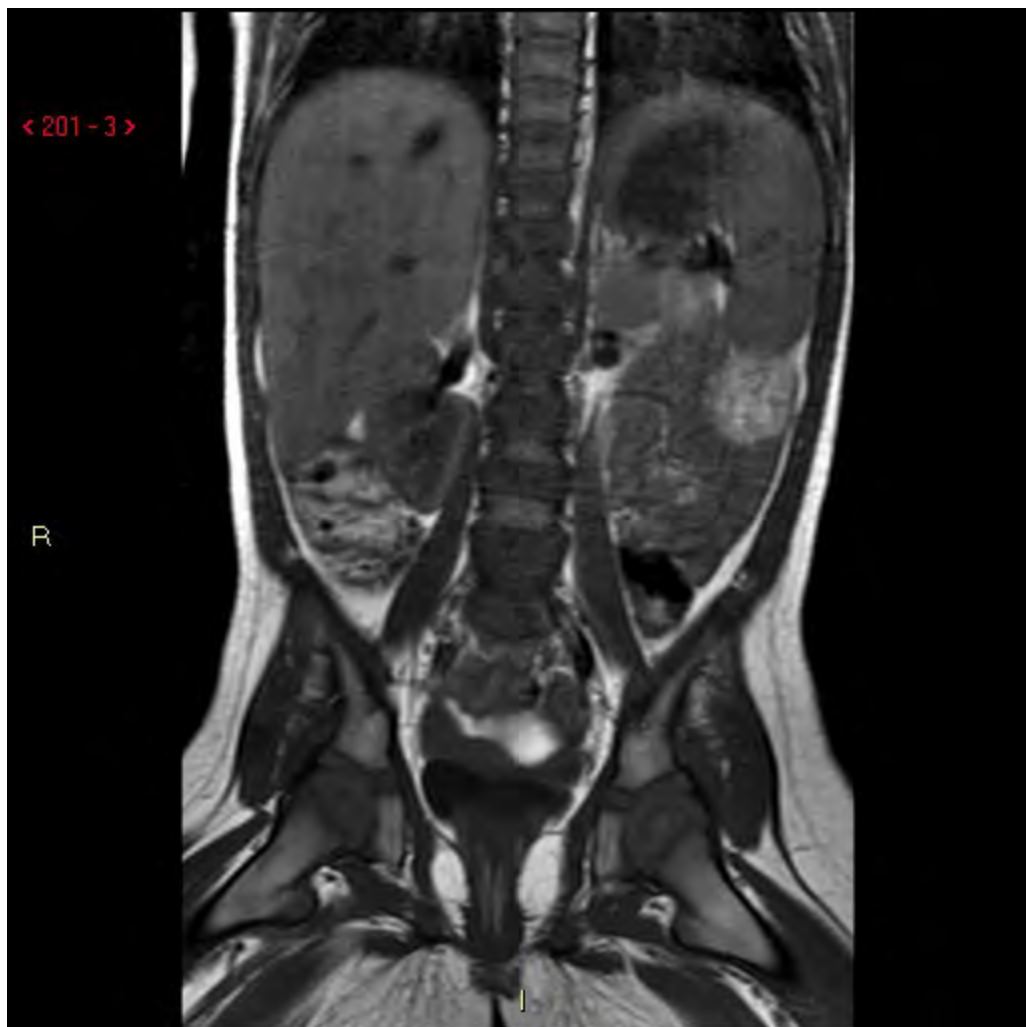Inkommer till Barnkir-Neurokir pga  
paraspinaltumor i ländryggen.

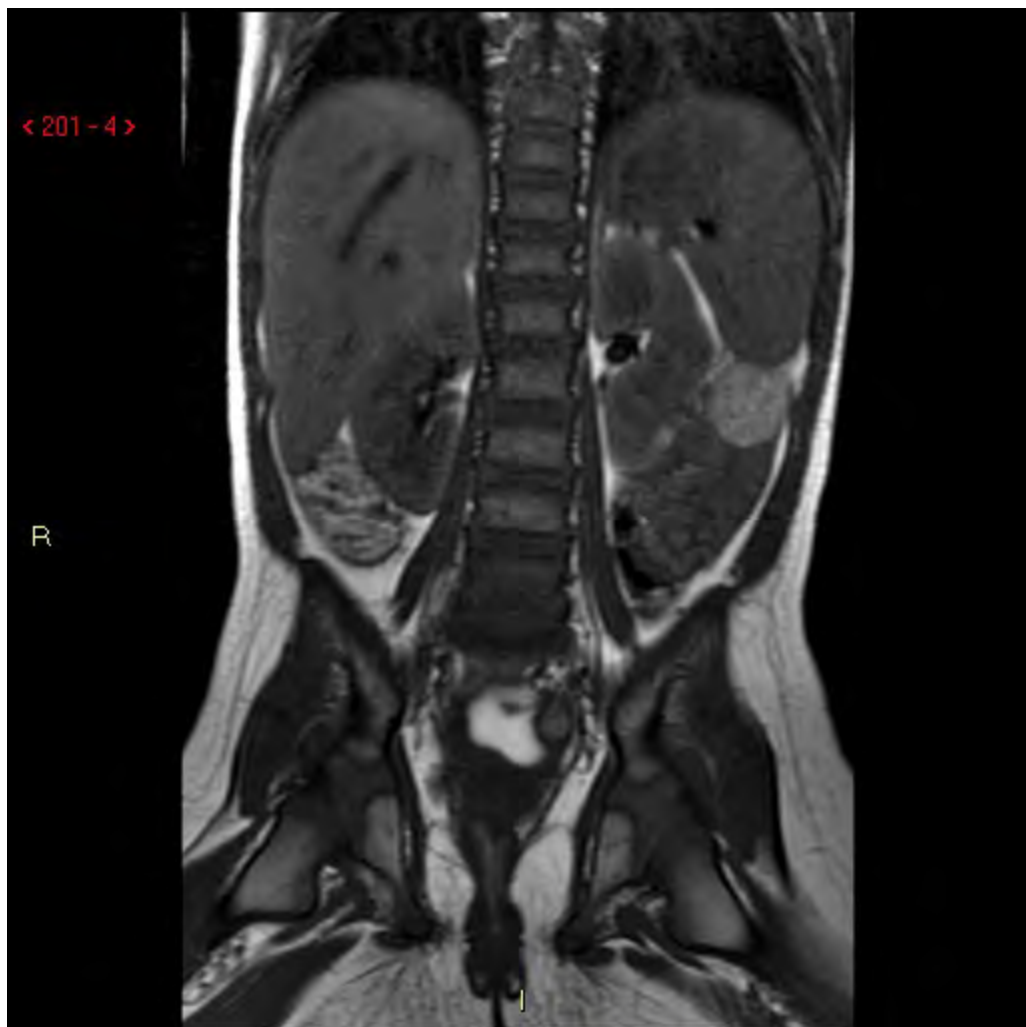Lärde sig gå vid 1 åå. Sedan 1månad svåra  
smärtor. Coxit? Nu svårt att sitta.

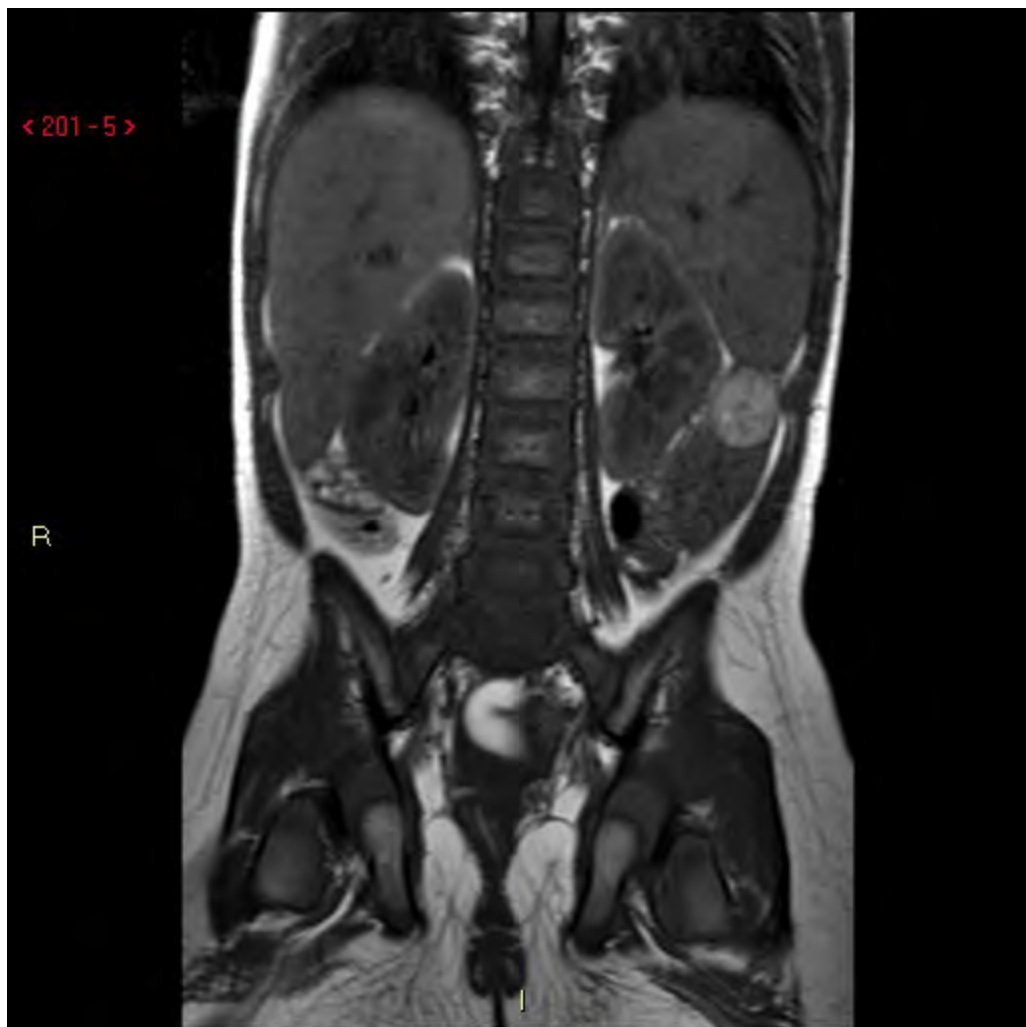MRT från hemorten.

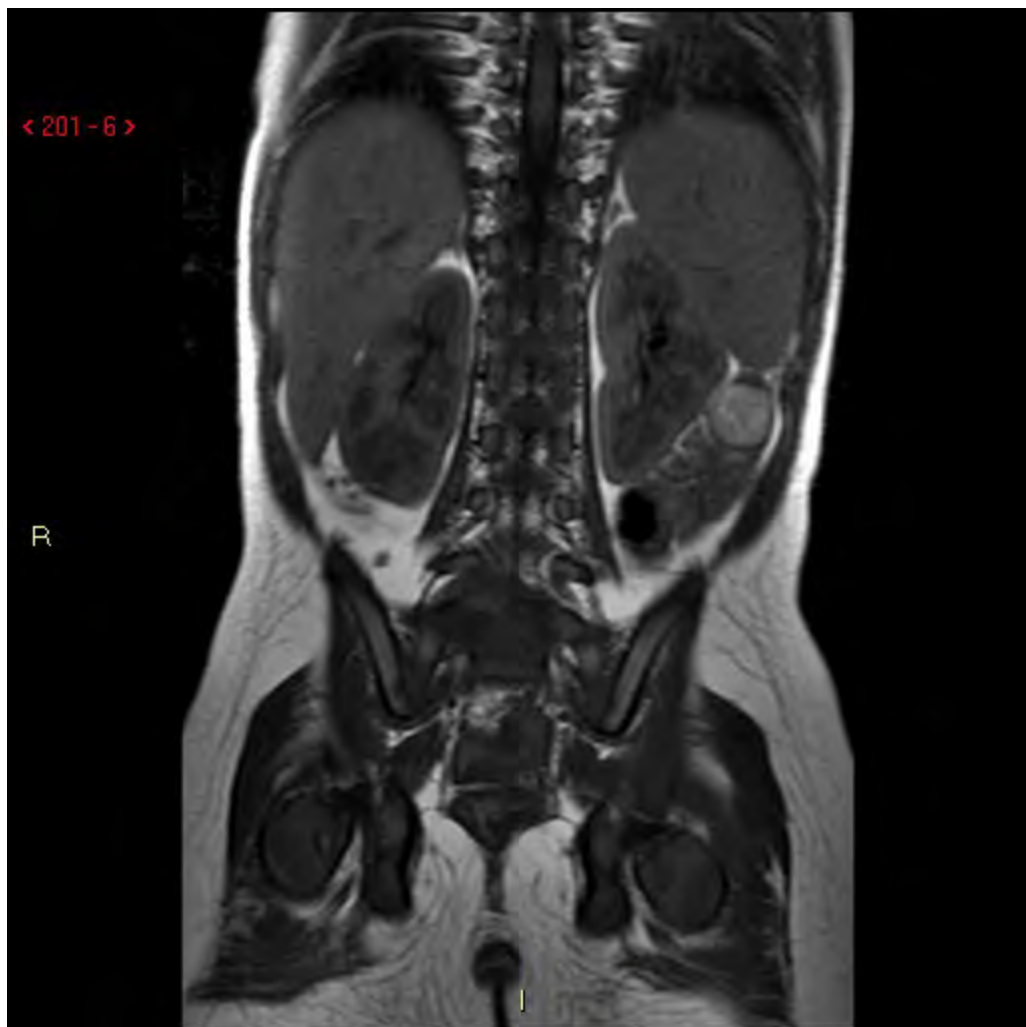




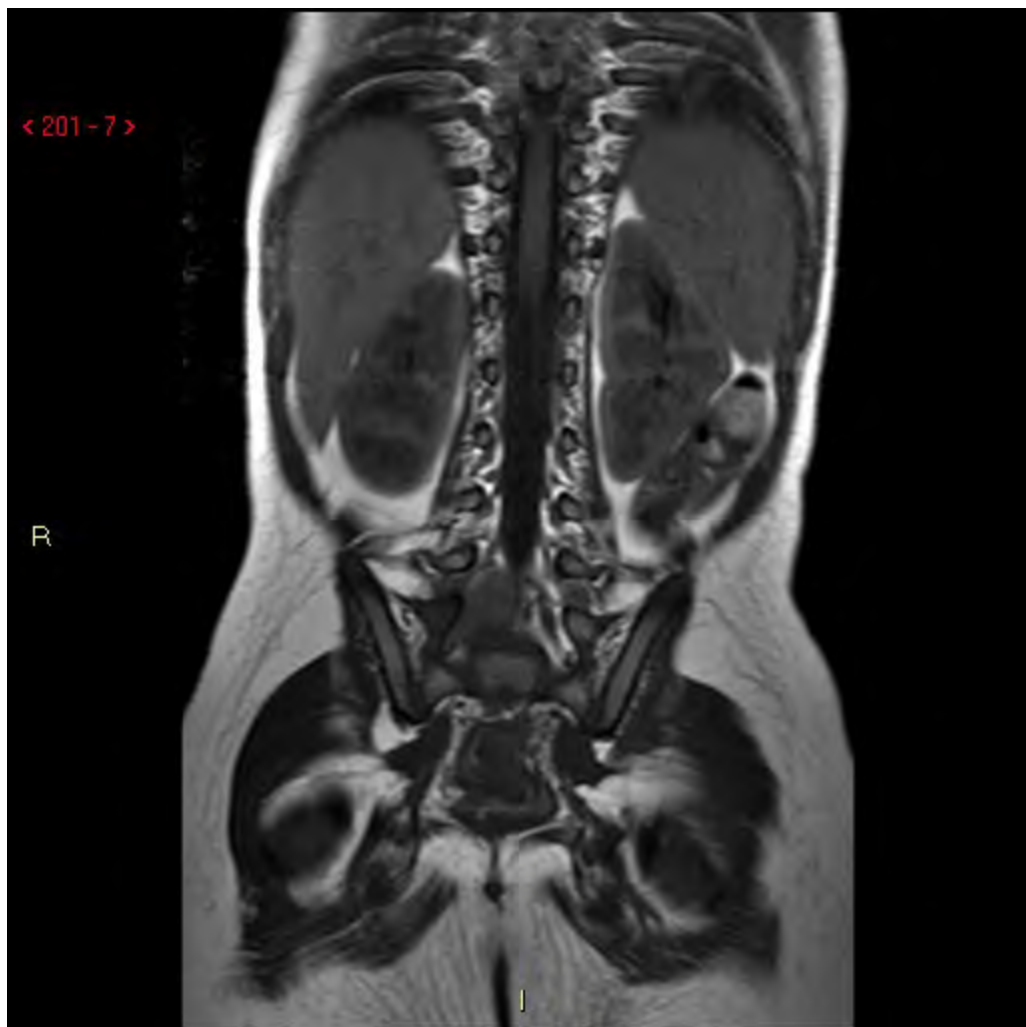


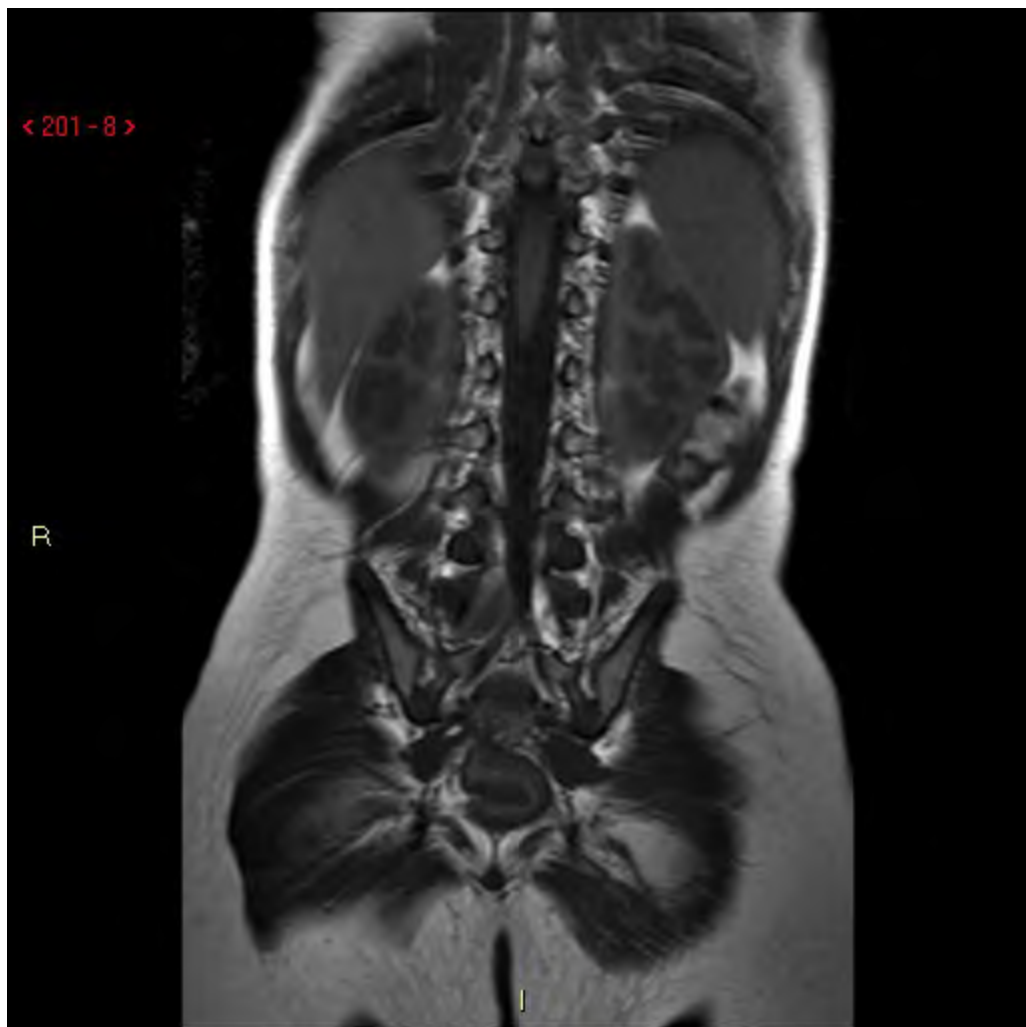


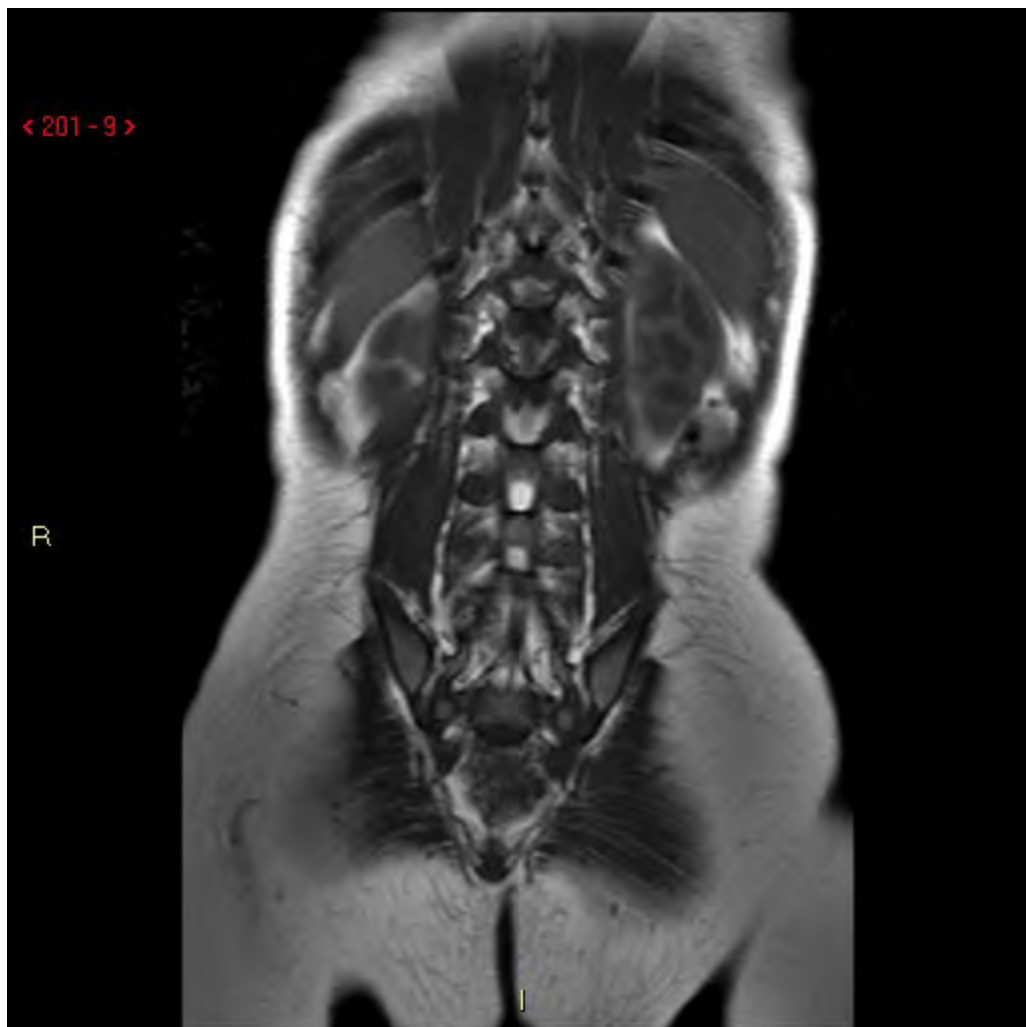


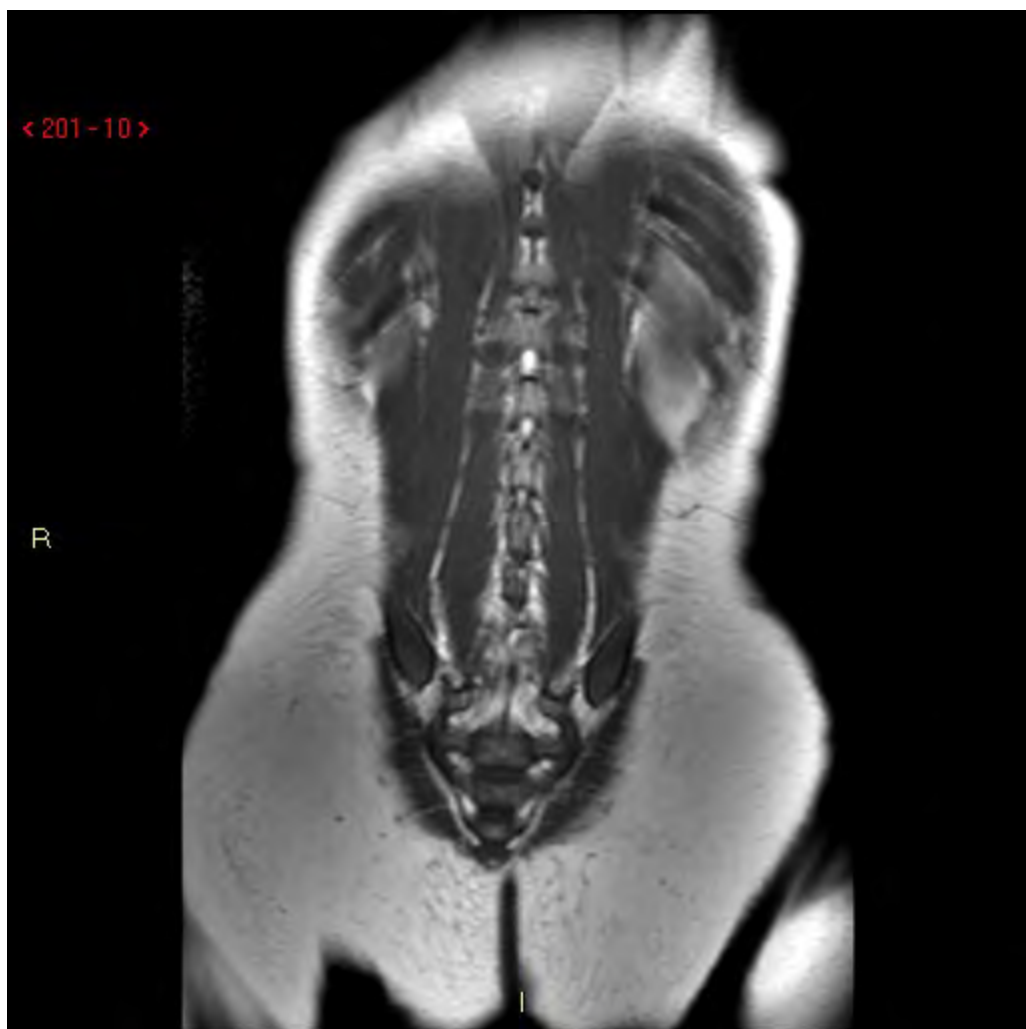







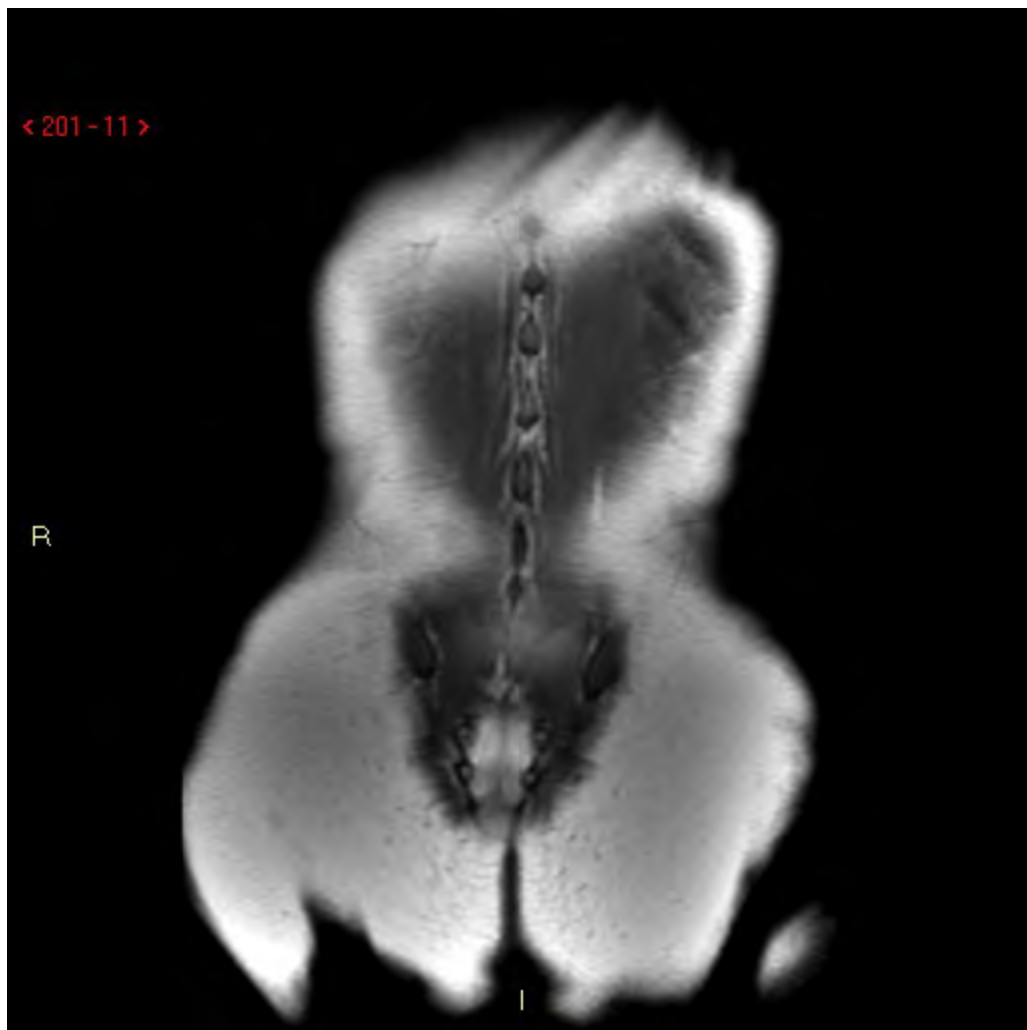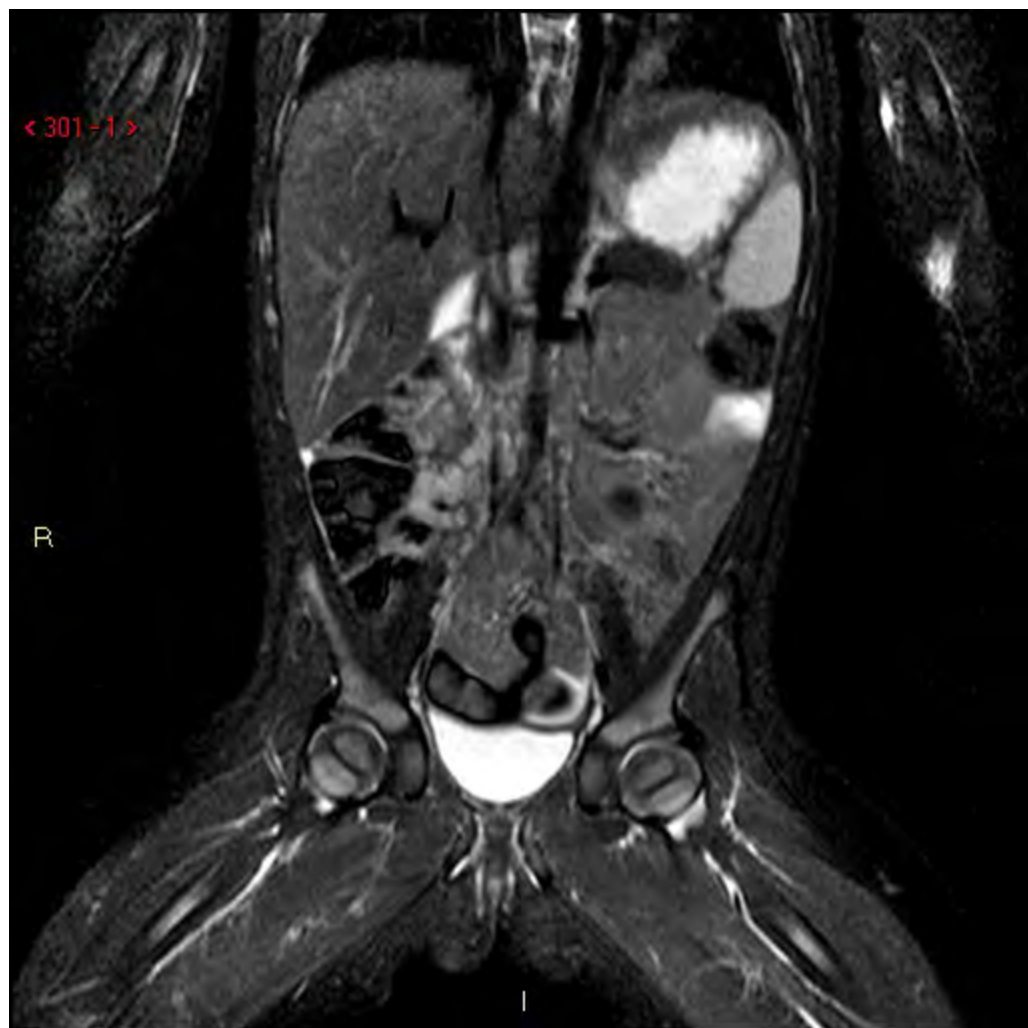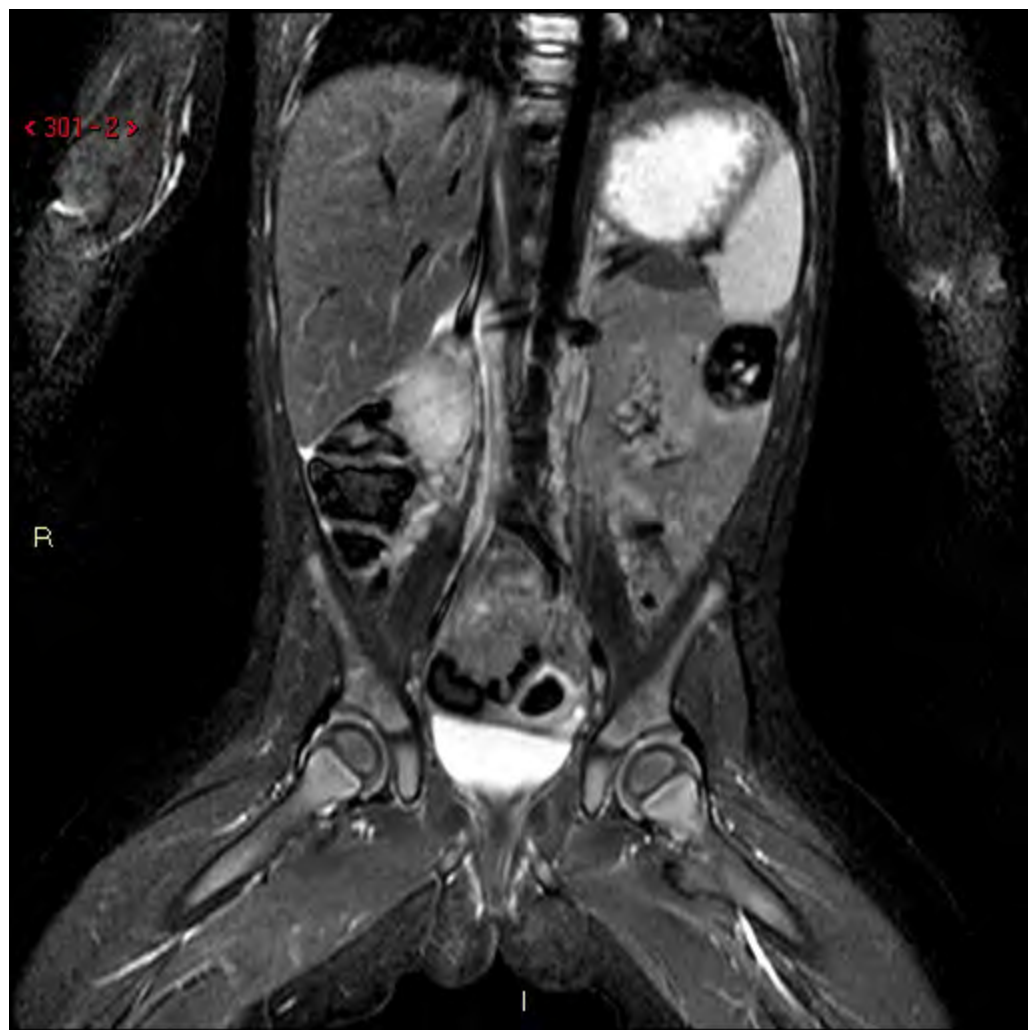< 201-11 >

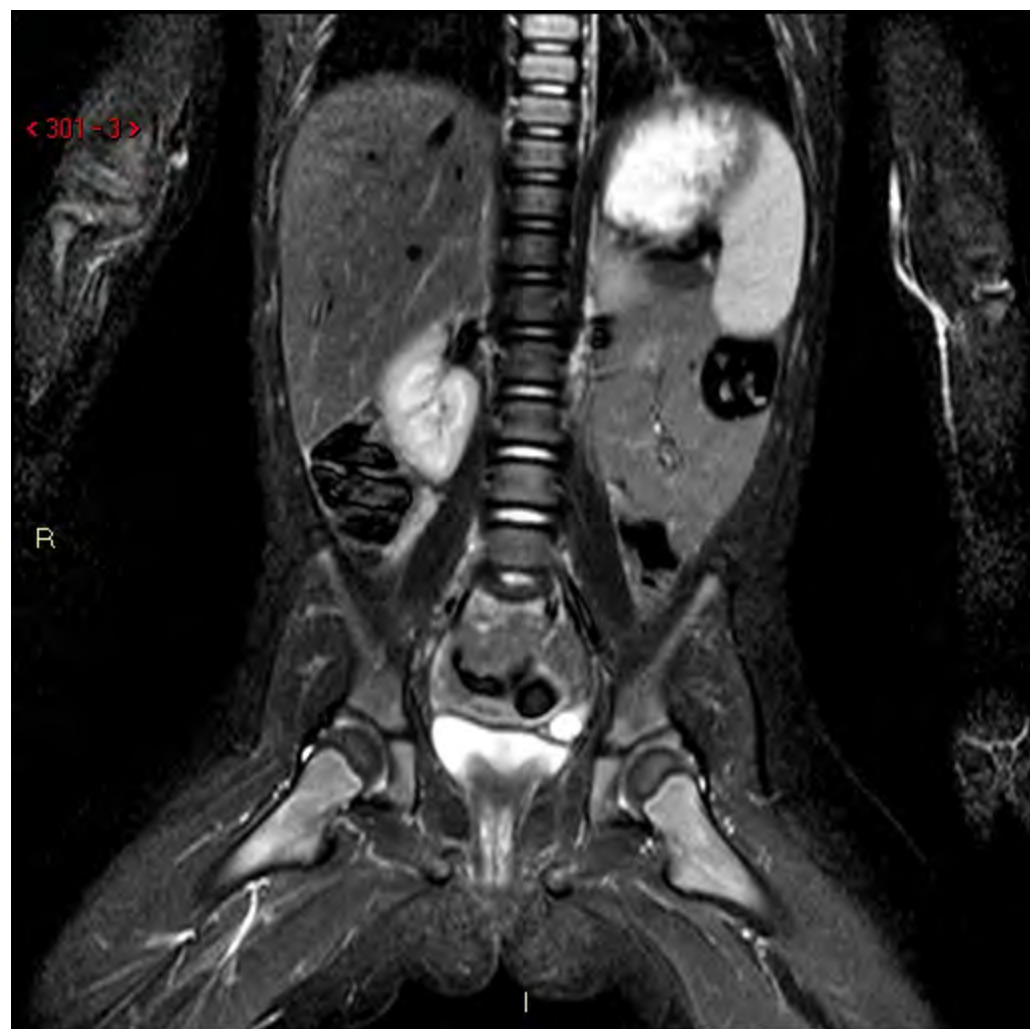
R

I

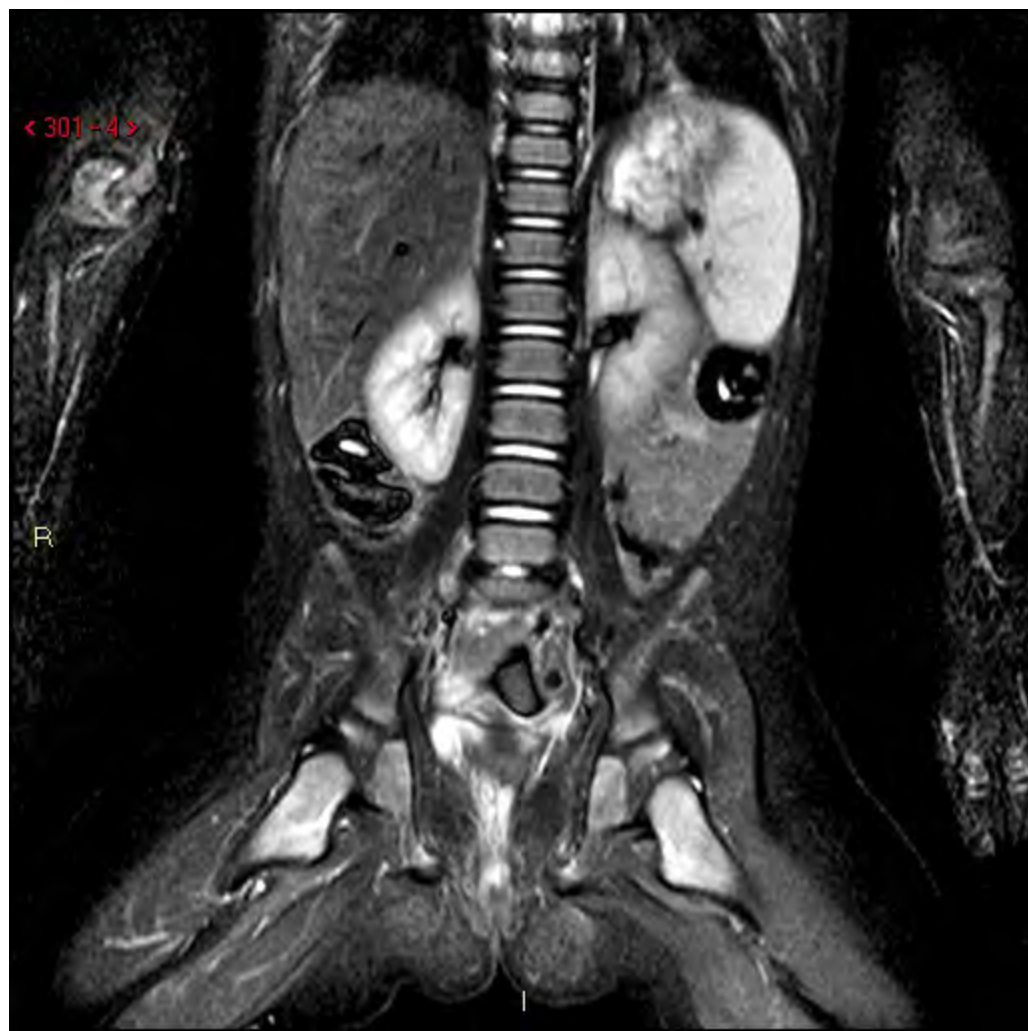


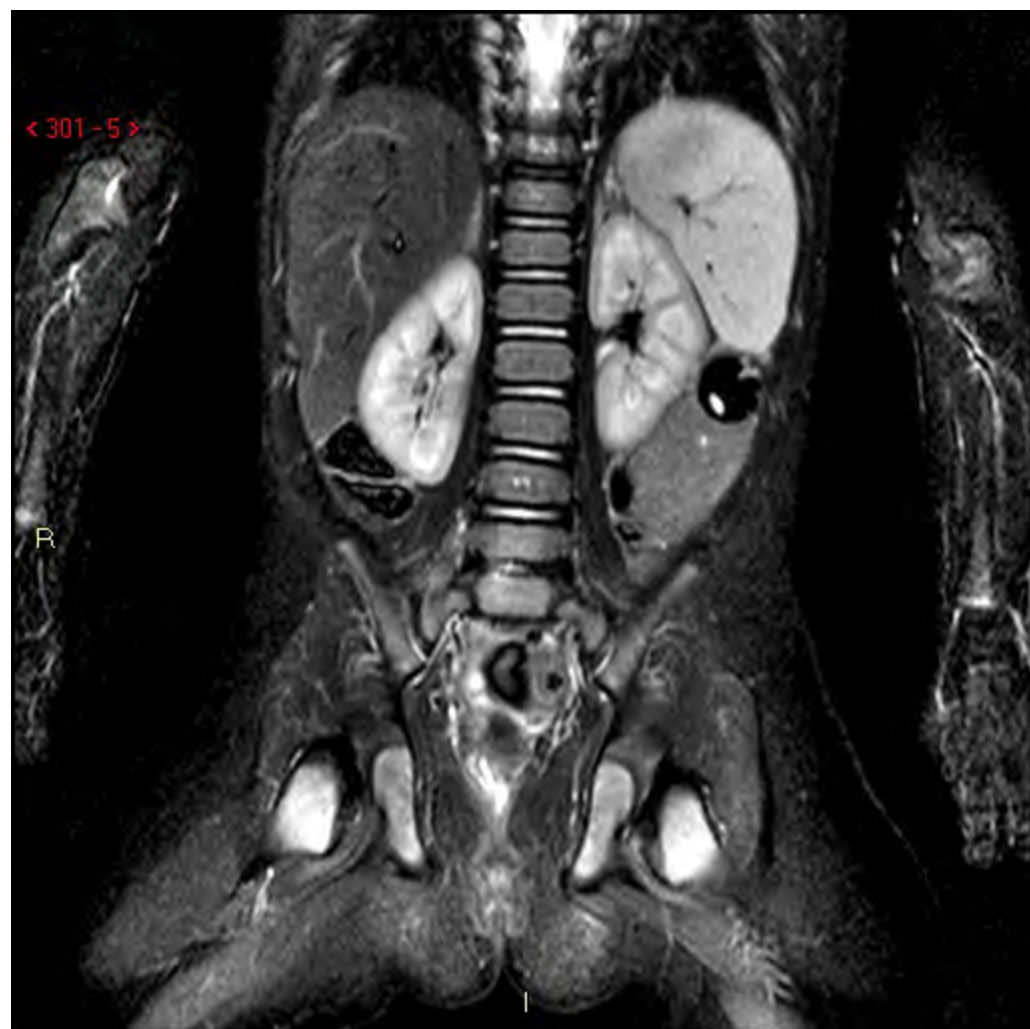


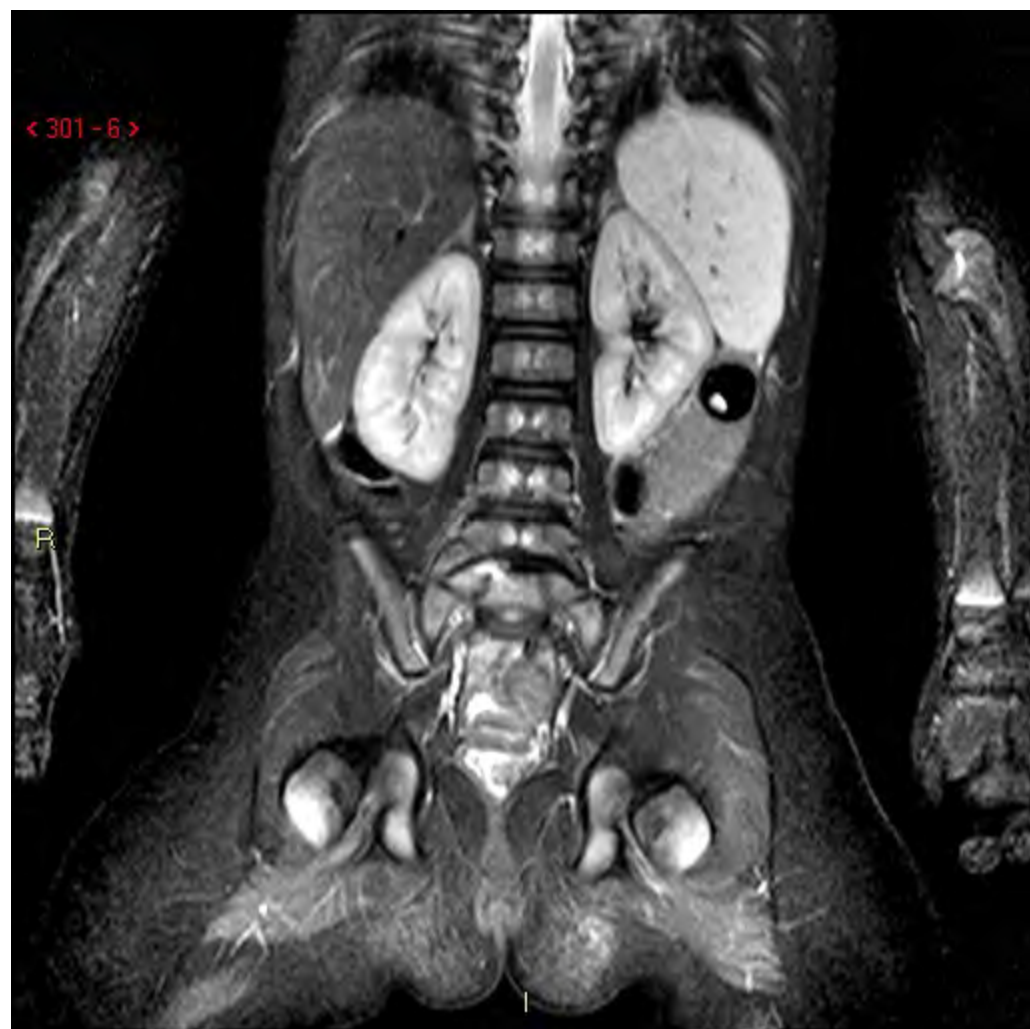


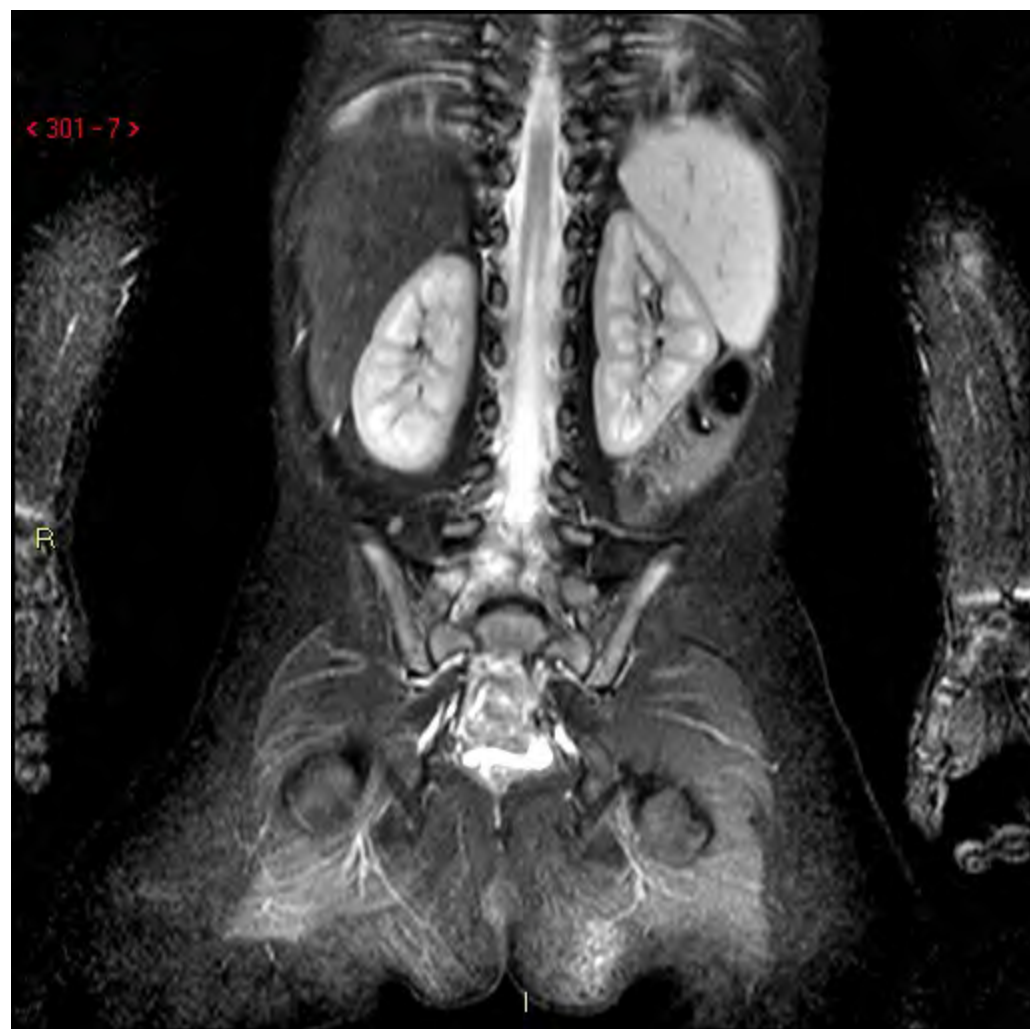
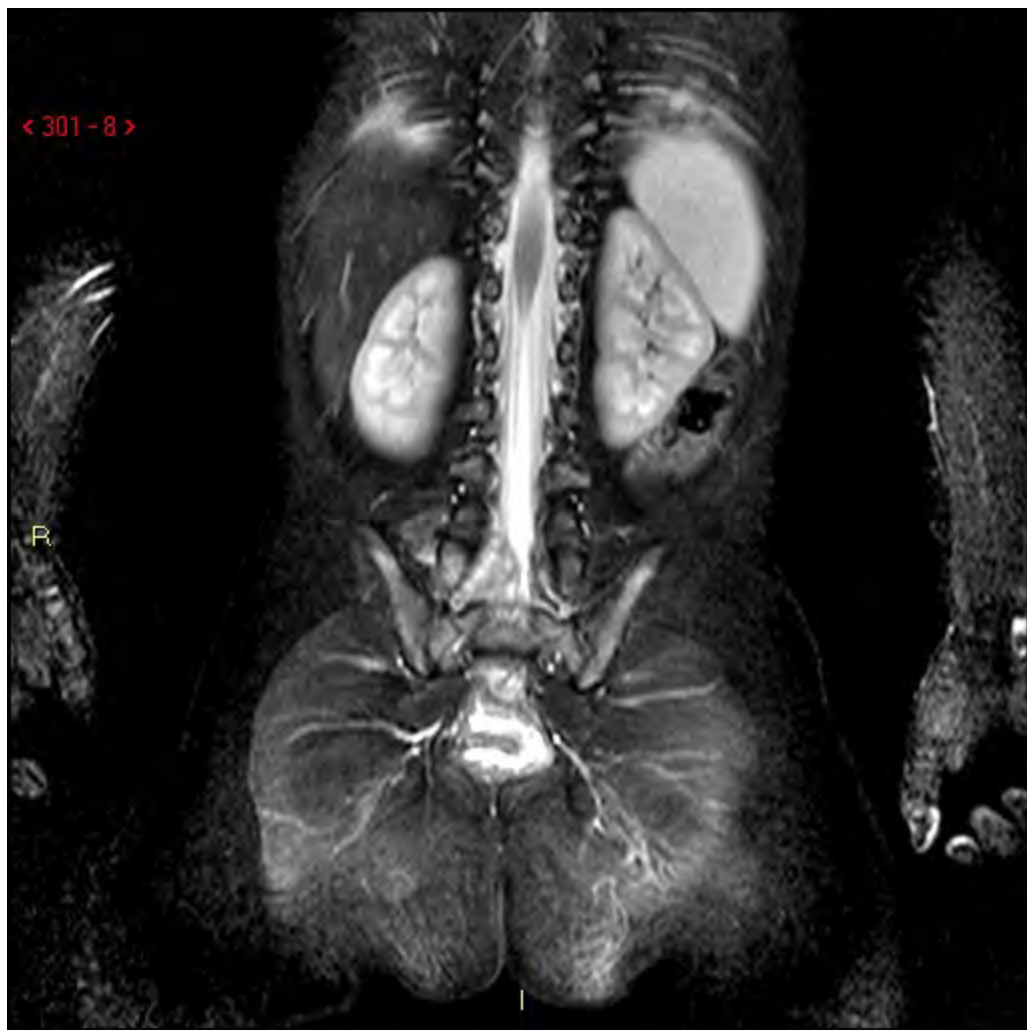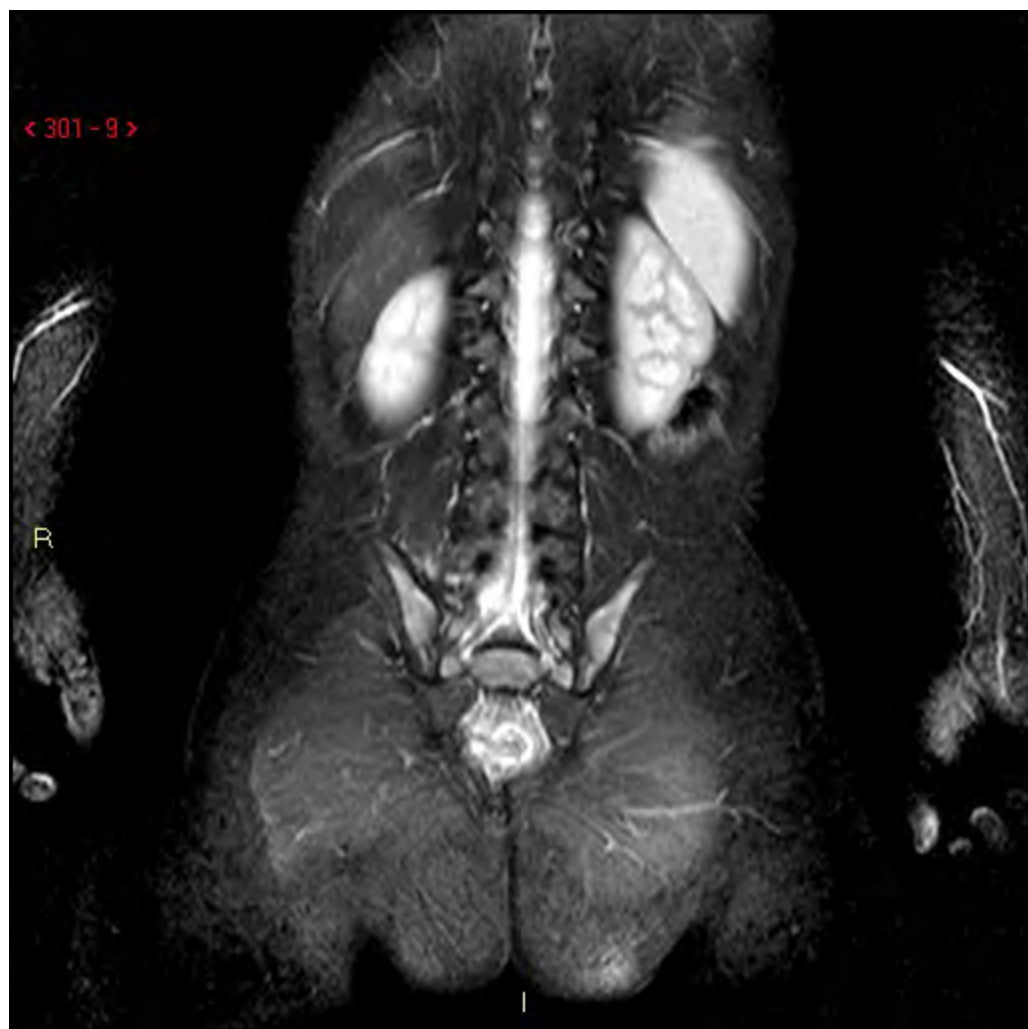









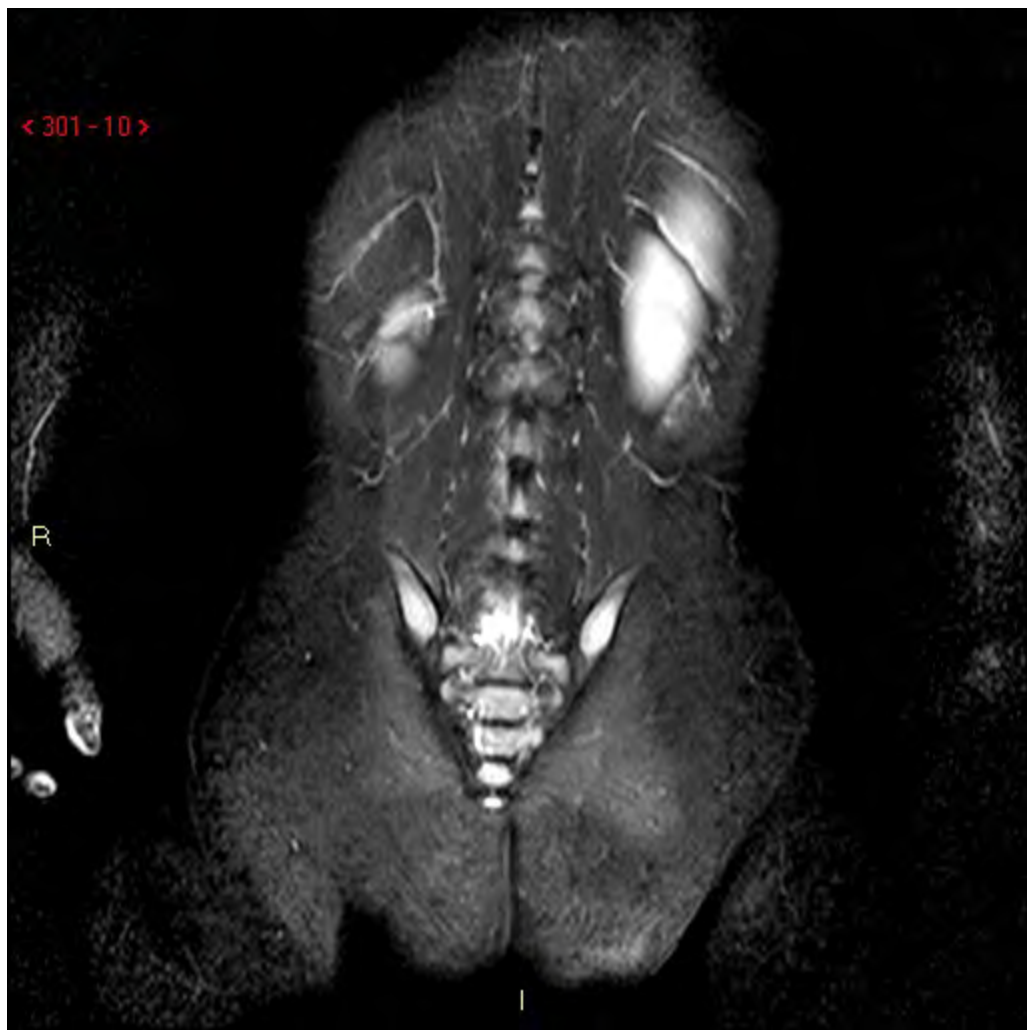


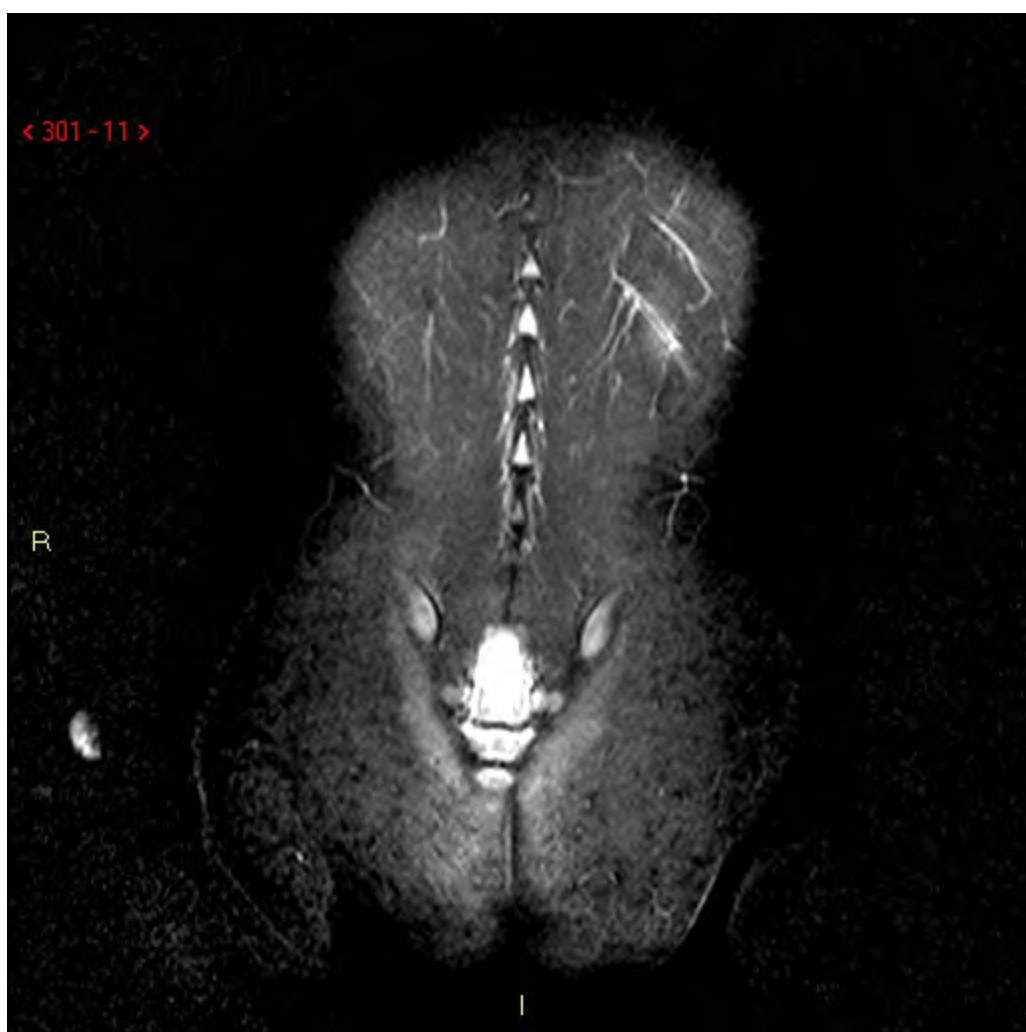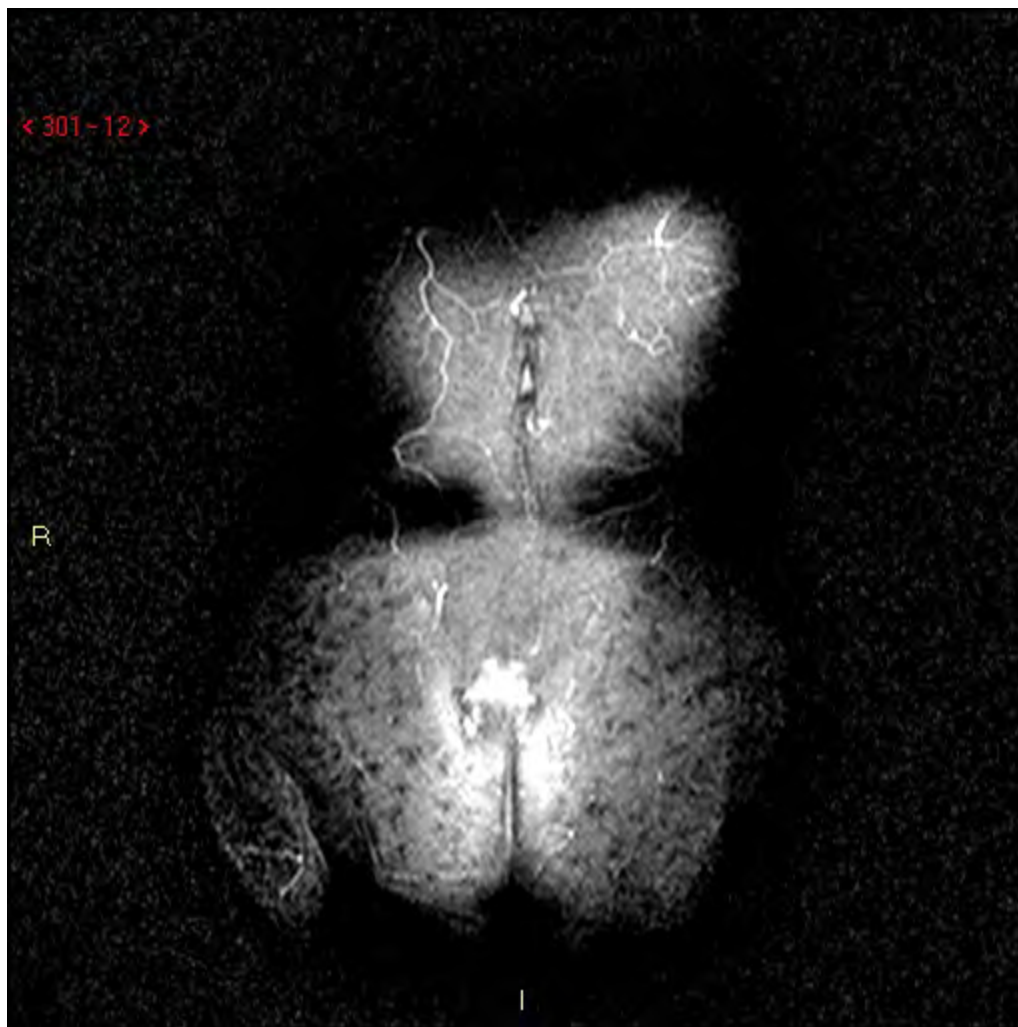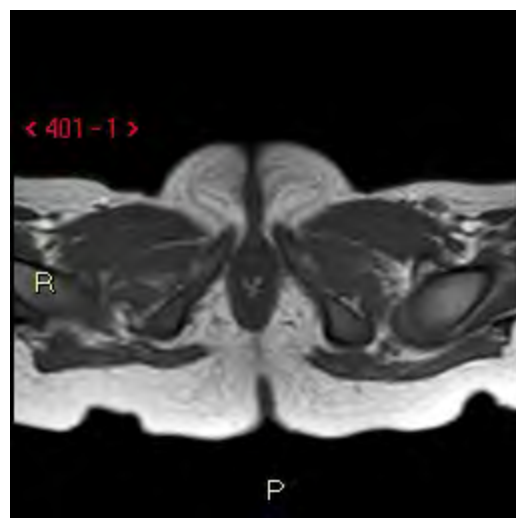


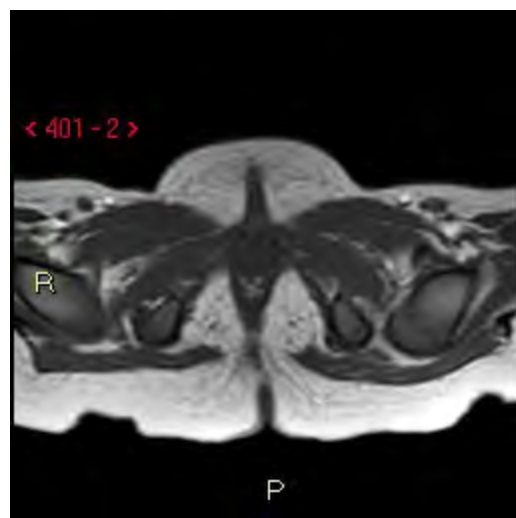


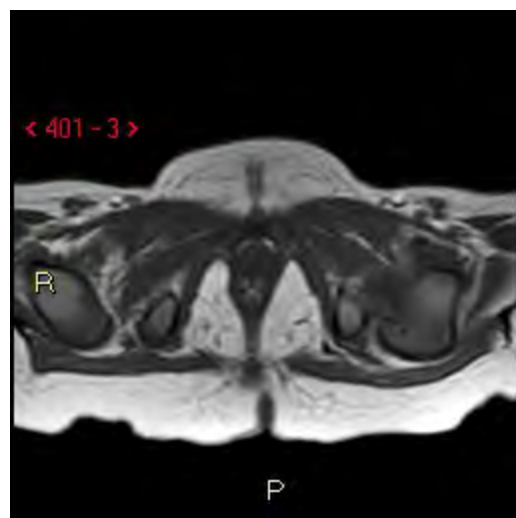


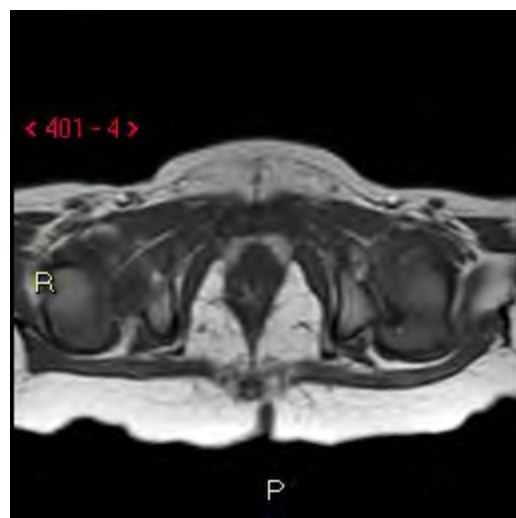


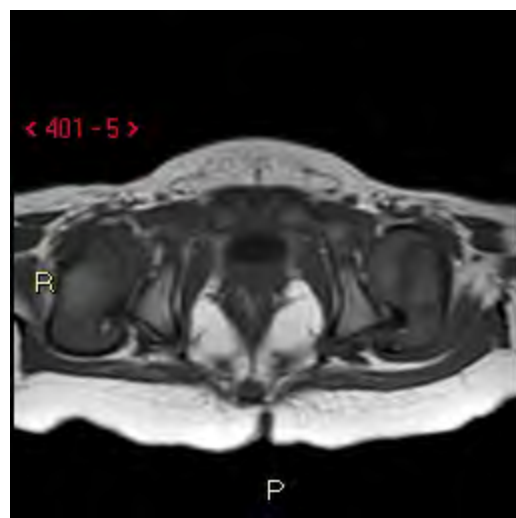


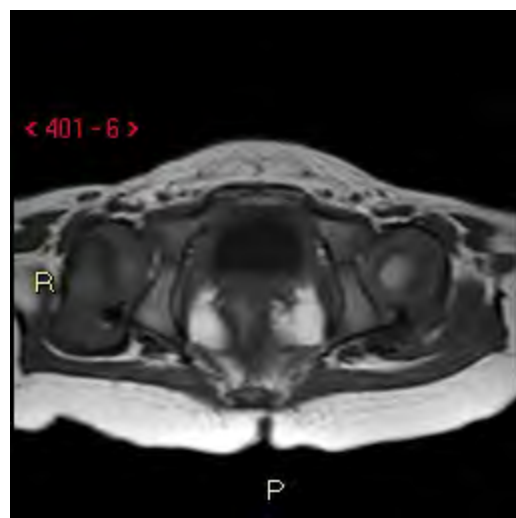


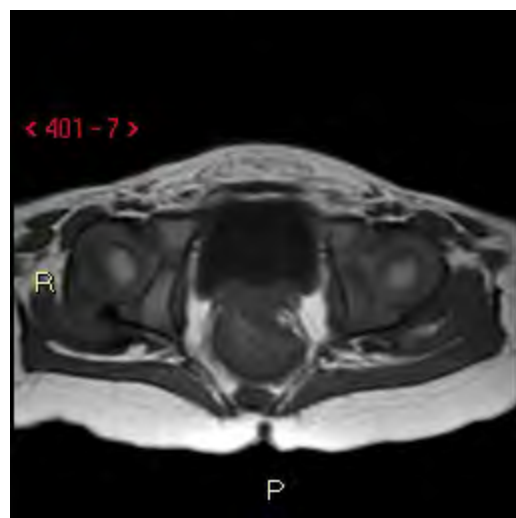




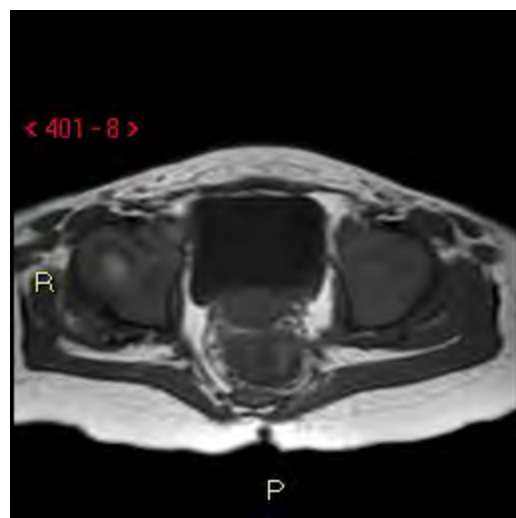


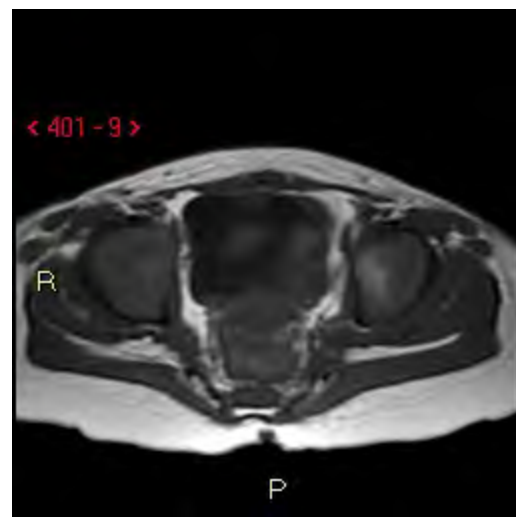


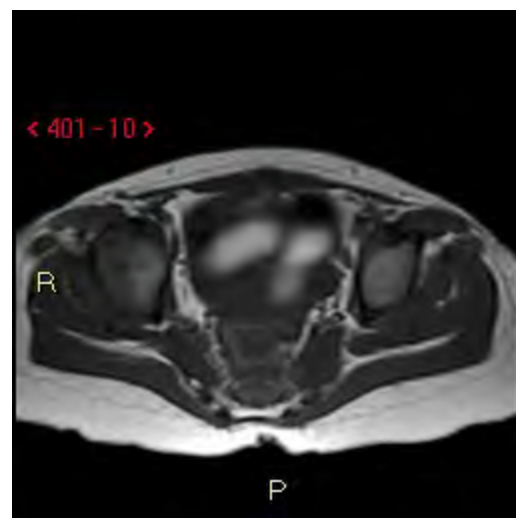


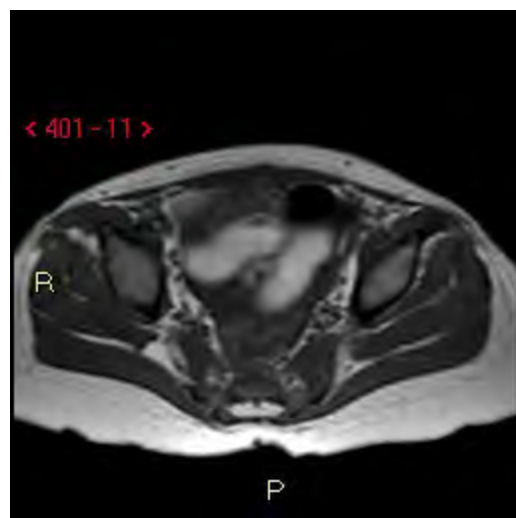


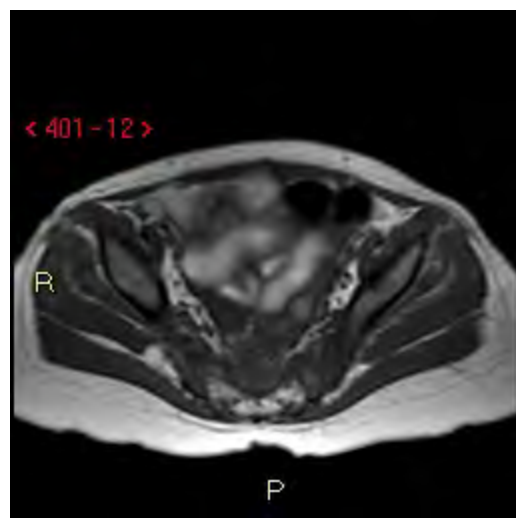


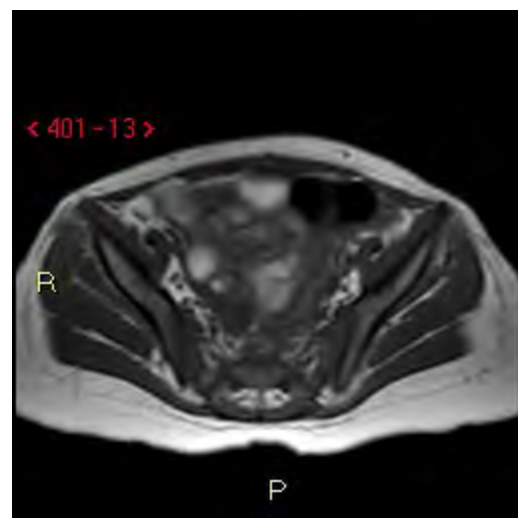


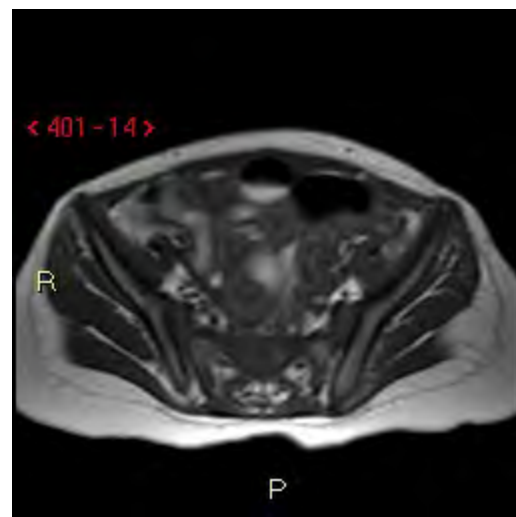


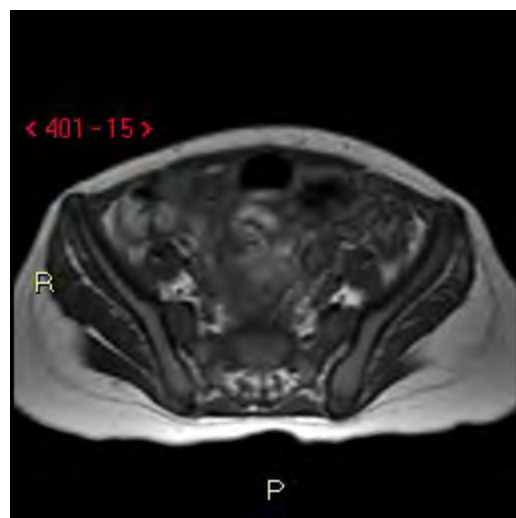




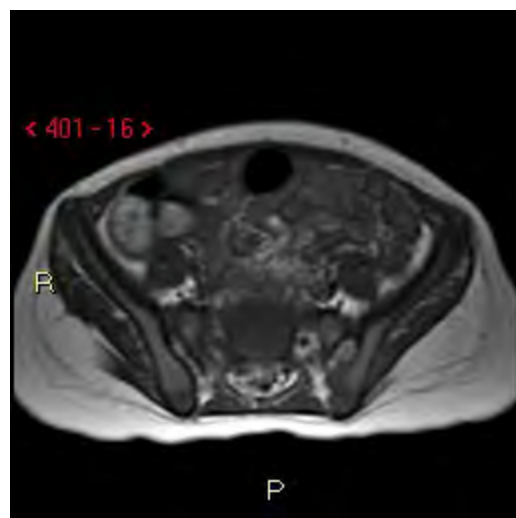


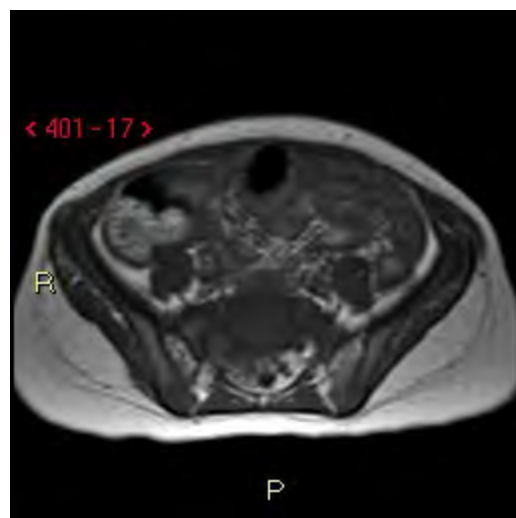


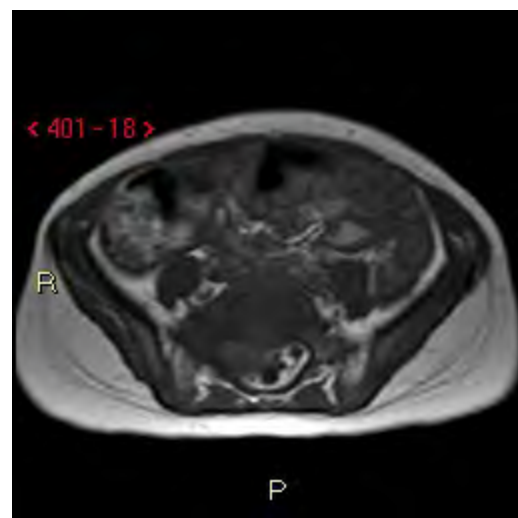


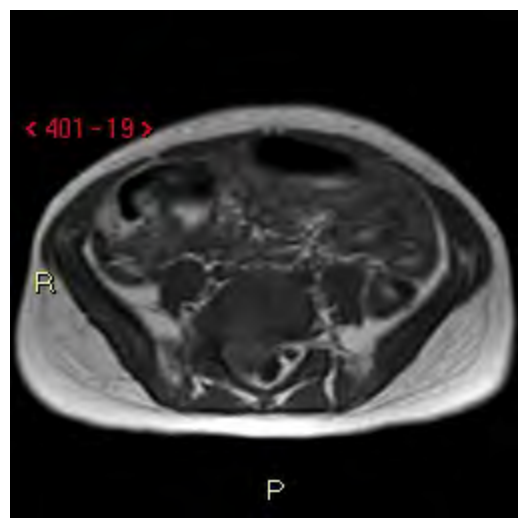


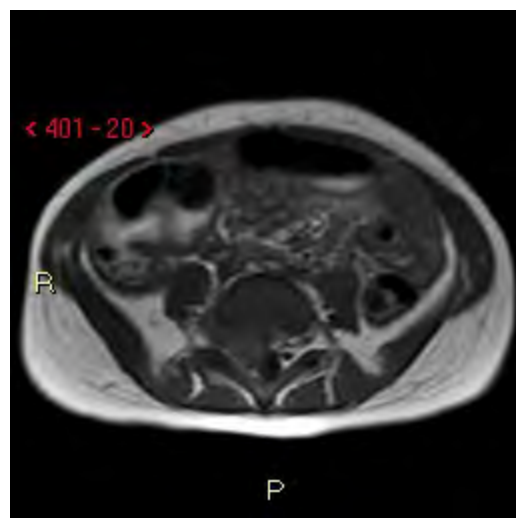


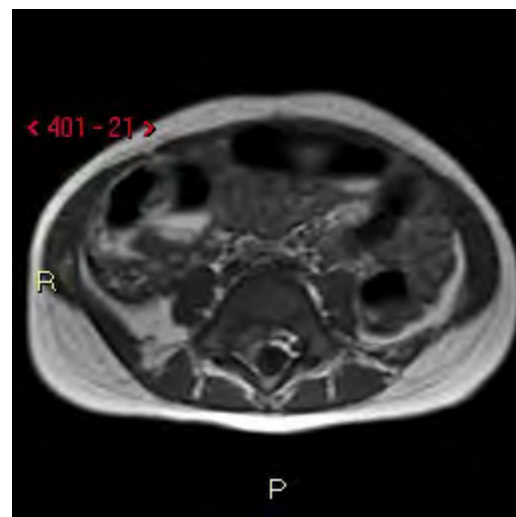


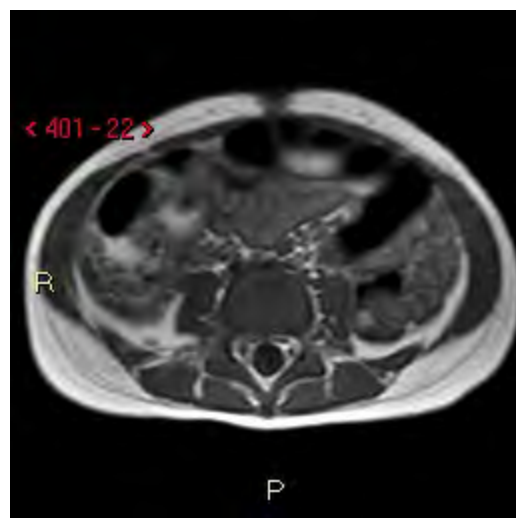


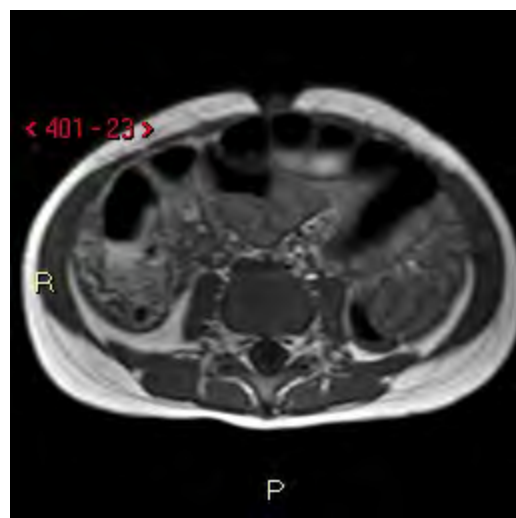




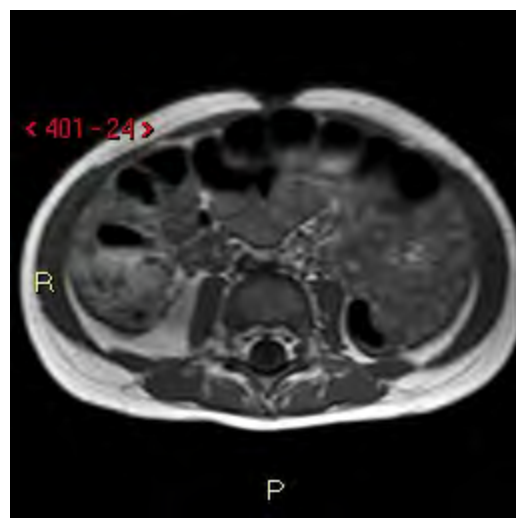


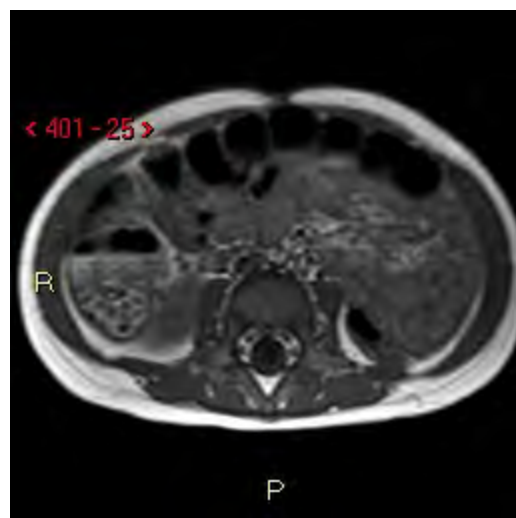


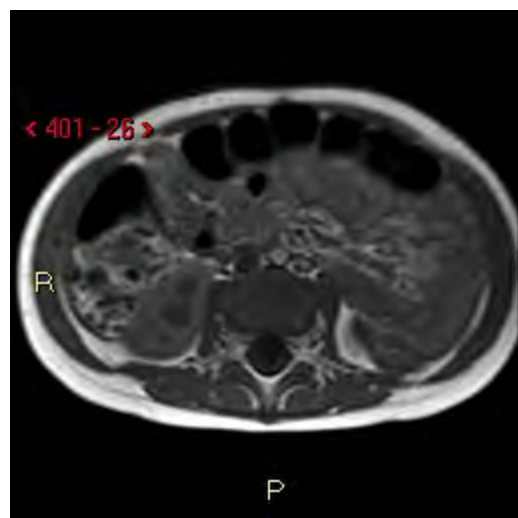


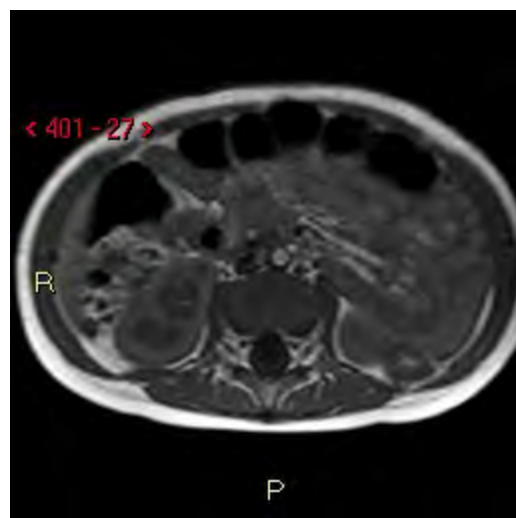


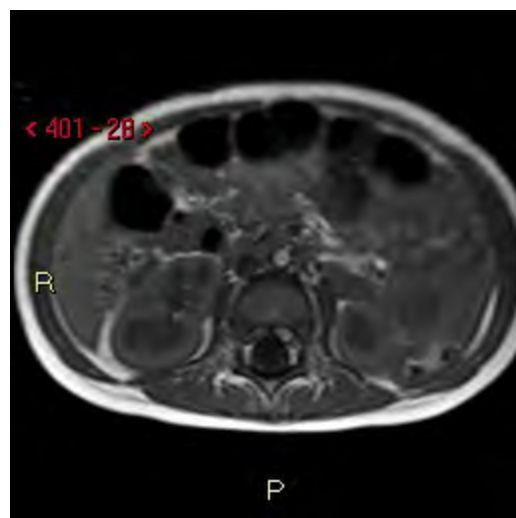


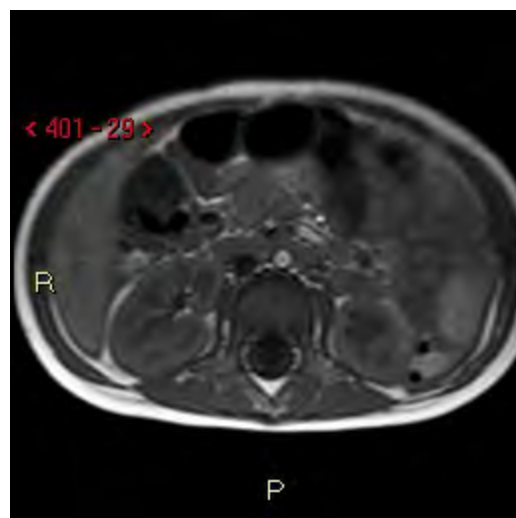


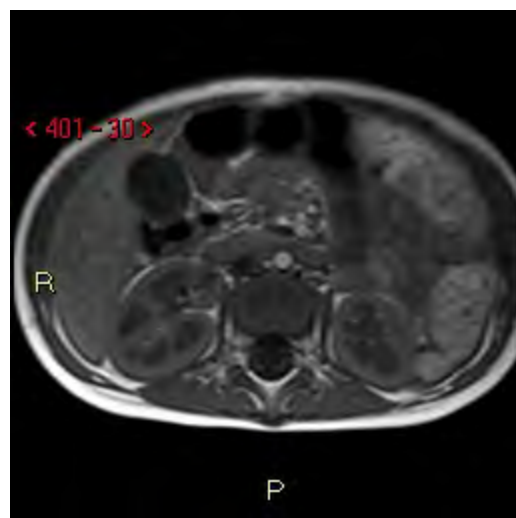


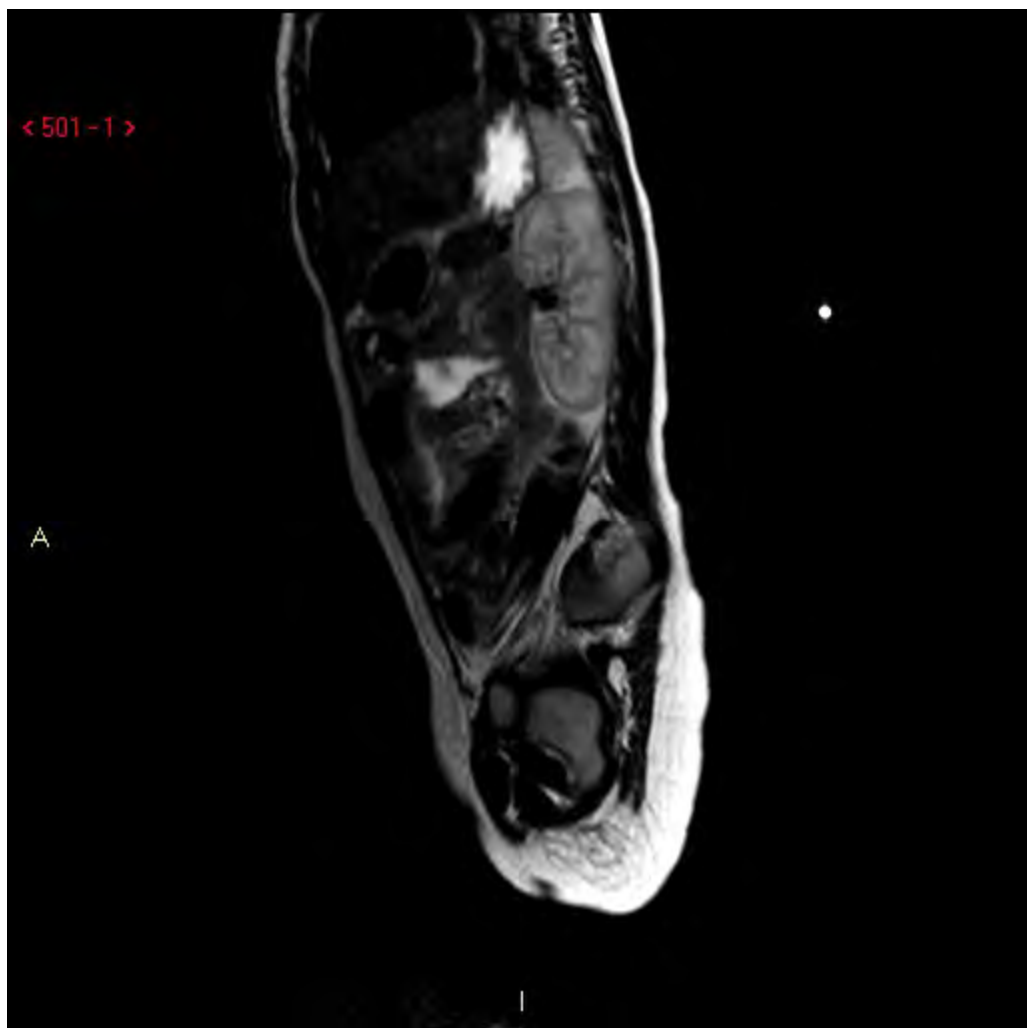




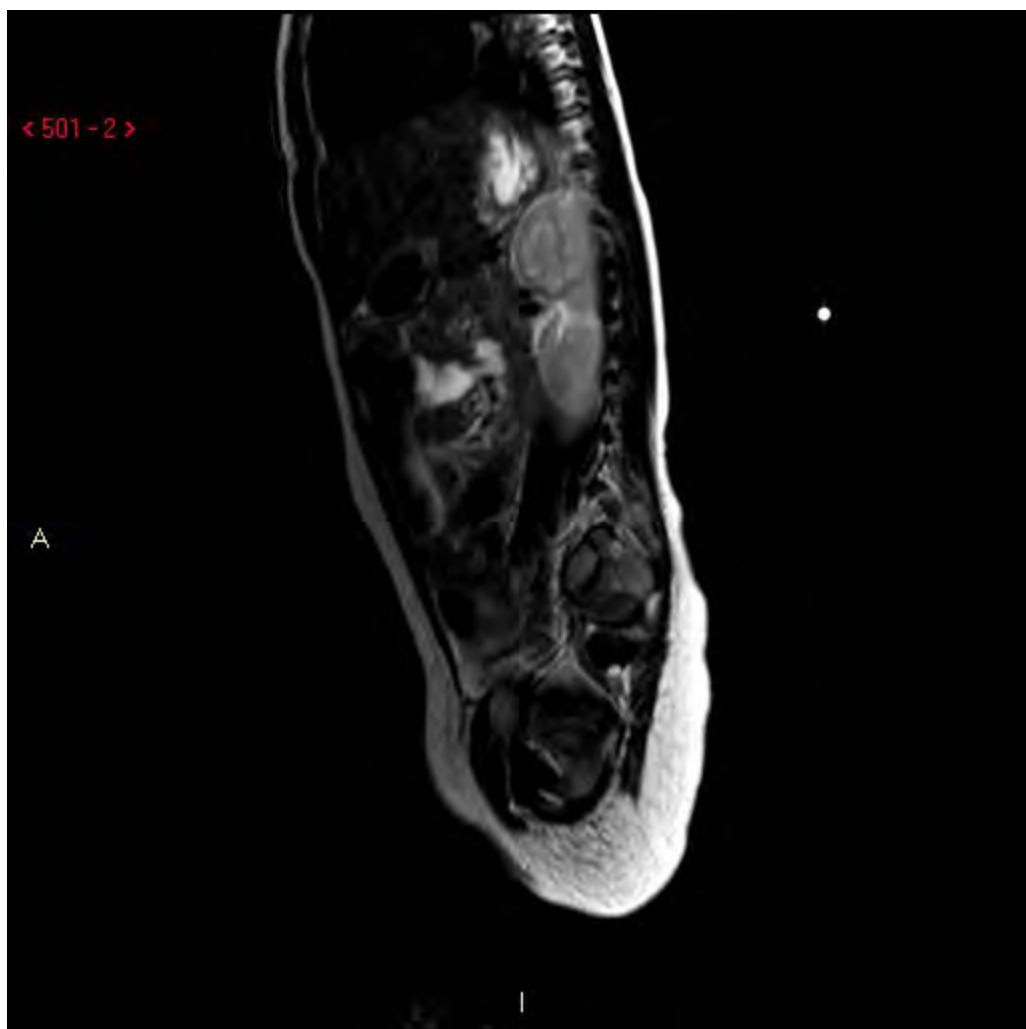


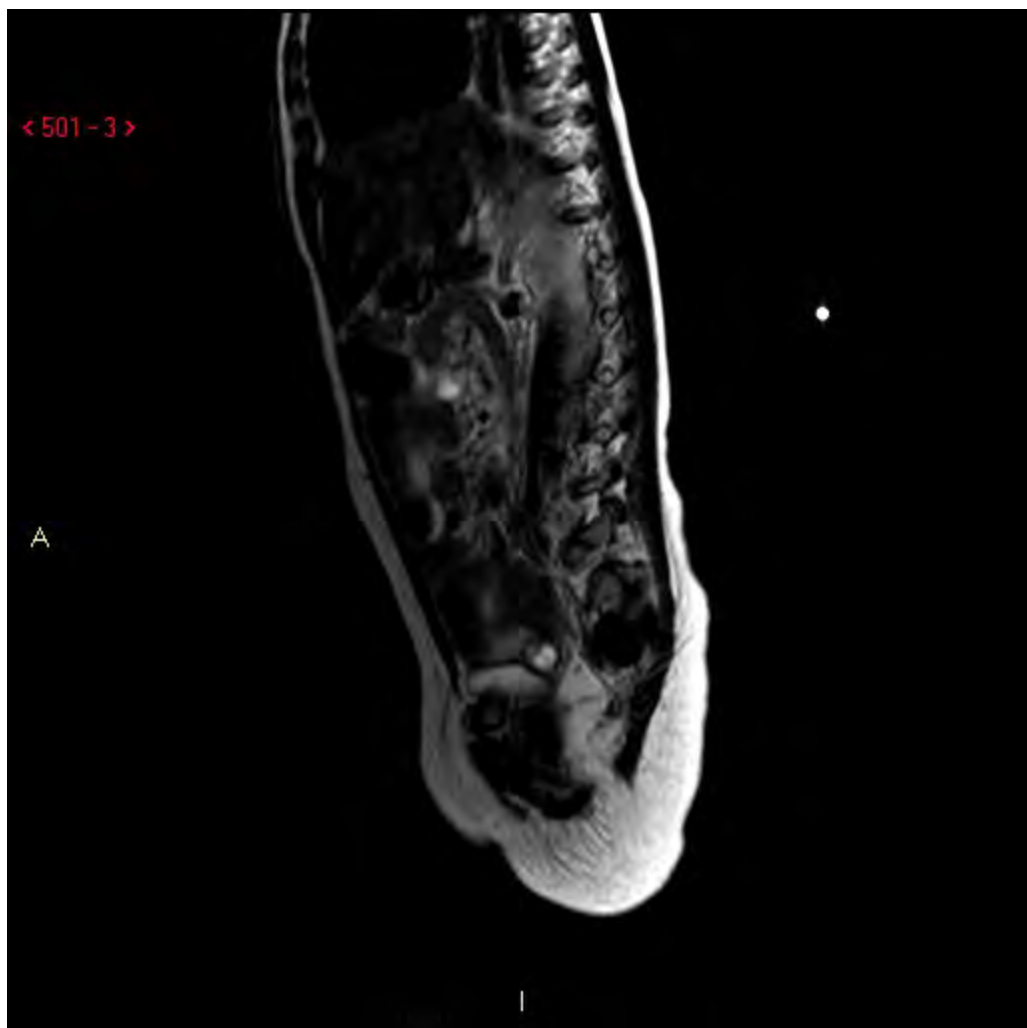










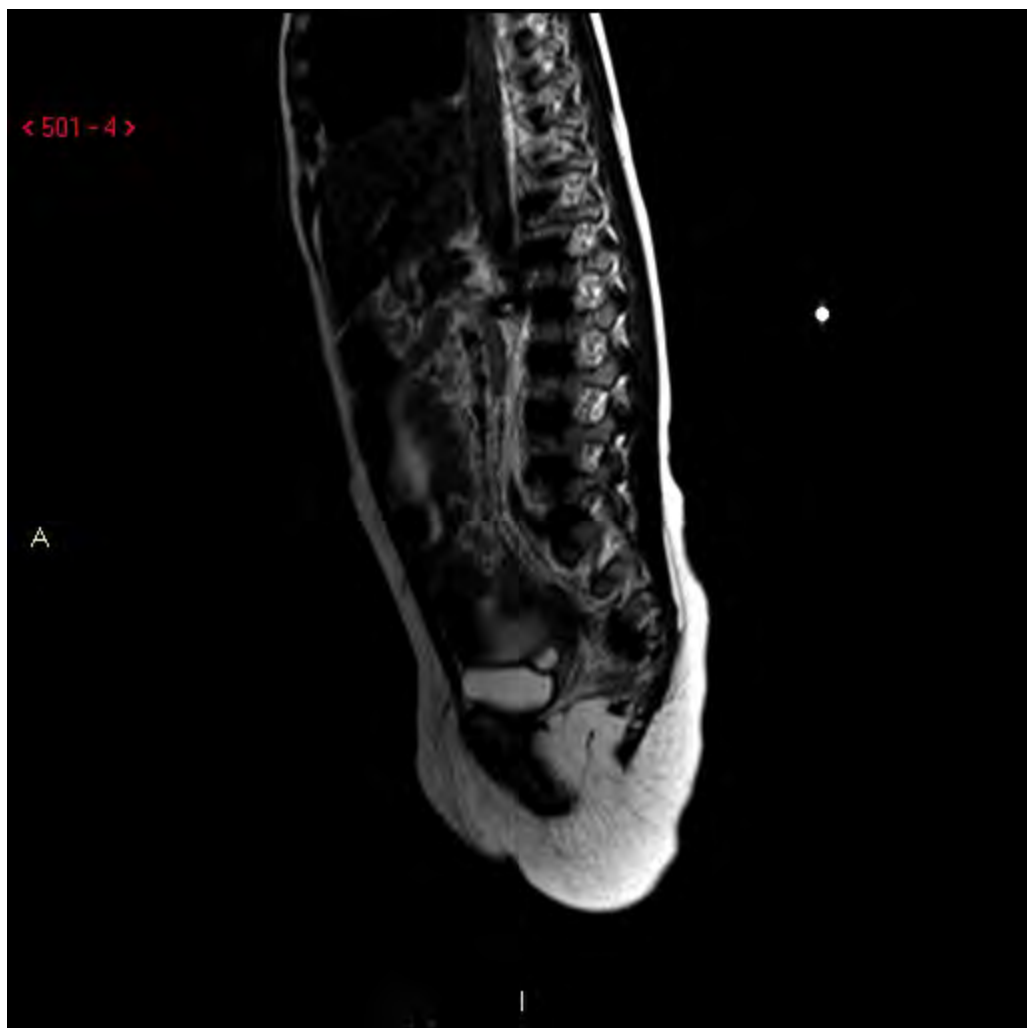

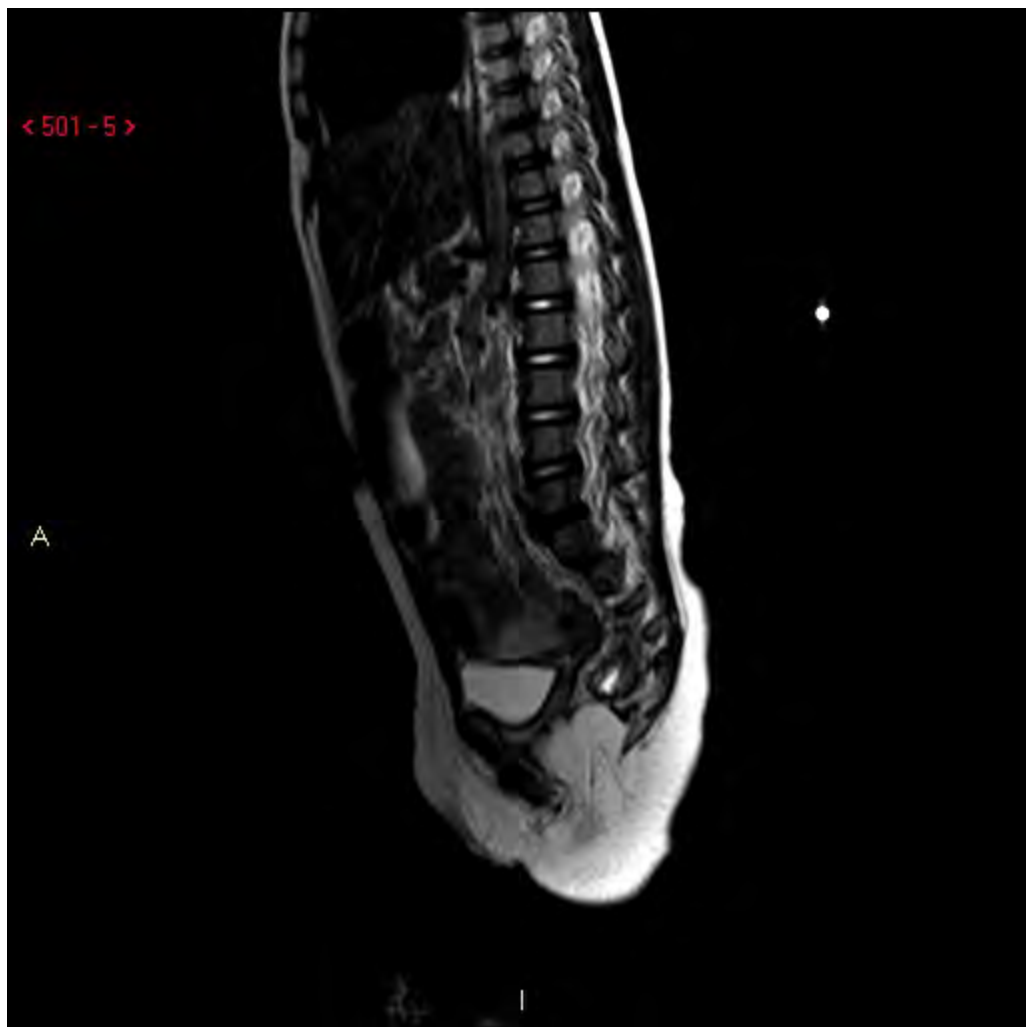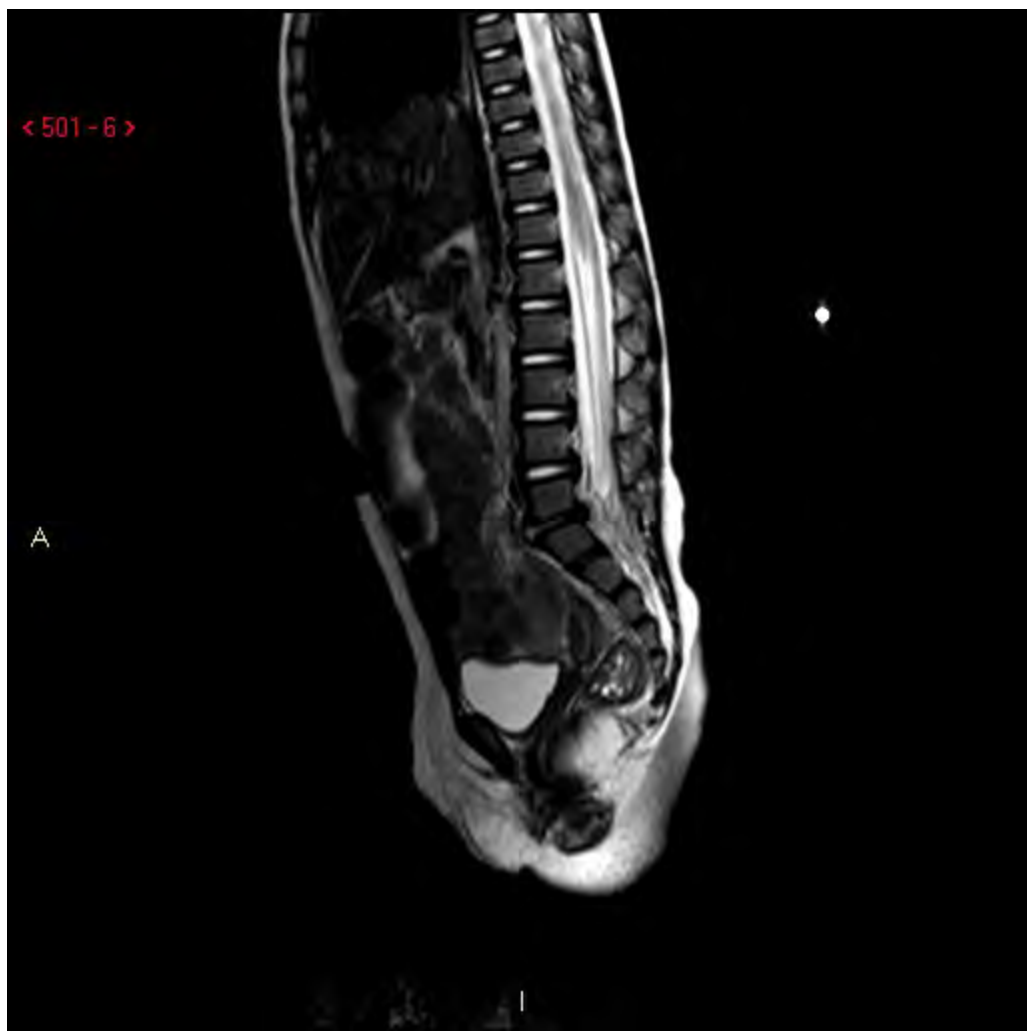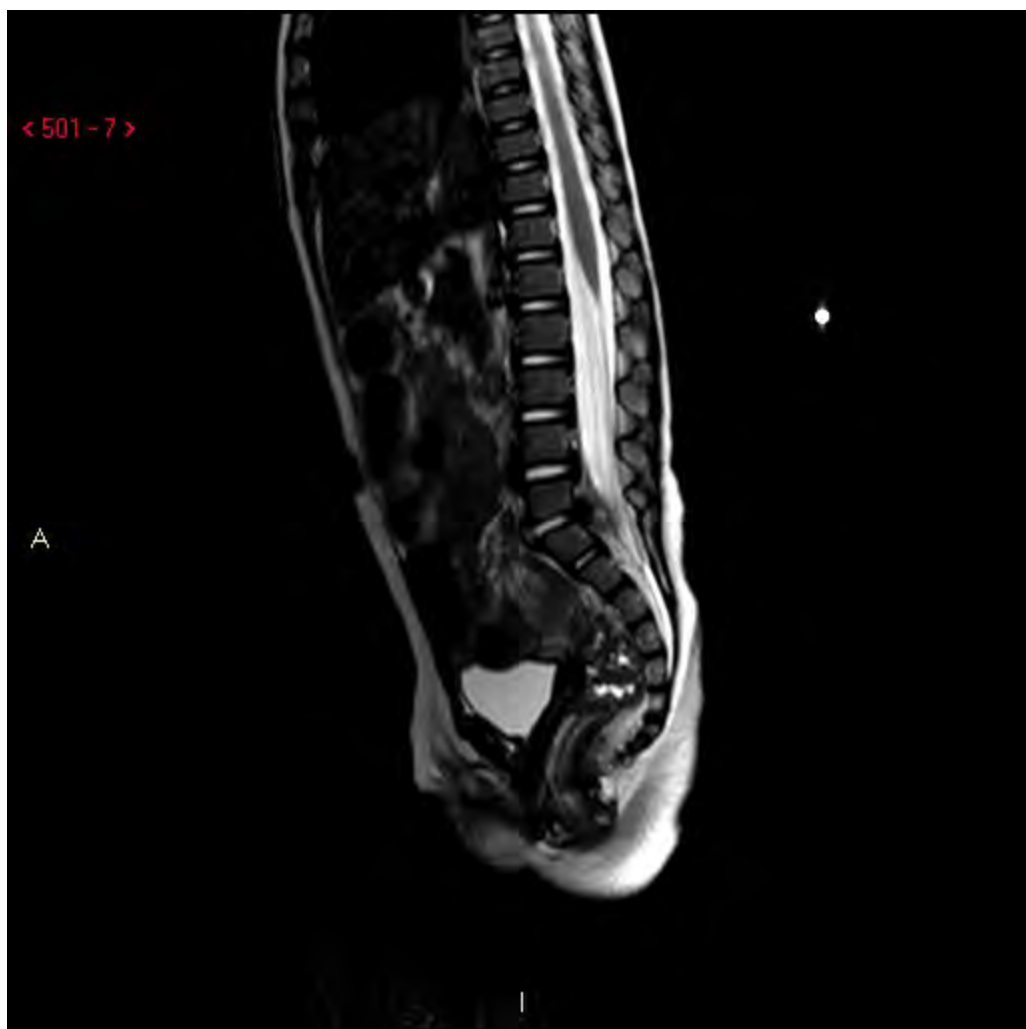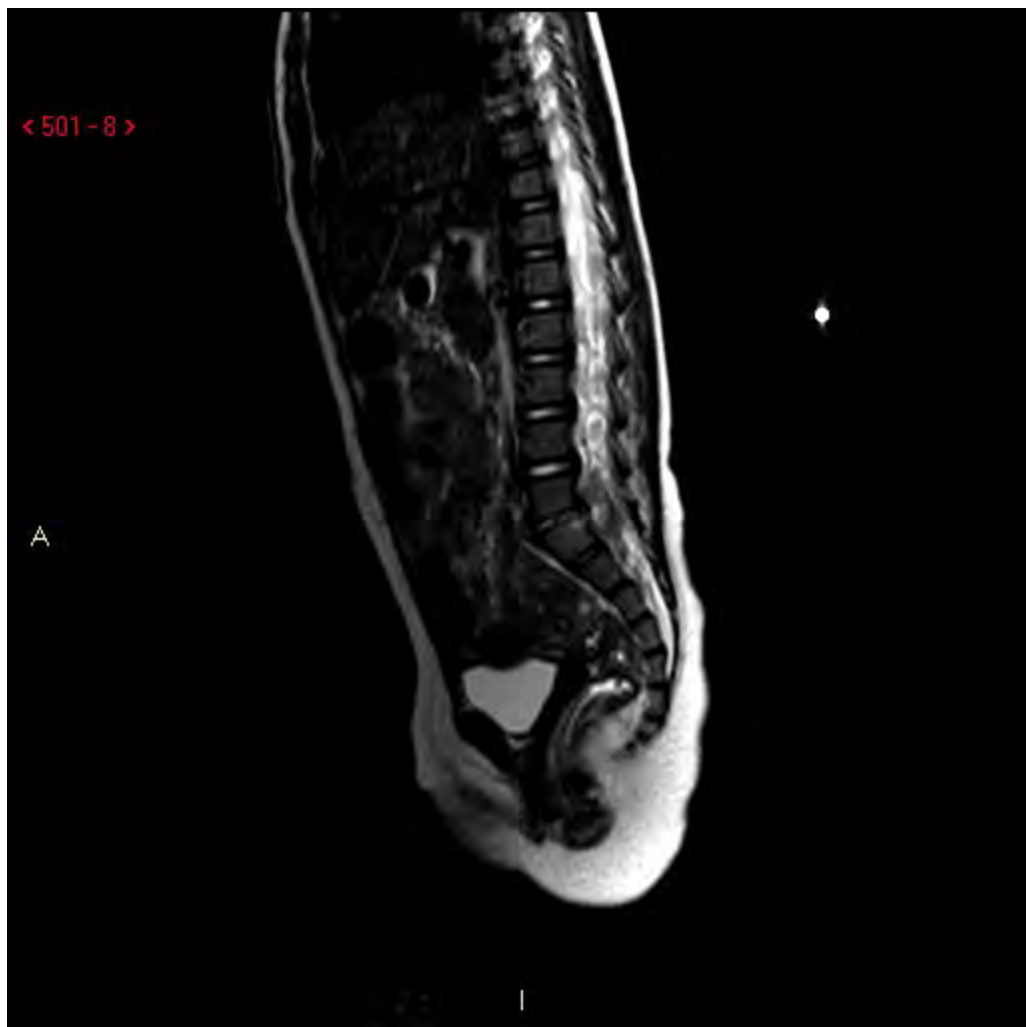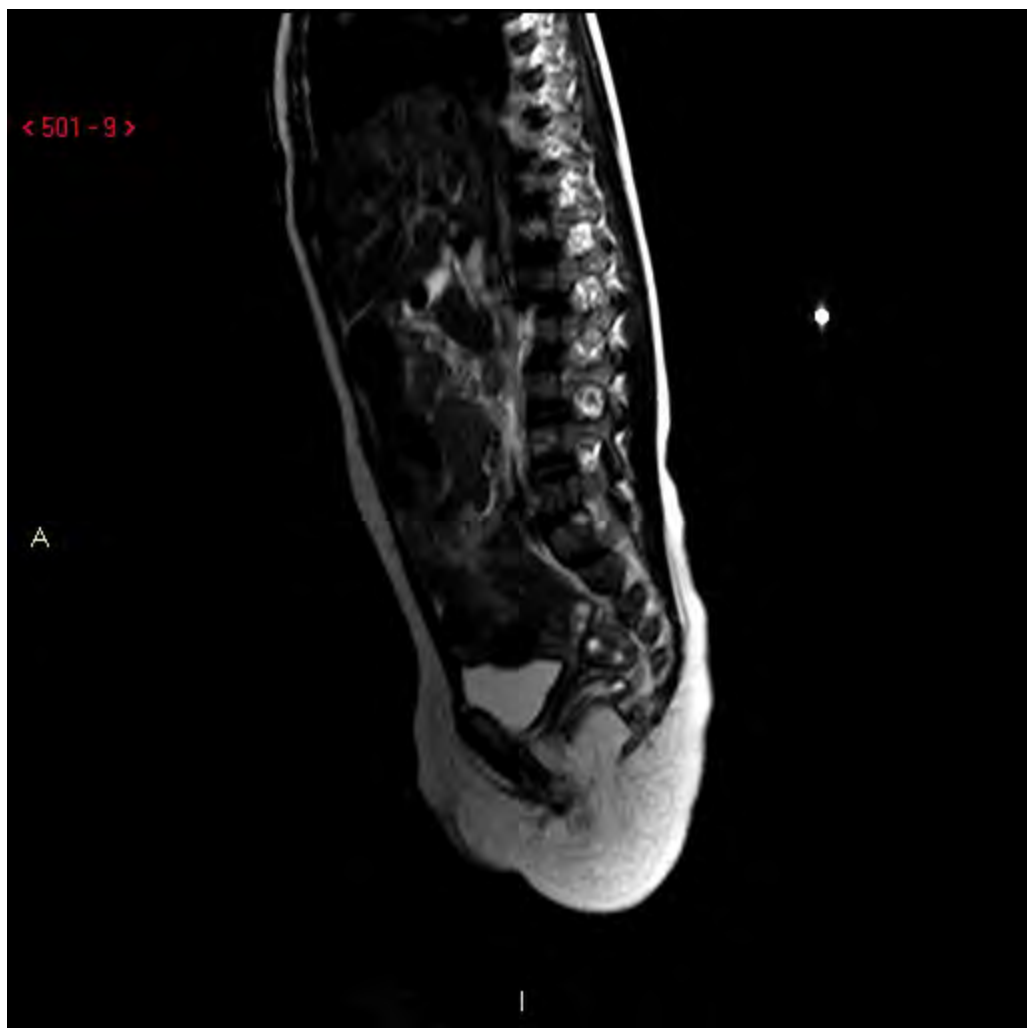






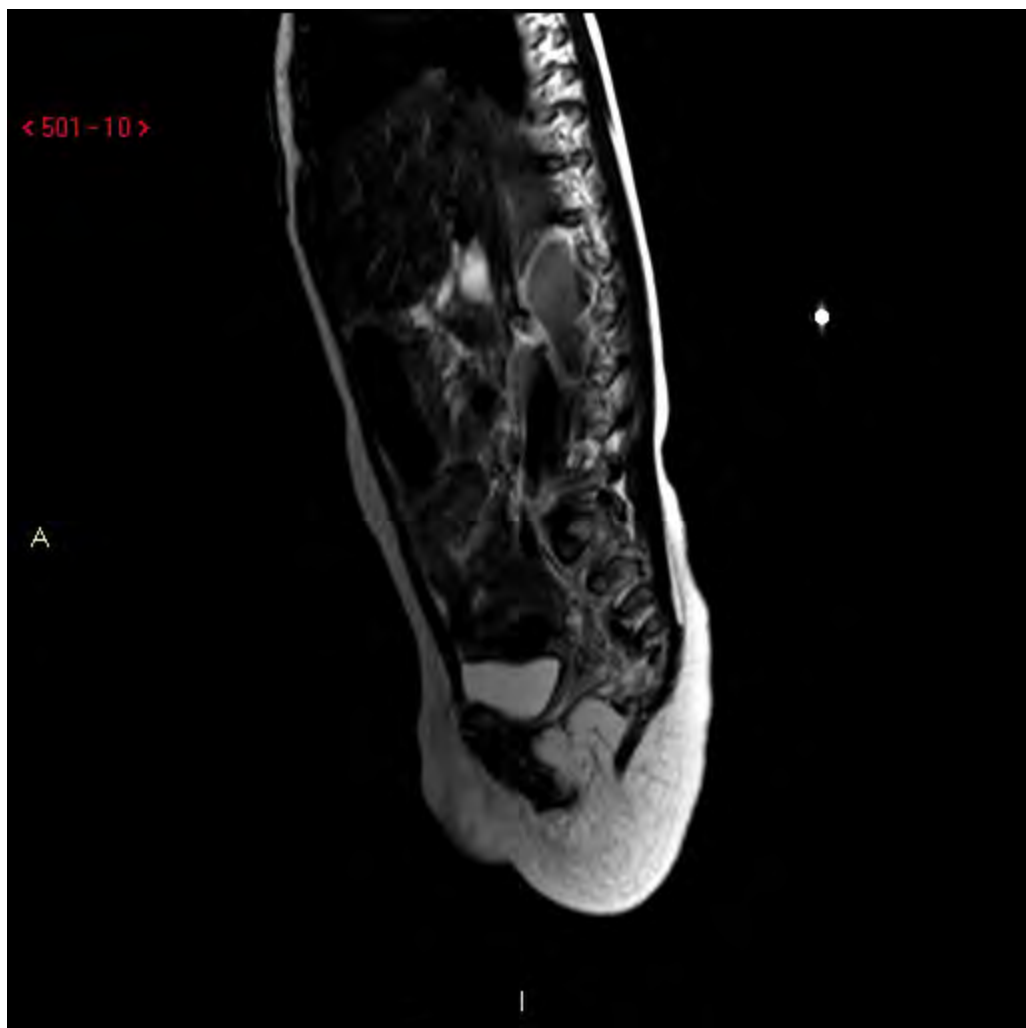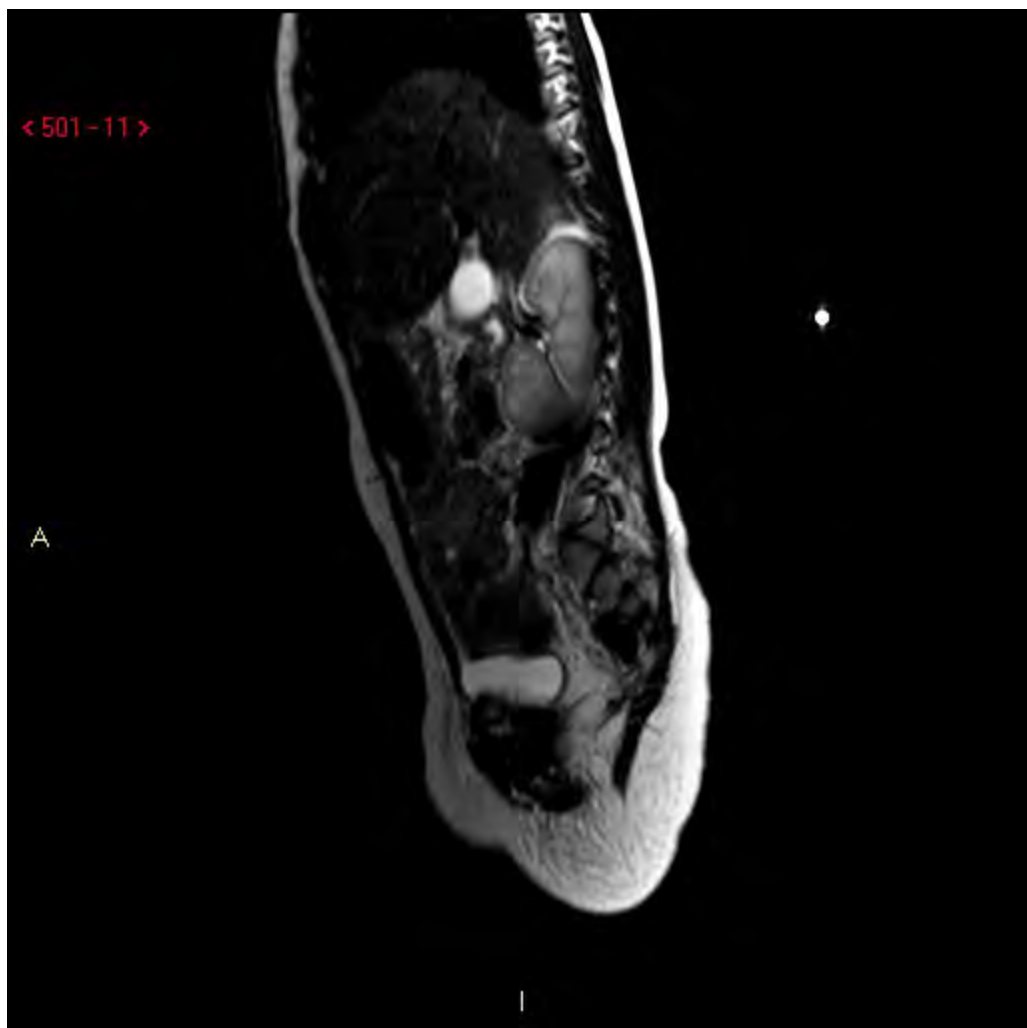


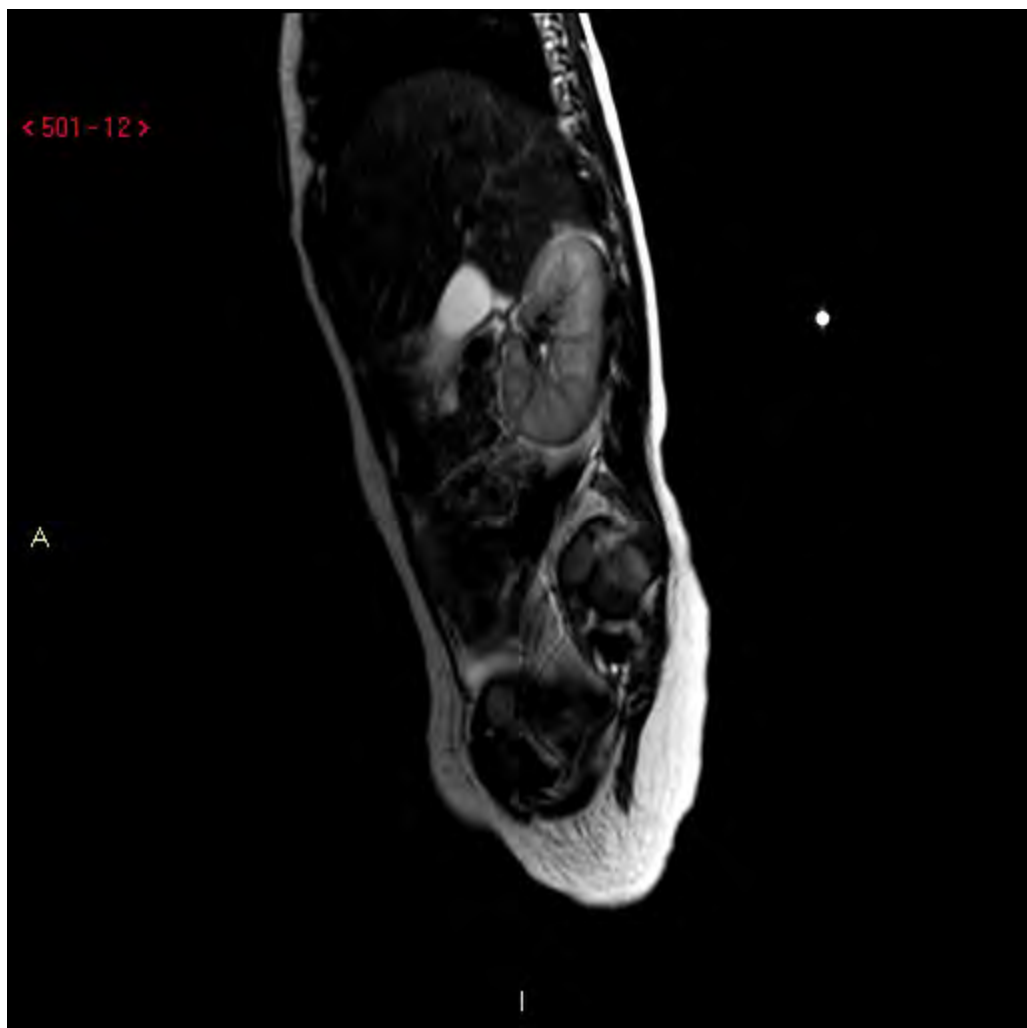


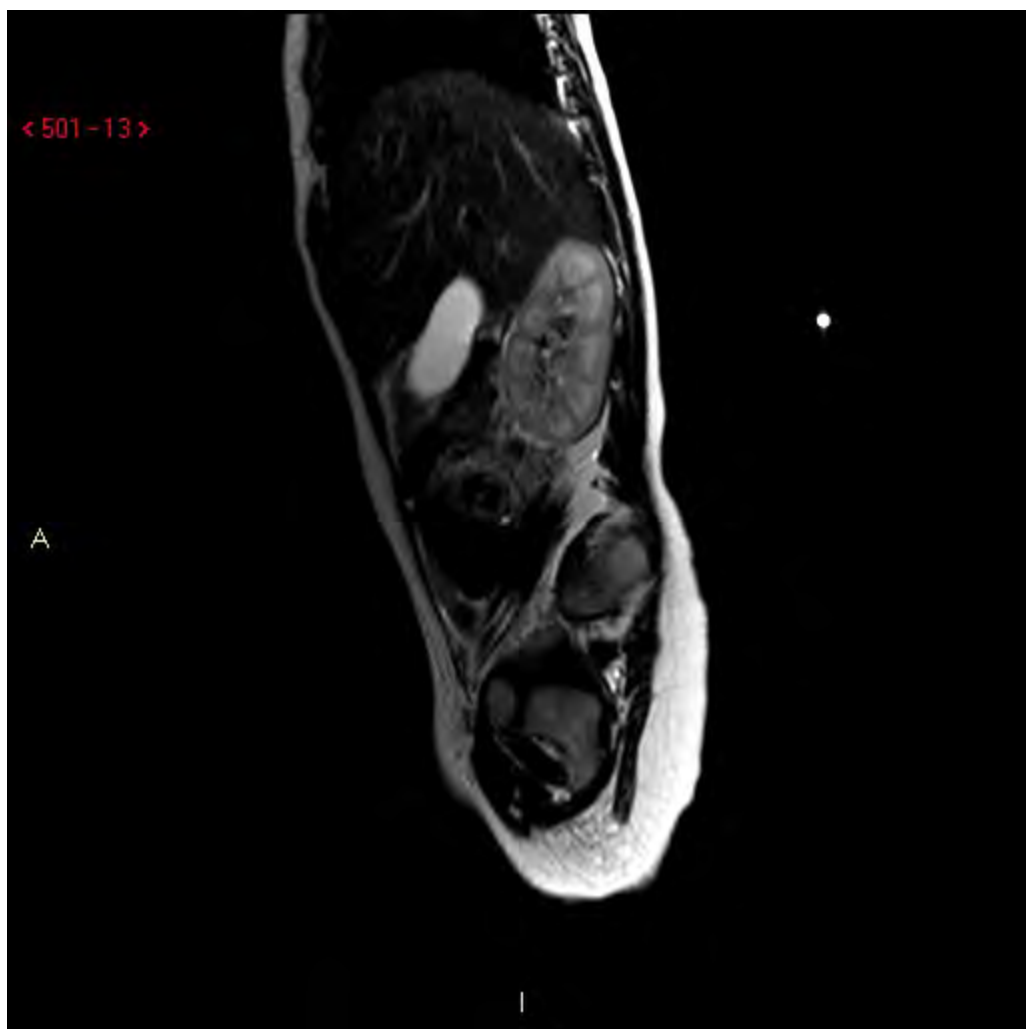
















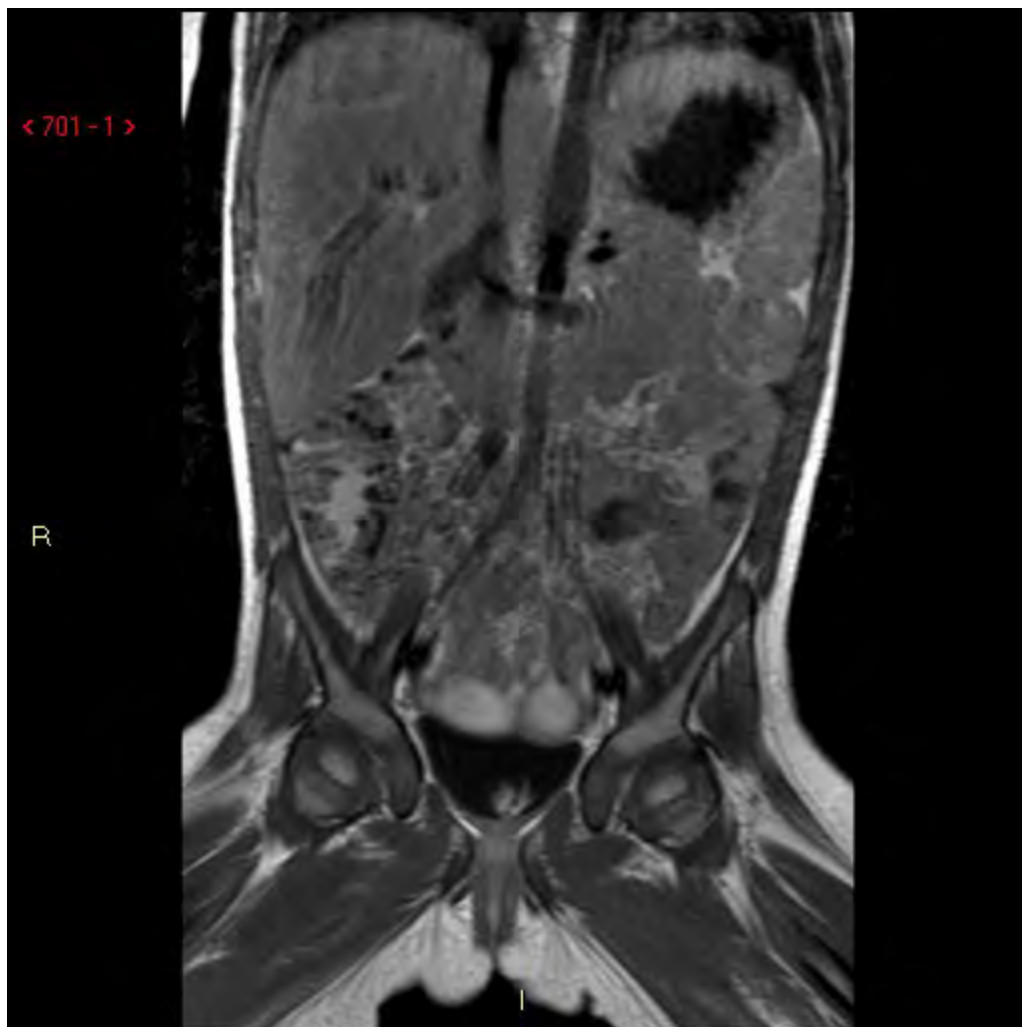


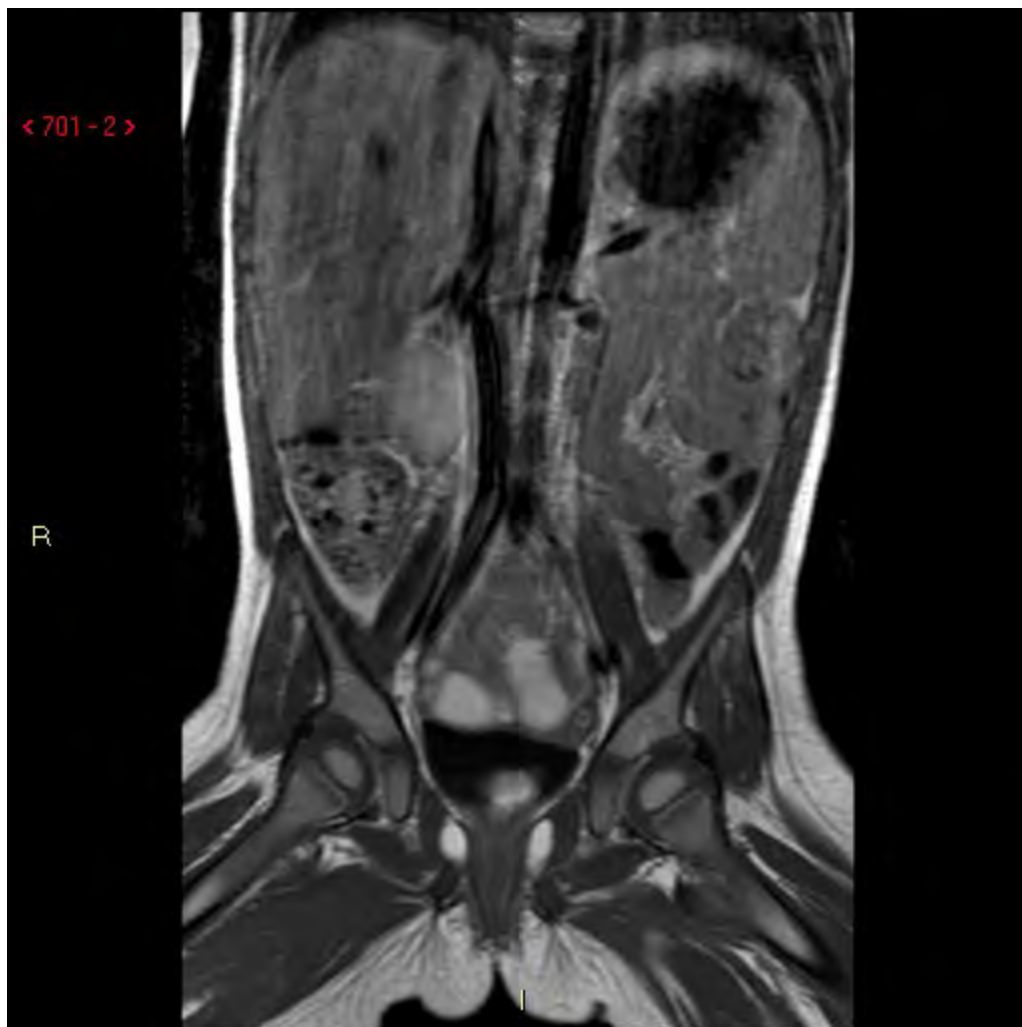


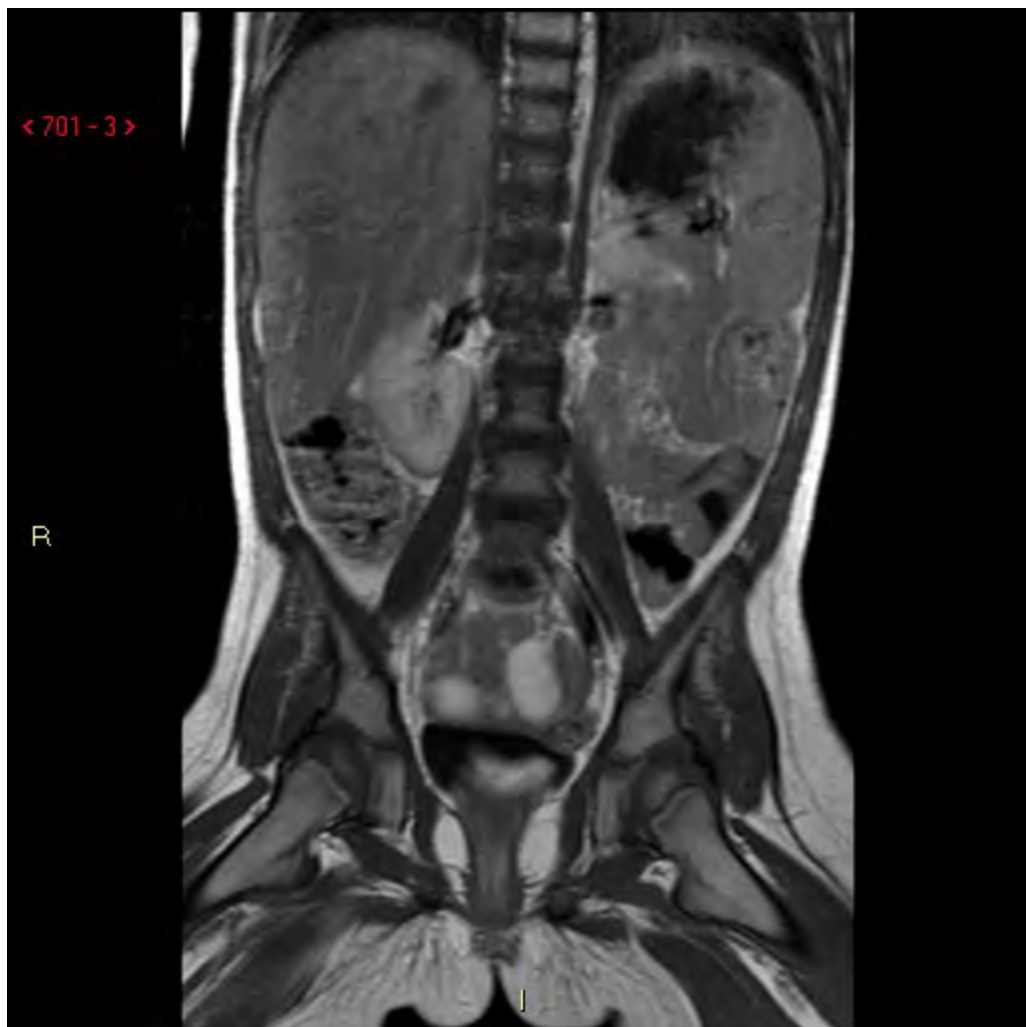


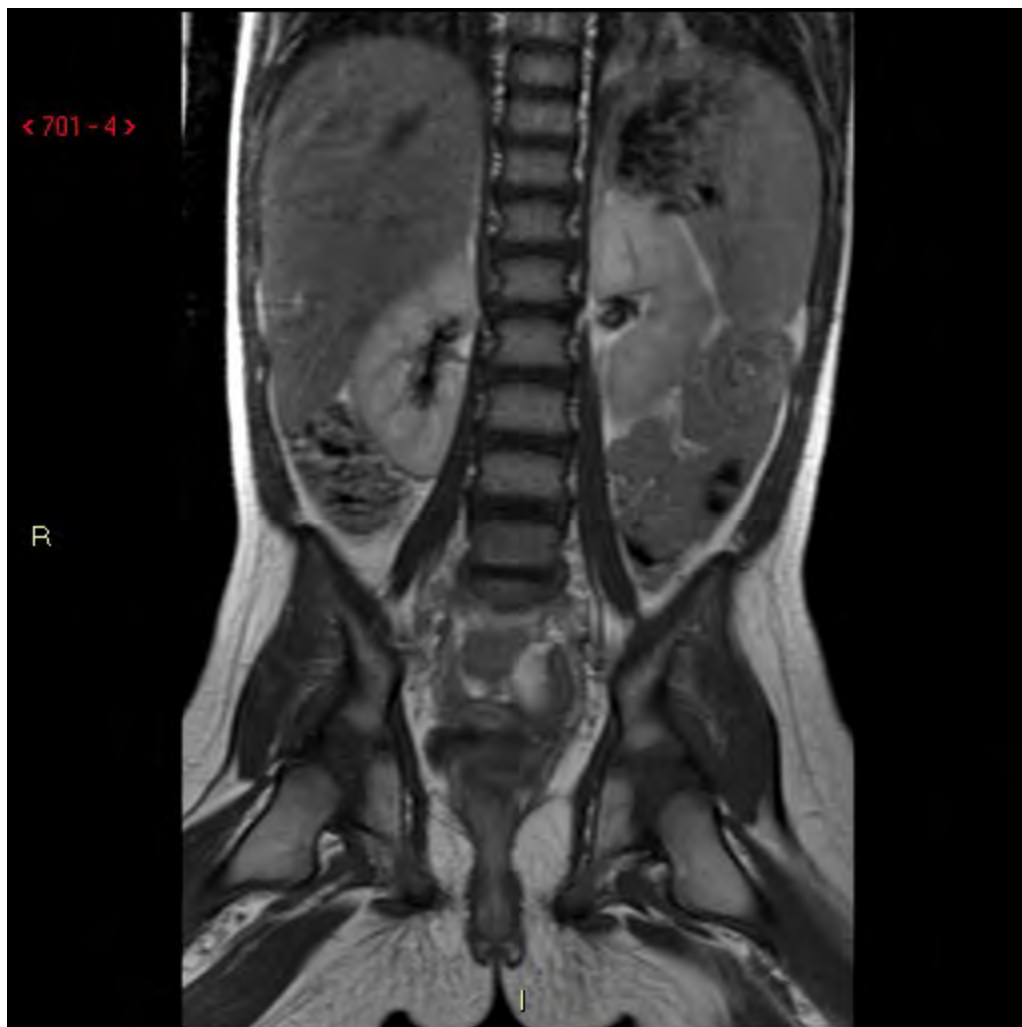




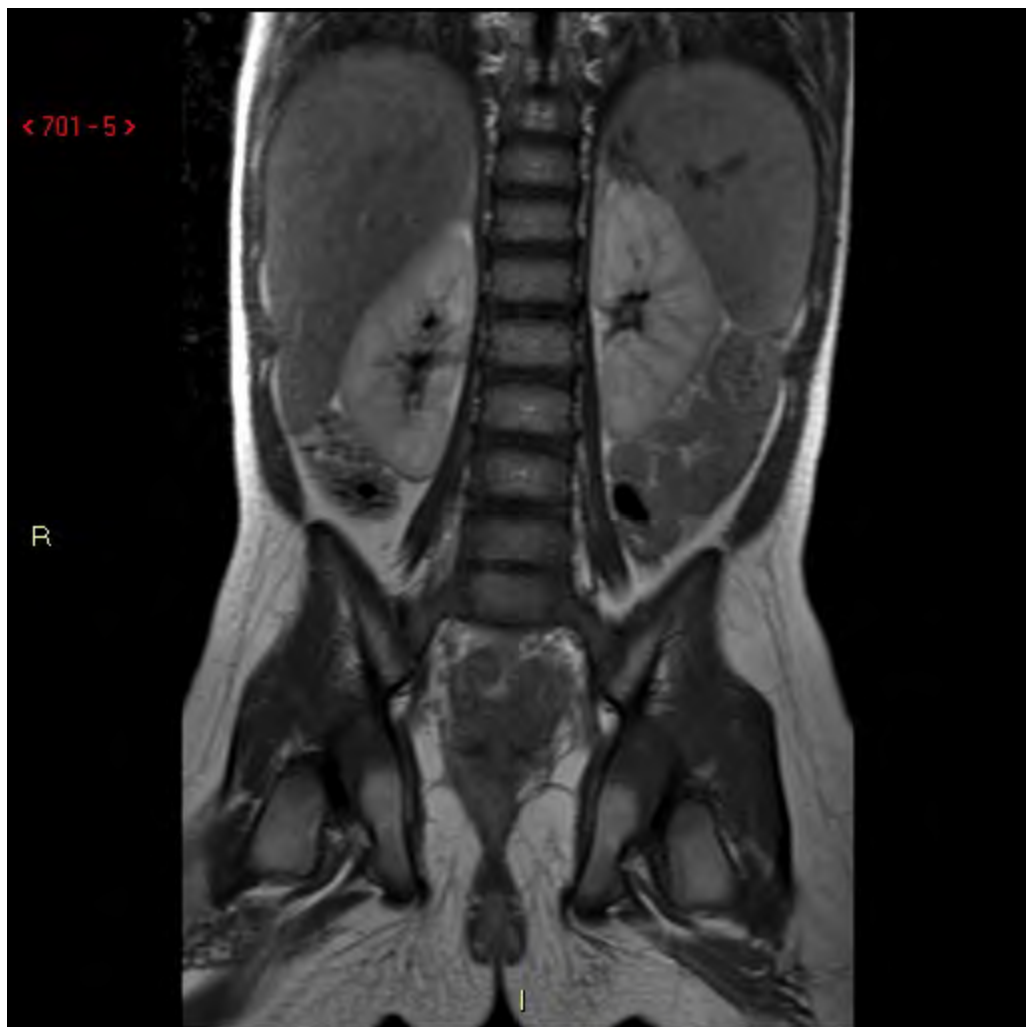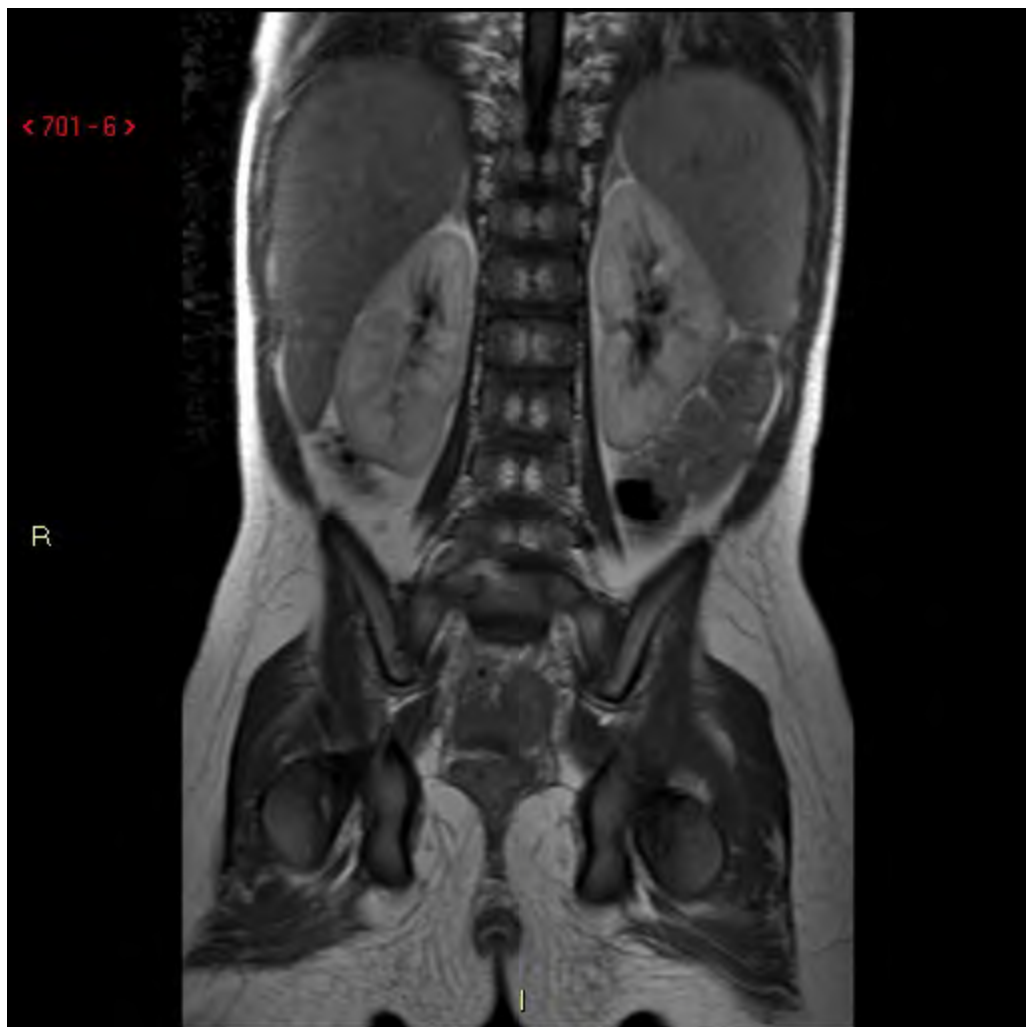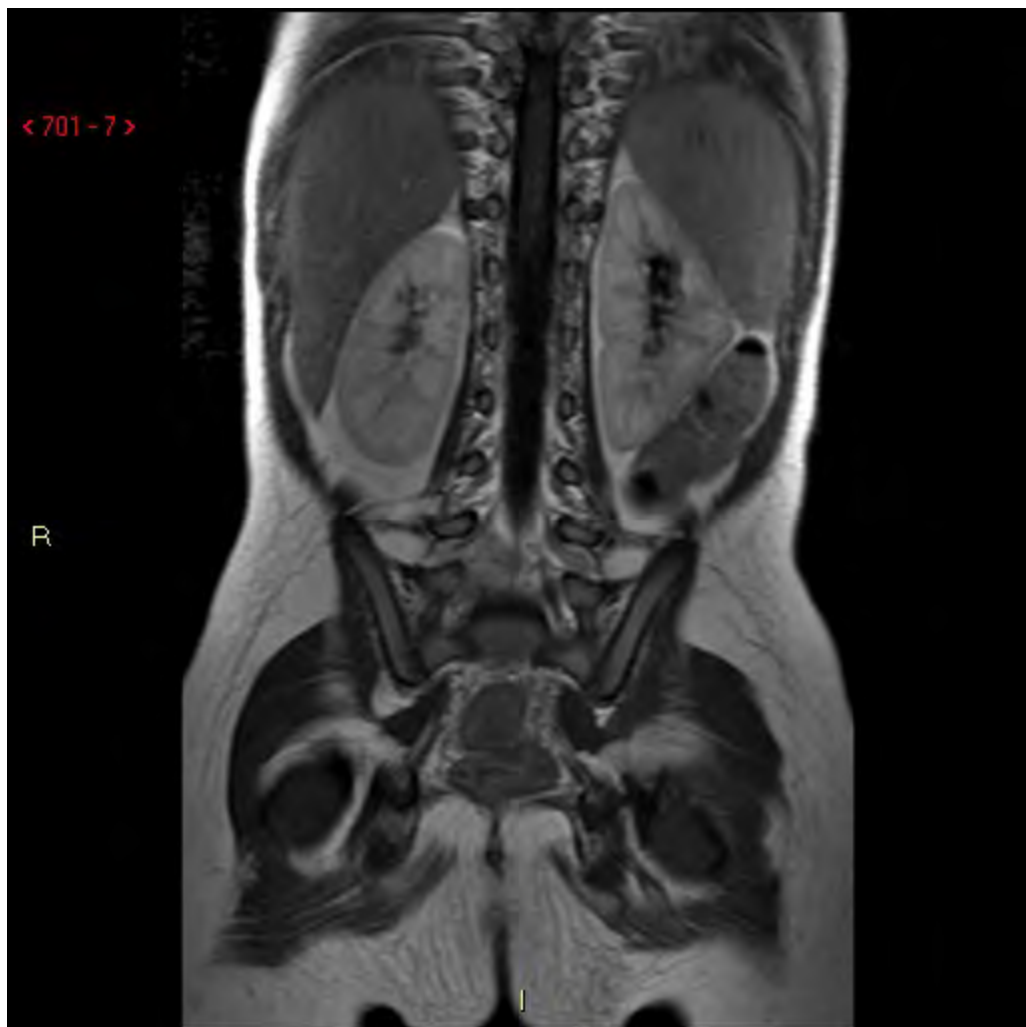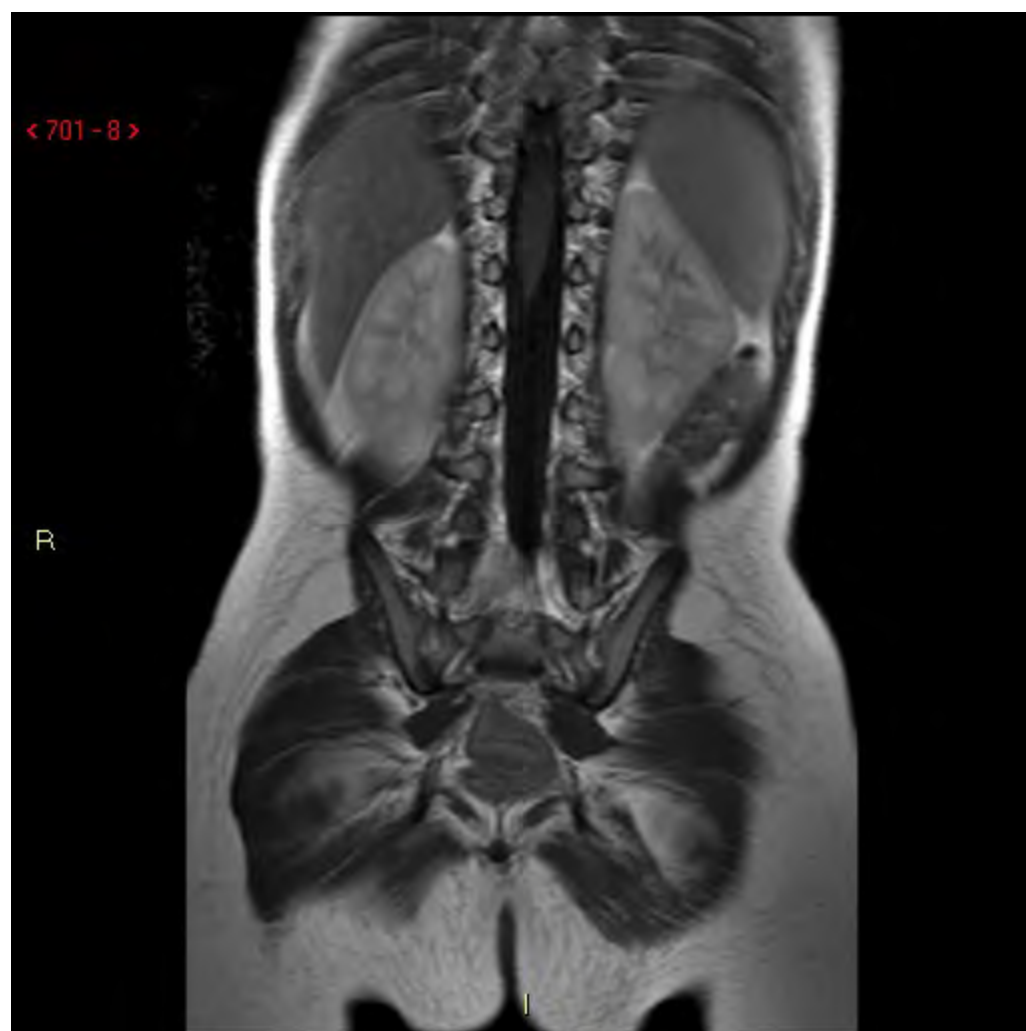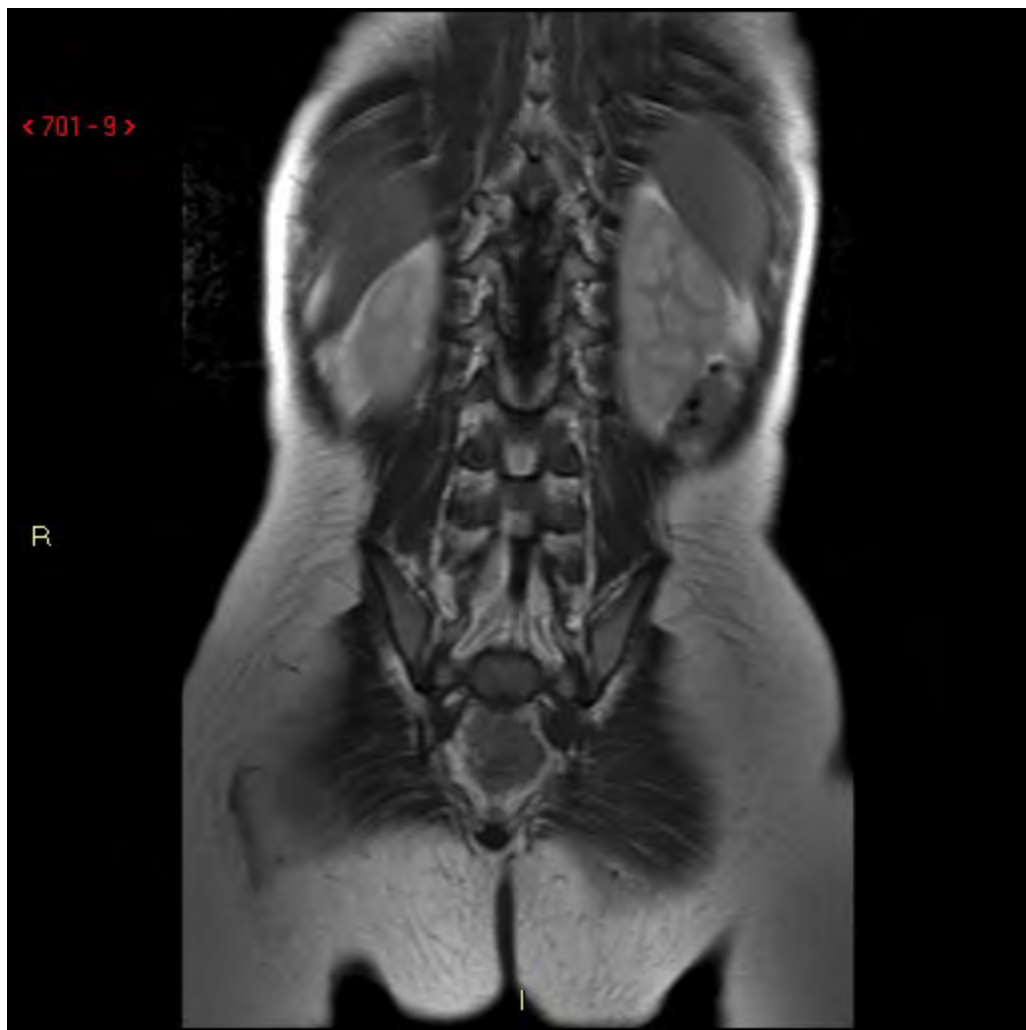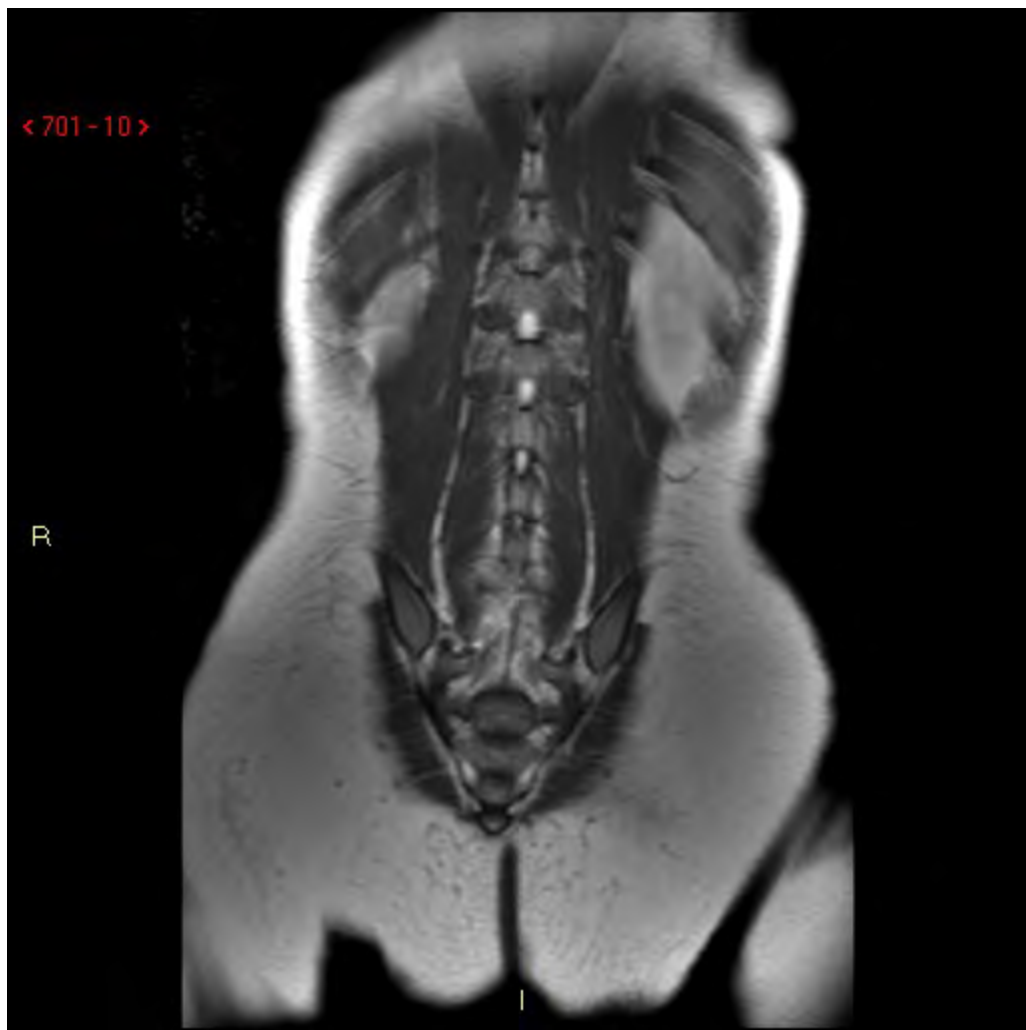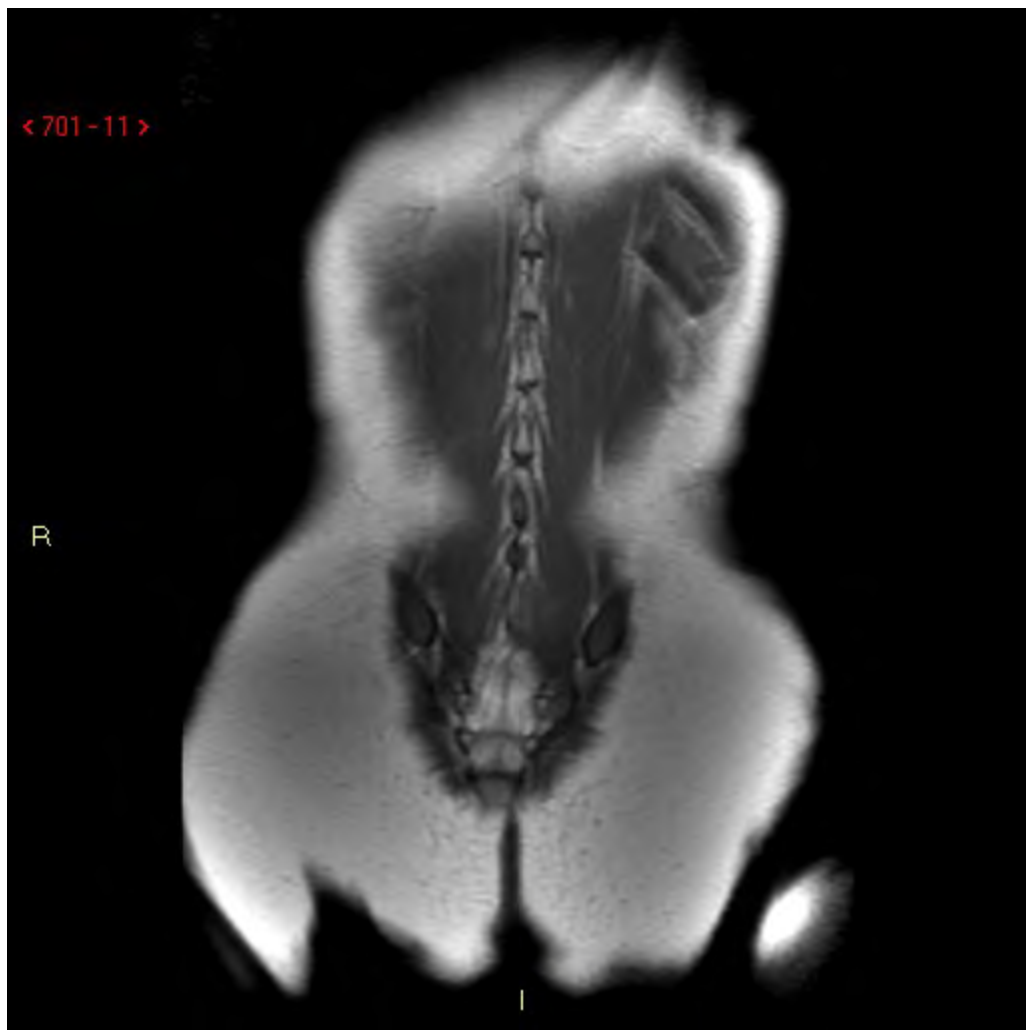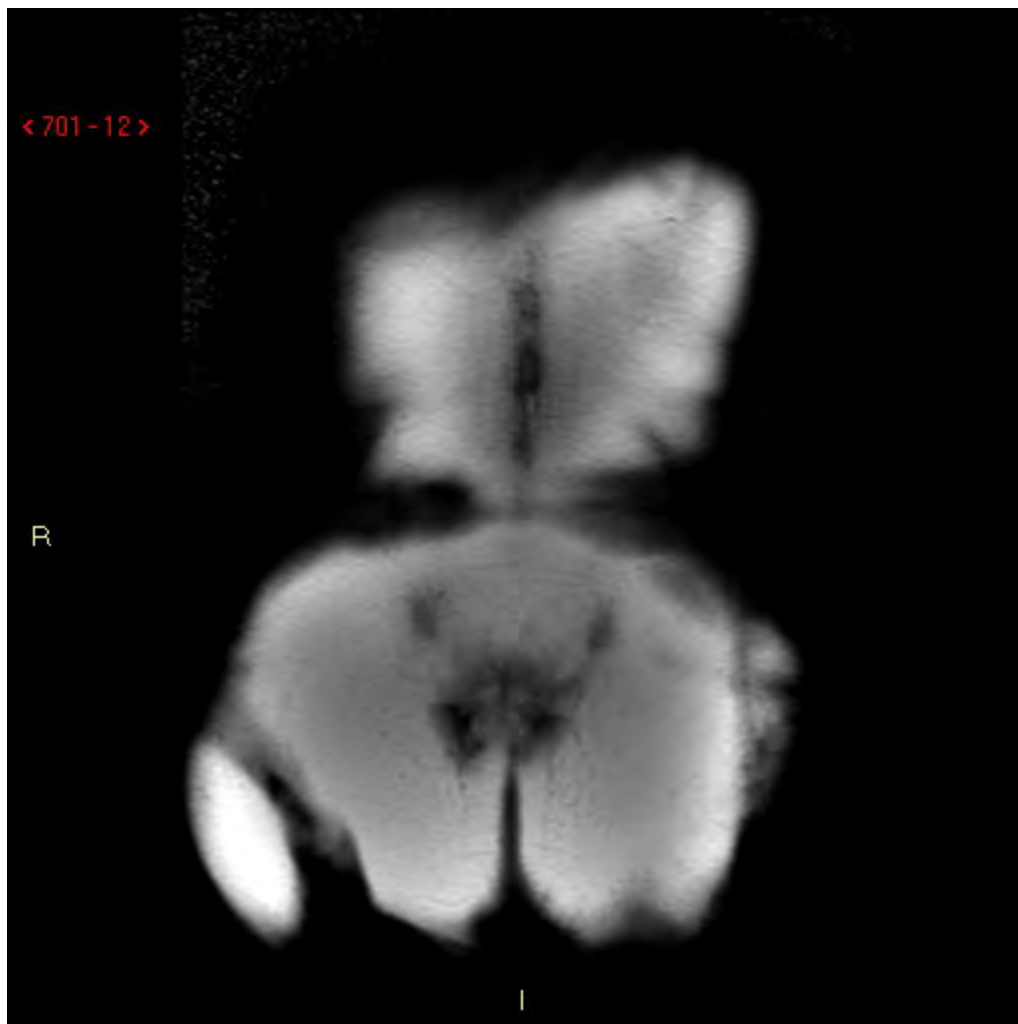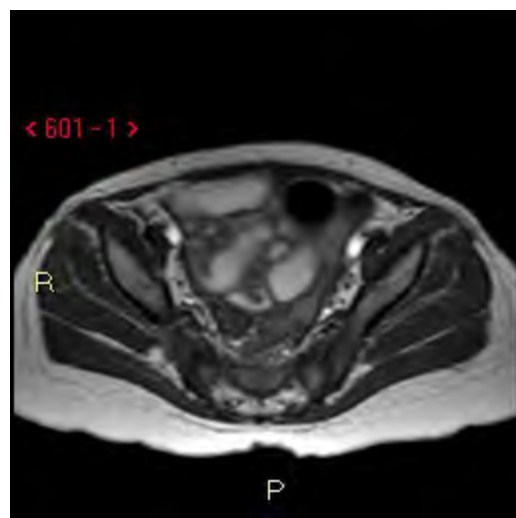


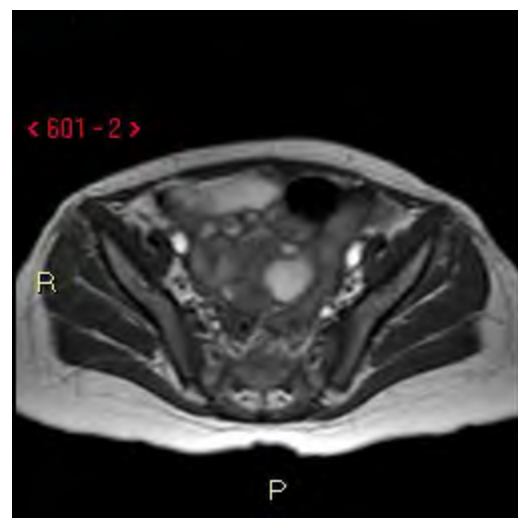


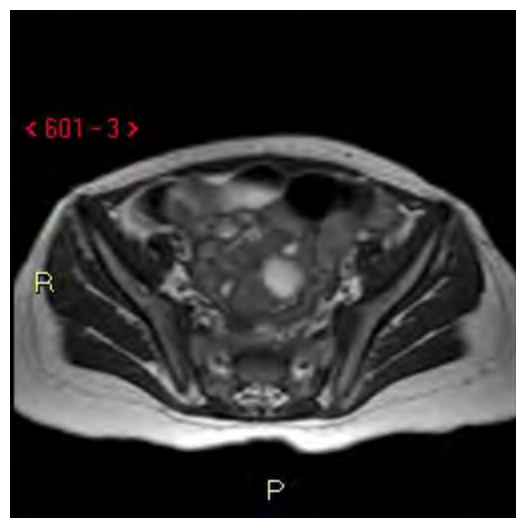


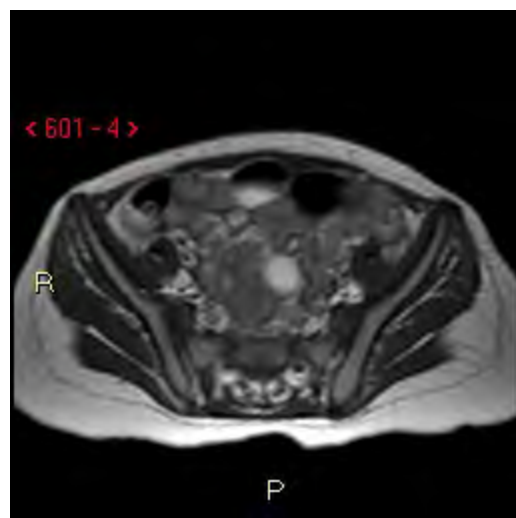


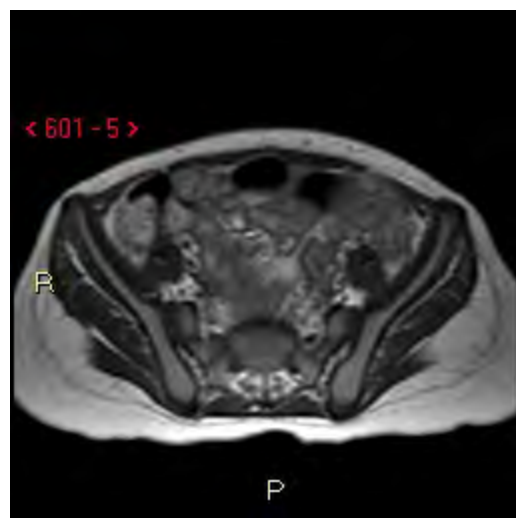


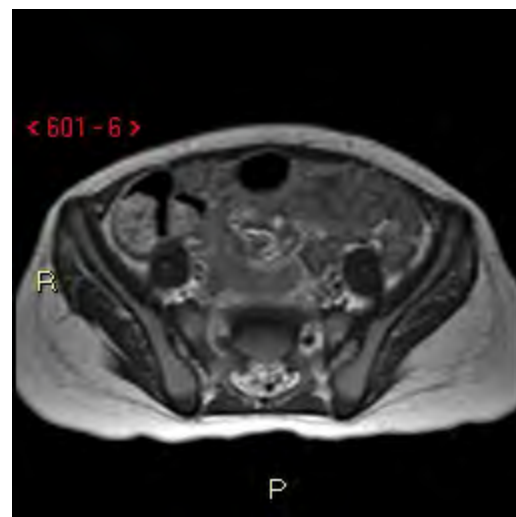


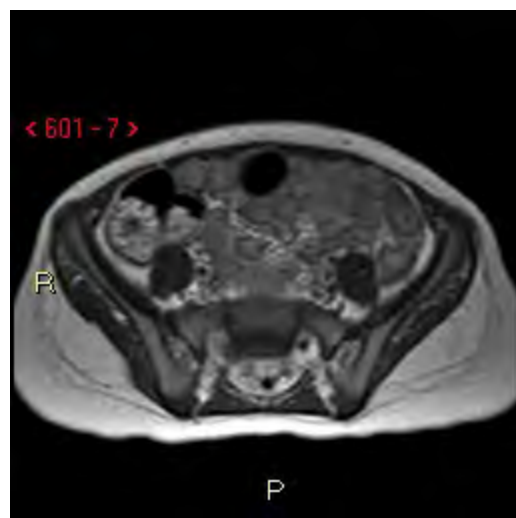


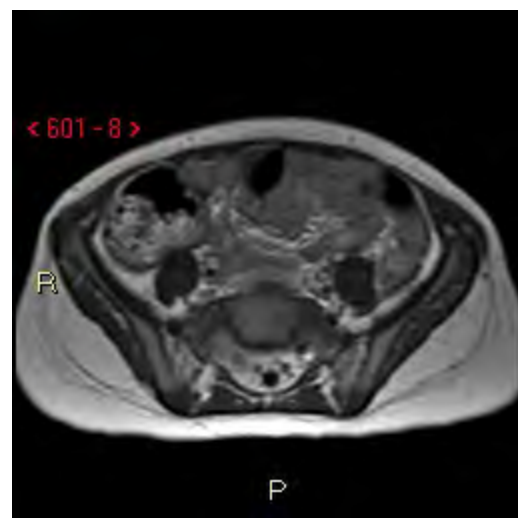




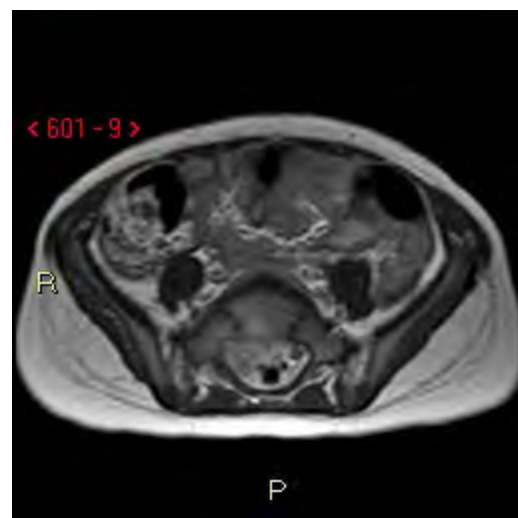


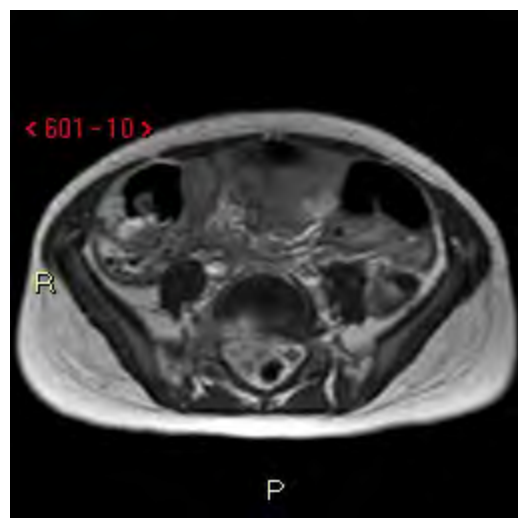


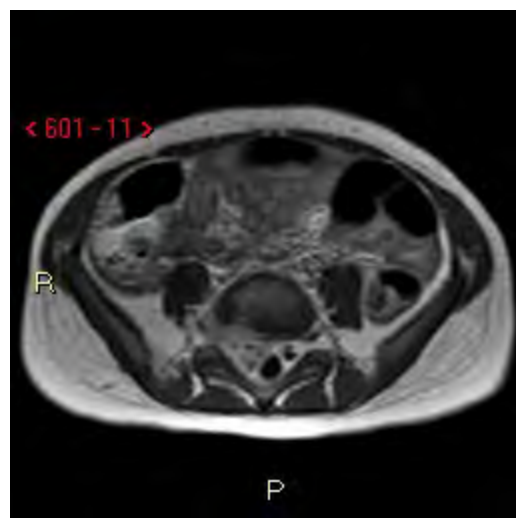


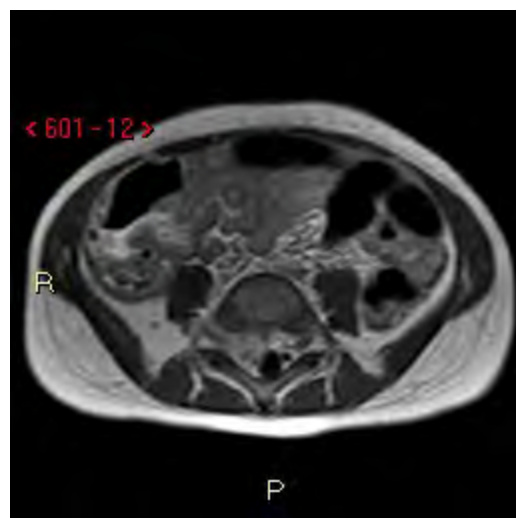


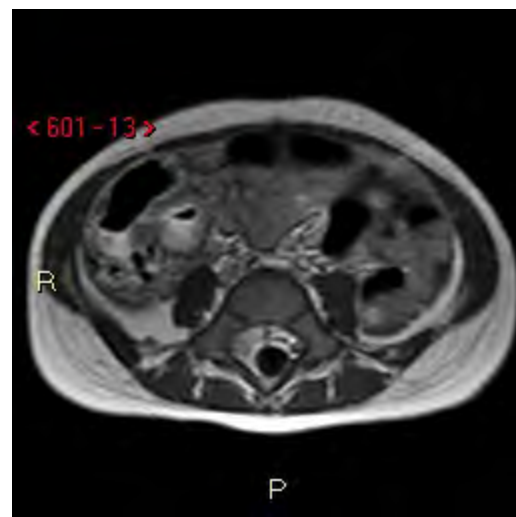


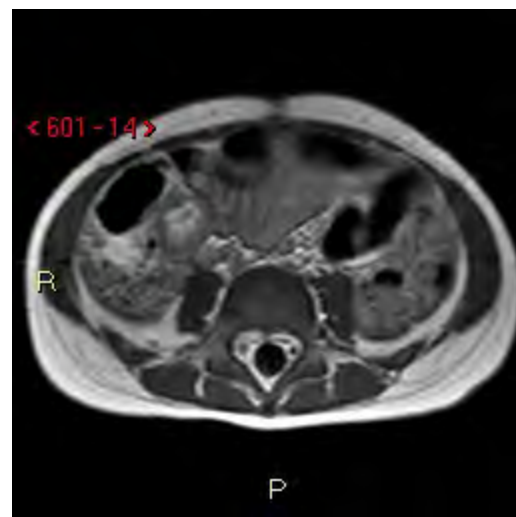


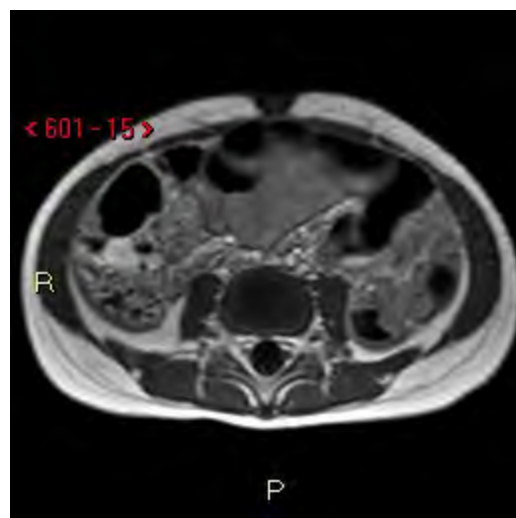


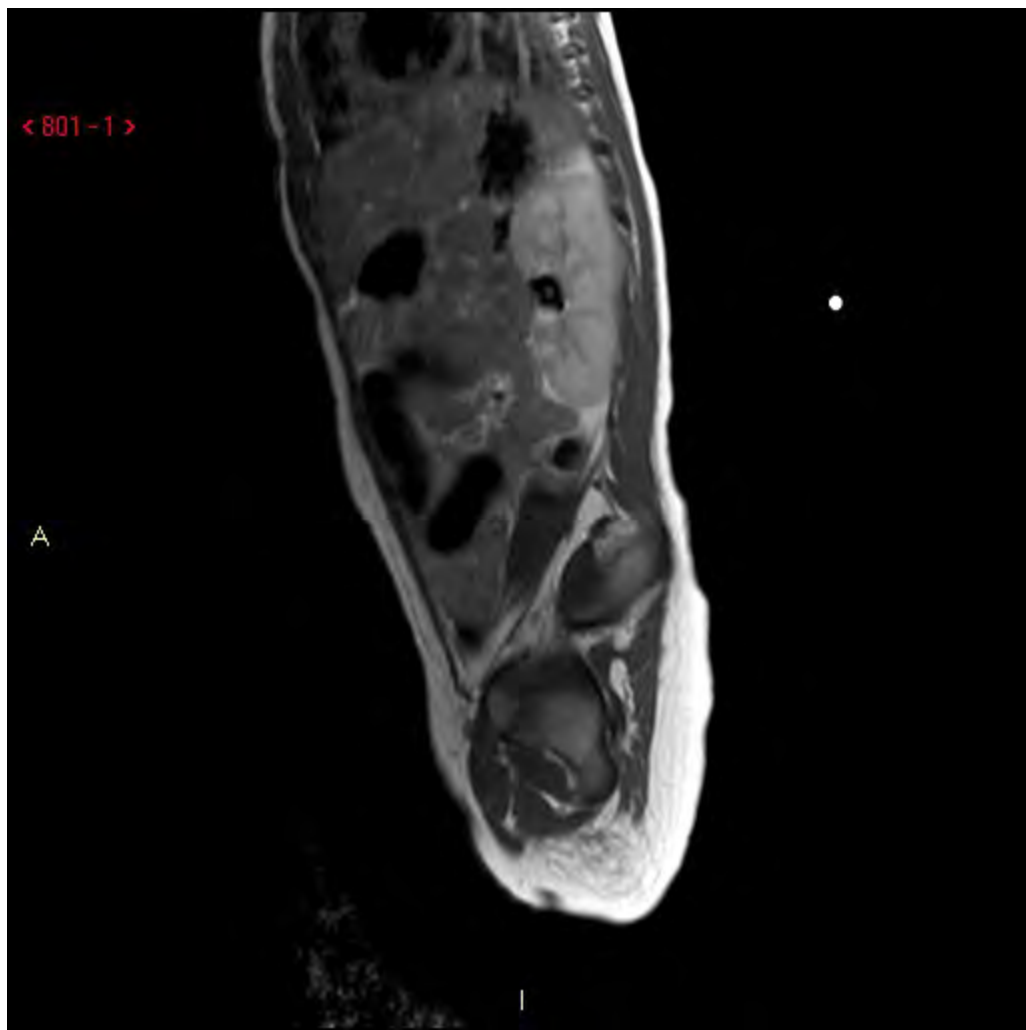




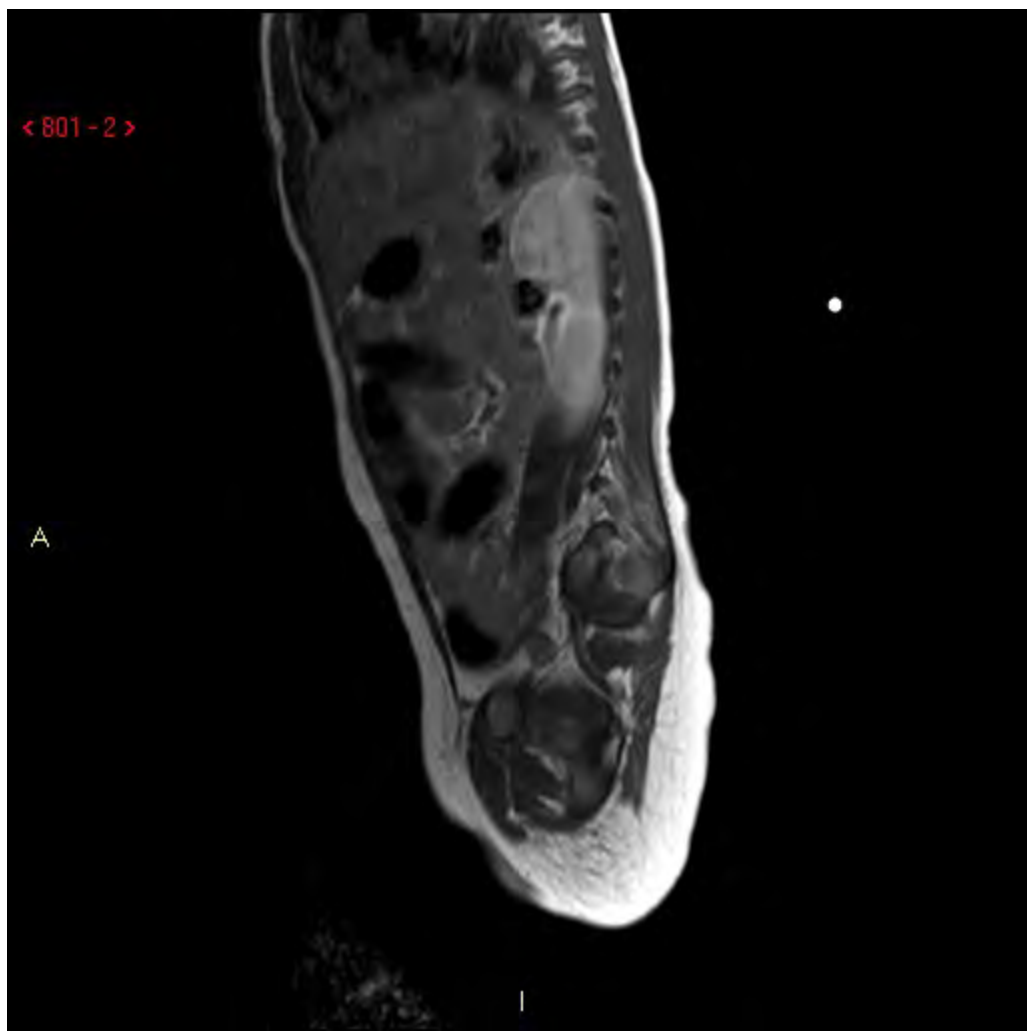


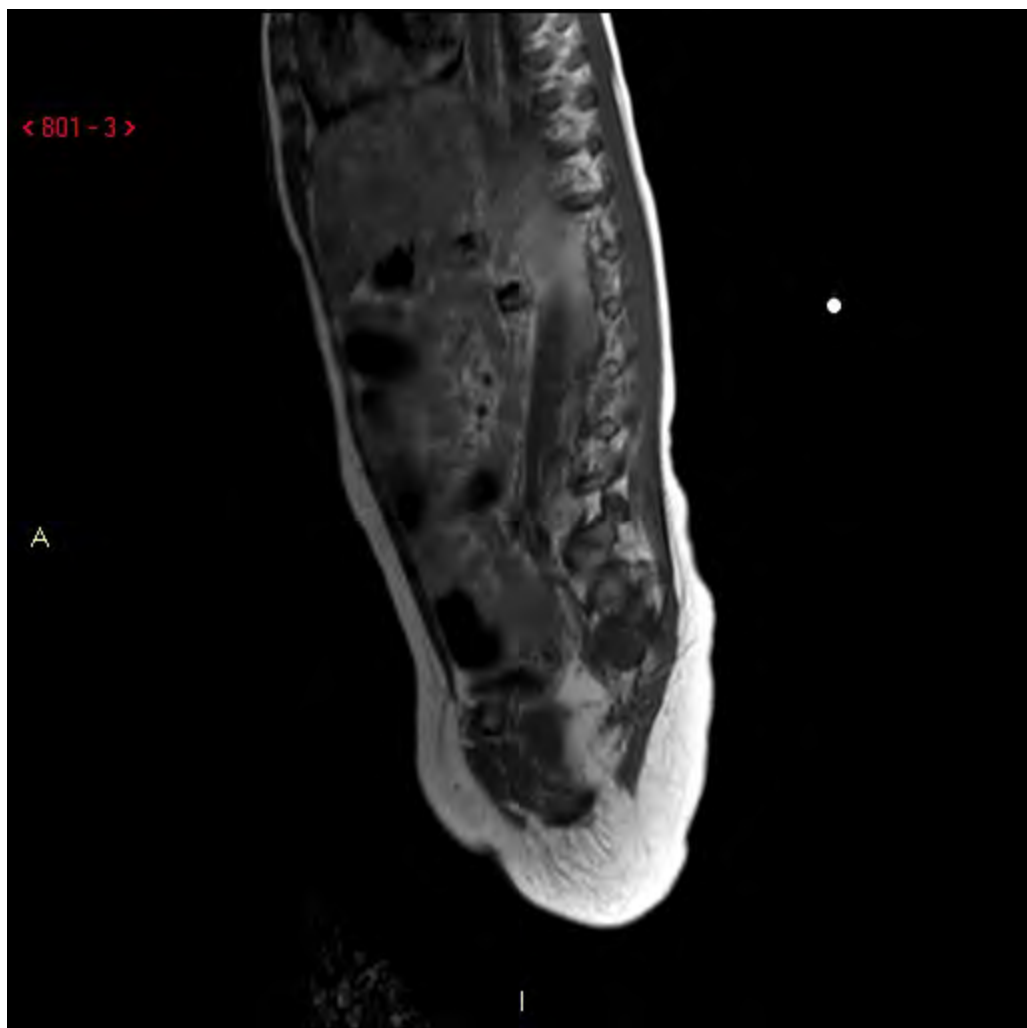


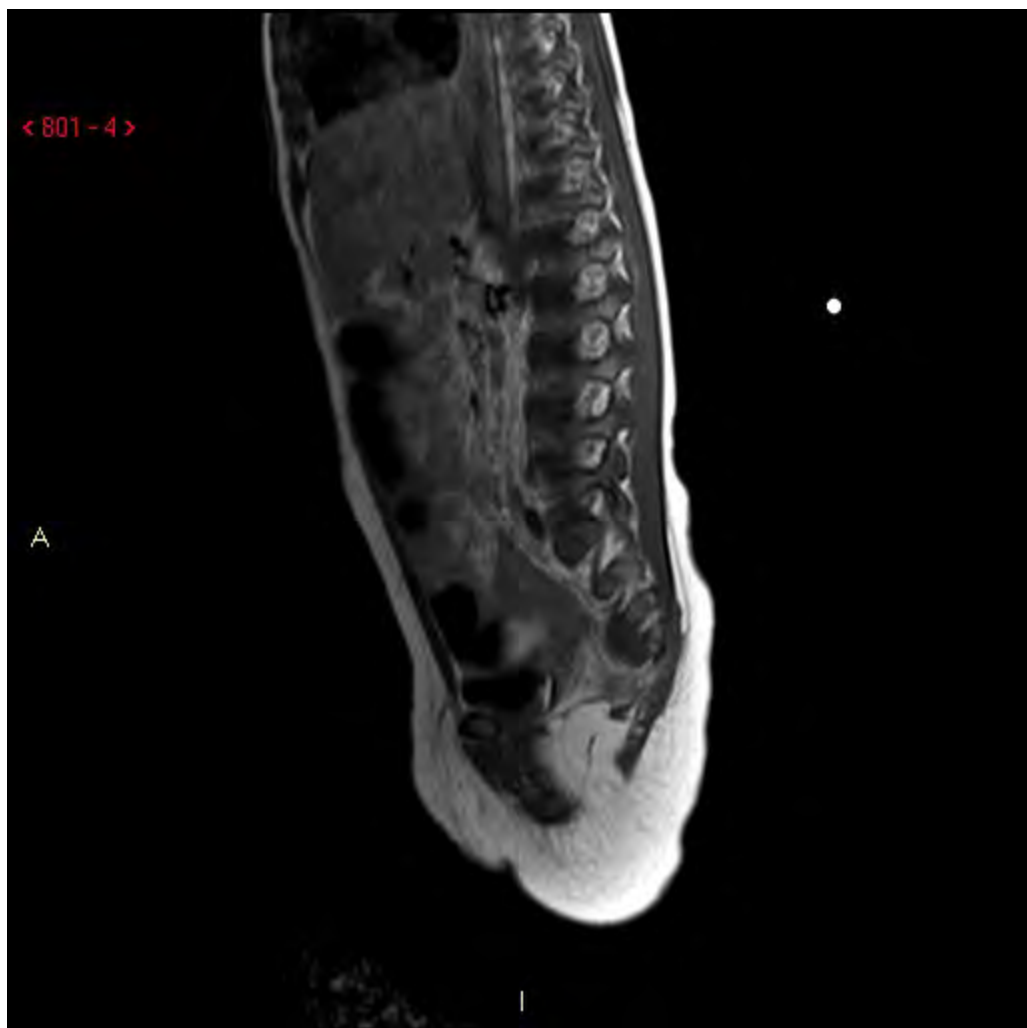


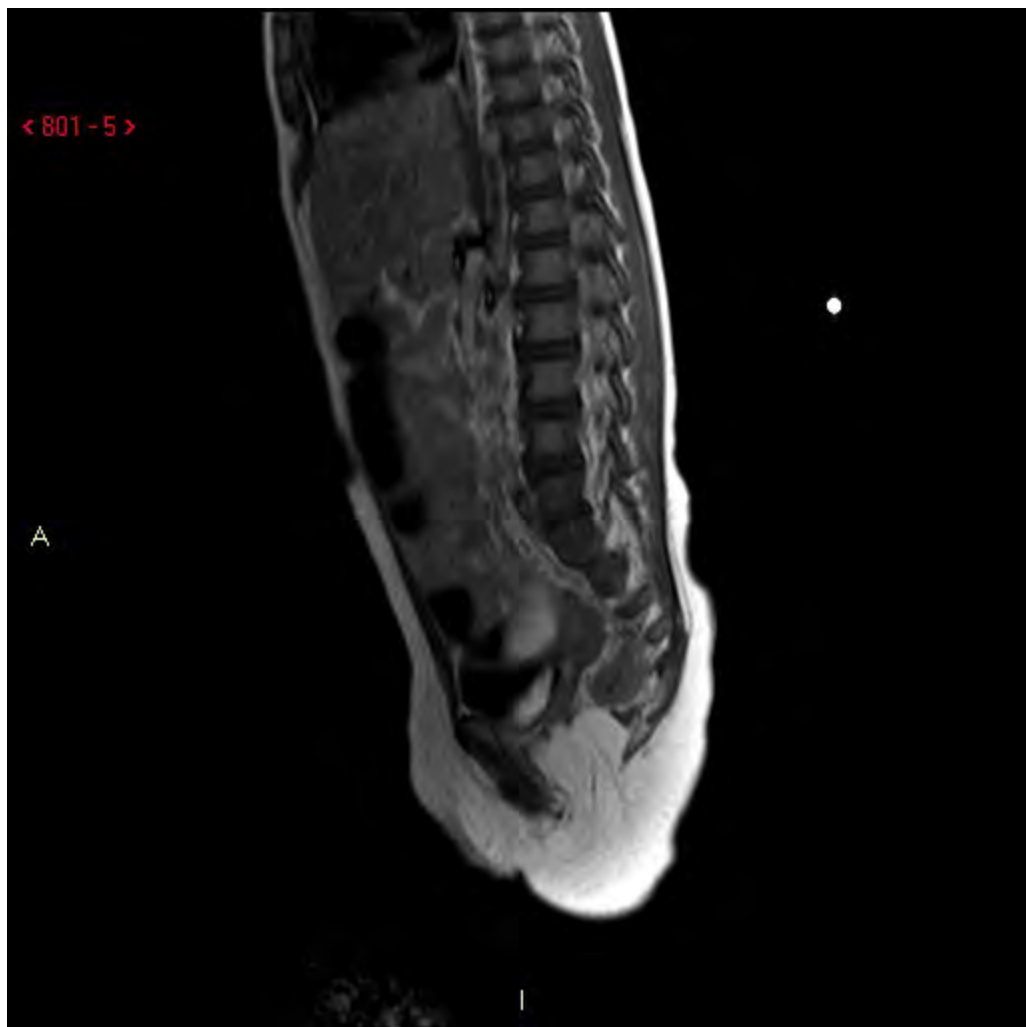


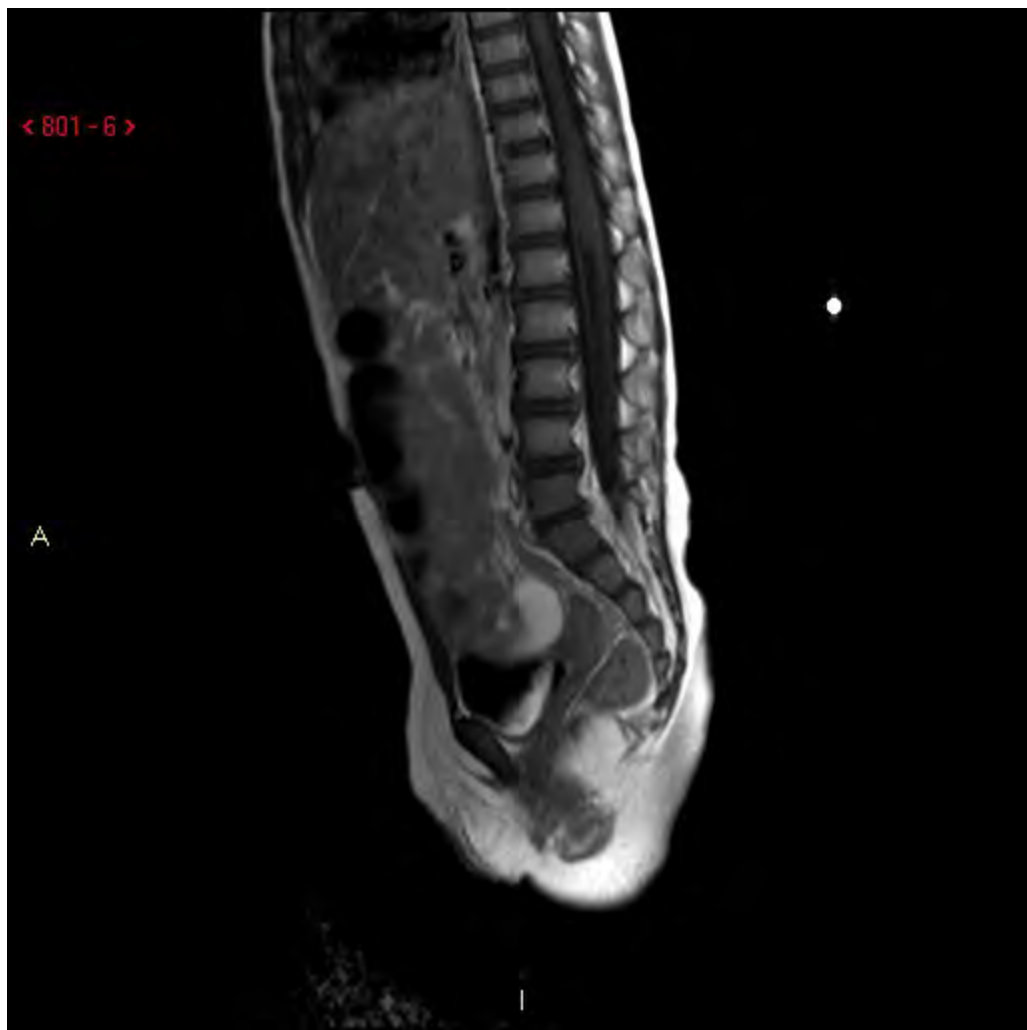


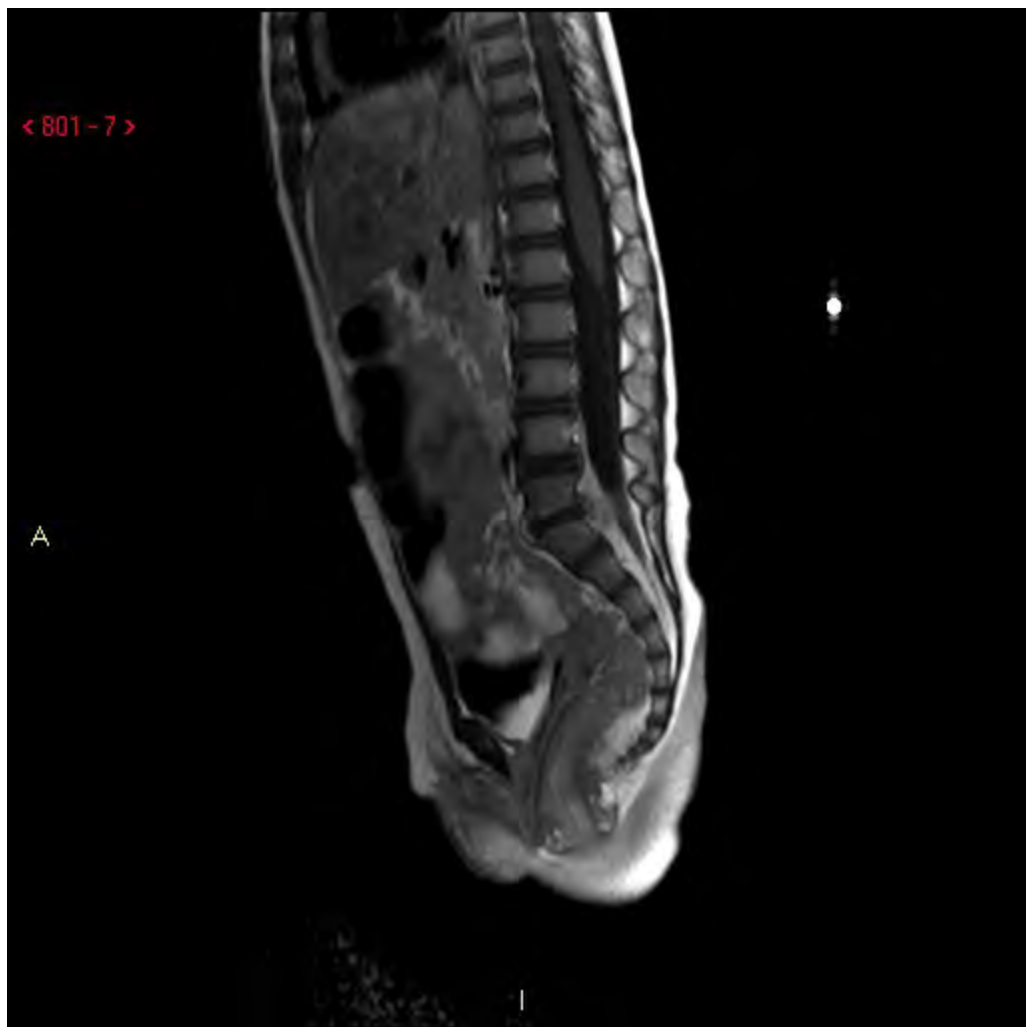


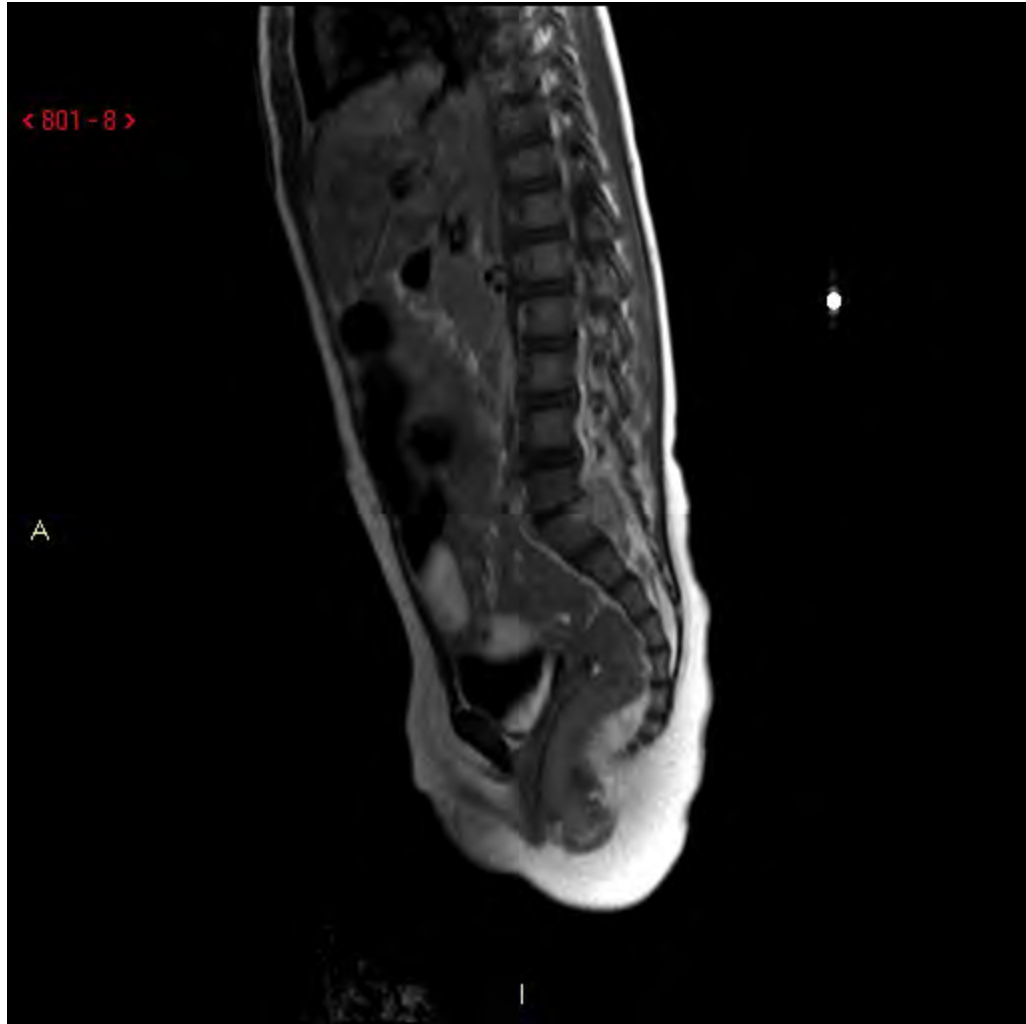


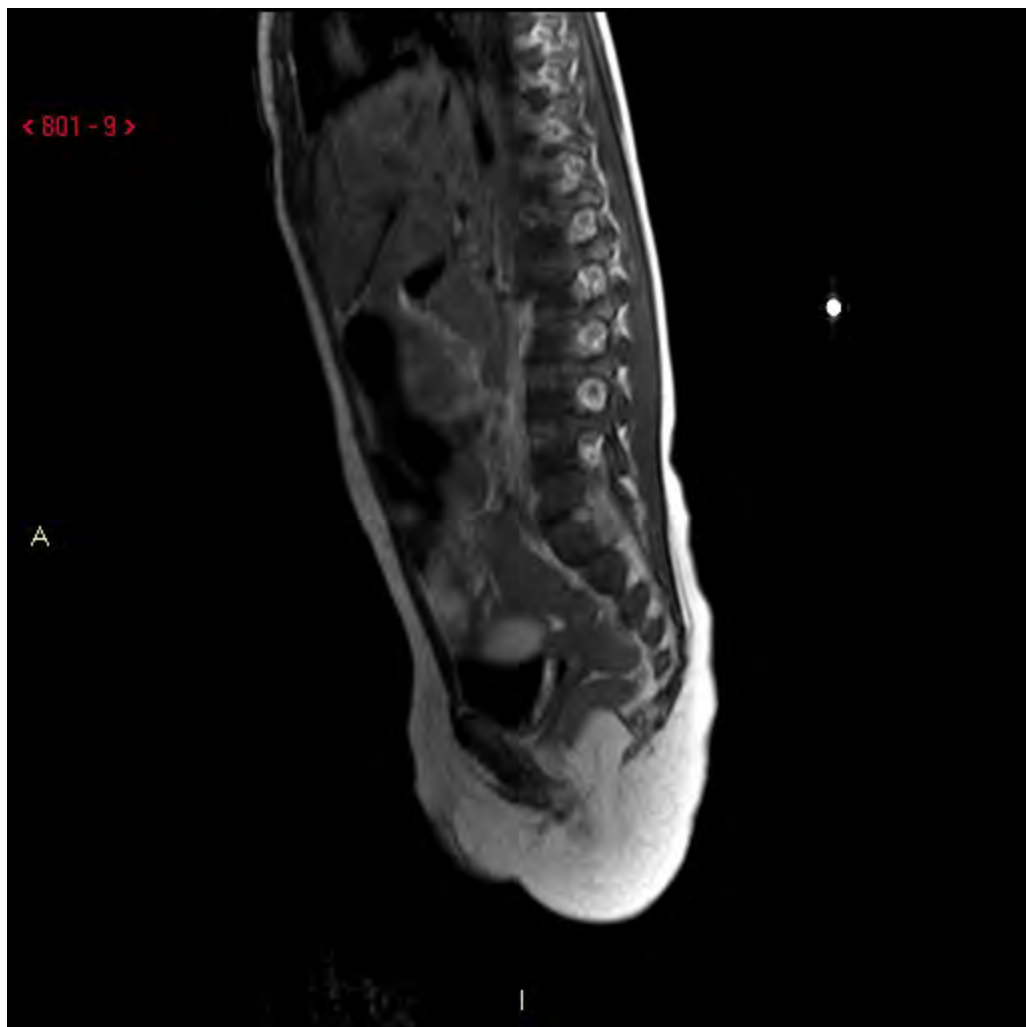




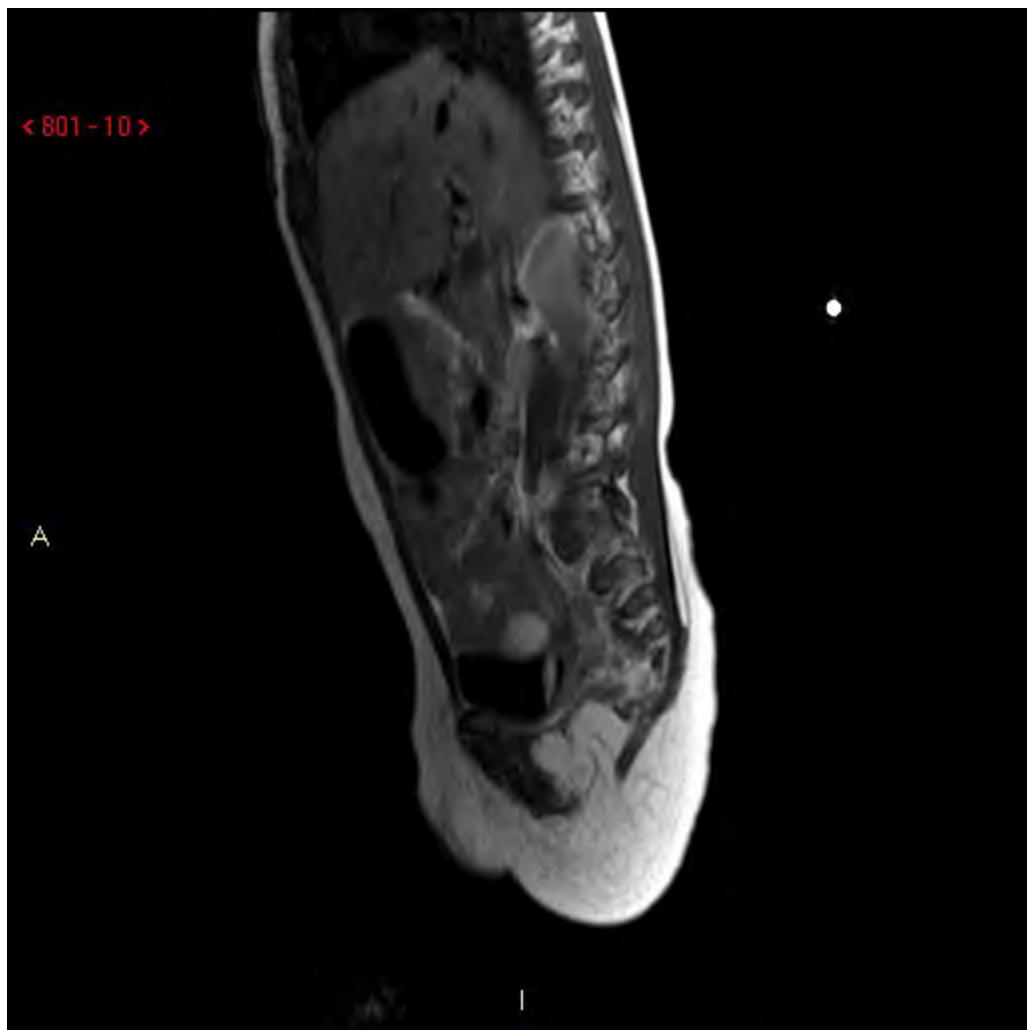


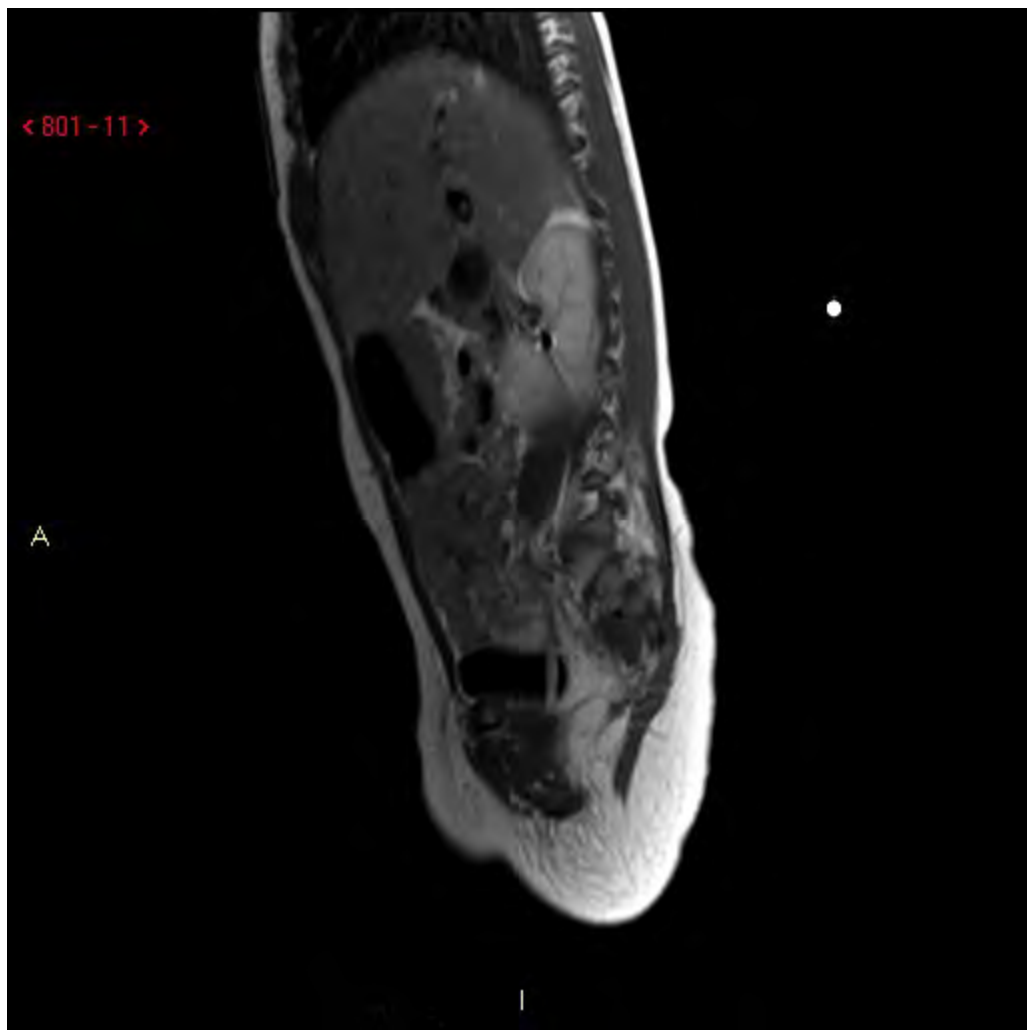


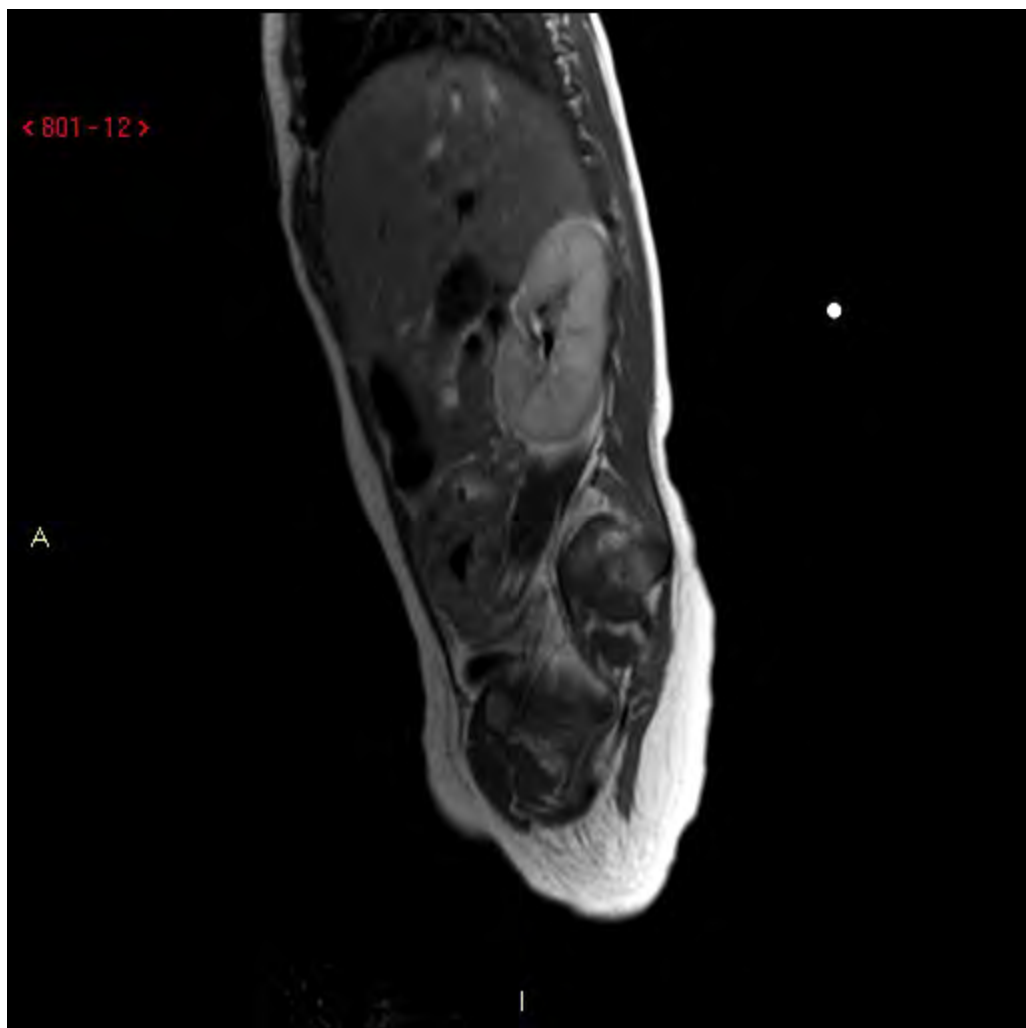


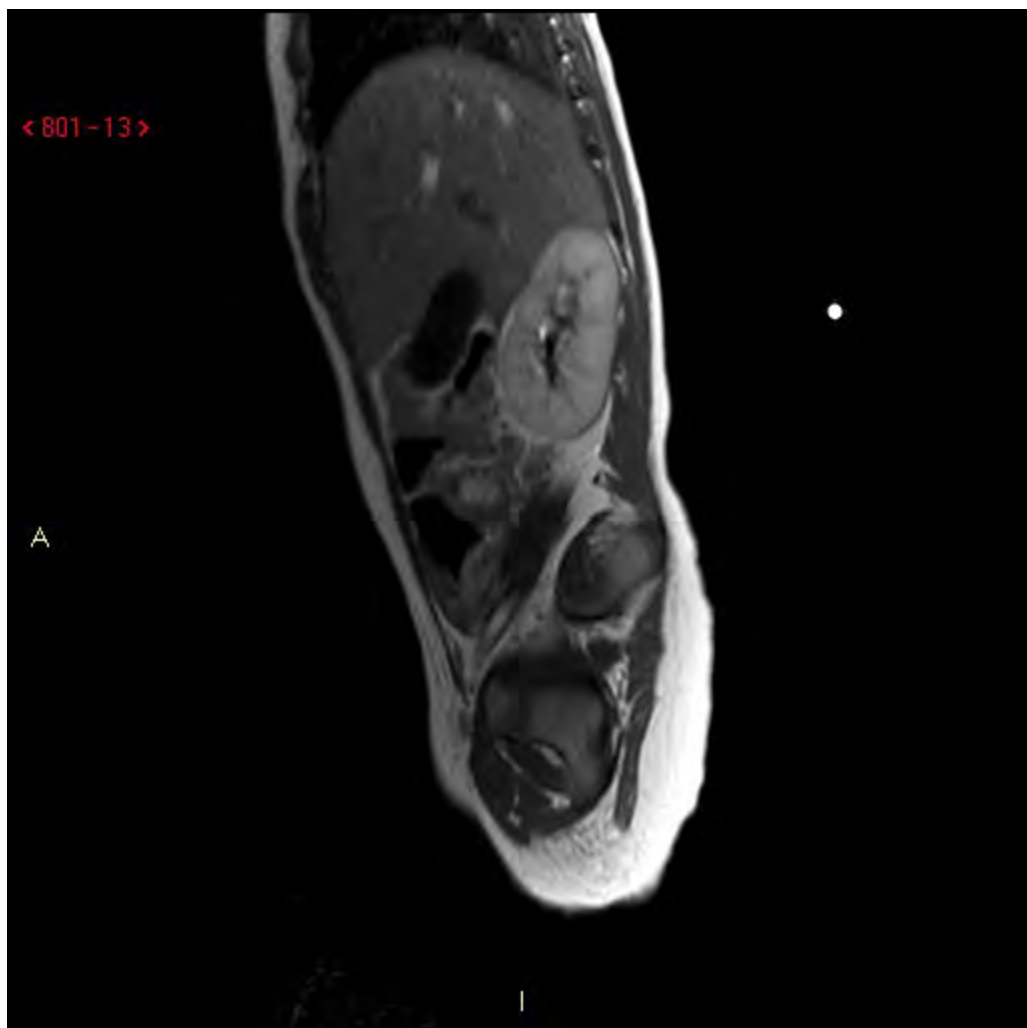








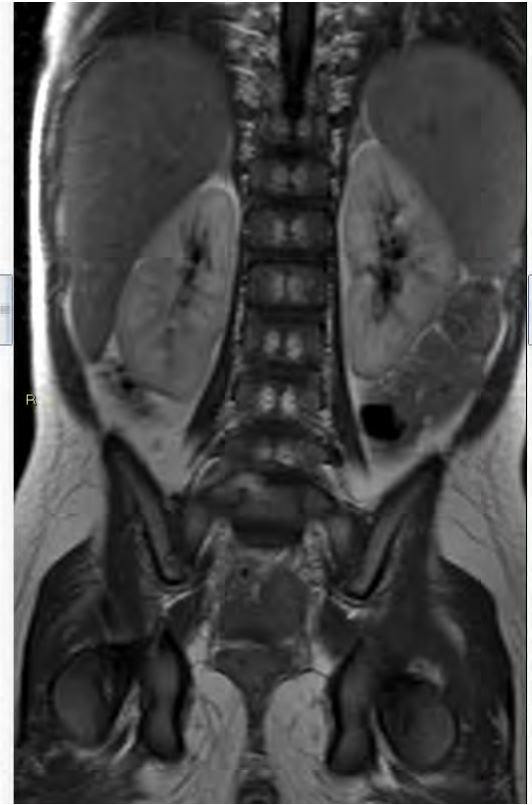
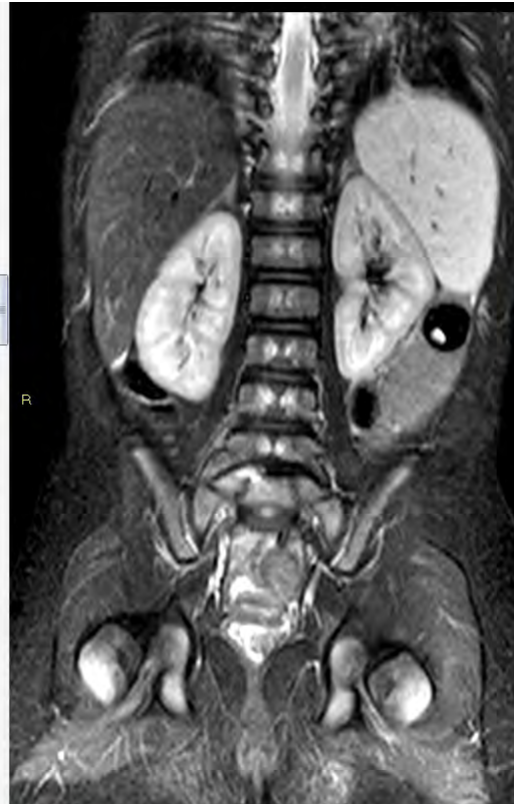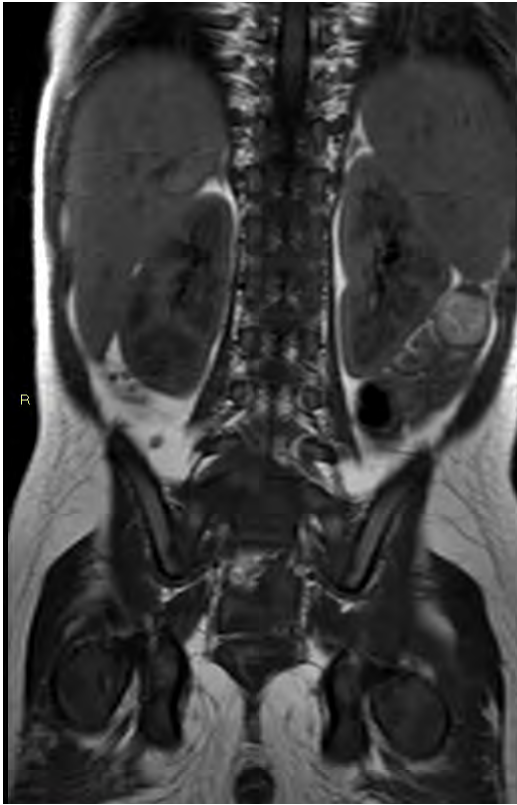




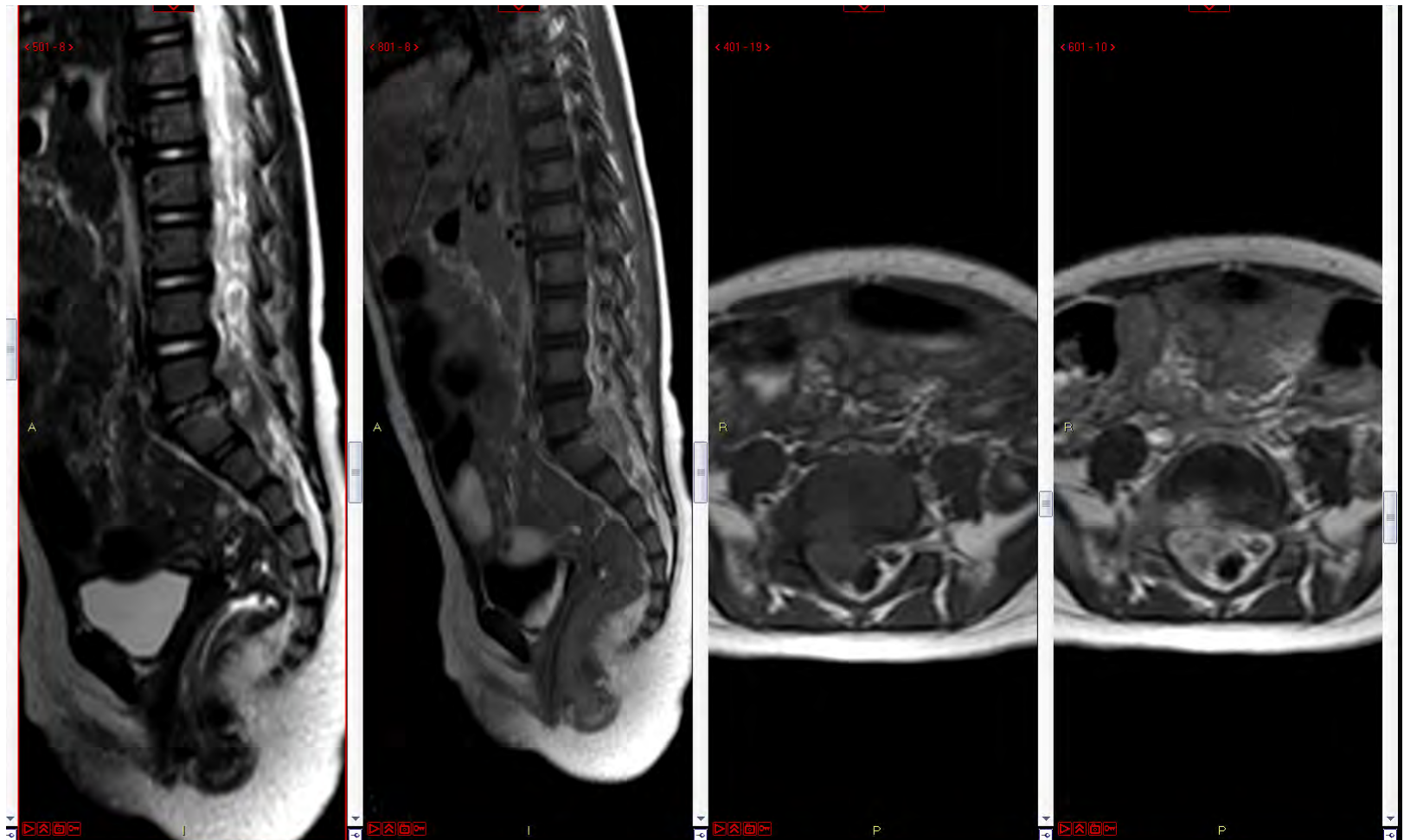
Fall 11

Fynd?

# Fall 11



# Fall 11



# Fall 11

Tänkbar diff diagnos?



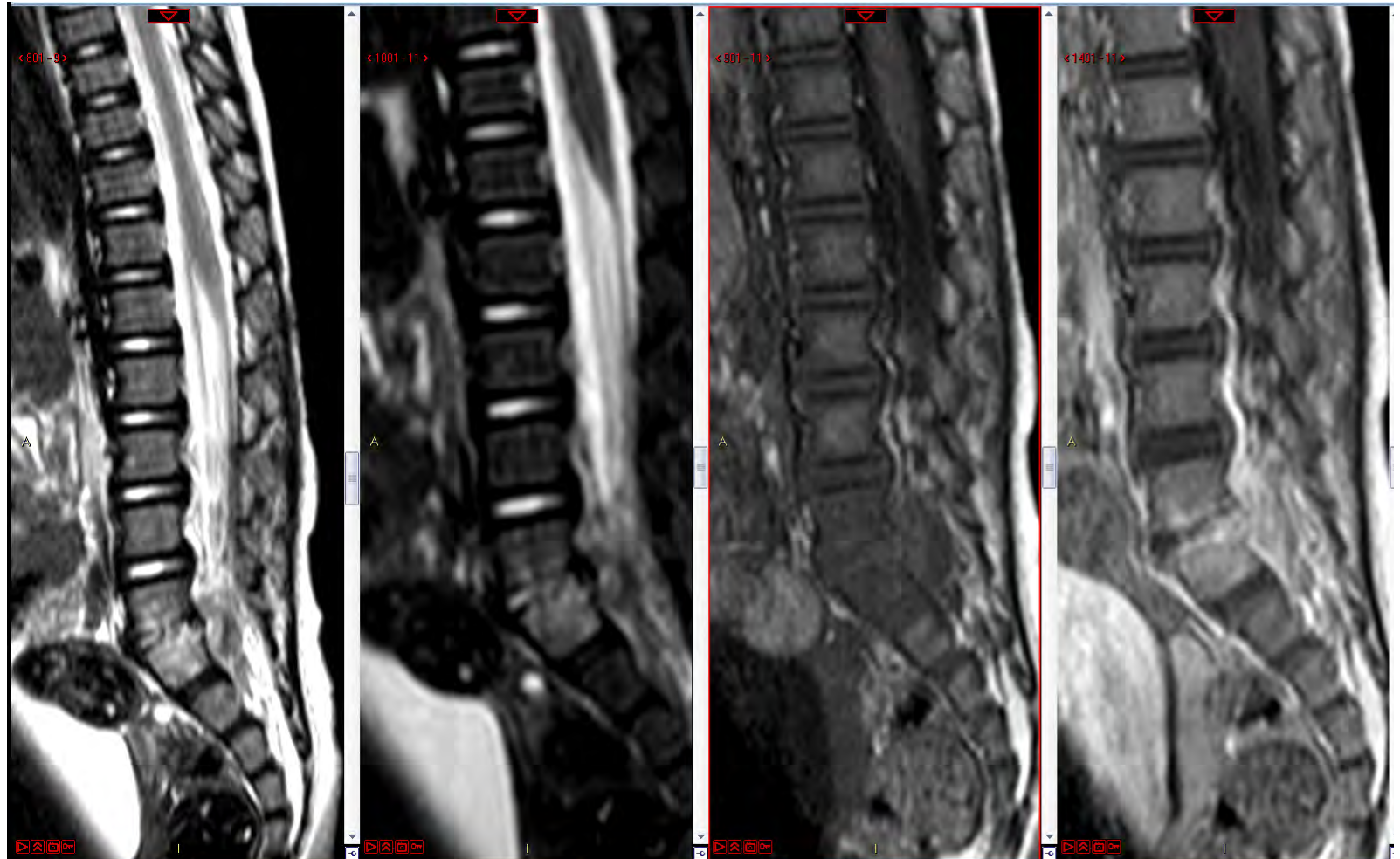
# Fall 11

Ovanligt med spinala tumörer hos barn.

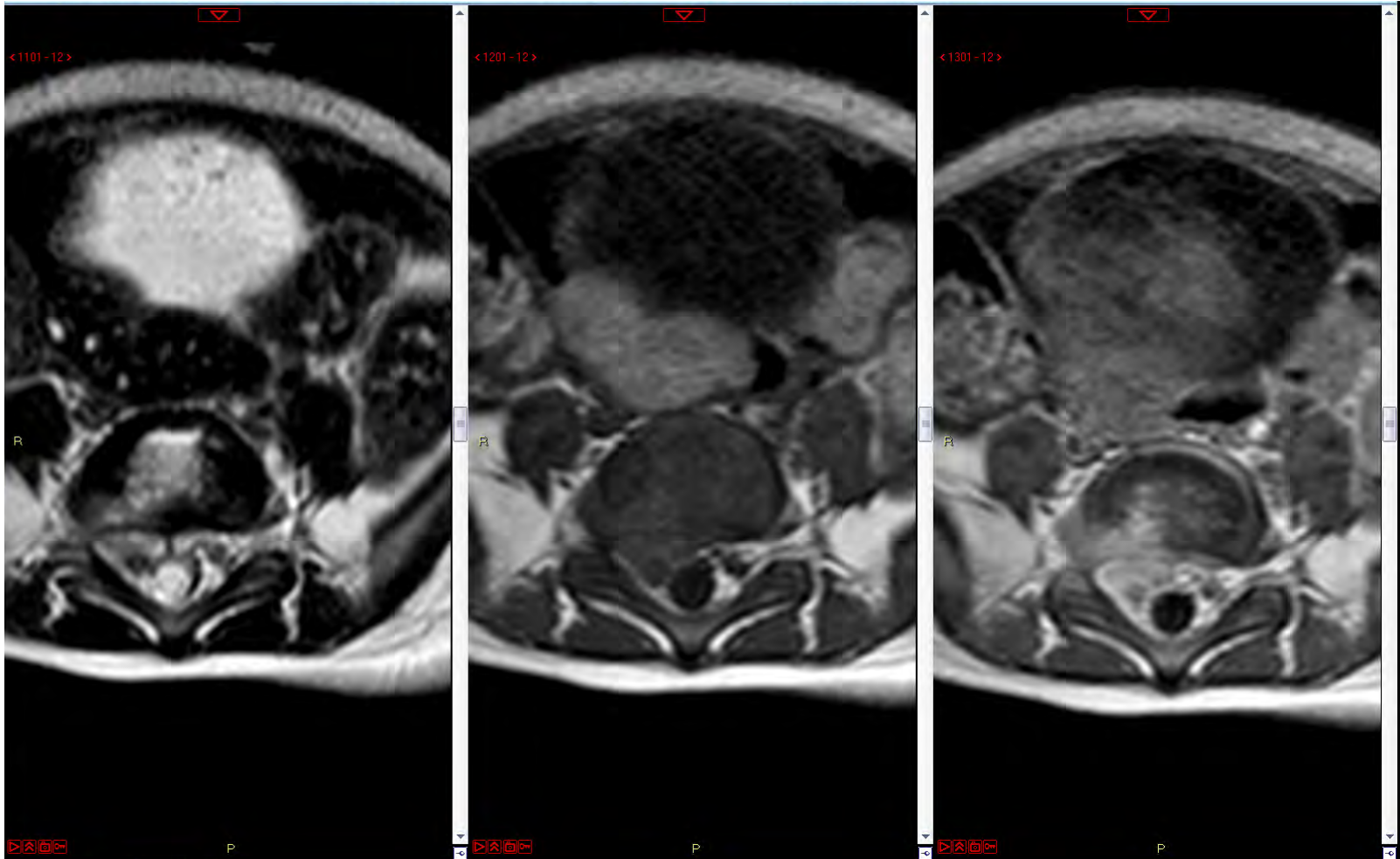
Uteslut alltid spondylodiskit!!!

5dagar sedan föregående MRT. Vi utför  
ny MR:

# Fall 11

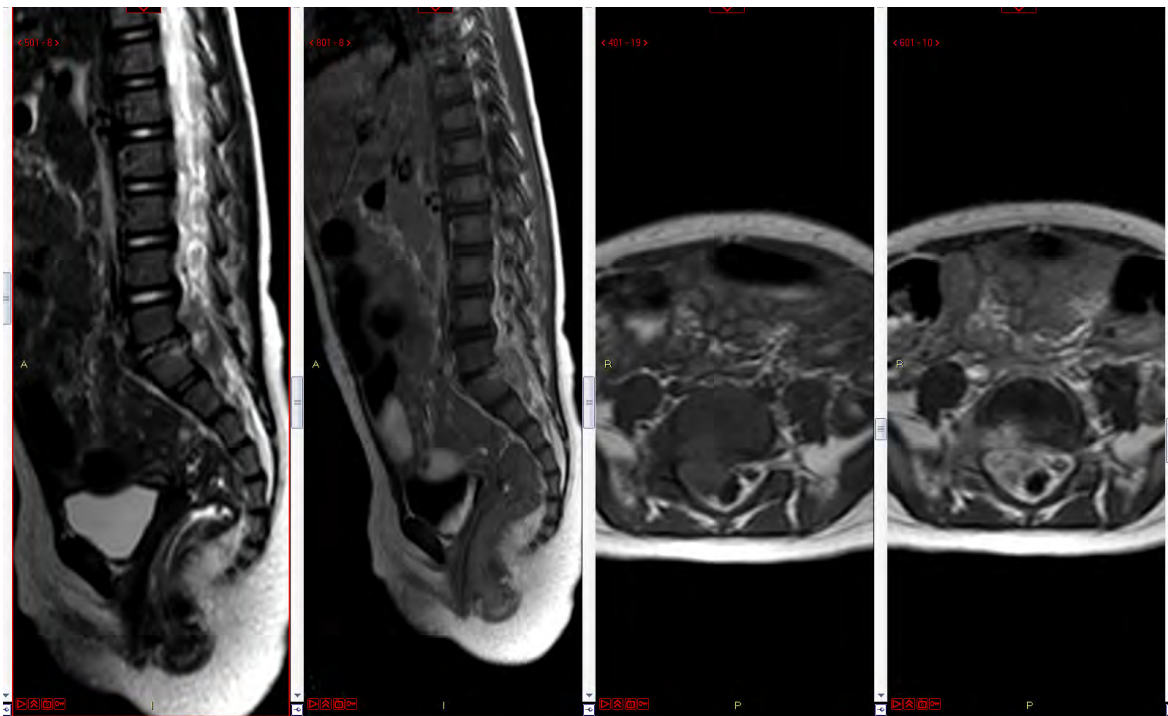


# Fall 11



# Fall 11

## MR 1



## MR 2

