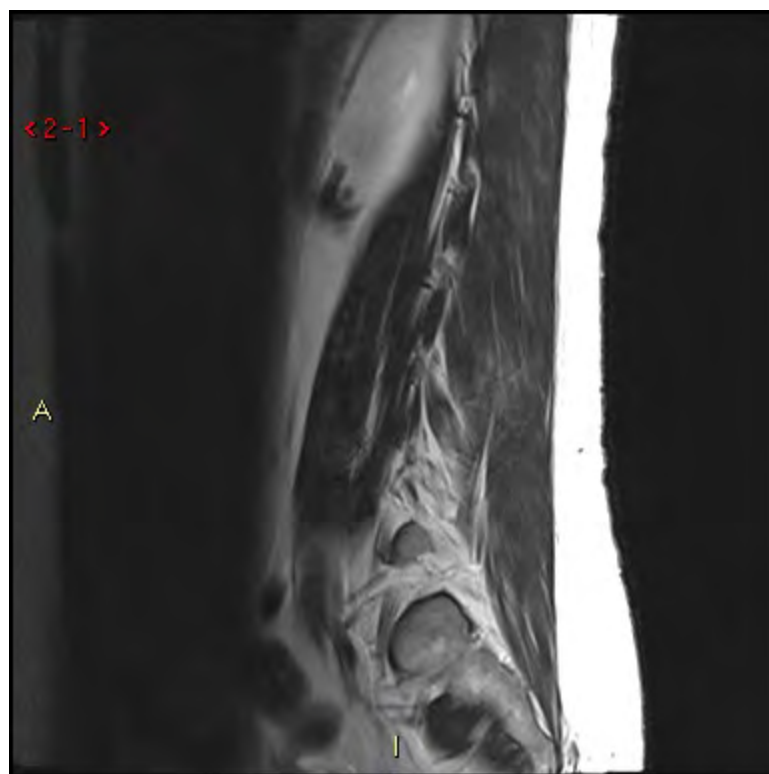
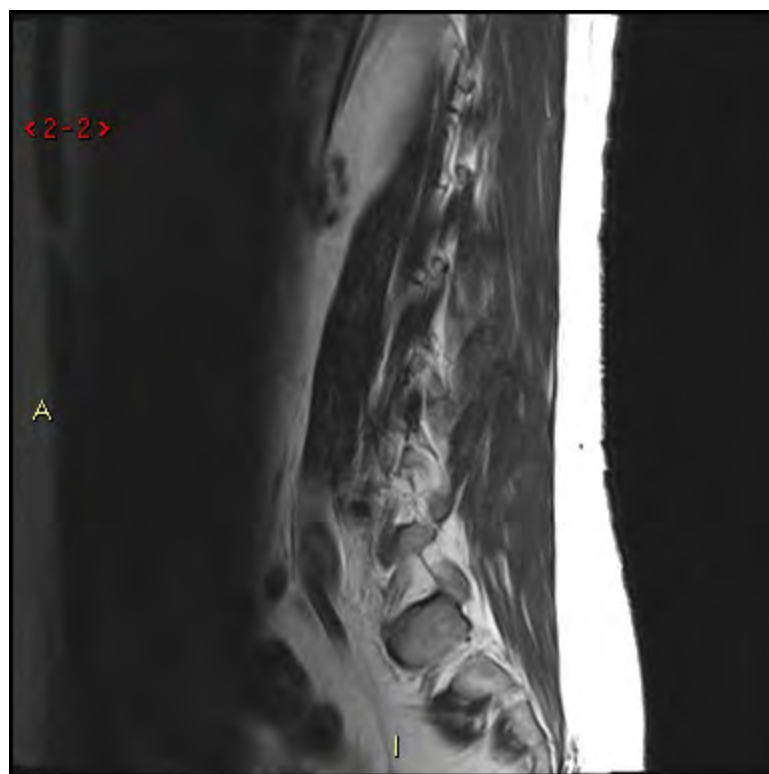


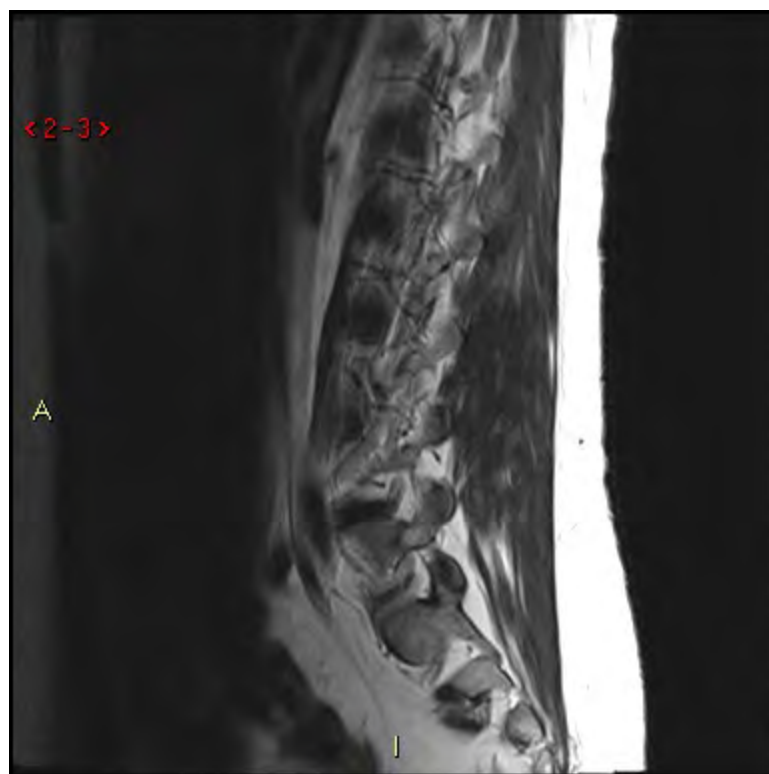
Fall 12

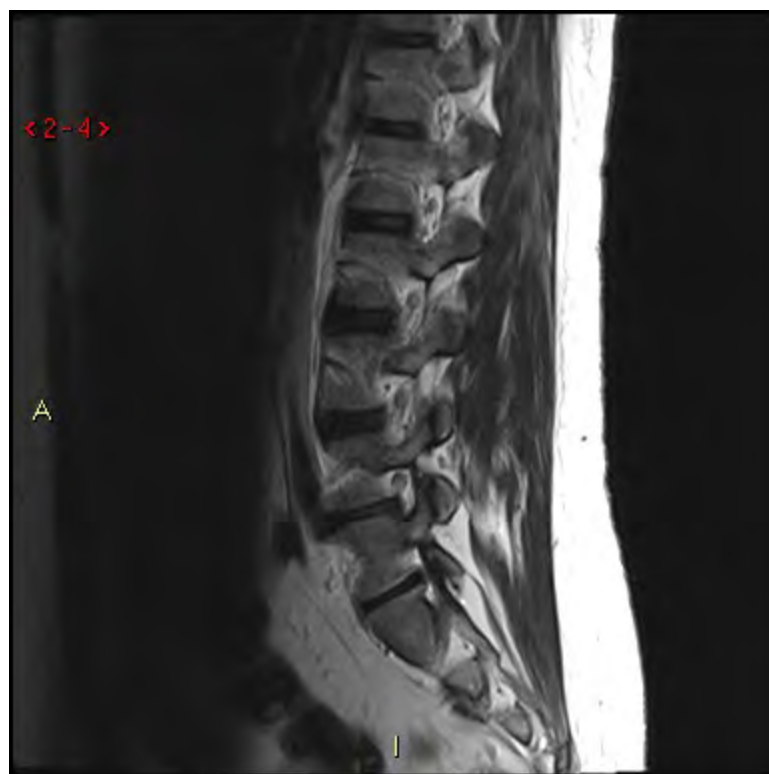# Fall 12

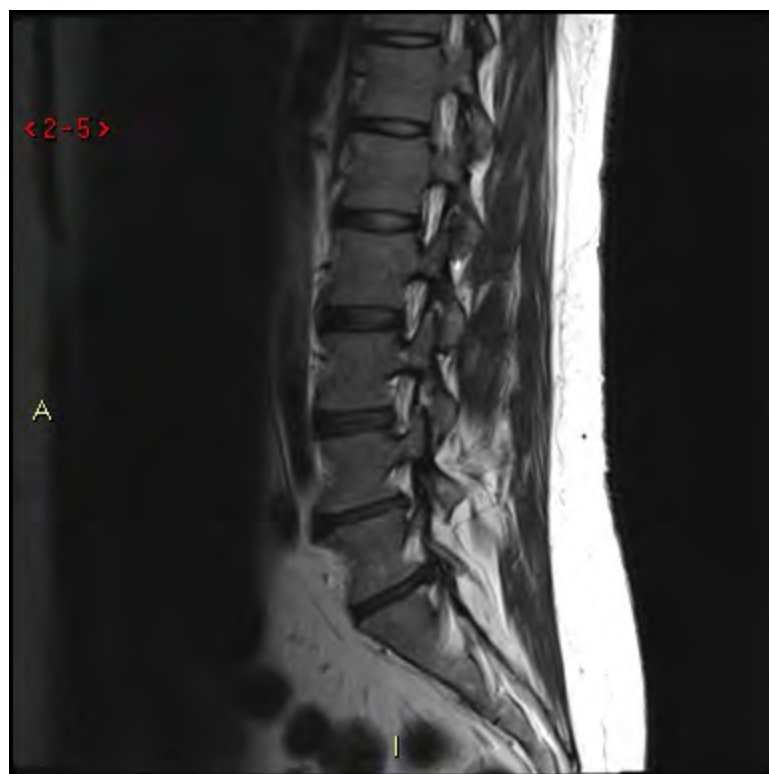35år K. Inkommer pga smärta utsida  
underbenen sedan 2mån. Sista 2v  
försämring. Minskad sens i S1-området.

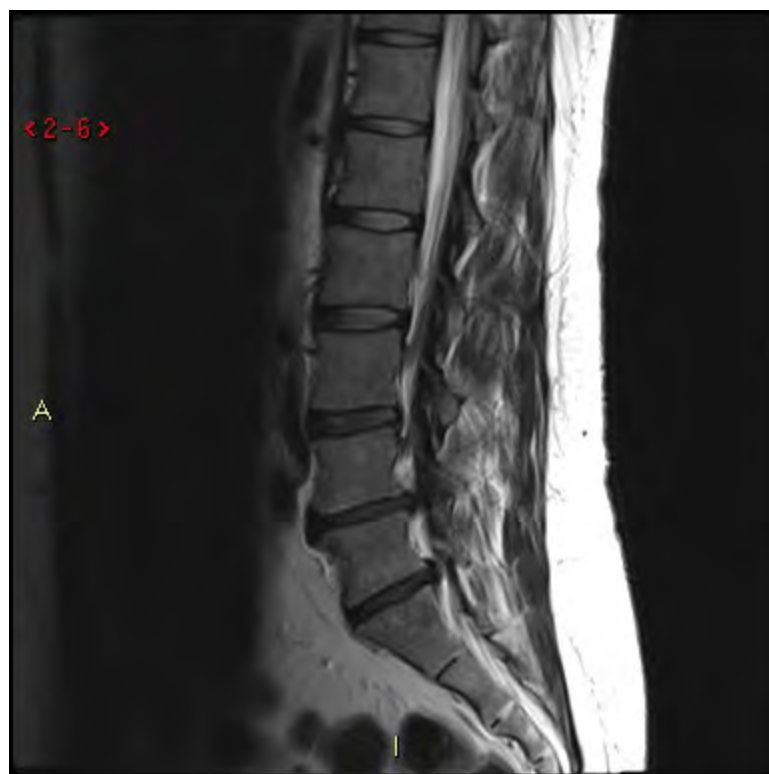




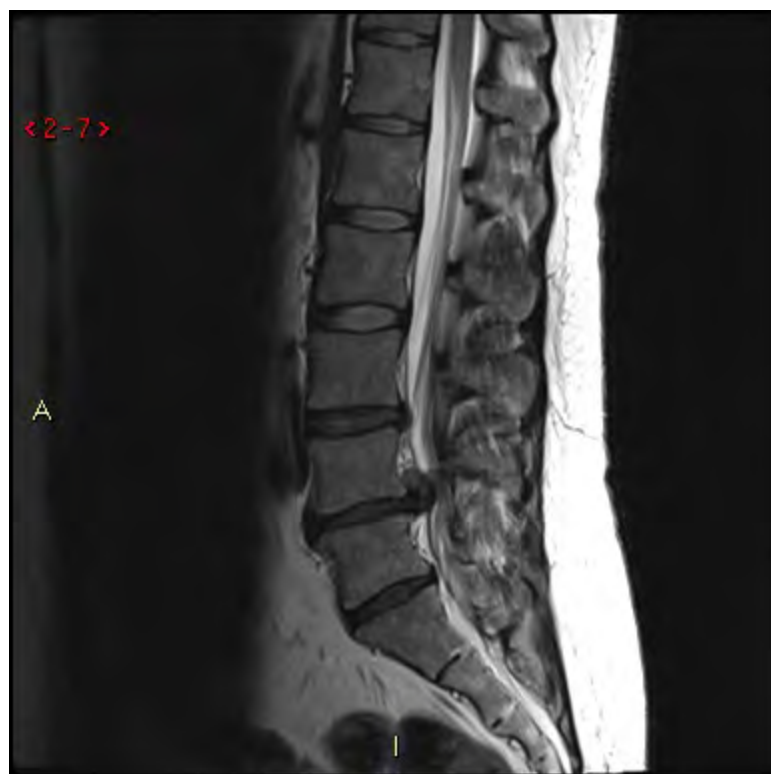


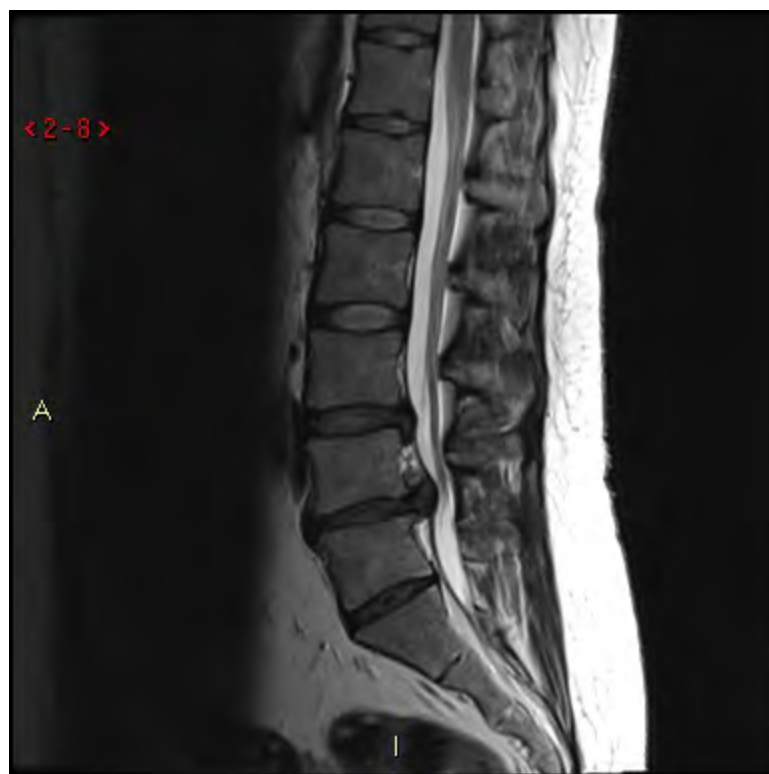


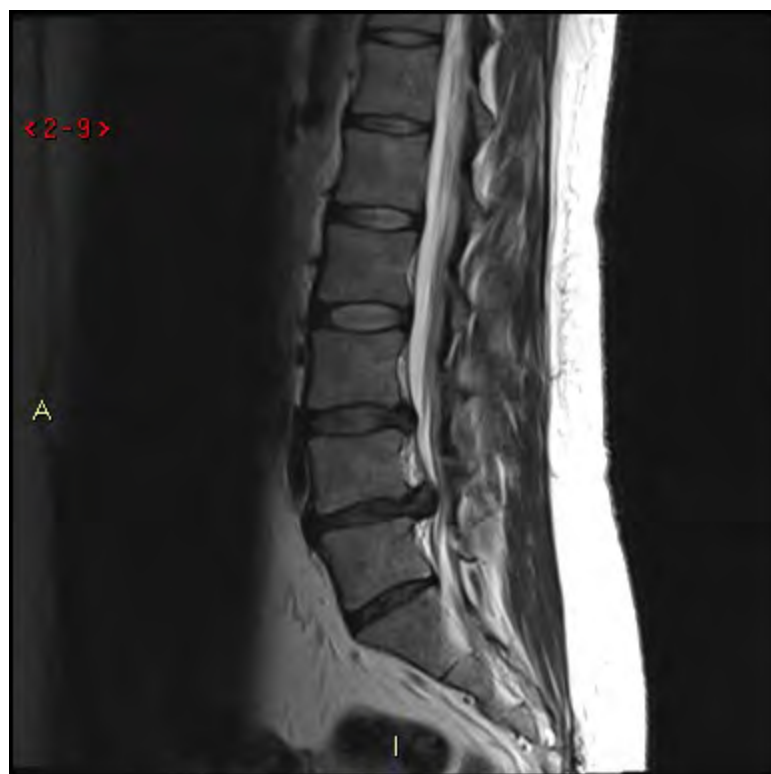


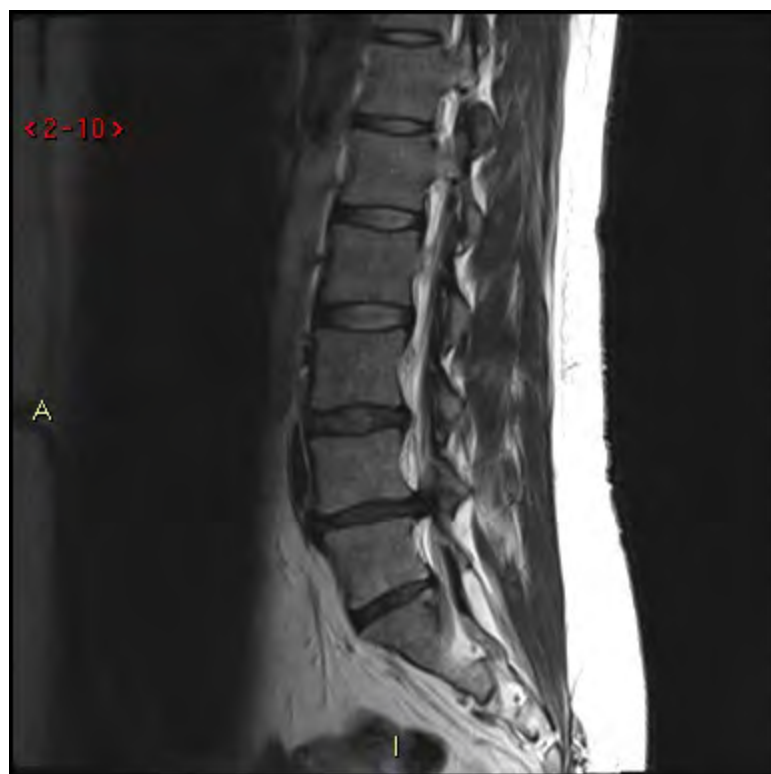


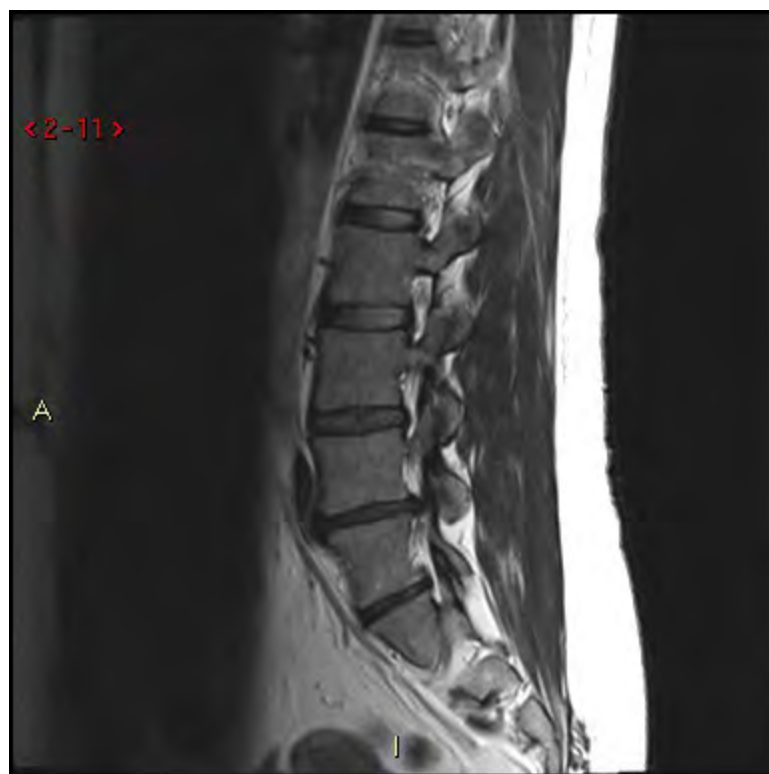
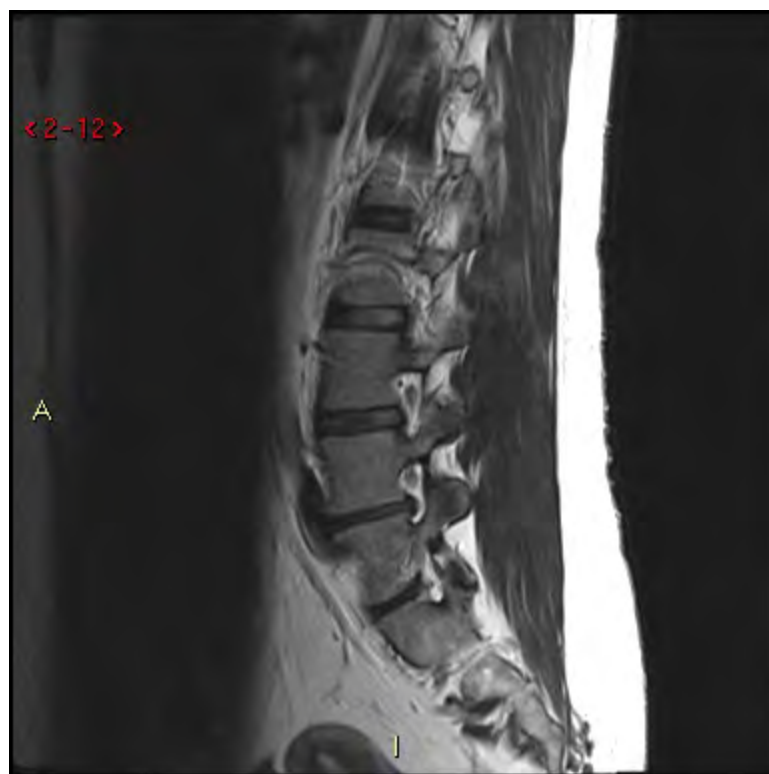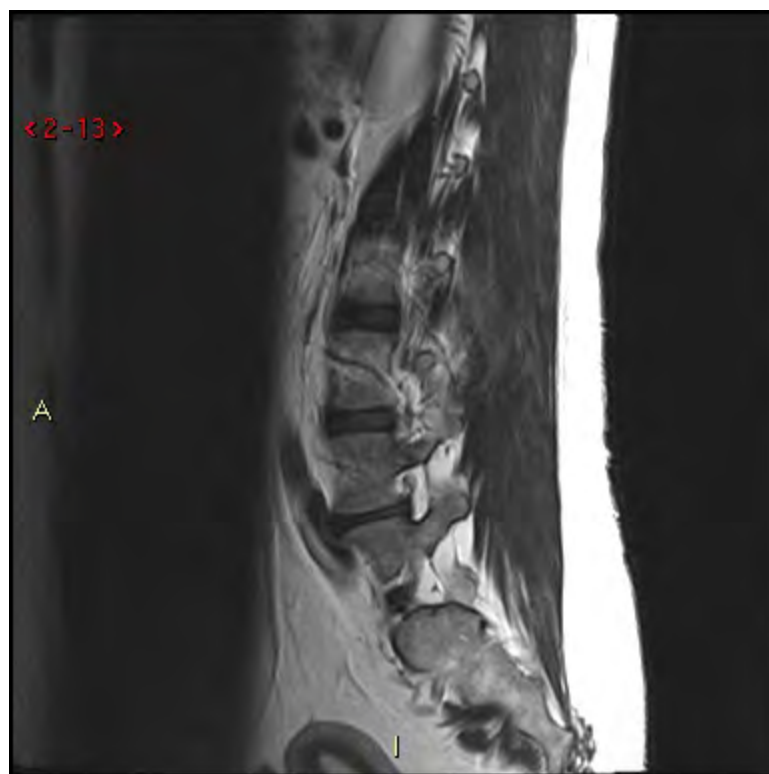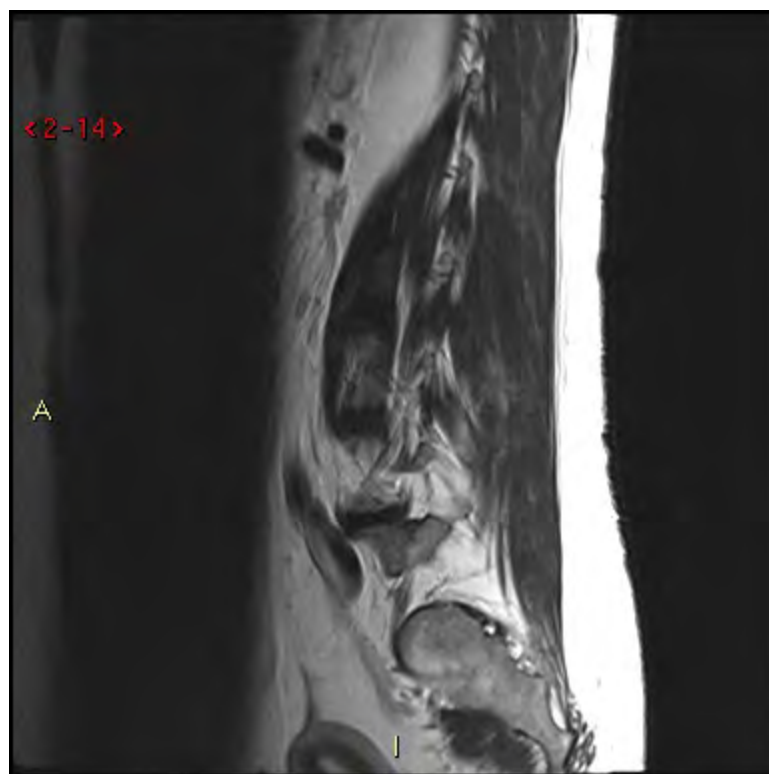




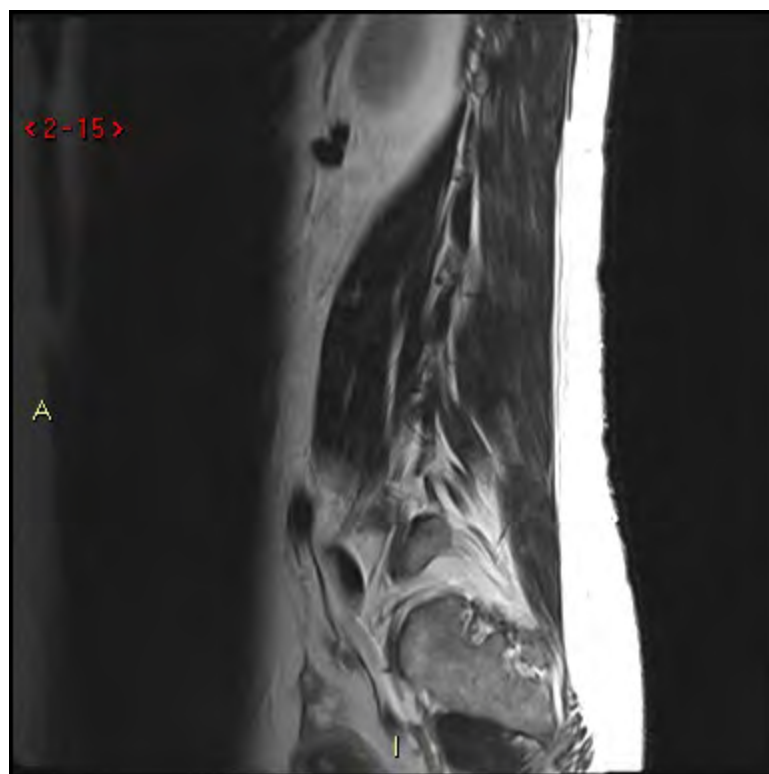


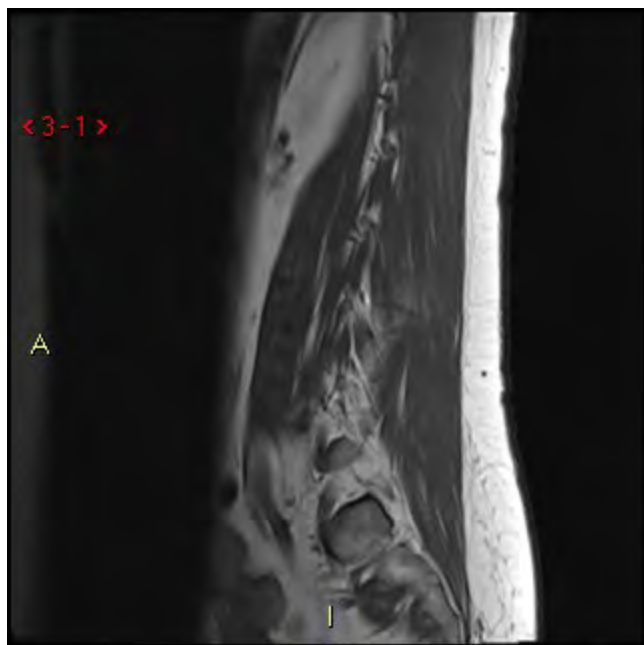


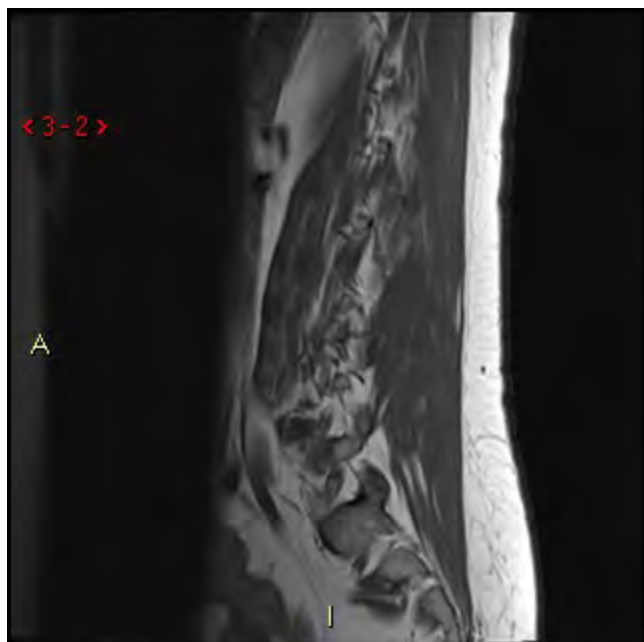










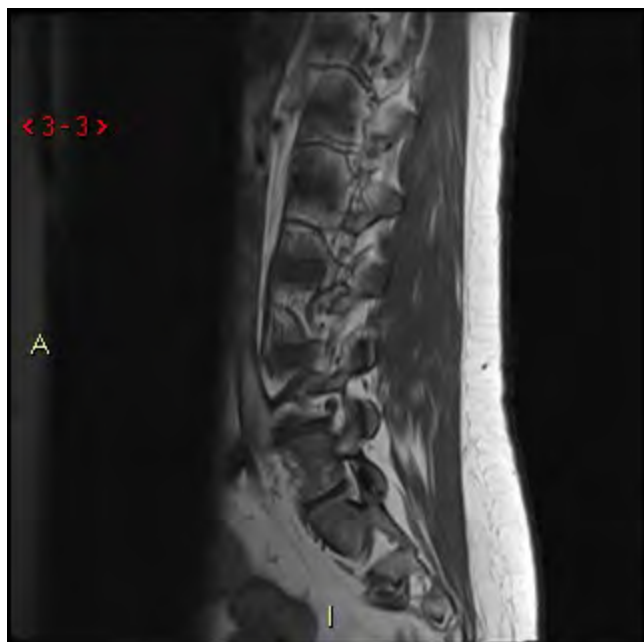


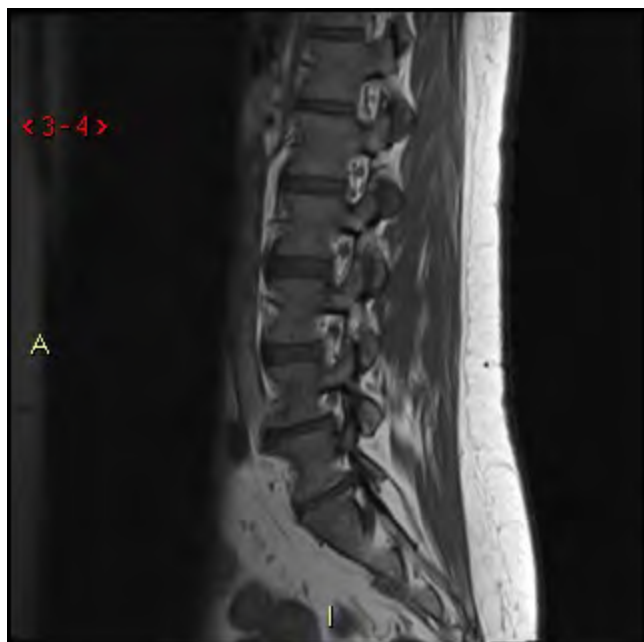


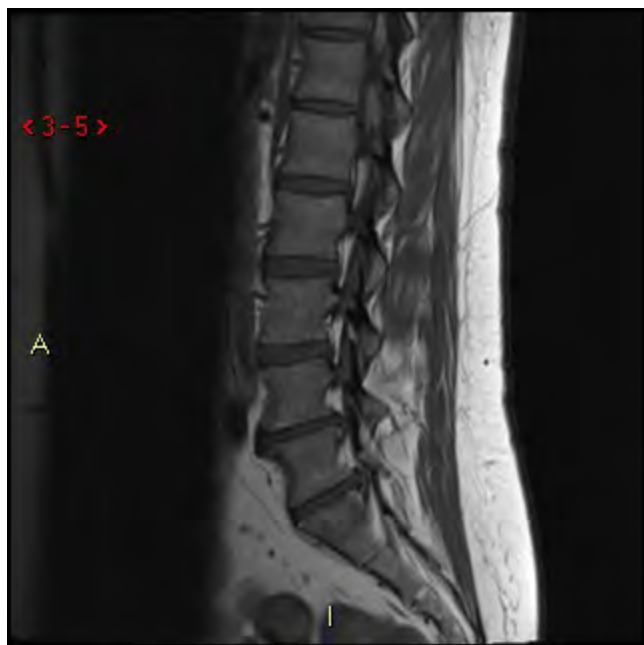


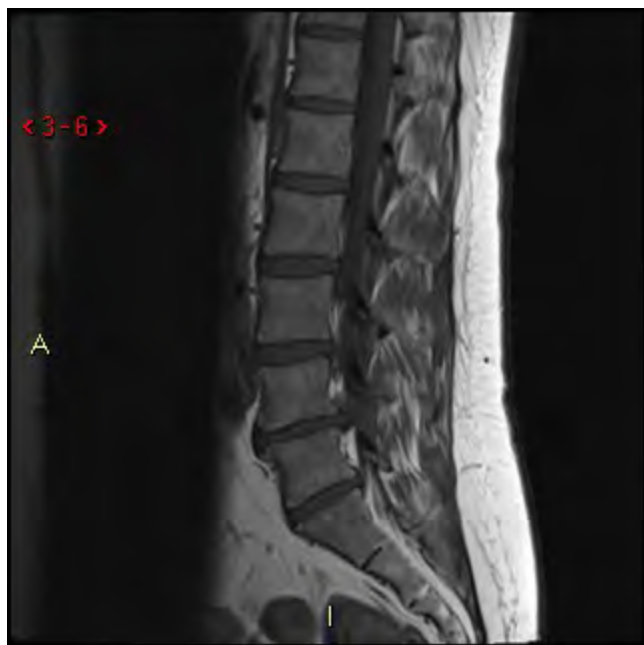


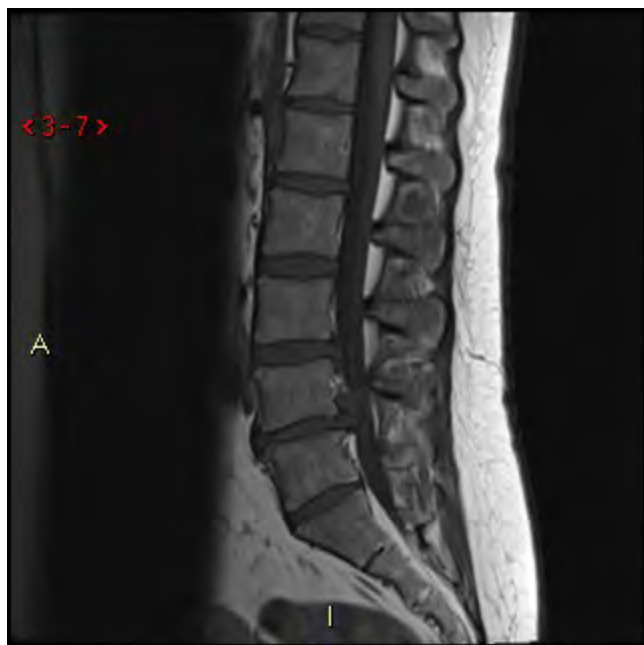



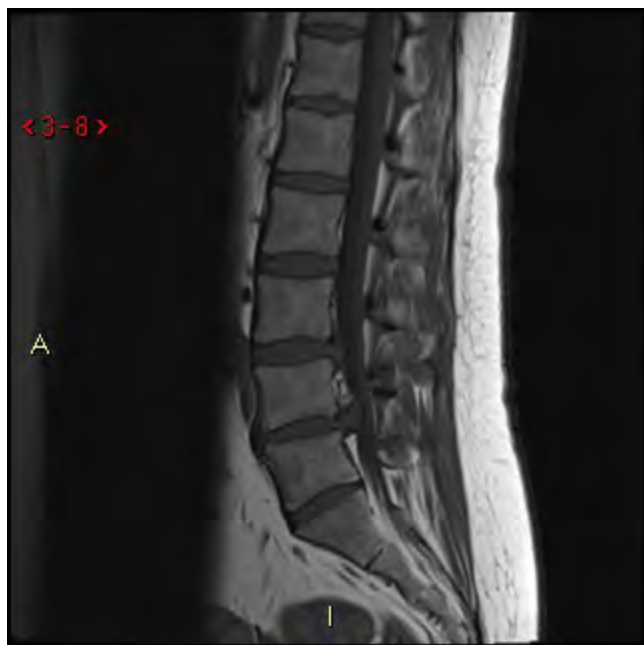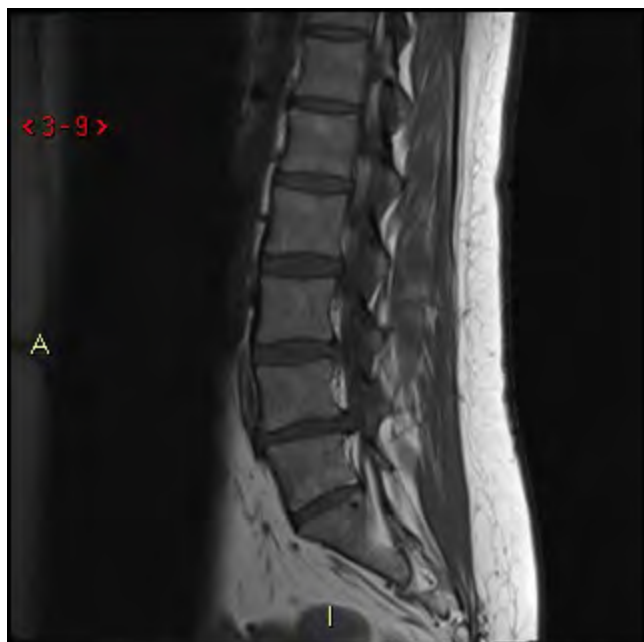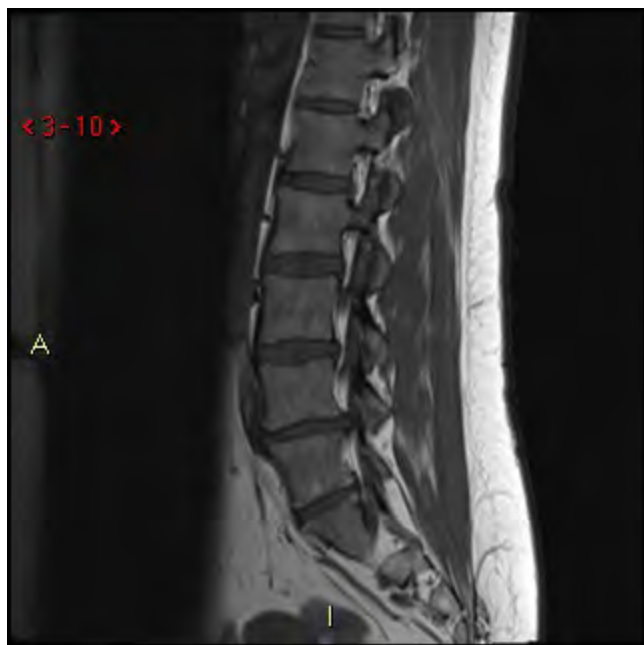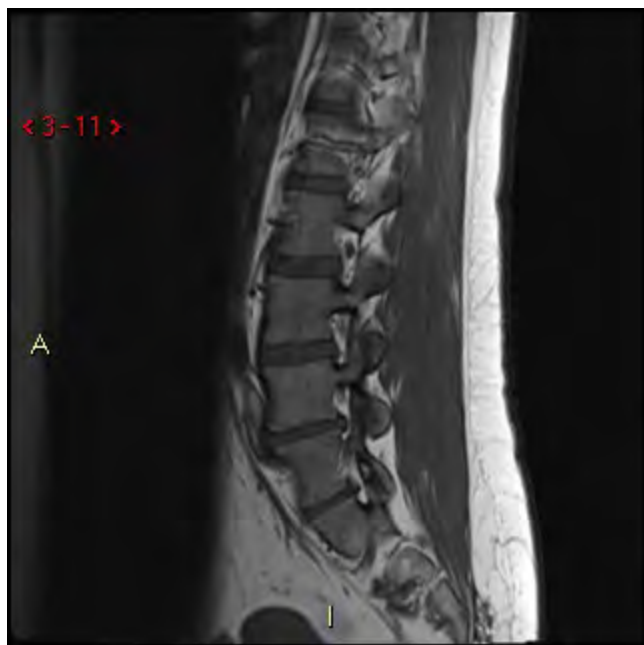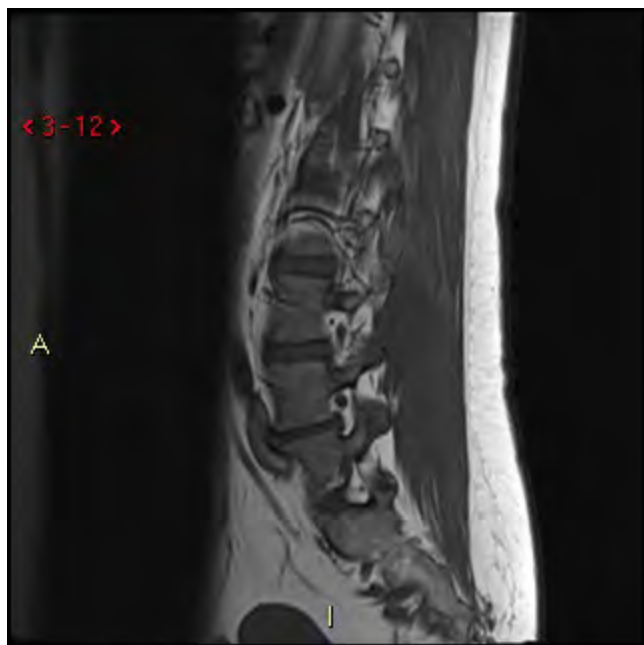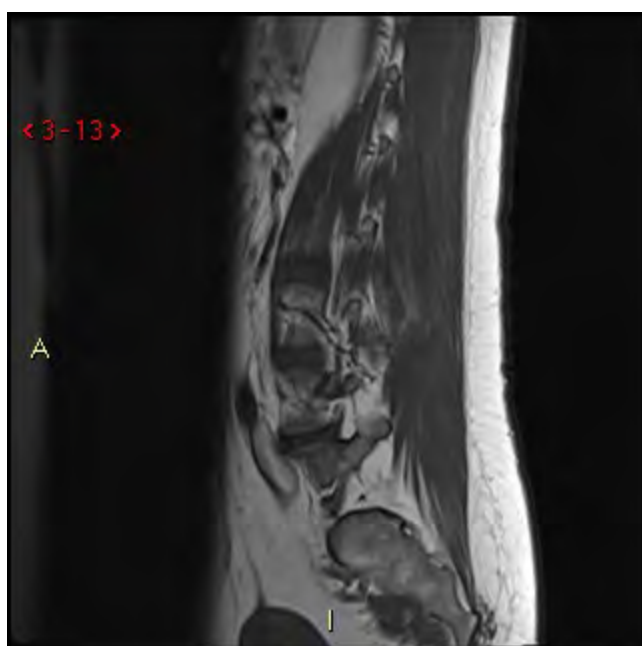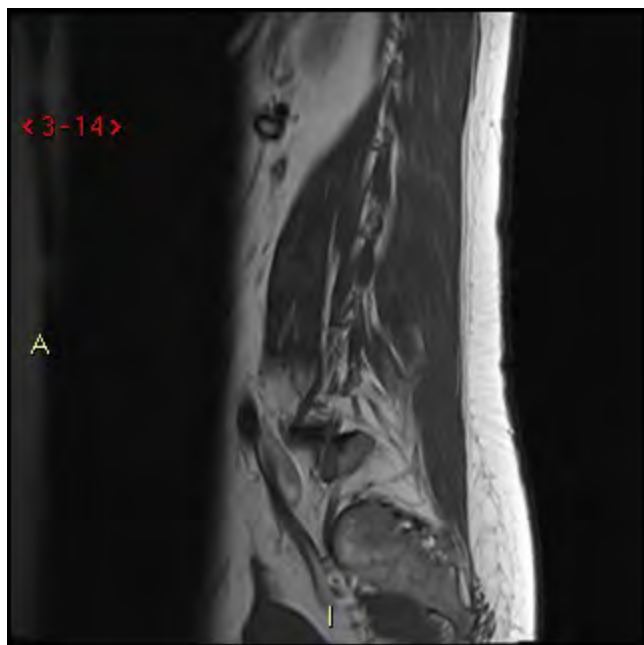


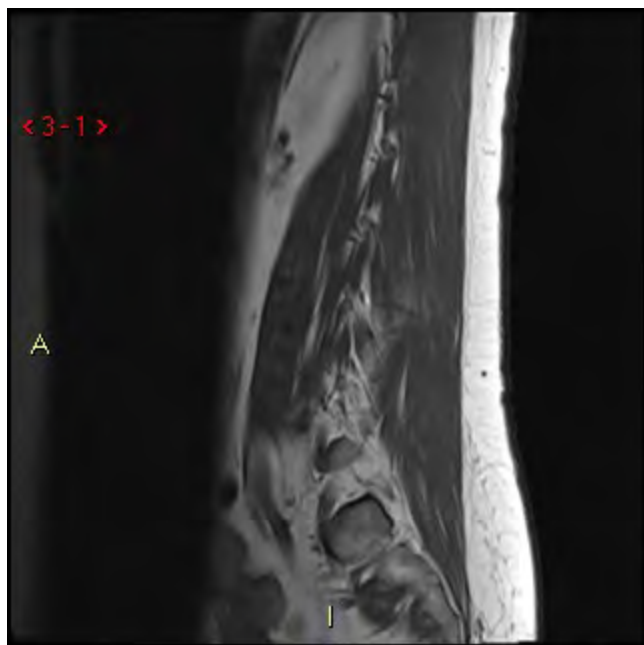




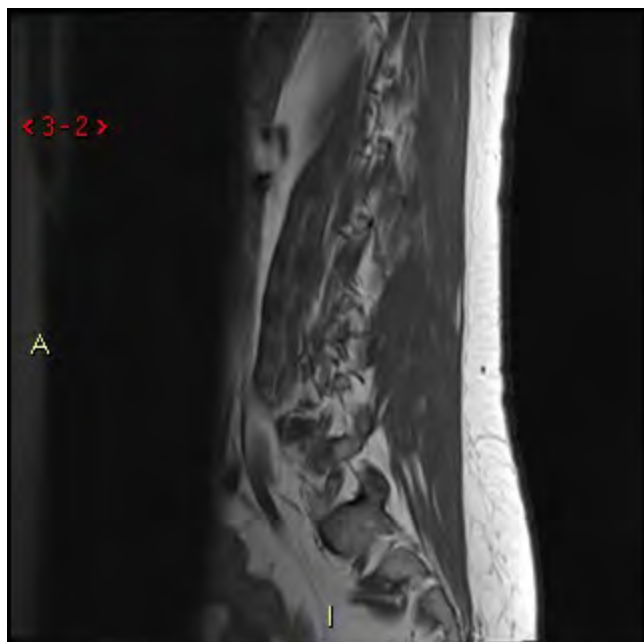


























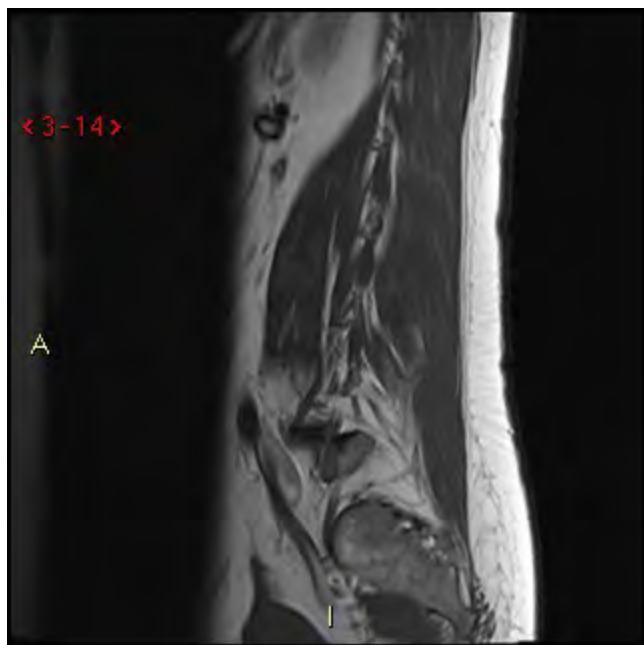


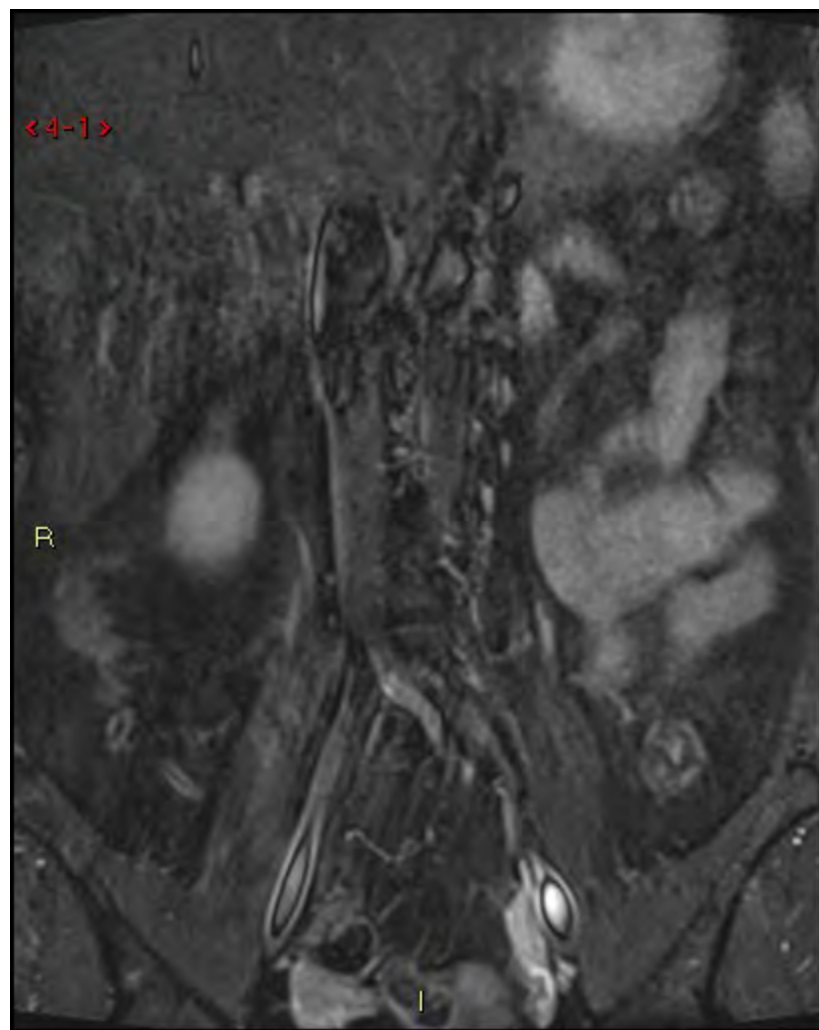


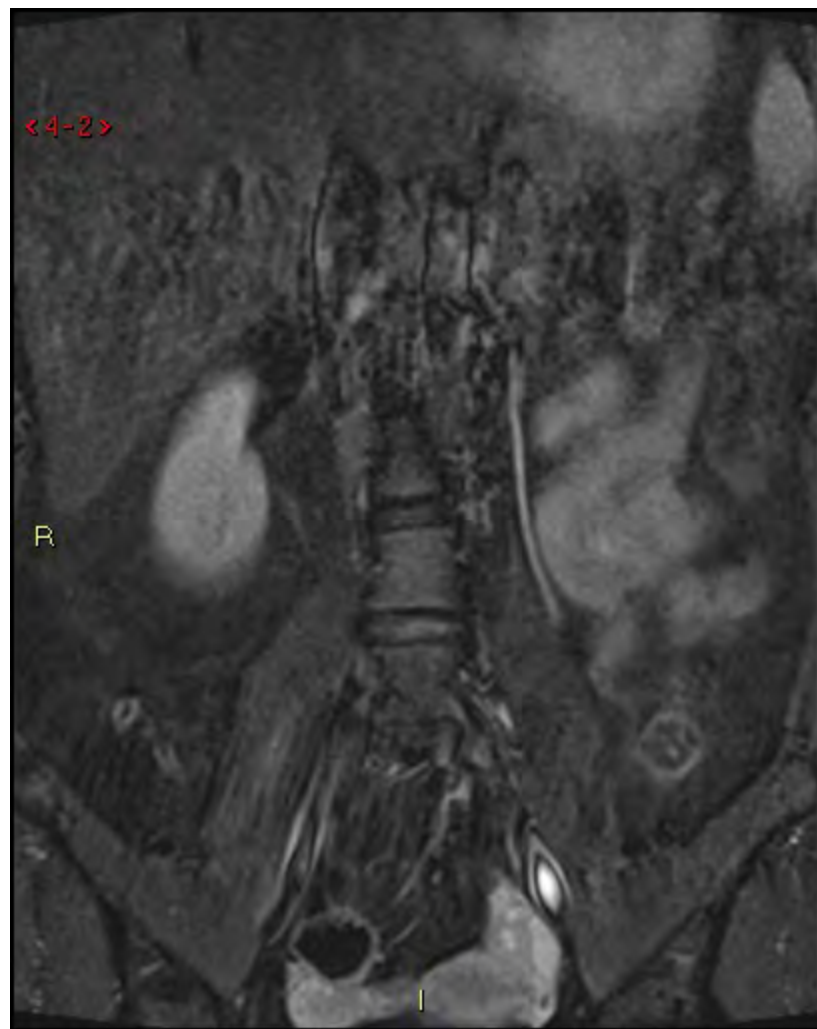






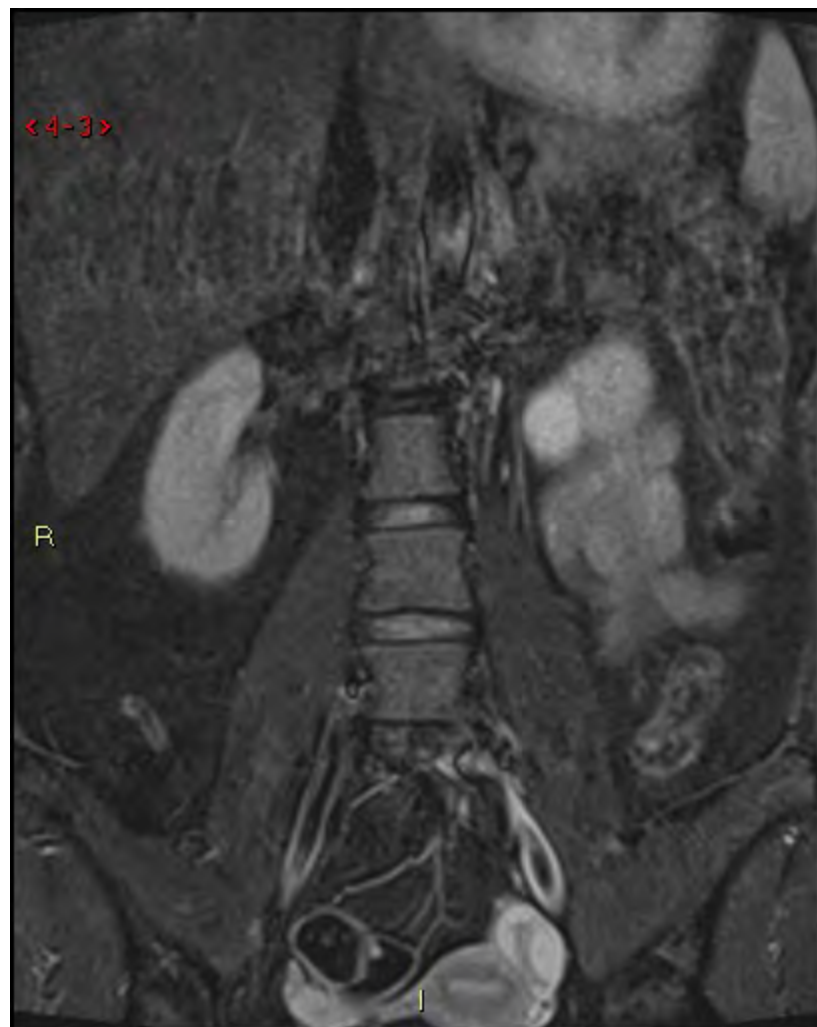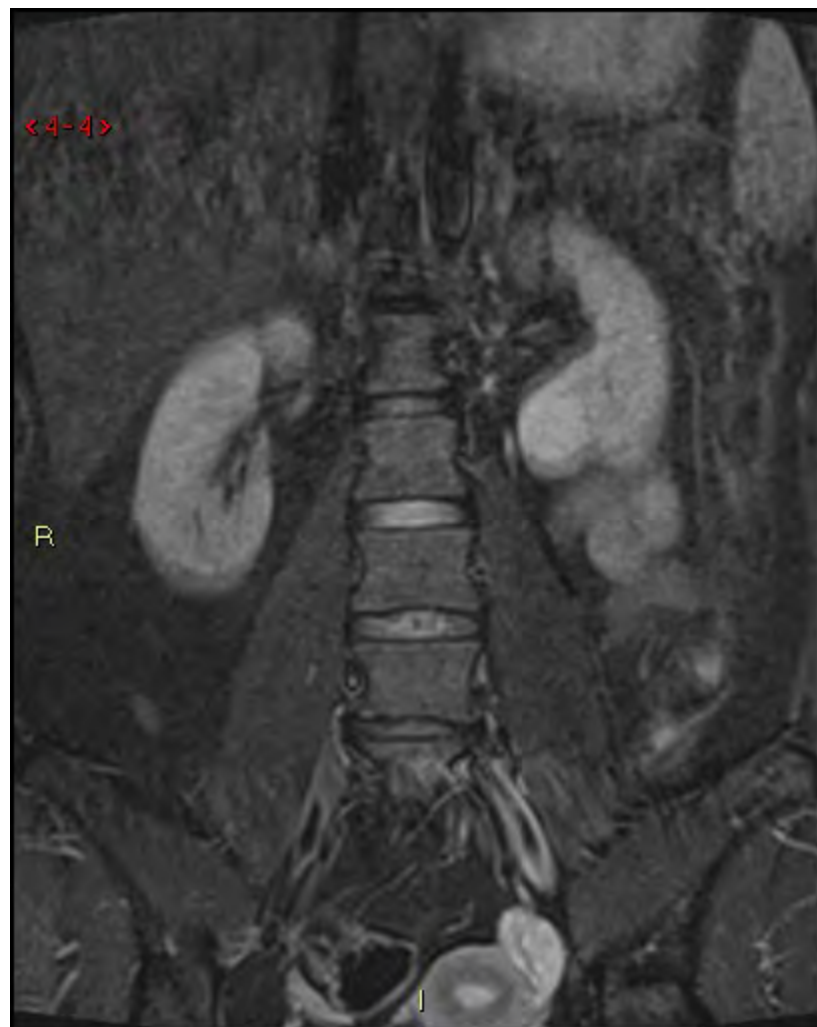


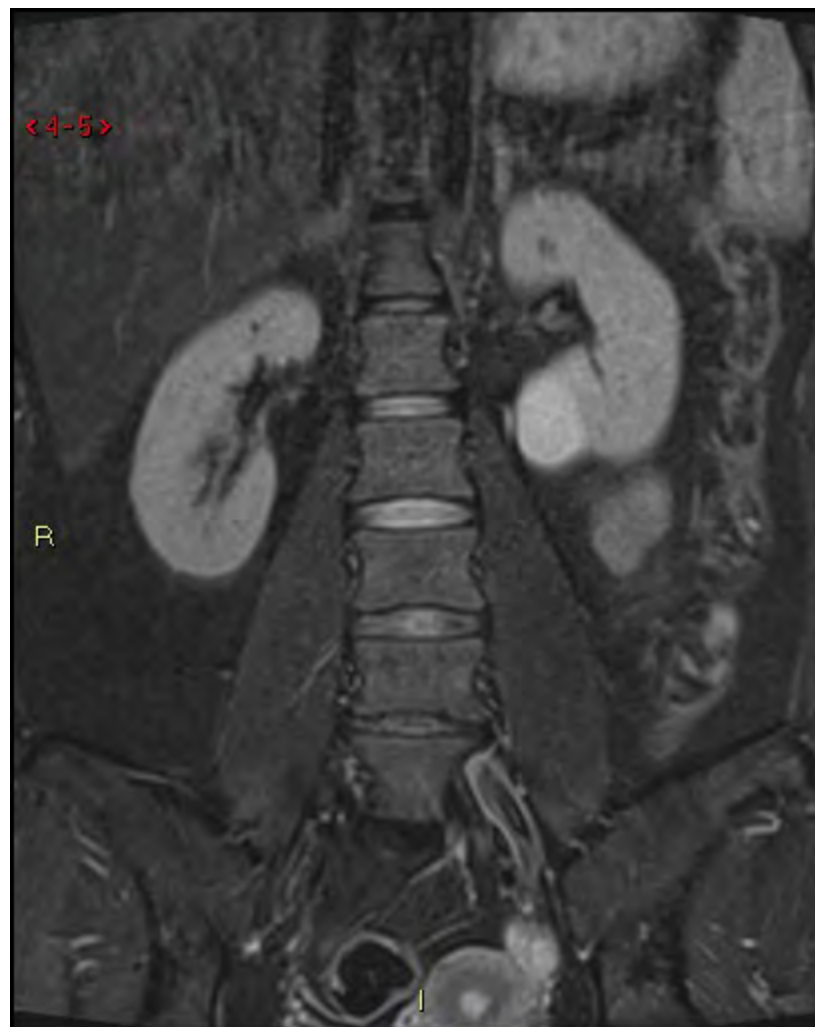




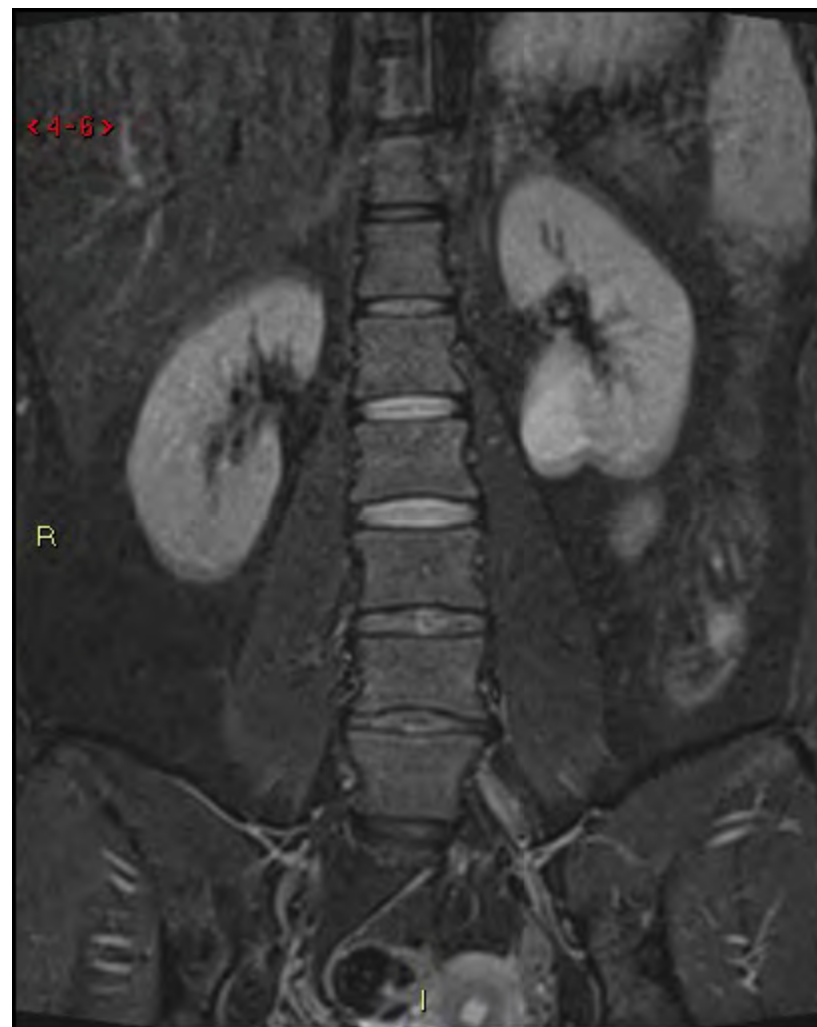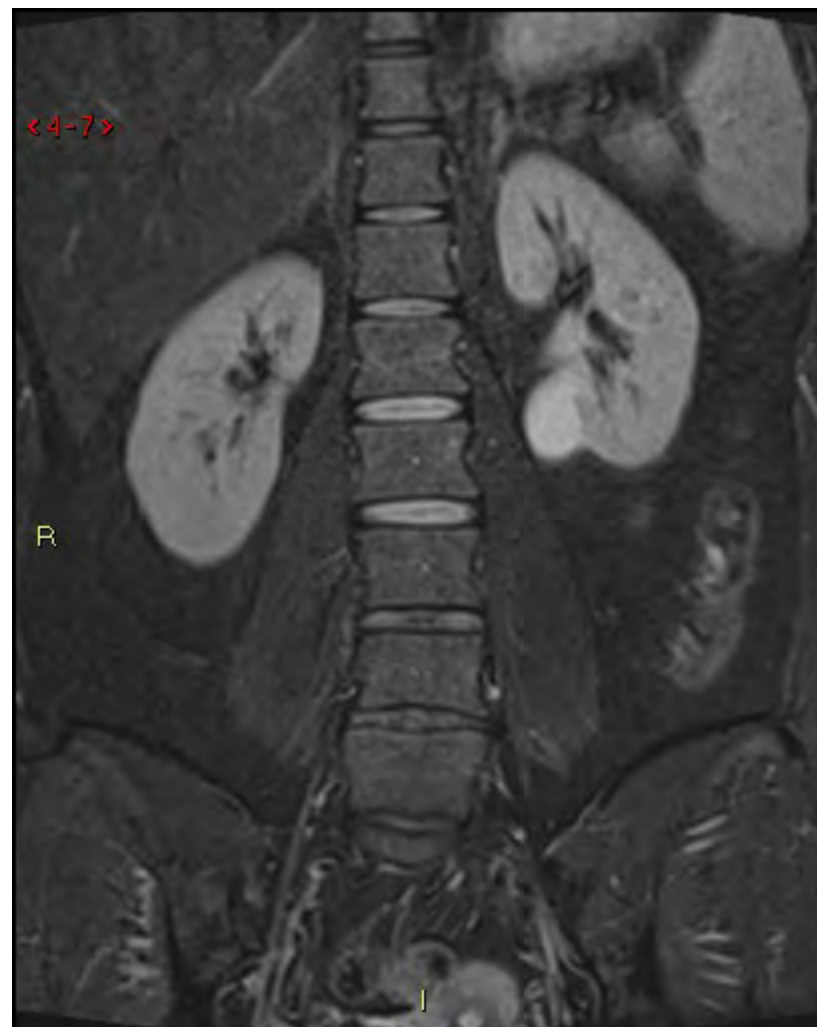




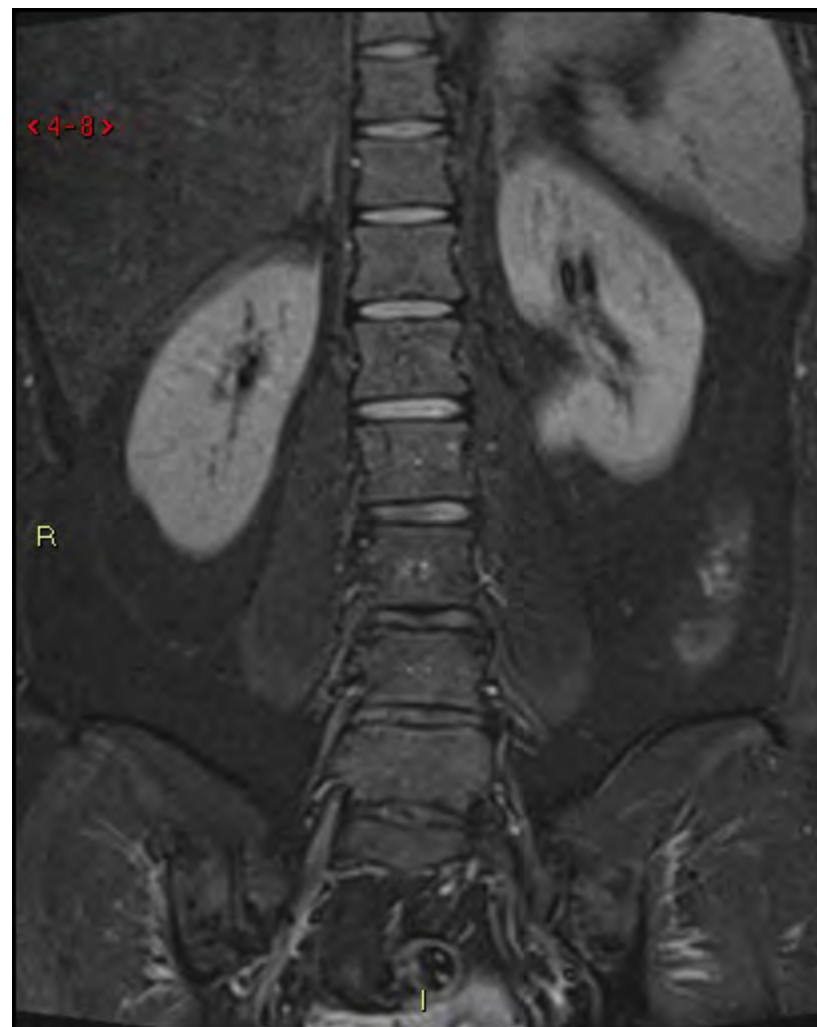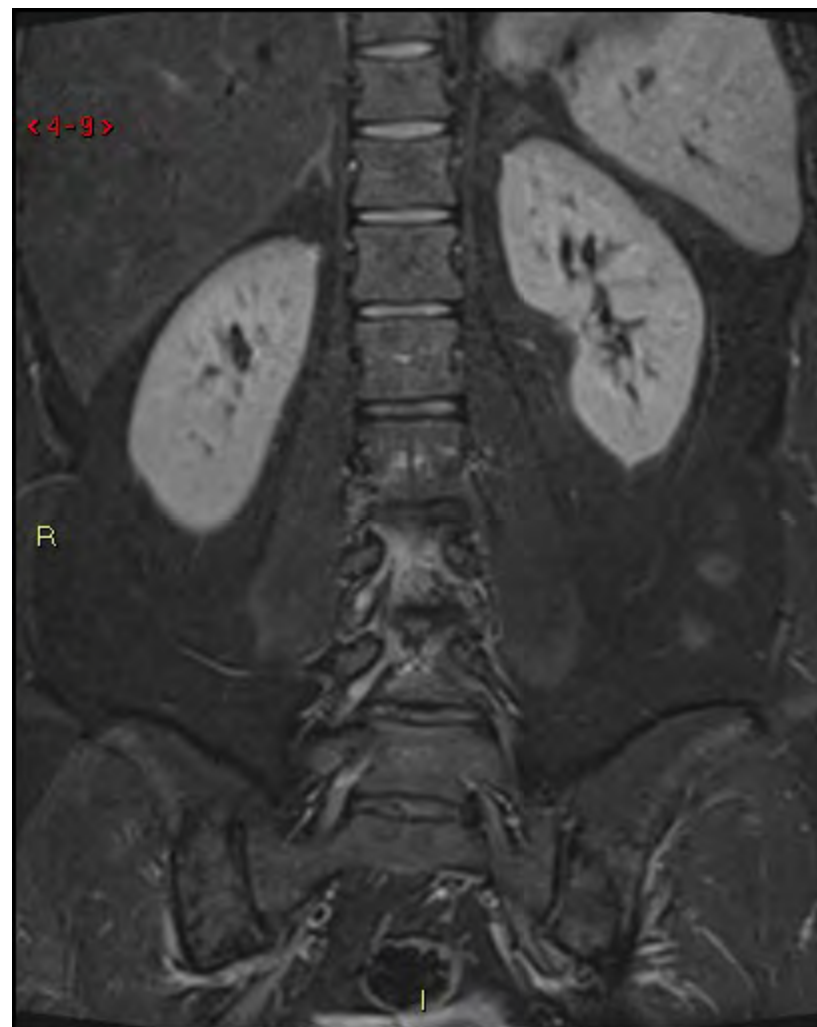


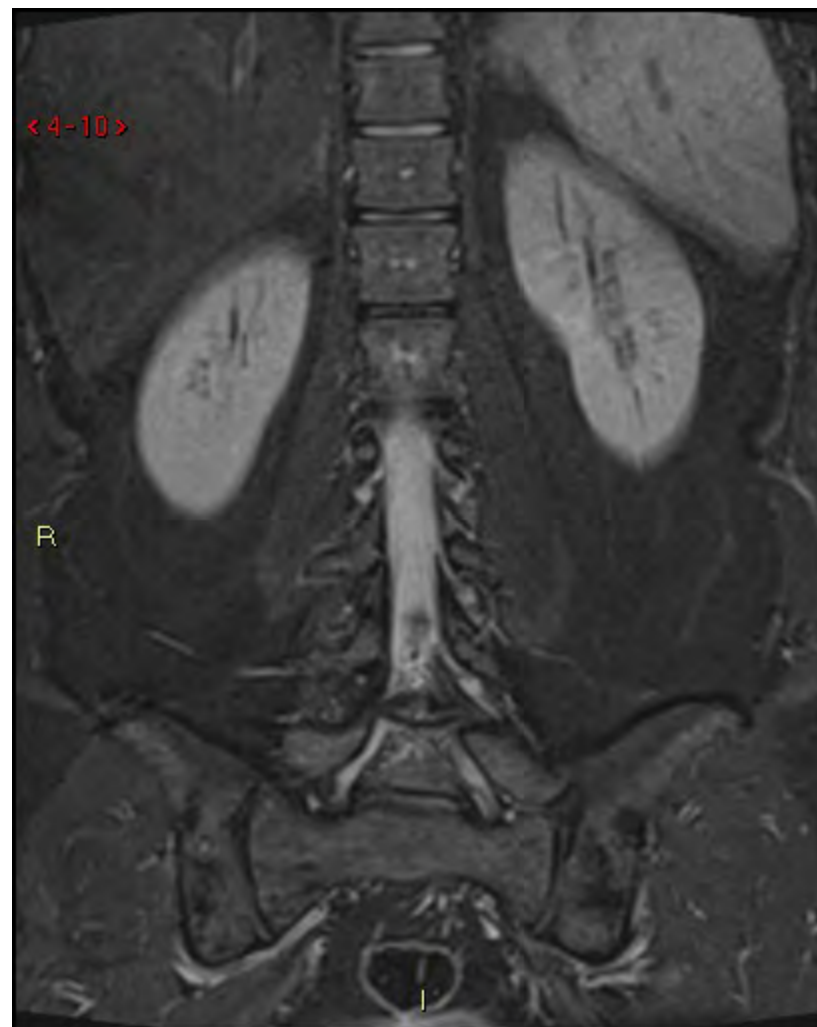






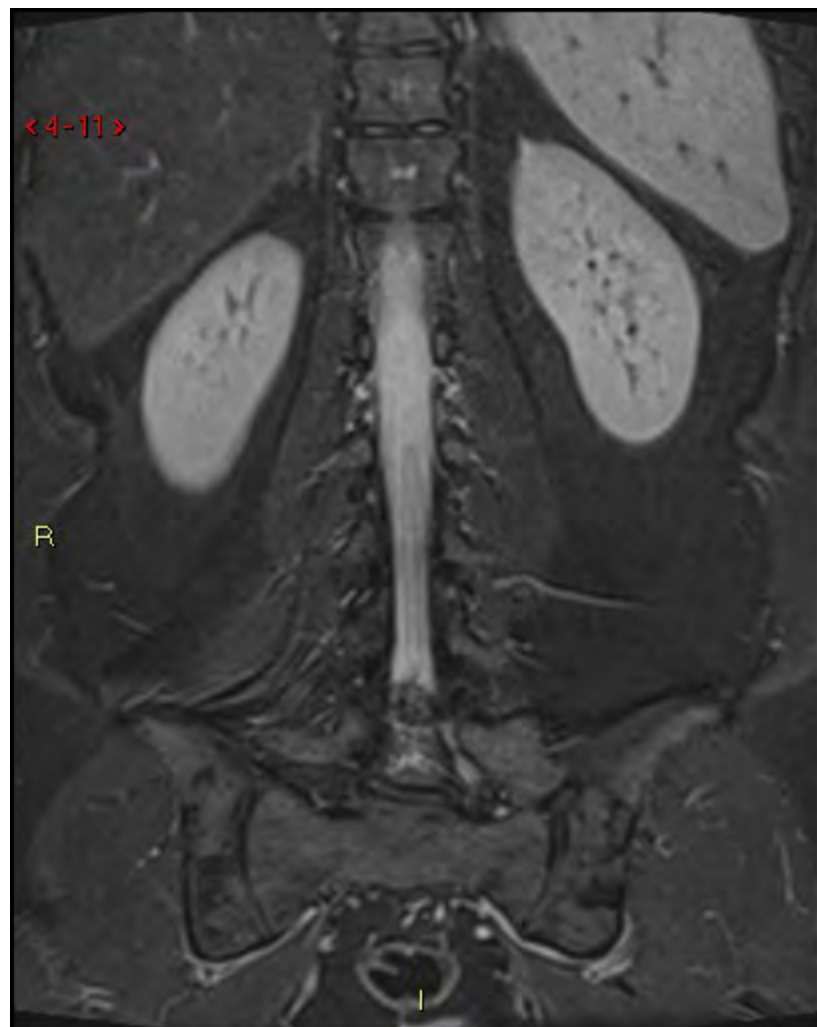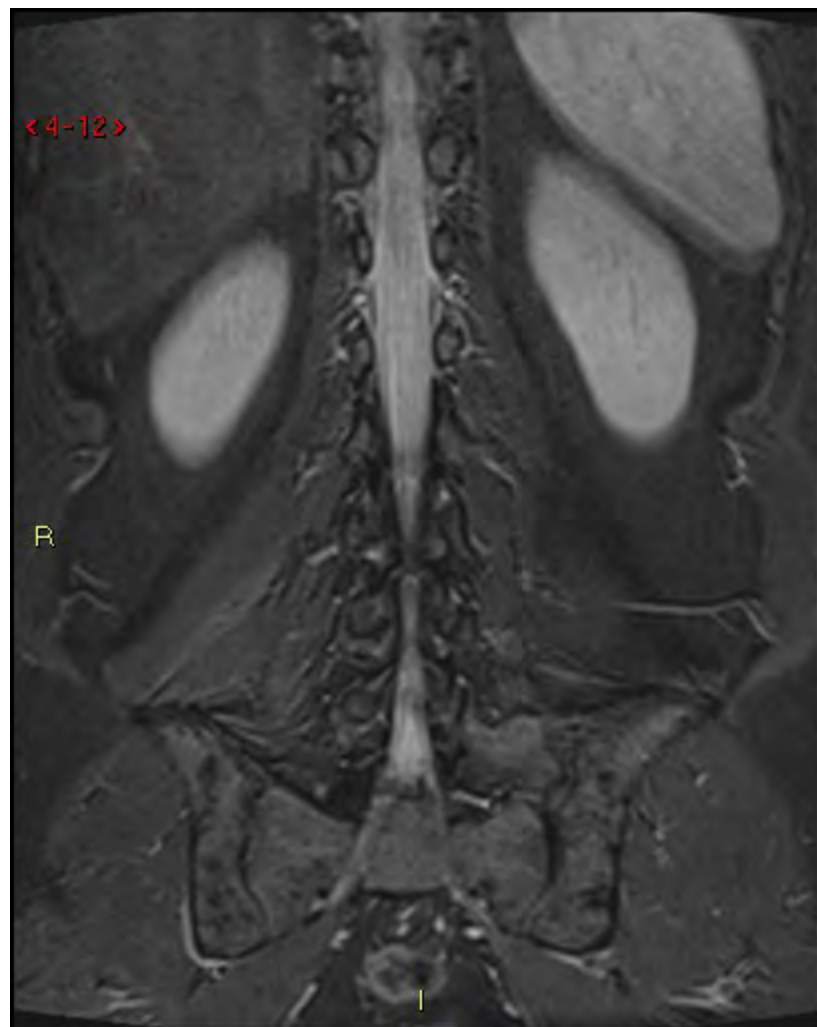


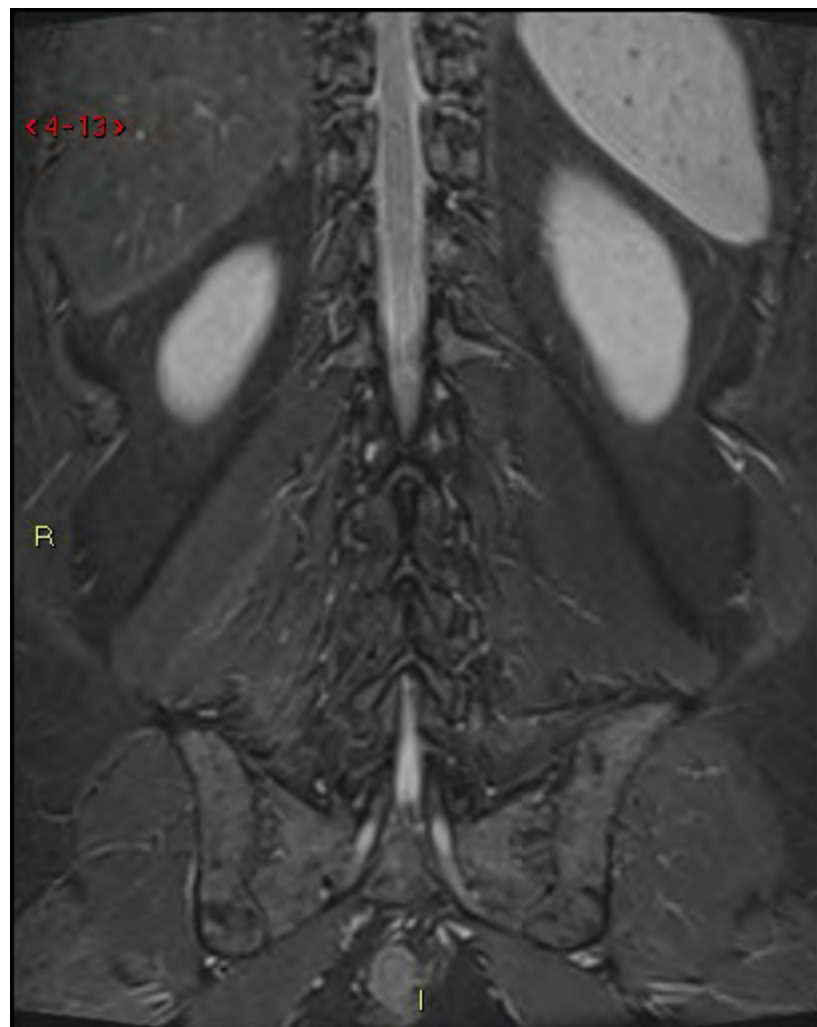


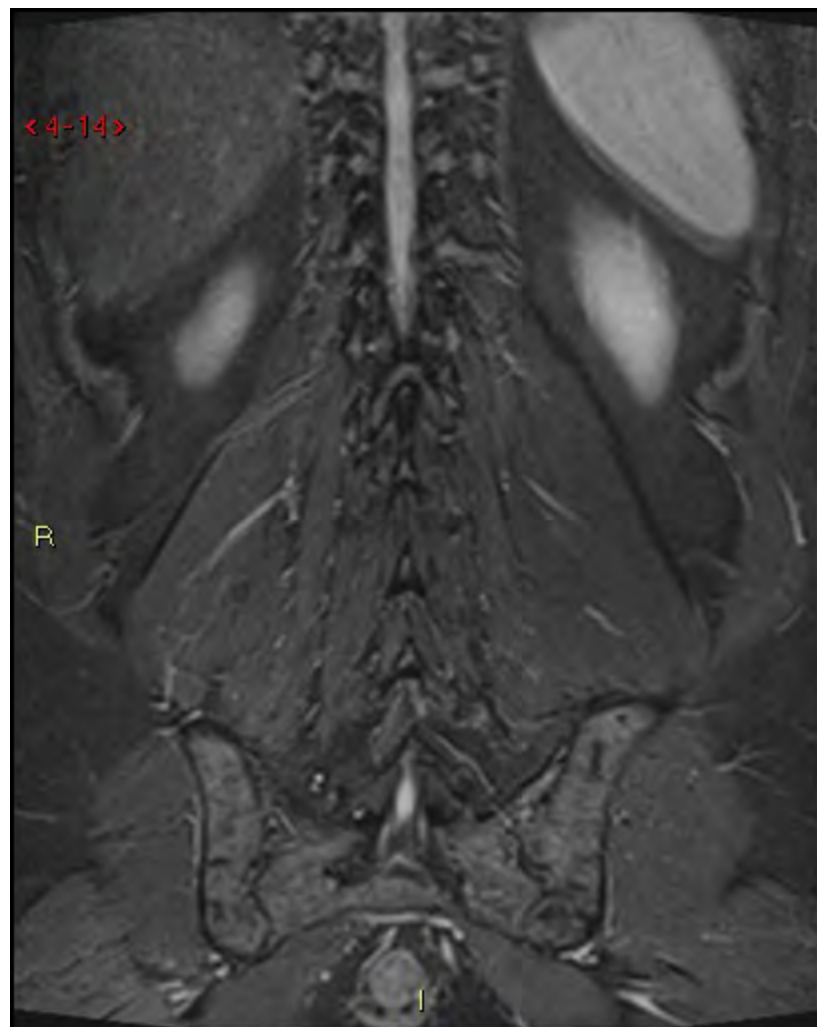






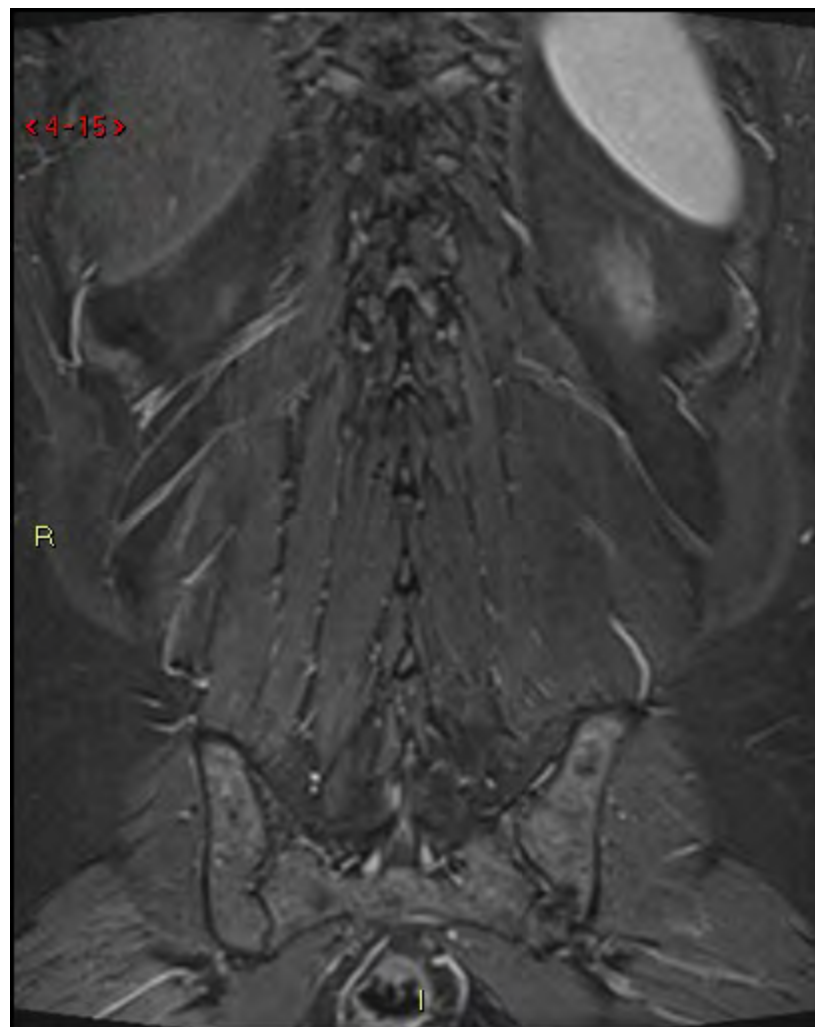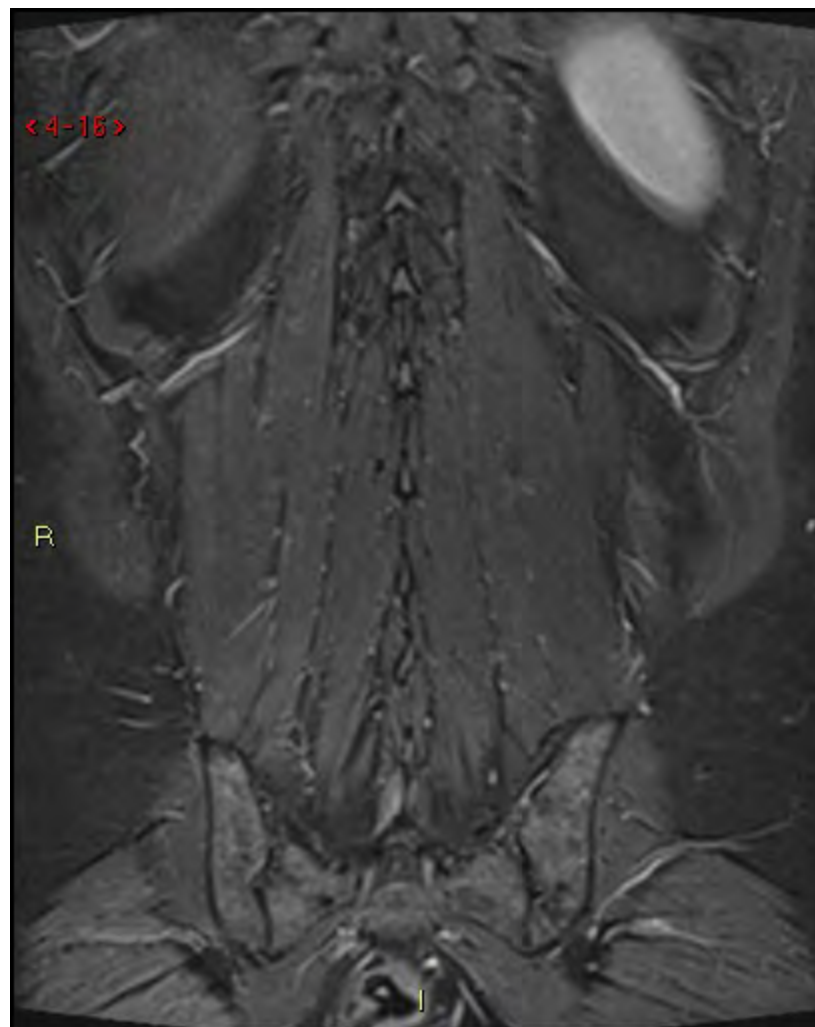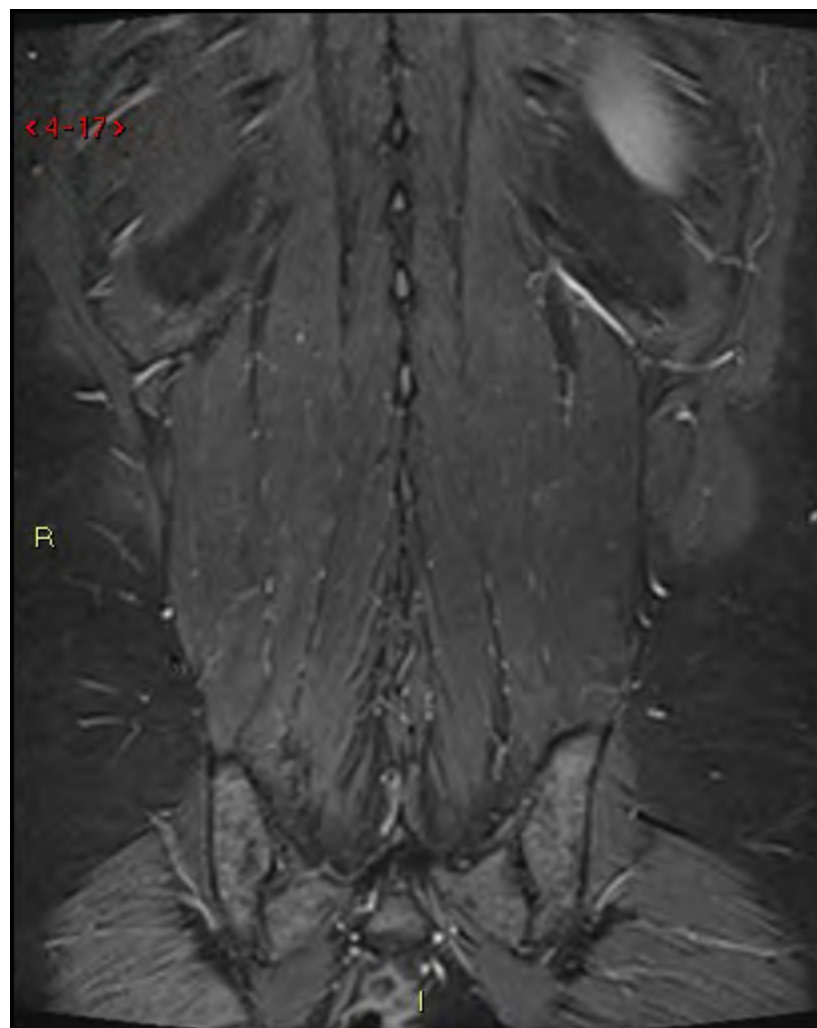


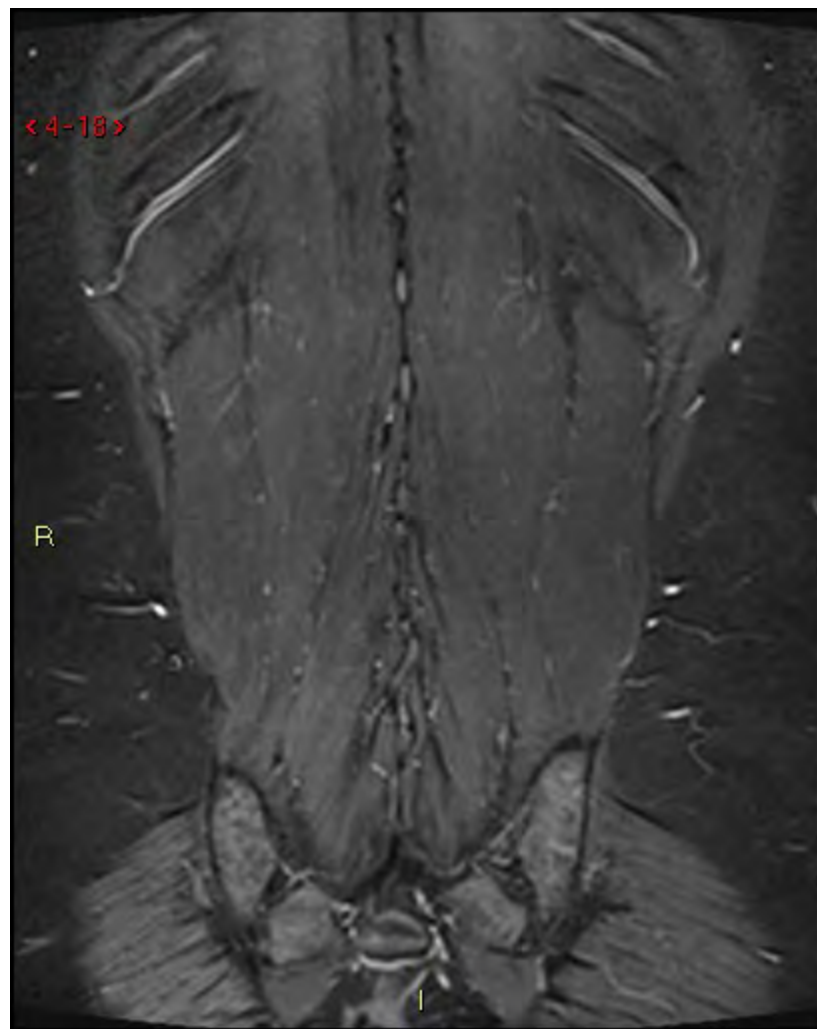


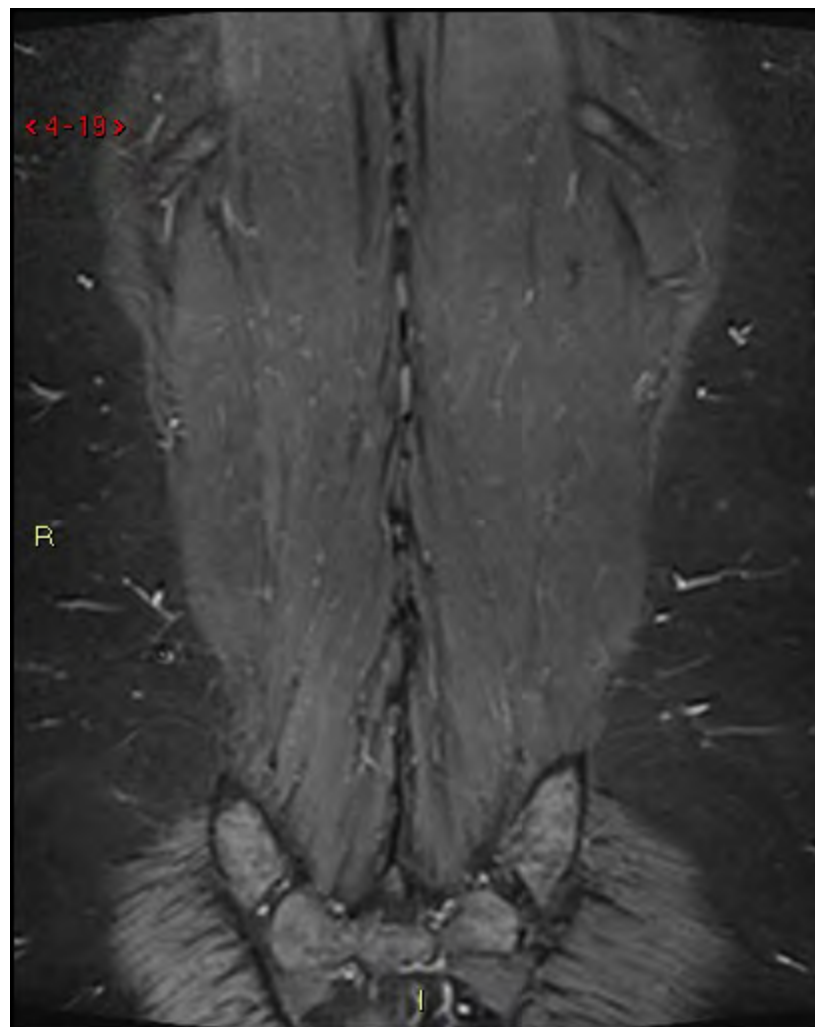




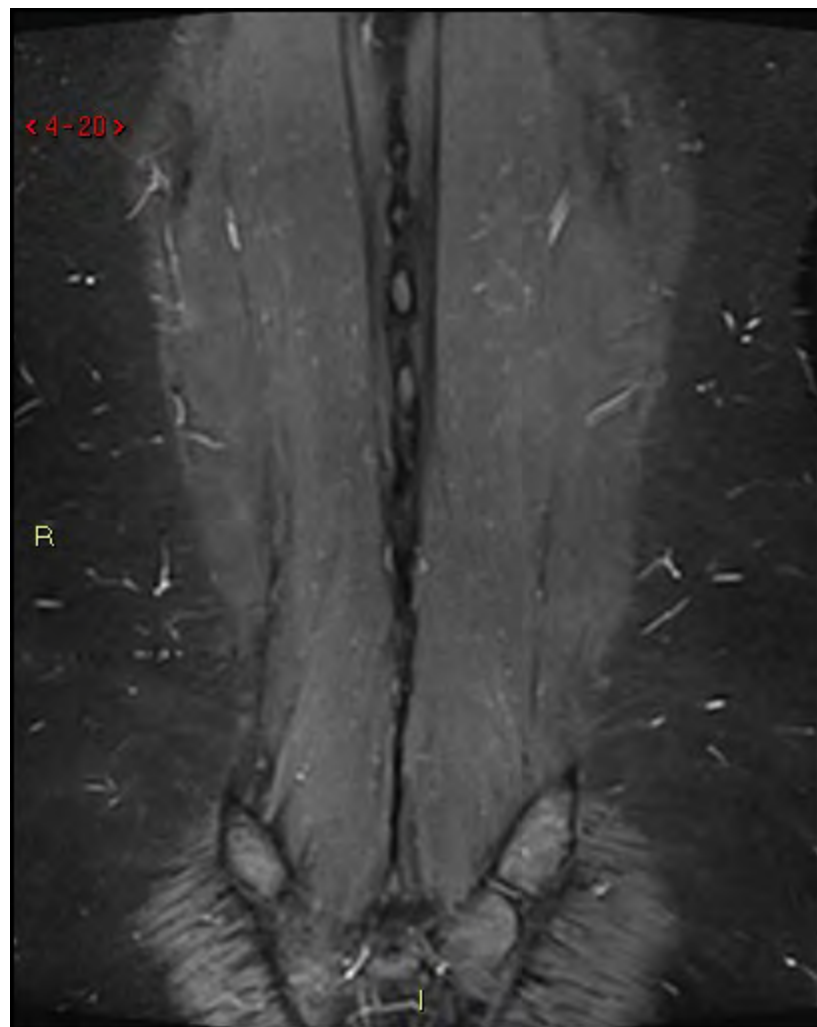








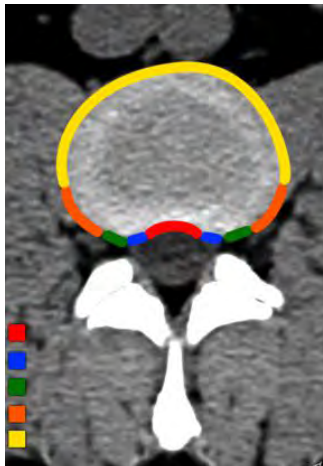
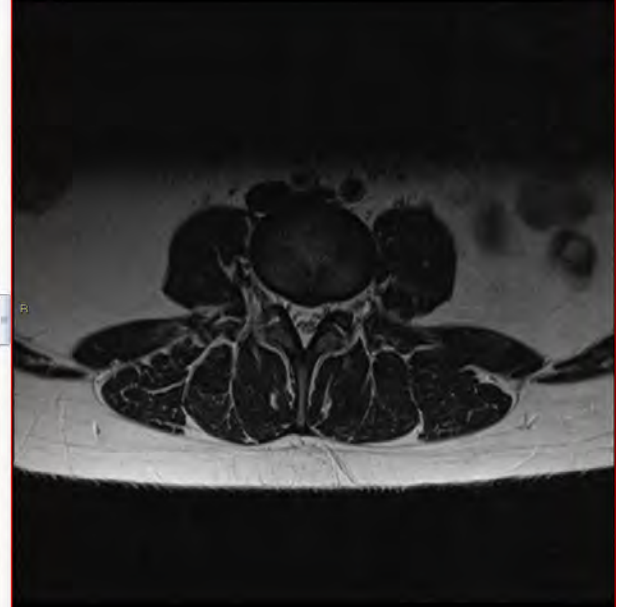
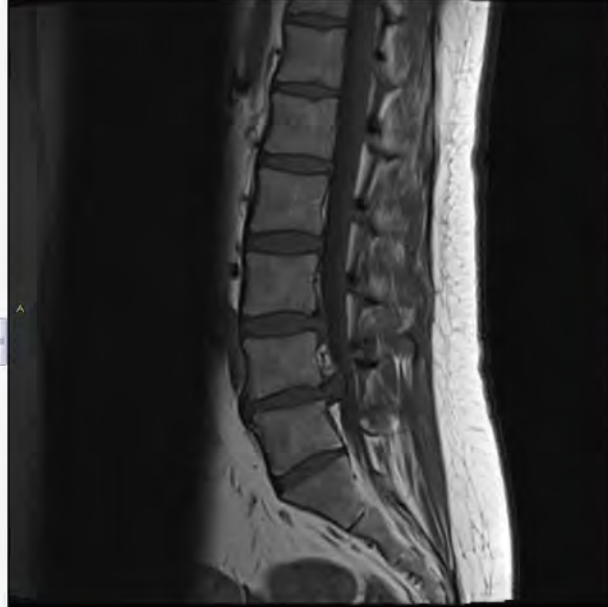
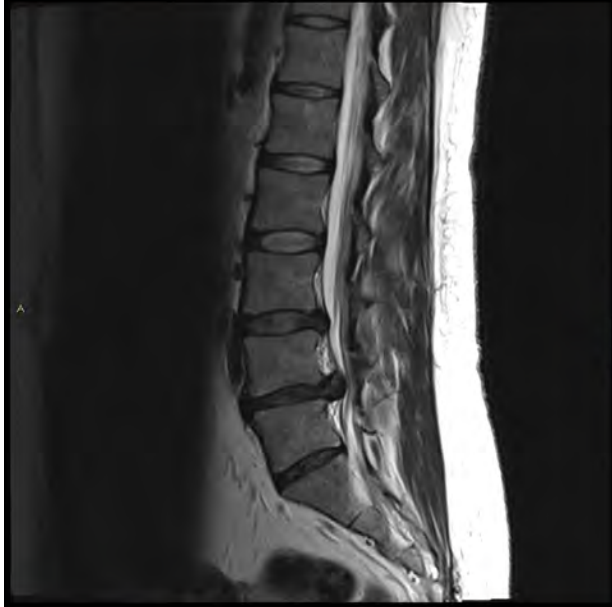




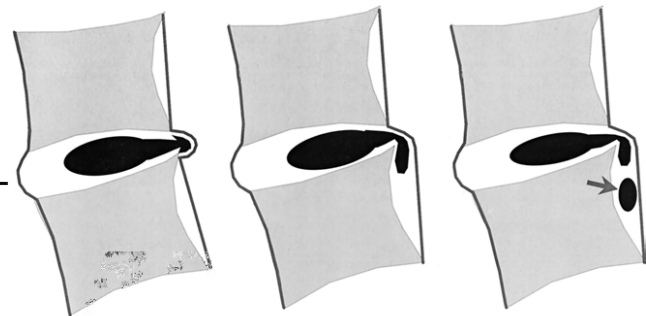
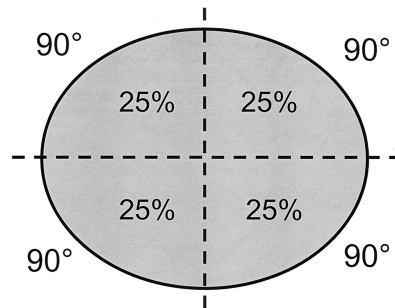
Fall 12

Fynd?

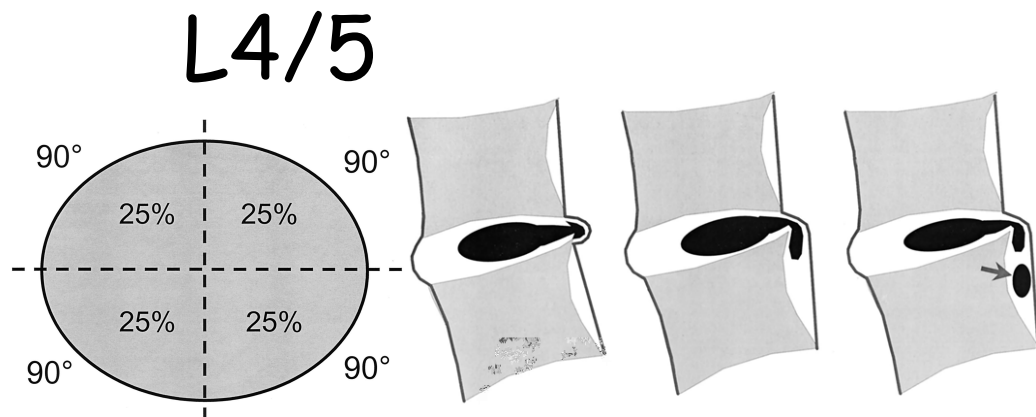
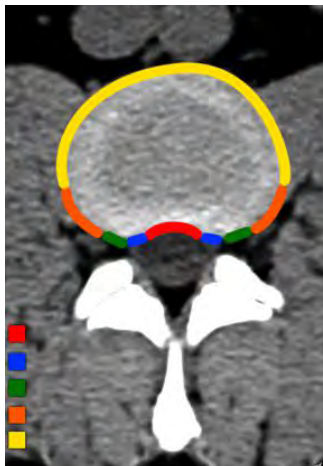
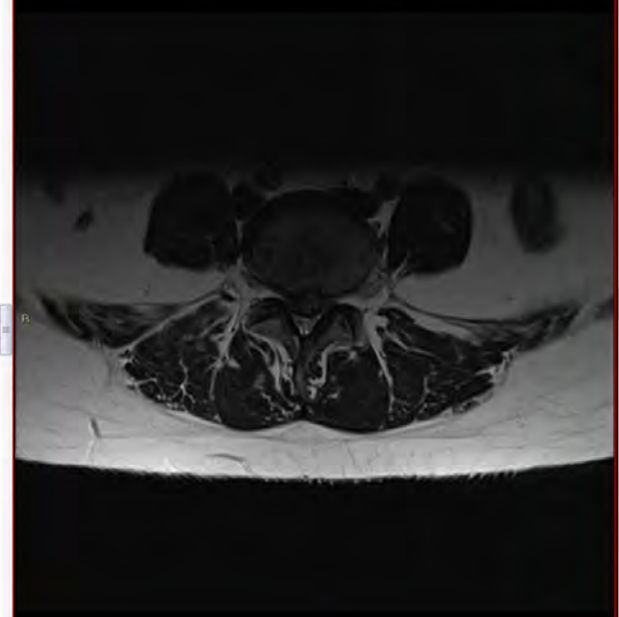
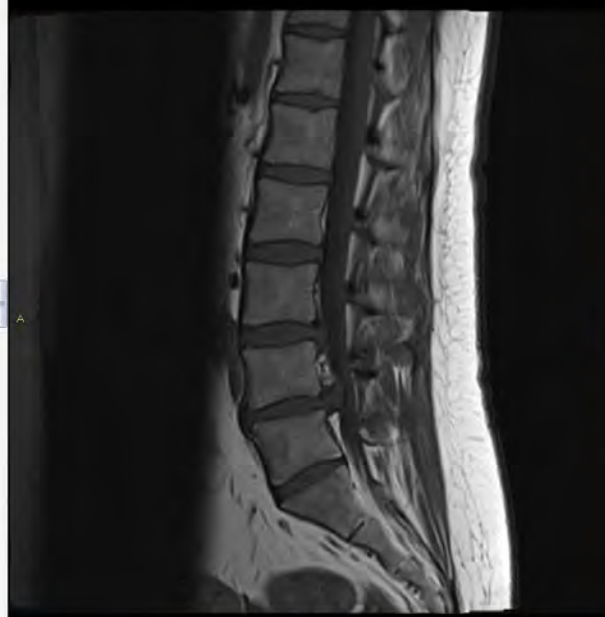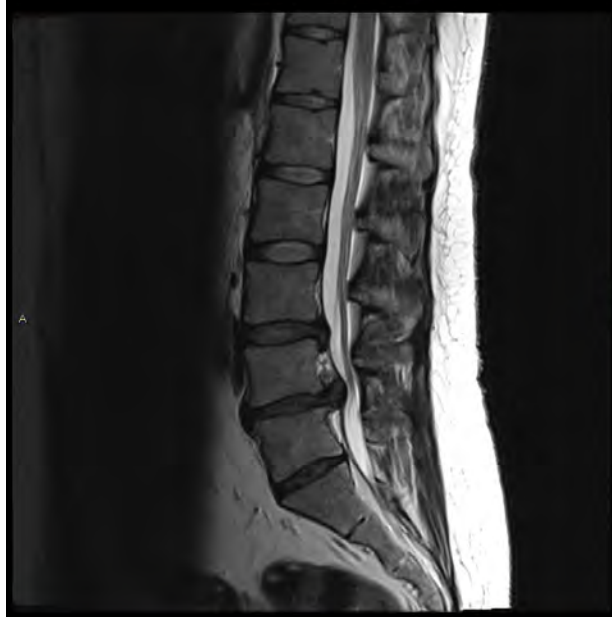# Fall 12



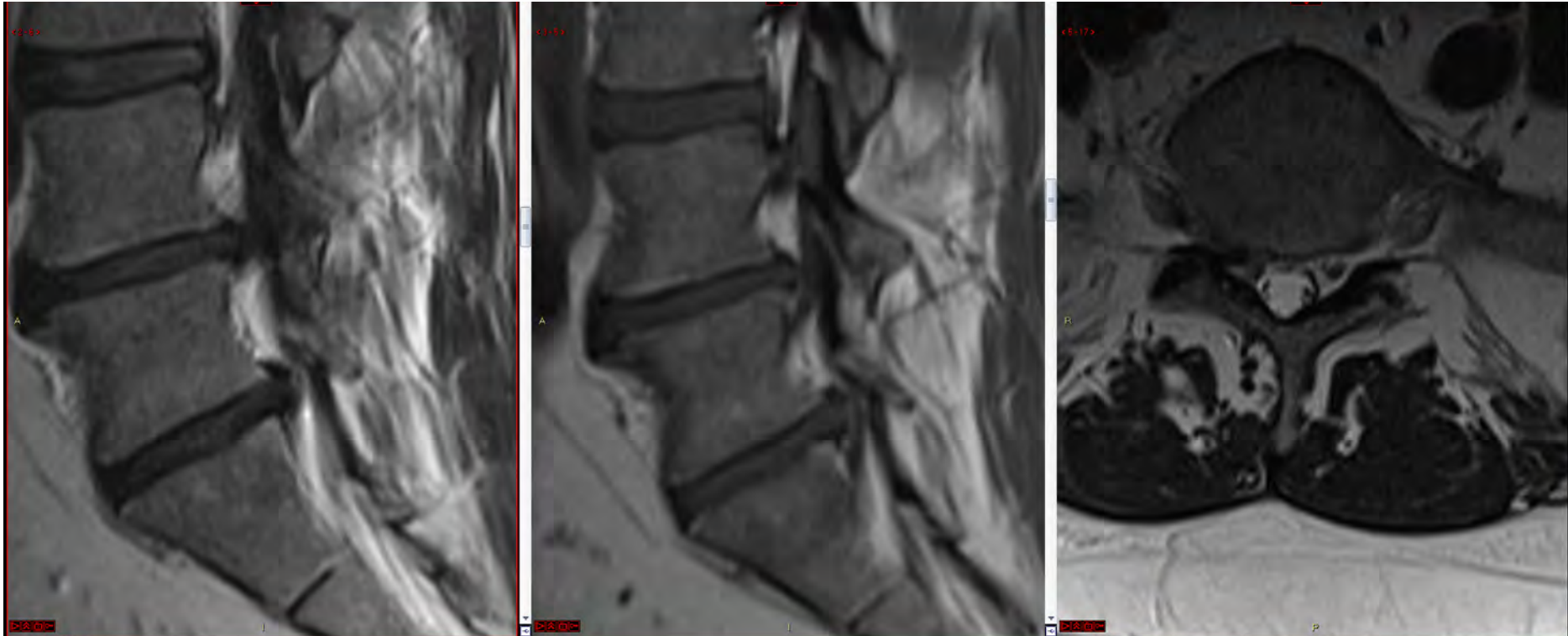
L3/4



# Fall 12



# Fall 12



Höger S1

# Fall 12

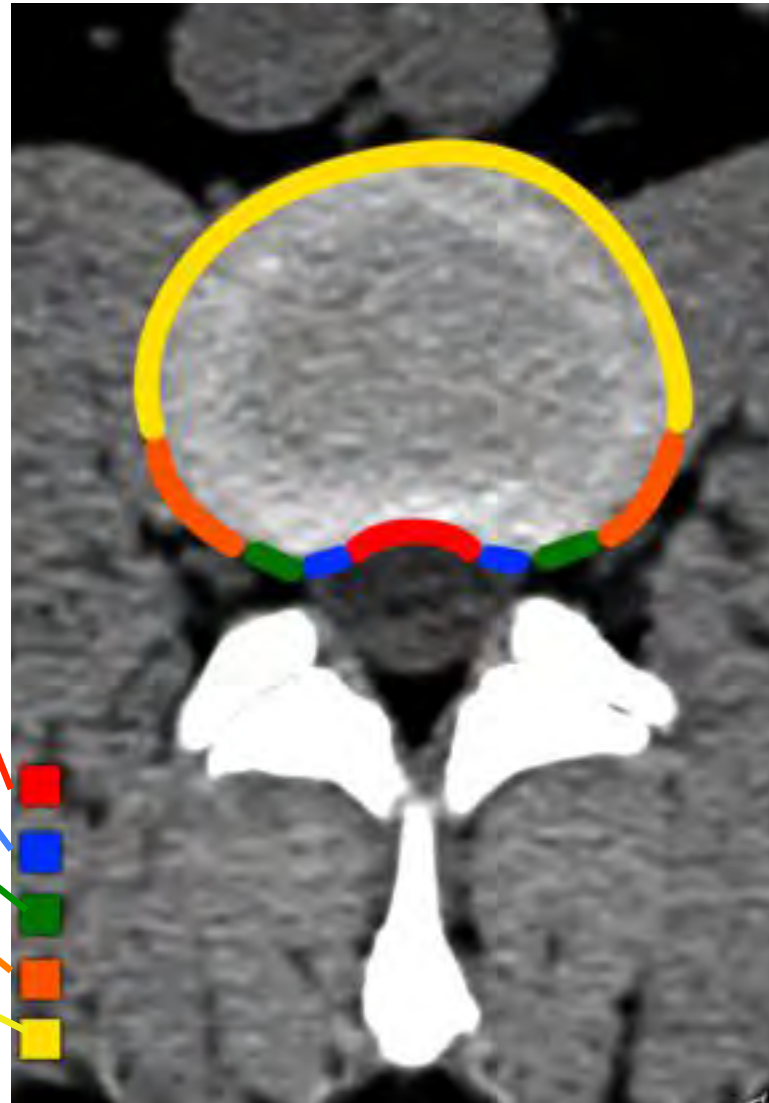
Centralt

Paramediant=lateral  
recess

Foraminalt

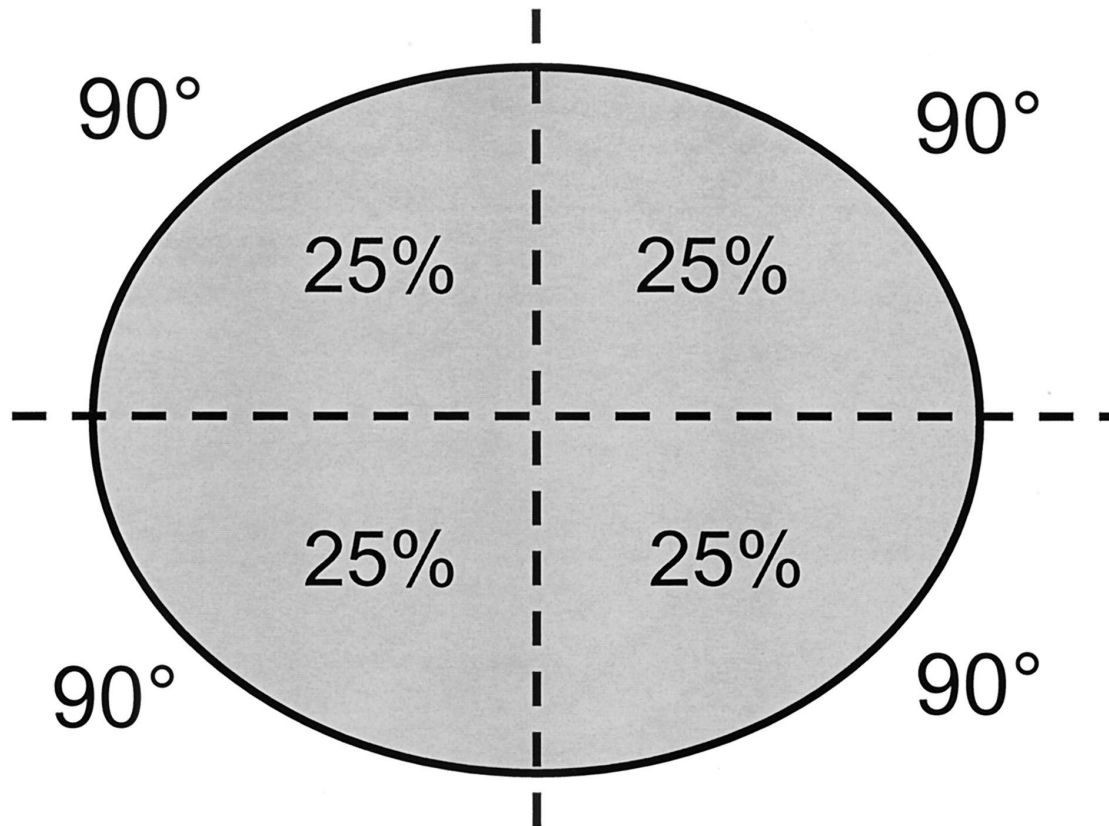
Lateral

Anterior/ventral





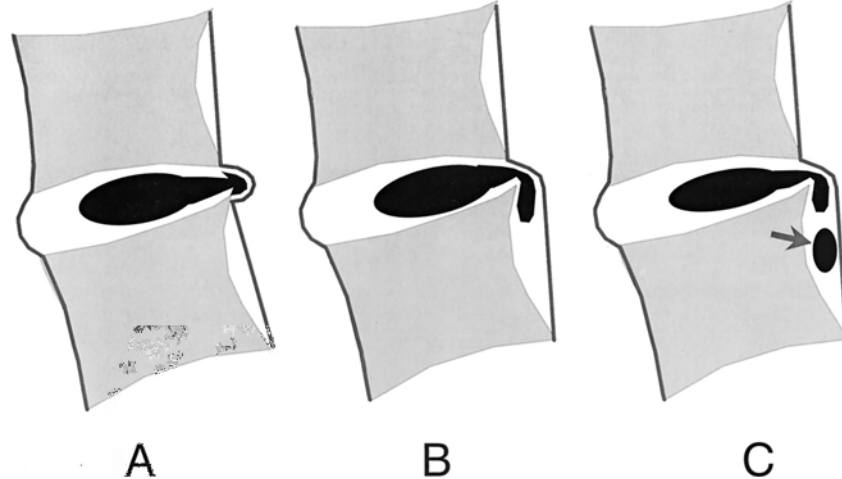

# Diskbråck



Bredbasigt  
Fokalt  
Symmetrisk/  
Koncentrisk

# Diskbråck

Protrusion  
Extrusion  
subligamentärt  
Sekvester





Fall 12